Comparative study of complications following laparoscopic TEP versus TAPP versus open hernioplasty in inguinal hernia repair

A DISSERTATION SUBMITTED TO

THE TAMILNADU DR.M.G.R MEDICAL UNIVERSITY

In partial fulfilment of the regulations for the award of the

M.S. DEGREE EXAMINATION

BRANCH I GENERAL SURGERY

DEPARTMENT OF GENERAL SURGERY

STANLEY MEDICAL COLLEGE AND HOSPITAL

THE TAMILNADU DR.M.G.R MEDICAL UNIVERSITY

CHENNAI

MAY 2018

CERTIFICATE

This is to certify that the dissertation titled **"*Comparative study of complications following laparoscopic TEP versus TAPP versus open hernioplasty in inguinal hernia repair*"** is the bonafide work done by

Dr. K.T. Sreekanth, Post Graduate student (2015 – 2018) in the Department of General Surgery, Government Stanley Medical College and Hospital, Chennai under my direct guidance and supervision, in partial fulfilment of the regulations of The Tamil Nadu Dr. M.G.R Medical University, Chennai for the award of M.S., Degree (General Surgery) Branch - I, Examination to be held in April 2018.

Prof. Dr.C.BALAMURUGAN, M.S.,
Professor of Surgery,
Dept. of General Surgery,
Stanley Medical College,
Chennai-600001.

Prof.Dr.A.K.RAJENDRAN, M.S
Professor and Head of the Department,
Dept. of General Surgery,
Stanley Medical College,
Chennai-600001.

Prof. Dr. PONNAMBALANAMASIVAYA, M.D., D.A.,

The Dean, Stanley Medical College, Chennai-600001.

DECLARATION

I, **Dr.K.T. SREEKANTH** solemnly declare that this dissertation titled ***"Comparative study of complications following laparoscopic TEP versus TAPP versus open hernioplasty in inguinal hernia repair"*** is a bonafide work done by me in the Department of General Surgery, Government Stanley Medical College and Hospital, Chennai under the guidance and supervision of my unit chief.

Prof. Dr.C. BALAMURUGAN

Professor of Surgery

This dissertation is submitted to The Tamilnadu Dr.M.G.R. Medical University, Chennai in partial fulfilment of the university regulations for the award of M.S., Degree (General Surgery) Branch - I, Examination to be held in April 2018.

Place: Chennai.

Date: October 2017

Dr.K.T. SREEKANTH

ACKNOWLEDGEMENT

My sincere thanks to **Dr. PONNAMBALANAMASIVAYA, MD., D.A.,** The Dean, Govt. Stanley Medical College for permitting me to conduct the study and use the resources of the College. I consider it a privilege to have done this study under the supervision of my beloved Professor and Head of the Department **Prof. Dr. A.K. RAJENDRAN,** who has been a source of constant inspiration and encouragement to accomplish this work.

I am highly indebted to my guide and mentor **Prof. Dr. D. NAGARAJAN,** Professor of Surgery for his constant help, inspiration and valuable advice in preparing this dissertation. I express my deepest sense of thankfulness to my present Chief **Prof. Dr. C. BALAMURUGAN**, Assistant Professors **Dr. MALARVIZHI, Dr. RAJESHWARAN, Dr. MATHUSOOTHANAN** for their valuable inputs and constant encouragement without which this dissertation could not have been completed. I also thank my previous assistant professor **Dr. JIM JEBAKUMAR** and **Dr. PONNMUTHU** for the constant support, able guidance and valuable help they rendered to me during my course.

I am extremely thankful to my patients who consented and participated to make this study possible.

TABLE OF CONTENTS

INTRODUCTION

Hernia repairs, both inguinal and ventral/incisional, are some of the most common surgeries performed in the world. Over the last 5 years, the field of hernia surgery has had a significant transformation thanks to many new and innovative surgical techniques as well as an exponential growth in mesh and mesh technology. Increased focus on hernia surgery has led to improved research and outcomes data and has provided strategies to treat both simple and complex hernias. Secondary to the increased complexity of patients and new techniques and mesh products available, there has been a renewed interest in hernia surgery amongst the general and plastic surgery community.

Inguinal hernia was repaired laparoscopically soon after the establishment of laparoscopic cholecystectomy as gold standard for cholelithiasis. However, unlike laparoscopic cholecystectomy, which was very quickly accepted by the surgical community, laparoscopic hernia repair has remained a contentious issue since its inception. The early laparoscopic techniques of plugging the internal ring with mesh or simply closing the ring with staples were surgically unsound and were quickly abandoned when early trends showed a high recurrence rate. The later technique of reinforcing the inguinal floor with a mesh placed pre-peritoneally was based on the open procedure introduced by Stoppa. It was in 1984 that Lichtenstein et al coined the term “Tension-Free Hernioplasty” and broke the convention by advocating routine use of mesh for hernia repair, thereby making tissue repair a thing of the past. The laparoscopic method of

tension-free mesh repair appeared to be gaining in popularity in the early 1990s among the enthusiasts. Early uncontrolled studies claimed that laparoscopic repair was superior to the conventional open repairs regarding postoperative pain, resumption of normal activities, and return to work, Real controversy started in 1990, when laparoscopic Tension-Free repair came in to vogue and was routinely advocated and aggressively marketed by promising less pain and shorter recovery period, but the things in the small prints were completely ignored.

The most scientific way to come to conclusion over superiority of one method over other is evidence-based medicine. Laparoscopic mesh repair cannot be compared with open tissue repair. So, the comparison should be between laparoscopic mesh repair and open mesh repairs. Few of the initial trials (Liem [1], Stoker [2], and Grant [3]) compared laparoscopic mesh repair with open tissue repair and came to conclusions, which are not valid.

Here we compare Lichtenstein tension free open hernioplasty with TEP and TAPP comparing the intra operative and early postoperative complications of the three.

AIM OF STUDY

- To compare the intra operative and early post-operative complications of laparoscopic hernioplasty TAPP versus TEP versus Lichtenstein tension free open hernioplasty.

PRIMARY OBJECTIVE

- To compare the intra operative complications of TEP vs TAPP vs open hernioplasty in terms of operative time, major visceral or vessel injury and conversion rates.
- To compare the post-operative complications of TEP vs TAPP vs open hernioplasty in terms of post-operative pain, urinary retention, wound seroma, hematoma, infection, bowel complications.

SECONDARY OBJECTIVE

- To decide which is the best method of inguinal hernia repair among the three in terms of rate of complications.

JUSTIFICATION OF STUDY

- The most scientific way to come to conclusion over superiority of one method over other is based on evidence-based medicine.
- I hereby share our experience regarding the safety of the three widely practiced methods of inguinal hernia repair to decide on the best method in terms of complication rates.

STUDY POPULATION

- All cases operated in elective theatre at Stanley Medical College were included in the study.

SAMPLE SIZE

- 75 patients (25 CASES OF OPEN HERNIOPLASTY, 25 CASES OF TAPP, 25 CASES OF TEP)

STUDY DURATION

- 10 months (NOVEMBER 2016 TO AUGUST 2017)

INCLUSION CRITERIA

- All cases of primary uncomplicated unilateral direct or indirect inguinal hernia operated in elective theatre at Stanley Medical College were included in the study.

EXCLUSION CRITERIA

- Patients who had an irreducible, obstructed or strangulated hernia.
- Patients with bilateral hernia, sliding hernia.
- Patients with recurrent hernia.

TYPE OF STUDY

- Single centre prospective study.

STUDY CENTRE

- Government Stanley Medical College.

METHODOLOGY

Method of collection of clinical sample and data

- All cases of uncomplicated primary unilateral inguinal hernia operated in Stanley medical college were considered for the study.
- Intra operative complications were seen and recorded.
- Post-operative pain was recorded based on Visual Analog Scale and requirement of analgesics.
- Post-operative complications like urinary retention, wound seroma, wound hematoma, wound infection, port site infection, recurrence, mesh

infection, bowel complication was collected with clinical examination and complications recorded.

- The total duration of hospital stay is also noted.

STATISTICAL ANALYSIS

- The collected data were analysed with IBM.SPSS statistics software 23.0 Version. To describe about the data descriptive statistics frequency analysis, percentage analysis was used for categorical variables and the mean & S.D were used for continuous variables. The Shapiro Wilk's test for normality shows the data was skewed hence to find the significant difference in the multivariate analysis the Kruskal Walli's test was and followed by the Mann-Whitney U test was used. To find the significance in categorical data Chi-Square test was used. In all the above statistical tools the probability value .05 is considered as significant level.

REVIEW OF LITERATURE

Inguinal hernia is the most common abdominal wall hernia and consequently inguinal hernia repair ranks among one of the most often performed surgical procedures [4]. It is estimated that more than 20 million groin hernia repairs are performed every year worldwide. Of these, nearly 800,000 are inguinal hernia repairs performed in the USA [4].

Epidemiologic data on inguinal hernias originate from either large-scale population-based studies or register studies revealing that the disease is multifactorial and affects individuals of all ages and both gender. As many as 30 % of the patients presenting with an inguinal hernia are asymptomatic and up to 50 % of the patients are unaware of their inguinal hernia [5]. Less than 3 % of patients diagnosed with inguinal hernia experience incarceration, if a nonoperative strategy is chosen [6]. Emergency procedures account for 5–10 % of all inguinal hernia repairs, and are almost solely performed due to incarceration [7]. In women, femoral hernias account for 15 % of elective groin hernia repair, whereas 53 % of emergency groin repairs are femoral [8]. In men, the same trend is observed, as elective femoral hernia repair makes up less than 1 % of all groin hernia repairs, compared to 7 % in an emergency setting [8]. Importantly, emergency femoral hernia repair is associated with a sevenfold increased 30-day mortality compared to the background population [8].

Different types of groin hernias exist. An indirect inguinal hernia protrudes through the deep inguinal ring lateral to the inferior epigastric vessels—often because of a patent processus vaginalis. Indirect inguinal hernias account for more than 50 % of inguinal hernias in adults. A direct inguinal hernia protrudes through a defect in the posterior wall of the inguinal canal, medial to the inferior epigastric vessels. A pantaloon or saddle bag hernia is a combined direct and indirect hernia with protrusion on both sides of the inferior epigastric vessels.

The biology of hernia formation

Hernia formation is a multifactorial process involving endogenous factors including age, gender, anatomic variations, and inheritance and exogenous factors such as smoking, comorbidity, and surgical factors [9]

The following are some of the important recent developments in research of biology of hernia formation:

- Emerging evidence suggests that inguinal hernias represent an inherited disease; however, the inheritance pattern remains to be clarified [10].
- Type I to III collagen ratio is decreased in patients with hernias resulting in thinner and weaker collagen fibres [11]
- The connective tissue alterations found in patients with hernias are pronounced in patients with direct and recurrent inguinal hernias as opposed to patients with indirect inguinal hernias. [12]

Future research on the biology of hernia formation may focus on developing serological markers enabling identification of patients at high risk of developing secondary hernias, thus opening for preventive measures such as prophylactic mesh placement after elective non-hernia surgery.

Anatomy

The inguinal region is an often discussed and seldom understood region of the abdominal wall. Ebers Papyrus wrote the earliest recorded reference to hernias in 1552 BC: “When you judge a swelling on the surface of a belly…what comes out…(is) caused by coughing” [13]. Since then the anatomy of the groin and the pathophysiology of the groin hernia has been studied and recorded by many of the greatest scholars of anatomy and surgery. Still it remains an area that is confusing even to most seasoned surgeons today.

The inguinal, or “groin” area of the human abdominal wall, is bound by the thigh inferiorly, the pubic tubercle medially, and the anterior superior iliac spine (ASIS) superolateraly. The “watershed” area of weakness of the inguinal region is the acquired inguinal canal. The inguinal canal is an oblique passage connecting the peritoneal surface of the abdomen to the scrotum or, in females, the labia majoris. It is bound by a pair of openings called the deep (or posterior) inguinal ring and the superficial inguinal ring anterior and external to the abdominal cavity. The inguinal rings are thought to overlie each other at birth and separate in a superolateral to inferomedial orientation by adulthood. In the

average adult, the inguinal canal is 4–5 cm long. The structure central to the anatomy and repair of this region is the inguinal ligament, otherwise known as the Poupart ligament, which is formed from the external oblique aponeurosis as it folds over and inserts from the ASIS to the pubic tubercle.

The Layers of the Lower Anterior Body Wall in the Inguinal Region (Adapted from Skandalakis)

1. Skin.
2. Subcutaneous tissue or superficial fasciae (Camper's and Scarpa's) containing fat.
3. Innominate fascia (of Gallaudet). This is the superficial or external layer of fascia of the external oblique muscle. It is not always recognizable and its absence is of no surgical importance.
4. External oblique aponeurosis, including the inguinal (Pourpart's), lacunar (Gimberat's), and reflected inguinal (Colles') ligaments.
5. Spermatic cord in the male; round ligament in the female.
6. Transversus abdominis muscle and aponeurosis, internal oblique muscle, falx inguinalis (Henle), and the conjoined tendon (when present).
7. Transversalis fascia and aponeurosis associated with the pectineal ligament (Cooper's), the iliopubic tract, falx inguinalis, and transversalis fascia sling.
8. Preperitoneal connective tissue with fat.
9. Peritoneum.
10. Superficial and deep inguinal rings.

The inguinal canal is bordered by two openings: the deep (internal) inguinal ring and the superficial (external) inguinal ring. The boundaries of the canal are as follows:

• Posterior wall (floor)—Formed laterally by the aponeurosis of the transversus abdominis muscle and the transversalis fascia laterally in three-fourths of subjects; in a quarter of subjects, the posterior wall is formed by the transversalis fascia only. Medially, the posterior wall is formed by the internal oblique aponeurosis or conjoint tendon.

• Anterior wall—Internal oblique muscle laterally and aponeurosis of external oblique muscle. There are no external oblique fibres in the inguinal area; only aponeurotic fibres.

• Superior (Roof)—formed by the lower edge of the internal oblique muscle and transversus abdominis muscle and aponeurosis.

• Floor—Inguinal (Poupart's) ligament and medially by the lacunar (Gimbernat's) ligament.

The superolateral margin of the inguinal canal is the internal (deep) inguinal ring. It is formed as a defect of the transversalis fascia. The external (superficial) inguinal ring, which forms the inferomedial margin, is an opening in the aponeurosis of the external oblique muscle.

The male inguinal canal contains several structures of importance:

• The ilioinguinal nerve which enters the abdominal wall by piercing the posterior surface of the transversus abdominis just above and medial to the anterior superior iliac spine. It extends into the inguinal canal between the external and internal obliques. In the canal, it can be found traveling along the inferior aspect of the spermatic cord. Care must be taken to identify and protect this nerve during anterior hernia repairs as it can often be entrapped in mesh causing hyperesthesia or hypoesthesia of the skin of the upper medial thigh, scrotum, penis, or labia majora.

• The spermatic cord which contains structures that pass from the deep to superficial inguinal rings. The cord is bound by coverings that are extensions of the layers of the anterior abdominal wall. The structures contained within the spermatic cord are as follows:

- The ductus deferens
- Three arteries
    - The testicular artery
    - The deferential artery
    - The cremasteric artery
- A venous (pampiniform) plexus
- Three nerves
    - Genital branch of the genitofemoral nerve
    - Ilioinguinal nerve

- Sympathetic fibres from the hypogastric plexus

■ Three layers of fascia

- The external spermatic fascia
- The middle, or cremasteric layer, continuous with the internal oblique muscle and fascia
- The internal spermatic fascia, an extension of the transversalis fascia

As described by Hesslelbach in 1814, the base of the triangle was formed by the pubic pectin and the pectineal ligament. The boundaries of this triangle as usually described today are.

• Superolateral: The inferior (deep) epigastric vessels

• Medial: The rectus lateral border of the rectus sheath

• Inferior: The inguinal ligament

Most direct inguinal hernias occur in this area.

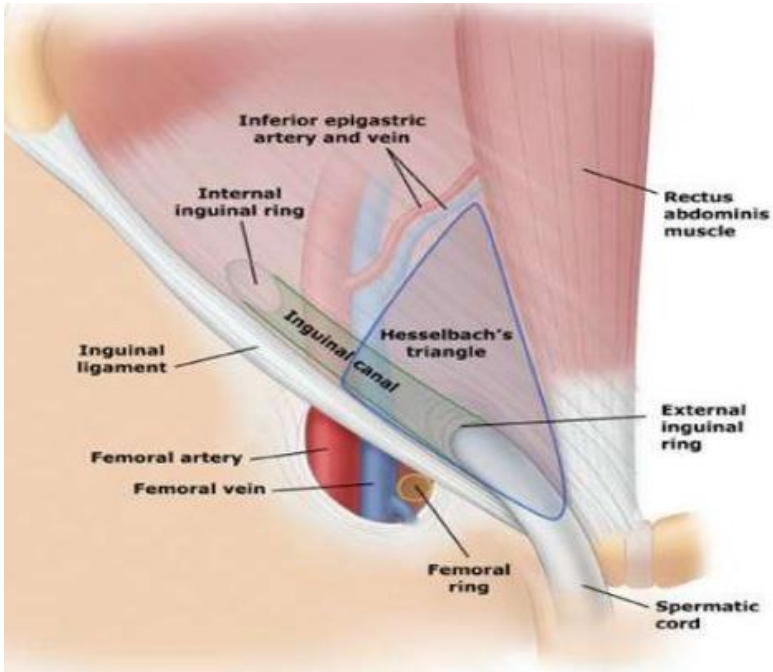

TECHNIQUES IN HERNIA REPAIR

The ancient history of inguinal hernia is remarkable with many creative but mostly futile approaches to its treatment. One illustrated and informative resource for the work and workers of that era are the early chapters in Hernia Healers by Stoppa et al. [14,15].

The modern era of inguinal hernia repair began with the works of Bassini [16]. He recognized that the transversalis fascia was the Achilles tendon of the groin, the layer through which hernias develop. He proffered that to correctly repair an inguinal hernia the groin must be dissected layer by layer knowledgably and carefully from the skin into the preperitoneal space. Only then could the muscles, fascial elements, vessels, nerves and vassal structures be identified and preserved. His reconstruction began with the posterior wall opened. After checking for a femoral hernia, he dissected the peritoneal sac to its true neck and ligated it there. He then used a three-layered interrupted suture repair to reconstruct the canal's posterior wall. His deepest suture line included the lateral edge of the rectus muscle, the internal oblique muscle, the tranversus abdominus muscle, and the medial edge of the transversalis fascia. He approximated that four-layer composite to the lateral edge of the transversalis fascia and the inguinal ligament. He replaced the spermatic cord in its normal position and sutured the external oblique aponeurosis to comfortably re-create the obliquity of the canal and the external inguinal ring. In his earlier operations, starting in 1844, Bassini insisted his patients be awakened enough

from anaesthesia to perform straining motions to prove that his repair was sound. Bassini's results for inguinal hernia repair was astounding compared to the poor results of other surgeons of his time. With 90 % personal follow-up of 262 cases over 4 years, his failure rate was less than 3 %. He eventually reported this in a paper entitled, *Nuovo metodo operativo per la cura dell'ernia inguinale*. While some have noted that Bassini never specifically wrote about the importance of opening the posterior wall, illustrations by his devoted pupil, Catterina, clearly showed that he did open it and that he had described doing so in his own paper, *Bassini's operation for the radical cure of inguinal hernia* [17]. Bassini's true repair was altered and became known as the Modified Bassini Repair/North American Bassini Repair as was its impressive results. Many North American surgeons, influenced by Andrews, did not appreciate the importance of completely reconstructing the canal's posterior wall. Most simply ligated the peritoneal sac and pulled the transversus arch to the inguinal ligament, frequently under enough tension that a relaxing incision was needed. The short- and long-term result of the Modified Bassini repair was not good. Most failures could be traced to the inability of tissues pulled together under tension to withstand normal intraabdominal forces associated with ordinary bodily functions.

In the early part of the twentieth century several other suturing techniques were used to approximate the internal oblique and transversus abdominus muscle, with or without the medial flap of the external oblique, to the shelving

edge of the inguinal ligament. The “Darn” technique was popular in the UK, Europe and the Far East [18]. Continuous single or double strands of nylon or silk suture that bridged the canal created a mesh-like structure. This technique never gained much interest with American surgeons.

E.E. Shouldice, a Canadian surgeon, revitalized Bassini’s original principals of inguinal hernia repair [19]. Using a local anaesthetic Shouldice dissected the structures of the groin including opening the posterior wall into the preperitoneal

space. Differing from Bassini’s interrupted suture technique, Shouldice used continuous 34-gauge stainless steel wire to reconstruct the posterior wall and repair the hernia. The results of many-thousand repairs at the Shouldice hospital are impressive. Shouldice championed using local anaesthesia and insisted on patients ambulating early. His detailed dissection through the double layers of transversalis fascia, along with the contributions of Rives and Stoppa of France and Nyhus and Condon in the USA and the earlier work of Henry and Cheatle helped set the stage for the eventuality of posterior repairs.

In 1958, Usher of Texas introduced Marlex mesh in the form of a polyethylene patch to fill tissue defects. He wrote, “by suturing it to the edge of the defect in the preperitoneal space it did a ‘tension-eliminating’ repair” [20]. When polyethylene was found unstable to sterilizing temperatures the polymer product was altered to polypropylene. Usher’s work was revolutionary as it introduced a reproducible synthetic barrier to block the hernia defect. Polypropylene in

various forms and weights has remained the mainstay of many forms of mesh products. Mesh penetration into the hernia market was not immediate. Initially it was used infrequently and only in cases of complex and unusually challenging hernias that had recurred multiple times. From the author's personal observation of polls taken in different years at the five hernia conferences, *Advances and Improvements in Hernia Surgery, mesh gradually became part of most surgeon's* armamentarium.

In 1984 mesh was used in less than 5 % of operations, by 1987 it rose to about 10 % and by 1989 it reached about 15 %. Brewing at the 1991 meeting, and clear by the 1993 meeting was that mesh was accepted and essential for all laparoscopic repairs and it had gained acceptance for most open hernia repairs as well. In countries where laparoscopic techniques lagged in acceptance the use of mesh for open repairs also was slow.

In France, Rives used nylon mesh, and Stoppa used polyester mesh to do preperitoneal inguinal hernia repairs [21]. Their operation was known as *Giant Reinforcement of the Visceral Sac* (*GPRVS*). Colleagues saw the technique applicable for very challenging hernias but the technique was considered difficult and reserved it as a tool mostly for surgeons experienced using it. It was Wantz who brought that operation to America and helped it to gain interest to be used in operations to repair multiple time bilateral recurrent inguinal hernias and giant scrotal hernias.

It was Lichtenstein of California who was the strongest and most vocal advocate for the use of Marlex in hernia repairs. He used a local anaesthetic and initially did a tissue repair approximating the conjoined tendon to the shelving portion of the inguinal ligament. He then reinforced that repair with a patch of Marlex mesh that he sutured above the tissue suture-line. Initially he based his repairs on the part played by Marlex as an adjunct to reinforce his tissue repair [22]. In 1984, Newman of New Jersey, after meeting Lichtenstein in Miami Beach at the 1984 conference, encouraged him to use his Marlex tension-sparing repair. Additionally, Newman gave Lichtenstein permission to call the operation the "Lichtenstein Tension-free Inguinal Hernia Repair". Lichtenstein clearly deserves credit and kudos for popularizing the "tension-free" concept that now pertains in every technique of inguinal hernia repair, regardless of the approach to the hernia defect or the type of barrier used. Shouldice and Lichtenstein both showed that most open hernia operations could be done under local anaesthesia, that patients could ambulate immediately and return to usual activities much sooner that was typical for those times. Ralph Ger in New York in 1982, viewing the deep inguinal ring in 15 dogs through a peritoneoscope, used Kocher clamps to apply Michele staple clips to the neck of the peritoneal sac [23]. Ger's work was interesting but it did not create much clinical interest. In June of 1988, McKernin and Saye in Marietta, GA, and Reddick and Olson in Nashville, TN, successfully removed gall bladders laparoscopically in

humans [24]. Though surgeons in Europe, including Muhe (1987) in Germany, and Mouret (1988) and Dubois (1988) in France, had done laparoscopic cholecystectomy, none stimulated the amount of interest in this new approach, as did these American surgeons. It was their work that proved revolutionary and opened the world's surgical community and its supportive industries to further explore and to teach the numerous possibilities of laparoscopic surgery. Three basic approaches to laparoscopic groin hernia have evolved: the intraperitoneal on lay mesh (IPOM), the transabdominal preperitoneal inguinal hernia repair (TAPP), and the transabdominal extraperitoneal inguinal hernia repair (TEP).

Robotic techniques are being explored for hernia repair.

LICHTENSTEIN TENSION FREE HERNIOPLASTY

The Lichtenstein technique avoids the hazard of suture line tension by placing mesh between the transversalis fascia and the external oblique aponeurosis, where it reinforces the entire inguinal floor. While increased intra-abdominal pressure (such as that associated with straining) results in increased tension on the suture line of a tissue-based repair, this is not the case with the Lichtenstein hernioplasty. As pressure increases and the external oblique muscle contracts, the external oblique aponeurosis applies counter pressure on the mesh, allowing for excellent durability even under high intra-abdominal pressures [25]. Accordingly, the Lichtenstein tension-free hernioplasty both addresses the

present herniation and protects the inguinal floor against future mechanical stresses.

Preoperative Management

Patients are screened for hernia type and comorbidity. Risk stratification and medical optimization are undertaken prior to elective hernia repair for patients of advanced age or those with medical comorbidities. Smoking cessation is encouraged and glycaemic control in diabetics is optimized. They are instructed that shaving of the groin or abdomen should be avoided in the preoperative period, as resulting microtraumas may increase the infectious risk of the operation.

Operative Technique

Positioning and Preparation

The operation is performed with the patient in the supine position. Skin preparation with an antiseptic solution is performed, extending from superior to the umbilicus to the scrotum inferiorly. The scrotum should be included in the operative field if a large inguinoscrotal hernia is present. Perioperative antibiotics are not required for clean, elective cases.

Anaesthesia and Sedation

Lichtenstein hernia repair can be safely and comfortably performed under local anaesthesia. If the hernias are not reducible, general anaesthesia or epidural anaesthesia is preferred in addition to local infiltration of anaesthetics. As an adjunct to local or epidural anaesthesia, light sedation using short-acting

anxiolytic and amnestic medications (e.g., midazolam, propofol) along with analgesic medications may serve the reduce anxiety and decrease the required volume of local anaesthetic mixture.

Immersing the canal in 10 mL of the anaesthetic mixture prior to closure of the external oblique aponeurosis may improve the duration of local anaesthesia and minimize immediate postoperative discomfort.

Operative Steps

After skin preparation, the planned line of incision is marked. The skin incision starts from the pubic tubercle and extends 5–6 cm laterally, following the Langer line. This position and orientation provides exposure from the pubic tubercle to the internal ring.

The skin is then incised and the subcutaneous tissues are divided. The external oblique aponeurosis is divided over the course of the entire inguinal floor, starting from the external ring to and proceeding superiorly. The upper leaf of the aponeurosis is separated from the internal oblique muscle, and the lower leaf is separated from the spermatic cord structures.

These steps provide exposure of the entire inguinal floor and the field into which the mesh prosthesis will be placed. The internal oblique aponeurosis should be exposed at least 3 cm superior to the upper margin of the inguinal floor to ensure adequate overlap with the mesh. Now the ilioinguinal and iliohypogastric nerves are exposed and should be identified so that subsequent injury or entrapment can be avoided. The ilioinguinal nerve will originate medial to the anterior superior

iliac spine and then typically courses over the cord structures to exit the external ring. The iliohypogastric pierces the internal oblique medially and will then proceed caudally and medially to exit the canal at the conjoined tendon. There is considerable neuroanatomic variation of these nerves and identification is key to determine preservation versus pragmatic division.

The spermatic cord is next separated from the inguinal floor and pubic tubercle, continuing approximately 2 cm inferiorly past the tubercle. This is performed atraumatically with a gauze peanut dissector, lifting the structures off the floor and tubercle from the inguinal ligament, preventing trauma to the cremasteric bundle and its contents.

A Penrose drain may be passed around the cord and used to retract it away from the inguinal floor if necessary at any time during dissection and mesh placement.

Now, the genital branch of the genitofemoral nerve is identified coursing alongside the more easily visible external spermatic vein, which appears as a blue streak lateral and posterior within the cord.

All three major nerves should be preserved during dissection. If a nerve is noted to be injured or transected during the operation, it is our practice to ligate the nerve ending and to bury it in the muscle belly to avoid neuroma formation and minimize development of neuropathic pain (known as a “pragmatic neurectomy”).

The cremaster muscles which for the outer covering of the spermatic cord are divided longitudinally near the deep inguinal ring, and the cord is explored to

determine whether an indirect hernia sac is present. Complete removal or transection of the cremasteric fibres is not recommended as it results in increased risk of exposure of cord structures to mesh, increasing risk of nerve injury and chronic pain. If present, the indirect hernia sac is dissected away from cord structures until the neck of the sac is freed. The sac is then inverted into the pre-peritoneal space.

Ligation of the sac is not necessary, does not affect recurrence rate, and increases risk of postoperative pain. In the case of a large non-sliding hernia extending into the scrotum, the sac is transected at a midpoint in the canal and the distal section is left in place. The anterior wall of the distal sac should be incised to prevent hydrocele formation, but does not need to be dissected free and removed, as this increases the risk of injury to testicular vessels and testicular atrophy or loss.

If a direct hernia is observed and a large sac is present, it may be inverted to allow for adequate positioning and contact of the mesh. This closure should not be performed under tension and approximates only the transversalis fascia. A narrow-necked direct hernia may be imbricated and closed with an absorbable purse string suture. A broad-based direct hernia can be imbricated with a running suture along the floor approximating the transversalis fascia along the length of the defect.

A small opening in the inguinal floor through the transversalis fascia or an opening in the hernia sac is used to interrogate the femoral canal. (The presence

of a coexisting femoral hernia may be addressed by extending the subsequent mesh fixation to Cooper's ligament.)

A 7.5 × 15 cm mesh sheet is tailored to the shape of the myopectineal orifice as described above. The mesh is first affixed at its apex to the pubic tubercle using a nonabsorbable, monofilament suture. Suturing through the periosteum of the bone increases postoperative pain and should be avoided. The mesh should overlap the tubercle inferiorly by

1–2 cm. Failure to adequately cover and overlap the pubic bone with the mesh may result in recurrence of the hernia as the mesh contracts. Once the initial stitch has been placed at the pubic tubercle, the same running stitch. The suture is continued up to a point lateral to the deep inguinal ring, as going any further risks injury to the lateral femoral cutaneous nerve.

A slit is cut along the long dimension of the mesh starting from the lateral end. This creates two tails; the superior tail should be approximately twice as wide as the inferior tail. The wider tail is passed medially and superiorly under the spermatic cord using forceps. The spermatic cord is now positioned between the two tails of the mesh. The two mesh tails are then crossed with the wider, superior tail on top, and are held in place with a clamp.

The spermatic cord is then retracted downward while the upper leaf of the external oblique aponeurosis is retracted upward, exposing the lateral edge of the rectus sheath and the internal oblique aponeurosis. When possible, the course of the iliohypogastric nerve should be identified as medial fixation places it at risk.

The superior border of the mesh is sutured to the aponeurotic portion the internal oblique adjacent to the conjoined tendon using absorbable suture in an interrupted fashion to minimize injury to the iliohypogastric nerve. These sutures should proceed superiorly to a point just medial to the internal inguinal ring. Care should again be taken in identification and avoidance of the iliohypogastric nerve which may run a sub-aponeurotic course at this level, and the mesh should not be entrapment of the intramuscular portion of the iliohypogastric nerve.

Avoidance of overtightening stitches may also reduce the likelihood of nerve injury. Finally, a single stitch of nonabsorbable monofilament suture is used to affix both the inferior edges of both mesh tails to the inguinal ligament just lateral to where the lower running suture ends. The tails should be pulled sufficiently tight to recreate the mesh internal ring while allowing for passage of the spermatic cord. A general rule is that the recreated ring should allow for passage of the tip of a haemostat, but should not be so loose as to allow passage of a finger.

The lateral mesh tails should extend at least 5 cm beyond the recreated internal ring, but any excess mesh beyond this distance may be trimmed and the corners of the tails rounded. The tails are then tucked underneath the external oblique aponeurosis, and the external oblique is closed over the cord and mesh with an absorbable suture. Care should be taken not to constrict the cord vessels at the new external inguinal ring created by this closure.

Scarpa's fascia and subcutaneous tissues are closed using absorbable suture in an interrupted fashion. Skin closure is achieved with an absorbable subcuticular suture or staples.

In 2014, the European Hernia Society (EHS) published updated consensus guidelines on the treatment of inguinal hernia in adults [21]. Based on data from the latest randomized controlled trials (RCTs), the use of the Lichtenstein tension-free hernioplasty for repair of primary, unilateral, symptomatic inguinal hernias is supported by the highest level of evidence (1A) and the highest grade of recommendation (A). This technique is considered superior to the Bassini and Shouldice methods of tissue repair.

The Lichtenstein tension-free hernioplasty has evolved over the past 20 years to produce optimal patient outcomes. The technique has the benefits of being low cost and rapidly learned, and can be performed under local anaesthesia. It compares equivalently or favourably to other repair technique methods in terms of recurrence, postoperative pain, chronic pain, and other complications. The Lichtenstein repair remains the operation of choice for repair of initial, unilateral inguinal hernias and in patients wishing to avoid the risks of general anaesthesia.

TAPP (Total Abdominal PrePeritoneal Hernioplasty)

The origin of the TAPP repair dates back to the early 1990s and was born out of the developing interest in preperitoneal approaches to the repair of inguinal hernias. In Europe, Rives and Stoppa developed the concept of preperitoneal

reinforcement of the myopectineal orifice using prosthetic mesh [22]. Over the next decade as laparoscopic approaches to general surgical problems began to take off, some early laparoscopic enthusiasts began to take interest in the laparoscopic repair of inguinal hernias. Arregui and colleagues published their early experience of a laparoscopic transabdominal approach to inguinal hernias with good results [27].

In Canada and Europe, early adopters of the TAPP approach also began publishing their results with excellent outcomes in the early to mid-1990s [28–31]. Leibl and colleagues compared the TAPP approach (n = 48) to the Shouldice repair (n = 43) and found a decrease in postoperative pain and earlier return to normal activities in the TAPP group. At 16 months of follow-up there were no recurrences noted in either group. At 6 years follow-up, the rates of recurrence were 2 % in the TAPP group (1/48) and 5 % in the Shouldice group (2/43) [31]. While TAPP is now a widely accepted repair technique, laparoscopy is utilized in a minority of inguinal hernia repairs worldwide. Trevisonno and colleagues found that laparoscopy was used in only 8 % of all laparoscopic inguinal hernia repairs and only 28 % of bilateral inguinal hernia repairs where its indication is more widely accepted [32].

The underutilization of laparoscopic inguinal hernia repair is multifactorial. Seventy percent of surveyed surgeons who don’t perform laparoscopic inguinal hernia repair state that they consider the benefits of laparoscopy to be minimal and 59 % feel that they lack the requisite training to perform the procedure [33].

Preoperative

All patients are seen and evaluated in clinic prior to surgical intervention. An in-depth history and physical exam is performed paying significant attention to any previous groin surgeries or prostatic interventions. Both groins are inspected for the presence of hernias with manual examination. In patients with a history suspicious for inguinal hernia but no physical exam findings, an ultrasound is obtained to assess for occult hernias. Those with symptomatic hernias are offered repair and counselled extensively about the perioperative and long-term risks of repair including bleeding, infection, recurrence, and inguinodynia.

Operative technique

The patient is laid supine on the operating room table with both arms tucked. In cases of unilateral inguinal hernias, the contralateral arm may be tucked with the ipsilateral arm left at 90°. However, if an occult hernia is found on the contralateral side intraoperatively it will make the repair of the contralateral side more difficult, thus we prefer to routinely tuck both sides. All patients must void prior to moving to the operating room and thus we do not routinely place Foley catheters. Patients with a history of urinary retention or benign prostatic hypertrophy will undergo placement of a Foley catheter for bladder decompression once they have been placed under general anaesthesia. Sequential compression devices are placed on both lower extremities for prophylaxis against deep venous thrombosis but due to the relatively short length of case time subcutaneous heparin is not administered. Hair on the

abdomen is clipped for a relatively small area surrounding the umbilicus, but the groins are not routinely clipped of hair. The abdomen is then prepped and draped.

Pneumoperitoneum is obtained using a Hasson open technique via a 1.2 cm infraumbilical incision. A 12 mm Hasson port is placed and secured to the anterior fascia using an 0 vicryl suture which will be used for fascial closure at the completion of the case. If there is a concomitant umbilical hernia present then the defect is utilized for port placement and a formal repair is performed utilizing 0 PDS suture at the completion of the case. Larger umbilical defects (greater than 2 cm) will also be reinforced with mesh during the repair. The abdomen is insufflated to a pressure of 15 mmHg and the patient is then placed in steep Trendelenburg to improve visualization of the groin. Both groins are then inspected for the presence or absence of hernias. Two additional 5 mm ports are then placed at the level of the umbilicus in the right and left midclavicular lines. A 30° 5 mm laparoscope is then moved to the 5mm port on the ipsilateral side of the hernia so that the operating surgeon can improve their ergonomics by utilizing the contralateral 5 mm port and the umbilical port for the procedure. A generous peritoneal incision is then made from the medial umbilical fold out laterally cephalad to the myopectineal orifice. As the incision is carried laterally it can be arced posteriorly towards the psoas muscle. The dissection then begins laterally on the inferior peritoneal flap. Ample working space is created by mobilizing the peritoneum off the preperitoneal fat. The

peritoneum is grasped through the instrument in the lateral port and retracted towards the contralateral side. The instrument in the umbilical port is used to push the preperitoneal fat laterally off the underlying peritoneum.

In male patients, the gonadal vessels will be the first structures of importance that are identified and these are pushed laterally off the peritoneum utilizing the umbilical port. As the dissection is carried towards the internal ring the vas deferens will be identified medial to the gonadal vessels. The vas is also mobilized off the peritoneum and hernia sac and pushed laterally. Once both the vas deferens and the gonadal vessels are mobilized off the peritoneum we transiently stop our dissection of the indirect space and move to the medial dissection. In female patients, the round ligament of the uterus is generally quite adherent to the peritoneum and attempts to mobilize the round ligament off the peritoneum will generally result in a tear of the peritoneum. Thus, we prefer to clip and divide the round ligament in nearly all patients.

We then move to the direct space to mobilize the bladder in the space of Retzius. The inferior peritoneal flap is grasped with the lateral instrument medial to the inferior epigastric vessels. The flap is retracted posteriorly and the medial instrument is used to bluntly spread through the preperitoneal fat until the rectus abdominis muscle is identified. Both instruments are then placed through this area towards the bony pelvis. The lateral instrument is used to mobilize the bladder posteriorly and is held in place while the medial

instrument sweeps the bladder off the bony pelvis towards the contralateral side. These two manoeuvres should allow for excellent bladder mobilization and visualization of Cooper's ligament on both the ipsilateral and contralateral side. At this point in the procedure all three potential hernia spaces of the myopectineal orifice are now ready for exploration. For indirect hernias, the sac is grasped with the lateral instrument and retracted medially. The instrument through the umbilical port is then used to push the vas deferens and gonadal vessels laterally off the hernia sac until the sac is completely reduced. In large inguinoscrotal hernias, the hernia sac can be divided leaving the distal portion open in the scrotum and the more proximal portion will be closed during re-peritonealisation at the end of the procedure. The indirect space should always be assessed for the presence of cord lipomas as failure to reduce a cord lipoma is a common cause of recurrence following laparoscopic repair of inguinal hernias. For direct hernias, the transversalis fascia is identified as an inverted white structure medial to the epigastric vessels. The transversalis is mobilized anteriorly off the underlying preperitoneal fat until Cooper's ligament and the epigastric vessels are easily identified. Lastly, the femoral space is explored between the iliopubic tract and Cooper's ligament medial to the iliac vessels. Any preperitoneal fat herniating through this space is reduced. Once all the myopectineal orifice has been explored and all hernia contents and sacs have been reduced, a groove is created between the peritoneum and bladder medially and the psoas, gonadal vessels, vas deferens, iliac vessels, and bony pelvis

laterally to ensure adequate inferior mesh coverage. Finally, the cephalad peritoneal flap is mobilized so that it hangs down off the abdominal wall to facilitate peritoneal closure following mesh placement. Mesh is then brought into the field through the umbilical port and positioned to cover the entire myopectineal orifice with wide overlap in all directions. There are a wide variety of mesh options available for use. As the mesh will reside in the preperitoneal space barrier coated meshes are not necessary. There are also a variety of options for mesh fixation including self-gripping meshes, fibrin glue, permanent or absorbable tack fixation, or no fixation whatsoever. If tack fixation is planned care must be taken not to place any tacks into the major vascular structures within the field or the lateral femoral cutaneous and genitofemoral nerves which run through the field inferior to the iliopubic tract laterally. Care must also be taken not to tack within the area of the inguinal canal as the iliohypogastric, ilioinguinal, and genital branch of the genitofemoral nerve can all be injured anteriorly to transversalis fascia in this location. In general, safe areas for tack fixation include Cooper's ligament and the rectus abdominis muscle medially and the abdominal wall superior to the iliopubic tract laterally. Once the mesh is in position then the peritoneum should be closed to avoid exposure of the mesh to the viscera. There are a variety of methods available for peritoneal closure including suture, tacks, and clips. We prefer a running continuous barbed suture closure, which is run from lateral to medial. After peritoneal closure the bed is returned to its normal position and

the abdomen is desufflated under direct visualization. The fascia of the umbilical port is closed with interrupted 0-Vicryl sutures and skin sites are closed with 4-0 subcuticular Monocryl and covered with dry sterile dressings. If a Foley catheter was placed it is now removed, and the patient is then awoken from general anaesthesia and transferred to the recovery room.

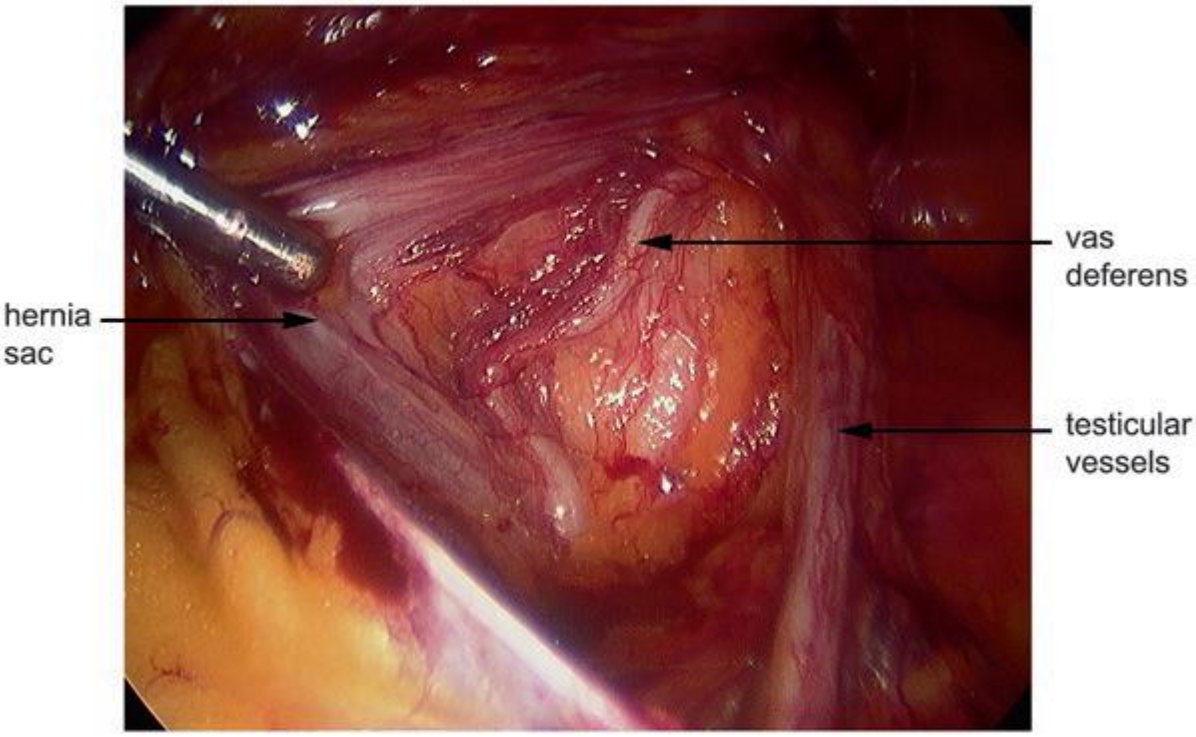

TAPP Versus TEP

Muschalla and colleagues recently reported their long-term outcomes with the TAPP procedure. Between January of 2000 and January of 2001 they performed 1208 inguinal hernia repairs in 952 patients. Ninety-eight percent of these repairs were performed with the laparoscopic TAPP technique. With 85.3 % follow-up at 5 years, they found a recurrence rate of 0.4 % and 0.59 % rate of severe chronic pain [34]. These long-term results support the recommendations

of the European Hernia Society Guidelines regarding the treatment of symptomatic unilateral inguinal hernias. They state that the best evidence supports a mesh-based repair utilizing either an open Lichtenstein technique or an endoscopic technique if sufficient expertise in this area is available [35]. Despite these recommendations, there still remains some debate about the best endoscopic method for repair, TAPP versus Totally Extraperitoneal (TEP).

The European Hernia Society has reviewed the literature regarding the differences in both technique and outcomes between TAPP and TEP. They found that both techniques have their own technical differences and each has its own advantages and disadvantages. Overall, however, there are no statistically significant differences in long-term outcomes, including both recurrences and chronic pain, between TAPP and TEP. The authors noted that TAPP may be associated with a slightly decreased learning curve but there is no strong evidence to support this belief [36].

Since the publication of these guidelines several other studies comparing TAPP and TEP have been released. Bansal and colleagues assessed the differences in long-term rates of chronic groin pain and quality of life following TAPP or TEP [37]. With respect to pain, they found that the TAPP repair was associated with higher rates of acute pain but no significant differences in chronic pain between the two techniques. There were improvements in quality of life for both from the perioperative period to the postoperative period noted with both techniques but no significant differences in quality of life between TAPP and TEP.

Additionally, costs were comparable between the two techniques [37]. Köckerling and colleagues reviewed the outcomes of 17,587 patients who underwent laparoscopic inguinal hernia repair in a large prospectively enrolled hernia registry [38]. 10,887 (61.9 %) underwent TAPP and 6700 (38.1 %) were repaired with the TEP technique. On both univariate and multivariable analysis, surgical technique was not associated with differences in intraoperative or general postoperative complications. TAPP was associated with higher rates of postoperative surgical complications but this did not lead to a difference in reoperation rate between the two techniques. Overall, they noted no significant differences between the two techniques [38]. In general, the differences between TAPP and TEP are largely technical and do not lead to significant differences in long-term outcomes. Surgeons comfortable with both techniques should choose which to offer to appropriate patients.

TOTALLY EXTRAPERITONEAL HERNIA REPAIR (TEP)

Totally extraperitoneal hernia repair (TEP) is a relatively new technique of repairing inguinal hernias where the dissection and repair are carried out without violating the peritoneal cavity. McKernan and Law first introduced totally extraperitoneal hernia repair in 1993 [39]. They reported 51 cases, of which, 11 were recurrent and 12 were bilateral. The procedure has since been refined, especially with advancements is surgical technology and training.

Some proponents of TEP advocate for this technique over the transabdominal approach due to the potential complications of accessing and working in the peritoneal cavity [40]. When compared to open hernia repair, and particularly recurrent (after open) and bilateral hernias, many surgeons prefer the laparoscopic approach due to quicker recovery times, and less postoperative and chronic pain [41–42].

Totally extraperitoneal hernia repair is feasible in most patients with inguinal hernias, but in certain situations the open repair might be more appropriate depending on hernia anatomy, surgeon experience, and the patient's medical and surgical history. Bilateral inguinal hernias and recurrent hernias after open repair are two well-accepted indications for TEP. In patients with bilateral hernias, both sides can be dissected, examined, and repaired using the same ports, thus the morbidity associated with port insertion and wound complications remains low [43,44, 45]. Treating recurrent hernias is more challenging, depending on the approach used in the past. Scarring and the presence of mesh or a mesh plug can obliterate planes and make it more likely to injure the peritoneum or other structures. Patients who have had prior repairs that did not invade the pre-peritoneal space, like Lichtenstein repair, are the best candidates for TEP repair if they recur while patients who had repairs that invaded the pre-peritoneal space, like mesh plug repair or open pre-peritoneal repair, may be more challenging with a TEP approach if they recur. In experienced hands, there are no absolute contraindications to totally

extraperitoneal hernia repair; however, a careful decision should be made to tailor the approach to both patient and surgeon factors [45–47].

TEP is technically challenging and the learning curve has been reported to be at least 60 procedures, if not more [36, 37].

Operative Surgery

Multiple techniques can be used to access the pre-peritoneal space. We prefer the open technique. It is quick, easy, and reproducible. It is widely used and has been reported by multiple authors [48–51]. We make a 10 mm infraumbilical incision, usually on the same side as the hernia, or on the larger side in the case of bilateral hernias, slightly off the midline.

The anterior rectus sheath is incised and the rectus muscle is retracted laterally and anteriorly to visualize the posterior rectus sheath. This provides safe and direct access to the preperitoneal space. In this technique, care should be taken to avoid injury to the underlying rectus muscle which can lead to bleeding and less than optimal views of the appropriate planes. Dulucq et al. insert a Veress needle directly into the space of Retzius, followed by carbon dioxide insufflation and direct trocar insertion. In this method, it may be difficult to insert the needle in the correct space and the working space is initially quite limited. Others have also reported establishing pneumoperitoneum first, followed by raising a pre-peritoneal blister using bupivacaine and then inserting

the trocars in the pre-peritoneal space [51]. This technique has the disadvantage of the potential morbidity associated with entry into the peritoneal cavity such as bowel injury and port site hernia.

Multiple methods to create the pre-peritoneal working space have been described. The most commonly used method is using a balloon dissector [52–55]. A commercially made balloon is inserted just under the rectus muscle and advanced toward the symphysis pubis until the bone is felt at the tip of the introducer. It is then inflated, under direct vision, after confirming that it is appropriately placed in the pre-peritoneal space. This is followed by insertion of a balloon-tip trocar.

There are two common port configurations used in laparoscopic totally extraperitoneal hernia repair. The midline configuration: where the 10mm camera port is inserted in the infraumbilical position, followed by insufflation of carbon dioxide to a pressure of 12 mmHg of pneumo-preperitoneum. Then, under direct vision, two 5 mm trocars are inserted in the midline between the rectus muscles. Enough distance to allow free movement of instruments, usually four fingerbreadths, separates the 5 mm trocars.

The advantage of the midline configuration is that the same ports can be used to dissect both sides. The other configuration depends on triangulating the three trocars. A 10mm camera port is inserted infraumbilical, followed by two 5 mm trocars, one along the midline just below the camera port and one lateral port on the same side as the hernia close to the anterior superior iliac spine [43].

This provides better triangulation and may facilitate the dissection of a large hernia sac [52]. Totally extraperitoneal hernia repair requires the creation of a space that allows insertion of a large enough piece of mesh to appropriately cover the myopectineal orifice without the peritoneal edge slipping below the lower border of the mesh.

Familiarity with inguinal anatomy from the pre-peritoneal perspective is essential for safe and adequate dissection of this space and reduction of all hernias. The inferior epigastric vessels should be identified at the beginning of the procedure and serve as an important landmark. We then perform lateral dissection of the peritoneum, up to the level of the anterior superior iliac spine, followed by medial dissection of Cooper's ligament and the pubic tubercle past the midline. If there is a direct hernia, it is reduced either at the beginning or at the time of the medial dissection. Care should be taken during the dissection of Cooper's, as there are often vessels draped over the ligament that can be easily damaged and lead to unnecessary bleeding.

The spermatic cord and internal ring are lateral to the inferior epigastric vessels; this is where the dissection of an indirect hernia sac should begin. Laterally and inferiorly, an important landmark is the fascia over the psoas muscle (Bogros space) where the mesh needs to lay laterally. This is achieved by beginning the lateral dissection just posterior to the inferior epigastric vessels and following

the characteristic white border of the peritoneum. It is important not to violate the fatty plane directly on the psoas, which protects the nerves as they course over the psoas muscle. Superiorly, the dissection should be carried out up to the level of the anterior superior iliac spine.

Posteriorly, the peritoneum is reflected to where the vas deferens courses medially or until enough space has been created for an adequate sized mesh to be placed [52]. If the dissection of the space is not enough to clear the entire myopectineal orifice, the mesh will be susceptible to folding and increase risk of recurrence or pain due to bunching of the mesh [52].

In direct hernias, the sac is protruding through a defect medial to the inferior epigastric vessels. Direct hernias are often reduced by insufflation of the pre-peritoneal space or by the space-making balloon. If it is not completely reduced, the sac can be easily reduced using a “hand over hand” technique until the interface between the herniated sac and the fascia transversalis is encountered. This will give the appearance of a “reversed hernia sac” being pulled down because of the white appearance of the transversalis.

Once reduced, considerable dead space exists where a large direct hernia was. This can lead to the formation of large seromas post-op. The surgeon can attempt to reduce this dead space by fixing the fascia transversalis to Cooper’s ligament, using either a tacking device or sutures, or by using pre-tied suture around the fascia transversalis after pulling it into the operative field. In indirect hernias, the sac is adherent to the spermatic cord and protrudes through the

internal ring, which is lateral to the inferior epigastric vessels. The sac here needs to be separated from the cord structures. The sac should be gently mobilized off the cord structures both medially and laterally before it is completely reduced from the internal ring. The surgeon needs to visualize the cord structures and protect them during the mobilization to reduce the chance of injuring them. The cord is first identified lateral to the inferior epigastric vessels, followed by identification of the hernia sac. This can be done by following the peritoneal reflection laterally to where it joins the spermatic cord. Then, the surgeon's nondominant hand holds the sac to provide counter traction. Then, the sac can be separated from the cord structures by gently peeling the cord structures off the hernia sac. We do not recommend using laparoscopic graspers to hold cord structures, the vas deferens, and the spermatic vascular bundle.

The surgeon can, however, grasp the cremasteric muscle fibres adherent to the spermatic cord. The mesh is rolled like a scroll and introduced through the 10 mm trocar. The previously marked midline of the mesh is aligned parallel to the inferior epigastric vessels and centred around the internal ring for indirect hernias and a little bit more medially for direct defects. The mesh is also aligned to have at least one-third of the mesh lying below the iliopubic tract. The mesh is unrolled laterally and then medially. In the case of large direct hernias, we recommend using a larger mesh to ensure appropriate medial coverage (beyond the midline).

In a randomized controlled trial, it was shown that mesh overlap of less than 3 cm can lead to hernia sac protrusion through the defect and so they recommended an overlap of at least 4 cm (even more might be better).

At the end of the dissection and mesh placement, the repair should be checked before closing and as the air is evacuated from the pre-peritoneal space under direct vision. We highly recommend checking the following:

1. The mesh is laying nice and flat and covering the entire myopectineal orifice.
2. The hernia sac is dissected posterior enough such that the peritoneal reflection is not creeping under the mesh.
3. The mesh stays in place as the space collapses.

COMPLICATIONS OF HERNIA SURGERY

Interpretation of the outcomes of abdominal wall surgery is difficult and obscured by the large number of variables included in this surgery. As illustrated in the Triple P-triangle of abdominal wall hernia repair, many *patient* variables, characteristics of the *prosthesis* used, and the details of the surgical *procedure* will influence the outcome for the patients [56]. The variables of the upper part of the triangle will be described in the many chapters of this book. In this chapter we will focus on the lower part of the Triple-P triangle, the outcome parameters and variables. We measure and describe the results of our surgery in

terms of the recurrence rate, the number of complications, and the Quality of Life of the patients postoperatively.

Complications are an inherent part of surgery and an important outcome parameter to evaluate hernia repair. Clavien et al. defined in 1992 a negative outcome after surgery in three groups [57]:

— Complication: "*any deviation from the normal postoperative course*"

— Sequela: "*an after-effect of surgery that is inherent to the procedure*"

— Failure to cure: "*if the original purpose of the surgery has not been achieved*"

To determine exactly the number of complications

following these definitions, it is of primordial importance to describe what is the normal postoperative course of your patients and what will be considered sequelae.

Hernia-specific adverse events like postoperative seroma, hematoma and pain, need to be defined either as a sequela or a complication. This is highly relevant when we compare studies across the literature. Some studies will report every seroma detected postoperatively, but some will only report those needing treatment. This will obviously be reflected in the overall reported complication rate. Postoperative pain is inherent after surgery, but when it is much higher than expected it might be considered a complication. What is the expected normal duration of hospital stay for the patients and when will it be considered a complication?

Recurrence after hernia repair is a clear *"failure to cure"* and thus should be reported separately and is not considered a complication.

The Clavien–Dindo classification of surgical complications [57] are defined

Classification and grading of surgical complications as proposed by Dindo et al. [57]

Grade 0 No complications

Grade I Any deviation from the normal postoperative course without the need for pharmacological treatment or surgical, endoscopic, and radiological interventions.

Grade II Requiring pharmacological treatment with drugs other than such allowed for grade I complications. Blood transfusion and TPN are included

Grade III Requiring surgical, endoscopic, and radiological interventions

Grade IIIa Intervention not under general anaesthesia

Grade IIIb Intervention under general anaesthesia Grade IV Life-threatening complication requiring IC/ICU management

Grade IVa Single organ dysfunction

Grade IVb Multi-organ dysfunction

Grade V Death of the patient

By using this classification, we change from the dichotomous variable (Yes or No complication) to categorical variable according to the severity of the complications.

From the definitions of Grade I and II complications, it is clear that retrospective studies based on review of patient charts is very unreliable and likely to underestimate the number of complications. It seems useful to group the complications in minor (Grade I, II, and IIIa) and major (Grade IIIb, IVa, IVb, and V) complications in comparing outcome results.

Seroma

As mentioned above some surgeons might consider a seroma an inevitable sequela after surgery and others as a complication. Morales et al. proposed a classification of postoperative seroma, as shown [58].

Classification of postoperative seroma after ventral hernia repair as proposed by Morales-Conde [58]

Seroma type	Definition	Clinical significance
0	No clinical seroma	No clinical seroma
I	Clinical seroma lasting <1 month	Incident
II	Clinical seroma lasting >1 month	
III	Symptomatic seroma that may need medical treatment: minor seroma related complications	Complication
IV	Seroma that need to be treated: major seroma-related complications	Complication

Another classification for seroma is as clinical, minor and major complications.

Clinical seroma: Those seromas detected during physical examination of patients which do not cause any problem, or just a minimum discomfort that allows normal activity

Minor complication: Important discomfort which does not allow normal activity to the patient, pain, superficial infection with cellulitis, aesthetic complaints of the patient due to seroma or seroma lasting more than 6 months

Major complication: Infection, recurrence, mesh rejection or need to be punctured

Surgical Site Infections

Wound infections after hernia repair is a very relevant complication that might induce significant morbidity and treatment costs and compromise the repair at longer term.

Surgical Site Infection (SSI) is classified categorically for severity by the Centre of Disease Control (CDC) as superficial SSI, deep SSI, or organ space SSI. There is a correlation to the degree of wound contamination during surgery, stratified as: clean/clean–contaminated/contaminated/dirty [56].

Surgical Site Occurrences

The Ventral Hernia Working Group introduced Surgical Site Occurrence (SSO) as a new combined complication variable after hernia repair [59]. This is a

combination of SSI, seroma, hematoma, wound dehiscence, and entero-cutaneous fistula.

There are two important issues related to use of SSO as an outcome parameter.

Inclusions in the definitions of Surgical Site Occurrence (SSO) according to different authors and publications

Reference	SSI	Seroma	Hematoma	Wound	EC Fistula	Reoperation
Kanters et al. [18]	X	X	X	X	X	
Baucom et al. [20]	X	X		X	X	
Fischer et al. [21]	X			X		
Ranger et al. [22]	X			X		X
Petro et al. [19]	X	X	X	X	X	

Firstly, the SSO definition as used by the several authors is different from the original five components. Some use the same five component definition [60]. Some have not included hematoma [61]. Others have also not included seroma and entero-cutaneous fistula, leaving only SSI and wound dehiscence as part of

their SSO [62]. Others have added to SSI and wound dehiscence, *return to the operating room*, as part of SSO [63].

So, there is need for a consensus on the definition of SSO to use it as a standard outcome measurement. Second issue with SSO is that it reduces postoperative complications again into a dichotomous variable, not considering the variation in severity of the SSO. It is clear that a superficial SSI is very different from a wound dehiscence needing reoperation, but they will both be classified similarly as a SSO.

Visual Analogues Scale (VAS) for Pain

The VAS score is often used routinely in hospitals for measuring postoperative pain and manage the pain medication. The VAS score is recorded by asking the patient to mark on a calibrated line of 10 cm long the amount of pain experienced. The left side of the line is mentioned to be “No pain” and the right side as “The worst imaginable pain.” It is a good measurement in the immediate postoperative period, but less valuable to asses late chronic pain.

OUTCOMES FOLLOWING HERNIA

Inguinal herniorrhaphy is one of the most common procedures performed by surgeons worldwide reflecting how prevalent the disease process is. In the past, this disease process was managed exclusively by open techniques, but is now seeing a movement towards minimally invasive techniques—more so in the developed world. While the initial focus in inguinal herniorrhaphy was to reduce recurrence, later achieved with the Lichtenstein technique, focus has more recently shifted to other outcomes such as reduced postoperative complications, chronic pain, early return to normal activity, and better cosmesis [63]. The desire to improve outcomes continues to drive the evolution of surgical management techniques. The 1990s brought about the rise of minimally invasive techniques with the adoption of laparoscopy, and more recently the addition of robotics technology continues to expand the field. In this section, we summarize inguinal herniorrhaphy outcomes; postoperative pain, quality of life, recurrence, and complication rates, as they pertain to the open and minimally invasive techniques in repair of inguinal hernias.

Laparoscopic techniques are increasingly in use, mostly in the developed world, and outcomes data is promising. In the early years when compared to open techniques, laparoscopic techniques had worse recurrence rates, 10.1 % versus 4.9 %, and were more expensive secondary to the required specialized

instruments [65]. However, as laparoscopic technology and techniques have developed over the years recurrence rates following laparoscopic inguinal herniorrhaphy have fallen to similar rates when compared to the standard mesh-based open techniques [66]. In addition, a meta-analysis of randomized clinical trials demonstrated that laparoscopic techniques provide benefits when compared to open techniques, evident in shorter hospital stay, diminished acute postoperative pain, improved recovery time with return to normal activities sooner, and better cosmesis. In addition, a long-term randomized study of 314 patients managed with totally extraperitoneal (TEP) and transabdominal preperitoneal (TAPP) repairs demonstrated that the two laparoscopic techniques have similar outcomes pertaining to chronic pain, quality of life, and time to return to work [67]. Thus, minimally invasive techniques have a strong role in the repair of inguinal hernias.

Some degree of postoperative pain is common and expected following surgery. However, persistent pain becomes a problem. Chronic pain has been defined as surgical site pain persisting beyond 3 months. The incidence of chronic pain following open inguinal hernia repair has been reported at 18 %. Meanwhile the incidence following laparoscopic repair is 6 %. Sajid et al. notes that the aetiology of chronic pain is unclear, but is thought to include inguinal nerve irritation by suture or mesh, inflammatory reaction to mesh and foreign material, scaring incorporating inguinal nerves, and abdominal

wall compliance reduction. In a 2014 update to the European Hernia Society (EHS) guidelines based on metanalysis data there was no difference in chronic pain after Lichtenstein when compared to TEP hernia repair [68]. However, a review of prospectively collected data with 17,388 patients demonstrated worse pain on exertion in the Lichtenstein group (OR 1.420; CI 1.264–1.596) at 1 year postoperatively with a rate of 9.23 % compared to 7.90 % in the TEP group, and overall prevalence of 8.7 %. Hence, laparoscopy seems to reduce chronic postoperative pain compared to open repair.

The meta-analysis data leading to the 2014 update to the EHS guidelines demonstrated no difference in the recurrence rate following Lichtenstein and laparoscopic repair of inguinal hernias [68]. This observation has also been demonstrated in a review of prospectively collected data with 17,388 patients, with a 1year recurrence rate of 0.83 % versus 0.94 % when comparing Lichtenstein to TEP repair, respectively. One-year postoperative data by Mayer et al. following 11,228 patients who underwent TAPP repair for a primary inguinal hernia demonstrated a similar recurrence when mesh was fixed (0.88 %) versus not fixed (1.1 %). In addition, the International Endohernia Society (IEHS) has published that there is no difference in recurrent rates when comparing fixed or non-fixed mesh in repair of small hernias (<3 cm) repaired with laparoscopic techniques. This goes to suggest that better mesh options now exist, allowing for less need for mesh fixation thereby reducing potential cost and pain that may come with fixation techniques.

Surgical complications lead to undesired morbidity and potential mortality. Kockerling et al. demonstrated a higher postoperative complication rate following Lichtenstein repair in comparison to TEP repair in their review of prospectively collected data on 17,388 patients (OR 2.152; CI 1.734–2.672), and a prevalence rate of 3.2 % [68]. When comparing TEP versus Lichtenstein repair, the data demonstrated a postoperative bleeding rate of 1.16 % versus 2.46 %, a seroma rate of 0.51 % versus 1.48 %, wound infection rate of 0.06 % versus 0.26 %, and wound healing disorders of 0.07 % versus 0.35 %, respectively [68]. The above study failed to demonstrate a difference in intraoperative complication rates when assessing for vascular injury, bowel injury, and bladder injury, with overall rates <0.28 %. However, intraoperative bleeding was higher in the TEP repair group (0.76 %) compared to 0.41 % in the Lichtenstein repair group. When comparing TEP to TAPP complications, data has largely been of limited quality and suggests overall similarities in outcomes. A recent small prospective randomized trial of 60 patients failed to show a difference in 30-day postoperative outcomes (urinary retention, hematoma, seroma, wound infection, pain, return to normal activity, and recurrence) between the two techniques. However, in a large prospective review of 17,587 patients, Köckerling et al. demonstrated that the overall surgical complication rates were higher for TAPP (3.97 %) when compared to TEP (1.70 %). The noted difference was largely secondary to a higher seroma rate in the TAPP group (3.06 %) versus 0.51 % in the TEP group. In their

discussion, the difference could be explained by the higher number of large defects and scrotal hernias in the TAPP group. The study also suggested a higher postoperative bleeding rate in the TEP group (1.18 %) compared to the TAPP group (0.82 %).

Overall, it appears laparoscopic techniques have lower postoperative complications relative to open techniques, while TEP and TAPP outcomes are largely comparable.

Minimally invasive techniques continue to evolve affecting other inguinal herniorrhaphy outcomes such as small bowel obstruction and urinary retention. In a series of 3017 patients undergoing TAPP repair, Kapiris et al. demonstrated a reduced incidence in small bowel obstruction from 0.8 % with closure of the peritoneal flap with tacks to 0.1 % when suture closure was adopted. Others have shown a small bowel obstruction incidence of 0.2–0.5 % following the use of tacks to close the peritoneal flap [69]. This complication of small bowel obstruction is extremely rare following open inguinal herniorrhaphy, only described in case reports with mesh migration as the aetiology [69]. Urinary retention incidence following laparoscopic techniques is anywhere between 0.2 and 35 % based on various studies; however, the true rate is thought to be 2–7 %. Ross et al. in a 227-patient prospective database study of hernias repaired using the TAPP approach demonstrated a urinary retention rate of 4.9 % with no statistical difference between peritoneal flap closure with tacks, staples, or suture. A meta-analysis of randomized controlled trials by Tam et al.

demonstrated an incidence of urinary retention following TEP with mesh fixation at 3.10 % compared to 1.01 % without fixation. In a prospective study of 471 patients, Vigneswaran et al. demonstrated a urinary retention rate of 3.3 % in patients <65 years and 15.7 % for those older following laparoscopic herniorrhaphy [69]. On the other hand, open repair techniques have an overall lower urinary retention rate when compared to laparoscopic techniques. Such is the case given that general anaesthesia, an integral component of laparoscopic techniques, is thought to be the main cause of urinary retention after hernia repair. Following inguinal herniorrhaphy with local anaesthesia, Finley et al. demonstrated a urinary retention rate of 0.2 % in comparison to a rate of 13 % among patients managed with general or spinal anaesthesia [70].

OBSERVATIONS AND RESULTS

The study was conducted at Stanley Medical College from October 2016 to August 2017 in the Department of General Surgery. The study involved 75 male patients who satisfied the inclusion criteria. 25 patients were subjected to Lichtenstein tension free open hernioplasty, 25 treated with TEP, and another 25 subjected to TAPP.

1.Age distribution

Age

	N	Mean	Std. Deviation	Minimum	Maximum
Lichtenstein	25	49.72	10.632	25	70
TEP	25	48.24	10.818	24	62
TAPP	25	48.88	9.884	31	62
Total	75	48.95	10.328	24	70

The age distribution of the subjects ranged from 24 to 70 years. The mean age of patients subjected to TEP and TAPP group were similar around 48 years. However, the mean age for Lichtenstein repair was 49 years. Elderly patients were preferred for Lichtenstein tension due to risks of subjecting to general anaesthesia.

2. Diagnosis

Each of the cases were clinically examined and diagnosed as per the European Hernia Society classification.

2.A. Side of hernia

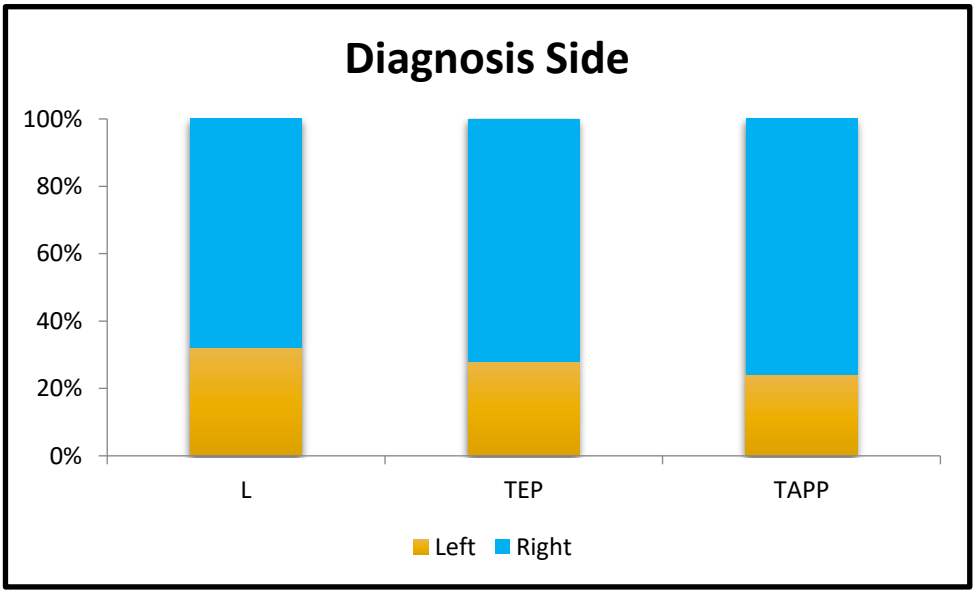

	L	TEP	TAPP
Left	32.0%	28.0%	24.0%
Right	68.0%	72.0%	76.0%

			Groups			Total
			L	TEP	TAPP	
Diagnosis Side	L	Count	8	7	6	21
		% within Groups	32.0%	28.0%	24.0%	28.0%
	R	Count	17	18	19	54
		% within Groups	68.0%	72.0%	76.0%	72.0%
Total		Count	25	25	25	75
		% within Groups	100.0%	100.0%	100.0%	100.0%

Among the 75 cases studied 21 cases were found to have left sided inguinal hernia, whereas 54 cases were having right sided hernia.

2.b. Type of hernia

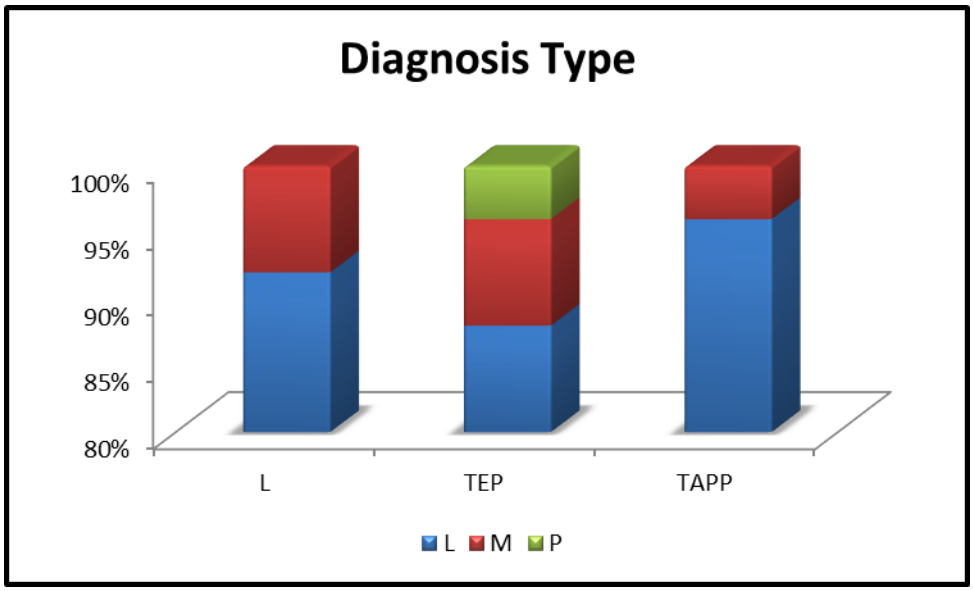

	L	TEP	TAPP
L	92.0%	88.0%	96.0%
M	8.0%	8.0%	4.0%
P		4.0%	

Among the 75 cases studied 92% were lateral inguinal hernia, 6% were medial inguinal hernia and 4% were pantaloon hernia. Although all hernias were preoperatively evaluated, most of the diagnosis on the type of the hernia was made intraoperatively.

3.Comorbidities

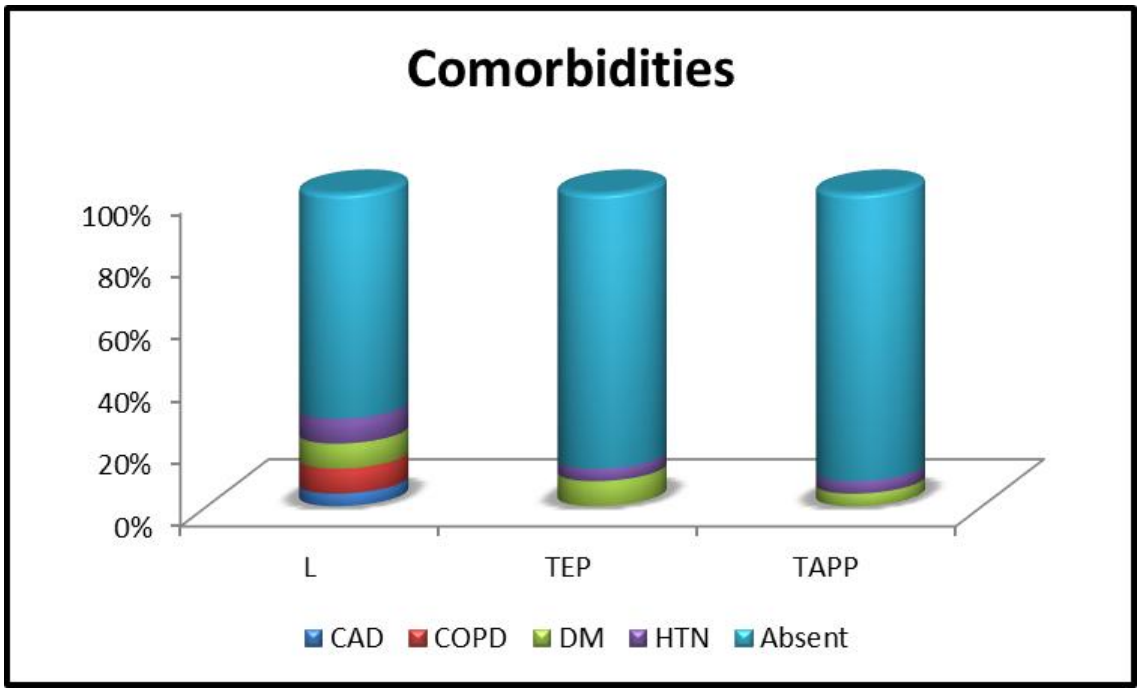

			Groups			Total
			L	TEP	TAPP	
Diagnosis Type	L	Count	23	22	24	69
		% within Groups	92.0%	88.0%	96.0%	92.0%
	M	Count	2	2	1	5
		% within Groups	8.0%	8.0%	4.0%	6.7%
	P	Count	0	1	0	1

	% within Groups	0.0%	4.0%	0.0%	1.3%
Total	Count	25	25	25	75
	% within Groups	100.0%	100.0%	100.0%	100.0%

Diabetes was the most common comorbidity in the present study group. Other comorbidities included in the present study are systemic hypertension, Chronic Obstructive Pulmonary Disease and Coronary Heart Disease. Patients with cardiopulmonary diseases were subjected to Lichtenstein tension free open hernioplasty.

4. Intraoperative complications

Intraoperative complications like major vessel injury or bladder injury were observed. No intraoperative complications were encountered during the study period in any of the groups.

5. Post-operative urinary retention

			Groups			Total
			L	TEP	TAPP	
Urinary retention	No	Count	23	25	25	73
		% within Groups	92.0%	100.0%	100.0%	97.3%
	Yes	Count	2	0	0	2
		% within Groups	8.0%	0.0%	0.0%	2.7%
Total		Count	25	25	25	75
		% within Groups	100.0%	100.0%	100.0%	100.0%

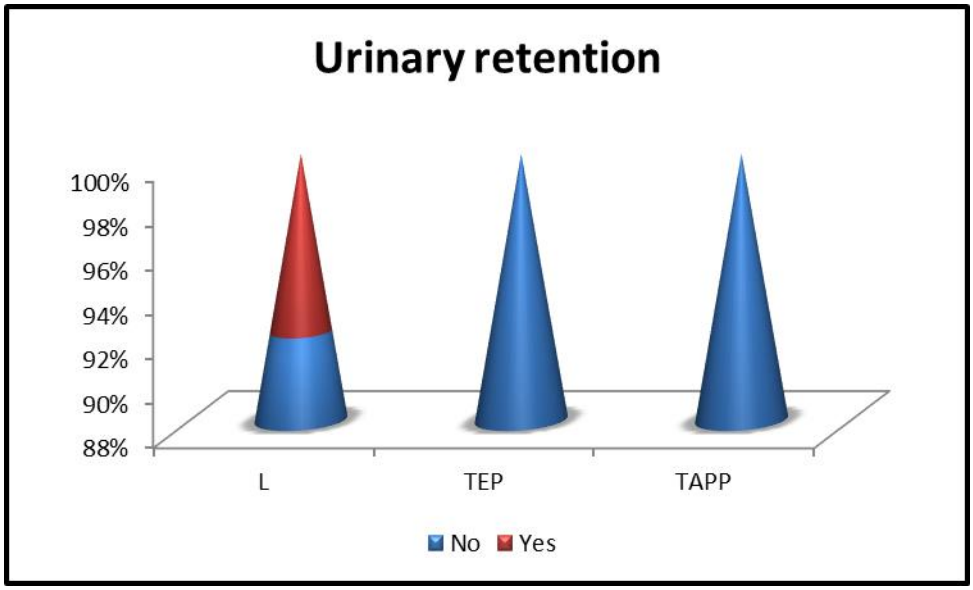

Post-operative urinary retention was found only in a two cases of Lichtenstein tension free open hernioplasty and this required bladder catherization. All cases of laparoscopic hernioplasty were catheterized intraoperatively and catheter retained till post-operative day 1, hence urinary retention could not be assessed.

6. Duration of surgery

		N	Mean	Std. Deviation	Minimum	Maximum
Duration of surgery	L	25	55.00	8.416	40	70
	TEP	25	101.20	11.662	80	120
	TAPP	25	106.40	11.504	80	120
	Total	75	87.53	25.513	40	120

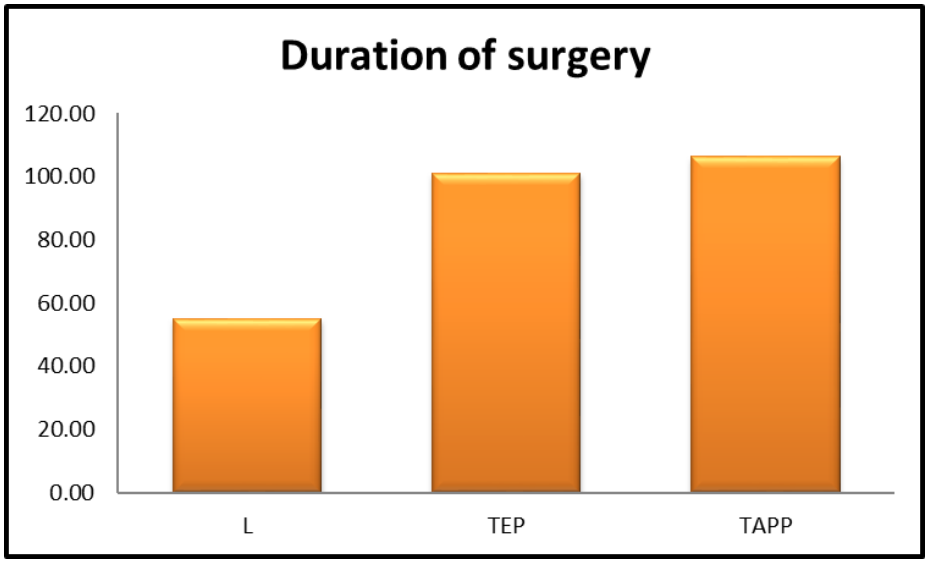

	Duration of surgery
Chi-Square	51.606
df	2
Asymp. Sig.	.0005

The duration of surgery was the observed to be longer for laparoscopic hernia repair when compared with Lichtenstein tension free open hernioplasty. Among the laparoscopic hernioplasty TAPP took an average of 106 minutes whereas TEP took an average of 101 minutes only.

7. Post-operative pain.

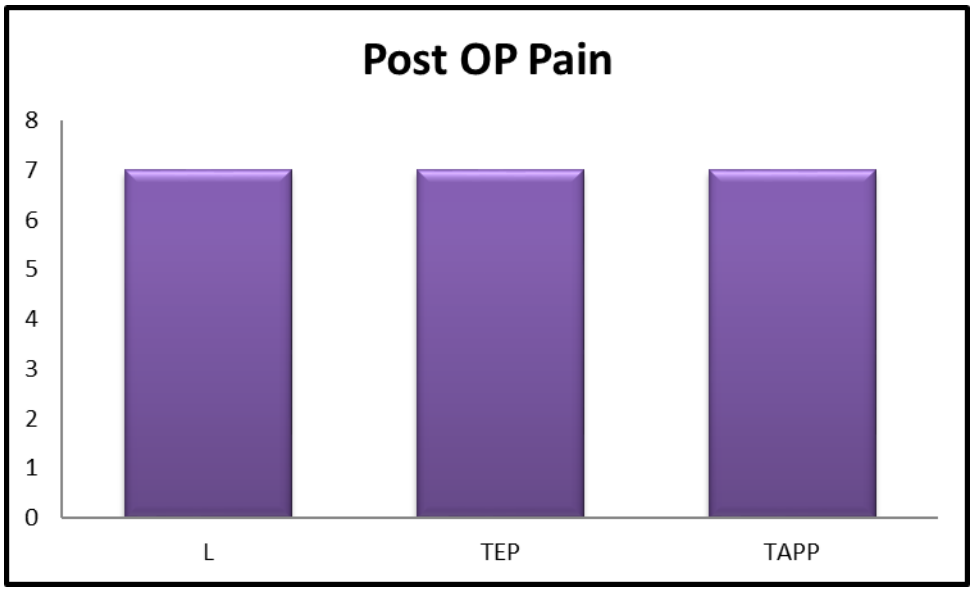

		N	Mean	Std. Deviation	Minimum	Maximum
Post OP Pain	L	25	7	.645	6	8
	TEP	25	7	.961	4	8
	TAPP	25	7	.802	4	8
	Total	75	6.88	.885	4	8

	Post OP Pain
Chi sq.	14.531
Df	2
Asymp. Sig	.001

The post-operative pain was measured using Visual Analog Scale (VAS) 6 hours after the surgery. The patient was given a dose of Injection Tramadol 100mg in after the surgery. The next dose of analgesic was given based on the VAS score. The pain scores were analysed with Chi square and the difference found to be statistically significant. Lichtenstein tension free open hernioplasty was found to have increased post-operative pain when compared to laparoscopic repair. Among the laparoscopic repair TAPP was found to have increased post-operative compared to TEP.

8.Seroma

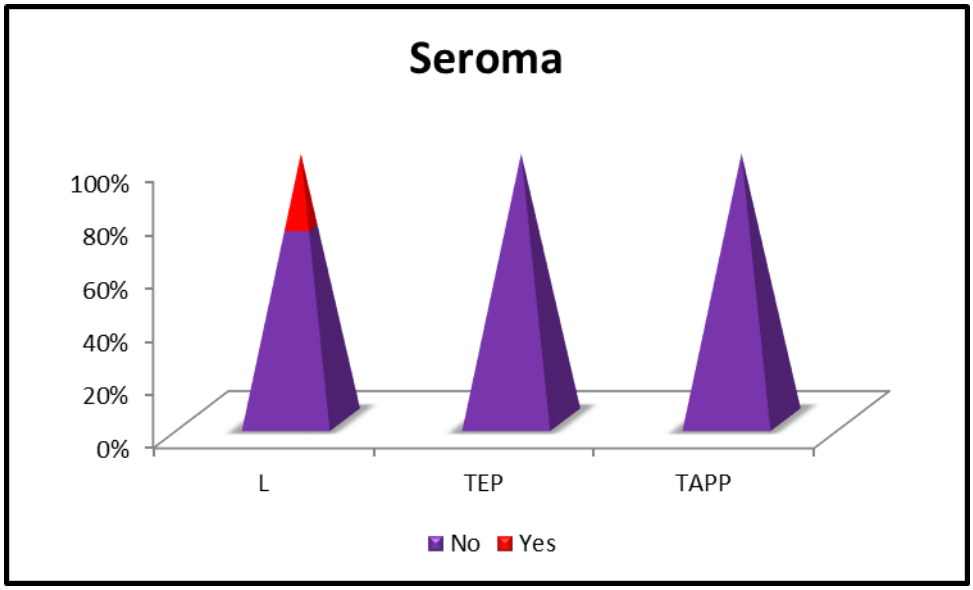

			Groups			Total
			L	TEP	TAPP	
Seroma	No	Count	18	25	25	68
		% within Groups	72.0%	100.0%	100.0%	90.7%
	Yes	Count	7	0	0	7
		% within Groups	28.0%	0.0%	0.0%	9.3%
Total		Count	25	25	25	75
		% within Groups	100.0%	100.0%	100.0%	100.0%

Post-operative seroma was observed only in Lichtenstein tension free open hernioplasty. 28 % of cases developed seroma which required drainage. This caused prolonged hospital stay and wound infections.

9. Hematoma

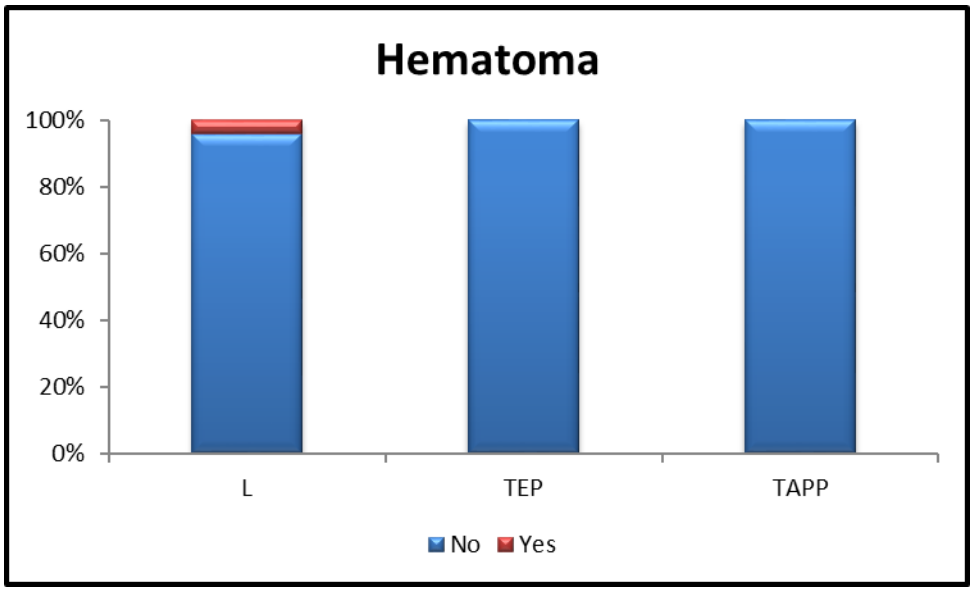

			Groups			Total
			L	TEP	TAPP	
Hematoma	No	Count	24	25	25	74
		% within Groups	96.0%	100.0%	100.0%	98.7%
	Yes	Count	1	0	0	1
		% within Groups	4.0%	0.0%	0.0%	1.3%
Total		Count	25	25	25	75

			% within Groups	100.0%	100.0%	100.0%	100.0%

	L	TEP	TAPP
No	96.0%	100.0%	100.0%
Yes	4.0%		

Post-operative hematoma was observed in a single case of Lichtenstein open hernioplasty. The hematoma was in the subcutaneous plain and required drainage.

10. Wound infection

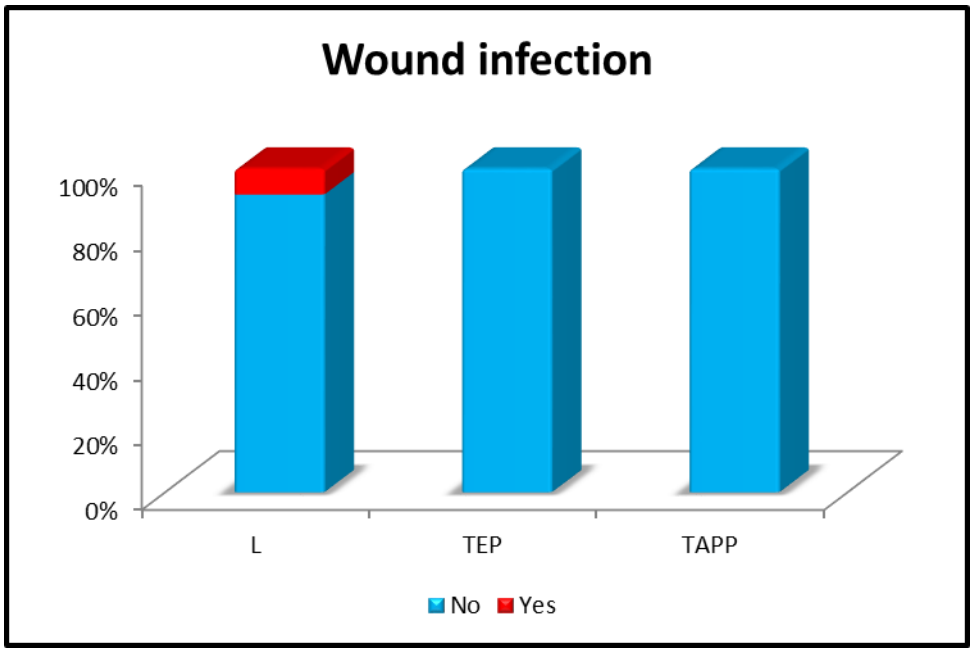

			Groups			Total
			L	TEP	TAPP	
Wound infection	No	Count	23	25	25	73
		% within Groups	92.0%	100.0%	100.0%	97.3%
	Yes	Count	2	0	0	2
		% within Groups	8.0%	0.0%	0.0%	2.7%
Total		Count	25	25	25	75
		% within Groups	100.0%	100.0%	100.0%	100.0%

	L	TEP	TAPP
No	92.0%	100.0%	100.0%
Yes	8.0%		

Wound infection was also observed only in cases of open hernioplasty procedure. Wound culture and sensitivity shoved Staph. aureus, managed with antibiotic and drainage.

11. Recurrence

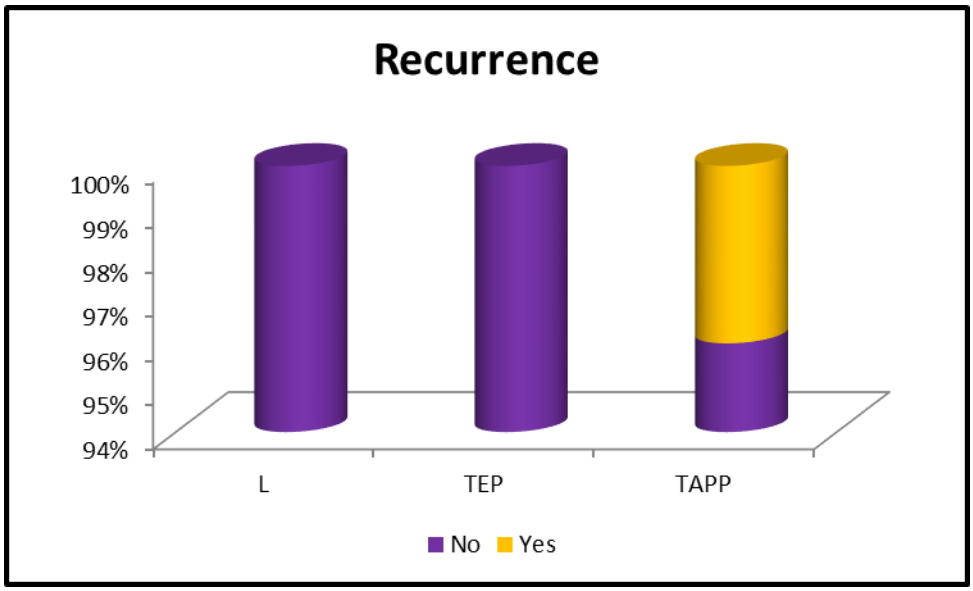

			Groups			Total
			L	TEP	TAPP	
Recurrence	No	Count	25	25	24	74
		% within Groups	100.0%	100.0%	96.0%	98.7%
	Yes	Count	0	0	1	1
		% within Groups	0.0%	0.0%	4.0%	1.3%

Total			Count	25	25	25	75
			% within Groups	100.0%	100.0%	100.0%	100.0%

	L	TEP	TAPP
No	100.0%	100.0%	96.0%
Yes			4.0%

Recurrence in the immediate postoperative period was observed in case of TAPP repair. The recurrent hernia was repaired with open hernioplasty. This led to prolonged hospital stay.

12. Time of discharge

		N	Mean	Std. Deviation	Minimum	Maximum
Time of discharge	L	25	5	1.222	4	9
	TEP	25	3	.611	2	5
	TAPP	25	4	1.915	2	12
	Total	75	4.00	1.610	2	12

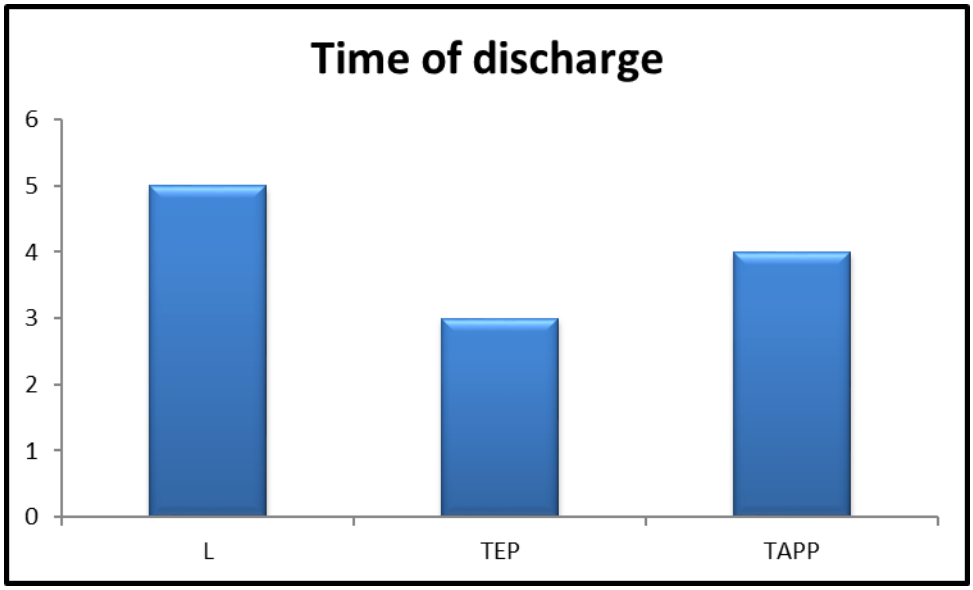

	Time of discharge
Chi-Square	44.496
df	2
Asymp. Sig.	.0005

The mean duration of post-operative hospital stay was compared. Laparoscopic hernioplasty groups were discharged earlier when compared to open hernioplasty. Among the laparoscopic hernioplasty, TEP patients were discharged earlier than TAPP patients.

DISCUSSION

1.Age

The cumulative prevalence of inguinal hernia in males aged 25–34 years is 5 %, rising to 10 % for age 35–44 years, 18 % for age 45–54 years, 24 % for age 55–64 years, 31 % for age 65–74 years, and finally 45 % for males of age 75 years or more [71]. Inguinal hernias occur eight times as often in men as in women, and consequently approximately 90 % of all inguinal hernia repairs are performed in male patients [72].

Our study the mean age was 49 and 95% of cases were between age group of 39-59. All cases selected were males.

2.Comorbidities

Several comorbidities, some of which are associated with altered collagen metabolism, have been proposed to be associated with inguinal hernia formation. It has been suggested that patients diagnosed with aortic abdominal aneurism or thoracic aortic disease are predisposed to inguinal hernia formation, but the evidence on this is inadequate [73, 74].

Ehlers–Danlos syndrome, characterized by altered collagen metabolism, increases the risk of inguinal hernia by a factor 4–5 depending on gender [75].

Prostatic hypertrophy, diagnosed by physical examination, proposedly increases the risk of inguinal hernia in men [71].

In one study chronic obstructive pulmonary disease is a risk factor for direct inguinal hernia [76], and in another, that chronic coughing is associated with a higher risk of inguinal hernia [77]. It is, however, still unclear whether coughing and chronic obstructive pulmonary disease associates with inguinal hernia, due to conflicting published results.

In our study diabetes, hypertension and COPD was evaluated. It was found that preoperative diabetes was associated with in increased post-operative complications. Also in presence of cardiopulmonary comorbid patients were preferably subjected to open hernioplasty.

Cases of hernia with prostatic hyperplasia were referred to Urology department and were excluded from the study.

3. Operating time

Laparoscopic inguinal hernia repair takes longer than open mesh repair. In technology appraisal guidance 83 by National Institute for clinical excellence, Sept. 2004, it was stated that laparoscopic surgery was associated with a statistically significant increase in operation time compared with open methods of hernia repair. Meta-analysis of 16 randomized control trials of Trans abdominal pre- peritoneal (TAPP) repair demonstrated on overall increase of 13.33 minutes compared with open repair. Meta-analysis of eight randomized control trial of trans extraperitoneal (TEP) repair demonstrated an overall increase of 7.89 minutes compared with open repair. Memon and colleagues

reviewed the data from 29 published randomized clinical trials and concluded that patients who underwent laparoscopic repair of inguinal hernia took longer time for surgery. In a Bringman13 trial operating time was found to be 5 minutes shorter in open mesh repair in comparison to laparoscopic group. The average time taken for TAPP/TEP (65.7 min) was significantly longer than that for the Lichtenstein repair (55.5 min) in a meta-analysis published by Schmidt et al [78] in 2005 involving 34 trials.

First Author	**Laparoscopic**	**Open**
MC Cormack22	14.8 minute longer ($p < 0.0001$)	
Memon8	15.2 minute longer ($p < 0.0001$)	
MRC Trial group 5	58.4 minute	43.3 minute
Bringman9	50 minutes	45 minutes
Picchio23	49.6 minute	33.9 minute
Chung 24	Laparoscopic longer in all groups	
Wright25	58 minutes	45 minutes

In our study, the mean duration for a Lichtenstein tension free open hernioplasty was 55 minutes. Whereas mean operating time for TEP was 101 minutes and TAPP was 106 minutes. This is due to the prolonged learning curve required for laparoscopic repair compared to open repair.

4. Conversion rate

2 cases of TAPP were converted to open procedure due to technical problems like lack of tacking device and learning curve for the procedure.

5.Postoperative pain

Some degree of postoperative pain is common and expected following surgery. However, persistent pain becomes a problem. Chronic pain has been defined as surgical site pain persisting beyond 3 months [79]. The incidence of chronic pain following open inguinal hernia repair has been reported at 18 %. Meanwhile the incidence following laparoscopic repair is 6 % [80]. Sajid et al. notes that the aetiology of chronic pain is unclear, but is thought to include inguinal nerve irritation by suture or mesh, inflammatory reaction to mesh and foreign material, scaring incorporating inguinal nerves, and abdominal wall compliance reduction [81]. In a 2014 update to the European Hernia Society (EHS) guidelines based on meta-analysis data there was no difference in chronic pain after Lichtenstein when compared to TEP hernia repair [82]. However, a review of prospectively collected data with 17,388 patients demonstrated worse pain on exertion in the Lichtenstein group (OR 1.420; CI 1.264–1.596) at 1 year postoperatively with a rate of 9.23 % compared to 7.90 % in the TEP group, and overall prevalence of 8.7 % [83]. Hence, laparoscopy seems to reduce chronic postoperative pain compared to open repair.

In our study although the mean pain score in the post-operative period was 7, open hernioplasty patients had a statistically significant pain increased postoperative pain.

6.Complications

Surgical complications lead to undesired morbidity and potential mortality. Köckerling et al. demonstrated a higher postoperative complication rate following Lichtenstein repair in comparison to TEP repair in their review of prospectively collected data on 17,388 patients (OR 2.152; CI 1.734–2.672), and a prevalence rate of 3.2 % [83]. When comparing TEP versus Lichtenstein repair, the data demonstrated a postoperative bleeding rate of 1.16 % versus 2.46 %, a seroma rate of 0.51 % versus 1.48 %, wound infection rate of 0.06 % versus 0.26 %, and wound healing disorders of 0.07 % versus 0.35 %, respectively [83]. The above study failed to demonstrate a difference in intraoperative complication rates when assessing for vascular injury, bowel injury, and bladder injury, with overall rates <0.28 %. However, intraoperative bleeding was higher in the TEP repair group (0.76 %) compared to 0.41 % in the Lichtenstein repair group. When comparing TEP to TAPP complications, data has largely been of limited quality and suggests overall similarities in outcomes. A recent small prospective randomized trial of 60 patients failed to show a difference in 30-day postoperative outcomes (urinary retention,

hematoma, seroma, wound infection, pain, return to normal activity, and recurrence) between the two techniques [84]. However, in a large prospective review of 17,587 patients, Köckerling et al. demonstrated that the overall surgical complication rates were higher for TAPP (3.97 %) when compared to TEP (1.70 %) [85]. The noted difference was largely secondary to a higher seroma rate in the TAPP group (3.06 %) versus 0.51 % in the TEP group. In their discussion, the difference could be explained by the higher number of large defects and scrotal hernias in the TAPP group. The study also suggested a higher postoperative bleeding rate in the TEP group (1.18 %) compared to the TAPP group (0.82 %).

Overall, it appears laparoscopic techniques have lower postoperative complications relative to open techniques, while TEP and TAPP outcomes are largely comparable.

In our study the surgical site complications like seroma, hematoma and wound infection were unique to Lichtenstein tension free open hernioplasty due to the larger incision. The incidence rates were compared using Chi square test and found to be statistically significant.

There was a single case of recurrence following TAPP which was detected in the immediate post-operative period.

6.Time of discharge

Majority of patients can perform normal activities at one week whether after open or laparoscopic surgery. Data regarding time to return to activity are rather subjective. Type of employment or profession, to which patient is returning will influence how long he needs to be away from work. Patient who is doing desk job in office will return to work earlier than a patent with a job that entails heavy lifting. Some patients will be getting paid sick leave, so they will have less incentive to go back to work early. Time to return to daily activities was found to be one day shorter for laparoscopic group than those undergoing open repair of hernia in a VA hernia trial group, but the time to resumption of sexual activity was similar in the two groups. However, at 3 months of follow up, there was no difference in the activity level between the laparoscopic and open group. Lawrence et al18 did not find any significant difference in return to normal activities in two groups.

Because of the unreliability in accurately measuring the time of return to normal activity, we have taken the time of discharge as a parameter. The mean time of discharge was found to be 5 days in Lichtenstein tension free open hernioplasty, 3 days for laparoscopic TEP repair and 4 days for laparoscopic TAPP repair.

CONCLUSION

Primary unilateral inguinal hernia without complications can be treated with Lichtenstein tension free open hernioplasty or laparoscopic trans abdominal preperitoneal hernioplasty or laparoscopic totally extraperitoneal hernioplasty. Lichtenstein open hernioplasty has advantage over laparoscopic repair in terms of shorter duration of surgery and learning curve. Although no major intra operative complications were noticed in the present study, literature shows evidence of major vessel and organ damage, even mortality following laparoscopic procedures. But laparoscopic hernia repair outscores Lichtenstein repair in terms of post-operative complications and early discharge of the patient. Among the laparoscopic hernia repair, between TEP and TAPP, TEP has statistically significant lesser complication rates and time of discharge. But these are surgeon dependent factors and varies between studies.

Hence according to the present study TEP is the best method of hernioplasty for a primary inguinal hernia. However, large scale studies and long-term follow-up studies are required to evaluate for the chronic pain, recurrence rates and learning curve in laparoscopic hernia repair.

BIBILOGRAPHY

1.Liem MSL, van der Graaf Y and van Steensel CJ. Comparison of conventional anterior surgery and laparoscopic surgery for inguinal -hernia repair. N Eng J Med 1997;336:1541-1547.

2.Stoker DL, Spiegelhalter DJ, Singh R and Wellwood JM. Laparoscopic versus open inguinal hernia repair. Randomized prospective trial. Lancet 1994;343:1243-1245.

3. Grant A. Laparoscopic compared with open methods of inguinal hernia repair: Systematic review of randomized controlled trials. Br J Surg 2000;87:860-867.

4. Rutkow IM, Robbins AW. Demographic, classificatory, and socioeconomic aspects of hernia repair in the United States. Surg ClinNorth Am. 1993;73:413–26.

5. Hair A, Paterson C, Wright D, Baxter JN, O'Dwyer PJ. What effect does the duration of an inguinal hernia have on patient symptoms? J Am Coll Surg. 2001;193:125–9.

6.Fitzgibbons Jr RJ, Ramanan B, Arya S, Turner SA, Li X, Gibbs JO, Reda DJ. Long-term results of a randomized controlled trial of a nonoperative strategy (watchful waiting) for men with minimally symptomatic inguinal hernias. Ann Surg. 2013;258:508–15.

7. Primatesta P, Goldacre MJ. Inguinal hernia repair: incidence of elective and emergency surgery, readmission and mortality. Int J Epidemiol. 1996;25:835–9.

8. Nilsson H, Stylianidis G, Haapamaki M, Nilsson E, Nordin P. Mortality after groin hernia surgery. Ann Surg. 2007;245:656–60.

9. Jansen PL, Mertens PP, Klinge U, Schumpelick V. The biology of hernia formation. Surgery. 2004;136(1):1–4. doi:10.1016/j.surg.2004.01.004.

10. Burcharth J, Pommergaard HC, Rosenberg J. The inheritance of groin hernia: a systematic review. Hernia. 2013;17(2):183–9. doi:10.1007/s10029-013-1060-4.

11. Rosch R, Junge K, Knops M, Lynen P, Klinge U, SchumpelickV. Analysis of collagen-interacting proteins in patients with incisional hernias. Langenbecks Arch Surg. 2003;387(11–12):427–32.doi:10.1007/s00423-002-0345-3.

12. Klinge U, Si Z, Zheng H, Schumpelick V, Bhardwaj R, Klosterhalfen B. Collagen I/III and matrix metalloproteinases (MMP) 1 and 13 in the fascia of patients with incisional hernias. J Invest Surg. 2001;14(1):47–54. http://dx.doi.org/10.1080/089419301750072202.

13. Skandalakis J, et al. Surgical anatomy: the embryological and anatomic basis of modern surgery. Athens: Paschalidis Medical Publications; 2004. p. 396.

14. Stoppa R, Wantz GE, Munegato G, Pluchinotta A. Hernia healers. Villacoublay: Arnette; 1998.

15. Stoppa R, Wantz GE, Munegato G, Pluchinotta A. Hernia healers.

Villacoublay: Arnette; 1998.

16. Nicolo E, Guanieri A, Guanieri F. Hernia surgery in Italy: how far have we come since Bassini? In: Hernia. 5th ed. Philadelphia: Lippincott Williams and Wilkins; 2001. p. 117–9.

17. Catterina A. Catterina's operation for the radical cure of inguinal hernia. London: Lewis; 1934.

18. Lifshutz H. The inguinal darn. Arch Surg. 1986;121:717–8.

19. Bendavid R. The Shouldice repair. In: Fitzgibbons RJ, Greenburg G, editors. Hernia. 5th ed. Philadelphia: JB Lippincott; 2009. p. 129–38.

20. Usher F, Fries J, Oschner JL. Clinical studies. Arch Surg. 1959;78:138–45.

21. Stoppa R, Petit J, Henry X. Unsutured Dacron prosthesis in groin hernias. Int Surg. 1975;60(8):411–2.

22. Lichtenstein IL. Hernia repair without disability. St. Louis: Ishiyaku Euroamerica; 1987. p. 77–109.

23. Ger R. The management of certain abdominal hernia by intraabdominal closure of the neck of the sac. Ann R Coll Surg Engl. 1982;64:342–4.

24. Geis WP. J. Barry McKernan, MD, PhD—a profile. JSLS. 2004;8(4):399–400.

A.I. Gilbert et al.

25. Miserez M, Peeters E, Aufenacker T, et al. Update with level 1 studies of the European Hernia Society guidelines on the treatment of inguinal hernia in adult patients. Hernia. 2014;18(2):151–63

26. Dulucq JL, Wintringer P, Mahajna A. Laparoscopic totally extraperitoneal inguinal hernia repair: lessons learned from 3,100 hernia repairs over 15 years. Surg Endosc. 2009;23(3):482–6.

27. Bittner R, et al. Update of guidelines on laparoscopic (TAPP) and endoscopic (TEP) treatment of inguinal hernia (International Endohernia Society). Surg Endosc. 2015;29(2):289–321. 106

28. Eklund A, et al. Short-term results of a randomized clinical trial comparing Lichtenstein open repair with totally extraperitoneal laparoscopic inguinal hernia repair. Br J Surg. 2006;93(9):1060–8.

29. Choi YY, Kim Z, Hur KY. Learning curve for laparoscopic totally extraperitoneal repair of inguinal hernia. Can J Surg. 2012;55(1):33–6.

30. Park BS, et al. Factors influencing on difficulty with laparoscopic total extraperitoneal repair according to learning period. Ann Surg

31. Trevisonno M, Kaneva P, Watanabe Y, Fried GM, Feldman LS,

32.Andalib A, et al. Current practices of laparoscopic inguinal hernia repair: a population-based analysis. Hernia. 2015;19(5):725–33.

33. Trevisonno M, Kaneva P, Watanabe Y, Fried GM, Feldman LS, Lebedeva E, et al. A survey of general surgeons regarding laparoscopic inguinal hernia repair: practice patterns, barriers, and educational needs. Hernia. 2015;19(5):719–24.Treat Res. 2014;87(4):203–8..

34. Muschalla F, Schwarz J, Bittner R. Effectivity of laparoscopic inguinal

hernia repair (TAPP) in daily clinical practice: early and longterm result. Surg Endosc. 2016. doi:10.1007/s00464-016-4843-8

35. Simons MP, Aufenacker T, Bay-Nielsen M, Bouillot JL, Campanelli G, Conze J, et al. European Hernia Society guidelines on the treatment of inguinal hernia in adult patients. Hernia. 2009;13(4):343–403.

36. Bittner R, Arregui ME, Bisgaard T, Dudai M, Ferzli GS, Fitzgibbons RJ, et al. Guidelines for laparoscopic (TAPP) and endoscopic (TEP) treatment of inguinal hernia [International Endohernia Society (IEHS)]. Surg Endosc. 2011;25(9):2773–843.

37. Bansal VK, Misra MC, Babu D, Victor J, Kumar S, Sagar R, et al. A prospective, randomized comparison of long-term outcomes: chronic groin pain and quality of life following totally extraperitoneal (TEP) and transabdominal preperitoneal (TAPP) laparoscopic inguinal hernia repair. Surg Endosc. 2013;27(7):2373–82.

38. Kockerling F, Bittner R, Jacob DA, Seidelmann L, Keller T, Adolf D, et al. TEP versus TAPP: comparison of the perioperative outcome in 17,587 patients with a primary unilateral inguinal hernia. Surg Endosc. 2015;29(12):3750–60.

39. McKernan JB, Laws HL. Laparoscopic repair of inguinal hernias using a totally extraperitoneal prosthetic approach. Surg Endosc. 1993;7(1):26–8.

40. Bittner R, et al. Guidelines for laparoscopic (TAPP) and endoscopic (TEP) treatment of inguinal hernia [International Endohernia Society (IEHS)]. Surg Endosc. 2011;25(9):2773–843.

41. Dulucq JL, Wintringer P, Mahajna A. Laparoscopic totally extraperitoneal inguinal hernia repair: lessons learned from 3,100 hernia repairs over 15 years. Surg Endosc. 2009;23(3):482–6.

42 Bittner R, et al. Update of guidelines on laparoscopic (TAPP) and endoscopic (TEP) treatment of inguinal hernia (International Endohernia Society). Surg Endosc. 2015;29(2):289–321.

43 Bittner R, et al. One-year results of a prospective, randomised clinical trial comparing four meshes in laparoscopic inguinal hernia repair (TAPP). Hernia. 2011;15(5):503–10.

44. Eklund A, et al. Short-term results of a randomized clinical trial comparing Lichtenstein open repair with totally extraperitoneal laparoscopic inguinal hernia repair. Br J Surg. 2006;93(9):1060–8.

45. Choi YY, Kim Z, Hur KY. Learning curve for laparoscopic totally extraperitoneal repair of inguinal hernia. Can J Surg. 2012;55(1):33–6.

46. Park BS, et al. Factors influencing on difficulty with laparoscopic total extraperitoneal repair according to learning period. Ann Surg Treat Res. 2014;87(4):203–8.

47. Poelman MM, et al. EAES Consensus Development Conference on endoscopic repair of groin hernias. Surg Endosc. 2013;27(10):3505–19.

48. Garg P, et al. Laparoscopic total extraperitoneal inguinal hernia repair with nonfixation of the mesh for 1,692 hernias. Surg Endosc. 2009;23(6):1241–5.

49. Ferzli GS, Massad A, Albert P. Extraperitoneal endoscopic inguinal hernia repair. J Laparoendosc Surg. 1992;2(6):281–6.

50. Chowbey PK, et al. Extraperitoneal endoscopic groin hernia repair under epidural anaesthesia. Surg Laparosc Endosc Percutan Tech. 2003;13(3):185–90.

51. Misra MC, Kumar S, Bansal VK. Total extraperitoneal (TEP) mesh repair of inguinal hernia in the developing world: comparison of low-cost indigenous balloon dissection versus direct telescopic dissection: a prospective randomized controlled study. Surg Endosc. 2008;22(9):1947–58.

52. Arregui ME, Young SB. Groin hernia repair by laparoscopic techniques: current status and controversies. World J Surg. 2005;29(8):1052–7.

53. Winslow ER, Quasebarth M, Brunt LM. Perioperative outcomes and complications of open vs laparoscopic extraperitoneal inguinal hernia repair in a mature surgical practice. Surg Endosc. 2004;18(2):221–7.

54. Bringman S, et al. Is a dissection balloon beneficial in bilateral, totally extraperitoneal, endoscopic hernioplasty? A randomized, prospective, multicentre study. Surg Laparosc Endosc Percutan Tech. 2001;11(5):322–6.

55. Ramshaw B, et al. Laparoscopic inguinal hernia repair: lessons learned after 1224 consecutive cases. Surg Endosc. 2001;15(1):50–4.

56. Muysoms F, Campanelli G, Champault GG, Deneau AC, Dietz UA, Jeekel J, et al. EuraHS: the development of an international online platform for registration and outcome measurement of ventral abdominal wall hernia repair. Hernia. 2012;16(3):239–50.

57. Dindo D, Demartines N, Clavien P-A. Classification of surgical complications. Ann Surg. 2004;240(2):205–13.

58. Morales-Conde S. A new classification for seroma after laparoscopic ventral hernia repair. Hernia. 2012;16(3):261–7.

59. Kanters AE, Krpata DM, Blatnik JA, Novitsky YM, Rosen MJ. Modified hernia grading scale to stratify surgical site occurrence after open ventral hernia repairs. J Am Coll Surg. 2012;215(6): 787–93.

60. Petro CC, O'Rourke CP, Posielski NM, Criss CN, Raigani S, Prabhu AS, et al. Designing a ventral hernia staging system. Hernia. 2015;20(1):111–7.

61. Baucom RB, Ousley JM, Oyefule OO, Stewart MK, Holzman MD, Sharp KW, Poulose BK. Incisional hernia classification predicts wound complications two years after repair. Am Surg. 2015;81(7): 679–86.

62. Fischer JP, Basta MN, Mirzabeigi MN, Bauder AR, Fox JP, Drebin JA, et al. A risk model and cost analysis of incisional hernia after elective, abdominal surgery based upon 12,373 cases. Ann Surg. 2016;263(5):1010–7.

63 Regner JL, Mrdutt MM, Munoz-Maldonado Y. Tailoring surgical approach for elective ventral hernia repair based on obesity and Nsqip outcomes. Am J Surg. 2015;210(6):1024–30.

64 Yang GPC, Tung KLM. A comparative study of single incision versus conventional laparoscopic inguinal hernia repair. Hernia. 2015;19:401–5. doi:10.1007/s10029-014-1246-4.

65 Neumayer L, Giobbie-Hurder A, Jonas son O, Fitzgibbons Jr R, Dunlop D, Gibbs J, Reda D, Henderson W, Veterans Affairs Cooperative Studies Program 456 Investigators. Open mesh versus laparoscopic mesh repair of inguinal hernia. N Engl J Med. 2004;350(18):1819–27.

66. McCormack K, Scott NW, Go PM, Ross S, Grant AM, EU Hernia Trialists Collaboration. Laparoscopic techniques versus open techniques for inguinal hernia repair. Cochrane Database Syst Rev. 2003;1, CD001785

67.Bansal VK, Misra MC, Babu D, Victor J, Kumar S, Sagar R, Rajeshwari S, Krishna A, Rewari V. A prospective, randomized comparison of long-term outcomes: chronic groin pain and quality of life following totally extraperitoneal (TEP) and transabdominal preperitoneal (TAPP) laparoscopic inguinal hernia repair. Surg Endosc. 2013;27:2373–82. doi:10.1007/s00464-013-2797-7.

68. Miserez M, Peeters E, Aufenacker T, Bouillot JL, Campanelli G, Conze J, Fortelny R, Heikkinen T, Jorgensen LN, Kukleta J, Morales-Conde S, Nordin P, Schumpelick V, Smedberg S, Smietanski M, Weber G, Simons MP. Update with level 1 studies of the European Hernia Society guidelines on the treatment of inguinal hernia in adult patients. Hernia. 2014;18:151–63.

69 Fitzgerald HL, Orenstein SB, Novitsky YW. Small bowel obstruction owing to displaced spiral tack after laparoscopic TAPP inguinal hernia repair. Surg Laparosc Endosc Percutan Tech. 2010;20(3):e132–5. doi:10.1097/SLE.0b013e3181dfbc05.

70. Finley Jr RK, Miller SF, Jones LM. Elimination of urinary retention following inguinal herniorrhaphy. Am Surg. 1991;57:486;

71. Abramson JH, Gofin J, Hopp C, Makler A, Epstein LM. The epidemiology of inguinal hernia. A survey in western Jerusalem. J Epidemiol Community Health. 1978;32:59–67.

72. Ruhl CE, Everhart JE. Risk factors for inguinal hernia among adults in the US population. Am J Epidemiol. 2007;165:1154–61.

73. Pleumeekers HJ, De Gruijl A, Hofman A, Van Beek AJ, Hoes AW. Prevalence of aortic aneurysm in men with a history of inguinal hernia repair. Br J Surg. 1999;86:1155–8. K.K. Jensen et al.

74. Henriksen NA, Sorensen LT, Jorgensen LN, Lindholt JS. Lack of association between inguinal hernia and abdominal aortic aneurysm in a population-based male cohort. Br J Surg. 2013;100: 1478–82.

75. Liem MS, van der Graaf Y, Beemer FA, van Vroonhoven TJ. Increased risk for inguinal hernia in patients with Ehlers-Danlos syndrome. Surgery. 1997;122:114–5.

76. Lau H, Fang C, Yuen WK, Patil NG. Risk factors for inguinal hernia in adult males: a case-control study. Surgery. 2007;141:262–6.

77. Carbonell JF, Sanchez JL, Peris RT, Ivorra JC, Del Bano MJ, Sanchez CS, Arraez JI, Greus PC. Risk factors associated with inguinal hernias: a case control study. Eur J Surg. 1993;159:481–6.

78.. Schmedt CG, Sauerland S, and Bittner R. Comparison of endoscopic procedures vs Lichtenstein and other open mesh techniques for inguinal hernia repair: a meta-analysis of randomized controlled trials. Surg Endosc 2005;19:188-199.

79. Poobalan AS, Bruce J, King PM, Chambers WA, Krukowski ZH, Smith WC. Chronic pain and quality of life following open inguinal hernia repair. Br J Surg. 2001;88(8):1122–6.

80. Aasvang E, Kehlat H. Chronic postoperative pain: the case of inguinal herniorrhaphy. Br J Anaesth. 2005;95:69–76.

81. Sajid MS, Craciunas L, Singh KK, Sains P, Baig MK. Open transinguinal reperitoneal mesh repair of inguinal hernia: a targeted systematic review and meta-analysis of published randomized controlled trials. Gastroenterol Rep. 2013;1:127–37. doi:10.1093/gastro/got002

82. Miserez M, Peeters E, Aufenacker T, Bouillot JL, Campanelli G, Conze J, Fortelny R, Heikkinen T, Jorgensen LN, Kukleta J, Morales-Conde S, Nordin P, Schumpelick V, Smedberg S, Smietanski M, Weber G, Simons MP. Update with level 1 studies of the European Hernia Society guidelines on the treatment of inguinal hernia in adult patients. Hernia. 2014;18:151–63.

83. Kockerling F, Stechemesser B, Hukauf M, Kuthe A, Schug-Pass C. TEP versus Lichtenstein: which technique is better for the repair of primary

unilateral inguinal hernias in men? Surg Endosc. 2015.doi:10.1007/s00464-015-4603-1.

84. Sharma D, Yadav K, Hazrah P, Borgharia S, Lal R, Thomas S. Prospective randomized trial comparing laparoscopic transabdominal preperitoneal (TAPP) and laparoscopic totally extraperitoneal (TEP) approach for bilateral inguinal hernias. Int J Surg. 2015;22:110–7. doi:10.1016/j.ijsu.2015.07.713.

85. Kockerling F, Bittner R, Jacob DA, Seidelmann L, Keller T, Adolf D, Kraft B, Kuthe A. TEP versus TAPP: comparison of the perioperative outcome in 17,587 patients with a primary unilateral inguinal hernia. Surg Endosc. 2015;29:3750–60. doi:10.1007/ s00464-015-4150-9.

MASTER CHART

Sno.	Name	IpNo.	Age	Sex	Diagnosis	Diagnosis	Comorbidities	Procedure done	Duration of surgery	vascular injury	visceral injury	Urinary retention	postoperative pain	seroma	Hematoma	wound infection	time of discharge	recurrence
					Side	Type												
1	Srinivasan	1715028	50	M	L	M	DM	L	60	0	0	0	8	0	0	0	5	0
2	Subramani	1717863	63	M	R	L	COPD	L	50	0	0	0	6	1	0	0	7	0
3	Manikandan	1718993	48	M	R	L	0	L	60	0	0	0	7	0	0	0	5	0
4	Beerkhan	1719411	62	M	R	L	0	L	60	0	0	0	8	0	0	1	8	0
5	Sivaprakasam	1714364	53	M	L	L	0	L	60	0	0	0	8	0	0	0	4	0
6	Govindasamy	1710392	44	M	R	L	0	L	40	0	0	0	7	0	0	0	5	0
7	Palani	1710256	56	M	R	L	0	L	70	0	0	0	7	0	0	0	4	0
8	Shenbagarathai	1720785	25	M	R	L	0	L	50	0	0	0	6	0	0	0	5	0
9	Sarathy	1722185	70	M	L	L	DM	L	60	0	0	1	8	0	1	1	9	0
10	Babu	1722349	49	M	R	L	0	L	60	0	0	0	8	0	0	0	5	0
11	Kamal	1720205	45	M	R	L	0	L	50	0	0	0	7	0	0	0	5	0
12	Srinivasan	1723234	48	M	R	L	0	L	60	0	0	0	7	1	0	0	5	0
13	Kannappan	1722230	35	M	L	L	0	L	60	0	0	0	8	0	0	0	5	0
14	Palani	1719128	38	M	R	L	0	L	40	0	0	0	8	0	0	0	4	0
15	Govindasamy	1722287	44	M	L	L	0	L	45	0	0	0	7	0	0	0	5	0
16	Tamim Ansari	1738463	63	M	R	L	HTN	L	70	0	0	1	7	0	0	0	5	0
17	Prakash	1720663	68	M	L	L	COPD	L	60	0	0	0	7	1	0	0	5	0
18	Selvam	1722088	49	M	R	L	0	L	50	0	0	0	7	1	0	0	5	0
19	Rajendran	1723156	43	M	L	L	0	L	50	0	0	0	7	0	0	0	5	0
20	Sekar	1723217	51	M	L	L	0	L	60	0	0	0	8	0	0	0	5	0
21	Somapandiyan	1724668	51	M	R	M	0	L	60	0	0	0	8	0	0	0	4	0
22	Rajendran	1713767	42	M	R	L	0	L	50	0	0	0	8	1	0	0	4	0
23	Saran	1723070	48	M	R	L	HTN	L	50	0	0	0	8	0	0	0	5	0

24	Karunakaran	1725057	38	M	R	L	0	L	40	0	0	0	8	1	0	0	4	0
25	Balaraman	1724028	60	M	R	L	CAD	L	60	0	0	0	7	1	0	0	4	0
26	Akbarbasha	1724042	48	M	L	L	0	TEP	110	0	0	0	8	0	0	0	3	0
27	Sreeram	1724232	52	M	R	L	0	TEP	120	0	0	0	8	0	0	0	3	0
28	Raman	1721370	53	M	R	M	0	TEP	120	0	0	0	8	0	0	0	3	0
29	Sathhyaraj	1725706	26	M	L	L	0	TEP	100	0	0	0	6	0	0	0	3	0
30	Shahul Hameed	1725795	47	M	R	L	0	TEP	120	0	0	0	6	0	0	0	4	0
31	Mani	1725015	58	M	R	L	DM	TEP	90	0	0	0	6	0	0	0	3	0
32	Hari	1712150	41	M	R	L	0	TEP	100	0	0	0	6	0	0	0	3	0
33	Elangovan	1723008	38	M	R	L	0	TEP	110	0	0	0	7	0	0	0	3	0
34	Gunasekaran	1726476	36	M	R	L	0	TEP	100	0	0	0	7	0	0	0	3	0
35	Madan	1727080	49	M	L	L	0	TEP	110	0	0	0	6	0	0	0	3	0
36	Abdul Nasar	1724272	62	M	R	P	DM	TEP	110	0	0	0	6	0	0	0	3	0
37	Chandran	1728079	44	M	R	L	0	TEP	120	0	0	0	6	0	0	0	3	0
38	Subramani	1728058	52	M	L	L	0	TEP	90	0	0	0	6	0	0	0	3	0
39	Ramu	1728810	24	M	L	L	0	TEP	100	0	0	0	6	0	0	0	2	0
40	Mohan	1727274	46	M	R	L	0	TEP	100	0	0	0	7	0	0	0	3	0
41	Alagesan	1728125	60	M	R	L	0	TEP	90	0	0	0	6	0	0	0	5	0
42	Venkatesh	1729508	55	M	R	L	0	TEP	90	0	0	0	6	0	0	0	3	0
43	Datchinamoorthy	1723126	33	M	R	L	0	TEP	100	0	0	0	6	0	0	0	3	0
44	Parthiban	1729129	61	M	R	L	0	TEP	90	0	0	0	7	0	0	0	2	0
45	Natarajan	1708773	47	M	R	M	0	TEP	80	0	0	0	8	0	0	0	3	0
46	Mathialagan	1729495	58	M	L	L	0	TEP	90	0	0	0	7	0	0	0	2	0
47	Prabhakaran	1726946	61	M	R	L	HTN	TEP	90	0	0	0	7	0	0	0	2	0
48	Shankar	1729522	43	M	R	L	0	TEP	100	0	0	0	6	0	0	0	3	0
49	Venkatraj	1731485	62	M	R	L	0	TEP	110	0	0	0	4	0	0	0	3	0
50	Selvam	1731144	50	M	L	L	0	TEP	90	0	0	0	8	0	0	0	3	0
51	Selvadurai	1731247	35	M	R	L	0	TAPP	110	0	0	0	7	0	0	0	4	0

52	Ajith	1730451	44	M	R	L	0	TAPP	110	0	0	0	7	0	0	0	3	0
53	Prabakaran	1732456	58	M	R	L	0	TAPP	120	0	0	0	6	0	0	0	3	0
54	Gopi	1733633	56	M	R	L	0	TAPP	120	0	0	0	7	0	0	0	4	0
55	Kathavarayan	1733705	52	M	L	L	0	TAPP	110	0	0	0	8	0	0	0	3	0
56	Pandiyan	1733674	44	M	L	L	0	TAPP	110	0	0	0	7	0	0	0	3	0
57	Philips	1732631	62	M	L	L	DM	TAPP	100	0	0	0	7	0	0	0	3	0
58	Deenadayalan	1733258	39	M	R	L	0	TAPP	110	0	0	0	7	0	0	0	5	0
59	Paul	1731679	43	M	R	L	0	TAPP	110	0	0	0	7	0	0	0	3	0
60	Kiana Bahadur	1736751	42	M	R	L	0	TAPP	110	0	0	0	7	0	0	0	3	0
61	Pandurangan	1736720	41	M	R	L	0	TAPP	120	0	0	0	8	0	0	0	3	0
62	Krishnamoorthy	1735014	54	M	R	L	0	TAPP	100	0	0	0	7	0	0	0	6	0
63	Abdul Rahman	1736750	62	M	R	L	0	TAPP	120	0	0	0	6	0	0	0	3	0
64	Maildasan	1738386	31	M	R	L	0	TAPP	120	0	0	0	6	0	0	0	3	0
65	Mohammad Ali	1720588	37	M	R	L	0	TAPP	110	0	0	0	4	0	0	0	3	0
66	Selvam	1738119	58	M	R	L	0	TAPP	110	0	0	0	6	0	0	0	3	0
67	Ramankutty	1736128	60	M	R	L	0	TAPP	110	0	0	0	7	0	0	0	12	1
68	Palaiyam	1738995	54	M	L	L	0	TAPP	120	0	0	0	7	0	0	0	3	0
69	Shanmugam	1739887	41	M	L	M	0	TAPP	100	0	0	0	7	0	0	0	3	0
70	William	1742278	33	M	L	L	0	TAPP	100	0	0	0	6	0	0	0	3	0
71	Pradeep	1739845	59	M	R	L	0	TAPP	90	0	0	0	7	0	0	0	3	0
72	Abdul Lateef	1743032	61	M	R	L	HTN	TAPP	80	0	0	0	6	0	0	0	3	0
73	Veeraragavan	1745350	53	M	R	L	0	TAPP	90	0	0	0	7	0	0	0	3	0
74	Dhanaraj	1746845	46	M	R	L	0	TAPP	90	0	0	0	6	0	0	0	2	0
75	Saravanan	1746801	57	M	R	L	0	TAPP	90	0	0	0	7	0	0	0	3	0

URKUND

Urkund Analysis Result

Analysed Document: Thesis - final.docx (D31050560)
Submitted: 10/5/2017 7:49:00 PM
Submitted By: ktsreekanth06@gmail.com
Significance: 10 %

Sources included in the report:

28.09.2017 Thesis typing.docx (D30912879)
DISSERTATION.docx (D22508517)
Peder Rogmark 2017_02_14 Plagiatkontroll kappa & manuscript.pdf (D25815186)
PARAUMBLICAL.docx (D30957749)
140004867-Diss-2232010.pdf (D27172140)
http://emedicine.medscape.com/article/2075362-overview
https://link.springer.com/article/10.1007/s10029-006-0152-9
https://link.springer.com/chapter/10.1007/978-3-319-43045-4_7
http://www.anzjsurg.com/view/0/clavienClassification.html
http://uroweb.org/guideline/urological-trauma/
http://emedicine.medscape.com/article/1534281-overview
https://link.springer.com/article/10.1007/s00464-016-5258-2
https://link.springer.com/article/10.1007/s00464-014-3857-3
https://link.springer.com/article/10.1007/s00464-003-8185-y
http://jamanetwork.com/journals/jamasurgery/fullarticle/405875
https://www.uptodate.com/contents/overview-of-complications-of-inguinal-and-femoral-hernia-repai
http://www.aqc.ch/download/Clavien-Dindo%20Classification.pdf

PLAGIARISM CERTIFICATE

This is to certify that this dissertation work titled

"Comparative study of complications following laparoscopic TEP versus TAPP versus open hernioplasty in inguinal hernia repair"

of the candidate K.T.SREEKANTH with registration Number 221511061 for the award of **M.S. DEGREE EXAMINATION** in the branch of **BRANCH I GENERAL SURGERY**.

I personally verified the urkund.com website for the purpose of plagiarism Check. I found that the uploaded thesis file contains from introduction to conclusion pages and result shows 9 percentage of plagiarism in the dissertation.

Guide & Supervisor sign with Seal.

GOVT.STANLEY MEDICAL COLLEGE, CHENNAI- 600 001

INFORMED CONSENT

DISSERTATION TOPIC:

"COMPARATIVE STUDY OF COMPLICATIONS FOLLOWING LAPARASCOPIC TEP VERSUS TAPP VERSUS OPEN HERNIOPLASTY IN INGUINAL HERNIA REPAIR"

Place of study: Govt. Stanley medical college, Chennai

I ……. have been informed about the details of the study in my own language.

I have completely understood the details of the study.

I am aware of the possible risks and benefits, while taking part in the study.

I agree to collect samples of blood/saliva/urine/tissue if study needs.

I understand that I can withdraw from the study at any point of time and even then, I can receive the medical treatment as usual.

I understand that I will not get any money for taking part in the study.

I will not object if the results of this study are getting published in any medical journal, provided my personal identity is not revealed.

I know what I am supposed to do by taking part in this study and I assure that I would extend my full cooperation for this study.

Volunteer:	Witness:
Name and address	Name and address
Signature/thumb impression:	Signature/thumb impression
Date:	Date:

PROFORMA

SL. NO:

- **NAME :** **AGE /SEX:** **IP NO:**
- **ADDRESS WITH CONTACT NUMBER:**
- **DATE OF ADMISSION:**
- **DATE OF DISCHARGE:**

- **FINAL DIAGNOSIS**:
- P = primary hernia 0 = no hernia detectable

  L = lateral/ indirect hernia

  M = medial/ direct hernia
- Co morbid disease:

Details of surgery

- Pre-op diagnosis
- Post op diagnosis
- Procedure done
- Duration of surgery
- Amount of bleeding
- Injury to major structures
- Conversion from lap to open (TEP vs TAPP)

- **Post operative complications**
- Post operative Pain as analysed with VAS and analgesic used.
- Urinary Retention
- Wound Seroma
- Wound hematoma
- Suture site infection
- Bowel Complication
- Recurrence
- Total duration of hospital stay

INSTITUTIONAL ETHICAL COMMITTEE,
STANLEY MEDICAL COLLEGE, CHENNAI-1

Title of the Work : Comparative study of complications following laparoscopic TEP versus TAPP versus open hernioplasty .

Principal Investigator : Dr. K T Sreekanth

Designation : PG MS (General Surgery)

Department : Department of General Surgery
Government Stanley Medical College,
Chennai-01

The request for an approval from the Institutional Ethical Committee (IEC) was considered on the IEC meeting held on 02.12.2016 at the Council Hall, Stanley Medical College, Chennai-1 at 2PM

The members of the Committee, the secretary and the Chairman are pleased to approve the proposed work mentioned above, submitted by the principal investigator.

The Principal investigator and their team are directed to adhere to the guidelines given below:

1. You should inform the IEC in case of changes in study procedure, site investigator investigation or guide or any other changes.
2. You should not deviate from the area of the work for which you applied for ethical clearance.
3. You should inform the IEC immediately, in case of any adverse events or serious adverse reaction.
4. You should abide to the rules and regulation of the institution(s).
5. You should complete the work within the specified period and if any extension of time is required, you should apply for permission again and do the work.
6. You should submit the summary of the work to the ethical committee on completion of the work.

MEMBER SECRETARY, 4/1/17
IEC, GMC, CHENNAI

MEMBER SECRETARY
ETHICAL COMMITTEE,
STANLEY MEDICAL COLLEGE
CHENNAI-600 001.