Supinator Muscle and the Anatomical Basis for the Posterior Interosseous Nerve Entrapment

Dissertation submitted for

M.D Anatomy Branch V Degree Examination,

The Tamil Nadu Dr.M.G.R. Medical University

Chennai, Tamil Nadu.

May – 2018

DECLARATION

I hereby declare that the dissertation entitled **"Supinator muscle and the anatomical basis for posterior interosseous nerve entrapment"** is a bonafide research work done by me under the supervision of Dr. Bina Isaac., Professor of Anatomy, Christian Medical College, Vellore, in partial fulfilment of the requirements for the MD Anatomy examination (Branch V) of the Tamil Nadu Dr. M.G.R. Medical University, Chennai to be held in May 2018.

Name: Dr. Jenny Jacob

MD Anatomy (Branch V)

CERTIFICATE

This is to certify that **"Supinator muscle and the anatomical basis for posterior interosseous nerve entrapment"** is a bonafide work of **Dr. Jenny Jacob** in partial fulfillment of the requirements for the M.D Anatomy examination (Branch V) of The Tamil Nadu Dr. M.G.R. Medical University to be held in May 2018.

Dr. Bina Isaac, M.S,
Professor and Guide,
Department of Anatomy,
Christian Medical College,
Vellore, Tamil Nadu.

CERTIFICATE

This is to certify that **"Supinator muscle and the anatomical basis for posterior interosseous nerve entrapment"** is a bonafide work of **Dr. Jenny Jacob** in partial fulfillment of the requirements for the M.D Anatomy examination (Branch V) of The Tamil Nadu Dr. M.G.R. Medical University to be held in May 2018.

Suganthy

Dr. J. Suganthy, M.S, D.N.B, Ph.D
Professor and Head,
Department of Anatomy,
Christian Medical College,
Vellore, Tamil Nadu.

Professor & Head
Department of Anatomy
Christian Medical College
Vellore - 632 002
Tamil Nadu, S. INDIA

Dr. Anna. B. Pulimood, M.D
Principal,
Christian Medical College,
Vellore, Tamil Nadu.

CERTIFICATE - II

This is to certify that this dissertation work titled SUPINATOR MUSCLE AND THE ANATOMICAL BASIS FOR THE POSTERIOR INTEROSSEOUS NERVE ENTRAPMENT of the candidate ....DR. JENNY JACOB..... with registration Number 201533202 for the award of .....M.D..... in the branch of .ANATOMY..... . I personally verified the urkund.com website for the purpose of plagiarism Check. I found that the uploaded thesis file contains from introduction to conclusion pages and result shows ...1%.. percentage of plagiarism in the dissertation.

Guide & Supervisor sign with Seal.

Professor
Department of Anatomy
Christian Medical College
Vellore - 632 002.
Tamilnadu, S.India.

PLAGERISM SCREENSHOT

URKUND

Urkund Analysis Result

Analysed Document: Thesis for plagerism.docx (D30276294)
Submitted: 2017-08-29 09:07:00
Submitted By: dr.jennyjacob@gmail.com
Significance: 1 %

Sources included in the report:

http://onlinelibrary.wiley.com/doi/10.1002/ar.21275/full

Instances where selected sources appear:

1

ACKNOWLEDGEMENTS

- I thank God Almighty for helping me finish this thesis with His presence in each and every step
- I am grateful to the Institutional Review Board (IRB) of Christian Medical College, Vellore for giving me the permission and funding for this project
- I sincerely thank Dr. Bina Isaac, my guide for entrusting and encouraging me to start this study and for being an inspiration and support all the time
- Dr . Visalakshi. J, Lecturer, Department of Biostatistics for helping me in calculation of sample size and analysis of the thesis data
- Dr. J. Suganthy (Professor and Head of Department), Department of Anatomy for her prayer, support and encouragement throughout the study
- To all Associate Professors and Assistant professors for their help in times of need
- To all co - postgraduates for their valuable suggestions, help and encouragement
- Mr. K. R. Gopi and Mr. Balakrishnan, technicians in the gross anatomy dissection hall for all the help during the dissection work for the thesis
- To all non- teaching staff in the Department of Anatomy – Mr. S.Thirumurugan (late), Mr. Antonyswamy, Mr. R. Gopi, Mr. Dhandapani, Mr. Babu, Mr. Collin, Mr. N. Narayanan for their help with arrangement of cadavers and support all the time

- Mr. V. Gopinath (Secretary) and Mr. G. Rajkumar (Artist) in the Department of Anatomy for their timely help
- To all generous volunteers who donated bodies
- Finally I thank all my family members for their constant support, encouragement and prayers

CONTENTS

1. INTRODUCTION

The supinator muscle belongs to the deep group of extensor muscles of the forearm. It has two heads of origin – a superficial and a deep head. The superficial head originates from the lateral epicondyle, the annular ligament and the radial collateral ligament of the elbow joint. The deep head originates from the supinator crest on the posterolateral surface of the ulna. The two heads wrap around the posterior and lateral aspects of the head, neck and proximal shaft of the radius to insert on the lateral surface of the shaft of the radius. The supinator helps in supination of the forearm and hand and is innervated by the deep branch of the radial nerve (DBRN) called the posterior interosseous nerve (PIN). The posterior interosseous nerve (PIN) supplies supinator, then passes between the two heads of the muscle and continues in the forearm. The other muscles supplied by the PIN are the extensors of the superficial group namely extensor digitorum communis, extensor digiti minimi and extensor carpi ulnaris. In the deep group of extensors, the PIN supplies abductor pollicis longus, extensor pollicis brevis, extensor pollicis longus and extensor indicis proprius. The posterior interosseous nerve is sensory to the dorsal aspect of the wrist joint (1).

Entrapment neuropathies of the upper extremity are common, debilitating conditions. Several authors have described a host of structures, including the arcade of Frohse, that may lead to compression of the PIN in the forearm region (2,3). Adhesions between the brachialis and brachioradialis muscles, the edge of the extensor carpi radialis brevis, fibrous bands associated with the supinator

muscle, and a set of vascular arcades termed the 'leash of Henry' are other factors implicated in PIN neuropathy (4). Idiopathic entrapment occurs in 0.7% of cases.

The arcade of Frohse (AF) was so named by Frohse and Frankel in 1908 (5). It was Kopell and Thompson who first reported the entrapment of the deep branch of radial nerve (DBRN) by the arcade of Frohse (6). Capener described the vulnerability of the DBRN at the AF in 1966 (7) and later in 1968, Spinner stated that there could be compression of the DBRN at the AF (8). Many workers have found that the AF is the most common structure causing entrapment of PIN (4,9–12).

Entrapment of the PIN may present in one of two distinct ways: with a painless palsy (sometimes preceded by transient extensor forearm aching) or as a painful condition. It may develop after strenuous use of the forearm, following blunt injury, or develop insidiously. There may be pain or tenderness over the nerve in the extensor muscle group approximately 3 cm distal to the elbow itself. Posterior interosseous nerve palsy may be either complete or partial (13).

The initial treatment of posterior interosseous nerve palsy is conservative therapy—including rest, modification of behavior, nonsteroidal medications, and sometimes steroid injections (2,13). Surgery is indicated, if there is no relief of symptoms even after 3 months.

In the present study, the location of structures that can be a cause of posterior interosseous nerve entrapment are described, the knowledge of which can help the surgeon in decompression procedures. The arcade of Frohse is the structure that is most often implicated in posterior interosseous nerve compression and its

morphometry has been studied in detail. The useful and reproducible reference landmarks that have been determined can help in the surgical treatment of posterior interosseous nerve entrapment.

2. AIMS

1. To study the internal architecture of the supinator muscle in order to describe potentially compressive structures for the posterior interosseous nerve.
2. To establish reference landmarks for the surgical treatment of posterior interosseous nerve neuropathy.

3. OBJECTIVES

1. To determine the division of the radial nerve in relation to the transepicondylar line and humeroradial joint line.
2. To determine the nature of the proximal and distal borders of superficial layer of supinator muscle.
3. To determine the nature of the superomedial margin of extensor carpi radialis brevis muscle.
4. To measure the distance between humeroradial joint line and the structures that cause compression of the posterior interosseous nerve.
5. To measure the distance between transepicondylar line and the structures that cause compression of the posterior interosseous nerve.
6. To determine the location of arcade of Frohse.
7. To determine the morphometry of the arcade of Frohse.
8. To determine the pennation angles of the superficial and deep layers of the supinator muscle.
9. To determine the distance between the lateral epicondyle and the entry and exit of posterior interosseous nerve (PIN) from supinator.
10. To determine the distance between the radial head and proximal and distal borders of superficial layer of supinator muscle.
11. To determine the distance between the radial head and the entry and exit of posterior interosseous nerve (PIN) from supinator.
12. To determine the innervation pattern of the supinator muscle.

4. REVIEW OF LITERATURE

The supinator muscle

The supinator muscle is a composite muscle (14). It spirals around the proximal third of the radius. It has two layers, superficial and deep, between which the posterior interosseous nerve passes through.

Davis et al.(15) described the complex structure of the supinator muscle in a study done on 21 upper limbs. He reported that the superficial layer of the supinator muscle originated partly from the lateral epicondyle of the humerus, the annular ligament around the head of the radius, and partially from the supinator crest of the ulna. The superficial fibres of the superficial layer of supinator were tendinous in nature and deeper fibres were muscular. The superficial layer inserted on the anterior and the lateral surface of the proximal third of radius. The deeper layer originated from the lower margin of the annular ligament, supinator crest and posterior part of the triangular depression in front of the supinator crest. The origin of deeper layer was slightly anterior to the origin of the superficial layer and inserted chiefly into the lateral and posterior part of the proximal third of the radius . It was noted that the deep layer extended 1.5 cm beyond the superficial layer. Twelve specimens showed a bare, smooth area on the radius between the insertions of the superficial and deep layers of the supinator muscle. The position and the size of this area varied according to the insertion of

the deep layer of the muscle. The length of the area was calculated to be 1.7 – 3.5 cm and breadth was 0.4 – 1.0 cm.

Berton et al. (14) did a study on the structure of the supinator muscle in 30 upper limbs. He described that all the limbs had two layers. The superficial layer originated from the lateral epicondyle by a tendinous band and from the ulna as a tendinous body. The deep layer originated from the lateral epicondyle, lateral collateral ligament and the supinator crest on the ulna. It had both tendinous and fleshy fibres. It was noted that the fibres of both the layers were directed distally, anteriorly, and laterally. Two thirds of the superficial aspect of the superficial layer was tendinous and muscular. The deeper aspect of the superficial layer was muscular whereas the deep layer was purely muscular except at the point of origin. The superficial layer had two arcades at the entry and exit of posterior interosseous nerve described as proximal arcade (arcade of Frohse) and distal arcade.

Proximal arcade of superficial layer of supinator (arcade of Frohse)

An entrapment neuropathy is defined as a pressure-induced segmental injury to a peripheral nerve from an anatomic or pathologic process (16). The posterior interosseous nerve can be compressed due to intrinsic and extrinsic factors leading to paralysis of muscles supplied by it. There are various anatomic factors implicated in the entrapment of the posterior interosseous nerve of which the arcade of Frohse is the most common (17). The proximal portion of the superficial layer of the supinator muscle formed a fibrous edge which was first described by Frohse and Frankel in the year 1908 (5).

Spinner (1968) reported a study of upper limbs of 25 adults and 10 full term foetuses and described the arcade of Frohse as a semicircular tendinous arch from the tip of the lateral epicondyle. The fibres arch downwards to attach on the medial aspect of the lateral epicondyle. The posterior interosseous nerve enters the plane between the superficial and the deep heads of the supinator muscle after passing under the edge of the arcade of Frohse. He reported that in 70% of specimens, the medial half of the arcade was membranous and in 30% the medial half of the arcade was tendinous just as the lateral half. In newborn foetuses, he reported that the tendinous edge of the arcade of Frohse was not demonstrable and it was said to be muscular (8).

Ozturk et al. (5) did a study in 55 upper limbs where they studied the shape, width, length, and thickness of the arcade. The shape of the arcade was classified into two based on Prasartritha et al. (10), where if the medial and lateral halves of the arcade were fibrous, it was considered tendinous and if the medial half of the arch was muscular and lateral half tendinous, it was considered membranous. The results showed that 87% of the arcade in upper limbs were tendinous and 13% membranous. The width was found to be 10.13 ± 2.10 mm, length was 8.60 ± 3.51 mm, and thickness of arcade was 0.77 ± 0.34 mm.

Berton et al. (14) did a similar study on the shape of the arcade of Frohse on 30 upper limbs based on the classification by Debouck and Rooze (9). The classification was - the arcade of Frohse was tendinous, if the fibres were pearly white in appearance, musculotendinous if the fibres were muscular and tendinous, muscular if it was similar to muscle fibres, and

membranous if the fibres were a fine unorganised sheet. It was found that in 66% of upper extremities it was tendinous, in 17% musculotendinous and in 17% muscular.

Konjengam and Elangbam (18) in their study with forty six upper limbs, found that the superior border of the superficial layer of supinator (arcade of Frohse) was tendinous in 40 (87%) upper extremities and musculotendinous in 6 (13%) specimens.

Clavert et al. (17) found in their study of thirty upper limbs, that the superior border of the superficial layer of supinator (arcade of Frohse) was tendinous in 87% of cases and membranous in 13%.

Debouck and Rooze (9) found the arcade of Frohse to be tendinous in 64%, musculotendinous in 22%, muscular in 12% and membranous in 2% in the 106 upper extremities of their study.

Ebraheim et al. (19) found the arcade of Frohse to be tendinous in 70% and membranous in 30% in 20 upper extremities.

Ozkan et al. (12) found the arcade of Frohse to be tendinous in 80% of the specimens and membranous in 20% in 60 upper limbs.

Papadopoulos et al. (20) found the arcade of Frohse to be tendinous in 61% among the 120 upper limbs studied.

Prasartritha et al.,(10) found the arcade of Frohse to be tendinous in 57% and membranous in 43% among the 60 upper limbs studied.

The arcade of Frohse was tendinous in 52%, musculotendinous in 40%, and membranous in 8% in the 25 specimens of the study by Riffaund et al. (21).

Thomas et al. (11) did a study on 31 upper extremities and found the arcade of Frohse to be tendinous in 32%, and membranous in 68%.

Hazani et al. (22) found the proximal border of superficial layer of supinator to be tendinous in 14 of their 18 dissections (78%).

High percentages of tendinous arcade of Frohse were seen in certain clinical studies (Werner - 89% and Lister et al. 100%) (23,24).

The width, length, and thickness of arcade of Frohse was determined by Ebraheim et al. (19) in both males and females. The width was found to be 2.8mm, length 18.6mm, thickness 0.8mm in males and in females, the width was found to be 2.5mm, length 18.5mm, and thickness 0.7mm.

Clavert et al. (17) found the length of the arcade of Frohse to be 26 ± 5 mm (range: 16.9 – 32.4 mm).

The average thickness of arcade of Frohse was found to be 0.7 mm (14).

Predicted distance of arcade of Frohse

Ozturk et al. (5) from their study found that surgeons can predict the distance of arcade of Frohse of any upper extremity by dividing the forearm length by 5 (predicted distance AF = forearm length of the patient/5).

Distal arcade of superficial layer of supinator

Berton et al. (14), in their study of thirty upper limbs found the distal arcade to be tendinous in 37%, musculotendinous in 33%, muscular in 27% and membranous in 3%.

Konjengam and Elangbam (18), in their study of forty six upper limbs found the distal arcade to be tendinous in 65%, musculotendinous in 11%, muscular in 22% and membranous in 2%.

Prasartritha et al. (10) found the distal arcade to be tendinous in 65% and membranous in 35% among the 60 upper limbs studied.

The distal arcade was tendinous in 4%, musculotendinous in 8%, and muscular in 88% in the twenty five specimens of the study by Riffaund et al. (21).

Hazani et al. (22) found the distal border of superficial layer of supinator to be tendinous in 10 of their 18 dissections (55%).

Pennation angle

Pennation angle is an important factor in determining the force acting along the line of action. It is defined as the angle between the direction of the muscle fibres and the axis of the tendon to which it is attached (25)(Fig.1). It varies in different muscles from 0° to 30°. It is said that the angle increases during muscle contraction and in muscle hypertrophy (26).

Berton et al. (14) did a study on the pennation angle of the superficial and deep fibres of the supinator muscle. They measured the direction of fibres to the radius shaft axis. The pennation angle of the superficial layer was 33.6° ± 4.2° (range: 28° to 41°) and of the deep layer was 50.2° ± 6.6 °.

Papadopoulos et al. (20) found the pennation angle of the superficial layer varied from 18° to 38°.

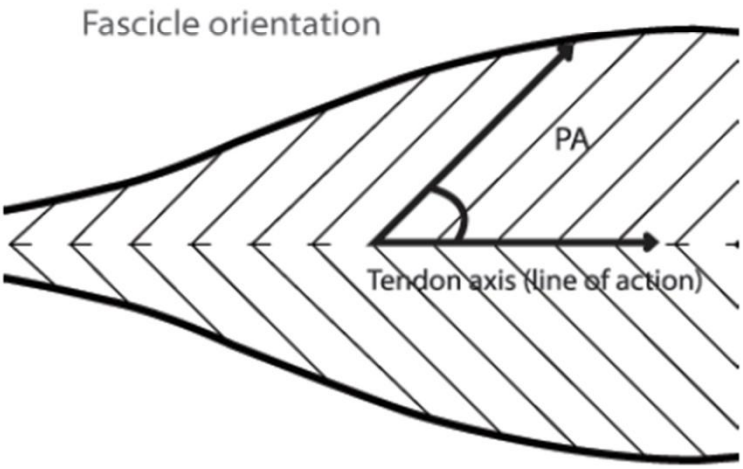

Fig. 1 Schematic representation of pennation angle
PA – pennation angle

Line diagram ref: Lee D. A 3 dimensional approach to pennation angle estimation for human skeletal muscle.
Journal of biomechanics(2013)

Clavert et al. (17) found the pennation angle of the superficial layer to be 23° (range: 7° to 49°).

Causes of compression of posterior interosseous nerve

The posterior interosseous nerve lies between the superficial and deep layers of the supinator muscle (8). There are several factors that cause compression of the posterior interosseous nerve. It includes traumatic and non traumatic causes including pathological and anatomical factors. The proximal portion of the superficial layer of the supinator muscle was described as the arcade of Frohse (14). It was reported to be the most common site for entrapment of posterior interosseous nerve (5,8,11,17,22). The posterior interosseous nerve compression was severe if along with the tendinous arcade of Frohse, there was some other pathological condition (23).

The posterior interosseous nerve lies within the radial tunnel which begins at the division of the radial nerve into superficial and posterior interosseous nerve at the humeroradial joint and ends where the PIN exits the supinator muscle. Structures within the radial tunnel that can cause compression of posterior interosseous nerve are fibrous fascial bands coursing superficial to the radial head, radial recurrent artery and its venae comitantes, leash of Henry, the proximal fibrous edge of extensor carpi radialis brevis, proximal edge and distal edge of the superficial layer of the supinator muscle (22).

The tendinous margin of ECRB can compress the PIN before it enters the arcade of Frohse. Vergara et al. (27) did a study on 21 upper limbs and examined the position of ECRB in relation to the arcade of Frohse and posterior interosseous nerve. There was an aponeurosis under the ECRB. The width of the aponeurosis under ECRB had severe thickness in 14.3%, moderate thickness in 57.2 % and mild in 28.5 %. A tendinous arch was found at the superomedial margin of ECRB in 95.2 % of specimens. The arch of ECRB was in direct contact with the PIN in 71.5%. In 9.5%, the tendinous arch of ECRB was at the level of arcade of Frohse and in 19%, it was in a distal position without direct contact with the PIN. The width of the aponeurosis underlying ECRB was 14.6 mm.

Clavert et al. (17) reported that the posterior interosseous nerve was less frequently compressed by deep layer of the supinator muscle. They reported that repetitive pronation and supination of the forearm promotes compression of the radial nerve and its two branches. It is aggravated during repeated activity of supinator muscle and the perineurial pressure is increased during continous sustained supination.

Iatrogenic compression of PIN may occur after surgical procedures involving the proximal radioulnar joint (28). Recompression of the PIN by scarring was found in as much as 17% of 110 patients who were operated for compression syndrome of radial nerve. This proved to be a serious complication of direct decompression of the PIN (29).

Konjengam and Elangbam (18) studied 46 upper limbs and described the presence of fat and fibrous adhesions between anterior part of the humeroradial joint capsule and posterior interosseous nerve. Fibrous adhesions were seen in 50% of cases, and vascular arcades in 72%. The radial recurrent artery was noticed posterior to PIN in 85% cases, posteromedial to PIN in 8.7% and anterior to PIN in 6.5% specimens.

The PIN is susceptible to traumatic and non traumatic entrapment which include ganglions, bursitis, lipoma, radial head fractures like Monteggia fracture, radial head dislocation, and rheumatoid arthritis (30,31).

Variations of the supinator muscle could be a possible element like accessory fasciculus from lateral epicondyle and fibres inserted into tendon of biceps or a bursa under the radial tuberosity. An accessory muscle called supinator brevis accessories muscle may be present and cause compression of PIN. It can arise as a slip from the lower border of brachialis and get inserted to the radial tuberosity (32).

Thomas et al. (11) found in their study, the majority of specimens were noted to have only one continuous head of the supinator. The remainder were classified as “two heads,” but more appropriately could be described as having diverging muscle fibers. The specimens with the diverging muscle fibers had a clear association with tendinous arcades. This could be another factor contributing to the compression of PIN.

Molina et al. (3) studied in 20 forearms the distal part of the posterior interosseous nerve from the distal edge of superficial layer of supinator muscle to the dorsal capsule of the wrist. They found that the posterior interosseous nerve distal to the supinator muscle may be compressed by various structures like the distal border of the supinator muscle, the ramifications of the anterior and posterior interosseous vessels, and the septum between the extensor carpi ulnaris and the extensor digiti minimi. The posterior interosseous nerve can be elongated and rotated during passive supination and compressed during passive pronation.

Berton et al. (14) stated that the mass of the muscle hypertrophy can cause compression of PIN and he studied the volume of the superficial and deep layers of the supinator muscle and reported the volume for superficial layer as 7.1 ml ± 0.4 ml and deep layer as 7.4 ml ± 0.3 ml.

Entrapment of posterior interosseous nerve

The PIN travels through the radial tunnel and supplies the extensor muscles and compression at any point may cause motor symptoms and significant pain localised over the extensor mass just below the elbow (22). Suematsu and Hirayama in 1998 (33) reported that traumatic and non traumatic lesions of motor branches of PIN can cause drop thumb deformity and isolated drop fingers and the sign of horns by Spinner et al. (8).

Suematsu et al. (33) did an anatomic study in classifying non traumatic lesions and described three types.

Type 1 - drop fingers and drop thumb occurred when the recurrent branch and descending branch of posterior interosseous nerve (PIN) were compressed together at the entry of the nerve into the supinator muscle.

Type 2 - Drop fingers due to compression of recurrent branch of posterior interosseous nerve (PIN)

Type 3 - Drop thumb due to compression of descending branch of posterior interosseous nerve (PIN)

Traumatic palsies of posterior interosseous nerve was classified by Hirachi et al. in 1998 (34)

Type 1 - Complete PIN palsy

Type 2 - Loss of extension of little and ring fingers without loss of extension of thumb, index and middle fingers

Type 3 - Loss of extension of index and thumb and a loss of abduction of thumb without loss of extension of the other fingers (35).

The posterior interosseous nerve can be compressed by the arcade of Frohse and this can cause pain on the lateral side of the elbow and misdiagnosed as epicondylitis (27). During tennis, the position used is extension of the elbow with the forearm pronated and wrist flexed which causes entrapment of the posterior interosseous nerve by the tendinous edge of the supinator and the

proximal edge of the extensor carpi radialis brevis muscle. This causes pain restricted to lateral epicondyle and is called resistant tennis elbow (36).

Chronic compression of posterior interosseous nerve can cause two types of clinical manifestations - it includes radial tunnel syndrome which results only as sensory deficit and posterior interosseous nerve syndrome which manifests as paralysis of the extensor muscles. Patients will present with weakness of the wrist and the extensors of the forearm and hand. There is pain in the distal and lateral aspect of the elbow (17). Pathological causative factor for PIN palsy includes rheumatoid arthritis. The inflammation caused by this condition can cause synovial hyperplasia and effusion in the elbow joint which in turn can cause changes in the surrounding structures which includes PIN. Clinically, patients will be able to slightly extend their wrist but with radial deviation as the nerve supply to extensor carpi radialis longus and extensor carpi ulnaris are still preserved. There is inability to extend the second to fifth digits and the thumb. Inability to extend the thumb is diagnostic (37). Posterior interosseous nerve palsy is reported to occur in 0.7% of all upper limb peripheral nerve compression syndromes (22). The compression of PIN may be aggravated by repetitive pronation and supination (8).

Locating the posterior interosseous nerve

The posterior interosseous nerve is a branch of the radial nerve and runs in between the superficial and deep layers of the supinator muscle (5).

Localizing the posterior interosseous nerve in the proximal part of the forearm is important in diagnosing nerve compression by physical examination and for injections at the site of the nerve, exposure of the nerve during surgery, and reducing the incidence of iatrogenic nerve injury during surgical interventions (38).

Hazani et al. (22) did a study on 18 fresh cadaveric upper limbs to identify the anatomic landmarks to locate the posterior interosseous nerve for decompression in a case of PIN entrapment or to facilitate a minimal incision approach for the treatment of this condition. The landmarks that were used were the proximal radial edge of the radial head and the mid width of the wrist distally. The PIN was identified entering and exiting the supinator muscle. Measurements were taken from the distal part of head of radius to the PIN entry and was found to be 3.4 ± 0.3 cm. Distance between the distal part of head of radius to the exit of PIN from the supinator was 7.4 ± 0.4 cm. The proximal radial head could be easily identified as it moves with supination and pronation of the forearm.

Vergara and Ramirez (27) studied 21 fresh cadaveric upper limbs and measured the distance from the division of the radial nerve to the arcade of Frohse. It was found to be 25.8mm. The distance from lateral epicondyle to the entrance of PIN into arcade of Frohse was 47.1mm and distance from lateral epicondyle to PIN exit was 84.2mm. Distance from the radial head and the entrance of PIN into arcade of Frohse was 24.4mm and distance from radial head to exit of PIN from supinator was 63mm.

Low et al. (39) did a study on 12 cadaveric upper limbs. The distance of the radial nerve bifurcation was 1.8cm below the lateral condyle and the PIN passed beneath the arcade of Frohse 3.8cm below the lateral condyle.

Clavert et al. (17) did measurements on 30 embalmed upper limbs. The radial nerve bifurcated into superficial and PIN at a distance of 11.76 cm from the lateral intermuscular septum and 3.75cm from the arcade of Frohse. The mean distance from radial nerve bifurcation to joint line was 0.87 cm. Average distance from radial nerve to radial head was 4.8mm. Distance from radial tubercle to PIN in pronation was 2.67 cm which decreased to 2.17 cm in supination. It was noted that the radial nerve bifurcation is typically noted to be proximal to humeroradial joint line in 97% of specimens.

Duquin et al. (40) did a study where they measured the distance from the radial tuberosity to the PIN. The distance from the proximal portion of radial tuberosity to PIN was 19.40 ± 5.51mm, middle of radial tuberosity to PIN was 16.91 ± 5.24mm and distal part of the radial tuberosity to PIN was 13.00 ± 5.39mm. The average distance from interepicondylar reference point to exit of PIN from supinator was 90.21 ± 15.61mm.

Kirci et al. (28) measured the length of the radial nerve from the point it pierced lateral intermuscular septum to humeroradial joint line in the right limb was 8.48 ±1.05 mm and 9.20 ± 1.70 mm on the left side with a p value of 0.012. The length of PIN from the radial nerve branching to

humeroradial joint line was 3.48 ± 1.08mm in right limb and 3.23 ± 1.10mm on the left side. The length of PIN from humeroradial joint line to proximal edge of superficial layer of supinator muscle on the right side was 1.98± 0.58mm and on the left side was 2.07 ± 0.42 mm. The length of PIN from the humeroradial joint line to distal edge of supinator was 6.12±1.04mm on the right and 6.28 ± 1.05 mm on the left side.

Ebrahim et al. (19) studied PIN in relation to the radial head and ulna in 20 upper limb specimens. The length of PIN from radial head to arcade of Frohse was 26.5 ± 1.6mm in males and 25.3 ± 1.1 mm in females respectively. The length of the PIN from radial head to the PIN exit point from the supinator was 66.7 ± 4.7 mm and 64.0 ± 2.5 mm in males and females, respectively. The length of the PIN within the supinator muscle was 44.0 ± 0.5 mm and 37.0 ± 0.5 mm in males and females, respectively. The distance between the PIN exit point from the supinator and the radial margin of the radius was 15.0 ± 0.9 mm and 14.5 ± 0.9 mm in males and females, respectively. The distance between the PIN exit point from the supinator and ulnar margin of ulna was 18.2 ± 0.6 mm and 17.9 ± 0.7 mm in males and females, respectively.

Tubbs et al. (41) did a study on thirty-four adult cadaveric upper extremities in which measurements were made between PIN and surrounding superficial bony landmarks. The PIN was identified by retracting the muscle bellies of brachioradialis, extensor carpi radialis longus and extensor carpi radialis brevis. The posterior interosseous nerve entered between the two layers of the supinator at the level of the neck of radius 6cm distal to the

lateral epicondyle of humerus and exited at a distance of 12cm from the lateral epicondyle. The exit site from the distal edge of the supinator was found to be at a mean distance of 18 cm proximal to the styloid process of the ulna.

Thomas et al. (11) in 31 upper limbs found the distance between the bifurcation of the radial nerve and lateral intermuscular septum to be 8.0 ± 1.9cm. The radial nerve bifurcation was 3.6 ± 0.7 cm proximal to the arcade of Frohse. The PIN exited the supinator 3.8 ± 0.9 cm distal to the arcade of Frohse. The distance of PIN from the lateral aspect of the biceps insertion to the arcade of Frohse was 1.0 ± 0.3 cm.

Berton et al. (14) in 30 upper limbs found that the radial nerve divided into superficial and deep branches 90 mm (66 – 106 mm) beyond its exit from the lateral intermuscular septum.

Ozkan et al. (12) did a study on the radial tunnel in 60 upper extremities. The findings were that the radial nerve divided into superficial and deep branches 92 mm (85 to 120 mm) beyond its exit from the lateral intermuscular septum. The length of the posterior interosseous nerve from its division to the arcade of Frohse (AF) was 46 mm (35 to 65 mm).

Hackl et al. (42) did a 3D X-ray scan study on six fresh frozen cadaveric specimens and the location of the PIN was identified in supination and pronation. In coronal view PIN crossed the radial neck 33.4 ± 5.9 mm below the radial head in pronation and 16.9 ± 5.0 mm in supination. It crossed 4.9 ± 2.2 mm distal of the most prominent part of the radial tuberosity in pronation and 9.6 ± 5.2 mm proximal in supination.

Kamineni et al. (38) did a non invasive study inorder to localize PIN. Sixty three upper limb cadavers were used for this study. The transepicondylar distance (TED) was measured. In pronation, the PIN was within two confidence intervals of 1.0 TED in 95% of cases (range 0.7-1.3 TED); in neutral, within two confidence intervals of 0.84 TED in 95% of cases (range 0.5-1.1 TED); in supination, within two confidence intervals of 0.72 TED in 95% of cases (range 0.5-0.9 TED). The mean PIN distance from the lateral epicondyle was 100% of TED in a pronated forearm, 84% in neutral, and 72% in supination. Predictive accuracy was highest in supination.

Locating the structures causing compression of the posterior interosseous nerve

Knowledge of the relative position of the structures that cause compression of posterior interosseous nerve, will help the surgeon during decompression procedures of the PIN.

Konjengam and Elangbam (18) did a study on the structures that could cause compression of the posterior interosseous nerve. The structures identified were superior and inferior borders of superficial layer of supinator, medial border of extensor carpi radialis brevis (ECRB) and radial recurrent artery. Distances of these structures were taken from transepicondylar line (Hueter's line) and humeroradial joint line. The superior border of the superficial layer of the supinator muscle was 38.88 mm (range: 22.5–58 mm) from Hueter's line and 23.59 mm (range: 7–47 mm) from humeroradial joint line. The inferior border of the superficial layer of the supinator muscle was 80.25 mm from Hueter's line

(range: 60.5–97 mm) and 65.32 mm (range: 40–85 mm) from humeroradial joint line. The medial border of ECRB at point where it was applied to PIN was 36.44 mm (range: 20–50 mm) from Hueter's line and 18.51 mm (range: 4–39mm) from humeroradial joint line. The radial recurrent artery at point where it was applied to the PIN was 22.30 mm (range: 0–36 mm) from Hueter's line and 6.26 mm (range: - 9 to 24 mm) from humeroradial joint line. Vascular arcades (leash of Henry) formed by the radial recurrent vessels, where it crossed PIN was few mm to about 10 mm proximal to the superior border of superficial layer of the supinator muscle.

Berton et al. (14) found the distance between humeroradial joint line and the arcade of Frohse was 24.3 mm (15 – 30 mm). The distance between the lateral epicondyle and the arcade of Frohse was 41.6 mm (32.5 – 61.5 mm).

Ozturk et al.(5) found the distance between lateral epicondyle and arcade of Frohse to be 46.23 mm.

Fuss and Wurzl (43) found the arcade of Frohse to be 3 – 5 cm below Hueter's line.

Ozkan et al. (12) found that the average distance between the radial head and AF was 21 mm (17 to 30 mm).

Predicted distance of arcade of Frohse

Ozturk et al. (5) found a method to determine the predicted distance of the arcade of Frohse. The distance between the tip of the lateral epicondyle of the humerus and the AF was measured on the coronal plane and this distance was named as the ''distance AF''. The distance between the tip of the lateral

epicondyle of the humerus and the tip of the styloid process of the radius was measured as the ‘‘length of the forearm’’ on the coronal plane. The ‘‘ratio AF’’ was found by dividing the distance AF by the forearm length (ratio AF = distance AF/forearm length) for each upper extremity. The mean value of the ratio AF was calculated. This value may be used to predict the distance AF of any upper extremity with a known forearm length. Thus, the predicted distance AF of any upper extremity may be found by multiplying its forearm length by the mean ratio AF (predicted distance AF = measured forearm length x mean ratio AF).

5. MATERIALS AND METHODS

This study was done after approval from the institutional review board (IRB) and Ethics Committee.

A total of 40 upper limbs from 20 formalin embalmed adult cadavers (males - 28 and females – 12) aged between 40 and 90 years available in the Department of Anatomy, Christian Medical College, Vellore were used for the study. Any limbs with injuries or deformities were excluded from the study. The measurements were taken twice by a single observer and the average of the values were determined. The instruments used were scalpel, toothed and non toothed forceps, coloured pins, threads, measuring tape, scale and a protractor.

The sample size was calculated as 40 limbs. The formula used for the sample size calculation was

$$n = \frac{2Sp^2[Z_{1-\alpha/2}+Z_{1-\beta}]^2}{\mu^2 d} \quad , \quad S_p^2 = \frac{S_1^2 + S_2^2}{2}$$

where n - number of cadavers needed, α – significance level, 1-β - power, S_1^2 - standard deviation in first group , S_2^2 – standard deviation of second group, μ^2 d – mean difference between the samples.

Method of dissection

The cadaver was placed in supine position on the dissection table. Both the upper limbs were extended and placed in mid prone position and tied to the

arm boards. The palpable bony landmarks like the lateral and medial epicondyles, head of the radius, radial styloid process, and ulnar styloid process were identified. A longitudinal incision was made from 5cm above the cubital fossa till the wrist. Transverse incisions were made at the proximal and distal ends of the longitudinal incision. The skin flaps were reflected. The superficial fascia with cutaneous nerves and vessels was removed. The deep fascia covering the muscles was cleaned. The brachioradialis muscle, extensor carpi radialis longus and extensor carpi radialis brevis muscles were defined. The medial margin of extensor carpi radialis brevis muscle was defined. The superficial layer of the supinator muscle was identified. The proximal and distal borders of the superficial layer of supinator muscle were exposed. The radial nerve was identified between the brachioradialis muscle and the brachialis muscle and the division of the nerve into superficial branch and the posterior interosseous nerve was dissected. The fatty fibrous tissue around the head of the radius was also removed. The posterior interosseous nerve was seen to enter the arcade of Frohse.

The nature and knowledge of distances of the structures that cause compression of the PIN from bony landmarks is necessary to decompress the PIN in the treatment of posterior interosseous nerve entrapment. The following were noted

- Nature of the proximal border of the superficial layer of the supinator muscle
- Nature of the distal border of the superficial layer of the supinator muscle
- Nature of superomedial margin of extensor carpi radialis brevis (ECRB)
- Distance between proximal and distal borders (arcades) of superficial layer of supinator muscle

The lateral epicondyle was palpated and a coloured pin was used to mark it and another pin was used to mark the point of entry of PIN to the arcade of Froshe. The following measurements were done using an inch tape

- Distance from lateral epicondyle to proximal border of superficial layer of supinator muscle (arcade of Frohse)
- Distance from lateral epicondyle to distal border of superficial layer of supinator muscle
- Distance from lateral epicondyle to vascular arcades of the radial recurrent vessels (leash of Henry) where it crossed PIN

Distances were measured from the humeroradial joint line to the structures that cause compression of PIN.

- Distance from humeroradial joint line to proximal border of superficial layer of supinator muscle (Fig. 2)
- Distance from humeroradial joint line to distal border of the superficial layer of supinator muscle (Fig. 2)
- Distance from humeroradial joint line to the medial border of ECRB
- Distance from humeroradial joint line to radial recurrent artery where it is applied to PIN

The transepicondylar line was determined in the following manner - the lateral epicondyle and the medial epicondyle were palpated and coloured pins placed

27

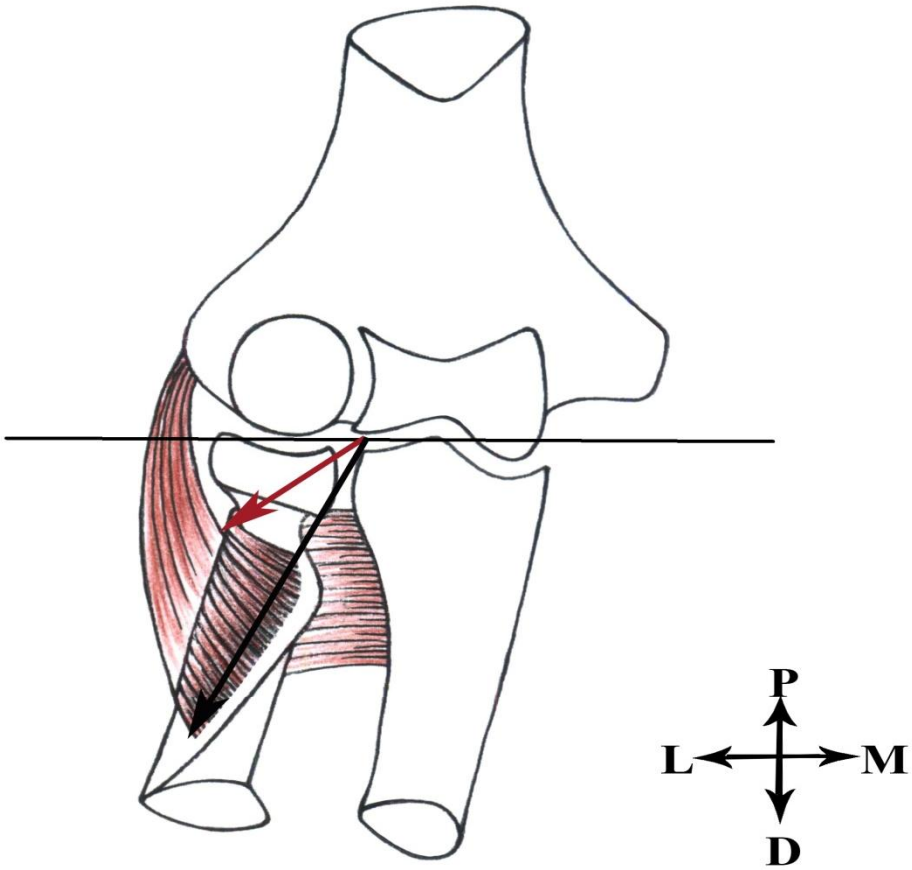

Fig. 2 Line drawing of the right elbow showing the distance between humeroradial joint line and proximal border of superficial layer of supinator muscle (red arrow) and distance between humeroradial joint line and distal border of superficial layer of supinator muscle (black arrow)

on these bony points. A white thread was used to measure the distance between these two points and the midpoint was determined.

Distances were measured from the transepicondylar line to the structures that cause compression of PIN.

- Distance from transepicondylar line to proximal border of superficial layer of supinator muscle (Fig. 3)
- Distance from transepicondylar line to distal border of the superficial layer of supinator muscle (Fig. 3)
- Distance from transepicondylar line to the medial border of ECRB
- Distance from transepicondylar line to radial recurrent artery where it is applied to PIN

Distances were measured from the radial head to the superficial layer of supinator

- Distance from the proximal radial edge to the proximal border of the superficial layer of the supinator muscle
- Distance from the proximal radial edge to the distal border of the superficial layer of the supinator muscle

Pennation angles

The direction of muscle fibres of the superficial and deep fibres are oriented differently. The angle made by the fibres and the shaft of the radius was measured. The tendons of brachioradialis, extensor carpi radialis longus and extensor carpi radialis brevis were released from their insertions and the supinator muscle was exposed. The scale is placed on a line from the head of the radius to the radial styloid process

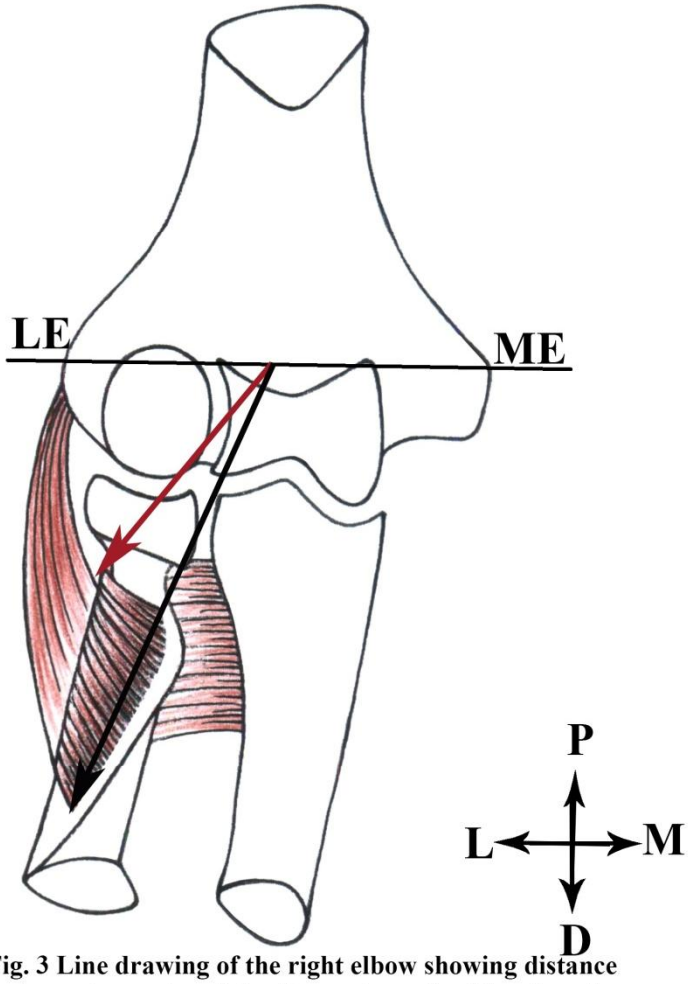

Fig. 3 Line drawing of the right elbow showing distance between tranepicondylar line and proximal border of superficial layer of supinator muscle (red arrow) and distance between tranepicondylar line and distal border of superficial layer of supinator muscle (black arrow)

and using a protractor the direction of fibres of the superficial layer (pennation angle) was measured. In a similar manner, after reflecting the superficial layer of the supinator muscle, the pennation angle of the deep layer was measured.

Morphometry of the arcade of Frohse

The length and width of the arcade was measured. In order to do this, the superolateral tip of the AF was named as the proximal tip. The inferomedial tip of the AF was named as the distal tip. The proximal and distal tips were marked. First, two imaginary lines were drawn to measure the width and length of the AF

(1) the first passed horizontally from the proximal tip (the imaginary horizontal line),

(2) the second passed vertically from the distal tip (the imaginary vertical line). Then, the point where the first imaginary line met the second imaginary line was marked. This point was named as the meeting point. The horizontal distance between the proximal tip and the meeting point was measured as the width of the AF on the coronal plane, and the vertical distance between the distal tip and the meeting point was measured as the length of the AF on the coronal plane (Fig 4).

Localisation of posterior interosseous nerve

It is important to localise the posterior interosseous nerve (PIN) in the treatment of its entrapment. Measurements were taken from bony landmarks like lateral epicondyle, head of radius and ulnar styloid process to the posterior interosseous nerve (PIN) in order to localise the nerve.

- Distances from humeroradial joint line and transepicondylar line to the division of radial nerve

- Distance between the lateral epicondyle and the entry of PIN into supinator muscle

- Distance between the lateral epicondyle and exit of PIN from supinator

- Distance between PIN and the proximal border of superficial layer of bsupinator

- Distance between ulnar styloid process and exit of PIN from supinator muscle

- Distance of PIN from the radial head to the arcade of Frohse

- Distance of PIN from radial head to PIN exit from the supinator muscle

- Distance from intercondylar reference point (midpoint of intercondylar line) to the exit of PIN from supinator muscle

The other aspects which were noted were -

PIN - single or double trunk

PIN - in cases where there were two trunks, whether the trunks supplied supinator and then entered the plane between the two layers of the muscle or travelled between the two layers and then supplied the muscle

PIN - exited supinator at distal border or before distal border

PIN - flattened or not at the proximal and distal borders of the superficial layer of supinator

Prediction of the location of arcade of Frohse

The forearm length was measured from the lateral epicondyle to radial styloid

process. This forearm length divided by 4 gives the predicted distance of arcade of Frohse (AF).

Branches of posterior interosseous nerve to supinator

The number of branches supplying the supinator muscle was noted. If the branches were directed to the ulnar side, it was taken as ulnar branches and if they were directed to the radial side, it was taken as radial branches.

Data analysis

The data was entered into Excel worksheet (Microsoft Office Excel; version 2010) and analysed using SPSS (version 16.0). The measurements made were compared between the side of the specimen using paired t-test. $P < 0.05$ was considered to be significant.

6. RESULTS

Forty upper limbs were dissected and the following observations were made.

6.1 Measurements to find the location of the division of radial nerve

The radial nerve divided into a superficial branch and the posterior interosseous nerve (Fig. 5). The following variables were used to locate the division of the radial nerve from bony landmarks such as the transepicondylar line (Hueter's line) and the humeroradial joint line. The mean, standard deviation, and the range shown are for both right and left upper limbs taken together (Table 1).

Table 1. Location of division of radial nerve

Parameter	Mean distance (mm)	SD (mm)	Range (mm)
Distance between division of radial nerve and transepicondylar line	Above the line 21.3 Below the line 21.3	14.20	- 23 to 32
Distance between division of radial nerve and humeroradial joint line	Above the line 23.6 Below the line 21.9	19.50	- 27 to42

Minus (-) sign indicates distances proximal to the two fixed lines (Hueter's and humeroradial joint lines)

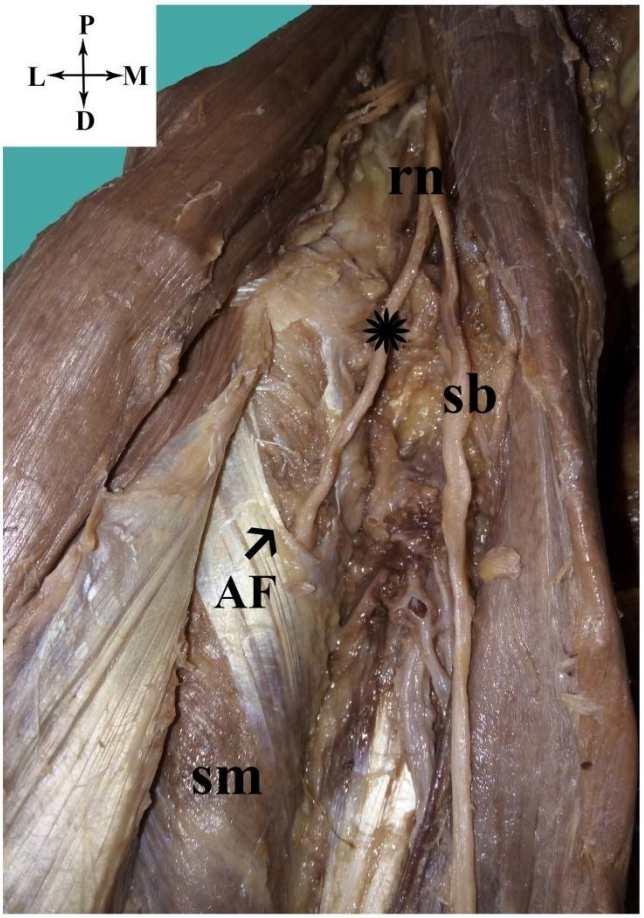

Fig. 5 Division of radial nerve
rn –radial nerve; sb – superficial branch ; asterisk - posterior interosseous nerve; AF – arcade of Frohse; sm - supinator muscle

Distance between the division of radial nerve and the transepicondylar line

The mean distance between the radial nerve and the transepicondylar line was observed to be 21.3 mm above the line and 21.3 mm below the line. The standard deviation was 14.20 mm. The minimum distance was found to be 23 mm above the transepicondylar line and the maximum distance was 32 mm below the transepicondylar line.

Distance between the division of radial nerve and the humeroradial joint line

The mean distance between the radial nerve and the humeroradial joint line was 23.6 mm above the line and 21.9 mm below the line. The standard deviation was 19.50 mm. The minimum distance was found to be 27 mm above the humeroradial joint line and the maximum distance was found to be 42 mm below the humeroradial joint line.

6.2 Nature of compressive structures

The compression of the posterior interosseous nerve can be due to the nature of the adjoining structures which includes the proximal border of the superficial layer of supinator muscle or arcade of Frohse (Fig.6), the distal border of the superficial layer of the supinator muscle (Fig.6) and the superomedial margin of extensor carpi radialis brevis where it is applied onto the posterior interosseous nerve. Table 2 shows the percentages of the

Fig. 6 Anterior view of left forearm showing proximal border (black arrow) and distal border (red arrow) of superficial layer of supinatormuscle; sm - supinator muscle

nature of these structures which are classified as tendinous, musculotendinous, muscular and membranous (Figs.7-10).

Table 2. Nature of compressive structures

Nature	Tendinous	Musculotendinous	Muscular	Membranous
Proximal border of superficial layer of supinator muscle	19 (47.5%)	18 (45 %)	2 (5 %)	1 (2.5%)
Distal border of superficial layer of supinator muscle	8 (20%)	15 (37.5%)	17 (42.5%)	0 (0%)
Superomedial margin of extensor carpi radialis brevis	4 (10 %)	8 (20%)	23 (57.5%)	5 (12.5%)

Nature of proximal border of superficial layer of supinator muscle

In the 40 limbs that were dissected, it was observed that the proximal border of supinator muscle was tendinous in 47.5%, musculotendinous in 45%, muscular in 5%, and membranous in 2.5 % (Chart 1).

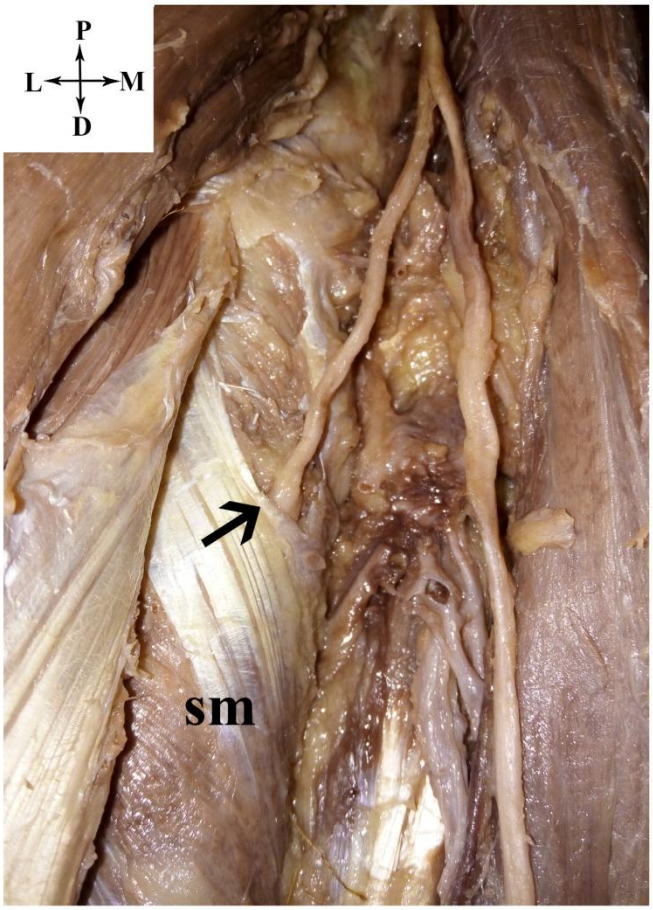

Fig.7 Tendinous arcade of Frohse (arrow), sm - supinator muscle

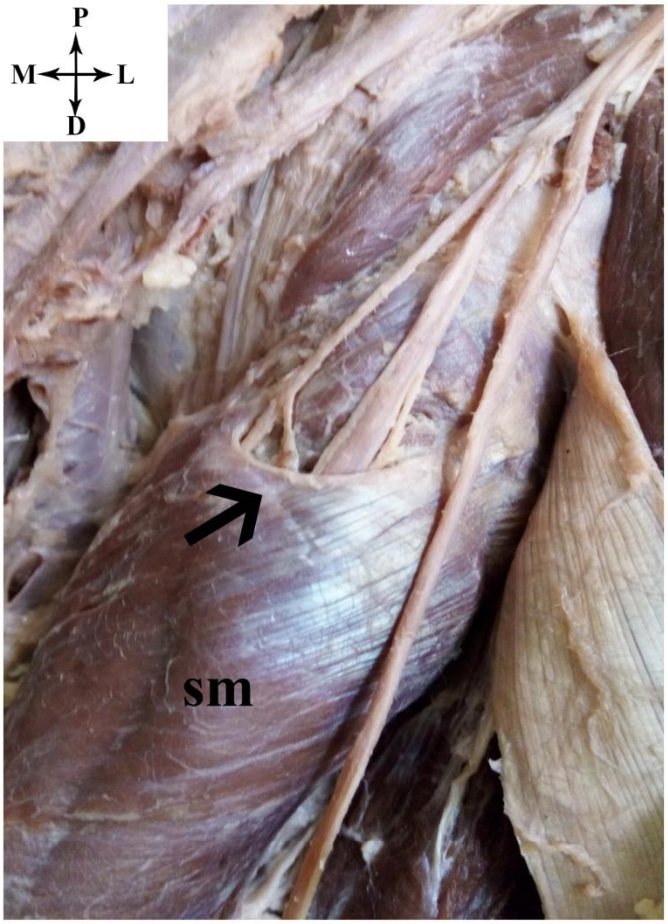

Fig. 8 Musculotendinous arcade of Frohse (arrow)
sm - supinator muscle

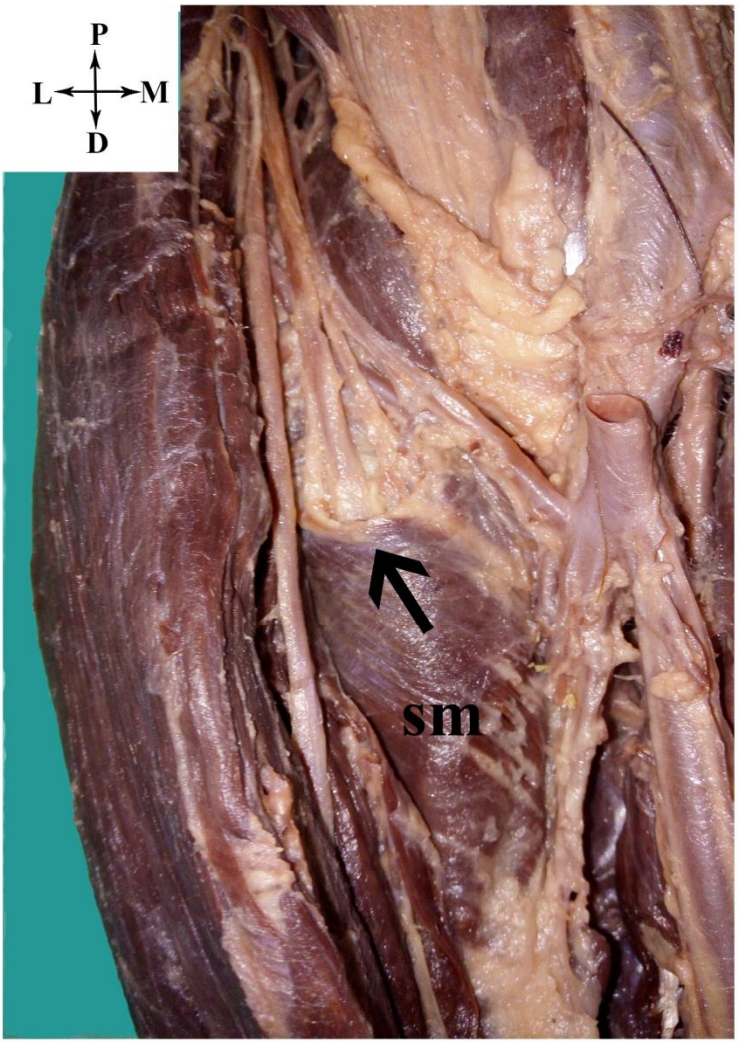

Fig. 9 Muscular arcade of Frohse (arrow)
sm - supinator muscle

Fig. 10 Membranous arcade of Frohse (arrow), sm - supinator muscle

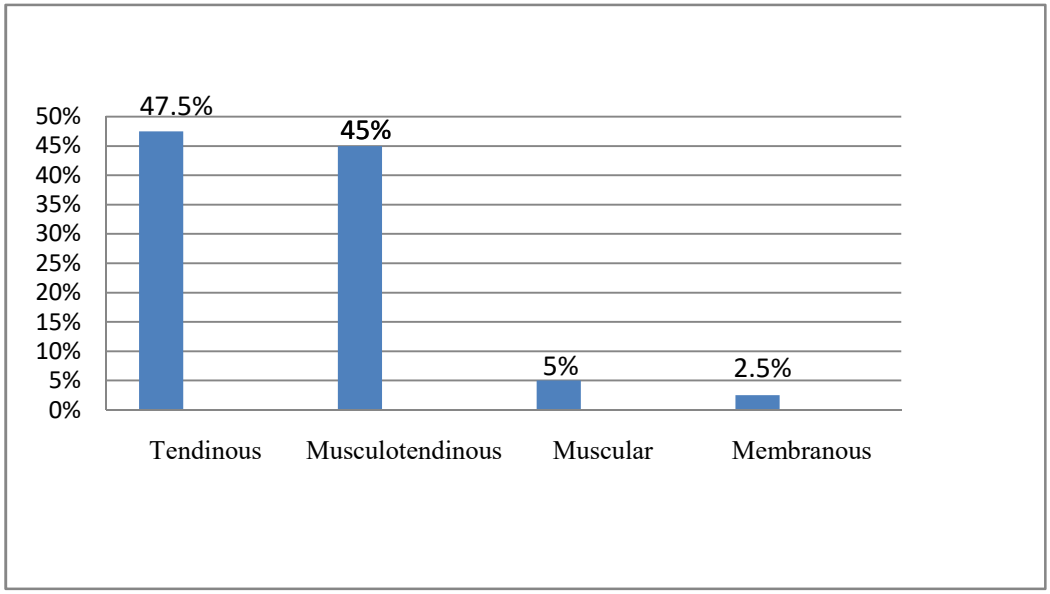

Chart 1.Nature of proximal border of superficial layer of supinator muscle (arcade of Frohse)

Table 3. Nature of compressive structures in males

Nature	Tendinous	Musculotendinous	Muscular	Membranous
Proximal border of superficial layer of supinator muscle	14 (50%)	12 (42.8%)	2 (7.14%)	0 (0%)
Distal border of superficial layer of supinator muscle	4 (14.2%)	11 (39.2%)	13 (46.4%)	0 (0%)
Superomedial margin of extensor carpi radialis brevis	4 (14.2%)	5 (17.8%)	14 (50%)	5 (17.8%)

Table 4. Nature of compressive structures in females

Nature	Tendinous	Musculotendinous	Muscular	Membranous
Proximal border of superficial layer of supinator muscle	5 (41.6%)	6 (50%)	0 (0%)	1 (8.3%)
Distal border of superficial layer of supinator muscle	4 (33.3%)	4 (33.3%)	4 (33.3%)	0 (0%)
Superomedial margin of extensor carpi radialis brevis	0 (0%)	3 (25%)	9 (75%)	0 (0 %)

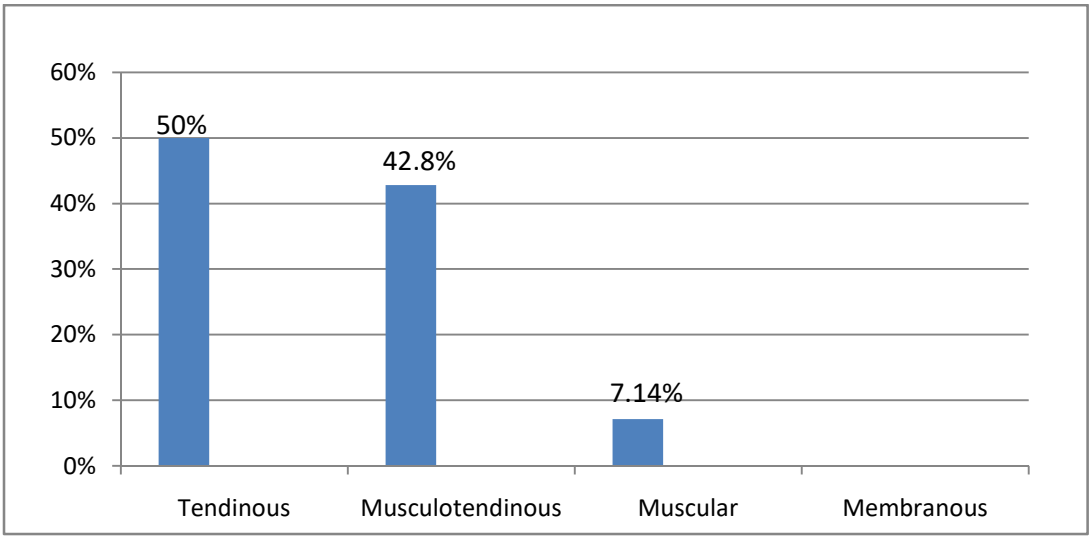

Chart 2. Nature of proximal border of superficial layer of supinator muscle (arcade of Frohse) in males

In chart 2, the type of arcade of Frohse in the 28 limbs that belonged to males is shown. The proximal border of supinator muscle was tendinous in 50%, musculotendinous in 42.8%, and muscular in 7.14 %. No membranous type was found (Table3).

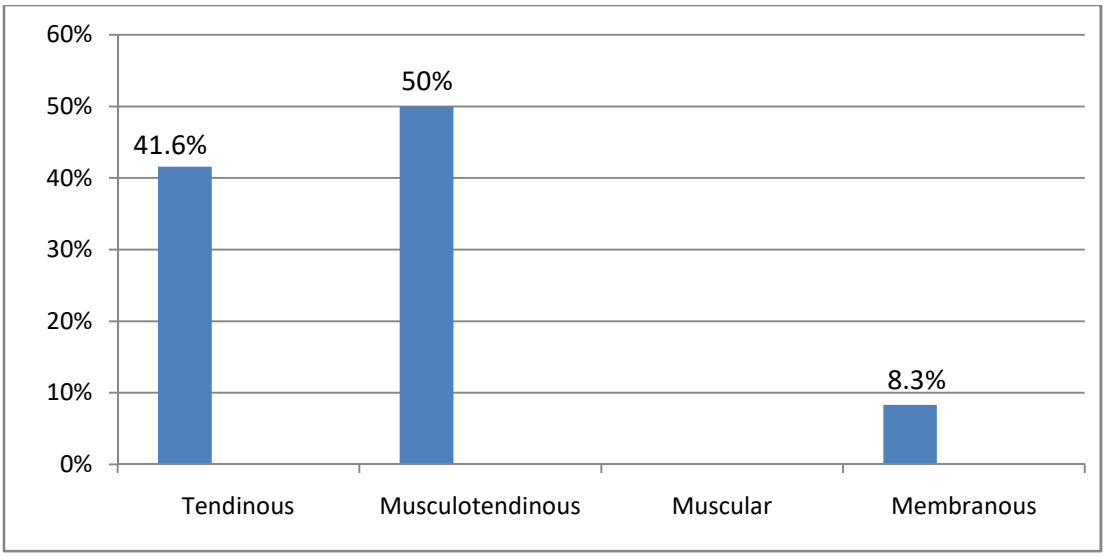

Chart 3. Nature of proximal border of superficial layer of supinator muscle (arcade of Frohse) in females

In chart 3, the type of arcade of Frohse in the 12 limbs that belonged to females is shown. The proximal border of the superficial layer was tendinous in 41.6%, musculotendinous in 50%, and membranous in 8.3%. No muscular type was found (Table 4).

<u>Nature of distal border of superficial layer of supinator muscle</u>

In the 40 limbs that were dissected, it was observed that the distal border of supinator muscle was tendinous in 20%, musculotendinous in 37.5%, and muscular in 42.5%. No membranous type was found (Figs. 11–13) (Table 2) (Chart 4).

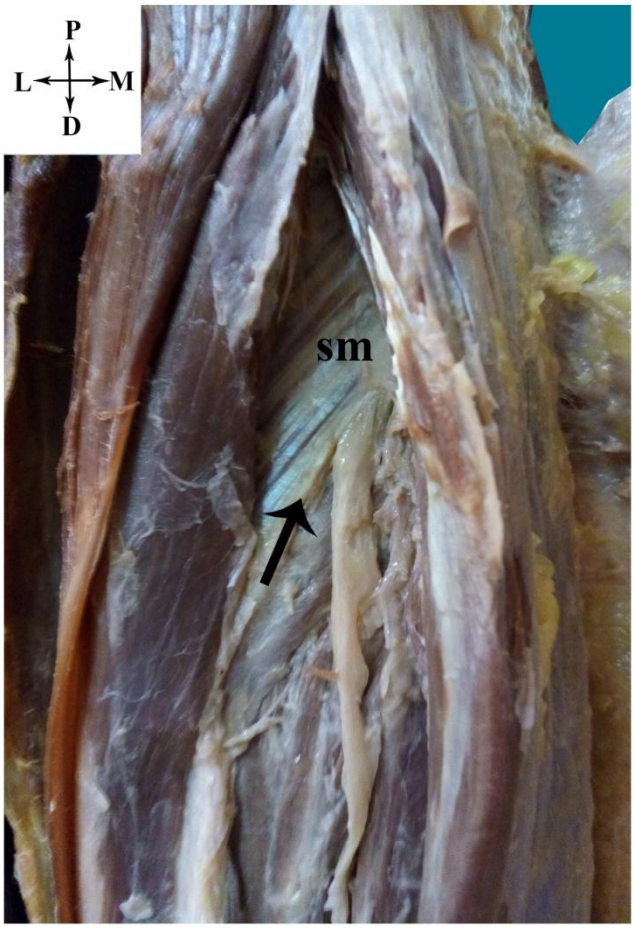

Fig. 11 Showing tendinous distal border of superficial layer of supinator muscle (arrow); sm - supinator muscle

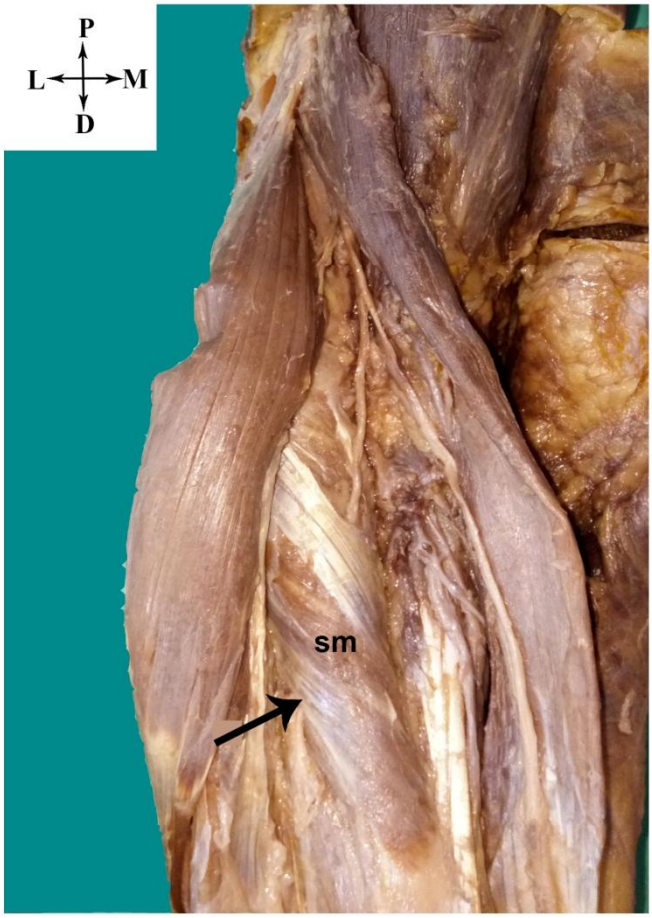

Fig. 12 Showing musculotendinous distal border of superficial layer of supinator muscle (arrow); sm - supinator muscle

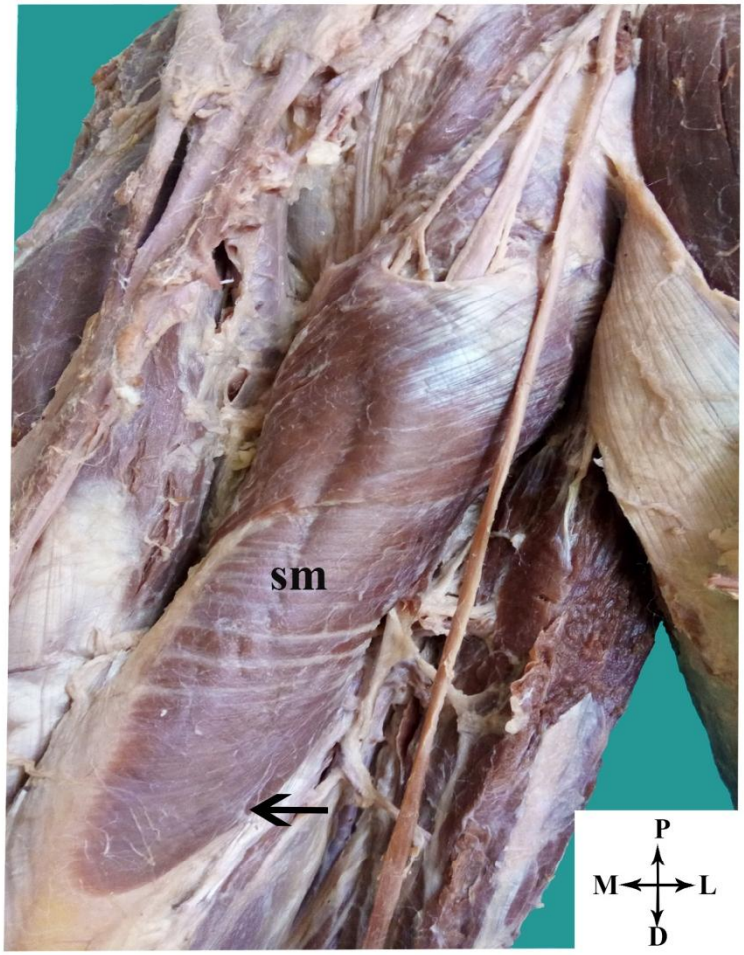

Fig. 13 Showing muscular distal border of superficial layer of supinator muscle (arrow); sm - supinator muscle

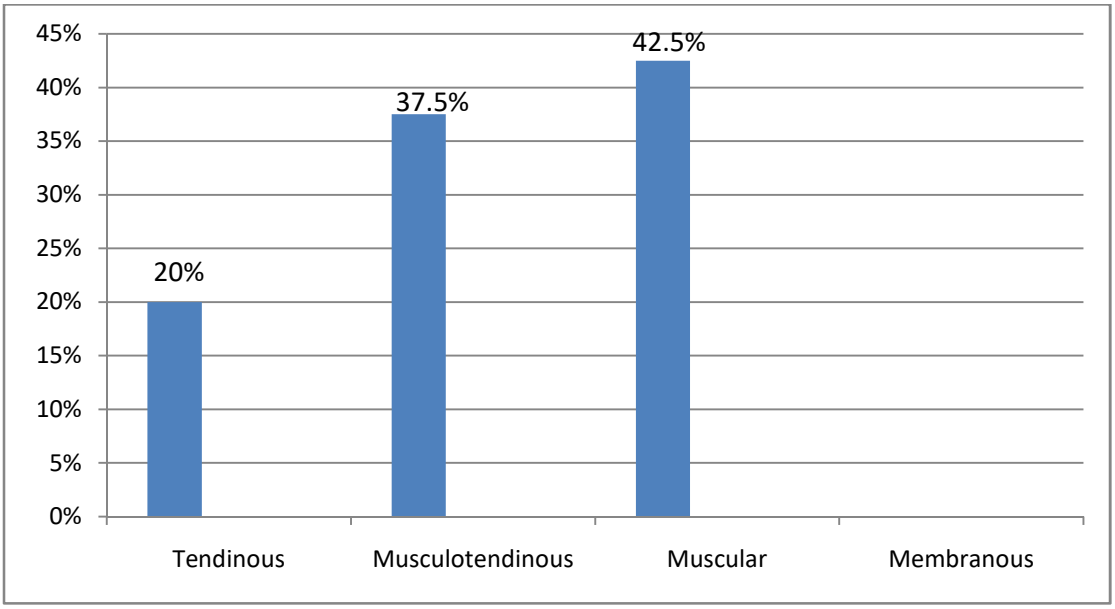

Chart 4. Nature of distal border of superficial layer of supinator muscle

The percentage of the nature of the distal border of superficial layer of supinator muscle seen in males and females are shown in charts 5 and 6 respectively.

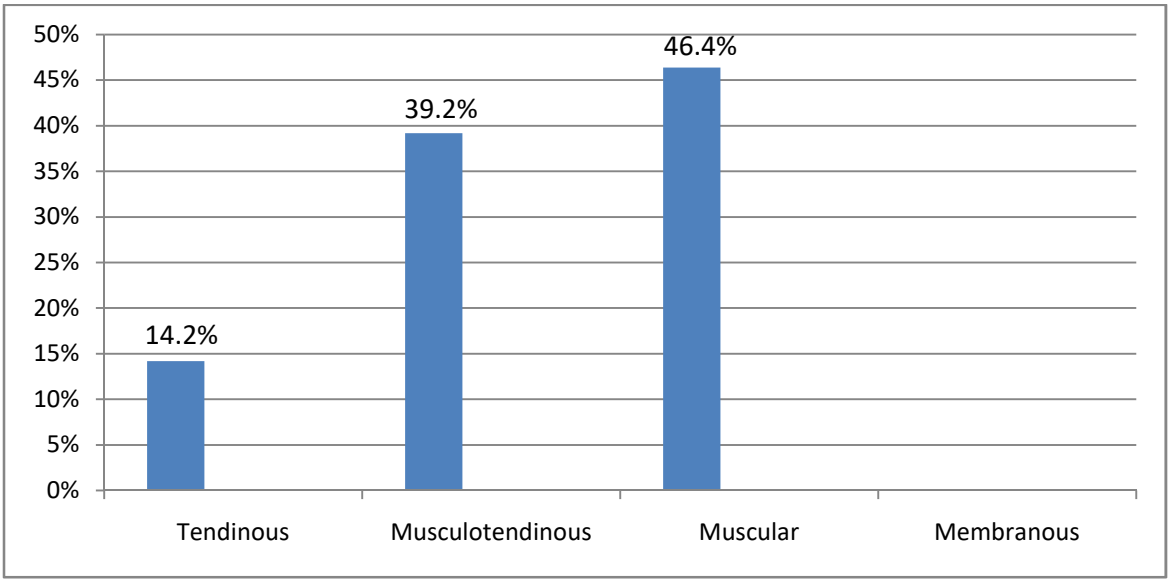

Chart 5. Nature of distal border of superficial layer of supinator muscle in males

In chart 5, the nature of the distal border of superficial layer of supinator muscle in the 28 limbs that belonged to males is shown. It was found to be tendinous in 14.2%, musculotendinous in 39.2%, and muscular in 46.4%. No membranous type was found (Table 3).

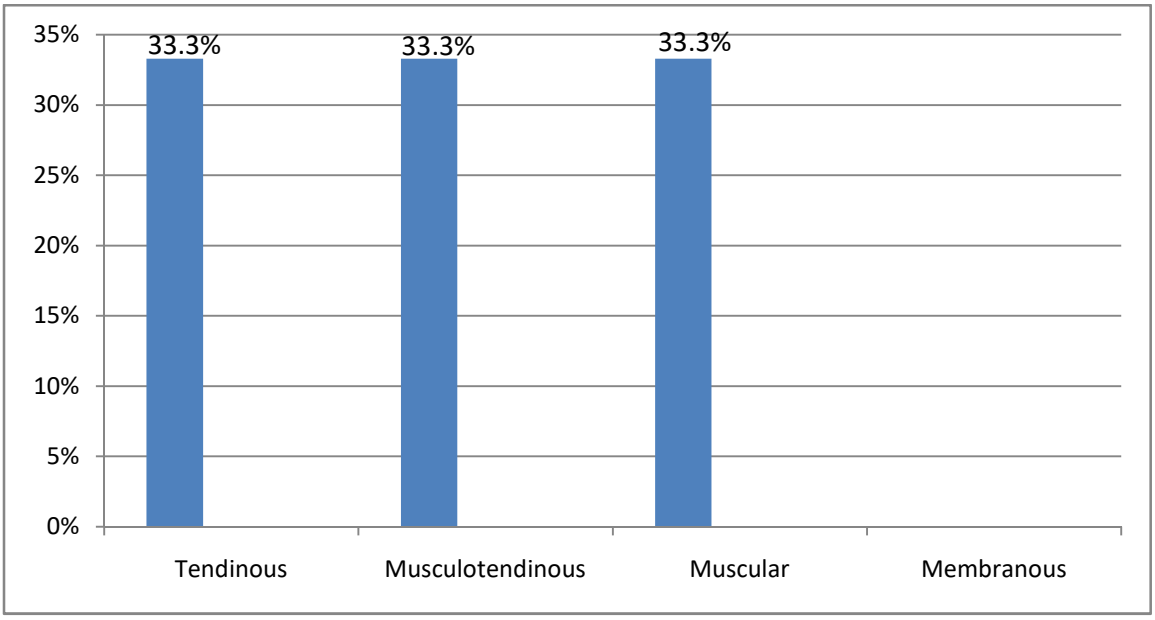

Chart 6. Nature of distal border of superficial layer of supinator muscle in females

In chart 6, the nature of the distal border of superficial layer of supinator muscle in the 12 limbs that belonged to females is shown. It was found to be tendinous in 33.3%, musculotendinous in 33.3% and muscular in 33.3%.No membranous type was found (Table 4).

<u>Nature of superomedial margin of extensor carpi radialis brevis</u>

In the 40 limbs that were dissected, it was observed that the superomedial margin of extensor carpi radialis brevis (Fig. 14) was tendinous in 10%,

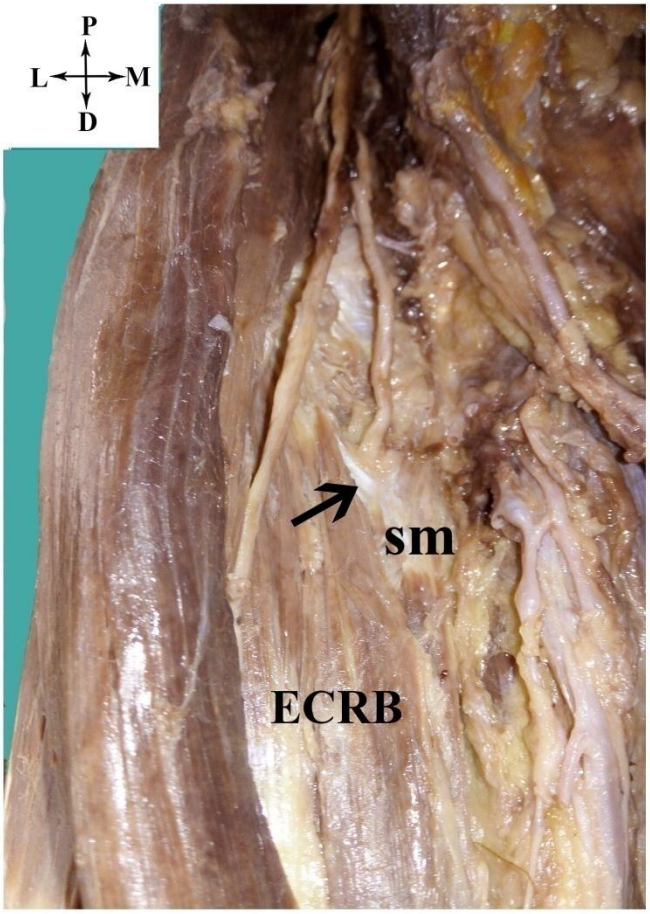

Fig. 14 Anterior view of right elbow showing tendinous superomedial margin (arrow) of extensor carpi radialis brevis (ECRB);sm - supinator muscle

musculotendinous in 20%, muscular in 57.5 % and membranous in 12.5 % (Table 2) (Chart 7). The extensor carpi radialis brevis muscle was applied to the PIN in 38 upper extremities (95%).

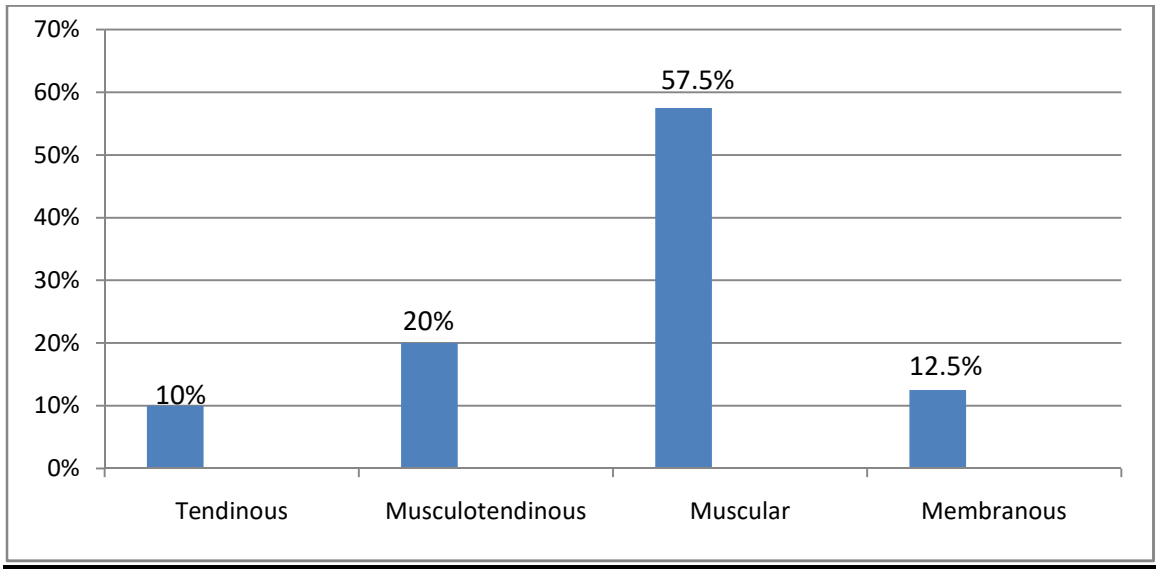

Chart 7. Nature of superomedial margin of extensor carpi radialis brevis

The nature of the superomedial margin of the extensor carpi radialis brevis seen in males and females are shown in charts 8 and 9 respectively.

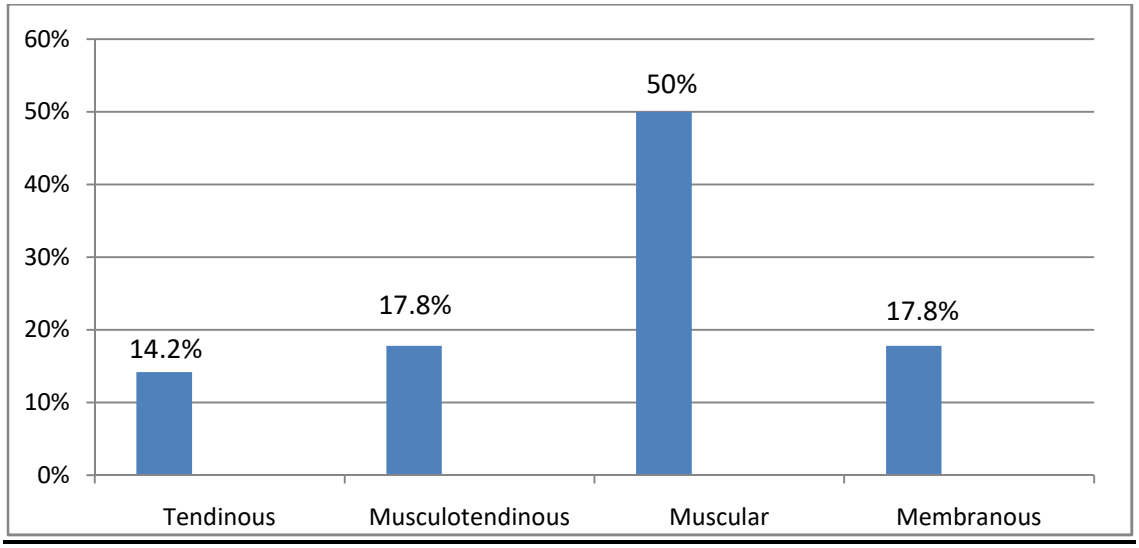

Chart 8. Nature of superomedial margin of extensor carpi radialis brevis in males

In chart 8, the nature of the superomedial margin of extensor carpi radialis brevis in the 28 limbs that belonged to male cadavers is shown. It was found to be tendinous in 14.2%, musculotendinous in 17.8%, muscular in 50%, and membranous in 17.8% (Table 3).

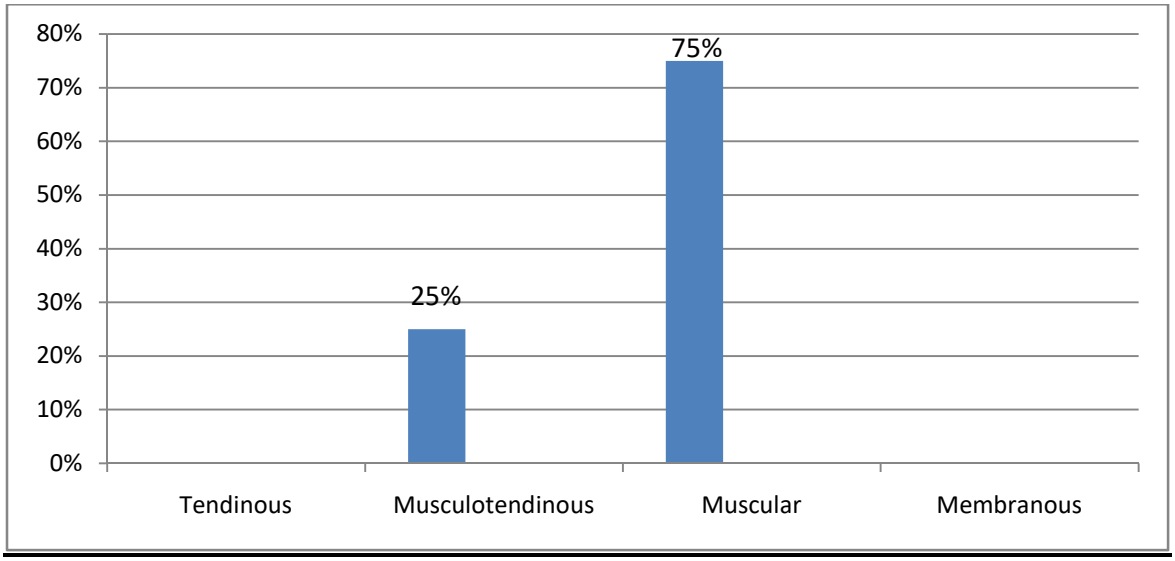

Chart 9. Nature of superomedial margin of extensor carpi radialis brevis in females

In chart 9, the nature of the superomedial margin of extensor carpi radialis brevis in the 12 limbs that belonged to female cadavers is shown. It was found to be musculotendinous in 25% and muscular in 75%. The tendinous and membranous types were not found (Table 4).

Table 5. Nature of borders according to sides

Nature of borders	Tendinous	Musculotendinous	Muscular	Membranous
Proximal border in right forearm	10 (50%)	9 (45%)	1 (5%)	0
Proximal border in left forearm	9 (45%)	9 (45%)	1 (5%)	1 (5%)
Distal border in right forearm	3 (15%)	10 (50%)	7 (35%)	0
Distal border in left forearm	5 (25%)	5 (25%)	10 (50%)	0

Table 5 shows that a tendinous proximal border of the superficial layer of supinator muscle is more common in the right forearm (50%) than in the left forearm (45%). This indicates that movements of the right limb (dominant limb) can produce a tendinous arcade of Frohse which can lead to entrapment of PIN (Chart10). A musculotendinous distal border of the superficial layer of supinator muscle is more common in the right forearm (50%) than in the left forearm (25%). This indicates that movements of the right limb (dominant limb) can produce a musculotendinous distal border which can lead to entrapment of PIN (Chart 11).

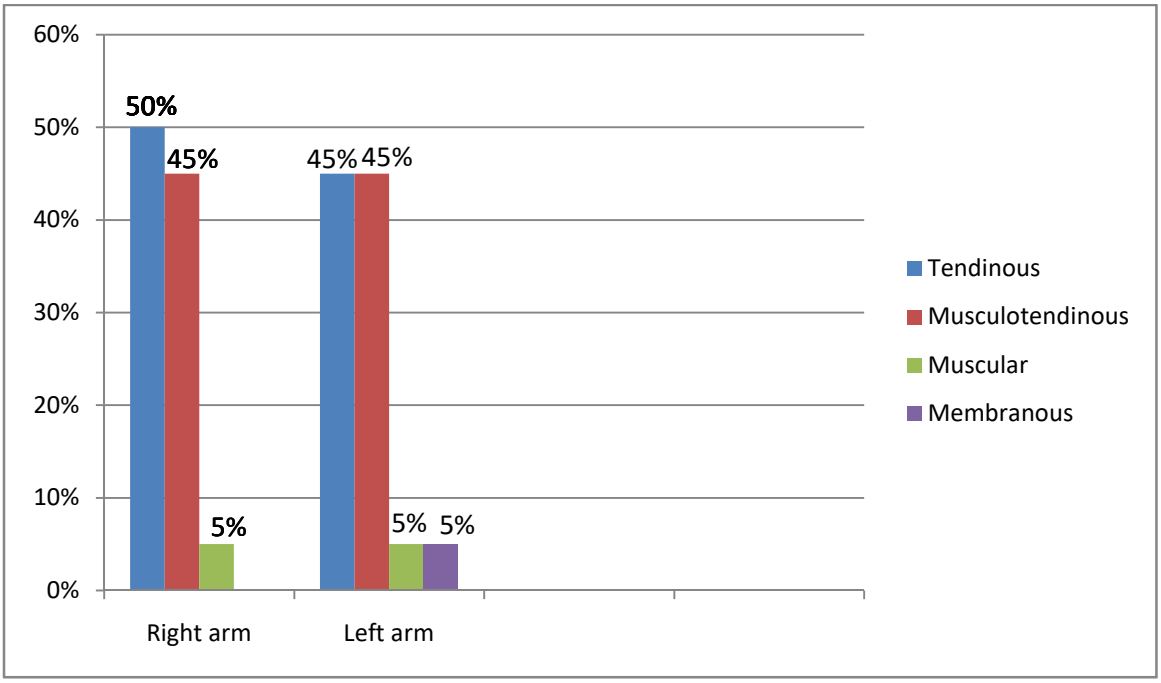

Chart 10. Nature of proximal border of superficial layer of supinator according to sides

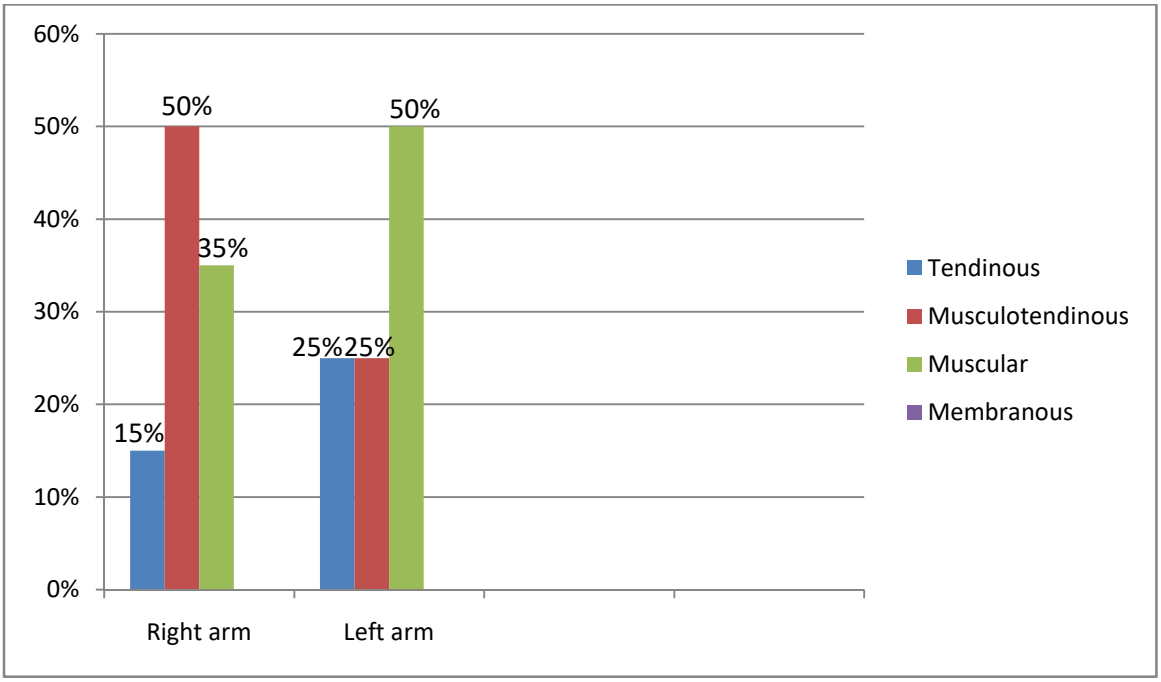

Chart 11. Nature of distal border of superficial layer of supinator according to sides

6.2 Variables to locate the structures causing compression of the posterior interosseous nerve

The distances from the compressive structures and the humeroradial joint line and the transepicondylar line (Hueter's line) were measured (Tables 6 and 7). The mean, standard deviation, and the range shown are for both right and left upper limbs taken together.

Table 6. Distance between humeroradial joint line and structures that cause compression of posterior interosseous nerve

	Mean distance (mm)	SD (mm)	Range (mm)
Proximal border of superficial layer of supinator muscle	27.62	5.18	17-37
Distal border of superficial layer of supinator muscle	90.27	10.17	71-108
Medial border of extensor carpi radialis brevis at point where it is applied to PIN	28.52	5.90	16 - 40
Radial recurrent artery at point where it is applied to PIN	18.69	10.18	-2 to 29

Minus (-) sign indicates distances proximal to the humeroradial joint line

The radial recurrent artery at point where it is applied to PIN is shown in Fig. 15.

The radial recurrent artery was applied to PIN in 36 upper extremities (90%).

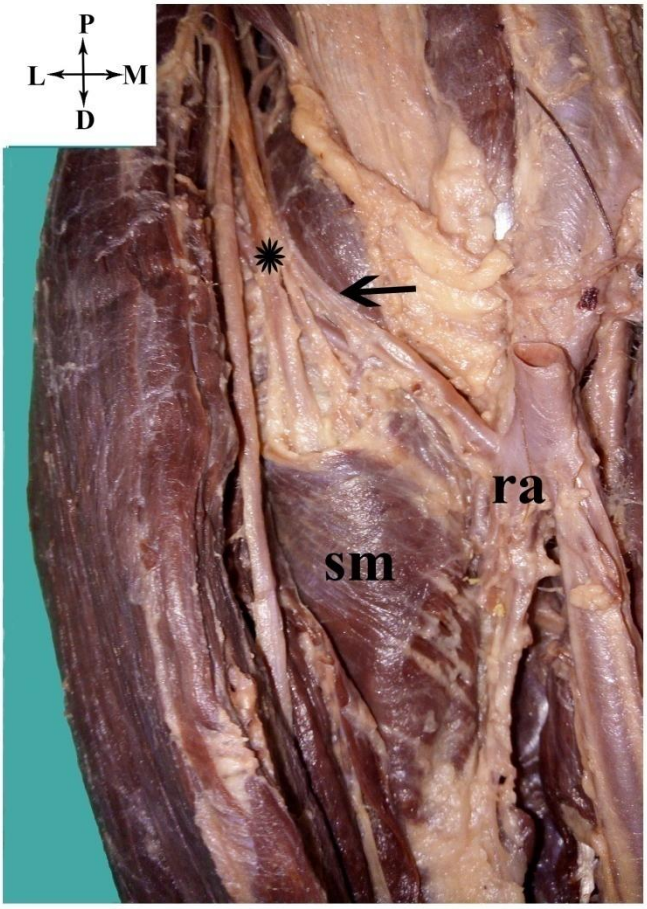

Fig. 15 Radial recurrent artery (arrow) applied to posterior interosseous nerve (asterisk), ra – radial artery; sm - supinator muscle

Table 7. Distance between transepicondylar line and structures that cause compression of posterior interosseous nerve

Parameter	Mean distance (mm)	SD (mm)	Range (mm)
Proximal border of superficial layer of supinator muscle	42.05	5.82	30 -55
Distal border of superficial layer of supinator muscle	105.62	10.80	82 - 122
Medial border of extensor carpi radialis brevis (ECRB) at point where it is applied to PIN	42.42	7.36	21 -53
Radial recurrent artery at point where it is applied to the PIN	33.22	12.47	-7 to 46

Minus (-) sign indicates distances proximal to the transepicondylar line

Leash of Henry

The leash of Henry which is a vascular plexus formed by the radial recurrent vessels which if it crosses the posterior interosseous nerve can compress it (Fig.16). The leash of Henry crossed the posterior interosseous nerve 55.20 ± 9.90

mm

Fig. 16 Leash of Henry (arrows) compressing posterior interosseous nerve (asterisk); sm - supinator muscle

below the lateral epicondyle (range: 31 to 72.50 mm). It crossed the PIN in 30 upper extremities (75%).

6.4 Pennation angle

Pennation angle is the angle between the line along the radius and the direction of muscle fibres. The pennation angle for both the superficial and deep layers of the supinator were measured (Table 8) (Figs. 17 and 18).

Table 8. Pennation angles of the superficial and deep layers of supintor

Parameter	Mean angle	SD	Range
Pennation angle of the superficial layer	32.62°	9.68	16°- 57°
Pennation angle of the deep layer	47.27°	13.97	31°-80°

6.5 Morphometry of the arcade of Frohse

The morphometry of the arcade of Froshe was done by measuring the length and width of the arcade (Table 9) (Fig. 4).

Table 9. Morphometry of arcade of Frohse

Parameter	Mean value (mm)	SD (mm)	Range (mm)
Length of arcade of Frohse	7.32	1.95	4 - 11
Width of arcade of Frohse	12.35	2.67	6 - 18

Fig. 17 Pennation angle of superficial layer of supinator muscle
rh - radial head; rs -radial styloid process; sm - supinator muscle

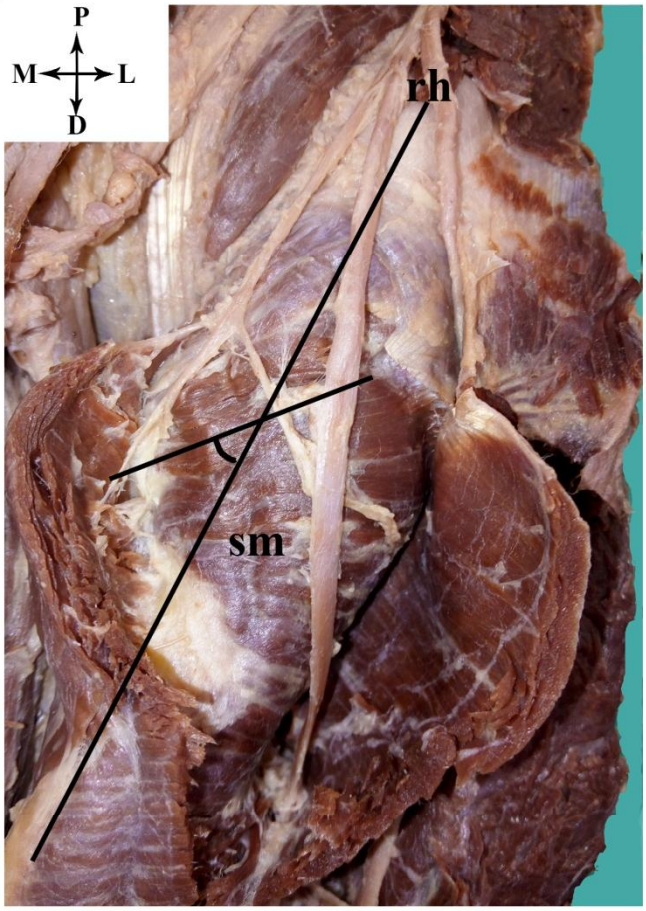

Fig. 18 Pennation angle of deep layer of supinator muscle
rh – radial head; sm - supinator muscle

6.6 Variables to locate the arcade of Frohse

The proximal border of the superficial layer of supinator muscle also referred to as the arcade of Frohse and the distal border of the superficial layer may compress the posterior interosseous nerve. Measurements were taken from bony landmarks like the lateral epicondyle to these borders (Table 10).

Table 10. Measurements to locate the arcade of Frohse

Parameter	Mean distance (mm)	SD (mm)	Range (mm)
Distance between tip of lateral epicondyle and proximal border of superficial layer of supinator muscle (distance AF)	59.60	8.49	50 - 74
Distance between proximal and distal borders of superficial layer of supinator muscle	52.45	13.96	30 -80

Distance between the lateral epicondyle and the proximal border of the superficial layer of the supinator muscle (Distance AF)

The mean distance from the lateral epicondyle to the proximal border of the superficial layer of the supinator muscle was 59.60 ± 8.49 mm. The minimum distance was 50 mm and the maximum distance was 74 mm.

Distance between the proximal and distal borders of the superficial layer of the supinator muscle

The mean distance between the two borders was 52.45 ± 13.96 mm. The minimum distance was observed as 30mm and the maximum distance as 80 mm.

Prediction of the distance AF of any upper extremity

The distance between the tip of the lateral epicondyle and the arcade of Frohse is the "distance AF". The mean distance AF was found to be 59.60 ± 8.49 mm. The distance between the tip of the lateral epicondyle and the tip of the styloid process of the radius is the "length of the forearm". The mean length of the forearm was found to be 258.12 ± 18.63mm. The "ratio AF" was determined by dividing the distance AF by the forearm length (ratio AF = distance AF/forearm length) for each upper extremity. Mean ratio AF was calculated. It was found to be 0.23. This value can be used to predict the distance AF of any upper extremity with a known forearm length. Hence, the predicted distance AF of any upper extremity may be found by multiplying its forearm length by the mean ratio AF (predicted distance AF = measured forearm length x mean ratio AF).

6.7 Variables to localize posterior interosseous nerve

Localisation of posterior interosseous nerve is required to decompress the nerve in cases of posterior interosseous nerve entrapment. The measurements are taken from bony landmarks like the lateral epicondyle and the ulnar styloid process (Table 11).

Table 11. Measurements to localize posterior interosseous nerve (PIN)

Parameter	Mean Value (mm)	SD (mm)	Range (mm)
Distance between lateral epicondyle and entry of PIN into supinator	61.47	9.20	45 -79
Distance between lateral epicondyle and exit of PIN from supinator	85.60	9.66	64 -98
Distance between PIN and proximal edge of supinator	31.75	16.59	- 25 to 50
Length of PIN within supinator	48.35	9.37	27 -64
Distance from interepicondylar reference point to exit of PIN from supinator	88.87	11.98	67 -109
Distance between styloid process of ulna and exit of PIN from supinator	177.30	15.27	154 - 205

Minus (-) sign indicates distances proximal to the transepicondylar line

The distance between lateral epicondyle and the entry and exit of PIN from supinator is shown in Fig. 19.

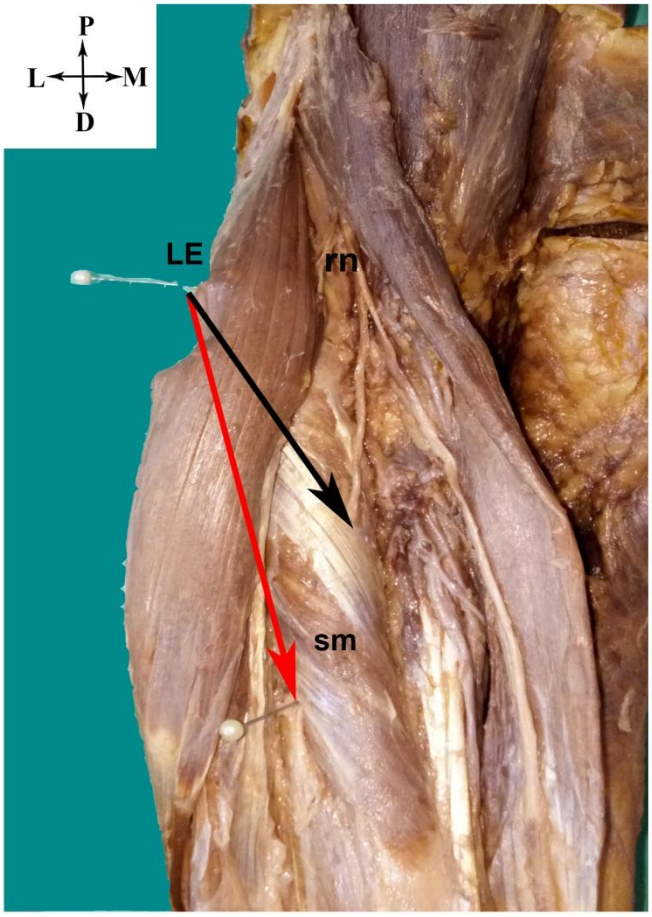

Fig. 19 Distance between lateral epicondyle (LE) and the entry of posterior interosseous nerve into supinator muscle (black arrow) and exit of posterior interosseous nerve from supinator muscle (red arrow); supinator muscle- sm; radial nerve - rn

6.8 Measurements from radial head to supinator muscle and posterior interosseous nerve

The radial head is an easily palpable bony landmark. Measurements were taken from the radial head to the proximal and distal borders of supinator muscle and to the posterior interosseous nerve (Table 12).

Table 12. Measurements from radial head to supinator and posterior interosseous nerve (PIN)

Parameter	Mean Value (mm)	SD (mm)	Range (mm)
Distance between proximal edge of the radial head and proximal border of superficial layer of supinator muscle	25.17	6.50	12 -37
Distance between proximal edge of the radial head and distal border of superficial layer of supinator muscle	83.87	9.87	59 -100
Distance of PIN from radial head to arcade of Frohse	25.25	5.91	11 -37
Distance of PIN from radial head to the PIN exit point from the supinator	69.45	8.86	47 – 85

The distance between proximal edge of radial head and entry and exit of PIN from supinator is shown in Fig. 20.

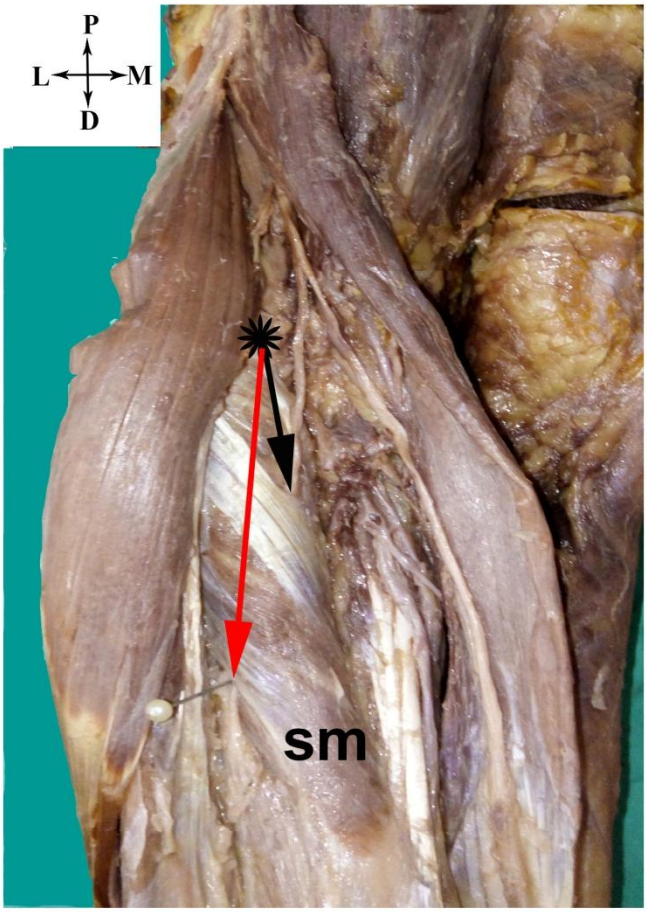

Fig. 20 Distance between the radial head (asterisk) to entrance of posterior interosseous nerve into supinator (black arrow) and exit of it (red arrow); sm - supinator

6.9 i) Trunks of posterior interosseous nerve

The posterior interosseous nerve entered most commonly as a double trunk. Nine of the PIN entered as a single trunk (22.5%) (Fig. 21) and 31 entered the supinator muscle as a double trunk (77.5%) (Fig. 22). Of the 20 right forearms, 7 (35%) had a single trunk and 13 (65%) a double trunk. In the 20 left forearms, 2 (10%) had a single trunk and 18 (90%) a double trunk.

ii) Termination of double trunks of posterior interosseous nerve

Among the 31 limbs which had double trunks of PIN, 11 limbs (35.4%) had PIN supplying supinator before its entry into the muscle and 20 limbs (64.51 %) had PIN travelling through the muscle and then supplying it. Of the 13 right forearms which had double trunks, 3 limbs (23.1%) had PIN supplying supinator muscle before entry and 10 limbs (76.9%) had PIN travelling through the muscle and then supplying it. Of the 18 left forearms which had double trunks, 8 limbs (44.4%) had PIN supplying supinator before its entry into the muscle and 10 limbs (55.5%) had PIN travelling through the muscle and then supplying it.

iii) Exit of PIN from supinator

The posterior interosseous nerve left before the distal edge of the supinator muscle in 37 (92.5%) specimens (Fig. 23) and at the distal edge in 3 specimens (7.5%). In the 20 right limbs, 18 (90%) left before the distal edge of supinator muscle and 2 left (10%) at the distal edge of supinator. In the

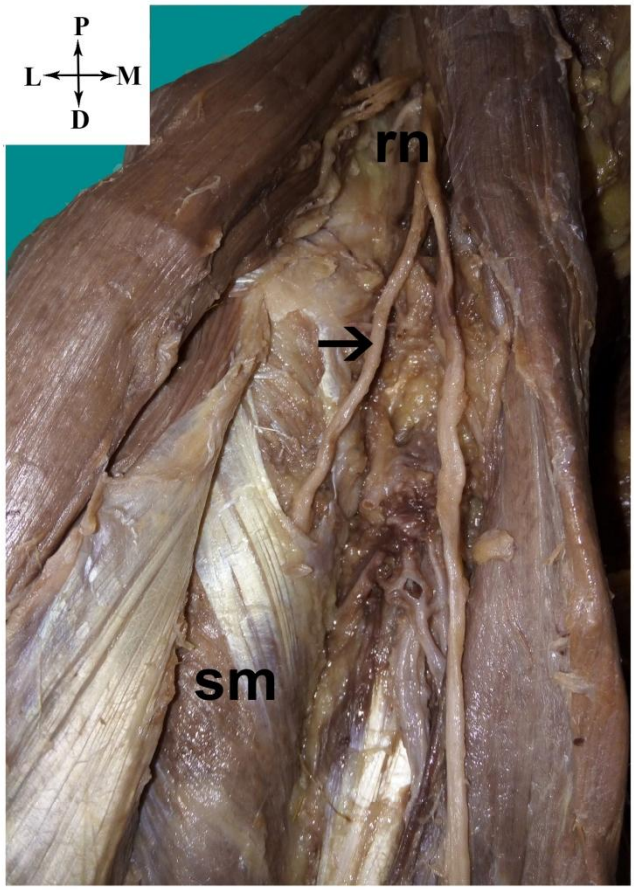

Fig. 21 Single trunk of posterior interosseous nerve (arrow)
rn – radial nerve; sm - supinator muscle

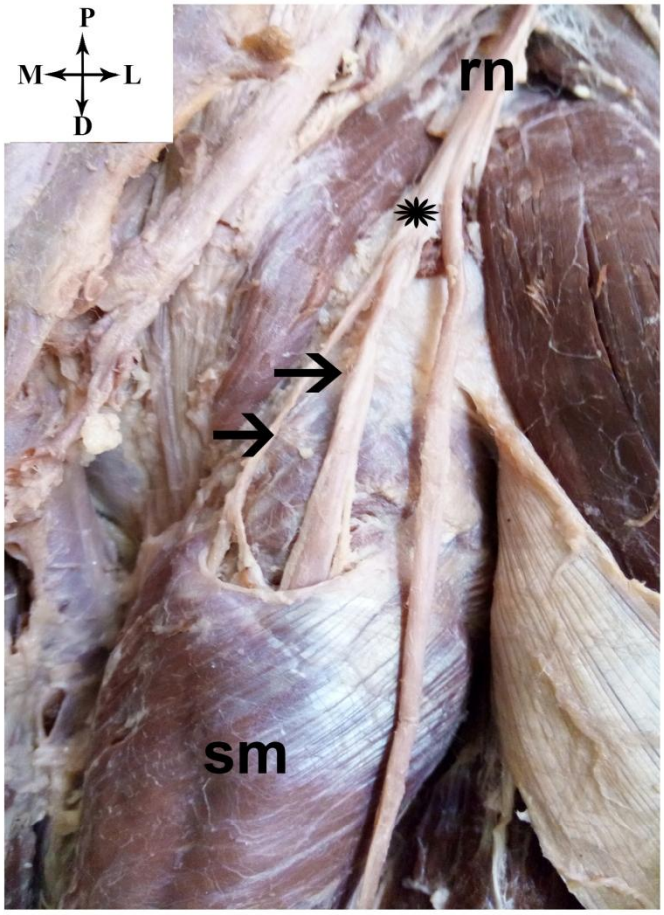

Fig. 22 Double trunk of posterior interosseous nerve (arrows)
rn – radial nerve; sm - supinator muscle;
posterior interosseous nerve (asterisk)

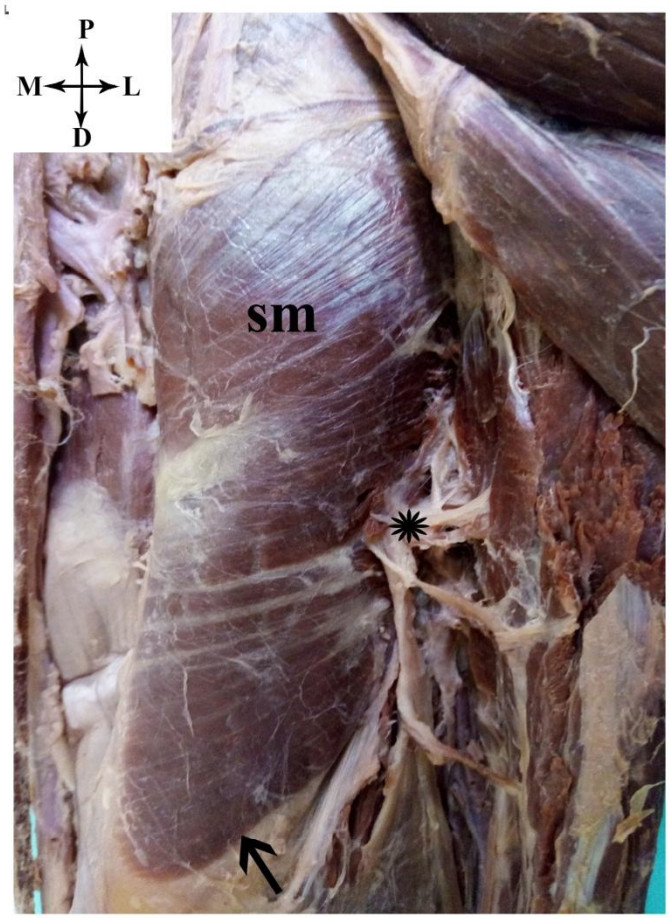

Fig. 23 Posterior interosseous nerve (asterisk) leaving before dista border of supinator muscle (arrow), sm - supinator muscle

supinator muscle and 2 left (10%) at the distal edge of supinator. In the 20 left limbs, 19 (95%) of the limbs had the PIN leaving before the distal edge of the supinator muscle and 1 (5%) at the distal edge.

iv) Flattening of PIN at the proximal or distal borders of supinator

Fourteen limbs (35%) showed flattening at the proximal border (arcade) and 16 limbs (40%) showed flattening at the distal border (arcade). In the 20 right limbs, 4 (20%) limbs showed flattening at the proximal arcade and 7 (35%) at the distal arcade. In the 20 left limbs, 10 (50%) showed flattening at the proximal arcade and 9 (45%) showed flattening at the distal arcade.

6.10 Branches of the posterior interosseous nerve supplying supinator muscle

The total number of branches from the posterior interosseous nerve supplying supinator and branches that were directed to the radial and ulnar side were noted (Fig. 24). The average number of total branches supplying supinator were found to be 3.32. The average number of radial branches were 1.65 and the average number of ulnar branches were 1.67.

6.11 i) <u>Comparison between sides</u>

Comparison of the different parameters between side of the specimen was done using paired t-test. Only one parameter showed a statistically significant difference (Table13).

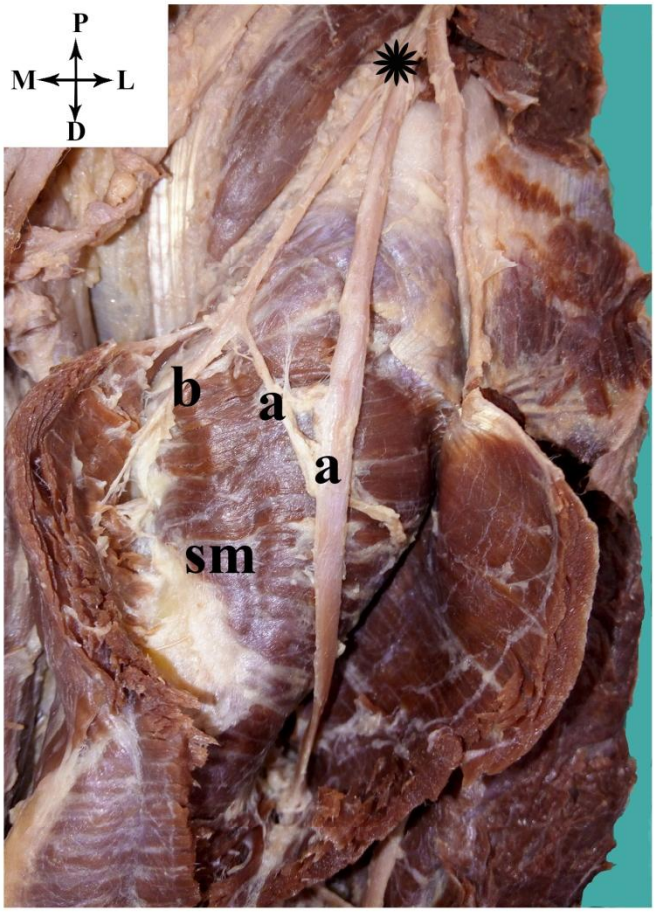

Fig. 24 Radial (a) and ulnar (b) branches of posterior interosseous nerve (asterisk), sm - supinator muscle

Table 13. Comparison of measurements between sides

Parameter	P value
Distance between the proximal and distal arcades of the superficial layer of supinator	0.041

ii) Comparisons between males and females

The different types of proximal and distal borders of superficial layer of supinator muscle were compared between males and females. No significant difference was found.

iii) Comparison of pennation angles of superficial and deep layers of supinator

Table 14. Comparison of pennation angles

Parameter	P value
Pennation angles of superficial and deep layers of supinator	0.0001

There was a statistical significant difference between the pennation angles of the superficial and deep layers of the supinator muscle ($p < 0.0001$) (Table14).

7. DISCUSSION

Posterior interosseous nerve entrapment syndrome, is a condition where there is reduction or loss of extension of all digits and atrophy of the posterior forearm muscles with the exclusion of brachioradialis and extensor carpi radialis longus, as they are supplied from the trunk of the radial nerve. It is important to define the posterior interosseous nerve and its relationship to the musculo-aponeurotic structures at the elbow joint, in order to determine the most common sites likely to promote compression syndrome of the nerve. The most common site implicated is at the arcade of Frohse—that is, the site at which the nerve enters into the supinator muscle. Repetitive movements of pronation and supination can lead to compression of PIN under a tendinous arcade of Frohse. The other site is the distal border (arcade) of the supinator. Localization of these arcades and PIN can facilitate exposure and release of the compressed nerve.

Location of radial nerve division

The radial nerve divides into the superficial radial nerve and posterior interosseous nerve at or around the region of the lateral epicondyle of the humerus (10). The location of the division of the radial nerve is essential to identify the posterior interosseous nerve. Konjengbam and Elangbam (18) did a study on the radial nerve and took measurements from bony landmarks to identify or locate the division of the radial nerve into its

terminal branches. The measurements were marked from two fixed points - the transepicondylar

line (Heuter's line) and the humeroradial joint line. The radial nerve divided from 27mm above transepicondylar line to 30mm below the transepicondylar line. The division was from 48 mm above humeroradial joint line to 12mm below the humeroradial joint line. The mean distance of radial nerve division was 8.93mm distal to transepicondylar line and 8.47 mm proximal to the humeroradial joint line (18).

Fuss and Wurzl (43) in their study, found the radial nerve divided into its superficial and deep branches from 2.5cm above to 3cm below the transepicondylar line

Prasartritha et al. (10) found the mean distance from the humeroradial joint line to the division of the radial nerve as 1.3cm above the humeroradial joint line (10).

Clavert et al. (17) found the mean distance from the humeroradial joint line to the bifurcation of the radial nerve to be -0.87cm. Negative value refers to above the joint line.

Low et al. (39) measured the division of the radial nerve from the lateral condyle. The mean distance was found to be 1.8cm below the lateral condyle.

In the present study, the radial nerve division was measured from the transepicondylar and the humeroradial joint lines. The division of radial nerve was 23 mm proximal to transepicondylar line to 32 mm distal to the transepicondylar line. The findings are similar to those of Konjengbam and Elangbam (18).

The division of the radial nerve was 27 mm proximal to humeroradial joint line to 42 mm distal to the humeroradial joint line.

Knowledge of the division of the radial into its terminal branches in relation to bony landmarks will help in locating PIN for neurolysis.

Nature of compressive structures

There have been various studies on the nature of the structures that can cause compression of the posterior interosseous nerve. Table 15 shows the nature of the proximal border of the superficial layer of the supinator muscle found by different workers.

Konjengbam and Elangbam (18) in their study on Indian cadavers, found that 87% of the upper extremities had a tendinous arcade of Frohse and 13% had a musculotendinous type.

In the present study done on Indian cadavers, the most common type was the tendinous one (48%) followed by the musculotendinous type (45%). The finding that the tendinous type is the most common type seen was in consensus with the findings of Konjengbam and Elangbam and the other workers.

Table 15. Nature of the proximal border of the superficial layer of the supinator muscle in different studies

	n	Tendinous %	Musculotendinous %	Muscular %	Membranous %
Berton et al. (2013)	30	66	17	17	0
Clavert et al. (2009)	30	87	0	0	13
Debouck and Rooze (1995)	106	64	22	12	2
Ebraheim et al. (2000)	20	70	0	0	30
Konjengbam and Elangbam (2004)	46	87	13	0	0
Ozkan et al. (1999)	60	80	0	0	20
Ozturk et al. (2005)	55	87	0	0	13
Papadopoulos et al.(1989)	120	61			
Prasartritha et al. (1993)	60	57	0	0	43
Riffaud et al. (1999)	25	52	40	0	8
Thomas et al. (2000)	31	32	0	0	68
Hazanietal. (2008)	18	78			
Present study	40	48	45	5	2

n - number of dissections

Table 16 shows the nature of the distal border of the superficial layer of the supinator muscle found by different workers.

Table 16. Nature of the distal border of the superficial layer of the supinator muscle in different studies

	n	Tendinous (%)	Musculotendinous (%)	Muscular (%)	Membranous (%)
Berton et al. (2013)	30	37	33	27	3
Konjengbam and Elangbam (2004)	46	65	11	22	2
Prasartritha et al. (1993)	60	65	0	0	35
Riffaud et al. (1999)	25	4	8	88	0
Hazani et al. (2008)	18	55			
Present study	40	20	37	43	0

n - number of dissections

The above table indicates that the tendinous type is the most common type of distal border of the superficial layer of the supinator. But in the study by Riffaud et al. (21) done on European cadavers, the muscular type of distal border had the highest incidence.

Konjengbam and Elangbam (18) in their study on Indian cadavers, found that the most common type of distal border was tendinous (65%) followed by the muscular type (22%).

In the present study done on Indian cadavers, the most common type was muscular (43%) followed by the musculotendinous type (37%). These findings were similar to the findings of Riffaud et al. (21) but contrary to those of Konjengbam and Elangbam (18).

Table 17 shows the nature of the superomedial margin of extensor carpi radialis brevis.

Table 17. Nature of superomedial margin of extensor carpi radialis brevis in different studies

	n	Tendinous %	Musculotendinous %	Muscular %	Membranous %
Konjengbam and Elangbam (2004)	46	78	6.5	13	2
Present study	40	10	20	58	12

n - number of dissections

Konjengbam and Elangbam (18) in their study on forty six upper extremities, found the superomedial margin of extensor carpi radialis brevis was tendinous in the majority of specimens (78%).

In the present study on forty upper extremities, the most common type of superomedial margin of extensor carpi radialis brevis seen was muscular (58%) and in only 10% of extremities was it tendinous. This was not in accordance with the findings of Konjengbam and Elangbam (18).

Distance between humeroradial joint line and structures that cause compression of posterior interosseous nerve (PIN)

Table 18 shows the distance from the humeroradial joint line to the structures causing compression of the posterior interosseous nerve

Table 18. Studies showing comparable values of the distance between humeroradial joint line and compressive structures

Parameters	Mean distance from humeroradial joint line	Mean distance from humeroradial joint line
	Konjengbam and Elangbam (2004)	Present study
Proximal border of superficial layer of supinator muscle	23.59 mm	27.62 mm
Distal border of superficial layer of supinator muscle	65.32 mm	90.27 mm
Medial border of extensor carpi radialis brevis at point where it is applied to PIN	18.51 mm	28.52 mm
Radial recurrent artery at point where it is applied to PIN	6.26 mm	18.69 mm

Konjengbam and Elangbam (18) in their study found the distance of the proximal and distal borders of the superficial layer of supinator to be 23.59 mm and 65.32 mm from the humeroradial joint line respectively.

Berton et al. (14), found the distance between the proximal border of the superficial layer of the supinator muscle and the humeroradial joint line to be 24.3 mm.

In the present study, the distance of the proximal border of the superficial layer of supinator was 27.62 mm from the humeroradial joint line, which was in accordance with the findings of Konjengbam and Elangbam (18) and Berton et al. (14).

The distal border of the superficial layer of supinator was found to be at a distance of 90.27 mm in the present study, which is higher than the value found by Konjengbam and Elangbam (18).

Konjengbam and Elangbam (18) in their study found the distance of the superomedial margin of extensor carpi radialis brevis where it was applied to PIN at a distance of 18.51 mm from humeroradial joint line. The radial recurrent artery at point where it was applied to PIN was at a distance of 6.26 mm from the humeroradial joint line.

In the present study, it was found that the distance of the superomedial margin of extensor carpi radialis brevis where it was applied to PIN was at a distance of 28.52 mm from the humeroradial joint line. The radial recurrent artery at point where it was applied to PIN was at a distance of 18.69 mm from the

humeroradial joint line. The findings were in accordance with those of Konjengbam and Elangbam (18).

Knowledge of these distances of the compressive structures from a fixed bony landmark like the humeroradial joint line is important while undertaking treatment procedures in PIN entrapment.

Distance between transepicondylar line and structures that cause compression of posterior interosseous nerve (PIN)

Table 19 shows the distance from the transepicondylar line to the structures that cause compression of the posterior interosseous nerve.

Table19. Studies showing comparable values of the distance between transepicondylar line and compressive structures

Parameters	Mean distance from transepicondylar line	Mean distance from transepicondylar line
	Konjengbam and Elangbam (2004)	Present study
Proximal border of superficial layer of supinator muscle	38.88 mm	42.05 mm
Distal border of superficial layer of supinator muscle	80.25 mm	105.62 mm
Medial border of extensor carpi radialis brevis at point where it is applied to PIN	36.44 mm	42.42 mm
Radial recurrent artery at point where it is applied to PIN	22.30 mm	33.22 mm

Konjengbam and Elangbam (18) in their study found the distance of the proximal and distal borders of the superficial layer of supinator to be 38.88 mm and 80.25 mm from the transepicondylar line respectively.

Fuzz and Wurzl (43) found the proximal border of the supinator muscle (arcade of Froshe) to be 3 to 5 cm below the transepicondylar line.

In the present study, the distance of the proximal and distal borders of the superficial layer of supinator was found to be 42.05 mm and 105.62mm from the transepicondylar line respectively, which was in keeping with the findings of Konjengbam and Elangbam (18) and Fuzz and Wurzl (43).

Konjengbam and Elangbam (18) in their study found the distance of the superomedial margin of extensor carpi radialis brevis where it was applied to PIN was at a distance of 36.44 mm from the transepicondylar line.

In the present study, it was found that the distance of the superomedial margin of extensor carpi radialis brevis where it was applied to PIN was at a distance of 42.42 mm from the transepicondylar line. The findings were in line with those of Konjengbam and Elangbam (18).

Konjengbam and Elangbam (18) found the radial recurrent artery at point where it was applied to PIN at a distance of 22.30 mm from the transepicondylar line.

In the present study, the radial recurrent artery at point where it was applied to PIN was at a distance of 33.22 mm from the transepicondylar line.

Tubbs et al. (41) found the leash of Henry where it crossed the posterior interosseous nerve was 5 cm (range: 3.5 to 6cm) below the lateral epicondyle.

In the present study, the leash of Henry, where it crossed the posterior interosseous nerve was 55.20 ± 9.90 mm (range: 31 to 72.50mm) below the lateral epicondyle.

Knowledge of these distances of the compressive structures from a fixed bony landmark like the transepicondylar line is important while undertaking treatment procedures in PIN entrapment.

Distance between proximal and distal borders

Berton et al. (14), found the mean distance between the proximal and the distal borders of the superficial layer of the supinator muscle to be 41.4mm with a range of 34 to 53mm.

In the present study, the mean distance between the proximal and the distal borders of the superficial layer of the supinator muscle was found to be 52.45±13.96 with a range of 30 – 80mm. This finding is similar to that of Berton et al. (14).

Pennation angles

Pennation angle is the angle formed between the radial shaft axis and the direction of muscle fibres of the supinator muscle. Berton et al. (14) found the pennation angle of the superficial layer to be 33.6° ± 4.2° (range: 28°-41°) and of the deep layer to be 50.2° ± 6.6 ° (range: 42°-70°).

Comparison of the pennation angles of the superficial and deep layers showed a statistically significant difference ($p<0.0001$).

Papadopoulos et al. (20) found the pennation angle of the superficial layer ranged from18° to 38°.

In the present study, the mean of the pennation angle of the superficial layer of the supinator muscle was found to be 32.62°±9.68° (range: 16° – 57°) and the mean of the pennation angle of the deep layer was found to be 47.27°±13.97 (range: 31° - 80°). Comparison of the pennation angles of the superficial and deep layers showed a statistically significant difference ($p<0.0001$). The findings are similar to those of Berton et al. (14) and Papadopoulos et al. (20).

Morphometry of arcade of Frohse

The arcade of Frohse is the most common structure causing compression of the posterior interosseous nerve (5).

Ozturk et al. (5) described the morphometry of the arcade of Frohse by measuring the length, width and thickness of the arcade. The mean length of the arcade was found to be 8.60±3.51mm (range: 2.77- 20.20mm) and the mean width was found to be 10.13±2.10 mm (range: 5.65-13.61mm). The mean thickness of the arcade of Frohse was found to be 0.77±0.34mm (range: 0.25 – 1.78mm).

Clavert et al. (17) found the average length of the arcade of Frohse to be 26± 5mm (range: 16.9 – 32.4mm).

In the present study, the mean length of the arcade of Frohse was found to be 7.32 ± 1.95 mm (range:4 – 11mm). The mean width of the arcade was found to be 12.35± 2.67 (range:6 – 18mm). The findings in the present study were similar to those obtained by Ozturk et al.(5)(Chart 12).

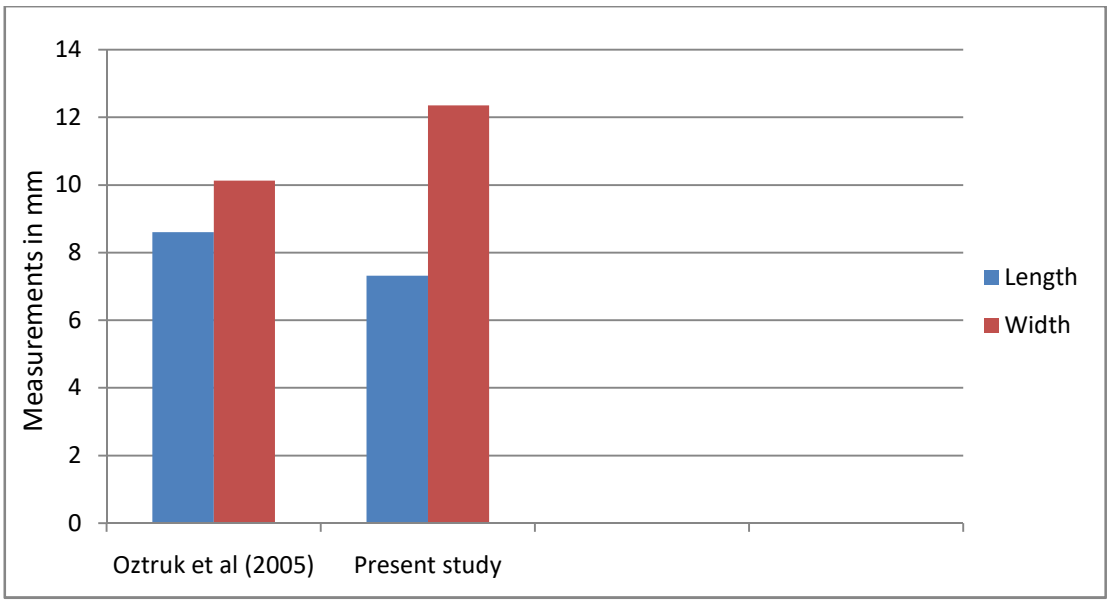

Chart 12. Morphometry of arcade of Frohse

Measurements to locate the arcade of Frohse

i. Distance between tip of lateral epicondyle and proximal border of superficial layer of supinator muscle (distance AF)

Inorder to decompress the nerve at the arcade of Frohse, measurements were taken from bony landmarks such as the lateral epicondyle. The lateral epicondyle is a reliable landmark (14).

Berton et al. (14) found the average distance from the lateral epicondyle to the arcade of Froshe to be 41.6mm (range 32.5 – 61.5mm).

The distance AF was found to be 38.9 mm by Konjengbam and Elangbam (18), 47 mm by Werner (23),46.2 mm by Ozturk et al. (5), 49.1 mm by Papadopoulos et al. (20) and 53 mm by Artico et al (44).

In the present study, the average distance to the arcade of Frohse from the lateral epicondyle was 59.60 ± 8.49mm (range: 50 – 74 mm). This was similar to the findings of Berton et al. (14) and the other workers.

ii) Distance between proximal and distal borders of superficial layer of supinator muscle

Berton et al. (14) found the mean distance between the proximal and distal borders of superficial layer of supinator muscle to be 41.4mm (range: 34- 53mm).

Konjengbam and Elangbam (18) and Artico (44) found the mean distance between the proximal and distal borders of superficial layer of supinator muscle to be 42 mm and 31 mm respectively.

In the present study the distance between the proximal and distal borders was found to be52.45 ± 13.96 mm (range: 30 – 80mm). This was similar to the findings of Berton et al. (14) and the other workers.

Measurements to localize posterior interosseous nerve (PIN)

Identifying the precise location of the posterior interosseous nerve will help during decompressive procedures or neurotization. Knowledge of the motor branches to supinator is important as its branches can be transferred to PIN.

i) Distance between lateral epicondyle and entry of PIN into supinator

Tubbs et al. (41) measured the average distance between the lateral epicondyle and the entry of posterior interosseous nerve between the superficial and deep layers of supinator muscle was 6cm (range 4.5 to 7.5 cm).

Vergara and Ramírez (27) found the distance between the lateral epicondyle and the entrance to the AF was 47.1 mm (range: 39–57 mm).

In the present study, the average distance between the lateral epicondyle and the entry of posterior interosseous nerve into supinator was 61.47 ± 9.20mm (range: 45 – 79 mm). The findings conform to the findings of Tubbs et al. (41) and Vergara and Ramírez (27).

ii) Distance between lateral epicondyle and exit of PIN from supinator

The distal border of the supinator muscle can be a compressive structure for the posterior interosseous nerve. Hence, distance from the lateral epicondyle to the exit of the nerve from supinator muscle was measured

Tubbs et al. (41) found the average distance from the lateral epicondyle to the exit of the posterior interosseous nerve from supinator muscle was 12cm (range: 10 -15 cm).

Vergara and Ramírez (27) found the distance from the lateral epicondyle to the exit of the PIN from supinator was 84.2 mm (76–96 mm).

In the present study, the average distance from the lateral epicondyle to the exit of posterior interosseous nerve from supinator was 85.60 ± 9.66mm (range: 64- 98 mm). The findings conform to the findings of Tubbs et al. (41) and Vergara and Ramírez (27).

iii) Distance between PIN and proximal edge of supinator

Ozkan et al.(12) found the average distance of the posterior interosseous nerve from the radial nerve division to the proximal edge of the supinator muscle was 46mm (range: 35 – 65mm).

Clavert et al. (17) found the distance of the posterior interosseous nerve from the radial nerve division to the proximal edge of the supinator muscle was 3.75 cm (from 2.01 to 5.48cm;S.D. =0.98 cm).

In a similar study, Thomas et al. (11) found the distance of the posterior interosseous nerve from the radial nerve division to the proximal edge of the supinator muscle was 3.6± 0.7 cm.

The distance between PIN and the arcade of Frohse was found to be 25.8 mm (range : 18–30 mm) by Vergara and Ramírez (27) in their study.

In the present study the average distance from the radial nerve division to proximal edge of the supinator muscle was 31. 75± 16.59 mm.

iv) Length of PIN within supinator

The posterior interosseous nerve is at risk to iatrogenic injury during surgeries in the region of the elbow joint. Knowledge of the relationship between the PIN and the supinator is essential to prevent such injuries.

Thomas et al. (11) found the average length of the posterior interosseous nerve within the supinator muscle to be 3.8 ± 0.9 cm.

Tubbs et al. (32) found the average length of posterior interosseous nerve within the supinator muscle to be 4cm (range: 2.9 – 5.2cm).

Molina et al.(3) measured the average length of the nerve to be 2.9 cm (range : 2- 6cm).

In the present study, the length of the nerve within supinator was 48.35 ± 9.37 mm (range: 27 – 64mm). The findings are similar to those of Thomas et al. (11), Tubbs et al. (32) and Molina et al (3).

v) Distance from interepicondylar reference point to exit of PIN from supinator

Duquin et al. (40), measured the average distance from the intercondylar reference point to the exit of the posterior interosseous nerve from supinator to be 90.21 ± 15.61 mm.

In the present study the average distance from the intercondylar reference point to the exit point of PIN from supinator was measured as

88.87 ± 11.98 mm (range: 67 – 109 mm). The finding is similar to the findings of Duquin et al. (40).

vi) Distance between styloid process of ulna and exit of PIN from supinator

Tubbs et al. (41) measured the average distance from the ulnar styloid process to the exit of posterior interosseous nerve from supinator muscle to be 18cm (range: 15 – 21cm).

In the present study, the average distance from the ulnar styloid process to the exit of posterior interosseous nerve from supinator was 177.30 ± 15.27mm (range:154 – 205mm). The finding conforms to those of Tubbs et al. (41).

vii) Trunks of posterior interosseous nerve

Tubbs et al.(32), mentioned that the posterior interosseous nerve entered the supinator muscle most commonly as a single trunk. Of the 26 cadavers (52 sides) dissected, 29 sides showed only a single trunk and the remaining 23 showed a double trunk.

In the present study, the posterior interosseous nerve entered the supinator muscle most commonly as a double trunk. Nine of the PIN entered as a single trunk (22.5%) and 31 entered the supinator muscle as a double trunk (77.5%). This finding is different from the findings of Tubbs et al.(32).

viii) Termination of trunks of posterior interosseous nerve

Tubbs et al. (32), described that in the 23 specimens, which had two trunks both the branches of the posterior interosseous nerve were of equal

size and the medial of the two branches terminated on the supinator muscle and the lateral branch travelled through the supinator and then supplied.

In the present study, in the 31 limbs which had double trunks,in 11 limbs (35.4%) PIN terminated on supinator before entering the muscle and in 20 limbs (64.51 %), PIN travelled through the muscle and then supplied it.

ix) Exit of PIN from supinator

Tubbs et al. (32), did a study on 52 limbs and found that in 10 specimens the posterior interosseous nerve left the supinator muscle before the distal edge.

In the present study, of the total of 40 limbs the posterior interosseous nerve left before the distal edge of the supinator muscle in 37 (92.5%) specimens and at the distal edge in 3 specimens (7.5%). This finding is different from the findings of Tubbs et al (32).

x) Flattening of PIN at the proximal or distal borders of supinator

Berton et al.(15), found that in all the 30 specimens that were dissected the posterior interosseous nerve showed slight flattening at the proximal and distal borders (arcades) of the supinator muscle.

In the present study, of the 40 limbs dissected, 14 limbs (35%) showed flattening at the proximal border (arcade) and 16 limbs (40%) showed flattening at the distal border (arcade).

Knowledge of variation of the PIN (single or double trunk) could provide an additional compression site for this nerve, which is responsible for some atypical presentations of symptoms and for partial recovery following surgical decompression. During exploration, it is essential to know how far the PIN travels distally or proximally (11).

Measurements from radial head to supinator and posterior interosseous nerve (PIN)

The proximal head of the radius at the humeroradial joint can be easily identified as it moves with pronation and supination of the forearm. Hence, measurements can be made from the radial head to the compressive structures and the posterior interosseous nerve, before surgical exploration is undertaken.

i) Distance between proximal edge of the radial head and proximal border of superficial layer of supinator muscle

Ozkan et al. (12), found the average distance from the radial head to the proximal border of the superficial layer of the supinator muscle to be 21mm (range: 17 – 30mm).

In the present study, the average distance from the proximal edge of the radial head to the proximal border of the superficial layer of the supinator muscle was 25.17± 6.50 mm (range 12 – 37 mm). This finding conforms to the results of Ozkan et al. (12).

ii) Distance between proximal edge of the radial head and distalborder of superficial layer of supinator muscle

In the present study, the average distance from the proximal edge of the radial head to the distal border of the superficial layer of the supinator muscle was 83.87 ± 9.87 mm (range: 12 – 37 mm).

iii) Distance of the PIN from radial head to arcade of Frohse

Hazani et al.(22) measured the distance of posterior interosseous nerve from the radial head to the arcade of Frohse and found it to be 3.4± 0.3cm.

In our present study, the average length of posterior interosseous nerve from the radial head to the arcade of Frohse was found to be 25.25 ± 5.91 mm (range: 11 – 37mm). The finding is similar to the findings of Hazani et al.(22).

iii) Distance of the PIN from radial head to the PIN exit point from the supinator

Hazani et al. (22) measured the distance from the radial head to the posterior interosseous nerve exit point from supinator muscle and found it to be 7.4 ± 0.4cm.

The distance between the radial head and the exit of PIN to the posterior compartment was 63 mm (range:50–78 mm) in the study by Vergara and Ramírez (27).

In the present study, the average distance from the radial head to the posterior interosseous nerve exit point from supinator muscle was found to be 69.45± 8.86 mm (range: 47 – 85mm). The finding is similar to the findings of Hazani et al. (22) and Vergara and Ramírez (27).

Branches of posterior interosseous nerve supplying supinator muscle

It is important to know the number of branches of PIN supplying supinator, since during the treatment of entrapment neuropathy of PIN, the whole superficial layer of supinator has to be opened up and not just the proximal edge, resulting in complete decompression of the PIN and its branches.

Duquin et al. (31), described that the branches supplying supinator muscle was highly varied and an average of the branches supplying the supinator muscle were 4.25±1.82 (range: 2 -9). The average of the radial branches was 2.33 ± 1.61 and of the ulnar branches was 1.92 ± 0.90 (range: 0-3).

Abrams et al. (45) found a mean of 3.9 branches to the supinator in a study of 20 cadavers.

In the present study, the average of the total branches supplying supinator was 6.65± 1.03 (range: 5-8) . The average of the radial branches was 3.30± 1.34 (range: 2-6) and of the ulnar branches was 3.35 ± 1.46 (range:0-6).

8. CONCLUSIONS

Precise anatomical knowledge of the supinator and its nerve supply is essential in understanding the pathophysiology of posterior interosseous nerve syndrome. Localization of the arcades and the posterior interosseous nerve (PIN) will help to reduce surgical morbidity in the treatment of PIN entrapment.

The following conclusions were drawn.

1. Division of the radial nerve into its terminal branches was within a range of 23 mm above the transepicondylar line to 32 mm below the transepicondylar line .
2. Division of the radial nerve into its terminal branches was within a range of 27 mm above the humeroradial joint line to 42 mm below the humeroradial joint line.
3. The most common type of proximal border of superficial layer of supinator is the tendinous type (47.5%).
4. The most common type of distal border of superficial layer of supinator is the muscular type (42.5%).
5. The mean distance between the humeroradial joint line and the proximal and distal borders of the superficial layer of the supinator muscle was found to be 27.62 ± 5.18 mm and 90.27 ± 10.17 mm respectively.

6. The mean distance between the transepicondylar line and the proximal and distal borders of the superficial layer of the supinator muscle was found to be 42.05 ± 5.82 mm and 105.62 ± 10.80 mm respectively.
7. The mean pennation angle of the superficial and deep layers of the supinator muscle was found to be 32.62° ± 9.68° and 47.27°± 13.97° respectively.
8. The mean length and width of the arcade of Froshe was found to be 7.32 ± 1.95mm and 12.35 ± 2.67mm respectively.
9. The mean distance from the lateral epicondyle to the proximal border of the superficial layer of the supinator muscle was found to be 59.60 ± 8.49 mm..
10. The mean distance between the proximal and distal borders of the superficial layer of supinator was found to be 52.45 ± 13.96 mm.
11. The mean distance from the radial head to the proximal and distal borders of the superficial layer of the supinator muscle was found to be 25.17 ± 6.50 mm and 83.87 ± 9.87 mm respectively.
12. The mean distance from the lateral epicondyle to the entry and exit of posterior interosseous nerve from supinator was found to be 61.47 ± 9.20 mm and 85.60 ± 9.66 mm respectively.
13. The mean distance from the ulnar styloid process to the exit of posterior interosseous nerve from the supinator was found to be 177.30 ± 15.27 mm.
14. The mean distance from the radial head to the entry and exit of posterior interosseous nerve from supinator was found to be 25.25 ± 5.91 mm and 69.45 ± 8.86 mm respectively.

9. LIMITATIONS

The present study was done on formalin embalmed upper extremities, where tissues are hard and fixed. In the actual surgical setting, the tissues are supple and soft. Further studies in fresh cadaveric specimens would be needed so that anatomic data derived from such studies can be applied to the clinical setting during the treatment of posterior interosseous nerve entrapment.

10. REFERENCES

1. Susan Standring. Gray's Anatomy. In: Forty First edition.

2. Barnum M,Mastey RD,Weiss AP,. Radial tunnel syndrome. Hand Clin. 1996;12:679–89.

3. Portilla Molina AE, Bour C, Oberlin C, Nzeusseu A, Vanwijck R. The posterior interosseous nerve and the radial tunnel syndrome: an anatomical study. Int Orthop. 1998;22(2):102–6.

4. Arle, Eric.L.Zalger. Surgical treatment of common entrapment neuropathies in upperlimbs. Muscle and Nerve 2000;1160-74

5. Ozturk A, Kutlu C, Taskara N, Kale AC, Bayraktar B, Cecen A. Anatomic and morphometric study of the arcade of Frohse in cadavers. Surg Radiol Anat. 2005 Aug;27(3):171–5.

6. Kopell HP, Thompson WAL. Peripheral entrapment neuropathies. In: 1st edn. Baltimore; 1963. p. 121–8.

7. Capener,Norman. The vulnerability of the posterior interosoeus nerve of the forearm, A Case Report and an Anatomical Study.The journal of bone and joint surgery.1966;770-3

8. Morton Spinner spinner. The arcade of frohse and its relationship to posterior interosseous nerve paralysis. J Bone Jt Surg. 1968;50B.

9. Debouck C, Rooze M. The arcade of Fröhse: an anatomic study. Surg Radiol Anat SRA. 1995;17(3):245–8.

10. Prasartritha T, Liupolvanish P, Rojanakit A. A study of the posterior interosseous nerve (PIN) and the radial tunnel in 30 Thai cadavers. J Hand Surg. 1993 Jan 1;18(1):107–12.

11. Thomas SJ, Yakin DE, Parry BR, Lubahn JD. The anatomical relationship between the posterior interosseous nerve and the supinator muscle. J Hand Surg. 2000 Sep;25(5):936–41.

12. Özkan M, Bacakoğlu AK, Gül Ö, Ekin A, Mağden O. Anatomic study of posterior interosseous nerve in the arcade of Frohse. J Shoulder Elbow Surg. 1999 Nov 1;8(6):617–20.

13. Kline DG, Hudson AR. Nerve injuries—operative results for major nerve injuries, entrapments, and tumors. Philadelphia; 1995.

14. Berton C, Wavreille G, Lecomte F, Miletic B, Kim H-J, Fontaine C. The supinator muscle: anatomical bases for deep branch of the radial nerve entrapment. Surg Radiol Anat. 2013 Apr 1;35(3):217–24.

15. Davies F, Laird M. The supinator muscle and the deep radial (posterior interosseous) nerve. Anat Rec. 1948 Jun 1;101(2):243–50.

16. Andrea M Trescot. Peripheral Nerve Entrapments: Clinical Diagnosis and Management. In: Peripheral Nerve Entrapments: Clinical Diagnosis and Management.

17. Clavert K. Frohse's arcade is not the exclusive compression site of radial nerve in its tunnel. otsr. 2008;95(2):114–8.

18. Konjengbam M, Elangbam J. Radial nerve in the radial tunnel: Anatomic sites of entrapment neuropathy. Clin Anat. 2004 Jan;17(1):21–5.

19. Ebraheim NA, Jin F, Pulisetti D, Yeasting RA. Quantitative anatomical study of the posterior interosseous nerve. Am J Orthop Belle Mead NJ. 2000 Sep;29(9):702–4.

20. Papadopoulos N, Paraschos A, Pelekis P. Anatomical observations on the arcade of Frohse and other structures related to the deep radial nerve. Anatomical interpretation of deep radial nerve entrapment neuropathy. Folia Morphol. 1989;37(3):319–27.

21. Riffaud L, Morandi X, Godey B, Brassier G, Guegan Y, Darnault P, et al. Anatomic bases for the compression and neurolysis of the deep branch of the radial nerve in the radial tunnel. Surg Radiol Anat SRA. 1999;21(4):229–33.

22. Hazani R, Engineer NJ, Mowlavi A, Neumeister M, Lee WP, Wilhelmi BJ. Anatomic landmarks for the radial tunnel. Eplasty. 2008;8:e37.

23. CARL-OL OF, WERNER. Lateral elbow pain and posterior interosseous nerve entrapment .Acta Orthopaedica Scandinavica ,1979:1-60

24. Lister K. The radial tunnel syndrome .The Journal of hand surgery.1979 Jan:52-9

25. Lee D. A 3 dimensional approach to pennation angle estimation for human skeletal muscle. Journal of biomechanics. 2013 Jun 20;

26. Enzo Silvestri DO. Ultrasound Anatomy of Lower Limb Muscles: A Practical Guide - Enzo Silvestri, Alessandro Muda, Davide Orlandi - Google Books ;20

27. Vergara-Amador E, Ramírez A. Anatomic study of the extensor carpi radialis brevis in its relation with the motor branch of the radial nerve. Orthop Traumatol Surg Res. 2015 Dec;101(8):909–12.

28. Kirici K. Investigation of two possible compression sites of deep branch of radial nerve and nerve supply of the extensor carpi radialis brevis. Neurol Med Chir. 2004;44:14–9.

29. Kalb K, Gruber P, Landsleitner B. [Compression syndrome of the radial nerve in the area of the supinator groove. Experiences with 110 patients]. Handchir Mikrochir Plast Chir Organ Deutschsprachigen Arbeitsgemeinschaft Handchir Organ Deutschsprachigen Arbeitsgemeinschaft Mikrochir Peripher Nerven Gefasse Organ V. 1999 Sep;31(5):303–10.

30. Chang LW, Gowans JDC, Granger CV, Millender LH. Entrapment neuropathy of the posterior interosseous nerve. A complication of rheumatoid arthritis. Arthritis Rheum. 1972 Jul 1;15(4):350–2.

31. Galbraith KA, McCullough CJ. Acute nerve injury as a complication of closed fractures or dislocations of the elbow. Injury. 1979 Jan 1;11(2):159–64.

32. Tubbs R, Mortazavi M, Farrington W, Chern J, Shoja M, Loukas M, et al. Relationships Between the Posterior Interosseous Nerve and the Supinator Muscle: Application to Peripheral Nerve Compression Syndromes and Nerve Transfer Procedures. J Neurol Surg Part Cent Eur Neurosurg. 2013 May 21;74(05):290–3.

33. Suematsu N, Hirayama T. Posterior interosseous nerve palsy. J Hand Surg Edinb Scotl. 1998 Feb;23(1):104–6.

34. Hirachi K, Kato H, Minami A, Kasashima T, Kaneda K. Clinical features and management of traumatic posterior interosseous nerve palsy. J Hand Surg Edinb Scotl. 1998 Jun;23(3):413–7.

35. Ay S, Apaydin N, Acar H, Akinci M, Piskin A, Tekdemir I, et al. Anatomic pattern of the terminal branches of posterior interosseous nerve. Clin Anat. 2005 May;18(4):290–5.

36. Roles M. Radial tunnel syndrome , Resistant tennis elbow as a nerve entrapment

37. Baklaci K, ÖZGÜL[2] A. Posterior Interosseous Nerve Entrapment in a Patient with Rheumatoid Arthritis. Arch Rheumatol. 2012;27(3):200–4.

38. Kamineni S, Norgren CR, Davidson EM, Kamineni EP, Deane AS. Posterior interosseous nerve localization within the proximal forearm - a patient normalized parameter. World J Orthop. 2017 Apr 18;8(4):310–6.

39. Low CK, Chew JT, Mitra AK. A surgical approach to the posterior interosseous branch of the radial nerve through the brachioradialis--a cadaveric study. Singapore Med J. 1994 Aug;35(4):394–6.

40. Duquin TR, Chavan PR, Bisson LJ. Innervation of the supinator muscle and its relationship to two-incision distal biceps tendon repair: An anatomic study. Clin Anat. 2010 May;23(4):413–9.

41. Tubbs RS, Salter EG, Wellons III JC, Blount JP, Oakes WJ. Superficial surgical landmarks for identifying the posterior interosseous nerve. J Neurosurg. 2006;104(5):796–9.

42. Hackl M, Wegmann K, Lappen S, Helf C, Burkhart KJ, Müller LP. The course of the posterior interosseous nerve in relation to the proximal radius: Is there a reliable landmark? Injury. 2015 Apr;46(4):687–92.

43. Fuss FK, Wurzl GH. Radial nerve entrapment at the elbow: surgical anatomy. J Hand Surg. 1991 Jul;16(4):742–7.

44. Artico M, Telera S, Tiengo C, Stecco C, Macchi V, Porzionato A, et al. Surgical anatomy of the radial nerve at the elbow. Surg Radiol Anat SRA. 2009 Feb;31(2):101–6.

45. T D, Mj B, Ra A. Anatomical considerations regarding the posterior interosseous nerve during posterolateral approaches to the proximal part of the radius. J Bone Joint Surg Am. 2000 Jun;82(6):809–13.

ANNEXURES

OFFICE OF RESEARCH
INSTITUTIONAL REVIEW BOARD (IRB)
CHRISTIAN MEDICAL COLLEGE, VELLORE, INDIA

Dr. B.J. Prashantham, M.A., M.A., Dr. Min (Clinical)
Director, Christian Counseling Center,
Chairperson, Ethics Committee.

Dr. Alfred Job Daniel, D Ortho MS Ortho DNB Ortho.
Chairperson, Research Committee & Principal

Dr. Nihal Thomas,
MD, MNAMS, DNB (Endo), FRACP (Endo), FRCP (Edin), FRCP (Glasg)
Deputy Chairperson,
Secretary, Ethics Committee, IRB
Additional Vice-Principal (Research)

January 14, 2016

Dr. Jenny Jacob
PG Demonstrator
Department of Anatomy,
Christian Medical College,
Vellore 632 004.

Sub: **Fluid Research grant project NEW PROPOSAL:**
The Supinator Muscle and the Anatomical Basis for the Posterior Interosseous Nerve Entrapment.
Dr. Jenny Jacob, Emp. No: 32340, PG Demonstrator, Anatomy. Dr. Bina Isaac, Emp. No: 12844, Anatomy, Dr.Visalakshi. J, Emp. No: 31093, Lecturer, Department of Biostatistics.

Ref: IRB Min No: 9719 [OBSERVE] dated 10.11.2015

Dear Dr. Jenny Jacob,
The Institutional Review Board (Blue, Research and Ethics Committee) of the Christian Medical College, Vellore, reviewed and discussed your project titled "The Supinator Muscle and the Anatomical Basis for the Posterior Interosseous Nerve Entrapment" on November 10th 2015.

I enclose the following documents:-

1. Institutional Review Board approval 2. Agreement

Could you please sign the agreement and send it to Dr. Nihal Thomas, Addl. Vice Principal (Research), so that the grant money can be released.

With best wishes,

Dr. Nihal Thomas
Secretary (Ethics Committee)
Institutional Review Board

Dr. NIHAL THOMAS
MD.,MNAMS.,DNB(Endo),FRACP(Endo),FRCP(Edin),FRCP(Glasg)
SECRETARY - (ETHICS COMMITTEE)
Institutional Review Board,
Christian Medical College, Vellore - 632 002.

Cc: Dr. Bina Isaac, Dept. of Anatomy, CMC

Ethics Committee Blue, Office of Research, 1st Floor, Carman Block, Christian Medical College, Vellore, Tamil Nadu 632 002
Tel: 0416 – 2284294, 2284202 Fax: 0416 – 2262788, 2284481 E-mail: research@cmcvellore.ac.in

OFFICE OF RESEARCH
INSTITUTIONAL REVIEW BOARD (IRB)
CHRISTIAN MEDICAL COLLEGE, VELLORE, INDIA

Dr. B.J. Prashantham, M.A., M.A., Dr. Min (Clinical)
Director, Christian Counseling Center,
Chairperson, Ethics Committee.

Dr. Alfred Job Daniel, D Ortho MS Ortho DNB Ortho.
Chairperson, Research Committee & Principal

Dr. Nihal Thomas,
MD, MNAMS, DNB (Endo), FRACP (Endo), FRCP (Edin), FRCP (Glasg
Deputy Chairperson,
Secretary, Ethics Committee, IRB
Additional Vice-Principal (Research)

January 14, 2016

Dr. Jenny Jacob
PG Demonstrator
Department of Anatomy,
Christian Medical College,
Vellore 632 004.

Sub: **Fluid Research grant project NEW PROPOSAL:**
The Supinator Muscle and the Anatomical Basis for the Posterior Interosseous Nerve Entrapment.
Dr. Jenny Jacob, Emp. No: 32340, PG Demonstrator, Anatomy. Dr. Bina Isaac, Emp. No: 12844, Anatomy, Dr.Visalakshi. J, Emp. No: 31093, Lecturer, Department of Biostatistics.

Ref: IRB Min No: 9719 [OBSERVE] dated 10.11.2015

Dear Dr. Jenny Jacob,
The Institutional Review Board (Blue, Research and Ethics Committee) of the Christian Medical College, Vellore, reviewed and discussed your project titled "The Supinator Muscle and the Anatomical Basis for the Posterior Interosseous Nerve Entrapment" on November 10th 2015.

The Committee reviewed the following documents:

1. IRB Application format
2. Proforma
3. Cvs of Drs. Jenny Jacob, Bina Isaac, Visalakshi. J
4. No. of documents 1 – 3

The following Institutional Review Board (Blue, Research & Ethics Committee) members were present at the meeting held on November 10th 2015 in the CREST/SACN Conference Room, Christian Medical College, Bagayam, Vellore 632002.

Ethics Committee Blue, Office of Research, 1st Floor, Carman Block, Christian Medical College, Vellore, Tamil Nadu 632 002
Tel: 0416 – 2284294, 2284202 Fax: 0416 – 2262788, 2284481 E-mail: research@cmcvellore.ac.in

Dr. B.J. Prashantham, M.A., M.A., Dr. Min (Clinical)
Director, Christian Counseling Center,
Chairperson, Ethics Committee.

Dr. Alfred Job Daniel, D Ortho MS Ortho DNB Ortho.
Chairperson, Research Committee & Principal

Dr. Nihal Thomas,
MD, MNAMS, DNB (Endo), FRACP (Endo), FRCP (Edin), FRCP
Deputy Chairperson,
Secretary, Ethics Committee, IRB
Additional Vice-Principal (Research)

Name	Qualification	Designation	Affiliation
Dr. Nihal Thomas	MD, MNAMS, DNB(Endo), FRACP (Endo) FRCP(Edin) FRCP (Glasg)	Professor & Head, Endocrinology. Additional Vice Principal (Research), Deputy Chairperson(Research Chairperson), Member Secretary (Ethics Committee), IRB. CMC, Vellore	Internal, Clinician
Dr. Vivek Mathew	MD (Gen. Med.) DM (Neuro) Dip. NB (Neuro)	Professor, Neurology, CMC, Vellore	Internal, Clinician
Dr. Mathew Joseph	MBBS, MCH	Professor, Neurosurgery, CMC, Vellore	Internal, Clinician
Dr. Chandrasingh	MS, MCH, DMB	Professor, Urology, CMC, Vellore	Internal, Clinician
Dr. Balamugesh	MBBS, MD(Int Med), DM, FCCP (USA)	Professor, Pulmonary Medicine, CMC, Vellore	Internal, Clinician
Rev. Joseph Devaraj	BSc, BD	Chaplaincy Department, CMC, Vellore	Internal, Social Scientist
Dr. Rajesh Kannangai	MD, PhD.	Professor, Clinical Virology, CMC, Vellore	Internal, Clinician
Dr. Niranjan Thomas	DCH, MD, DNB (Paediatrics)	Professor, Neonatology, CMC, Vellore	Internal, Clinician
Dr. Inian Samarasam	MS, FRCS, FRACS	Professor, Surgery, CMC, Vellore	Internal, Clinician
Dr. B. J. Prashantham	MA(Counseling Psychology), MA(Theology), Dr. Min(Clinical Counselling)	Chairperson, Ethics Comm IRB. Director, Christian Counse Centre, Vellore	External, Social Scientist

Dr. B.J. Prashantham, M.A., M.A., Dr. Min (Clinical)
Director, Christian Counseling Center,
Chairperson, Ethics Committee.

Dr. Alfred Job Daniel, D Ortho MS Ortho DNB Ortho.
Chairperson, Research Committee & Principal

Dr. Nihal Thomas,
MD, MNAMS, DNB (Endo), FRACP (Endo), FRCP (Edin), FRCP (Gl
Deputy Chairperson,
Secretary, Ethics Committee, IRB
Additional Vice-Principal (Research)

Dr. Ratna Prabha	MBBS, MD	Associate Professor, Clinical Pharmacology CMC, Vellore	Internal, Pharmacologist
Dr. Jayaprakash Muliyil	BSc, MBBS, MD, MPH, Dr PH (Epid), DMHC	Retired Professor, CMC, V	External, Scientist &Epidem
Mrs. Emily Daniel	MSc Nursing	Professor, Medical Surgica Nursing, CMC, Vellore	Internal, Nurse
Ms. Grace Rebecca	MSc (Biostatistics)	Lecturer, Biostatistics, CMC, Vellore	Internal, Statistician
Mr. C. Sampath	BSc, BL	Advocate, Vellore	External, Legal Expert
Dr. Anuradha Rose	MBBS, MD, MHSC (Bioethics)	Associate Professor, Comn Health, CMC, Vellore	Internal, Clinician

We approve the project to be conducted as presented.

Kindly provide the total number of patients enrolled in your study and the total number of withdrawals for the study entitled: "The Supinator Muscle and the Anatomical Basis for the Posterior Interosseous Nerve Entrapment" on a monthly basis. Please send copies of this to the Research Office (research@cmcvellore.ac.in)

Fluid Grant Allocation:

A sum of Rs.12,500/- INR (Rupees Twelve Thousand five hundred Only) will be granted for 2 years.

Yours sincerely

Dr. Nihal Thomas
Secretary (Ethics Committee)
Institutional Review Board

Dr. NIHAL THOMAS
MD, MNAMS, DNB(Endo) FRACP(Endo) FRCP(Edin) FRCP(Glasg)
SECRETARY - (ETHICS COMMITTEE)
Institutional Review Board,
Christian Medical College, Vellore - 632 002.

IRB Min No: 9719 [OBSERVE] dated 10.11.2015

Ethics Committee Blue, Office of Research, 1st Floor, Carman Block, Christian Medical College, Vellore, Tamil Nadu 632 002
Tel: 0416 – 2284294, 2284202 Fax: 0416 – 2262788, 2284481 E-mail: research@cmcvellore.ac.in

Proforma

Cadaver number :

Sex of cadaver:

Division of Radial Nerve

S.No	Parameters	Distance from Humeroradial joint line		Distance fromTransepicondylar line	
		Right arm	Left arm	Right arm	Left arm
1.	Radial nerve division				

Nature of Compressive Structures

S.No	Parameters	Right arm	Left arm
1.	Nature of proximal border of superficial layer of supinator muscle	a) Tendinous ( ) b) Musculotendinous ( ) c) Muscular ( ) d) Membranous ( )	a) Tendinous ( ) b) Musculotendinous ( ) c) Muscular ( ) d) Membranous ( )
2.	Nature of distal border of superficial layer of supinator muscle	a)Tendinous ( ) b) Musculotendinous ( ) c) Muscular ( ) d) Membranous ( )	a) Tendinous ( ) b) Musculotendinous ( ) c) Muscular ( ) d) Membranous ( )
3.	Nature of superomedial margin of ECRB	a) Tendinous ( ) b) Musculotendinous ( ) c) Muscular ( ) d) Membranous ( )	a)Tendinous ( ) b) Musculotendinous ( ) c) Muscular ( ) d) Membranous ( )
4.	Vascular arcades of radial recurrent vessels (Leash of Henry) crossed PIN (Yes/No)		

Distances from Lateral Epicondyle

S.No	Parameters	Right arm	Left arm
1.	Distance between tip of lateral epicondyle and proximal border of superficial layer of supinator muscle(distance AF)		
2.	Distance between proximal and distal arcades of superficial layer of supinator muscle		
3.	Distance of vascular arcades of radial recurrent vessels (Leash of Henry) from lateral epicondyle		

Distances between compressive structures and humeroradial joint line/transepicondylar line

S.No	Parameters	Distance from Humeroradial joint line		Distance from Transepicondylar line	
		Right arm	Left arm	Right arm	Left arm
1.	Medial border of ECRB at point where it is applied to PIN				
2.	Radial recurrent artery at point where it is applied to the PIN				
3.	Superior border of the superficial layer of the supinator muscle				
4.	Inferior border of the superficial layer of the supinator muscle				

Pennation Angles

S.No	Pennation Angles	Right arm	Left arm
1.	Pennation Angle of the superficial layer		
2.	Pennation Angle of the deep layer		

Morphometry of Arcade of Frohse

S.No	Parameters	Right arm	Left arm
1.	Length of arcade of Frohse		
2.	Width of arcade of Frohse		

Borders of Superficial layer of Supinator

S.No	Parameters	Right arm	Left arm
1.	Distance between proximal and distal arcades of superficial layer of supinator muscle		
2.	Distance between proximal radial edge of the radial head and distal border of superficial layer of supinator muscle		
3.	Distance between proximal radial edge of the radial head and distal border of superficial layer of supinator muscle		

Measurements of the Posterior Interosseous Nerve (PIN)

S.No	Parameters	Right arm	Left arm
1.	Distance between lateral epicondyle and entry of PIN into supinator		
2.	Distance between lateral epicondyle and exit of PIN from supinator		
3a)	Did PIN enter as a single trunk or double trunks		
3b)	If there were two trunks – how did they terminate? – *a)supplied supinator or b) travelled through it and then supplied it*		
4.	Distance from PIN and proximal edge of supinator		
5.	Length of PIN within supinator		
6.	Where did PIN leave the supinator?	a) Before distal edge ( ) b) At distal edge ( )	a)Before distal edge ( ) b) At distal edge ( )
7.	Whether the nerve was flattened at a) Proximal arcade b) Distal arcade		
8.	Distance between styloid process of ulna and exit of PIN from supinator		
9.	Length of PIN from radial head to arcade of Frohse		
10.	Length of the PIN from radial head to the PIN exit point from the supinator		
11.	Distance from Interepicondylar Reference Point to exit of PIN from supinator		

Number of branches of Posterior Interosseous Nerve (PIN) supplying the Supinator muscle

S.No	Branches of PIN	Right arm	Left arm
1.	Total branches		
2.	Radial branches		
3.	Ulnar branches		

Length of forearm

S.No	Length of forearm	Right arm	Left arm
1.	Forearm length (from lateral epicondyle to radial styloid process)		