PARTIAL OSSICULAR RECONSTRUCTION PROSTHESIS AND TOTAL OSSICULAR RECONSTRUCTION PROSTHESIS – A REVIEW ON ITS POSTOPERATIVE & FUNCTIONAL OUTCOME ON HEARING

Dissertation submitted to

THE TAMIL NADU DR.M.G.R. MEDICAL UNIVERSITY

In partial fulfillment of the regulations for the award of the degree of M.S., (Oto-Rhino-Laryngology) Branch – IV

DEPARTMENT OF UIORL
MADRAS MEDICAL COLLEGE
CHENNAI 600003

THE TAMIL NADU DR. M.G.R. MEDICAL UNIVERSITY
CHENNAI

CERTIFICATE

This is to certify that this dissertation entitled **"PARTIAL OSSICULAR RECONSTRUCTION PROSTHESIS AND TOTAL OSSICULAR RECONSTRUCTION PROSTHESIS- A REVIEW ON ITS POST-OPERATIVE/ FUNCTIONAL OUTCOME ON HEARING"** is a record of the bonafide research work done by **Dr.MEENAXI P. MEHTA,** under my guidance and supervision in the upgraded institute of otorhinolaryngology, Madras Medical College, Chennai - 600003.

GUIDE
Prof. DR.N.SURESH KUMAR, MS., DLO.,
Professor of ENT
Department of UIORL
Madras Medical College
Chennai 600003

DIRECTOR & PROFESSOR
Prof.DR.R.MUTHUKUMAR, MS., DLO.,
Department of UIORL
Madras Medical College
Chennai 600003

DEAN
Prof.Dr.R.NARAYANA BABU, MD, DCH
Madras Medical College,
Rajiv Gandhi Govt General Hospital,
Chennai – 600003.

DECLARATION

I, Dr.MEENAXI P. MEHTA, solemnly declare that the dissertation on - **"PARTIAL OSSICULAR RECONSTRUCTION PROSTHESIS AND TOTAL OSSICULAR RECONSTRUCTION PROSTHESIS- A REVIEW ON ITS POST-OPERATIVE/ FUNCTIONAL OUTCOME ON HEARING"** was done by me at Madras Medical College and Rajiv Gandhi Government General Hospital under the guidance and supervision of Prof.Dr. N. Suresh Kumar M.S.,D.L.O.,Professor of ENT, Department of ENT, Madras Medical College, Chennai.

The dissertation is submitted to the Tamil Nadu DR.MGR medical university towards the partial fulfillment of the requirements of MS Branch IV – Otorhinolaryngology degree examination.

Dr.MEENAXI P. MEHTA

Chennai
Date

ACKNOWLEDGEMENT

I thank our respected Dean **Prof.Dr.Narayana Babu, MD., D.Ch.,** Madras Medical College, Chennai for permitting me to utilize the facilities of the college for this work.

I have great pleasure in expressing my deep gratitude to my guide, **Prof.Dr.N.SURESH KUMAR, M.S., D.L.O.,** Professor of ENT, Department of ENT, Madras Medical College, Chennai, for his kind encouragements and valuable guidance during the period of the study without which this dissertation would not have materialized.

I express my sincere thanks to **Prof.Dr.R.MUTHUKUMAR, M.S., D.L.O.,** Director & Head of the department, Department of ENT, Madras Medical College, Chennai for his valuable suggestions and encouragement during my study.

It is my privilege to thank my assistant professors **Dr.S.MOHAMED SIDDIQUE, Dr.R.NANMULLAI, Dr.V.J.VIKRAM, Dr. J.PRAVEEN KUMAR** for their timely help and support.

I express my sincere gratitude to **Prof.Dr.M.K.RAJASEKAR, MS., DLO.,** Ex.Director, Department of ENT, Madras Medical College, Chennai for his valuable contribution.

I am also very grateful to professors, assistant professors and postgraduates of other departments and all the staff members of Madras Medical College & RGGGH who have helped me in the course of my study.

Last but not the least, I thank our patients for willingly submitting themselves for the study.

INDEX

INTRODUCTION

According to the World Health Organization, 63 million people in India have significant hearing impairment. Reports of NSSO survey in the year 2001 suggest that there are 291 persons per one lakh population suffering from severe to profound hearing loss.

With the development of ear microsurgery techniques for Chronic Suppurative Otitis Media (CSOM), the treatment of CSOM has improved from just preventing complications to a focus on the improvement and restoration of hearing. With the ability to reconstruct ossicles, the treatment of CSOM has made great progress over the past decades.

The primary objectives of tympanoplasty are infection control, hearing rehabilitation using ossicular reconstruction and closure of the tympanic membrane using grafting techniques.

Ossiculoplasty may be defined as restoring the hearing mechanism between the tympanic membrane and the oval window by re-establishing a functioning ossicular chain. By doing so, there is a reduction in the air-bone gap postoperatively, thus improving the hearing of the patient.

REVIEW OF LITERATURE

EMBRYOLOGY OF OSSICLES[1]

The First branchial pouch begins to expand to form the Eustachian tube, middle ear and mastoid around the fourth week of gestational life. It is filled with mesenchyme until there is resorption, expansion of the pharyngeal pouches and ossicular development.

The malleus, incus and the suprastructure of stapes develop from the mesoderm of the first and second branchial arch. The foot plate of stapes develops from the otic capsule, a derivative of the neuroectoderm. The first arch derivatives include the head of malleus and body and short process of incus. The second arch derivatives include the caudal structures the manubrium of the malleus, long process of incus and the suprastructure of the stapes. Development begins around the fifth week of intrauterine life. The incudostapedial joint develops during the seventh week. The mucosal lining is derived from the endoderm of the middle ear cleft after resorption of the supporting mesenchymal tissue, freeing the ossicular chain.

As mentioned above, the stapes has two developmental origins. The second arch cartilage gives rise to the suprastructure and tympanic part of the foot plate. The vestibular portion of the foot plate and the annular ligament are derived from otic capsule.

Ossicular abnormalities are often encountered. They may be near normal development to ossicular fusion or may be a rudimentary monoblock ossicular mass. If an atretic plate is present malleus is always fused to it.

Congenital Ossicular abnormalities[5] include:

1) Absent manubrium of malleus

2) Shortening of long process of incus

3) Failure of incus to connect with stapes

4) Fusion of incudostapedial joint

5) Incudomalleolar fixation

6) Stapedial foot plate fixation

ANATOMY OF MIDDLE EAR AND OSSICLES

The middle ear cleft consists of

1) Eustachian tube,

2) Tympanic cleft and

3) Mastoid air cell system.

Tympanic cavity is an irregular air filled space within the temporal bone and it contains auditory ossicles and their attached muscles. It is made up of 6 sides.

1) Lateral wall,

2) Anterior wall,

3) Roof,

4) Medial wall,

5) Posterior wall and

6) Floor.

Tympanic membrane forms the lateral wall of tympanic cavity. Pars flaccida is the portion of the tympanic membrane which lies above the anterior and posterior malleal folds.

There are 2 openings present in the bony tympanic cavity.

They are,

1) Iter chordae posterior through which chorda tympani nerve enters into the tympanic cavity

2) Iter chordae anterior through which chorda tympani nerve leaves the tympanic cavity.

TYMPANIC MEMBRANE

The tympanic membrane is a thin nearly oval disc. The longest diameter is posterosuperior to anteroinferior of about 9- 10mm and perpendicular to this, the shortest diameter is of about 8- 9mm. In the adult, it is angulated approximately 140 degree with respect to the superior wall of the external auditory canal. The malleal prominence, a projection formed by the lateral process of the malleus is located at the superior end of the manubrium of the malleus. The circumference of the tympanic membrane forms a thick cartilaginous ring, the tympanic annulus, which occupies the tympanic sulcus (only pars tensa has tympanic annulus).

- Tympanic membrane has 3 layers.
- Outer epidermis,
- Middle fibrous and

- Inner mucous layer.

- Otoscopic view of the tympanic membrane

OUTER EPIDERMIS

The outer epidermis has no nerve endings and no melanin.

Epidermis is divided into 4 layers (from outwards to inwards).

- ***Stratum corneum:*** 1-6 layers of cells with intercellular desmosomes (organelle is absent).

- ***Stratum granulosum:*** consists of 3 layers of smooth borders with intercellular bridges which is called desmosome, and keratatohyaline and lamellar granules with absent organelles.

- ***Stratum spinosum:*** 2-3 layers of cells, desmosomes and organelles present.

❖ ***Stratum basale:*** 1 layer of cells and separated by fibrous middle layer by lamina propria.

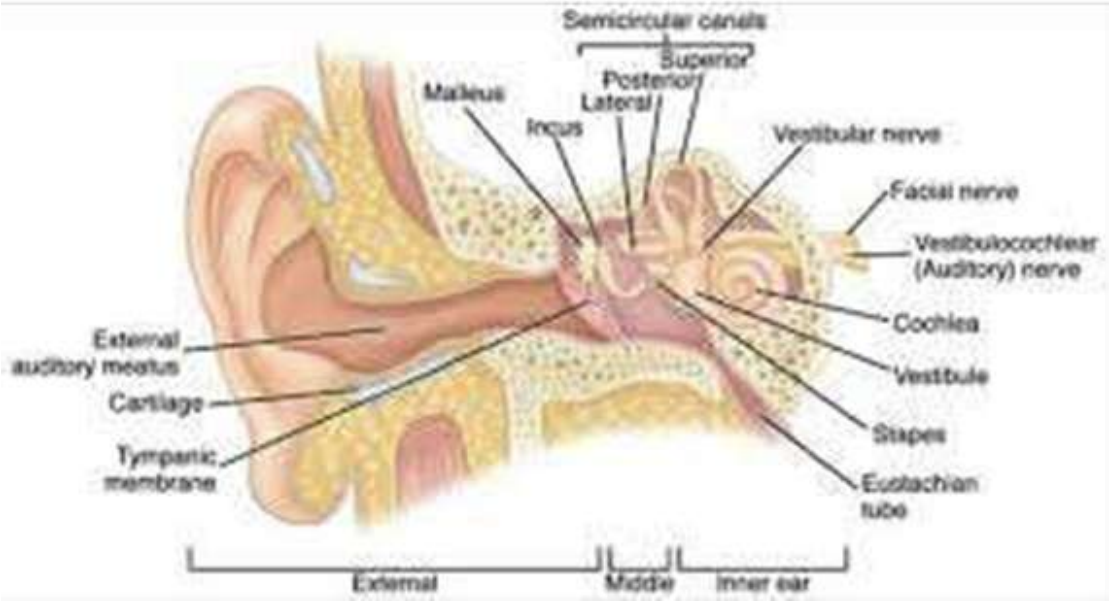

External ear, middle ear and inner ear

MIDDLE FIBROUS LAYER (LAMINA PROPRIA)

Collagen fibrils are scanty in pars flaccida. In pars tensa, the fibres are radially oriented laterally and deeper layers are parabolic, transverse and circular

Deeper layers have nerves and small arteries. In Pars flaccida, fibrous layer is less marked and randomly oriented.

INNER MUCOSAL LAYER

 The medial free surface is lined with columnar epithelium with microvilli with 9+2 arrangement like the rest of the respiratory epithelium. These cilia are patchy in distribution.

BLOOD SUPPLY OF TM:

Deep auricular branches of maxillary artery, anterior tympanic branch of maxillary artery, stylomastoid branches of post auricular artery

Nerve supply of tympanic membrane

Auriculotemporal nerve – a branch of 5th Cranial Nerve, Tympanic branch of 9th Cranial Nerve and Auricular branch of 10th Cranial Nerve.

MEDIAL WALL

The promontory lies in the centre of the medial wall. It is the basal turn of the cochlea. Posterosuperior to the promontory, a kidney shaped opening called fenestra vestibuli (oval window) is connected to the vestibule via scala vestibuli. It is closed by Stapes footplate. It is surrounded by annular ligament. It is 3.25mm long and 1.75mm wide.

Above the oval window is facial nerve and inferiorly is the promontory.

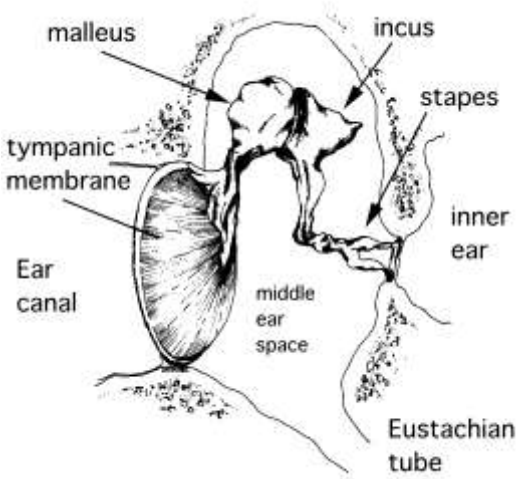

Round window is situated below and behind the oval window which is closed by secondary tympanic membrane. Subiculum separates these two windows. The round window niche is most commonly triangular in shape, with anterior, posterosuperior and posteroinferior walls. The posterosuperior and posteroinferior walls meet posteriorly and lead to the sinus tympani. The sinus tympani lies between the ponticulus, which bridges the gap between the pyramidal eminence and the promontory superiorly, and the subiculum inferiorly.

Secondary tympanic membrane has 3 layers:

- Inner mesothelial layer
- Middle fibrous layer and
- Outer mucosal layer

Only outer mucosal layer has nerves and capillaries. It is about 2.3mm long and 1.87mm wide. The inner layer is nothing but the cell layer

which is continuous with that of the scala tympani. The membrane of the fenestra cochleae forms part of the floor of the scala tympani. The scala tympani terminates medial and behind the round window membrane. The vestibular structure which is closest to the membrane is the ampulla of the posterior semicircular canal and the singular nerve which is parallel and 1mm beyond the posterior part of medial surface of membrane, which is the singular nerve's surgical landmark. The facial nerve canal lies above the oval window and the promontory in an anterior to posterior way. The lateral surface of the canal is smooth(deficient occasionally) and has a processus cochleariformis in the front of the lateral surface of the facial canal. The processus cochleariformis is a spoon shaped hook like projecting bone where the tendon of tensor tympani muscle gets attached and takes a 90 degree turn laterally to get attached to the malleus neck. Posterior to the oval window, the facial nerve takes an inferior turn to the posterior wall of tympanic cavity.

POSTERIOR WALL

It is narrow inferiorly than superiorly. Above there is an opening and it is called aditus which opens into the mastoid antrum. Fossa incudis is situated just below the aditus. The fossa incudis contains a ligament which connects the short process of the incus with it. Pyramid is a prominent bony projection which is related to the fossa incudis inferiorly and chorda tympani nerve laterally. Between the pyramid and

the tympanic annulus is the facial recess. Stapedius muscle is contained within the pyramid.

We can reach the middle ear without disturbing the tympanic membrane via the gap between the chorda tympani nerve and the facial nerve.

ANTERIOR WALL

The lower part is related to a thin bone of the carotid canal. This is pierced by upper and lower caroticotympanic nerves with the sympathetic nerve to the tympanic plexus.

The upper part has 2 parallel tunnels. The upper tunnel contains tensor tympani muscle. The lower tunnel leads into bony part of the Eustachian tube.

ROOF

The roof is formed by the tegmen tympani and comprises partly by the squamous bone and the petrous bone.

FLOOR

It is covered by a thin piece of bone separating the jugular bulb. Occasionally, the bony floor is dehiscent. An opening is present between the junction of the floor and the medial wall through which the glossopharyngeal nerve gives a tympanic branch.

Contents of middle ear

- Nerve: chorda tympani,

- muscles: tensor tympani and stapedius muscle,
- bones: malleus, incus and stapes,
- Tympanic plexus of nerves and
- Ear ossicles.

Malleus: The most lateral of the ossicles is the malleus. It consists of an head, neck , anterior process, lateral process and the handle. It is attached to the walls by the anterior malleal ligament to the petrotympanic fissure. On its thinner medial aspect, the chorda tympani nerve runs anteriorly to enter the Glasserian fissure. The malleus lateral process has a cartilaginous cap which gets adhered to the pars tensa of the tympanic membrane. The lower end of the handle of the malleus is firmly attached to the tympanic membrane as the pars propria splits to envelop it to form the umbo. The malleus, one joint, the tendon of tensor tympani and the tympanic membrane has five ligaments Three of them are

The anterior suspensory ligament,

The lateral suspensory ligament and

The superior suspensory ligament, which connects the space between the tegmen tympani and the head of the malleus.

Incus: The incus is the biggest of the ear ossicles which has a body, a long process, a short process and a lenticular process. The body of the incus lies in the epitympanum along with the malleus head. The short process of the incus projects behind to occupy the fossa incudis. The long process reaches inferiorly paralleling the manubrium to end in the lenticular process. The convex surface of this process joins with the concave surface of the head of the stapes. The long process of the incus is highly susceptible to osteitic resorption caused by chronic otitis media.

Stapes: The stapes is the smallest of the ear ossicles. It has a head, a footplate and two crura, anterior and posterior. There is an irregular area near the superior aspect of the posterior crus to which is attached the stapedius tendon. The footplate in association with the annular ligament seals the oval window. The head joins with the incus lenticular process.

STAPEDIUS

It originates from the pyramid and inserts into the neck of stapes . It is supplied by the Facial nerve.

TENSOR TYMPANI

It originates from the bony part of the Eustachian tube. It enters a spoon shaped processus cochleariformis and takes a 90 degree turn laterally and inserts onto the manubrium of the malleus. It is innervated

by the Trigeminal nerve. The chorda tympani nerve enters posteriorly and travels along the tympanic membrane. It is present medial to the handle of malleus. It exits through the iter chordae anticus and then enters the Glasserian fissure.

TYMPANIC PLEXUS

Arrangement is by the Jacobson's nerve which is a branch of glossopharyngeal nerve. It is also supplied by the caroticotympanic nerve, arising from the sympathetic plexus. It provides divisions of nerves to the mucosa that lines the tympanic cavity, lesser superficial petrosal nerve, auditory tube, mastoid antrum and air cells.

BLOOD SUPPLY OF MIDDLE EAR CAVITY

Tympanic membrane, ossicles, part of the tympanic cavity are supplied by the Anterior tympanic division- a branch of maxillary artery

The mastoid air cells are supplied by Stylomastoid artery (Mastoid branch)

The roof of the epitympanum is supplied by Petrosal division of middle meningeal artery

The tensor tympani muscle is supplied by Superior tympanic division of the middle meningeal artery

The mesotympanum is supplied by the inferior tympanic division of ascending pharyngeal artery

The mesotympanum and the hypotympanum are supplied by branches from the artery of pterygoid canal

The mesotympanum and the hypotympanum are supplied by tympanic branches of the internal carotid artery.

MECHANISM OF HEARING IN HUMAN BEINGS[3,4,5,6]

The sound waves travel from external environment to the ear through this pathway:

Pinna –to External canal – to Tympanic membrane – to Ossicles – to Oval window into Cochlea and then to Auditory nerve.

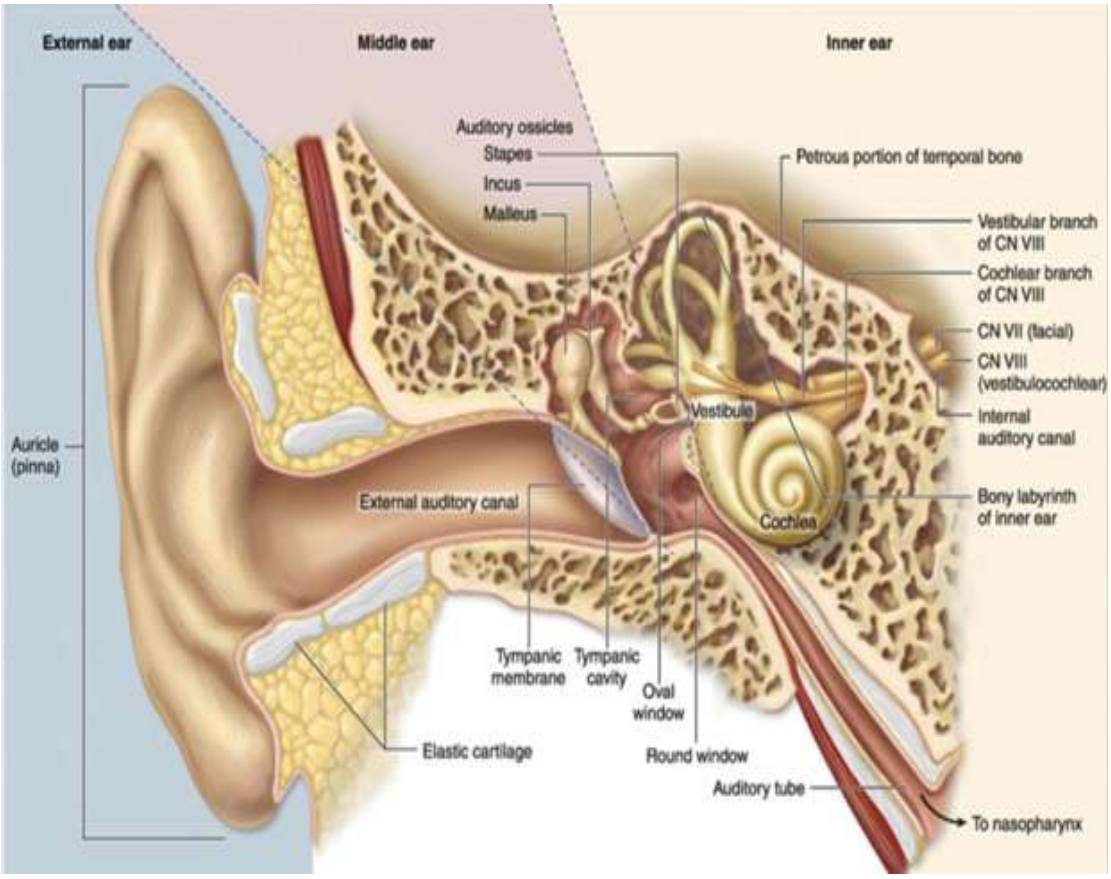

The Pinna protects the entrance to the ear canal. It job is to locate sounds, especially those at higher frequencies

External auditory meatus is the pathway for the auditory signal. It protects the inner ear from the direct impact of sound. It also acts as a tube resonator and favors the transmission of high- frequency sounds (2000-4000 Hz) .

The Tympanic membrane is deflected by air pressure variations. These are transmitted to the auditory ossicles and are converted to mechanical movements.

The Auditory ossicles include the Malleus, incus, stapes. These pick up the mechanical movement of the eardrum and then convey them to the inner ear through the oval window. Air pressure variation is then transformed into equivalent mechanical movements. The contraction between incus and stapes reduce the amplitude of sound and protect the inner ear.

The Oval window acts as an interface between the middle and inner ear. It transmits mechanical movement into the cochlea.

The Eustachian tube equalizes air pressure differences between the outer environment and the middle ear.

Any pathology affecting structures from pinna to the oval window cause conductive hearing loss.

Any pathology affecting the pathway from cochlea to auditory cortex will cause Sensorineural deafness.

The sound pathway from the cochlea has the following path.

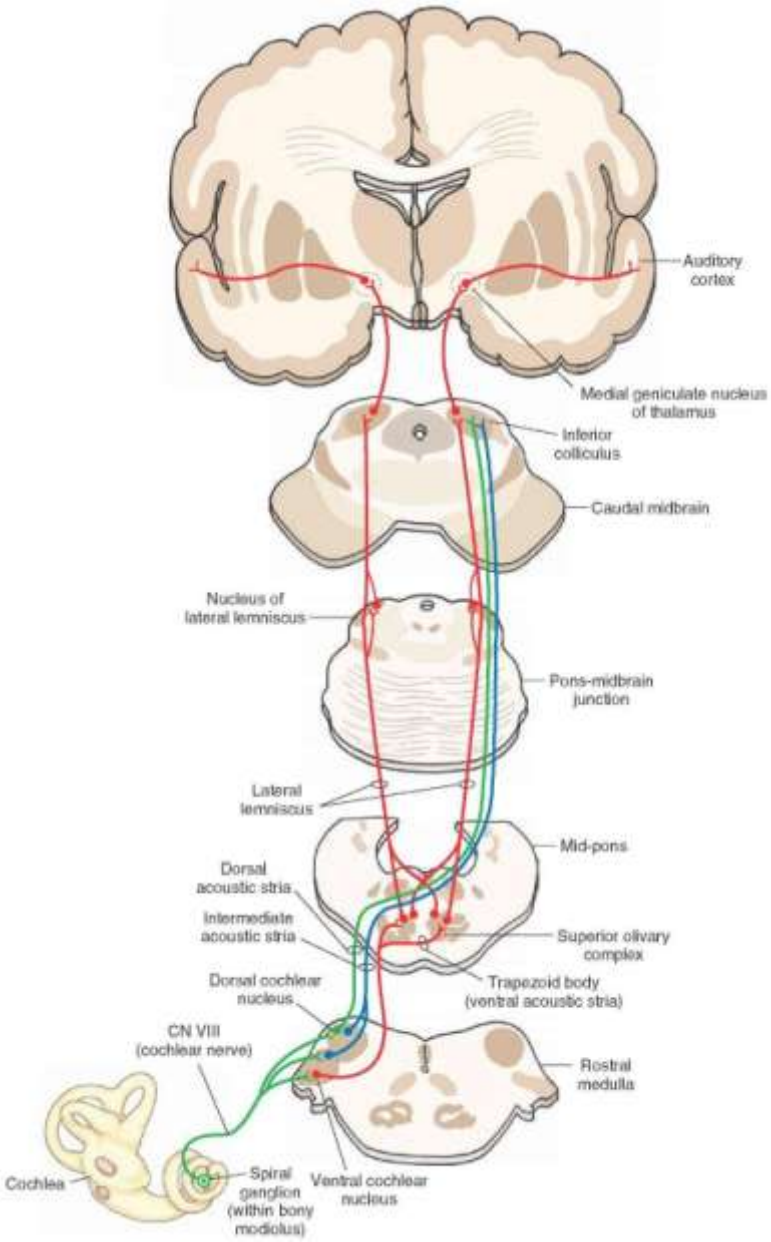

ESSENTIAL OF MIDDLE EAR OSSICLES FOR HEARING

The impedance sound energy is transformed in the external auditory canal with the help of the tympanic membrane and ossicles to a high impedance of the perilymph inside the oval window.

The sound transmitting mechanism of middle ear can be classified into three systems.

1) Catenary lever – by tympanic membrane

2) Ossicular lever – by auditory ossicles

3) Hydraulic lever – CATENARY LEVER This occurs by the difference between tympanic membrane and the foot plate of stapes

The tympanic membrane is attached to the annulus in a rigid manner. This causes increase in energy at the handle of Malleus. This occurs due to lack of the middle fibrous layer of

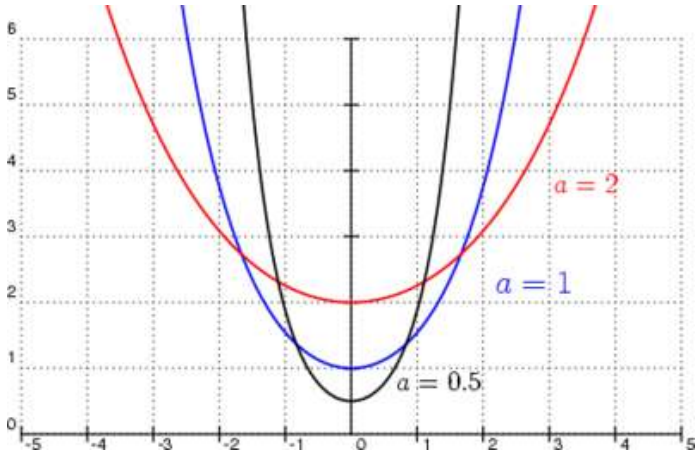

The tympanic membrane. As the annulus is fixed, the sound energy runs from the periphery to the centre. The handle of Malleus, thus, perceives the sound.

OSSICULAR LEVER

The Malleus and incus assembly moves together. This causes a gain of 1.3:1 due to the difference in length of the manubrium of Malleus and long process of incus. Both levers, Ossicular and catenary, give a ratio of 1:2.3

HYDRAULIC LEVER

There is an increase in force at the foot pate as the sound is conducted from a large tympanic membrane to a small foot plate. The entire ratio is 20.8:1.

Ossicular, catenary and hydraulic levers all put together give a sound gain of 34 decibels.

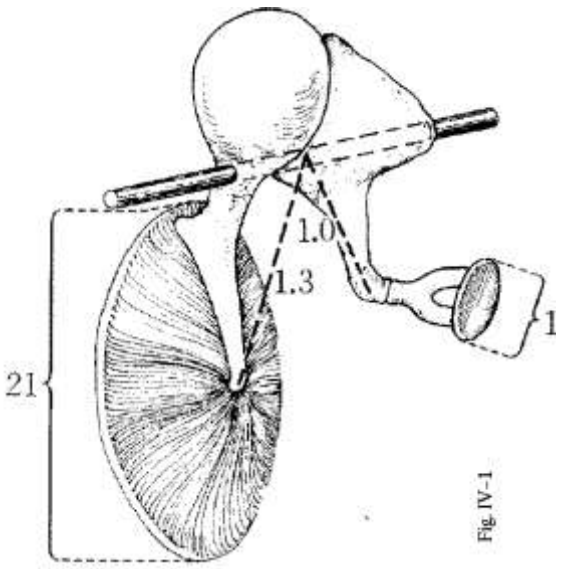

Fig. IV-1

OSSICULAR COUPLING

This is the real gain in pressure of sound as sound travels from the tympanic membrane through the ossicles. It depends on frequency and not the decibels always. It is 20 decibels in 250 to 500hz and 25 decibels in 1000hz and then decreases to 6decibels for every octave after that. This is because in higher frequencies the tympanic membrane vibrates at various portions.

This is also attributed to the Ossicular chain sloping at higher frequencies.

Acoustic coupling

The sound conducted hits the oval and round window and usually there is not much that is appreciated. In operated ears, the difference may be significant enough to cause deafness.

Stapes cochlear input impedance

The factors causing impairment of movement of the foot plate of stapes into oval window cause an increase in the impedance and hearing loss.

Middle Ear Aeration

The middle ear should normally contain air. If there is inadequate air or if the air is replaced by soft tissue or liquid, then there is impairment of conduction of sound.

OSSICULAR PATHOLOGY AND RECONSTRUCTION

CAUSES FOR OSSICULAR PATHOLOGY

Ossicles may be either discontinuous or fixed.

The causes of Ossicular fixation include

Ossicular tympanosclerosis secondary to healing after perforations

Idiopathic Ankylosis of the Malleus head

Scar bands after a chronic otitis media.

The causes for Ossicular discontinuity are

Erosion due to chronic otitis media and cholesteatoma and trauma

The most common ossicles eroded in order of frequency are

incudostapedial joint (Lenticular process of incus), absent incus, and stapes suprastructure, erosion of head of Malleus, handle of Malleus

MECHANISM OF OSSICULAR EROSION

The mechanism for erosion is usually chronic middle ear inflammation. This occurs with an increased production of cytokines—TNF alpha, interleukin-2, fibroblast growth factor, and platelet derived growth factor. These produce hypervascularisation, and bone resorption,

leading to ossicular damage. TNF-alpha also induces the production of granulation tissue.

METHODS FOR ASSESSING OSSICULAR PATHOLOGY

Clinical examination including otoscopic examination is important to look for congenital abnormality. Examination of the external auditory canal, looking at the status of the tympanic membrane and middle ear also play an important role in assessment. CT scan of the temporal bone will provide information of the extent of middle ear pathology (cholesteatoma), Ossicular chain status, fixity of the Malleus and the presence of Otosclerosis. Ossicular discontinuity should be suspected when the patient has conductive hearing loss of more than 50dB in Pure Tone Audiogram .

Ugo Fisch classification of Ossicular defects with hearing outcomes.

ABG	Pre op status of ossicles and mastoid
<10db	Malleus: Handle intact Incus: Absent Stapes: Intact
<20dB	Malleus: Handle intact Incus: Absent Stapes: Fixed /no suprastructure
<30dB	Open/closed cavity mastoidectomy Malleus: Absent Incus: Absent Stapes: Mobile/fixed/mobile footplate

Austin classification of types of condition regarding Ossicular status.

1) Perforation of tympanic membrane with intact ossicles

2) Perforation of tympanic membrane with Ossicular discontinuity

3) Complete erosion of the tympanic membrane and ossicles

4) Normal tympanic membrane with Ossicular discontinuity

5) Congenital Ossicular defects

MATERIALS USED FOR OSSICULOPLASTY

In 1901, the idea of connecting tympanic membrane with oval window by reconstruction began. The materials first used for ossiculoplasty were either biological or alloplastic in nature.

BIOLOGICAL MATERIALS

The biological materials used in reconstruction of ossicles include autograft or homograft. The first used material was Autologous cartilage and was used for Ossiculoplasty. However, it was found that cartilage shows erosion after three years. Another complication was Chondromalacia that may be seen in cartilage reconstructed ears because of the ingrowth of blood vessels with subsequent chondritis. It was thus concluded that cartilage was the best option for long term use. Autologous Ossicular graft is now the gold standard of ossicular reconstruction and proves to be an ideal material. The availability

depends on the presence or absence of ossicular remnants. Irradiated homograft ossicles were introduced in 1960 and are not used due to risk of transmission of AIDS and Cruetzfeldt-Jacob disease.

ALLOPLASTIC MATERIALS

Alloplastic materials are also commonly used now-a-days. They are classified as

Biocompatible

Bio inert

Bioactive

Biocompatible Materials

Polyethylene tubing, Teflon, and protoplast are bio compatible materials used in the 1950s . The side effects included movement into the inner ear, Migration, Extrusion, and reactivity to the material. Other biocompatible materials including silastic, stainless steel, titanium and gold have also been tried.

BIOINERT MATERIALS

These are derivatives of aluminium oxide and don't produce any by products. An advantage is that these Bio inert implants can be placed directly into the tympanic membrane without cartilage.

BIOACTIVE MATERIALS

These materials react with body tissue to produce soft tissue attachments. They produce a chemical bond that acts as a surface of the material. The first of bioactive materials were Bioglass and Ceravita that were introduced in 1970. Bioglasses because inactive when infection sets in.

PROGNOSTIC FACTORS IN OSSICULOPLASTY

Four groups of Ossicular status was described by Austin

A. malleus handle present, stapes suprastructure present (60%) M+ S+

B. malleus handle present, stapes suprastructure absent (23%) M+ S-

C. malleus handle absent, stapes suprastructure present (8%) M- S+

D. malleus handle absent, stapes suprastructure absent (8%) M- S-

Kartush in 1994 described a scoring system to find the success probability

Table I. Middle ear risk index (MERI) scores [10].

Risk factor	Risk value
Otorrhoea	
I: Dry	0
II: Occasionally wet	1
III: Persistently wet	2
IV: Wet, cleft palate	3
Perforation	
Absent	0
Present	1
Cholesteatoma	
O: M+I+S+	0
A: M+S+	1
B: M+S−	2
C: M−S+	3
D: M−S−	4
E: Ossicle head fixation	2
F: Stapes fixation	3
Middle ear: granulations or effusion	
No	0
Yes	1
Previous surgery	
None	0
Staged	1
Revision	2

Dornhoffer designed the Ossicular Outcomes Parameters Staging (OOPS)

To summarise the principal determinants[5] of the method of reconstruction and the expected hearing results are 1. Mobility of the stapes footplate 2. Integrity of the stapes supra structure 3. Presence/absence of a malleus handle

TABLE 2. *Ossiculoplasty outcome parameter staging index*

Risk factor	Risk value
Middle ear factors	
Drainage	
None	0
Present >50% of time	1
Mucosa	
Normal	0
Fibrotic	2
Ossicles	
Normal	0
Malleus +	1
Malleus –	2
Surgical factors	
Type of surgery	
No mastoidectomy	0
Canal-wall-up mastoidectomy	1
Canal-wall-down mastoidectomy	2
Revision surgery	
No	0
Yes	2

METHODS FOR OSSICULAR RECONSTRUCTION[7]

In 1956, Zoellner and Horst Ludwig Wullstein, in the publication of Theory and practice of tympanoplasty (The Laryngoscope, 66: 1076–1093) mentioned five types of tympanoplasty depending upon the ossicular status.

Type I: Tympanoplasty (or myringoplasty) when all three ossicles are normal, and should result in normal hearing.

Type II: graft (or tympanic membrane) is in contact with the incus and the stapes is present, both of which are connected and mobile, which produces a minimal hearing loss only.

Type III: graft (or tympanic membrane) is in direct contact with the suprastructure of the stapes (columella effect), causing mild hearing loss. It is also known as myringostapediopexy.

Type IV: Ossicular chain is absent and the tympanic membrane is in contact with a mobile stapes footplate (Cavum minor) causing moderate hearing loss..

Type V: A window is surgically made in the horizontal semicircular canal

Type IV. It also known as a fenestration.

DEFINITION

Ossiculoplasty is defined as the reconstruction of Ossicular chain to surgically optimize the ear transfer mechanism so that sound is transmitted from the environment to the inner ear with as minimal a loss as possible. Tympanoplasty usually preserves the hearing which is left over by the disease process. Ossiculoplasty aims to enhance hearing by a reconstruction of the middle ear. Ossiculoplasty using a PORP (Partial Ossicular Reconstruction Prosthesis) is done when the stapes is intact.

Ossiculoplasty with TORP (Total Ossicular Reconstruction Prosthesis) is required when the stapes s is absent and there is a mobile footplate.

OPERATIVE STEPS OF OSSICULOPLASTY

OSSICULOPLASTY FOR PARTIAL OR COMPLETE ABSENCE OF INCUS

When the incus is eroded, continuity of the ossicular chain may be re-established by using an autologous incus, cortical bone chip, head of malleus, or a PORP between the head of stapes and handle of malleus.

Autologous incus interposition

Autologous incus is used whenever possible as is situated in the surgical field, has a low cost and has a low extrusion rate.

However, it sometimes is absent, eroded, or covered by cholesteatoma.

Other methods of reconstructions when the incus does not fit well include when the stapes suprastructure and/or the malleus handle are absent. Incus interposition is performed during the primary surgery. The techniques are similar for open and closed cavities. The incus is removed, then rotated laterally with a 45° hook. The long process of incus is drilled with a diamond drill. A notch is then drilled in the body of the incus in order to accommodate the stapes head. This is done using

0.6mm and 0.8mm diamond burrs. The prosthesis is then placed in the middle ear, lateral to the chorda tympani. The incus is kept in position using the 1.5mm 45° hook. The notch is drilled into the body of incus over the head of stapes. PORP interposition is done using a Teflon Prosthesis. The PORP is placed on the stapes head. A piece of cartilage is interposed between the prosthesis and tympanic membrane to prevent extrusion.

OSSICULOPLASTY FOR AN INTACT STAPES

1. When the Stapes supra structure is intact and mobile, a PORP may be placed over the mobile stapes. A TORP can usually be placed between the crura of the intact stapes. This helps in a stable reconstruction.

2. When the Stapes suprastructure is eroded and there is a mobile footplate, a TORP may be placed onto the stapes footplate. Techniques include: Gelfoam can be placed at the footplate around the prosthesis. Small wedges of cartilage can be cut and placed on the footplate on either side of the prosthesis.This is done to stabilise the prosthesis on the footplate. A disc is cut around the perforation of the cartilage. The final sizing is done using a microscope to fit the oval window niche. The prosthesis shaft is then placed through the central perforation before placing it in the oval window niche.

Contraindications for ossiculoplasty include acute infection or Persistent disease. These lead to poor healing and extrusion of Prosthesis. The outcome is determined by the condition of middle ear at the time of ossiculoplasty. Eustachian tube function also plays an important role.

STAGING OF OSSICULOPLASTY

In some cases ossiculoplasty can be done as staged procedure, at a different date than the tympanoplasty or mastoidectomy. Staging improves the outcomes of Ossicular reconstruction as there is better assessment of the position of the tympanic membrane and eustachian tube

A staged procedure is also useful when the mucosa around the oval window have been traumatised, as there is a risk of scarring of the oval window. If ossiculoplasty is performed as a single stage in this situation healing becomes difficult.

The 2nd stage (ossiculoplasty) surgery is delayed for a year in situations like cholesteatoma surgery to make sure that there is no residue

If only the stapes is present, a late second stage surgery is useful.

If ossiculoplasty is staged and there is trauma to the the middle ear mucosa then a thin silastic sheeting is placed in the protympanum of

the middle ear to allow healing of the the middle ear mucosa. Patients are advised to avoid increasing pressure in middle ear as a post operative precaution for first two weeks after surgery. They are also advised to avoid water entering till the external auditory canal and tympanic membrane heals.

Complications include extrusion (common in 1-3 years after surgery). Literature shows an extrusion rate of 5-39% in literature. Other complications include infection, tinnitus, injury to semicircular canal, persistent or new perforation.

No hearing improvement after surgery is a functional complication. Revision ossiculoplasty is then usually considered after 1 year when there is no improvement.

PATHOLOGY OF CHRONIC SUPPURATIVE OTITIS MEDIA

Cholesteatoma is a cystic bag like structure lined by keratinizing stratified squamous epithelium, containing desquamated debris that rests on a fibrous stroma of varying thickness, the perimatrix. This results in hyperkeratosis and shedding of keratin debris which results in a cystic mass surrounded by an inflammatory reaction. It may be present extradurally or intradurally.

The first description of something corresponding to cholesteatoma was published in 1683 by Duverney. The term cholesteatoma was coined

by Muller in 1829, as he became aware of a tumor containing cholesterin and fat. Virchow first classified cholesteatoma among atheromas and squamous cell carcinomas. Von Troeltsch was among the first to consider an epidermal origin of cholesteatoma. Gruber and Wendt and Rokitansky considered that it was the middle ear mucosa and not bone that underwent malphigian metaplasia which was in response to chronic inflammation. Bezold and Habermann were the first to prove that cholesteatoma could also originate from the skin of external auditory canal.

The precise pathogenesis of cholesteatoma has been under debate for more than two centuries precisely. The four predominant theories that have been debated are 1) Invagination theory, 2) Theory of basal cell hyperplasia, 3) metaplasia theory 4) Theory of epithelial invasion. The primary theory for primary acquired cholesteatoma is the invagination theory. Anatomic or pathologic conditions that predispose to Eustachian tube dysfunction results in barometric perturbation of the middle ear space. Impaired ventilation secondary to a dysfunctional Eustachian tube leads to negative middle ear pressure. The negative pressure is the culprit for structural weakening of the tympanic membrane and development of the retraction pockets. The experimental model illustrating the implication of eustachian tube dysfunction in the formation of the retraction pockets and later cholesteatoma was described by Kim and Chole. The geometrical changes attributed to

progressive retraction lead to narrowing of the anatomic passages and impairment of the epithelial migration and cleaning of the debris. As the pocket deepens and insinuates between mucosal folds and crevices, it becomes nonself cleaning and leads to accumulation of keratin debris. Bacterial proliferation and super infection of the accumulated debris form a biofilm that leads to chronic infection and epithelial proliferation. Bacterial biofilms are anatomically defined as communities of bacteria enclosed in a self-produced glycocalyx matrix. They are structured by adhesion of plank-tonic or free-living bacteria to a surface, then proliferate in bacterial

microcolonies along with the production of the glycocalyx matrix. This active progression of biofilm formation results in a mature biofilm that persists on surfaces. Physiologically, bacterial biofilms are markedly resistant to host defense mechanisms and antibiotics; they can be up to a thousand times more resistant to antimicrobial treatments than planktonic bacteria of the same species The most common bacterial isolate of chronic otitis media is *P. aeruginosa*.12,16 Other isolates include aerobic organisms, such as enteric gram-negative bacilli, *S. aureus, streptococci, K. pneumoniae*, and *H. influenzae*. Anaerobic isolates, associated with a malodorous otorrhea, include Peptostreptococcus and Bacteroides species.

The exact mechanism and triggers that lead to development of an active cholesteatoma in some patients with and attic retraction pocket while others continue to have a quiescent and self-cleaning pocket remain unclear. It has been shown recently that the combination of tympanic membrane retraction and basal cell proliferation is the hallmark for cholesteatoma formation and development.

Sudhoff and Tos performed immunohistochemical analysis of surgical specimens obtained from 14 patients with middle ear cholesteatoma. In their clinical study, they compared the expression of MIB-1, a marker of cellular proliferation, between the cholestatoma content and the normal external auditory canal skin. In addition, the investigators analysed the integrity of the basement membrane by using avidin biotin complex peroxidase to stain collagen type IV. At the level of the basement membrane,

interruption in the continuity was seen at the cholesteatoma – lamina propria interface, whereas the integrity was preserved in the adjacent normal auditory canal skin. They also showed an increased expression of MIB-1 in the keratinocytic population of the basal cell layer. This increased expressivity was consistent with proliferating keratinocytes localized primarily in small epithelial cones or pseudopods growing into the subepithelial stroma through interruptions of the basement membrane. In the initial retraction pocket stage, the

epithelial migratory pattern is maintained until the pockets deepen and the drainage pathways become small leading to keratin debris accumulation. As the debris becomes infected, the bacterial proliferation and resultant inflammation leads to an influx of inflammatory cells and production of cytokines. This progression along with local release of collagenases created breaks in the basement membrane allowing the formation of epithelial cones that grow toward the stroma. The combination of subepithelial invasion and keratinocytic proliferation in the form of microcholesteatoma is the hallmark of the precholesteatomatous stage of cholesteatoma.

As the microcones expand and fuse together, an attic cholesteatoma is formed.

Using immunohistochemistry, Kim and Coworkers, analyzed the pattern of cellular proliferation and epithelial migration in the Mongolian gerbil animal model. They showed an increase in the expression of cytokeratin (CK0 13/16, markers of epidermal cell proliferation, in the expanding part of the cholesteatoma and to a lesser degree an increase in the expression of CK 5/6 and CK 1/10, markers of epithelial migration. They concluded that cellular migration (or invasion) and proliferation play a role in the expansion of cholesteatoma. Secondary acquired cholesteatoma has been described to occur as the result of the migration of tympanic membrane epidermis

into the middle ear at the site of a marginal perforation or as the result of the implantation of viable keratinocytes into the middle ear cleft. The implantation occurs during a blast injury to the tympanic membrane leaving keratinocytes behind a healed perforation, at the site of a temporal bone fracture, or as the result of an iatrogenic introduction of these cells. The latter have been described to occur in various otologic surgeries such as stapedectomy, tympanoplasty, pressure equalization tube placement, and middle ear exploration.

Incidence of 1.1% of middle ear cholesteatoma attributed to the insertion of the pressure equalization tube. The presence of cholesteatoma around the tube site was a prerequisite to incriminate the procedure as a cause of cholesteatoma.

Production of new keratin was observed up to 9 months post implantation. Various histopathologic changes ranging from granulation tissue to cholesteatoma formation were described. Neonatal aspiration of viable keratinocytes may not fully account for the development of congenital cholesteatoma, it provides a valuable experimental platform that the implantation of viable keratinocytes can lead to formation of middle ear or mastoid cholesteatoma. This is observed frequently in revision middle ear surgery and described as “Cholesteatomatous pearl” formation that is the result of a trapped viable keratinocytic formation that leads to a small localized cholesteaoma.

Pathogenesis of cholesteatoma is paralleled by the ongoing research to help elucidate the mechanism of expansion, bone destruction and invasion seen in middle ear cholesteatoma. Two predominant mechanisms are believed to account for the osteolysis seen in middle ear cholesteatoma: pressure-induced bone resorption and enzymatic dissolution of bone by cytokine-mediated inflammation. Pressure necrosis initially described by Steinbrugge in 1879 and Walsh in 1951, and direct bone resorption as described by Chole and coworkers in 1985 have been proposed as possible mechanisms of bone destruction. Chole and colleagues implanted silicone sheets in the middle ear of gerbils without cholesteatoma and noted bone resorption at the pressure site. They estimated that pressures of 50 to 120 mm Hg resulted in osteoclastic-induced bone resorption. The interaction of osteoclasts and osteo blasts to extrinsic biomechanical factors is a well-documented biological response.

PATHOLOGY OF OSSICULAR EROSION

Two predominant mechanisms are believed to account for the osteolysis seen in middle ear cholesteatoma: pressure-induced bone resorption and enzymatic dissolution of bone by cytokine-mediated inflammation. Pressure necrosis initially described by Steinbru¨gge in 1879 and Walsh in 1951, and direct bone resorption as described by Chole and coworkers in 1985 have been proposed as possible mechanisms of bone destruction. It is uncertain to what degree the

pressure-induced activation of osteoclasts play a role in the osteolysis seen in cholesteatoma. Enzymatic-induced and cytokine- induced bone destruction has been studied in the last two decades.

Matrix metalloproteinases (MMP), a family of zinc metalloenzymes that degrades unmineralized extracellular matrix, have been shown to be present in the cholesteatoma. MMP-2 (72 kD collagenase) and MMP-9 (92 kD collagenase) were expressed in suprabasal epithelial layers of Cholesteatoma. Other investigators found the increased expression of MMP-9 but not MMP-2 in cholesteatoma cells. Schmidt and coworkers analyzed the in vivo significance of MMP-9 activity in relation to the production of cytokines interleukin (IL)-1a, IL-1b, TNF-a, transforming growth factor (TGF)-b, and epidermal growth factor (EGF) in tissue homogenates of cholesteatoma and nine external ear skin specimens. IL-1a production was found to be significantly elevated; however, no correlation was found between MMP-9 activity and cytokine production.

IL-1 and IL-8, important intercellular mediators of osteoclastic activities have been shown to increase in cultured cholesteatoma cells compared with normal external auditory canal skin.

The role of another important cytokine, TNF-a, has also been found. Yan and coauthors found that by in vitro stimulating monocytes, they were able to produce multinucleated cells with osteoclast like

activity that produced acid phosphatase-induced bone demineralization. The amount of osteolysis was increased by adding osteoblasts to the TNF-a– treated osteoclasts containing medium, suggesting a cell to cell interaction mediated by TNF-a. In addition, the latter enhanced the production of collagenases by macrophages and osteoblasts. However, by performing enzyme- linked immunosorbent assay on tissue samples from 23 patients with cholesteatoma and 16 patients with chronic otitis without cholesteatoma, the detection of IL-1a, TNF-a, and EGF was significantly higher in the cholesteatoma samples. Histopathologic evidence was obtained from the temporal bone of two patients with ruptured cholesteatoma sac resulting in local inflammation and osteolysis . These changes were associated with a small abscess formation at the site of the rupture. They noted a marked inflammatory cellular infiltrate surrounding the rupture site with evidence of epithelial proliferation at the lining of the perforation site.

Histopathologic evidence was obtained from the temporal bone of two patients with ruptured cholesteatoma sac resulting in local inflammation and osteolysis. These changes were associated with a small abscess formation at the site of the rupture. They noted a marked inflammatory cellular infiltrate surrounding the rupture site with evidence of epithelial proliferation at the lining of the perforation site.

Jung and coworkers showed the possible role of nitric oxide as an important mediator of osteoclast function. Using in vivo analysis of a murine model of cholesteatoma-induced bone resorption and in vitro analysis of osteoclast culture, the investigators studied the gene expression of nitric oxide synthase (NOS) and the effect of aminoguanidine (an inhibitor of cytokine mediated nitrite production). They showed a selective upregulation of the inducible NOS or NOS II compared with NOS I and III and a dose-dependent stimulation of osteoclastic activity (not proliferation) using low concentration of nitric oxide donors (sodium nitroprusside and S-nitro-N-acetyl-D, L-penicillamine). In vitro, only interferon (IFN)-g (not IL-1b or TNF-a) was able to generate nitrite. This nitrite production was blocked in vitro by the addition of aminoguanidine (but not in vivo) and was synergistically enhanced in the presence of IFN-g, IL-1b, and TNF-a.

These findings indicate a role for nitric oxide in the osteoclastic-mediated bone resorption in cholesteatoma and suggest the implication of additional cytokines in the in vivo osteoclastogenesis and bone resorption. In contrast to the increased osteoclastic activity without increase in the number of osteoclasts seen by Jung and colleagues, in a separate study, Hamzei and coauthors found an increase in the number of the osteoclast precursor cells in the perimatrix of 21 cholesteatoma surgically obtained. These studies highlight the importance of osteolysis

and its regulatory mechanisms in the bone destruction seen in middle ear cholesteatoma that results in significant morbidity.

Austin's classification of ossicular chain defects

Malleus handle present, stapes suprastructure present.

Malleus handle absent, stapes suprastructure present.

Malleus handle present. Stapes suprastructure absent.

Malleus handle absent, stapes suprastructure absent.

Rare defects

Isolated loss of the malleus handle

Isolated loss of the stapes

Malleus handle present and stapes fixed

Malleus handle absent and stapes fixed Enzymatic-induced and cytokine-induced bone destruction has been studied in the last two decades. Matrix metalloproteinases (MMP), a family of zinc metalloenzymes that degrades unmineralized extracellular matrix, have been shown to be present in the cholsteatoma. MMP-2 (72kD collagenase) and MMP-9 (92kD colalgenase) were expressed in suprabasal epithelial layers of cholesteatoma.

Investigators found the increased expression of MMP-9 but not MMP-2 in cholesteatoma cells. Schmidt and coworkers analyzed the in vivo significance of MMP-9 activity in relation to the production of cytokines interleukin (IL)-1α, IL-1β,

α, transforming growthTNF- β, and epidermal growth factor (EGF) in tissue homogenates of 37factor (TGF)- production wascholesteatoma and nine external ear skin specimens. IL-1 α found to be significantly elevated; however, no correlation was found between MMP-9 activity and cytokine production. IL-1 and IL-8, important intercellular mediators of osteoclastic activities have been shown to increase in cultured cholestatoma cells compared with normal external auditory canal skin.

Yan and coauthors found that by in vitro stimulating monocytes, they were able to produce multinucleated cells with osteoclast like activity that produced acid phosphatase-induced bone demineralization. The amount of osteolysis was increased by adding osteoblasts α - treated osteoclasts containing medium, suggesting a cell toto the TNF- α. In addition, the latter enhanced thecell interaction mediated by TNF- production of collagenases by macrophages and osteoblasts.

Jung and coworkers showed the possible role of nitric oxide as an important mediator of osteoclast function. Using in vivo analysis of a murine model of cholesteatoma-induced bone resorption and in vitro

analysis of osteoclast culture, the investigators studied the gene expression of nitric oxide synthase (NOS) and the effect of aminoguanidine (an inhibitor of cytokine mediated nitrite production). They showed a selective upregulation of the inducible NOS or NOS II compared with NOS I and III and a dose-dependent stimulation of osteoclastic activity (not proliferation) using concentration of nitric oxide donors (sodium nitroprusside and S-nitro-N-acetyl-D, L-penicillamine). In vitro, only interferon was able to generate nitrite. This nitrite production was blocked in vitro by the addition of aminoguanidine (but not in vivo) and was synergistically enhanced in the presence of IFN-α, IL1-β, TNF-α.

REVIEW OF LITERATURE

OSSICULOPLASTY: A PROSPECTIVE STUDY OF 80 CASES

Shrinivas Shripatrao Chavan, Prateek V Jain, Jeevan N Vedi, Dharmendra kumar Rai, and Himayat Kadri 8

A prospective study by chavan et all studies 80 patients who underwent ossiculoplasty in the ear, nose, and throat (ENT) department at a single tertiary health care facility. The results of the study showed that the mean age at which patients were operated on was 34 years and 3 months, with males constituting 52.5% of patients. Decreased hearing was the most common presenting symptom followed by ear discharge. Mean hearing loss was 47.89dB preoperatively. Teflon TORP was used in 29 patients. Teflon PORP was used in 24 patients and refashioned incus was used in 27 patients. The ossicle most commonly eroded was the long process of incus seen in 74 patients, followed by the suprastructure of stapes. The ossicle that was least affected was the malleus seen in 10 patients. Tympanoplasty was done in 41 patients while canal wall down mastoidectomy was done in 34 patients and intact canal wall mastoidectomy was done in 5 patients.

Success was defined based on the air bone gap which was less than 25dB at postoperative day 90. This was achieved in 80% of the cases.

They concluded by saying that TORP fared better when the handle of malleus was found to be eroded and the suprastructure of stapes was

absent whereas PORP fared better when the handle of malleus was intact.

Tragal Cartilage Versus Polytetrafluoroethylene (TEFLON) Partial Ossicular Replacement Prosthesis (PORP): A Comparative Study of Outcomes of Ossiculoplasty F.Pathan, S.Satpathy, S. Bhalekar, K Sudarshan 9

This is a prospective study of 100 patients in whom ossiculoplasty was done. In 50 patients ossiculoplasty was done using tragal cartilage and in 50 patients ossiculoplasty was done using Teflon partial ossicular reconstruction prosthesis (PORP).

Out of the 100 cases, 62 were male and 38 were female. 72 patients presented with a perforated tympanic membrane, 8 with retraction pockets, 17 with limited cholesteatoma and 3 with aural polyp. In 42 cases, Incus alone was eroded.

They concluded that the postoperative hearing improvement was better when cartilage was used for ossiculoplasty when compared with Teflon PORP.

OTHER STUDIES

In the year 2000, Pasha [10] studied 33 cases of ossiculoplasty with Hydroxyl apatite PORP, TORP, or Kartush incus strut. Based on postoperative hearing results, mean ABG were studied. Among these three groups, best results were obtained in the group where incus struts were used. Patients that received incus struts had lower MERI scores.

These patients also had malleus handle present. On analysis of extrusion, 3 PORPs extruded and none of the incus struts or TORPs were extruded. However, in this study, hearing results are not reported as percentage of patients closing ABG to within 20 dB. This conclusion of this study is that the use of the Kartush incus strut is superior when both the handle of the malleus and the stapes suprastructure are preserved.

In a study by House, et al [11] a retrospective study of 1210 consecutive ossicular reconstructions with HydroxylApatite and Plastipore TORPs (n = 560) or PORPs (n = 650) was performed in the year 2001. 63% (68% of PORPs, 58% of TORPs) had a closure of the ABG to within 20 . Hearing results were better for cases who did not have any previous surgeries, in those diagnosed with disorders other than chronic otitis media, when cartilage grafts were used, and when Plasti-Pore was used in comparison to hydroxylapatite. Extrusion rate was 4%, and there was no significant difference between HA and Plastipore. House's study supports the importance of placing a cartilage cap between the prosthesis head and the tympanic membrane. He negates the idea that the stapes is unimportant to hearing results.

A Study by Lurato [12] in the year 2001 reviewed literature that investigated hearing results from ossicular reconstruction in among Austin-Kartush type A patients. With a follow-up of 12 months it was

was shown that there was a success of 84% in the incus interposition groups with a success of 82% for those with an allograft (ceramics or HA) PORP. In his sudy, the success rate of homograft ossiculoplasty was 85% with a 3- year stable hearing period post-operatively. Lurato reported no extrusions or displacements of the autografts.

A study by Ho et al [13] in the year 2003, reviewed patients who had undergone ossiculoplasty using titanium middle ear implants. He concluded that 64% and 45% of patients achieved air-bone gap less than 20 dB with PORP and TORP respectively. The procedure performed among that the group that he studies had the placement of the cartilage graft between the prosthesis and the tympanic membrane. In this study there were no extrusions observed.

Neff [14] studied 18 patients who underwent tympano-ossiculoplasty with a titanium TORP in the year 2003. Hearing results were analysed and showed 89% surgical success. The range of follow-up time was 2-12 months with an average of 8 months.He concluded that the use of a porous polyethylene TORP had a success rate of 67%. No extrusions were seen in his study in the follow up period.

Rondini-Gilli [15] in the year 2003, studied 100 patients who received either a HydroxylApatite PORP (n=65) or TORP (n=35). Extrusion or displacement of the implants occurred in 10% of cases.

These displacements were mostly seen when no cartilage cap was placed. The results showed that the majority did not have a successful closure less than 20 dB ABG. Poor auditory results were due to an absent stapedial arch with type 3 tympanoplasty, a radical mastoidectomy and previous tympanoplasty.

Hillman [16] published a retrospective study in 2003. He Reviewed 84 Patients who underwent tympanoplasty using Plastipore prosthesis and 53 who used titanium. There was 1 extrusion in the titanium group. There was one incidence of prosthesis failure in the titanium group. 60% of patients had postoperative air-bone gap of 20 dB or less in the Plastipore group. In the titanium group, 45.3% achieved a 20 dB or less air-bone gap.

In the year 2004, Gardner [17] published a retrospective study comparing titanium reconstructions to non-titanium reconstructions. With the use of titanium prosthesis, Successful rehabilitation of conductive hearing loss was obtained in 70% of PORPs and 44% of TORPs. Successful rehabilitation in 48% and 21% of non-titanium based partial and total reconstructions were observed.

A study by Martin [18] in the year 2004 reported 68 ossicular procedures using a titanium TORP (n = 30) or PORP (n = 38) An extrusion rate was 1.5% was reported. He also reported closure of the

ABG to within 20 dB in 57% of cases. Good hearing results were seen in primary cases for PORPs versus TORPs and for intact canal wall (ICW) procedures versus canal wall-down (CWD) procedures.

In the year 2005, O'Reilly [19] published a retrospective study of 137 patients (Austin-Kartush group A) demonstrating the effectiveness of incus interposition. Successful closure was seen in 66.4% of the air-bone gap to within 20 dB (mean 15.8 months post-op). N statistical correlation between MERI score and surgical success was noted.

Schmerber [20], in the year 2006 reported a retrospective study including 111 patients with implanted titanium PORP or TORP. Success was obtained in 77% of the PORP group and 52% of the cases in the TORP group. 2 extrusions (1.8%) of the prostheses were seen at 17 and 20 months after surgery. Revision procedures for functional failure were carried out in 20 patients (18%). This paper concluded that the major factors influencing good audiometric results were surgical procedures that preserved the external auditory canal and the preservation of stapes.

A study by Vassbotn et al [21] in the year 2007 published a retrospective study of procedures involving 73 titanium prostheses (38 PORPs and 35 TORPs). Average follow-up was 14 months. Success was seen in 77% of the patients, 89% for the Bell (PORP) prosthesis, and

63% for the Arial (TORP) prosthesis. The extrusion rate was 5%. The study concluded that the combination of CWD and TORP was inferior to TORP/CWU and PORP/CWD combinations.

A study by Siddiq et al [22] in the year 2007, analysed prospectively the early results of titanium partial and total ossicular replacement prostheses in chronic ear disease. 33 patients from both groups (20 PORPs and 13 TORPs) were analyzed. Results showed that PORP (85%) had a higher success rate in comparison to TORP (46%).

A study by De Vos et al [23] reported 149 cases that included implants with titanium PORPs and TORPs. Success rate was 60% and no difference was noted between the PORP and TORP groups. Prosthesis extrusions occurred in 3.5% of patients. Displacement of prosthesis occurred in 4.3%.

Emir [24] reviewed 304 patients in 2008 who underwent ossiculoplasty with an intact canal wall. A 58% success rate was seen in the group with autologous incus interposition , while those with plastipore PORPs resulted in 56% success rate. 9.3% of implants were extruded in this study.

A study by Coffey et al [25] in 2008 reviewed 105 cases, including 80 performed with titanium and 25 with non titanium implants.50.0% of non titanium cases were successful while 77.1% of titanium cases were

successful. Extrusion was seen with two non titanium prostheses (8.0%) in comparison to three titanium prostheses (3.8%) that were extruded.

AIM OF STUDY

- To study the effectiveness of Teflon PORP and TORP in ossicular reconstruction.
- To study the difference between pre-operative and post-operative pure tone audiogram showing an improvement in hearing.
- To study the post-operative graft uptake.

MATERIALS AND METHODOLOGY

It is a prospective study conducted at Madras Medical College and Rajiv Gandhi Government General hospital, Chennai 003 between October 2015 and September 2017.

The study population included patients who came to the outpatient department and were diagnosed with CSOM clinically.

INCLUSION CRITERIA

- Age between 20 and 50 years
- Both sexes (male and female)
- Chronic otitis media with ossicular erosion
- Chronic otitis media with conductive hearing loss
- Traumatic ossicular discontinuity

EXCLUSION CRITERIA:

- Age below 20yrs and above 50yrs
- Chronic otitis media with impending or overt complications
- Chronic otitis media with profound sensorineural hearing loss

After obtaining the institutional ethics committee approval, patients were voluntarily recruited for the study after obtaining informed consent.

A detailed history was collected from all the patients and a thorough physical examination of the ear was performed. HRCT temporal bone and pure tone audiogram were also done. The pure tone average and air-bone gap were calculated preoperatively. Patients were then prepared for surgery and ossicular status was assessed. If the ossicles were eroded, either a TORP or a PORP was used for ossicular reconstruction depending on the ossicles eroded. If the incus alone was eroded, a PORP was introduced and if the incus and suprastructure of stapes were eroded with or without erosion of malleus, a TORP was used. A postoperative pure tone audiogram was then done to calculate the pure tone average and the air-bone gap. This was compared to the preoperative audiogram.

Sample size was calculated using hypothesis testing method.

STUDY POPULATION

A total of 32 patients came to the outpatient department with complaints of ear discharge and hard of hearing. After a thorough history and examination, patients were enrolled in this study. Patients diagnosed with chronic otitis media with ossicular erosion and trauma causing ossicular discontinuity were included in the study.

Once the diagnosis was made, appropriate treatment in the form of conservative management for ear discharge after ear discharge for pus culture and sensitivity was started if the patients had complaints of ear discharge.

Routine blood investigations such as complete blood count, renal function test, random blood sugar, chest X-ray and electrocardiogram were done for anaesthetic purpose.

Visual analogue scale was used to assess the severity of symptoms.

1) Ear discharge- The characteristics of ear discharge were assessed.

If scanty, continuous, purulent, foul smelling and blood stained ear discharge – indicates chronic otitis media with cholesteatoma.

If profuse, intermittent, mucoid or mucopurulent – indicates tubotympanic disease.

The duration of the discharge and period of dryness tells us whether the ear is:

-Active

-Quiscent (dry for a period of less than 3 months)

-Inactive (dry for a period of 3 or more months)

2) Hard of hearing while conversing over the phone, whispering, regular conversation and for loud sounds indicates degree of hearing loss.

3) Ear pain indicates otitis externa, intracranial complications or active inflammation.

4) Tinnitus indicates involvement of cochlea.

5) Giddiness indicates vestibular pathology.

The tympanic membrane findings were recorded.

Preoperatively, a pure tone audiogram was done which gave a qualitative and quantitative analysis of hearing.

A pure tone average was taken to assess the degree of hearing loss at frequencies of 500Hz, 1000Hz and 2000Hz as they compare to the speech frequency.

They are quantified as follows:

Mild	:	25-40 dB
Moderate	:	41-55 dB
Moderately severe	:	56-70 dB
Severe	:	71-90 dB
Profound	:	>90 dB

The type of hearing impairment is classified as

1) Conductive when the threshold for air conduction is increased whereas bone conduction is normal.

2) Sensorineural hearing loss when the threshold for both air and bone conduction is increased.

3) Mixed hearing loss when the threshold for both air and bone conduction is increased with an increase in the air bone gap.

X-ray both mastoids lateral oblique view (law's view) was done in all cases preoperatively.

Computer tomography was done in certain cases to assess

1) The ossicular status.

2) The extent of the middle ear disease.

3) The mastoid air cells.

4) Inner ear anatomy.

OPRERATIVE PROCEDURE

An informed consent was obtained from all patients following which all our patients were operated under general anaesthesia.

MASTOIDECTOMY

A William Wilde postaural incision is made and extended up and temporalis fascia graft was harvested.

The incision was deepened and then a T shaped incision was made and periosteum was elevated. Spine of Henle was identified.

A meatotomy was done and pinna retracted forwards. Tympanomeatal flap was elevated.

Bone work was started in the MacEwan's triangle and the mastoid antrum reached which is usually located at a distance of 1-1.5cm from the mastoid cortex.

The following were analysed

1) Extent of the disease determining whether to do an intact canal wall or canal wall down procedure.

2) The ossicular status according to Austin's classification.

In an intact canal wall procedure, the canal wall is preserved.

In canal wall down procedures, the bridge is removed and the ridge is reduced while reducing the anterior and posterior buttresses, thereby making the mastoid and middle ear into a single cavity.

After disease clearance, an ossiculoplasty is done using TORP or PORP depending on the ossicular status.

If the incus alone is eroded, PORP is used. If incus and suprastructure is eroded, a TORP is used.

The TORP and PORP have to be altered for length before being used. A cartilage cap is then kept between the prosthesis and tympanic membrane.

In canal wall down mastoidectomy, conchal cartilage was used and in intact canal wall mastoidectomy, tragal cartilage was harvested.

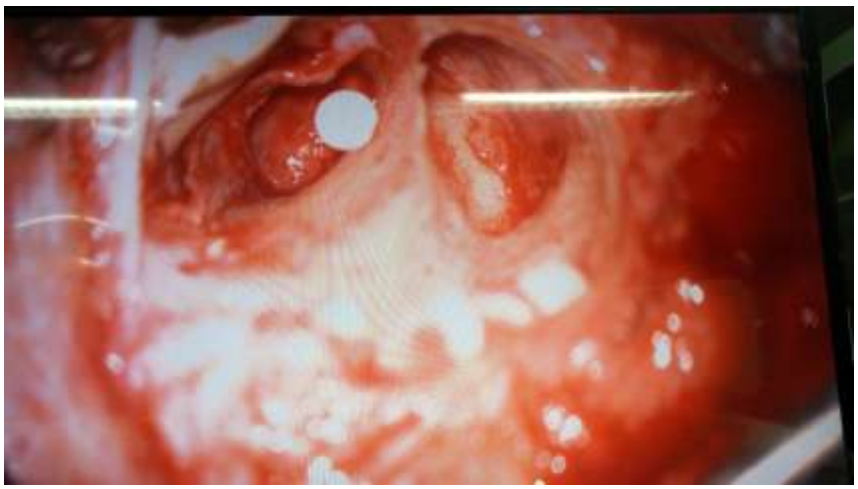

TYMPANOPLASTY

Temporalis fascia graft was harvested using a supraaural incision. Using 0° Hopkin's rodlens endoscope, infiltration was given in all 4 quadrants of external auditory canal. Edges of the perforation were freshened. 6 o'clock and 12 o'clock position incisions made and joined using a curvilinear incision. Tympanomeatal flap elevated. Middle ear inspected and ossicular integrity checked.

If the incus alone is eroded, PORP is used. If incus and suprastructure is eroded, a TORP is used.

The TORP and PORP have to be altered for length before being used. A cartilage cap is then kept between the prosthesis and tympanic membrane.

The tympanomeatal flap is then repositioned and gel foam is kept in the EAC. Medicated wick is then kept in the EAC and mastoid dressing done.

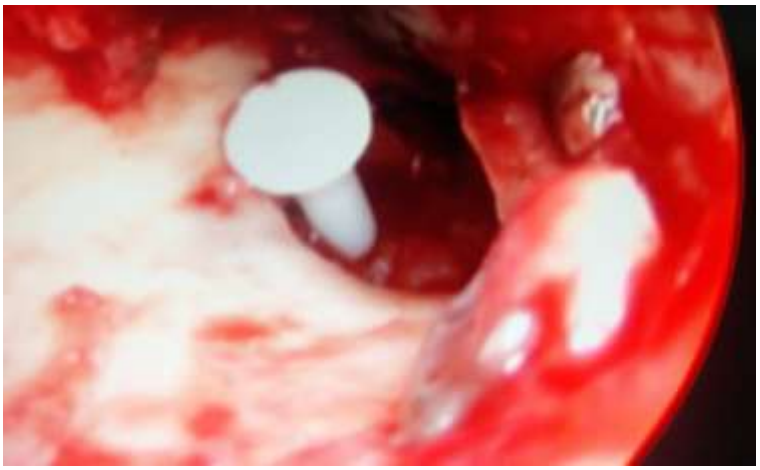

POST OPERATIVE FOLLOW UP

All the patients were started on Intravenous broad spectrum antibiotics (Inj. Cefotaxim), analgesics (Tab. Diclofenac), antihistamine (Tab. Cetrizine) in the immediate postoperative period for 1 week. The patients were discharged on Postoperative day 7 after suture removal. Medicated wick from the external auditory canal was removed at review on Postoperative day 14.

Patients were advised to avoid sneezing, and to keep the ear dry. Patients were followed up with otoscopic examination at weekly intervals for the first one week followed by monthly interval for the next 2 months. Patients were asked about the improvement in hearing, upper respiratory tract infection,ear discharge and giddiness at follow up. A thorough examination of ear,nose and throat was performed to look for any ear discharge, residual perforation and infection in throat or nose.

A pure tone audiogram was done postoperatively at 3 months.

OBSERVATION

Among the 32 patients that underwent ossiculoplasty, the following observations were made:

24 underwent PORP ossiculoplasty while

8 underwent TORP ossiculoplasty.

The Teflon prosthesis which was used in all the cases had to be altered in length and cartilage was harvested separately, if not during meatoplasty and took considerable time.

In the postoperative period, minor problems were encountered such as otomycosis and cavity problems.

One case had extrusion of the Teflon PORP.

Other complications which were noted in other studies such as facial palsy, severe sensorineural hearing loss, residual perforation, atelectasis and perilymph fistula were nil in our study.

There was no tinnitus or giddiness in our cases. This was probably due to good case selection with appropriate indications.

RESULT

The results were analysed after following up the patients every week for the first month postoperatively followed by monthly for the next 2 months postoperatively.

1) Written consent was obtained and the patient's privacy was maintained.

2) The patient was interviewed at every visit.

3) A thorough examination along with necessary investigations were done.

4) Intraoperative findings were recorded.

5) Postoperative findings were recorded.

6) The data was compiled and statistical analysis was done.

The collected data were analysed with IBM.SPSS statistics software 23.0 Version.To describe about the data descriptive statistics frequency analysis, percentage analysis were used for categorical variables and the mean & S.D were used for continuous variables.The Shapiro Wilk's test for normality shoed the data were normal hence to find the significant difference between the bivariate samples in Paired groups the Paired sample t-test was used and for Independent groups the Unpaired t test was used.In both the above statistical tools the probability value .05 is considered as significant level.

1. SEX GROUP TABULATION

		Fre-quency	Percent	Valid Percent	Cumulative Percent
Valid	FEMALE	14	46.7	46.7	46.7
	MALE	16	53.3	53.3	100.0
	Total	30	100.0	100.0	

There was a male predominance in the study group

2. DIAGNOSIS

		Fre-quency	Percent	Valid Percent	Cumulative Percent
Valid	Bilateral COM	5	15.6	15.6	15.6
	Left adhesive OM	3	9.4	9.4	25.0
	Left cholesteatoma	3	9.4	9.4	34.4
	Left COM	10	31.3	31.3	65.6
	Right adhesive OM	2	6.3	6.3	71.9
	Right cholesteatoma	2	6.3	6.3	78.1
	Right COM	7	21.9	21.9	100.0
	Total	32	100.0	100.0	

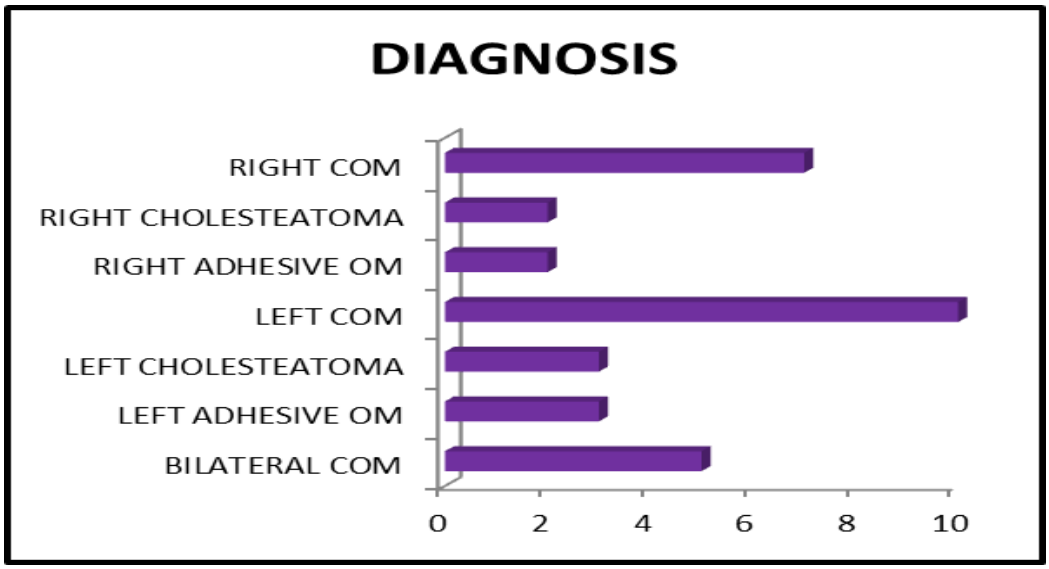

Majority of the patients presented with COM followed by adhesive OM and cholesteatoma.

3. PROCEDURE DONE

		Frequency	Percent	Valid Percent	Cumulative Percent
Valid	Left CWD mastoidectomy	2	6.3	6.3	6.3
	Left ICW mastoidectomy	5	15.6	15.6	21.9
	Left tympanoplasty	10	31.3	31.3	53.1
	Right CWD mastoidectomy	2	6.3	6.3	59.4
	Right ICW mastoidectomy	3	9.4	9.4	68.8
	Right tympanoplasty	10	31.3	31.3	100.0
	Total	32	100.0	100.0	

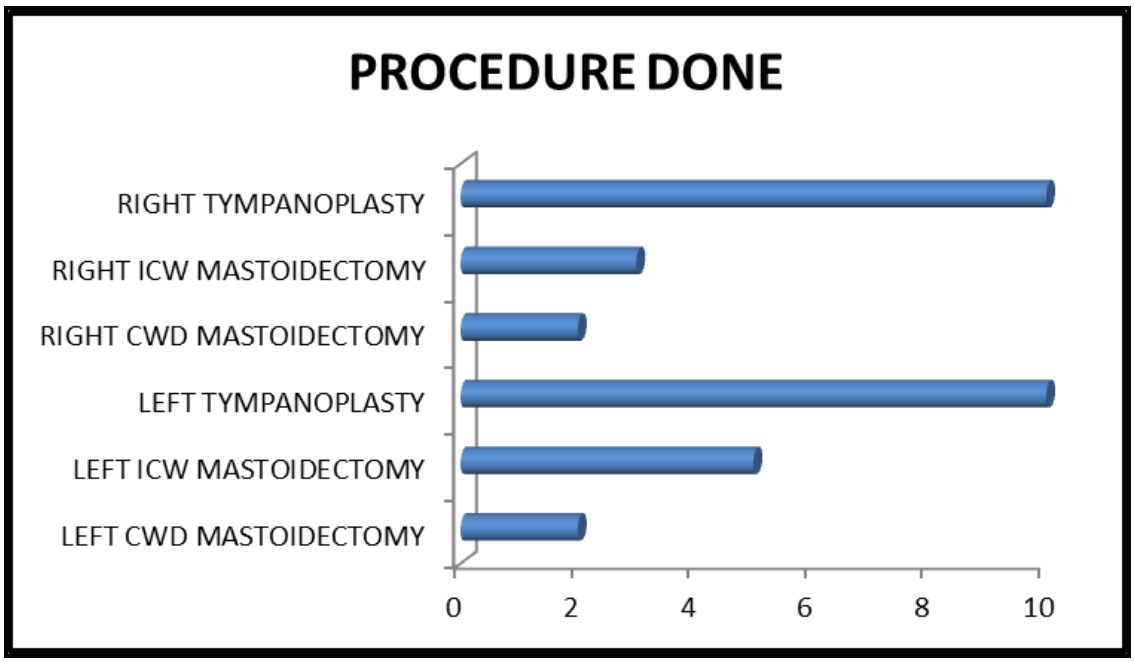

Majority of the surgeries performed was tympanoplasty

4. PROSTHESIS

		Frequency	Percent	Valid Percent	Cumulative Percent
Valid	PORP	24	75.0	75.0	75.0
	TORP	8	25.0	25.0	100.0
	Total	32	100.0	100.0	

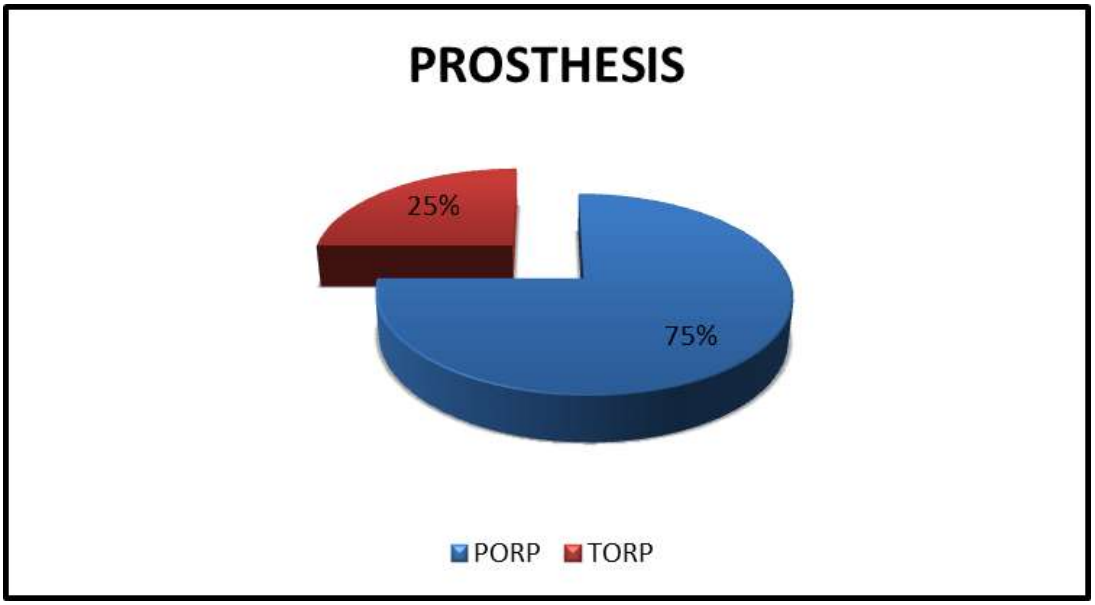

In majority of cases the prosthesis that was used was PORP

5. OSSICULAR STATUS

		Fre-quency	Percent	Valid Percent	Cumulative Percent
Valid	M-I-S-	2	6.3	6.3	6.3
	M+I-S-	6	18.8	18.8	25.0
	M+I-S+	24	75.0	75.0	100.0
	Total	32	100.0	100.0	

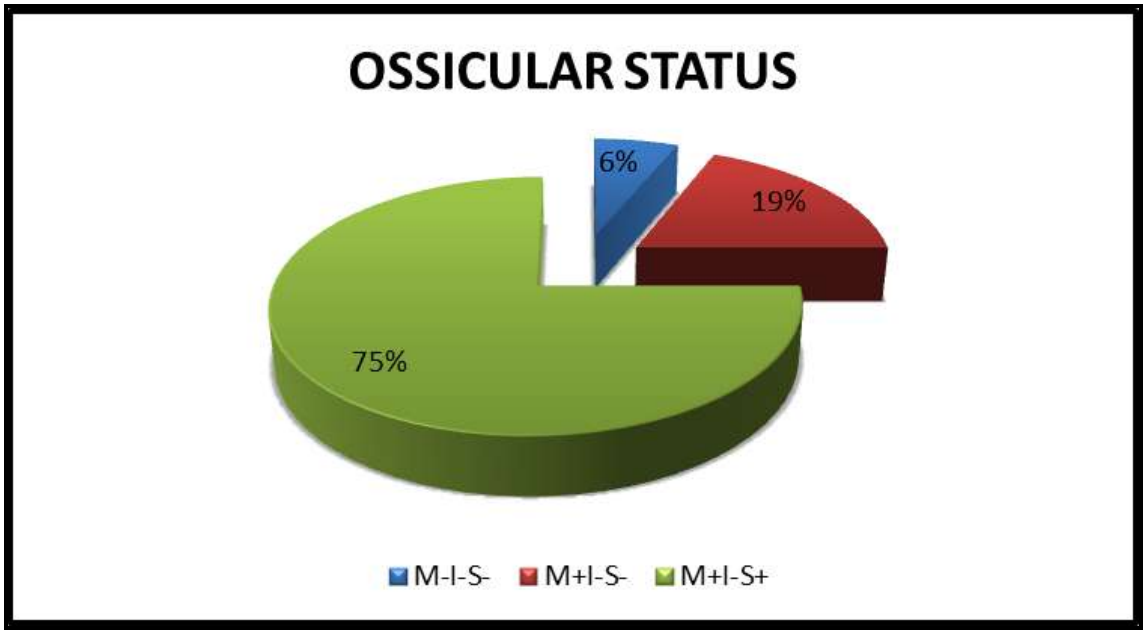

Most common ossicle eroded was the Incus.

6. PRE VERSUS POST OPERATIVE PTA

GROUPS		N	Mean	Std. Deviation	Std. Error Mean
PRE-OP PTA	PORP	24	44.17	2.839	.579
	TORP	8	64.00	8.036	2.841
POST- OP PTA	PORP	24	32.54	3.671	.749
	TORP	8	42.75	6.497	2.297
HEARING GAIN	PORP	24	11.63	2.516	.514
	TORP	8	21.25	3.327	1.176
DURATION OF ILLNESS	PORP	24	7.88	5.203	1.062
	TORP	8	5.25	2.188	.773

	Pre OP	Post OP
PORP	44.17	32.54
TORP	64.00	42.75

		Levene's Test for Equality of Variances		t-test for Equality of Means						
		F	Sig.	t	df	Sig. (2-tailed)	Mean Difference	Std. Error Difference	95% Confidence Interval of the Difference	
									Lower	Upper
PRE-OP PTA	Equal variances assumed	24.373	.000	-10.540	30	.0005	-19.833	1.882	-23.676	-15.990
	Equal variances not assumed			-6.840	7.590	.000	-19.833	2.900	-26.583	-13.084
POST- OP PTA	Equal variances assumed	2.581	.119	-5.566	30	.0005	-10.208	1.834	-13.954	-6.463
	Equal variances not assumed			-4.225	8.540	.003	-10.208	2.416	-15.720	-4.697
HEARING GAIN	Equal variances assumed	1.094	.304	-8.645	30	.0005	-9.625	1.113	-11.899	-7.351
	Equal variances not assumed			-7.498	9.815	.000	-9.625	1.284	-12.492	-6.758
DURATION OF ILLNESS	Equal variances assumed	.970	.333	1.375	30	.179	2.625	1.909	-1.274	6.524
	Equal variances not assumed			1.998	27.994	.056	2.625	1.314	-.066	5.316

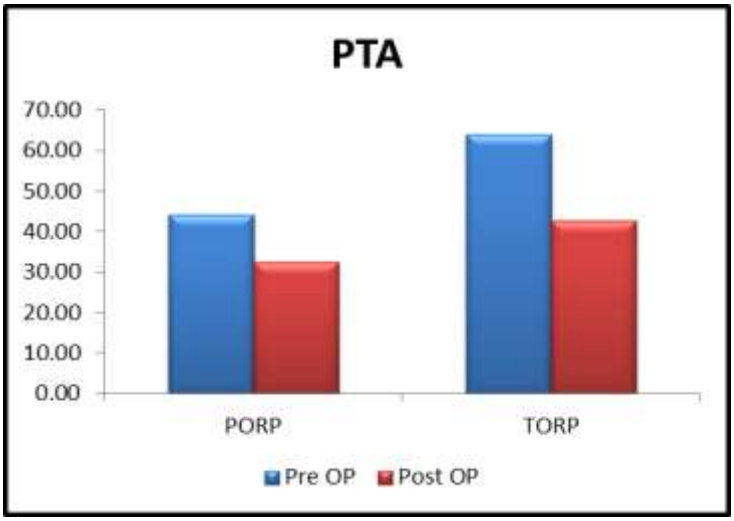

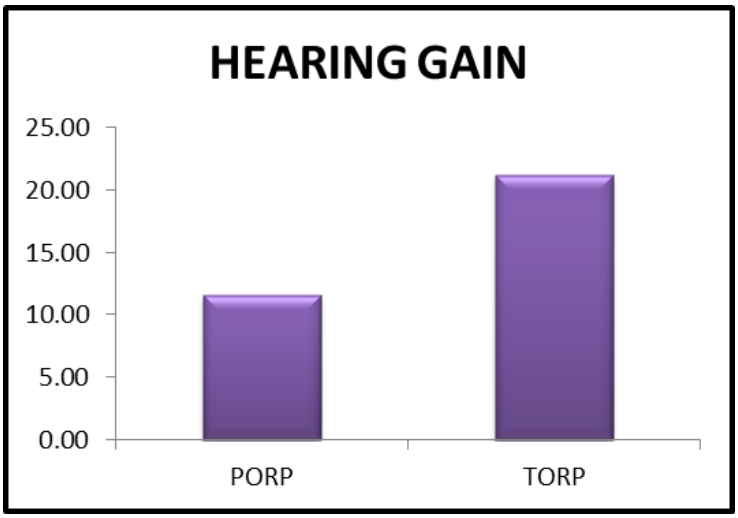

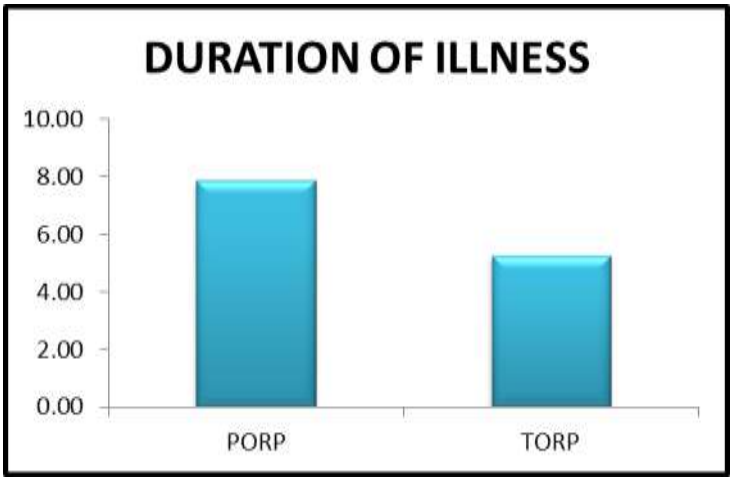

Comparison of the pure tone audiometry was done and on comparison of pre and post-operative pure tone average, there was a hearing gain that was significant (P= .0005)

7. PAIRED SAMPLES STATISTICSA

		Mean	N	Std. Deviation	Std. Error Mean
Pair 1	PRE-OP PTA	44.17	24	2.839	.579
	POST- OP PTA	32.54	24	3.671	.749
a. GROUPS = PORP					

Paired Samples Test-A									
		Paired Differences					t	df	Sig. (2-tailed)
		Mean	Std. Deviation	Std. Error Mean	95% Confidence Interval of the Difference				
					Lower	Upper			
Pair 1	PRE-OP PTA - POST-OP PTA	11.625	2.516	.514	10.562	12.688	22.633	23	.0005
a. GROUPS = PORP									

Comparison of the pure tone audiometry was done and on comparison of pre and post-operative pure tone average for PORP, there was a hearing gain that was significant (P= .0005)

GROUPS = TORP

Paired Samples Statisticsa					
		Mean	**N**	**Std. Deviation**	**Std. Error Mean**
Pair 1	PRE-OP PTA	64.00	8	8.036	2.841
	POST- OP PTA	42.75	8	6.497	2.297

Paired Samples Testa									
		Paired Differences					**t**	**df**	**Sig. (2-tailed)**
		Mean	**Std. Deviation**	**Std. Error Mean**	**95% Confidence Interval of the Difference**				
					Lower	**Upper**			
Pair 1	PRE-OP PTA - POST-OP PTA	21.250	3.327	1.176	18.468	24.032	18.064	7	.0005
a. GROUPS = TORP									

Comparison of the pure tone audiometry was done and on comparison of pre and post-operative pure tone average for TORP, there was a hearing gain that was significant (P= .0005)

DISCUSSION

The age group of the study population was 20 to 50 years. Out of these 15 were between 20-30 years of age, 7 were between 30-40 years and 8 were above 40 years of age.

14 of them were female patients and 18 were male patients.

Out of the 32 cases 24 underwent PORP ossiculoplasty while 8 underwent TORP ossiculoplasty.

ACCORDING TO THE OSSICULAR STATUS

Incus was always involved in the disease process. There was partial or total erosion in all cases.

Suprastructure of stapes was eroded in 8 cases.

Out of these, 3 patients had an eroded malleus.

4 patients underwent modified radical mastoidectomy with ossiculoplasty using TORP.

4 patients underwent Cortical mastoidectomy with ossiculoplasty using TORP.

Suprastructure of stapes was intact in 24 patients.

In all of these cases the incus was partially or completely eroded and malleus was intact.

20 patients underwent endoscopic tympanoplasty.

4 patients underwent intact canal wall mastoidectomy.

ACCORDING TO THE TYPE OF SURGERY

Modified radical mastoidectomy was done in 4 cases

1) Erosion of head of malleus, incus and suprastructure of stapes was seen in 2 cases. M-I-S-. Teflon TORP was placed over foot plate of stapes.

2) Erosion of incus and suprastructure of stapes with intact head of malleus was seen in 2 cases. M+I-S-. Head of malleus was removed and Teflon TORP was placed over foot plate of stapes

Intact canal wall mastoidectomy was done in 8 cases.

1. Erosion of incus and suprastructure of stapes with intact head of malleus was seen in 4 cases. M+I-S-. Head of malleus was removed and Teflon TORP was placed over foot plate of stapes

2. Erosion of incus alone with intact suprastructure of stapes and head of malleus was seen in 4 cases. M+I-S+. Teflon PORP was placed over suprastructure of stapes.

Tympanoplasty was done for 22 cases.

In all these cases, the incus was eroded while the head of malleus and suprastructure of stapes were intact.M+I-S+.

Teflon PORP was placed over suprastructure of stapes.

ACCORDING TO THE HEARING GAIN

Hearing gain was assessed by comparing the preoperative and postoperative pure tone average. Pure tone average was calculated from the average of intensity thresholds measured in decibels at frequency of 500, 1000 and 2000Hz.

In cases where MRM was done

In all cases TORP was used for ossiculoplasty.

In two cases the malleus was intact while the incus and suprastructure of stapes was eroded. In these cases the malleus was removed and Teflon TORP was put over the footplate of stapes.

In two cases the malleus, incus and suprastructure of stapes were eroded. In these cases, Teflon TORP was put over the footplate of stapes.

The average hearing gain for ossiculoplasty with canal wall down mastoidectomy is 22dB.

The mean of the pure tone average done postoperatively for canal wall down procedures is 42dB.

In cases where intact canal wall mastoidectomy was done

In 4 cases, there was erosion of incus and suprastructure of stapes with intact head of malleus. Head of malleus was removed and Teflon TORP was placed over foot plate of stapes.

The average postoperative hearing gain for these cases is 20dB.

In 4 cases, theres was partial erosion of incus alone with intact suprastructure of stapes and head of malleus. Teflon PORP was placed over suprastructure of stapes in these cases.

The average postoperative hearing for these cases is 13dB.

The average hearing gain for ossiculoplasty with intact canal wall mastoidectomy was 16dB.

The mean of the pure tone average done postoperatively for intact canal wall mastoidectomy with ossiculoplasty is 36dB.

In cases where tympanoplasty was done

The average hearing gain was 12dB.

The mean of the pure tone average postoperatively for tympanoplasty with ossiculoplasty was 32dB.

In patients with Teflon PORP ossiculoplasty

The average pure tone average preoperatively was 44dB

The average pure tone average postoperatively was 32dB

The net gain was 11dB

In cases with Teflon TORP ossiculoplasty

The average pure tone average preoperatively was 64dB

The average pure tone average postoperatively was 43dB

The net gain was 21dB

The average postoperative net gain following ossiculoplasty was 14dB

Average post-op hearing in patients with ossiculoplasty.

PROCEDURE	POST-OP PTA WITH OSSICULOPLASTY
TYMPANOPLASTY	32dB
ICW MASTOIDECTOMY	36dB
CWD MASTOIDECTOMY	42dB

Average is 34dB

CONCLUSION

1) Ossiculoplasty gives better results when compared to cases where ossiculoplasty isn't done.

2) Ossiculoplasty should always be done in patients with conductive hearing loss which is secondary to ossicular pathology. This can be done at a primary or second sitting.

3) Teflon prosthesis gives an acceptable hearing gain.

4) Teflon is cost effective when compared to other commercially available prosthesis.

5) Teflon is taken up well in the three month follow up period.

6) The only complication recorded was extrusion of the prosthesis which was seen in 1 case.

7) Long term results are awaited.

BIBLIOGRAPHY

1) Scott-Brown's Otorhinolaryngology, head and neck surgery 7th edition pg.966

2) Harold ludman & Tony wright's MAWSON TEXTBOOK for ―Diseases of the ear‖ 6th edition pg. 13-19

3) Harold ludman & Tony wright's MAWSON TEXTBOOK for ―Diseases of the ear‖ 6th edition pg. 13-19

4) Sade J, Berco E, Buyanover D, Brown M. Ossicular damage in chronic middle ear inflammation. Acta Otolaryngol. 1981;92:273–283.

5) De Vos C, Gersdorff M, Gerard JM. Prognostic factors in ossiculoplasty. Otol Neurotol. 2007; 28(1):61-7

6) Fisch U, May J. Tympanoplasty, Mastoidectomy and Stapes Surgery. New York: Thieme; 1994

7) Glasscock & Shambough Surgeries of the ear 6th edition pg. 63-68, Pg.489-498

8) **Shrinivas Shripatrao Chavan**. Ossiculoplasty: A prospective study of 80 cases. Iranian journal of otorhinolaryngology **2014 Jul; 26(76): 143–150.**

9) F Pathan. Tragal Cartilage Versus Polytetrafluoroethylene (TEFLON) Partial Ossicular Replacement Prosthesis (PORP): A Comparative Study of Outcomes of Ossiculoplasty. International Journal of Innovative Research in Medical Sciences (IJIRMS) Vol. 01, Issue 06, August 2016

10) Pasha R. Evaluation of hydroxyapatite ossicular chain prostheses. Otolaryngol Head Neck Surg. 2000 Oct;123(4):425-9.

11) House JW. Extrusion rates and hearing results in ossicular reconstruction. Otolaryngol Head Neck Surg. 2001 Sep;125(3):135-4

12) Iurato S. Hearing results of ossiculoplasty in Austin-Kartush group A patients. Otol Neurotol. 2001 Mar;22(2):140-4.

13) Ho SY. Early results with titanium ossicular implants. Otol Neurotol. 2003 Mar;24(2):149-52.

14) Neff BA. Tympano-ossiculoplasty utilizing the Spiggle and Theis titanium total ossicular replacement prosthesis. Laryngoscope. 2003 Sep;113(9):1525-9.

15) Rondini-Gilli E. Ossiculoplasty with total hydroxylapatite prostheses anatomical functional outcomes. Otol Neurotol. 2003 Jul;24(4) 543-7

16) Hillman, TA. Ossicular chain reconstruction: titanium versus plastipore. Laryngoscope. 2003 Oct;113(10):1731-5.

17) Gardner, EK. Results with titanium ossicular reconstruction prostheses. Laryngoscope. 2004 Jan;114(1):65-70.

18) Martin AD, Harner SG. Ossicular reconstruction with titanium prosthesis. Laryngoscope. 2004 Jan;114(1):61-4.

19) O'Reilly, R. Ossiculoplasty Using Incus Interposition: Hearing Results and Analysis of the Middle Ear Risk Index. Otology and Neurotology. 2005; 26

20) Schmerber S. Hearing results with the titanium ossicular replacement prostheses. Eur Arch Otorhinolaryngol. 2006 Apr;263(4):347-54.

21) Vassbotn FS. Short-term results using Kurz titanium ossicular implants. Eur Arch Otorhinolaryngol. 2007 Jan;264(1):21-5.

22) Siddiq MA. Early results of titanium ossiculoplasty using the Kurz titanium prosthesis--a UK perspective. J Laryngol Otol. 2007 Jun;121(6):539-44.

23) De Vos C. Prognostic factors in ossiculoplasty. Otol Neurotol. 2007 Jan;28(1):61-7.

24) Emir H. Ossiculoplasty with intact stapes: analysis of hearing results according to the middle ear risk. 2008 Dec 31:1-7

25) Coffey CS. Titanium versus nontitanium prostheses in ossiculoplasty. Laryngoscope. 2008 Sep;118(9):1650-8.

MASTER CHART

S.NO	NAME	AGE/SEX	DOS	DIAGNOSIS	DURATION OF ILLNESS	PROCEDURE DONE	OSSICULAR STATUS	PROSTHESIS	PRE-OP PTA	POST- OP PTA	HEARING GAIN
1	KAVITHA	31/F	04/08/2016	RIGHT ADHESIVE OM	5 YEARS	RIGHT TYMPANOPLASTY	M+I-S+	PORP	51dB	40dB	11dB
2	LALITHA	25/F	18/08/2016	LEFT COM	7 YEARS	LEFT ICW MASTOIDECTOMY	M+I-S-	TORP	58dB	40dB	18dB
3	AARIMUTHU	45/M	27/08/2016	BILATERAL COM	4 YEARS	RIGHT ICW MASTOIDECTOMY	M+I-S+	PORP	43dB	29dB	14dB
4	RAJU	50/M	22/09/2016	LEFT ADHESIVE OM	5 YEARS	LEFT TYMPANOPLASTY	M+I-S+	PORP	46dB	36dB	10dB
5	ARUNACHALAM	35/M	08/10/2016	LEFT COM	7 YEARS	LEFT TYMPANOPLASTY	M+I-S+	PORP	43dB	32dB	11dB
6	ANANDHAN	24/M	13/10/2016	LEFT COM	SINCE CHILDHOOD	LEFT ICW MASTOIDECTOMY	M+I-S+	PORP	42dB	30dB	12dB
7	VENGADESAN	33/M	20/10/2016	LEFT COM	6 YEARS	LEFT TYMPANOPLASTY	M+I-S+	PORP	43dB	30dB	13dB
8	KALA	42/F	03/11/2016	BILATERAL COM	11 YEARS	RIGHT TYMPANOPLASTY	M+I-S+	PORP	48dB	35dB	13dB
9	KUGAPRIYA	30/F	05/11/2017	RIGHT COM	7 YEARS	RIGHT TYMPANOPLASTY	M+I-S+	PORP	45dB	34dB	11dB
10	MARIYASELVAM	39/M	17/11/2016	LEFT ADHESIVE OM	5 YEARS	LEFT TYMPANOPLASTY	M+I-S+	PORP	49dB	33dB	16dB
11	KAMALA	25/F	24/11/2016	LEFT CHOLESTEATOMA	3 YEARS	LEFT CWD MASTOIDECTOMY	M+I-S-	TORP	70dB	49dB	21dB
12	BANUPRIYA	23/F	01/12/2016	BILATERAL COM	SINCE CHILDHOOD	LEFT ICW MASTOIDECTOMY	M+I-S+	PORP	46dB	35dB	11dB
13	GEETHA	34/F	03/12/2016	LEFT CHOLESTEATOMA	4 YEARS	LEFT CWD MASTOIDECTOMY	M+I-S-	TORP	51dB	30dB	21dB
14	MARUTHIPANDIYAN	25/M	03/12/2016	LEFT COM	6 YEARS	LEFT TYMPANOPLASTY	M+I-S+	PORP	41dB	29dB	12dB
15	JAYAVEL	28/M	08/12/2016	RIGHT CHOLESTEATOMA	3 YEARS	RIGHT CWD MASTOIDECTOMY	M-I-S-	TORP	71dB	48dB	23dB
16	PRAVEEN	20/M	15/12/2016	LEFT COM	8 YEARS	LEFT TYMPANOPLASTY	M+I-S+	PORP	41dB	29dB	12dB
17	KARTHICK	27/M	22/12/2016	LEFT CHOLESTEATOMA	2 YEARS	LEFT ICW MASTOIDECTOMY	M+I-S+	PORP	43dB	30dB	13dB
18	NATHIRA	43/F	05/01/2017	LEFT COM	6 YEARS	LEFT TYMPANOPLASTY	M+I-S+	PORP	46dB	38dB	8dB
19	FURKHAN	25/M	05/01/2017	BILATERAL COM	5 YEARS	RIGHT TYMPANOPLASTY	M+I-S+	PORP	44dB	39dB	5dB
20	RAMKIRT CHAUHAN	29/M	28/01/2017	LEFT COM	8 YEARS	LEFT TYMPANOPLASTY	M+I-S+	PORP	47dB	36dB	11dB
21	DURGA DEVI	27/F	02/02/2017	RIGHT COM	7 YEARS	RIGHT ICW MASTOIDECTOMY	M+I-S-	TORP	68dB	43dB	25dB
22	SAVITHRI	50/F	16/02/2017	LEFT COM	5 YEARS	LEFT ICW MASTOIDECTOMY	M+I-S-	TORP	73dB	50dB	23dB
23	MALINI	24/F	23/02/2017	RIGHT COM	10 YEARS	RIGHT TYMPANOPLASTY	M+I-S+	PORP	43dB	31dB	12dB
24	VIGNESWARAN	27/M	25/02/2017	RIGHT COM	6 YEARS	RIGHT TYMPANOPLASTY	M+I-S+	PORP	41dB	32dB	9dB
25	RAJARATHINAM	45/M	02/03/2017	RIGHT COM	9 YEARS	RIGHT ICW MASTOIDECTOMY	M+I-S-	TORP	56dB	41dB	15dB
26	ADITHYA	24/F	09/03/2017	RIGHT ADHESIVE OM	5 YEARS	RIGHT TYMPANOPLASTY	M+I-S+	PORP	41dB	30dB	11dB
27	RANJITH KUMAR	28/M	23/03/2017	RIGHT COM	7 YEARS	RIGHT TYMPANOPLASTY	M+I-S+	PORP	47dB	36dB	11dB
28	AYYAPPAN	38/M	15/03/2017	LEFT ADHESIVE OM	6 YEARS	LEFT TYMPANOPLASTY	M+I-S+	PORP	44dB	26dB	18dB
29	KUMAR	47/M	06/04/2017	BILATERAL COM	10 YEARS	RIGHT TYMPANOPLASTY	M+I-S+	PORP	42dB	32dB	10dB
30	PRIYA	20/F	01/05/2017	LEFT COM	6 YEARS	LEFT TYMPANOPLASTY	M+I-S+	PORP	40dB	28dB	12dB
31	KOTAMMA	45/F	01/05/2017	RIGHT CHOLESTEATOMA	4 YEARS	RIGHT CWD MASTOIDECTOMY	M-I-S-	TORP	65dB	41dB	24dB
32	ETHIRAJ	35/M	11/05/2017	RIGHT COM	7 YEARS	RIGHT TYMPANOPLASTY	M+I-S+	PORP	44dB	31dB	13dB

ABBREVIATIONS

COM – Chronic otitis media
M – Malleus
I – Incus
S – Stapes
CWD – Canal wall down
ICW – Intact canal wall

INSTITUTIONAL ETHICS COMMITTEE
MADRAS MEDICAL COLLEGE, CHENNAI 600 003

EC Reg.No.ECR/270/Inst./TN/2013
Telephone No.044 25305301A
Fax: 011 25363970

CERTIFICATE OF APPROVAL

To
Dr.Meenaxi P Mehta
Post Graduate in M.S. ENT
Upgraded Institute of Otorhinolaryngology
Madras Medical College
Chennai

Dear Dr.Meenaxi P Mehta,

The Institutional Ethics Committee has considered your request and approved your study titled **"PARTIAL OSSICULAR RECONSTRUCTION PROSTHESIS AND TOTAL OSSICULAR RECONSTRUCTION PROSTHESIS – A REVIEW ON ITS POST-OPERATIVE/FUNCTIONAL OUTCOME ON HEARING" NO. 24012017.**

The following members of Ethics Committee were present in the meeting hold on **03.01.2017** conducted at Madras Medical College, Chennai 3

1.Dr.C.Rajendran, MD.,	:Chairperson
2.Dr.M.K.Muralidharan,MS.,M.Ch.,Dean, MMC,Ch-3	:Deputy Chairperson
3.Prof.Sudha Seshayyan,MD., Vice Principal,MMC,Ch-3	: Member Secretary
4.Prof.B.Vasanthi,MD., Prof.of Pharmacology.,MMC,Ch-3	: Member
5.Prof.A.Rajendran,MS, Prof. of Surgery,MMC,Ch-3	: Member
6.Prof.N.Gopalakrishnan,MD,Director,Inst.of Nephrology,MMC,Ch	: Member
7.Prof.Baby Vasumathi,MD.,Director, Inst. of O & G	: Member
8.Prof.K.Ramadevi,MD.,Director,Inst.of Bio-Che,MMC,Ch-3	: Member
9.Prof.R.Padmavathy, MD, Director,Inst.of Pathology,MMC,Ch-3	: Member
10.Prof.S.Mayilvahanan,MD,Director, Inst. of Int.Med,MMC, Ch-3	: Member
11.Tmt.J.Rajalakshmi, JAO,MMC, Ch-3	: Lay Person
12.Thiru S.Govindasamy, BA.,BL,High Court,Chennai	: Lawyer
13.Tmt.Arnold Saulina, MA.,MSW.,	:Social Scientist

We approve the proposal to be conducted in its presented form.

The Institutional Ethics Committee expects to be informed about the progress of the study and SAE occurring in the course of the study, any changes in the protocol and patients information/informed consent and asks to be provided a copy of the final report.

Member Secretary – Ethics Committee

MEMBER SECRETARY
INSTITUTIONAL ETHICS COMMITTEE
MADRAS MEDICAL COLLEGE
CHENNAI-600 003

PATIENT CONSENT FORM

Title of the Project : PARTIAL OSSICULAR RECONSTRUCTION PROSTHESIS AND TOTAL OSSICULAR RECONSTRUCTION PROSTHESIS- A REVIEW ON ITS POST-OPERATIVE/ FUNCTIONAL OUTCOME ON HEARING

Institution : Upgraded Institute of Otorhinolaryngology,
Madras Medical College,
Chennai – 600003.

Name : Date :

Age : IP No. :

Sex : Project Patient No. :

The details of the study have been provided to me in writing and explained to me in my own language.

I confirm that I have understood the above study and had the opportunity to ask questions.

I understood that my participation in the study is voluntary and that I am free to withdraw at any time, without giving any reason, without the medical care that will normally be provided by the hospital being affected.

I agree not to restrict the use of any data or results that arise from this study provided such a use is only for scientific purpose(s).

I have been given an information sheet giving details of the study.

I fully consent to participate in the above study.

Name of the subject Signature Date

சுய ஒப்புதல் படிவம்

ஆய்வு செய்யப்படும் தலைப்பு :

காதில் உள்ள சிறு எலும்புகளின் குறைபாடு குறைந்த அளவு அல்லது முழுவதுமாக செயற்கை வடிவமைப்பு மாற்று அறுவை சிகிச்சை மூலம் காது கேட்கும் திறனின் வெளிபாடு அறிந்துகொள்ளும் முறை பற்றிய ஆய்வு.

ஆராய்ச்சி நிலையம் : இராஜீவ் காந்தி அரசு பொது மருத்துவமனை மற்றும்
சென்னை மருத்துவக் கல்லூரி,
சென்னை - 600 003.

பங்கு பெறுபவரின் பெயர் : உறவுமுறை :
பங்கு பெறுபவரின் எண். :

மேலே குறிப்பிட்டுள்ள மருத்துவ ஆய்வின் விவரங்கள் எனக்கு விளக்கப்பட்டது. என்னுடைய சந்தேகங்களை கேட்கவும், அதற்கான தகுந்த விளக்கங்களைப் பெறவும் வாய்ப்பளிக்கப்பட்டது.

நான் இவ்ஆய்வில் தன்னிச்சையாகத்தான் பங்கேற்கிறேன். எந்தக் காரணத்தினாலோ எந்தக் கட்டத்திலும் எந்த சட்ட சிக்கலுக்கும் உட்படாமல் நான் இவ்ஆய்வில் இருந்து விலகிக் கொள்ளலாம் என்றும் அறிந்து கொண்டேன்.

இந்த ஆய்வு சம்மந்தமாகவோ, இதை சார்ந்த மேலும் ஆய்வு மேற்கொள்ளும்போதும் இந்த ஆய்வில் பங்குபெறும் மருத்துவர் என்னுடைய மருத்துவ அறிக்கைகளைப் பார்ப்பதற்கு என் அனுமதி தேவையில்லை என அறிந்து கொள்கிறேன். நான் ஆய்வில் இருந்து விலகிக் கொண்டாலும் இது பொருந்தும் என அறிகிறேன்.

இந்த ஆய்வின் மூலம் கிடைக்கும் தகவல்களையும், பரிசோதனை முடிவுகளையும் மற்றும் சிகிச்சை தொடர்பான தகவல்களையும் மருத்துவர் மேற்கொள்ளும் ஆய்வில் பயன்படுத்திக் கொள்ளவும் அதைப் பிரசுரிக்கவும் என் முழு மனதுடன் சம்மதிக்கிறேன்.

இந்த ஆய்வில் பங்கு கொள்ள ஒப்புக்கொள்கிறேன். எனக்குக் கொடுக்கப்பட்ட அறிவுரைகளின்படி நடந்து கொள்வதுடன், இந்த ஆய்வை மேற்கொள்ளும் மருத்துவ அணிக்கு உண்மையுடன் இருப்பேன் என்றும் உறுதியளிக்கிறேன். என் உடல் நலம் பாதிக்கப்பட்டாலோ அல்லாத எதிர்பாராத வழக்கத்திற்கு மாறான நோய்க்குறி தென்பட்டாலோ உடனே அதை மருத்துவ அணியிடம் தெரிவிப்பேன் என உறுதி அளிக்கிறேன்.

பங்கேற்பவரின் கையொப்பம்..... இடம்..... தேதி
கட்டைவிரல் ரேகை

பங்கேற்பவரின் பெயர் மற்றும் விலாசம்.....

ஆய்வாளரின் கையொப்பம்..... இடம்..... தேதி

ஆய்வாளரின் பெயர்.....

[Urkund] 12% similarity - meenaxi.mehta1989@gmail.com

report@analysis.urkund.com Oct 18 (6 days ago)

to me

Document sent by: meenaxi.mehta1989@gmail.com
Document received: 10/18/2017 2:46:00 PM
Report generated 10/18/2017 3:34:20 PM by Urkund's system for automatic control.

Student message:

Document : FULL DISSERTATION.docx [D31433654]

IMPORTANT! The analysis contains 1 warning(s).

About 12% of this document consists of text similar to text found in 58 sources. The largest marking is 65 words long and is 79% similar to its primary source.

PLEASE NOTE that the above figures do not automatically mean that there is plagiarism in the document. There may be good reasons as to why parts of a text also appear in other sources. For a reasonable suspicion of academic dishonesty to present itself, the analysis, possibly found sources and the original document need to be examined closely.

Click here to open the analysis:
https://secure.urkund.com/view/31093241-205343-810428

Click here to download the document:
https://secure.urkund.com/archive/download/31433654-199130-601737

URKUND

Urkund Analysis Result

Analysed Document: FULL DISSERTATION.docx (D31433654)
Submitted: 10/18/2017 2:46:00 PM
Submitted By: meenaxi.mehta1989@gmail.com
Significance: 13 %

Sources included in the report:

THESIS FINAL Dr Vinson Fernandes.docx (D22021278)
6.10.docx (D31080314)
MASTOID.docx (D30971452)
https://link.springer.com/article/10.1007/s00405-005-1002-6
http://www.powershow.com/view1/f512c-ZDc1Z/
Ossicular_Reconstruction_powerpoint_ppt_presentation
http://emedicine.medscape.com/article/859889-overview
https://link.springer.com/article/10.1007/s00405-007-0293-1
http://ijorl.mums.ac.ir/article_2571.html
https://www.semanticscholar.org/paper/Ossiculoplasty-A-Prospective-Study-of-80-Cases-Chavan-Jain/be2edff18ec2619ad58555f75f615b445b352020
http://www.sciencedirect.com/topics/neuroscience/tympanic-cavity

Instances where selected sources appear:

59

PARTIAL OSSICULAR RECONSTRUCTION PROSTHESIS AND TOTAL OSSICULAR RECONSTRUCTION PROSTHESIS – A REVIEW ON ITS POSTOPERATIVE & FUNCTIONAL OUTCOME ON HEARING

0: 6.10.docx 69%

Dissertation submitted to THE TAMIL NADU DR.M.G.R. MEDICAL UNIVERSITY

In partial fulfillment of the regulations for the award of the degree of M.S., (Oto-Rhino-Laryngology) Branch – IV

Department of UIORL Madras Medical College Chennai 600003

THE TAMIL NADU DR. M.G.R. MEDICAL UNIVERSITY CHENNAI

CERTIFICATE

This is to certify that this dissertation entitled "PARTIAL OSSICULAR RECONSTRUCTION PROSTHESIS AND TOTAL OSSICULAR RECONSTRUCTION PROSTHESIS- A REVIEW ON ITS POST-OPERATIVE/ FUNCTIONAL OUTCOME ON HEARING" is a record of the bonafide research work done by Dr. MEENAXI P. MEHTA, under my guidance and supervision in the upgraded institute of otorhinolaryngology, Madras Medical College, Chennai - 600003.

Prof. N.SURESH KUMAR Professor of ENT Department of UIORL Madras Medical College Chennai 600003

PROFORMA

Name : Age & Sex :

Occupation : OP / IP No :

History :

Complaints : (Visual Analogue Scale)

	Right	Left
1. Ear Discharge	Yes/No	Yes/No
If yes,		
Type of discharge		
Continuous or Intermittent		
Foul smelling or Not		
Blood stained or Not		
2. Hard of Hearing	Yes/No	Yes/No
3. Ear Pain	Yes/No	Yes/No
4. Tinnitus	Yes/No	Yes/No
5. Giddiness	Yes/No	

H/o Trauma

Past History:

Treatment History:

H/o previous surgery:

H/o Medication:

Clinical Examination:

Ear:	Right	Left
1. Pre auricular region		
2. Pinna		
3. Post auricular region		
4. External auditory canal		
5. Tympanic membrane		
6. Tuning Fork Tests		
7. Vestibular function Tests		
8. Higher Function Examination		

Nose:

Throat:

DIAGNOSIS:

Investigations

1. Ear swab culture & sensitivity

2. X-ray mastoids/ CT Temporal bone

3. Pure tone Audiogram (pre-op)

SURGERY DONE:

FOLLOWUP

Graft uptake

Pure Tone Audiogram (post-op)

Hearing gain

Complications