

DISSERTATION ON

**“A PROSPECTIVE STUDY OF NON-MALIGNANT  
LESIONS OF LARYNX”**

Submitted in partial fulfillment of the requirements for

**M.S. DEGREE BRANCH -IV OTORHINOLARYNGOLOGY**

of

**THE TAMILNADU DR. M.G.R. MEDICAL UNIVERSITY,**



**UPGRADED INSTITUTE OF OTORHINOLARYNGOLOGY**

**MADRAS MEDICAL COLLEGE**

**CHENNAI – 600 003**

**MARCH – 2009**

## **DECLARATION**

I solemnly declare that the dissertation “ **A PROSPECTIVE STUDY OF NON-MALIGNANT LESIONS OF LARYNX**” done by me at the Madras Medical College and Government General Hospital, Chennai during 2006-2008 under the guidance and supervision of Prof. S. KULASEKARAN, M.S., D.L.O.

This dissertation is submitted to The Tamilnadu Dr. M.G.R Medical University, towards partial fulfillment of regulation for the award of M.S. DEGREE IN OTORHINOLARYNGOLOGY (BRANCH-IV).

**DR.M.P.CHANDRA MOULI**

**M.S. E.N.T. post graduate,**

**Place: Upgraded Institute of Otorhinolaryngology ,**

**Date: Madras Medical College**

## **ACKNOWLEDGEMENT**

I am immensely grateful to **Prof. S. Kulasekaran, M.S. D.L.O.**, The Director, Upgraded Institute of Otorhinolaryngology, for his valuable guidance, suggestions, encouragement and help in conducting this study.

I am greatly indebted to **Prof. K. Balakumar M.S., D.L.O.**, Professor, Upgraded Institute of Otorhinolaryngology, who encouraged and helped me throughout this study.

I express my sincere gratitude to **Ex-Director and Professor Late Dr. A. K. Sukumaran M.S., D.L.O.**, for his valuable support in conducting the study.

I would like to express my sincere gratitude to **Prof.T.P.KALANITI, M.D.**, The DEAN, Madras Medical College, for having permitted me to use the hospital material in this study.

I express my sincere thanks to all the Assistant Professors, for their thoughtful guidance throughout the work.

I thank the Secretary and Chairman of Institutional Ethical Committee, Government General Hospital and Madras Medical College, Chennai.

I thank all my colleagues and friends for their constant encouragement and valuable criticism.

Last but not least, I express my gratitude for the generosity shown by all the patients who participated in the study.

I am extremely thankful to my family members for their continuous support. Above all I thank God Almighty for His immense blessings.

# **CERTIFICATE**

This is to certify that this dissertation entitled **“A PROSPECTIVE STUDY OF NON-MALIGNANT LESIONS OF LARYNX”** submitted by **Dr.M.P.CHANDRA MOULI**, appearing for M.S. E.N.T.. Branch IV Degree examination in March 2009 is a bonafide record of work done by him under my direct guidance and supervision in partial fulfillment of regulations of the Tamil Nadu Dr. M.G.R. Medical University, Chennai. I forward this to the Tamil Nadu Dr.M.G.R. Medical University, Chennai, Tamil Nadu, India.

DIRECTOR & PROFESSOR,  
Upgraded Institute of Otorhinolaryngology,  
Madras Medical College,  
Government General Hospital,  
Chennai – 600 003.

# **CERTIFICATE**

This is to certify that this dissertation “**A PROSPECTIVE STUDY OF NON-MALIGNANT LESIONS OF LARYNX**” submitted by **Dr.M.P.CHANDRA MOULI**, appearing for M.S. E.N.T.. Branch IV Degree examination in March 2009 is a bonafide record of work done by him under my direct guidance and supervision in partial fulfillment of regulations of the Tamil Nadu Dr. M.G.R. Medical University, Chennai. I forward this to the Tamil Nadu Dr.M.G.R. Medical University, Chennai, Tamil Nadu, India.

DEAN,  
Madras Medical College,  
Government General Hospital,  
Chennai – 600 003.

# CONTENTS

INTRODUCTION	1
REVIEW OF LITERATURE	3
AIM OF STUDY	48
MATERIALS AND METHODS	49
INCLUSION AND EXCLUSION CRITERIA	50
OBSERVATIONS	51
DISCUSSION	63
CONCLUSION	74
BIBLIOGRAPHY	
PROFORMA	
ABBREVIATIONS	
MASTER CHART	

## INTRODUCTION

**Definition:-** Any tissue or mass in the larynx which does not present with the characteristics of malignancy is known as the non malignant lesion of the larynx.

Larynx is an important organ of the body. The primary function of the larynx is to provide protection to the lower airway. It secondarily evolved to serve as a vocal generator of sound. The larynx produces sound which is the major medium of communication. Voice helps in expressing emotions even without the help of language. It expresses the mood and attitude. It is the tone of voice which gives meaning, while in verbal use, the quality of voice is very significant specially for professional voice users like singers. The spectrum of voice disorders is very wide and its impact on different individuals also varies.

The larynx also known as the “Voice box” lodges the vocal cords and ligaments which on vibration produces voice. Any disease or disorder which affects vibration will produce phonatory and laryngeal



dysfunction. Various lesions produce this of which non-malignant lesions share a major part.

The laryngologist agrees to the fact that non malignant lesion not only includes true histologically benign tumours, but also lesions which are tumour like in appearance and behavior. Thus non malignant lesions can be classified as—

- (i) Benign neoplastic lesions.
- (ii) Benign non neoplastic lesions.

The laryngeal or phonatory dysfunction demands attention regardless of the age of the patient because of the fact that it is immediately noticed both by the patient and his attenders. In spite of the various etiologies, when diagnosed early and treated properly these lesions can have remarkable recovery. Some lesions like vocal nodule and Reinke's edema are treated by voice rest alone, while in others laser or microlaryngeal excision is needed.

The main aim of treatment is to give back the original voice to the patient.

## **REVIEW OF LITERATURE**

### **ANATOMY OF LARYNX:**

#### **Embryology:**

The development of larynx begins from the hypopharynx with the fusion of lateral structures derived from tracheobronchial primordium (arch 4 & 5 ) in the midline.

The larynx, trachea, bronchi and lungs have developed from midline ventral respiratory diverticulum namely the laryngo tracheo bronchial groove.

Supraglottis develops from buccopharyngeal primordium (arch 3 & 4). Glottis & Supraglottis develops from arches 4 & 6.

#### **Surgical Anatomy:**

The laryngeal frame work consists of muscles and their nerve supply overlying the architectural frame of bones and cartilages and their joints.

**Framework of the larynx:** The cartilages of the larynx are divided into three paired and three unpaired cartilages. The unpaired cartilages are thyroid, cricoid and epiglottis.

	Thyroid	Cricoid	Epiglottis
Shape	Shield	Ring	Leaf
Parts	Two lamina join at an angle of 90° in males and 120° in females.	Arch and a posterior lamina	Mobile suprahyoid and fixed infrahyoid parts
Muscles attached	Sternothyroid. Thyrohyoid Inferior constrictor, Thyroarytenoid.	Inferior constrictor Cricothyroid Cricoarytenoid	Aryepiglotticus
Ligaments attached	Thyrohyoid membrane and cricothyroid membrane.	Cricothyroid membrane	Thyroepiglottic ligament
Functions	Protects the larynx	Laryngotracheal connection	Guards the laryngeal inlet

Histology	Hyaline cartilage can calcify.	Hyaline cartilage can calcify.	Yellow elastic fibrocartilage will not calcify.
-----------	-----------------------------------	-----------------------------------	---

### **PAIRED CARTILAGES:**

The paired cartilages are arytenoids, corniculate and cuneiform. The arytenoids form the posterior support for laryngeal folds. It has two processes one pointing anteriorly attached to the vocal cord and the other pointing laterally called the muscular process, giving attachments to laryngeal muscles. The arytenoids articulate with the lamina of the cricoid cartilage. The insignificant corniculate cartilage articulates with the apex of the arytenoids.

### **LIGAMENTS OF LARYNX:**

The ligaments are classified as intrinsic ligaments and extrinsic ligaments. The extrinsic ligaments connect the larynx with the hyoid and trachea.

The thyrohyoid membrane connects the upper border of thyroid to the hyoid bone. The membrane is pierced by superior laryngeal

nerve and vessels. The cricothyroid ligament connects the lower border of the cricoid with the 1<sup>st</sup> tracheal ring. The hyoepiglottic ligament connects the hyoid to the epiglottis.

The intrinsic membrane is a fibro elastic membrane which connects the laryngeal cartilages, strengthens the joints and creates an internal frame work.

	Upper Quadrilateral membrane	Lower Quadrilateral membrane/ conus elasticus.
Upper attachment	Aryepiglottic fold	Thyroid to vocal process
Lower attachment	Vestibular folds	Cricoid
Ligaments	Inferior border- Vestibular ligament	Superior border – Vocal ligament
Special feature	Fibrous skeleton of laryngeal inlet.	Anterior part is called Cricovocal ligament.

## MUSCLES OF LARYNX:

The muscles of the larynx can be divided into extrinsic and intrinsic muscles.

The extrinsic muscles are sternothyroid, thyrohyoid, sternohyoid, mylohyoid, geniohyoid, stylohyoid, stylopharyngeus, palatopharyngeus and salpingopharyngeus.

The Intrinsic muscles connect one laryngeal cartilage to the other causing various movements of vocal cords.

The salient features of the muscles are given in the table:

Sl.No.	Name of muscle	Attachment	Function	Nerve
1.	Posterior Cricoarytenoid	Cricoid lamina lower part to muscular process of arytenoids	Open the Glottis	Recurrent laryngeal Nerve (RLN)
2.	Lateral Cricoarytenoid	Superior part of cricoid lamina to the muscular process of arytenoids	Adducts the vocal cord. Closes the glottis	Recurrent laryngeal Nerve (RLN)

3.	Interarytenoid	Arytenoid to arytenoid	Closes the post commissure	Recurrent laryngeal Nerve (RLN)
4.	Thyroarytenoid	Thyroid to arytenoids. Medial fibres are called vocalis	Internal tensor	Recurrent laryngeal Nerve (RLN)
5.	Cricothyroid	Cricoid to thyroid	External tensor	External laryngeal nerve.

The weight of abductors is not more than 25% of the weight of the adductors of the larynx. This may explain the greater vulnerability of the abductors<sup>(1)</sup> in the event of partial injury to the recurrent laryngeal nerve. This forms the base for the earlier concept of Semon's law.

## **INTERIOR OF LARYNX:**

The cavity extends from laryngeal inlet to the beginning of the lumen of the trachea at the lower border of cricoid cartilage and is divided by the vestibular and vocal folds into three compartments. The superior vestibule is above the vestibular folds. The ventricle or sinus of the larynx lies in between vestibular and vocal folds. The subglottic space extends from the vocal folds to the lower border of cricoid cartilage. The inlet is formed by aryepiglottic folds with free margin of epiglottis and mucosa in between the arytenoids and this is called as epilarynx. The sinus of the larynx is situated in between vestibular and vocal folds elongated in the anterior part as saccule. The saccule contains mucous glands and hence is known as the oil can of larynx.

## **MUCOUS MEMBRANE:**

The supraglottic and subglottic areas are lined by respiratory pseudostratified ciliated columnar epithelium. The squamous epithelium is seen over the vocal cord and transitional epithelium on few places. The mucous glands are situated all over the membrane more so over the posterior surface of epiglottis and saccule but devoid over the vocal cords. The vocal cords are lubricated by the saccule.



## **SPACES IN THE LARYNX:**

**Pre-epiglottic space of Boyer** – Potential space in front of the epiglottis. It has a bilateral and rich supply of lymphatics.

### **Boundaries**

- Anterior - Thyrohyoid membrane and Thyroid cartilage
- Posterior - Epiglottis
- Lateral - Communicates with paraglottic space
- Inferior - Attachment of epiglottis with thyroid cartilage
- Superior - Hyoepiglottic ligament

**Para Glottic space of Tucker** - lies on both sides of larynx lateral to the saccule and anterior to the pyriform fossa.

### **Boundaries**

- Anterior - Communicates with pre epiglottic space
- Posterior - Anterior reflection of pyriform fossa
- Medial - Quadrangular membrane and conus elasticus
- Lateral - Thyroid lamina

**Reinke's space:**

Sub epithelial potential space lying over the vocal ligaments. This space is devoid of lymphatics.

**Boundaries**

Anterior	-	Anterior Commissure
Posterior	-	Vocal process
Superior	-	Superior arcuate line
Inferior	-	Inferior arcuate line

**CELLULAR PHYSIOLOGY OF VOCAL CORDS:**

Knowledge of the macro and microscopic anatomy and physiological process is essential in understanding the aetiopathology of various clinical conditions.

The vocal cords consists of tissues such as epithelium, lamina propria, striated muscle, nerves, vascular structure and cartilage.

**Epidermis:**

Vocal cords are covered with stratified squamous epithelium while other parts of larynx have ciliated pseudo columnar epithelium. Most of the ciliated epithelium is found in the posterior glottis.

A layer of mucus, the mucociliary blanket lies over the epidermis. The mucus consists of 2 layers – a mucinous gel layer and a serous sol layer. The purpose of mucinous layer is to prevent dehydration of the serous layer and of underlying cilia and cells.

The serous layer which is the underlying layer of mucociliary blanket shows a higher percentage of water. It has been shown that one puff of cigarette can slow the clearance of mucociliary blanket to lower than normal levels<sup>(2)</sup>. This slow clearance of mucociliary blanket exposes the underlying epithelium to more toxins, inflammatory agents and dehydration.

Basement membrane zone – Epidermis serves as a protective covering that gives shape and consistency to lamina propria. Epidermis is secured to the lamina propria through the basement membrane zone. The basement membrane zone is collection of protein and non proteinous structures which together helps the basal cells secure themselves to the amorphous mass of proteins present in the lamina propria. In the epidermis, cells are attached to each other through desmosomes . Desmosomes are attachments between the cytoskeletons of adjacent cells. These attachments are strong and can resist the pounding to which skin and vocal folds are subjected. The lamina

propria on the other hand is a very loose connection of fibrous structures which are mainly non-cellular. Essentially the basal cells have anchoring filaments which secure the hemidesmosomes of the cells to the lamina densa and lamina lucida which itself is mainly composed of collagen type IV. Similarly other structures known as anchoring fibres composed of collagen type VII, loops from the lamina densa into the lamina propria and back up into the lamina densa. The number of anchoring fibres in the basement membrane zone is genetically determined. Genetic influence on predisposition to vocal disease has not been established. Nevertheless the genetic determination of anchoring fibril population density does raise some interesting questions and points out that genetics may influence vocal health and disease.

#### **THE LAMINA PROPRIA:**

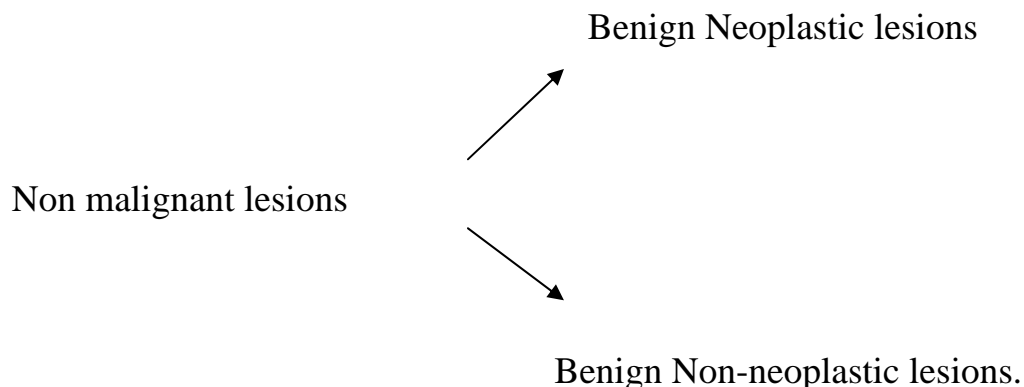
The lamina propria is divided into superficial layer (SLLP) middle layer (MLLP) and deep layer (DLLP). The SLLP has fewer elastic fibres than the MLLP and DLLP. Together the MLLP and DLLP constitute the vocal ligament, an area of the lamina propria that bears longitudinal stress and thus has a more dense concentration of collagen fibres.

Clinically most microscopic injury to the vocal fold seems to resolve itself quickly. Performers who have vocal overuse might feel that within 2-3 days the voice is back to a more normal performing standard. This is because the basement membrane zone is extremely competent in repairing microscopic injury within 36-48 hours. If, however constant and vigorous injury is being experienced by the vocal fold tissue, the vocal folds may not be able to repair themselves adequately enough, to prevent the onset of pathological condition.

Electron microscopy has shown several arterio- venous shunts that are present in the vocal fold micro circulation. These allow auto regulation of blood flow to this area <sup>(3)</sup>.

### **NON MALIGNANT LESION OF LARYNX**

Is defined as any tissue or mass in the larynx which does not present with the characteristic of malignancy is called as non malignant lesion of the larynx. <sup>(4)</sup>



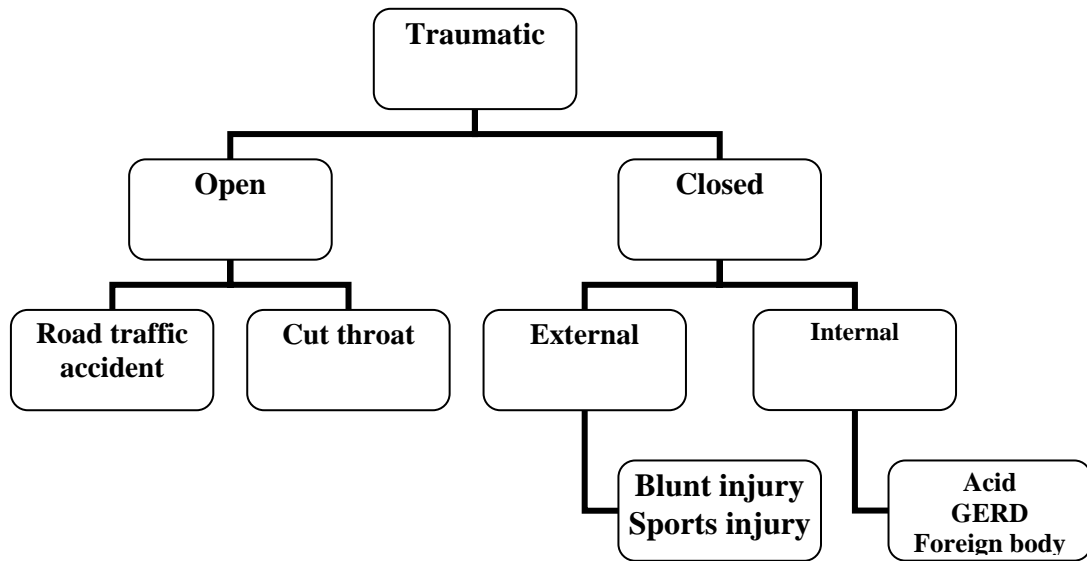
### Benign Neoplastic lesions

Epidermal	Papilloma
Neural	Neurofibroma Schwannoma Paranganglioma
Glandular	Oncocytic tumour
Vascular	Haemangioma
Cartilagenous	<u>Chondroma</u>
Miscellaneous	Lipoma Fibroma Rhabdomyoma

### Benign non neoplastic lesion

Congenital	Laryngocoele Saccular cyst Lymphangiomas Laryngeal webs Congenital subglottic stenosis
------------	--

	<p>Subglottic hemangioma</p> <p>Laryngeal &amp; <u>laryngo-tracheo-oesophageal</u> cleft</p>
Traumatic	
Inflammatory	<p>Keratosi</p> <p>Vocal polyp</p> <p>Vocal nodule</p> <p>Reinke's edema</p> <p>Intracordal cyst</p> <p>Contact ulcer</p>
Granuloma	<p><u>Bacterial</u></p> <p>Tuberculosis</p> <p>Leprosy</p> <p>Syphilis</p> <p>Rhinoscleroma</p> <p><u>Fungal</u></p> <p>Rhinosporidiosis</p>
Miscellaneous	<p>Sarcoidosis</p> <p>Amyloidosis</p> <p>Wegners Granuloma</p>



### **General Consideration:**

Benign lesions can be proliferative or stenotic . The proliferative lesions can be a polyp, granulation, or a mass lesion. The stenotic lesion can be a web, cleft or a stenotic segment. There can be two outcomes of these lesions symptomatically.

- 1) Phonatory dysfunction
- 2) Obstructed airway.

### **Benign neoplastic lesion:**

85% of benign neoplastic lesions are papilloma larynx ,of which 25% were recurrent respiratory papillomatosis.



**Papilloma larynx:**

These are squamous in origin, colour ranges from white to red, are usually sessile, may be keratinizing or non keratinizing. The adult type and children type are histologically the same, but tumour behaviour is different and they belong to clinically different groups.

**Recurrent Respiratory Papillomatosis**

This disease has a world wide distribution and involves all socioeconomic groups. In children there is a female preponderance. Jones, Myers and Barnes<sup>(5)</sup> found that 84% of the benign laryngeal tumours they managed were papillomas.

**Etiology:** Human papilloma virus – Types 6, 11

After infection the virus may remain in the basal layer of mucous membrane replicating by a process known as Episomal maintenance, where virus is undetectable but its presence can be determined by DNA hybridization<sup>(6)</sup>.

**Characteristics:** Occurs in clusters as multiple non keratinizing lesions, which recur even after radical stripping. The symptoms appear before the age of 4 years. The symptoms are hoarseness, abnormal cry, dyspnoea and later stridor. The papillomas are present more on the

anterior aspect of larynx, because of the thick mucous blanket with rapid clearance has a protective effect on the posterior aspect of the larynx. It can extend up to the trachea and major bronchii

**Natural history:** The transmission occurs from mother with genital warts to child in about 60% of cases. Remission can take place at any age unrelated to treatment and relapse can occur at any age. Malignant transformation is very rare<sup>(7)</sup> and usually seen after radiotherapy and in smokers.

**Management:**

The treatment of choice is microlaryngeal laserization.

**Adjuvant therapy:**

- Systemic Cis-Retinoids -The recurrence rate is reduced but serious side-effects like skin excoriation occurs.
- Indole-3-carbinol a natural derivative of cruciferous vegetables.
- Interferons – Causes only decrease in recurrence or temporary remission.
- Avidano and Singleton<sup>(8)</sup> reported the use of methotrexate in three patients.
- Intralesional cidofovir

### **ADULT PAPILLOMA:**

The papillomas are solitary, small and less aggressive in behaviour than child types. It occurs on the vocal cord and endoscopic removal usually cures. The histology consists of fronds of connective tissue covered by well differentiated squamous epithelium with no invasion of stroma or submucosa. Malignant transformation is more frequent.

### **LARYNGEAL PARAGANGLIOMA:**

It arises from paired superior and inferior paraganglia situated in relation to superior laryngeal nerve and loop of Gallen.

Clinical features: Usually small red painful mass located on the aryepiglottic fold. The striking feature is pain radiating to the ear which resolves after biopsy or excision. They are very vascular and may bleed if injured.

Treatment: Surgical excision by open surgical technique or endoscopic removal.

**NEUROFIBROMA** – Commoner in patients with Von Recklinghausens disease or independent of this. They are bulky slow growing mass over aryepiglottic fold and false vocal cord. Voice

change, fullness in the throat and slowly developing dyspnoea are the other features. The treatment is surgical excision.

### **HAEMANGIOMA:**

The haemangioma should be differentiated from granulation tissue in all cases. The haemangiomas are of two types - juvenile and adult forms. The juvenile type occurs in children in subglottic area and remission can occur. If remission does not occur endoscopic surgical excision preferably with laser is done. But in adults due to the bigger diameter of vessels, this is less successful. The adult type lesion occurs in the glottic or supraglottic areas, producing hoarseness and stridor and is treated by open surgical excision.

### **MISCELLANEOUS TUMOURS:**

The chondroma occurs between the age group of 60-70 with 4:1 male:female ratio, 20% are malignant. Cricoid cartilage is most commonly affected. They are clinically smooth, encapsulated masses and wide excision is the treatment of choice.

The lipoma, fibroma and rhabdomyoma are very rare. The granular cell tumours occurs between 30-50 years of age. The etiology is not clear. It may be congenital, neoplastic or degenerative. They

have PAS positive granular cytoplasm with pseudo epitheliomatous hyperplasia. Surgical excision is the treatment of choice.

## **BENIGN NON-NEOPLASTIC LESIONS**

### **Congenital Causes:**

Laryngeal cyst – The laryngeal cysts are classified as saccular, ductal and thyroid foraminal cysts. They are commoner in females<sup>(10)</sup>.

	Saccular Cyst	Ductal Cyst
Definition	Mucous filled dilatation of the saccule of the ventricle.	Obstruction to the glandular collecting ducts.
Position	Lateral saccular: On AE fold and can extend outwards. Anterior saccular: Into the larynx.	Anywhere in the larynx except on free margin of vocal cord.
Symptoms	Hoarseness, abnormal cry, stridor.	Asymptomatic, cough, throat pain, hoarseness
Treatment	Endoscopic deroofing. Aspiration by needle Larger ones : Surgical excision.	Endoscopic excision.

## **LARYNGOCOELE:**

It is an air containing sac due to dilatation of the saccule, an appendage of the laryngeal ventricle. More common in adult males. Ratio is 5:1 in favour of males<sup>(11)</sup>. The laryngocoele is differentiated from the cyst by the presence of air which is not present in the cyst.

**Classification** – There are 3 types of laryngocoeles.

- i) Internal laryngocoele – Confines to the interior of the larynx.
- ii) External laryngocoele – Presents as a mass, in the lateral aspect of neck coming through thyrohyoid membrane.
- iii) Mixed group.

**Etiology** : 1) Increased transglottic air pressure

2) Long saccule

3) Obstructed saccular orifice

4) Association with malignancy.

**Pathophysiology** – Any obstruction in the laryngeal ventricular lumen<sup>(12)</sup> traps air inside the sac producing laryngocoele. If it is filled with mucous it is called laryngomucocele and if with pus it is called laryngopyocoele<sup>(13)</sup>.

**Clinical features** – Usually asymptomatic patient can have hoarseness, cough, foreign body sensation in the throat and neck swelling. The laryngoscopy shows sub mucosal mass seen over false cord which increases on doing valsalva. It is present in the neck and on compression reduces with a hissing sound.

**Radiology** – Well defined radiolucent mass protruding into the soft tissues of neck.

**Treatment** – Laryngoscopy and marsupilization. Laser preferred.

Laryngofissure with submucosal or transmucosal approach.

Lateral external neck approach with lateral pharyngotomy and excision of sac – treatment of choice.

## TRAUMATIC

## Trauma



External		Internal
Open	Closed	<ul style="list-style-type: none"><li>▪ Burns</li><li>▪ Poisons</li><li>▪ Gastro Esophageal Reflux Disease</li><li>▪ Radiation</li><li>▪ Iatrogenic</li><li>▪ Foreign Body</li></ul>
<ul style="list-style-type: none"><li>▪ Cut throat</li><li>▪ Road traffic accident</li><li>▪ Bullet injury</li><li>▪ Iatrogenic</li></ul>	<ul style="list-style-type: none"><li>▪ Sports Injury</li><li>▪ Road Traffic Accident</li><li>▪ Hanging</li></ul>	

The injuries can cause acute or chronic problems. The acute problems are airway obstruction due to edema and haematoma and disruption of airway due to soft tissue injuries.

**Haematoma** – Blood collects between mucoperichondrium and underlying cartilagenous frame work and spreads along tissue spaces like Reinkes space or para glottic space. Spread to supra glottis is prevented by Conus elasticus.



Chronic Sequelae – Adhesion and web formation occurs at the glottic level while stenosis occurs more commonly at the subglottic level.

Pathophysiology – 2 types of reaction.

1. Haematoma – Over the cartilage with intact mucosa.

Cartilage gets absorbed leaving a thin fibrous scar which produces abnormal movement on respiration.

2. If cartilage is denuded, granulation tissue is produced which heals by a thick fibrous scar and causes stenosis.

Clinical features Hoarseness, pain ,cough, dysphagia and haemoptysis.

Dyspnoea and stridor can occur in some cases.

Treatment – Open surgical methods like Laryngofissure with a keel produces better results.

Laryngeal expansion with structural support and lining is done using autologous material.

### **INFLAMMATORY:**

Non specific infection produces laryngitis, vocal polyp, vocal nodules, Reinkes edema,

### **Etiology**

- Chronic irritation due to smoking, tobacco, alcohol.
- Chronic upper and lower respiratory tract infection.

- Gastro Esophageal Reflux Disease
- Voice abuse or misuse
- Occupational
- Mouth breathing.

### **PATHOLOGY:**

**Keratosis:** Epithelial hyperplasia with orderly maturation sequence with normal cellular cytogenic appearance with or without atypia and some degree of Keratinization.

**Contact ulceration** – Saucer like lesion on the medial edge of vocal cord at the vocal process. There is no epithelial defect but is caused due to central indentation in the thickened mucosa over the vocal process. The thin mucosa and perichondrium overlying the cartilagenous glottis becomes inflamed, perhaps due to forceful apposition of the arytenoids during chronic coughing and throat clearing. The traumatized area ulcerates and produces heaped up granuloma.

### **Treatment:**

- Anti reflux regimen
- Voice rest and speech therapy
- Removal of predisposing causes like smoking

- Surgery should be the last resort. If needed, Microlaryngeal excision and stripping can be done.

**Other inflammatory causes:**

	Vocal polyp	Vocal Nodule	Reinke's edema
Etiology	Voice misuse, Hyperkinetic dysphonia M : F = 2 : 1	Voice misuse, Hyperkinetic vociferous personality. Common in females	Idiopathic smoking (14)
Site	Free edge or under surface of vocal cord	Nodule at the junction of anterior and middle 3 <sup>rd</sup> of vocal cord	Reinke's space
Appearance	White glistening sessile polyp moves with respiration	Hard white nodule	Bilateral symmetrical polypoidal swelling
Pathology	Acellular stroma with greyish yellow exudates	Vascular congestion, hemorrhage, sub epithelial fibrosis with hyaline degeneration	Edema in Reinke's space
Voice	Hoarseness, rarely diplophonia	Throaty, cannot sing high notes	Weak, slightly husky voice
Treatment	Microlaryngeal excision Laser	Conservative microlaryngeal excision or laser	Microlaryngeal stripping

## **GRANULOMATOUS LESIONS**

i) Non-Specific      Vocal granuloma

ii) Specific          Tuberculosis, Leprosy, Syphilis, Rhinoscleroma

### **Vocal Granuloma:**

Granulomas are discrete, clearly defined lesions that occurs on the lower portion of the Vocal fold where it attaches to the arytenoid cartilage. Laryngopharyngeal reflux is the most common cause of granuloma formation. First suggested by Cherryard Margilies in 1968<sup>(15)</sup>. Endotracheal intubation is another cause of granuloma formation. Treatment depends upon the size of the lesion and length of time it is present but most likely will require control of reflux. Voice rest and laserization is also useful. Prolonged intubation is to be avoided.

### **Tuberculous laryngitis:**

Laryngeal tuberculosis is almost always secondary to pulmonary tuberculosis.

**Pathology** – Pathogenesis has two theories:

1. Sputogenic theory : Coughed up sputum lodges in the posterior commissure for a certain period of time causing disease due to mucosal invasion<sup>(16)</sup>.

2. Blood borne or Hematogenous theory: As in miliary tuberculosis<sup>(17)</sup>.

**Macroscopic** : Exudative type : Submucosa of epiglottis infiltrated by fibrous tissue producing pseudoedema leading to Turban Epiglottis.

**Microscopic** : When bacteria invades mucosa it is engulfed by macrophage which forms epithelioid cells. Tubercle consists of central area of caseation necrosis with surrounding epithelioid cells, macrophage, giant cells followed by lymphocytes and fibroblast.

**Clinical features** : Weak voice turns into rough whisper, odynophagia, referred otalgia, dyspnoea and stridor.

Signs – Congested vocal cord with mouse nibbled appearance, interarytenoid mammillation, edematous pyriform and arytenoids, edema of epiglottis, prolapse of ventricular bands and striking pallor of surrounding structures. Vocal cords may not be mobile due to palsy, joint involvement interarytenoid mammillation and myositis.

**Management** – Diagnosis is by radiological, serological examination and biopsy.

Treatment is by anti tuberculosis drugs.

## REVIEW OF PREVIOUS STUDIES DONE

Comparison of Benign to malignant laryngeal Lesions.

The ratio of benign to malignant laryngeal lesion in adult male is 2:3. In females the ratio is reversed.

**Table 1**

Author	Year	Ratio
Stewart <sup>(18)</sup>	1957	3:4
H.Shaw <sup>(19)</sup>	1979	2:3

Comparison of non neo plastic lesion to neo plastic lesion

**Table 2**

Author	Year	Total No. of benign lesion	Non-neo plastic	Neo plastic
Chathopadyay <sup>(20)</sup>	1972	97	66	31
Shaw	1972	1505	1300	205`
Sellars	1979	743	551	192

**AGE** – Benign tumours can occur at any age. Most frequently it occurs in 3<sup>rd</sup> – 5<sup>th</sup> decade.

**Table 3**

Author	Year	Lesions	Age
M.Nelson	1986	Reinke's Oedema	31-78
B.Benjamin <sup>(21)</sup>	1985	V.C.Granuloma	10-69
M.Bouchayer <sup>(22)</sup>	1985	Epidermoid cyst and sulci	5-59
Yates et al <sup>(23)</sup>	1984	Polypoid vocal cords	38-77

**SEX:**

Benign lesions are more common in males. But some studies have also shown female predominance like the study by M.Bouchayer (1988).

**Table 4**

Author	Year	M:F Ratio
Kleinsasser <sup>(24)</sup>	1982	3:1
Bruce Bengamin <sup>(25)</sup>	1985	4:1
Bouchayer	1988	1:4

## **AETIOLOGY:**

### **1) Vocal abuse:**

Benign lesions are caused due to faulty use of voice. Vocal Nodules are common in teachers, singers, vendors. Contact ulcers are commonly seen in pop singers, politicians and radio commentators. Polyps originate from micro rupture in the vocal ligaments due to forced use of voice (Harma 1975). Excessive vocal use, faulty vocal technique and unfavourable environment of work predisposes to polyp formation (Kambic 1981).

According to Walter and Larsen<sup>(26)</sup> (1984) the most common cause of hoarseness in childhood is vocal abuse.

### **2) Smoking:**

Though mainly associated with malignancy, it is also associated with formation of vocal cords nodules<sup>(27)</sup>, chronic inflammation due to smoking leads to vocal cord polyp<sup>(28)</sup> formation. Toriya<sup>(29)</sup> (1979) found significant association between smoking and development of sessile polyps and polypoidal changes in vocal cord.

### **3. Gastro esophageal reflux :**

Morning hoarseness is a frequent complaint as is chronic cough that is worst at night. Bad taste in the morning, excessive phlegm,



scratchy or dry throat irritation which is worse in the morning, habitual throat clearing, are some of the other symptoms. In advanced cases vocal cord inflammation occurs particularly in posterior commissure causing posterior laryngitis . It is also implicated in the development of granuloma and subglottic stenosis <sup>(30)</sup>.

Feder and Michell (1984) received series of 27 cases and found that granulomas were caused by hyperfunction, hyperacidity and intubation.

#### **4. Alcohol:**

Exposure to the combination of tobacco and alcohol increases the risk by approximately 50%. Specially in the supraglottic areas.<sup>(31)</sup> Alcohol also aggravates the gastro esophageal reflux.

#### **5. Miscellaneous factors:**

Allergy, infection and chronic sinusitis have all been implicated to causes chronic laryngitis.

#### **SYMPTOMS:**

Majority of laryngeal lesions present with some kind of voice disorder. It can be mild dysphonia to complete aphonia. Dysphonia in common parlance is hoarseness. In Epstein's (1957) <sup>(32)</sup>. study all the

366 cases of benign laryngeal lesions had some kind of voice problem.<sup>(33)</sup>

Other associated symptoms include vocal fatigue and reduced vocal range. Aphonia is rare as the patient usually reports earlier. Dyspnoea, cough, soreness and haemoptysis are some of the other symptoms.

### **VOICE DISORDERS:**

Benign lesions can cause wide range of voice disorders varying from mild dysphonia to total aphonia. Change of voice affects different individuals differently. A classification has been proposed by James A Kauffman<sup>(34)</sup> depending on the levels of vocal usage.

**Table 5**

Level I	Elite Vocal performer	Singers, actors
Level II	Professional voice user	Lecturers, clergyman
Level III	Non vocal professional	Doctors ,lawyers, teachers.
Level IV	Non vocal non professional	Clerk, labourer

This classification helps in planning treatment protocol.

**Table 6**

**Common Vocal Complaints**

Dysphonia	:	Abnormal voice
Aphonia	:	Loss of voice
Diplophonia	:	Double tone
Dysresonance	:	Loss of resonance
Vocal fatigue	:	Worsening of voice with prolonged use
Voice breaks	:	Pitch specific dysphonia
Reduction in vocal range	:	Reduced dynamic range
Odynophonia	:	Painful phonation

**MANAGEMENT**

The management of the lesions includes relevant investigation and required treatment.

**INVESTIGATIONS:** The investigations are done to pinpoint and confirm the diagnosis and select the treatment modality.

**COMPUTED TOMOGRAPHIC SCAN:**

Because of its ability to demonstrate the soft tissues and bone densities in the same image, the CT scan has improved the diagnostic

ability to a great extent. The selective uptake of contrast by tumours helps it to differentiate from other soft tissue structures. The extension into potential spaces and neck are diagnosed early. The draw back of CT scan is its inability to distinguish between tumour and infective mucosal congestion and difficulty in obtaining coronal images.

Typical radio logical signs of common condition are—

Tuberculosis	- Turban epiglottis, Irregular mucosa
Fungal diseases	- Heterogenous mass
Subglottic haemangioma	- Asymmetrical soft tissue density
Papilloma	- Irregular soft tissue excrescences in the glottis and subglottis
Chondroma	-Mottled calcification within a sharply defined mass

### **MAGNETIC RESONANCE IMAGING:**

Shows better soft tissue delineation but less effective on bony defects. The advantages are, improved soft tissue definition multiplanar imaging, and lack of ionising radiation. The use of coronal and sagittal planes has enhanced the ability to identify the intrinsic musculature, thereby increases recognition of subtle tumour extensions previously not identified . Disadvantages are (i) cost (ii) Failure to

identify recurrence after radiotherapy (iii) Poor quality images in debilitated patients. The Gadolinium enhanced MRI gives vascular anatomy of lesions like neurofibroma. The neurofibroma has significant enhancement like other vascular lesions due to abnormally permeable vessels causing leak of contrast into extra vascular tumour bed falsely mimicking vascular lesion.

**BIOPSY:** Final conclusion of non malignant lesion is confirmed by biopsy. It can be taken by endoscopy i.e. through flexible fibre optic scope or rigid scope. The biopsy can be taken as incisional, excisional or punch biopsy. Rarely open excision biopsy is needed.

#### **ASSESSMENT OF VOCAL CORD MOBILITY:**

##### **FIBRE OPTIC VIDEO LARYNGOSCOPY:**

This is most technically advanced. The entire anatomy including the movement of the vocal cord can be visually by asking the patient to phonate as it is done only under local anaesthesia.

The advantages of fibre optic video laryngoscopy are

- 1) It is an office procedure
- 2) Done under local anaesthesia
- 3) It is least traumatic
- 4) Can be used in patients with neck stiffness & trismus.

- 5) High resolution magnified change enable easy visualization of minute details.
- 6) Instrumentation can be done through separate channel.
- 7) Permit good documentation and teaching facilities.

## **STROBOSCOPY :**

Next important technical advancement.

According to Talbot's law, retina is able to resolve only 5 images/second. Therefore images which are presented to the retina for less than 0.2 seconds are fused together by the ocular cortex to produce apparent motion.

Principle: The laryngeal examination is done with flashes of light while patient phonates and the frequency of flashes are adjusted to the note of phonation. If the two are synchronized than the vocal cords appear to be in standstill. By slightly reducing the frequency of flashes, the delayed image of vocal cord motion appears as a slow motion film <sup>(35)</sup>.

Advantages: Detection of vibratory asymmetry,

- Detection of structural abnormalities such as small masses, scars and other conditions not visible by ordinary light
- Attaching a video camera the examination can be documented for teaching purposes

- Used for motivating the patient.
- Shows abnormal movements of certain segments.

By using stroboscope the examiner can observe how small lesions alter the normal laryngeal vibratory pattern. Hence, it helps the clinician determine the significance of the lesion. Ideally each patient should have baseline laryngeal stroboscopy performed. The finding can be compared with vocal fold appearance during dysphonic states.

### **ELECTROGLOTTGRAM:**

Electroglottography measures the efficiency of glottal closure by graphically recording the contact time of the vocal folds. It shows the opening and closing rates of the vocal folds not well visualised by stroboscopy.

Use two electrodes on the skin over thyroid lamina with passage of weak frequency voltage from one electrode to the other while the patient phonates. A transverse impedance of variation of electric current in phase with vocal cord vibration is noted and can be recorded also. This tracing is called electroglottogram and can be correlated with stroboscopic studies.

Advantages:

- Determines the presence of glottic vibration
- Fundamental period of vibration and tracing is reproducible. It reflects glottal condition more correctly in closed phase.

### **MANAGEMENT OF NON-MALIGNANT LESIONS:**

For all these non malignant lesions of larynx, surgery forms the main modality of treatment especially microlaryngeal excision or laser. Under these circumstances patient should be admitted and treated only in hospitals which has a microscope or laser with good postoperative care.

The modalities of treatment available are

- i) Conservative for lesions which can revert back to normal
- ii) Laser for lesions like vocal cord, polyp
- iii) Endoscopic excision particularly micro laryngeal excision
- iv) Open surgical technique like laryngofissure and lateral pharyngotomy.

### **LASER:**

Laser is an acronym that means Light Amplification by stimulated emission of Radiation. It is capable of generating an intense



almost parallel beam of electro magnetic energy of a given wavelength or colour.

In 1961 Johnson <sup>(36)</sup> developed Neodymium (Nd) doped Yttrium – aluminum Garnet (YAG) rod that emitted a laser near the infrared position of the spectrum. The argon laser was developed by Bennet <sup>(37)</sup> et al. The Carbondioxide laser in the far infrared portion was developed by Patel <sup>(38)</sup> et al.

### **Laser and Tissue Effects:**

#### **(Biophysics)**

The absorption and scattering of light through biologic tissue is dependent on many characteristics of the tissue. The amount of light absorbed by tissue will differ with the amount of an absorbing pigment or chromophore present. The thermal effect that light will have on tissue will be a function of the wavelength of the incident beam, and the absorption characteristic of tissue and chromophore present.

The extent of thermal damage is a function of the following parameters:

1. Absorption and scattering co-efficients at a particular wavelength. (scattering tends to be stronger in the presence of ion absorption).

2. Power density of the optical radiation on tissue
3. Duration of exposure
4. Size of radiated area
5. Cooling component of the tissue i.e., blood flow

**Neodymium** : Yttrium Aluminum Garnet Laser popularly known as Nd - YAG Laser.

**Physical Properties:**

The YAG is a solid state laser that uses a crystal of Yttrium aluminum garnet and this is doped with 1% to 3% neodymium which serves as an actual lasing medium. The Nd YAG wavelength most commonly used is in the near infra red spectrum at 1,060 nm. Most devices available for medical application provide a power range up to 100W. The Nd : YAG was a real break through mainly due to its fiberoptic delivery system. Unlike Carbon dioxide laser, the YAG light can be channeled through a flexible quartz fibre approximately 2mm in diameter which can be passed through either a rigid or a flexible bronchoscope. Nearly all the problems that exist with the open fibre Nd : YAG laser have been solved with the advent of contact probes. Contact probes are synthetic sapphires that have optically shaped to focus the Nd : YAG energy into a small tip.

A major advantage is that it is a contact laser. The surgeon gets tactile feedback which is vital where ever dissection and depth of penetration has to be controlled.

### **MICRO LARYNGEAL EXCISION:**

This procedure is done under General anesthesia with a smallest possible size (size 7) endotracheal tube and a suspension laryngoscope<sup>(39)</sup> with a microscope. The microscope used is with a 40 cm objective lens. The type of laryngoscope used are Kleinsassers suspension laryngoscope, Dedo pilling anterior commissure microlaryngoscope, Lynch laryngoscope and Regur's laryngoscope to name a few.

Surgery is done with special micro instruments. This procedure was initially used only for small benign lesions but is now used extensively for bigger lesions.

**LARYNGOFISSURE:** Synonym Median Thyrodotomy- It is not a surgery by itself but an approach by which larynx is opened in midline for various surgical procedures.

Indications: - Benign tumours of larynx<sup>(40)</sup>

- Impacted foreign body at glottic level
- T1 lesions of laryngeal malignancy planned for surgery.

- Laryngeal stenosis, anterior glottic web.
- Laryngocoele<sup>(41)</sup>

But due to the development of better micro laryngeal technique, the indications are becoming more and more limited.

Anaesthesia:

Under G.A. with nasotracheal or orotracheal intubation.

Position:

Supine position with neck extended with a sand bag and head fixed with a ring.

Incision: A skin crease incision on the middle of the neck and sub platysmal elevation of flap to expose from hyoid bone to tracheal rings is done.

Procedure: Exposure of larynx – The external perichondrium is elevated on the affected side with a blunt elevation upto the oblique line. A sharp elevation of the inner perichondrium of not more than 6 mm is done from both upper and lower borders of thyroid lamina. A groove is made in the midline and with a small bone nibbling forceps the cartilage on the affected side is removed in piecemeal.

Opening of the larynx – A vertical incision is made on the midline of cricothyroid membrane from the upper border of cricoid cartilage to the

lower border of thyroid cartilage. This is continued upwards in the inner perichondrium of the thyroid upto 2.5 cms and larynx retracted with a blunt mastoid retractor.

Excision of the mass :

If the mass is too extensive then earlier planned partial laryngectomies need to be done. After excising the mass intoto, haemostasis is obtained by coagulation diathermy.

Closure:

All packing are removed, bleeding controlled and cough reflex obtained to check the hemostasis. With 1-0 chromic catgut external perichondrium is sutured closed in layers.

**Lateral Pharyngotomy** – This is an approach for pharyngeal and lateral laryngeal masses, particularly posterior pharyngeal wall tumors and benign tumors of larynx extending into the pharynx in the region of aryepiglottic folds.

Anaesthesia position and incision are same as in laryngo fissure approach.

Using cutting diathermy the muscles attached to the hyoid bone just above its lateral ends are divided. The mucosa is cut with scissors and the pharynx is entered from the vallecula.

The exposure of the pharynx can be improved by resecting a part of the hyoid bone. The incision is continued downwards for better exposure and retracted with a blunt mastered retractor. Once the mass is well exposed, it is excised in toto.

#### Repair:

After securing perfect haemostasis from the cut edges repair is planned. Usually primary closure is possible, if not mucosa from the posterior pharyngeal wall is mobilized and sutured. If there is a large defect, a myocutaneous flap like pectoralis major<sup>(42)</sup> or Beckenjian flap<sup>(43)</sup> can be used. Wound is closed in layers.

#### Postoperative Care and Complications:

Postoperative care for haemodynamic and airway management are taken care of. Additional care for tracheostomy is taken, which is weaned and decannulated by the 7<sup>th</sup> day. Oral feeding are started after 14<sup>th</sup> day while all sutures are removed by the 10<sup>th</sup> day.

Except routine postoperative complication special complications can occur due to sloughing of the graft, leak from the pharynx through a pharyngocutaneous fistula and later stenosis can occur.

## **AIMS AND OBJECTIVES**

The present study on non malignant lesions of larynx is undertaken to study—

- The incidence and distribution of cases according to age, sex, etiology etc.
- Common etiology for the different diseases
- Pathophysiology of the disease
- Various presentations of the disease
- Various diagnostic tools
- Modalities of treatment available

## **MATERIALS AND METHODS**

The study was conducted in the upgraded Institute of Otorhinolaryngology of Govt.General Hospital, chennai ,during May 2007 –Nov 2008. The hospital caters to a population of around 2.5 lakhs based in Chennai and also receives a number of referred cases from all district Govt. Hospitals.

Seventy patients with benign lesion of larynx were analysed. Only cases with persistent hoarseness for more than three weeks were selected .Benign lesions included neoplastic and non neoplastic lesions. All cases under went a thorough ENT examination. Once suspected the cases were examined under direct laryngoscope, fibreoptic laryngoscope and if needed microlaryngeal examination was also done. Benign non neoplastic lesions were treated by voice rest, laser, or excision biopsy and the biopsy results were confirmed.

The benign neoplastic lesions underwent direct laryngoscopic examination and routine x-rays. If needed CT scan was done. The deserving cases underwent open surgical procedures and management results were analysed. With all this information analysis is made to obtain the aim of the study.



**Inclusion and exclusion criteria :**

Inclusion criteria:

All patients with manifestations of benign lesions of larynx presented to OPD from May 2007 – Nov 2008.

Exclusion criteria:

- All lesions of larynx that showed features of malignancy were excluded.
- All critically ill patients were also excluded.

## Sex Distribution of Patients

### OBSERVATIONS

**Table 7**

Age Distribution of patients

Age Group	Male	Female	Total	Percentage
1-10 years	0	0	0	0%
11-20years	1	3	4	5.7%
21-30years	11	13	24	34.3%
31-40years	10	9	19	27.1%
41-50years	9	5	14	20%
51-60years	4	1	5	7.2%
Above 60years	4	0	4	5.7%
Total	39	31	70	100%

The lesions are found in all age groups but according to our study it is commonest in the third and fourth decade of life.

**TABLE 8**

Diagnosis and Sex Distribution

Types	Male	Female	Total
Non-Neoplastic	34	23	57
Neoplastic	5	8	13
Total	39	31	70

The male female ratio is almost 1.4:1 in non-neoplastic lesions No definite sex preponderance for the non neoplastic lesions.

The male female ratio is 1:1.6 in neoplastic lesions in our study. No significant sex preponderance seen in neoplastic lesions also.

**TABLE 9**

Occupation Distribution in patients

Occupation	Female	Male	Total	Percentage
House Wife	13	0	13	18.6%
Students	3	1	4	5.7%
Manual Labourers	0	22	22	31.4%
Teachers	6	5	11	15.7%
Clerk	6	9	15	21.4%
Singer	3	1	4	5.7%
Lawyer	0	1	1	1.42%

In our study the commonest occupation was manual labourers followed by clerks and house wives. Traditionally these lesions have been associated with professions like lawyers, Priests and Singers. It is now however proved that these lesions can occur in any individual who are talkative, and have a tendency for voice abuse. Our hospital caters to the middle class and lower socio economic group. So an important point to be considered is that only housewives and labourers were our patients. Hence the percentage of professional voice users in our study is less.

**TABLE 10****Disease Distribution**

Disease distribution in male and female

Diagnosis	Female	Male	Total
Vocal Nodule	7	5	12
Vocal Polyp	4	12	16
Vocal Cyst	6	1	7
Recurrent Respiratory Papilloma	4	0	4
Intubation Granuloma	0	1	1
Laryngocoele	0	1	1
Amyloid	0	1	1
Reinke's Oedema	0	1	1
Sulcus Vocalis	0	1	1
Adult Papilloma	4	3	7
Haemangiopericytoma	0	1	1
Tuberculous Laryngitis	0	1	1
Laryngeal stenosis/stricture	4	6	10
Ventricular cyst	1	1	2
Keratosis			4
Schwanoma	0	1	1
Total	31	39	70

Though these disease have no definite sex prediction Our studies demonstrates that Vocal nodules are slightly commoner in Women. Whereas Vocal polyps are commoner in men, Vocal cyst have female predominance . Recurrent Respiratory Papilloma is common in females. Only papilloma of adult onset was found to be equal among both sexes.

### **Symptom distribution**

**TABLE 11**

#### **Symptoms Distribution of Patients**

	Hoarseness	Vocal fatigue	Aphonia	Reduced Vocal range
VN	<b>12</b>	<b>6</b>	<b>0</b>	<b>6</b>
VP	<b>14</b>	<b>10</b>	<b>0</b>	<b>8</b>
VC	<b>5</b>	<b>5</b>	<b>0</b>	<b>5</b>
GR	<b>1</b>	<b>0</b>	<b>0</b>	<b>1</b>
RRP	<b>4</b>	<b>4</b>	<b>2</b>	<b>3</b>
Pap	<b>7</b>	<b>5</b>	<b>2</b>	<b>3</b>
Haem	<b>1</b>	<b>1</b>	<b>0</b>	<b>1</b>
LR	<b>1</b>	<b>1</b>	<b>0</b>	<b>0</b>
Amy	<b>1</b>	<b>1</b>	<b>0</b>	<b>1</b>

**Hoarseness** is the commonest symptom and often the first symptom which brings the patient to the clinician.

Most of these patients are talkative and have a hyperkinetic personalities and inability to talk as previously and feeling of tiredness associated with talking is referred as **Vocal fatigue**, which was found in about 45% of cases.

**Reduced Vocal Range** was also present in about 40% of cases

**Aphonia** Total loss of voice is rare

**Risk factors distribution:**

**TABLE 12**

**Voice Abuse**

Pathology	Numbers
Vocal Nodule	12
Vocal Polyp	16
Vocal Cyst	4
Papilloma	1
Sulcus Vocalis	1
Recurrent Respiratory Papilloma	0
Intubation Granuloma	0

Amyloidosis	0
Reinke's Oedema	1
Tuberculous Laryngitis	0
Total	35

Vocal abuse – describes vocal behaviors associated with normal voice quality that often leads to vocal fold abnormalities and resultant dysphonia.

Vocal misuse refers to dysphonia caused by abnormal function of anatomically normal structure. Though patients often are not able to distinguish between the two. In our study it was the commonest risk factor which was found in almost 50% of the cases.



**TABLE 13****Smoking & Alcohol**

Pathology	Smoking	Alcohol	Smoking & Alcohol
Vocal Nodule	4	3	3
Vocal Polyp	7	5	5
Vocal Cyst	1	0	0
Papilloma	1	1	1
Sulcus Vocalis	0	0	0
Recurrent Respiratory Papilloma	0	0	0
Intubation Granuloma	0	0	0
Amyloidosis	0	0	0
Reinke's Oedema	1	0	0
Tuberculous Laryngitis	0	0	0
Total	14	9	9

All patients who gave a positive history for smoking and drinking were only males. Total number =21. Total number of patients with positive alcohol intake =9, Smokers –14 (Patients who smoked either Beedi or cigarette).

Smoking has been associated with decreased mucociliary clearance making the patients more prone for these lesions.

**TABLE 14**  
**LARYNGO-PHARYNGEAL REFLUX**

Pathology	Numbers
Vocal Nodule	5
Vocal Polyp	9
Vocal Cyst	1
Papilloma	2
Sulcus Vocalis	0
Recurrent Respiratory Papilloma	0
Intubation Granuloma	1
Amyloidosis	0
Reinkes Oedema	0
Tuberculous Laryngitis	0
Total	18

Criteria for patients who gave history of symptoms suggestive of Acid peptic disease are- Heartburns, dyspeptic symptoms- bloating, frequent burping, burning sensation in the abdomen relieved or aggravated while taking food.

Some patients can have significant reflux with no abdominal or chest complaints. This type is known as Extra Oesophageal or laryngo pharyngeal reflux. The symptoms are often frequent throat clearing, mild dysphonic, cough, foreign body sensation in the throat, vocal fatigue and decreased singing range.

Almost 25% of the patients gave history of some of these complaints.

#### **TABLE 15**

#### **ENDO-TRACHEAL INTUBATION**

Pathology	Numbers
Vocal Nodule	0
Vocal Polyp	0
Vocal Cyst	0
Papilloma	0
Sulcus Vocalis	0
Rec. Respiratory Papilloma	0

Intubation Granuloma	1
Amyloidosis	0
Reinke's Oedema	0
Tuberculous Laryngitis	0
Total	1

This history of endotracheal intubation was present in only two of our cases, who suffered from intubation granuloma.

### **Types of lesions observed**

#### Vocal Cord Polyp:

The most common lesion observed was vocal polyp (22.85%). Ten of them were pedunculated (62.5%) and six (37.5%) were sessile. Two of them were of angiomatous type. All of the polyps were visualized videoendoscopically and MLE done. No recurrence was observed.

#### Vocal Cord Nodules:

The second most common lesion observed was Vocal Nodule (17.14%). The lesion ranged from 1-4mm in size. Eight of them were less than 2mm in size and 4 of them were less than 1mm in size. Nine

were bilateral and three were unilateral in size. Under video endoscopic control, all were excised. No recurrence was observed.

#### Retention Cyst:

A total of seven cases of cyst were seen in which six cases of unilateral cysts were observed over the vocal cords. In one case epiglottic cyst was present. All were treated by excision under videolaryngoscopic guidance . No recurrence was noted.

#### Papillomas:

Seven cases of Papillomas were observed in this study (11.1%). Four were seen in females and three in male. It is the common true neoplasm observed . In two cases the mass was seen in the supra glottic region while in the other five, the lesions were seen occupying the vocal cords. In all cases under video endoscopic control, MLE was done. Only one case of recurrence was observed after a follow up of 8-6 months.

#### Recurrent Respiratory Papillomatosis:

Four cases were seen. All patients were adult females .Repeated micro laryngeal excision has been done. But recurrence were seen in two cases. Tracheostomy was done in two cases.

### Vocal Granuloma:

One case was observed. Patient had Endotracheal Intubation. MLE was done under endoscopic control. No recurrence was noted up to three months follow up.

Laryngeal Rhinosporidiosis :No case of Laryngeal Rhinosporidiosis noted in the study period .

## **DISCUSSION**

The present study on benign lesion of the larynx is compared with a previous study.

**TABLE 16**

Study	Non-Neoplastic	Neoplastic
Shaw1979	1300(86%)	205(14%)
Present study 07-08	57(81.43%)	13(18.57%)

The ratio of non -neoplastic to neoplastic lesion remains almost same as to the study done by Shaw 1979.

**TABLE 17**

### **Age Distribution**

Study	Age in years
M.Neilson	31-78years
Present study 07-08	11-70years

As discussed earlier, these lesions involve all the age groups commonest being third to fifth decade. But Recurrent Respiratory Papillomatosis is commonest in the paediatric age group.

**TABLE 18**

**SEX DISTRIBUTION**

Author	Year	Male :Female
Kleinsasser	1982	3:1
Mark Bouchayer	1998	1:4
Present Study	07-08	1.2:1

The Male : Female ratio in the study done by Kleinsasser was 3:1. While in the study done by Mark Bouchayer, the ratio was 1:4. But in our study the ratio was 1.2:1

**TABLE 19**

**Types Of Lesions**

**Vocal Nodules**

	Lancer et al	Present Study
Adult female	30 (68%)	7(58.3)
Children	11 (25%)	Nil
Male	3 (7%)	5(41.7)

In 1988 Lancer et al conducted a study on vocal nodules. In that he found that middle-aged women were most commonly affected. The pre-disposing factor in all cases was Vocal Abuse. In our study none of the cases that were treated with MLE had a recurrence during the following period of three months.

**TABLE 20**

**Vocal Cord Polyps**

	Jones SR et al	Present Study
Age Group	30-50years	22-55years
Males	76%	75%
Smokers	85%	56%

Our study shows male predominance in vocal polyps which is similar to the study conducted by Jones SR et al.

**TABLE 21**

**Laryngeal Cysts**

Comparison of the percentage of cysts among the benign lesion in some previous studies

Study	Percentage
Robinson	6.08%
Present Study	2.85%

In our study, the Laryngeal Cysts were not very common. The male female ratio was 1:1.



**TABLE 22**

**Vocal Granuloma:**

Study	Percentage
Shaw	2.12%
Present Study	1.42%

Vocal Granuloma is not very common in our study. However, both these patients had a preceding history of endotracheal intubation.

**DIAGNOSTIC TOOLS**

Besides Indirect laryngoscopic examination in the Out patient department, all the patients were examined with video laryngoscopy after spraying with 4% xylocaine. The entire anatomy of the larynx including the movement of the vocal cords could be studied after asking the patient to phonate. It is an office procedure, causing minimum discomfort to the patient.

The next important and useful investigation is stroboscopy. But it is not available in our institution and hence was not done. It was not considered cost effective to send the patient to another center for this procedure alone.

Computed Tomography was not done routinely for the patient. Only for two patients of schwannoma and hemangiopericytoma where the appearance was deceptive, a Computed Tomography of the neck was done.

Biopsy was done for large number of cases. In some cases it was done preoperatively to confirm the diagnosis as in case of tuberculous laryngitis. In other cases biopsy was done per operatively.

Xray neck soft tissue lateral view is needed for certain cases where any obstruction to the air passage is suspected. Since in our study large number of cases were small nodules or small polyps. Exposure to radiation was avoided, where ever it was felt that no extra information would be available.

**TABLE 23**

**Diagnostic Tools**

<b>Diagnostic Tools</b>	<b>No of Cases</b>
Videolaryngoscopy	70
X-ray neck soft tissue lateral view	20
Computed Tomography	8
Biopsy(pre-op)	15

Videolaryngoscopy gives clear picture of the pathology. It also allows for documentation of the cases. Hence it was done for all the cases.

Biopsy was done only in cases where the diagnosis had to be confirmed. In other cases where the presentation and appearance was classical it was avoided so as to save cost.

Magnetic Resonance Imaging and Electroglottogram is not routinely done for the non malignant lesions of the larynx. In our study also, it was not done.

**TABLE 24**

**Biopsy**

<b>Preoperative Biopsy</b>	<b>No of cases</b>
Tuberculous laryngitis	1
Amyloidosis	1
Papilloma	7
Keratoses	4
Hemangiopericytoma	1
Schwannoma	1
Total	15

**TABLE 25            -        Biopsy**

<b>Peroperative Biopsy</b>	<b>No of cases</b>
Recurrent Respiratory Papillomatosis	4
Angiomatous Polyp	2
Intubation granuloma	1
Hemangiopericytoma	1
Polyp	2
Total	10

## **MODALITIES OF TREATMENT**

**TABLE 26**

<b>Modalities of Treatment</b>	<b>No of cases</b>
Treated Conservatively only	6
Microlaryngeal excision	48
Open surgical procedures	5
Anti –TB drugs	1
Stricture release with silastic	10
<b>Total</b>	<b>70</b>

Management in our study was done with mainly by MLE. Large number of patients after treatment were discharged within a couple of days, while few others were discharged within a day thereby saving the number of man days lost. This is significant in an industrial set up.

Since Microlaryngeal excision was done under general anaesthesia, these patients were admitted to the hospital for more than 24 hours.

Laryngofissure and Lateral Pharyngotomy are open surgical procedures for very large masses which was done for five of our cases.

Conservative treatment of voice rest alone was sufficient for one case of Reinkes oedema. In all other cases after MLE patient was advised voice rest of about 10 days.

Anti Tuberculous treatment was given to the patient of Tuberculous laryngitis. Patient has completed the course and has no residual disease or recurrence.

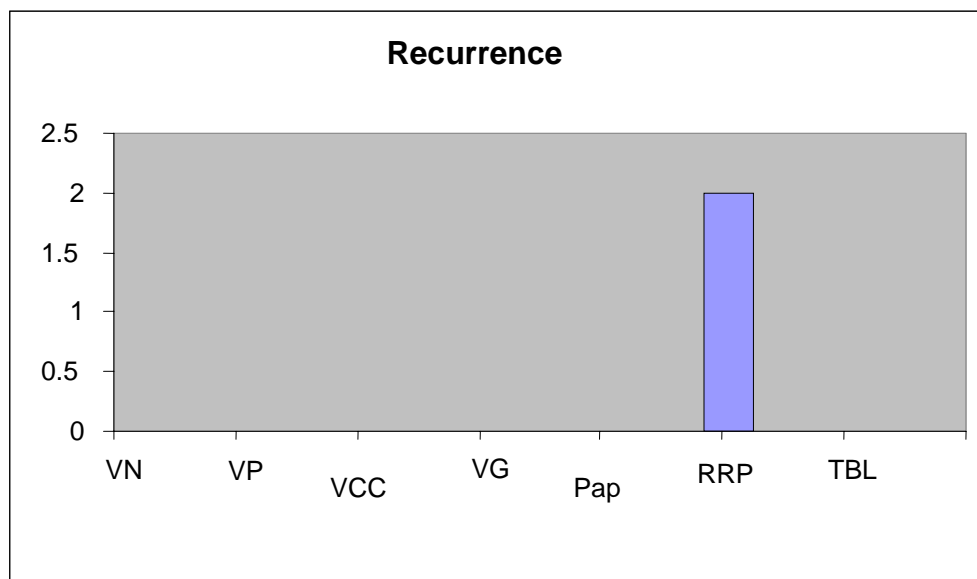
Patients who had associated symptoms of Acid Peptic Disease were given anti reflux medications. They were also advised certain life style modifications, like avoiding spicy meals and taking early dinner.

Patients who were smoking and taking alcohol regularly were explained the associated risks and were advised to discontinue.

### **Follow up**

All the cases were followed for a period of 6 months. At the end of 6 months much to our satisfaction none of the cases of vocal nodule, vocal polyp, vocal cord cyst and intubation granuloma reported with any recurrence. Two cases of Papilloma had to be taken up for second sitting.

However since Recurrent Respiratory Papillomatosis is known for recurrence both these cases were already prepared for repeated sittings. However Tracheostomy was avoided for both these cases.



## **Summary**

Benign lesions of the larynx include neoplastic and non-neoplastic lesions. They are broadly classified together because clinically they behave similarly. Any lesion affecting the larynx will cause a range of voice disorder. Voice disorders caused by benign lesions are correctable by surgery and voice rest and voice therapy in few cases.

In the present study 70 cases of benign lesions of the larynx were studied. Diagnosis was established by history clinical examination, routine blood examination and video laryngoscopy.

90% of the lesions observed were non-neoplastic lesions. The most common neoplastic lesion was papilloma. Only one case of haemangioma was noted. Vocal polyps were the most common non-neoplastic lesion (26.6%). Vocal nodules were the second most common lesion(22.2%), followed by Vocal Cyst. One case each of Sulcus vocalis, Reinke's edema, Amyloidosis and Tuberculous laryngitis was selected. Two cases of Vocal Granuloma(4.4%) were observed.

All lesions presented with some kind of voice disorder. 90% of the cases presented with hoarseness, while another 42% had vocal fatigue. 42% had reduced vocal range and 4.4% had aphonia.

Amongst the causative factors of vocal nodule, vocal abuse was a common constant cause. 57% of the affected patients were smokers while both the cases of vocal granuloma had a previous history of endotracheal intubation. The sex distribution of different lesions were different.

Maximum patients presented were in the third decade (26.8). This was followed closely by patients in the second, fourth and fifth decade.

Video laryngoscopy was the most specific modality of investigation. Computed Tomography, Magnetic Resonance Imaging and Electroglottogram were not considered necessary.

Microlaryngeal excision was done for majority of the cases followed by voice rest and anti reflux medicines in some cases. Results were very good thereby saving substantial number of man days.



## CONCLUSION

- 82% of the benign lesions observed were non-neoplastic type.
- 18% were true neoplastic lesions.
- Vocal polyp was the commonest benign non-neoplastic lesion.
- Papilloma was the commonest neoplastic lesion observed in adults while in children Recurrent Respiratory Papillomatosis was the commonest.
- In managing Recurrent Respiratory Papillomatosis minimal surgery to attain adequate airway and serviceable voice helped in preventing tracheostomy in both the cases.
- The most common symptom was hoarseness followed by an equal number of vocal fatigue and reduced vocal range.
- Vocal abuse was the predisposing factor in vocal nodules.
- Smoking was the major predisposing factor for vocal polyp.
- Previous history of endotracheal intubation predisposed to vocal granuloma formation.
- The most commonly done examination procedure in OPD was Indirect laryngoscopy.
- The most useful investigation of choice was video laryngoscopy.

- The most common modality of treatment was Microlaryngeal excision
- Laryngofissure approach is taken for larger lesions.
- The choice of approach depends upon the size of the lesion and the anatomical site involved.
- As far as mortality is concerned prognosis is good.
- Recurrent respiratory papillomatosis and trauma have poor prognosis as some morbidity is always there.
- All lesions when treated early and completely and followed up properly with voice rest have very good prognosis.

## PROFORMA

I.P./O.P.NO.:

Name:

Age:

Sex:

Occupation:

Address:

Level of vocal usage:

Presenting complaints:

History of present illness:

Change of voice	Yes	No	Duration
Hoarseness			
Breathiness of voice			
Vocal fatigability			
Voice breaks			
Reduction in voice range			
Double tone			
Aphonia			

Pain while talking

Pain while swallowing

Cough

Vocal abuse

Heart burn

Repeated sneezing

Nasal obstruction

Sore throat

Fever

Endotracheal intubation

Working in noisy surroundings

Past history : Pulmonary tuberculosis, Nasal allergy,  
Recurrent cold, Bronchial asthma,  
Hypertension, Diabetes mellitus

Personal history : Diet, Appetite, Sleep, Smoking, Alcohol  
intake, Bowel habits, Micturition.

Family history : Married/Unmarried No: of children

Socio-economic history: Low Middle High

## General Physical Examination

Appearance

Temperature

Pallor

Cyanosis

Jaundice

Pedal oedema

Lymphadenopathy

Thyroid enlargement

Pulse :

Blood pressure

Respiratory rate

Systemic examination:

Cardiovascular system

Respiratory system

Per abdomen

Central nervous system

Local examination :

Mouth and throat :

Palate

Pillars

Tonsil

Posterior pharyngeal wall

Indirect laryngoscopy

Base of tongue:

Valleculae:

Epiglottis:

Aryepiglottic folds:

Pyriform fossae:

Vestibular bands:

Vocal cords:

Sub glottis:

Diagram:

Ears: Rt.

Lt.

Neck:

EAC:

TM:

Investigations

Blood: Hb%

TC

DC

ESR

Urine:

Albumin

Sugar

Microscopic examination:

Video endoscopy

Date:

Patient Name:

Age/Sex:

MRD no.:

Diagnosis

Procedure:

Sitting:

Anesthesia: GA / LA

Procedure notes

Biopsy

Final Diagnosis:

## **Abbreviations**

RRP	-	Recurrent Respiratory Papillomatosis
TB	-	Tuberculous laryngitis
VN	-	Vocal Nodule
VP	-	Vocal Cord Polyp
VCC	-	Vocal cord cyst
LR	-	Laryngocoele
HM	-	Hemangiopericytoma
AMY	-	Amyloidosis
PAP	-	Papilloma
SV	-	Sulcus Vocalis
IG	-	Intubation Granuloma
RO	-	Reinke's oedema
SV	-	Sulcus Vocalis
RLN	-	Recurrent Laryngeal Nerve
VeC	-	Ventricular cyst
Sch	-	Schwanoma
LS	-	Laryngeal Stricture / Stenosis
KS	-	Keratosis



## MASTER CHART

S.no	Name	Age(Years)	Sex	I.P.No	Diagnosis
1.	Krubanithi	46	M	4503/07	Vocal cord polyp
2.	Irudhayam	42	M	17978/07	Vocal cord polyp
3.	Prabakaran	48	M	5495/07	Vocal cord polyp
4.	Muniyan	40	M	22046/07	Vocal cord polyp
5.	Jayalakshmi	24	F	2233/07	Vocal cord polyp
6.	Ayabkhan	22	M	5400/07	Vocal cord polyp
7.	Jamaludheen	39	M	31376/07	Vocal cord polyp
8.	Devaki	45	F	2729/07	Vocal cord polyp
9.	Sekhar	34	M	52375/07	Vocal cord polyp
10.	Lazar	45	M	52989/07	Vocal cord polyp
11.	Iniyen	29	M	38471/07	Vocal cord polyp
12.	Bhuvana	25	F	12335/08	Vocal cord polyp
13.	Shanmuga Sundaram	40	M	15932/08	Vocal cord polyp
14.	Selvaraj	46	M	23868/07	Vocal cord polyp
15.	Dilli Babu	55	M	34259/08	Vocal cord polyp
16.	Thilagavathy	33	F	17784/08	Vocal cord polyp
17.	Malar	23	F	17310/07	Vocal cord cyst
18.	Vasanthan	37	F	79360/07	Vocal cord cyst
19.	Banu	45	F	38506/07	Vocal cord cyst
20.	Paravatha devi	25	F	37896/07	Vocal cord cyst
21.	Manjula	27	F	38539/07	Vocal cord cyst
22.	Poonkodhi	26	F	33123/07	Vocal cord cyst
23.	Balayan	43	M	35820/08	Vocal cord cyst
24.	Ram	37	M	9934/07	Vocal cord nodule
25.	Manjula	28	F	3299/07	Vocal cord nodule
26.	Abdul sadhar	51	M	819081/07	Vocal cord nodule

27	Bhavani	24	F	4458/07	Vocal cord Nodule
28	Adhilakshmi	19	F	25756/07	Vocal cord Nodule
29	Lalitha	34	F	23360/07	Vocal cord Nodule
30	Jeri	35	M	18148/07	Vocal cord Nodule
31	Ganesan	63	M	39305/07	Vocal cord Nodule
32	Nagammal	35	F	75940/07	Vocal cord Nodule
33	Rathnam	47	M	4184/08	Vocal cord Nodule
34	Nagarathinam	28	F	45278/08	Vocal cord Nodule
35	Razia begum	34	F	29498/08	Vocal cord Nodule
36	Chellaiya	58	M	34122/07	Keratosis
37	Damodaran	69	M	57808/07	Keratosis
38	Paarvathi	23	F	47806/07	Keratosis
39	Govindhan	53	M	4160/08	Keratosis
40	Mahesh	18	M	76781/07	Intubation granuloma
41	Srinivasalu	27	M	61288/07	Laryngocoele
42	Dhanalakshmi	23	F	47501/07	RRP
43	Usha	43	F	49528/07	RRP
44	Ettiammal	40	F	35540/07	RRP
45	Mani	45	F	84803/07	RRP
46	Murugan	45	M	69273/07	Adult papilloma
47	Murugan	42	M	21845/07	Adult papilloma
48	Muniyammal	52	F	56620/07	Adult papilloma
49	Vijaya	20	F	9734/08	Adult papilloma
50	Anitha	33	F	15923/08	Adult papilloma
51	Chitra	45	F	21578/08	Adult papilloma
52	Karuppan	47	M	20768/08	Adult papilloma

53.	Akila	36	F	30084/07	Ventricular cyst
54.	Sekar	25	M	45235/07	Tuberculous Laryngitis
55.	Saravanan	27	M	84304/07	Hemangiopericytoma
56.	Sekar	40	M	38596/07	Amyloidosis
57.	Ramasamy	55	M	48752/07	Reinke 's edema
58.	Mani	45	M	84408/07	Ventricular cyst
59.	Akkthen	27	M	46901/07	Sulcus vocalis
60.	Appu	24	M	62939/07	Laryngeal stenosis / stricture
61.	Manikandan	28	M	13346/08	Laryngeal stenosis / stricture
62.	Ponnusamy	40	M	11788/08	Laryngeal stenosis / stricture
63.	Indra	32	F	37303/08	Laryngeal stenosis / stricture
64.	Parimala	21	F	8754/08	Laryngeal stenosis / stricture
65.	Hussain	26	F	1076/08	Laryngeal stenosis / stricture
66.	Ramasamy	65	M	21681/08	Laryngeal stenosis / stricture
67.	Ramasamy	65	M	48752/07	Laryngeal stenosis / stricture
68.	Suganthi	21	F	81364/07	Laryngeal stenosis / stricture
69.	Venkatesan	28	M	24061/08	Laryngeal stenosis / stricture
70.	Raja	57	M	29730/08	Schwanoma

## BIBLIOGRAPHY

1. *Watt – Boolsen, Blichert – Toft. M. Hense and Bobexg A. Late voice function after injury to the recurrent nerve Clinical Otolaryngology, 2,191-197*
2. *Goodman RM, Yergin BM, Landa JF et al : Relatonship of smoking history and pulmonary function tests to tracheal mucus velocity in non-smokers, ex-smokers and patients with chronic bronchitis. American Review Of Repiratory Diseases 117:205 – 214, 1978.*
3. *Nakai Y and others: Microvascular structure of the larynx. Acta Otolaryngol Suppl 486:254, 1991.*
4. *Holinger PH and Johnston K.C, Benign Tumours Of Larynx. Amn Otol 60 : 496, 1957.*
5. *Jones SR, Myers EN, Barnes L; Benign Neoplasms Of The Larynx, Otolaryngol Clinic of N. America 17:151, 1984.*
6. *JNG Evans, Scott Brown's Paedriatic Otolarygology Butterworth – Heinmann Co. 6/34/1 – 6/34/5.*
7. *Steinberg B, Topp WC, Scheinder and Abramson Laryngeal Papilloma virus infection during clinical remission. New England Journal Of Medicine 308 : 1262 – 1264.*

8. *Avidano MA, Singleton GT: Adjuvant drug strategies in the treatment of RRP, Head And Neck Surgery 112 – 197, 1995.*
9. *Batsaki's: Tumours Of Clinical And Pathological Considerations. Baltimore, 254 – 261.*
10. *Kleinsasser. O. Pathogenesis Of Vocal Cord Polyps Ann. Otl. 91:378 – 381.*
11. *AGD. Maran Laryngology And Head And Neck Surgery. Butterworth and Heinemann. Sixth edition 5/16/17 – 5/16/18*
12. *Micheau C, Lanchi P and Cachin Y : Relationship Between Laryngocoele And Laryngeal Carcinoma, Laryngoscope 88 : 680, 1978.*
13. *Thawley SE and Bone RC ; Laryngopyocoele, Laryngoscope 83 : 362, 1973.*
14. *Hjslet P, Moesgard – Neilson and KarlsloseM. Smoking cessation in chronic Reinkes edema.*
15. *Ohmanl, Tibbing, Oloffson J and Ericsson G : Esophageal Dysfunction in Patients with Contact Ulcer of Larynx. Ann, Otol, Rhinol, Laryngol 92 – 228 – 230, 1983*
16. *Auerbach : Laryngeal Tuberculosis. Arch Otol 44. 191 – 201, 1946.*

17. Hunter AM, Millar JW, and Wightman SJ. *The Changing Pattern of Laryngeal Tuberculosis. J Laryngol Otol* 95 : 393 – 395.
18. Stewart JP. *The Histopathology Of Benign Tumours Of The Larynx. J. Laryngol, 71: 718-729,1957.*
19. Brunings W Quoted by Myerson *Human Larynx. Springfield U.S.A.*
20. HJ. Shaw. *Scott Browne's Diseases of Ear, Nose, Throat. 4<sup>th</sup> edition, Butterworth Co. 421-508*
21. Eugene Rental, Michael Rental 1991. *Vocal Cord Injection Technique. OCNA 24:1145*
22. Marc Bouchayer and Gay Cornut. *Microsurgery for benign lesion folds. Ear Nose and Throat. 67:446-466 1988.*
23. Yates A. *Carbon dioxide laser enucleation of polypoid vocal cords .Laryngoscope 94:731- 736,1984.*
24. Kleinsasser O. *Pathogenesis of vocal cord polyps. Ann Otol 91: 378-381, 1982.*
25. Bruce Benjamin and Glen Croxson. *Vocal cord Granulomas Ann Otol 94:538-541*
26. Walter B. and Larsen B. *Hoarseness in children, follow up on no therapy, surgery, voice therapy alone or combined therapy. Otol Suppl 412: 40-42, 1984.*

27. *Myerson MC Smokers Larynx. A Clinicopathological Entity. Ann Otol.59: 541-546,1950.*
28. *Kubo R and Ohno M. Influence of smoking on the development of laryngeal polyps. Otol Tukoka 17: 22-125, 1971.*
29. *Toriya. A. A Statistical Study Of Polypoidal Lesions Of Vocal Folds related to cigarette smoking. 25:448-452, 1979.*
30. *Bam W, Harrington JW ,Thomas LE and Shaeffer SD. Head and Neck manifestations Of Gastroesophageal Reflux. Laryngoscope 93: 175-179.*
31. *Singer and Blom. An endoscopic for restoration of voice after laryngectomy. Ann. Otol. Rhin. Laryngol. 89 : 529-533,1980.*
32. *Epstein SS, Winston P. Ormerod FC. The Vocal Cord Polyp. J .Laryngol 71:673-688.*
33. *Jones SR. Myers EN and Barnes L. Benign Neoplasm of the Larynx. OCNA17:151, 1984.*
34. *James A Kaufman and Glen Issacson 1991. Spectrum of vocal dysfunction. OCNA 24:5 98-988.*
35. *Kitzing. Stroboscopy ; A Pertinent Laryngeal Examination. Journal of Otolaryngoloy 14,151-57*
36. *Johnson LF ; Optical Laser Characteristics Of Rare Earth Ions. In crystals J.Appl Physiol 1961 ; 34 ; 897 – 909.*

37. *Bennet WR, Faust WL, Mc Farlane RA et al: Dissociative Excitation Transfer and Optical Laser Oscillation in NeO<sub>2</sub> and ArO<sub>2</sub> discharges. Physiol 8 : 470 – 473.*
38. *Patel CKN, Mc Farlane RA, Fault WL: Selective Excitation Through Vibrational Energy Transfer Optical Maser Action in N<sub>2</sub> – Co<sub>2</sub> . Physiol Rev 13 : 617 – 619.*
39. *Parker R. Laryngoscopy, Microlaryngoscopy and Laser Surgery. In Rob and Smith's Operative Surgery, Head And Neck part 2, 4<sup>th</sup> edition, 451 – 463.*
40. *Booth JB and Birck HG, Operative Treatment and Post Operative Management Of Saccular Cyst and Laryngocoele. Arch Otol 107 : 500, 1981.*
41. *Benign tumors of the neck, Comprehensive Management Of Head And Neck Tumors Vol II. Chap 55 1350 – 1385.*
42. *Stell and Maran's Head and Neck Surgery 4<sup>th</sup> edition 124 – 126.*
43. *Gillies HD and Mullard DR: The Principles And Art Of Plastic Surgery, Little Brown and Co. Boston.*

**THE END**