FUNCTIONAL OUTCOME OF PATELLA FRACTURE FIXATION WITH HIGH-RESISTANCE SUTURE MATERIAL

Dissertation Submitted to

THE TAMIL NADU DR. MGR MEDICAL UNIVERSITY, CHENNAI- 600032.

In partial fulfillment of the regulations for the Award of the degree of

M.S. (ORTHOPAEDIC SURGERY)
BRANCH –II

GOVERNMENT KILPAUK MEDICAL COLLEGE
CHENNAI - 600 010.

MAY 2018

CERTIFICATE

This is to certify that the dissertation entitled **"FUNCTIONAL OUTCOME OF PATELLA FRACTURE FIXATION USING HIGH RESISTANCE SUTURE MATERIAL"** is a bonafide work done by **Dr.R.JAY GANESH, M.S. ORTHOPAEDIC SURGERY** BRANCH-II at Government Kilpauk Medical College. Chennai - 600010, to be submitted to The Tamilnadu Dr.M.G.R. Medical University, Chennai – 32, in partial fulfillment of the university rules and regulations for the award of M.S.Degree Branch-II Orthopaedic surgery, under my supervision and guidance during the period from May 2015 to May 2018

Prof.Dr.S.Veera Kumar,
M.S.Ortho.,
Professor,
Department of Orthopaedics,
Kilpauk Medical College,
Chennai – 600010.
(Guide for the study)

Prof.Dr.S.Senthil Kumar,
M.S.Ortho., D. Ortho.,
Professor & HOD,
Department of Orthopaedics,
Kilpauk Medical College,
Chennai – 600010.

Prof.Dr.P.VASANTHAMANI.,
M. D., D.G.O., MNAMS., DCPSY., MBA.
DEAN,
Govt. Kilpauk Medical College, Chennai – 600010.

DECLARATION

I solemnly declare that this dissertation titled **"FUNCTIONAL OUTCOME OF PATELLA FRACTURE FIXATION USING HIGH-RESISTANCE SUTURE MATERIAL"** is a bonafide work done by me at Govt. Kilpauk Medical College, during the period from May 2015 to May 2018, under the guidance and supervision of my Unit Chief **Prof.Dr.S.VEERA KUMAR, M.S.Ortho**., Professor of Orthopaedic Surgery, Govt. Kilpauk Medical College and Hospital, Chennai-10.

This dissertation is submitted to "**THE TAMILNADU DR MGR MEDICAL UNIVERSITY**", Chennai in partial fulfilment of regulations for the award of degree of **M.S.DEGREE BRANCH II in ORTHOPAEDIC SURGERY**.

Place: Chennai

Date : **Dr. R. JAY GANESH**

CERTIFICATE - II

This is to certify that this dissertation work titled **"FUNCTIONAL OUTCOME OF PATELLA FRACTURE FIXATION USING HIGH-RESISTANCE SUTURE MATERIAL"** of the candidate **Dr.R.JAY GANESH,** with registration Number **221512154** for the award of **M.S. DEGREE** in the branch of **ORTHOPAEDIC SURGERY**. I personally verified the urkund.com website for the purpose of plagiarism Check. I found that the uploaded thesis file contains from introduction to conclusion pages and result shows **7%** percentage of plagiarism in the dissertation.

Guide & Supervisor sign with Seal.

URKUND

Document	Functional outcome of patella fracture fixation with high-resistance suture material.docx (D31266557)
Submitted	2017-10-13 00:27 (+05:0-30)
Submitted by	Jay Ganesh R (kveimy@gmail.com)
Receiver	kveimy.mgrmu@analysis.urkund.com
Message	Show full message

7% of this approx. 23 pages long document consists of text present in 4 sources.

ACKNOWLEDGEMENT

I express my utmost gratitude to **Prof.Dr.P.VASANTHA MANI**, **M.D., D.G.O., MNAMS., DCPSY., MBA.,** Dean, Kilpauk Medical College, Chennai, for providing me an opportunity to conduct this study and for permitting me to use the college and hospital facilities for my study to the full extent.

I would like to express my sincere thanks and gratitude to my beloved Chief, **Prof. Dr. S.VEERA KUMAR**, **M.S. Ortho**, Professor, Kilpauk Medical College, Chennai -10, who allotted me this topic and kindly accepted to be my guide for the study and offered valuable suggestions to make this study a successful one.

I would like to express my gratitude and reverence to my beloved Head of the Department, **Prof.Dr.S.SENTHIL KUMAR**, **M.S. Ortho., D. Ortho**., whose guidance and help has elevated me to this level, to conduct this study successfully. I sincerely thank him for the expert guidance and constant encouragement to conduct this study.

I wish to express my sincere gratitude and heartfelt thanks to **Prof.R.PRABHAKAR, M.S.Ortho.,** and **Prof. R. BALACHANDRAN, M.S.Ortho., D.Ortho., DNB Ortho.,** for their encouragement.

I am deeply indebted to my beloved Assistant Professors **Dr.G.Mohan, M.S.Ortho, Mch Ortho., DNB.Ortho, MNAMS**, **Dr.S.Makesh RAM, M.S. Ortho., D.Ortho, DNB Ortho**., **Dr.S.Prabhakar, M.S.Ortho., D.Ortho., DNB Ortho**., **Dr.A.Anand**, **M.S.Ortho**., **Dr.M. Arunmozhi Rajan. M.S.Ortho, Dr. R. Prabhakar Singh. M.S. Ortho, Dr. R. Karu Shanmuga Karthikeyan. M.S.Ortho, Dr. R. Manoj Kumar. M.S. Ortho**, for not only guiding me in every aspect of this study, but also for the whole of my postgraduate residency through their valuable advice and guidance.

I wish to express my thanks to postgraduate colleagues, staff members, and theatre staff for the help they have rendered.

I am eternally grateful to my father and my mother for their unfaltering support.

Lastly, I thank all the patients who whole heartedly consented for the surgery for the betterment of science without whom this study would not have been possible.

CONTENTS

INTRODUCTION

Patella fractures account for 0.5% to 1.5% incidence of all bone fractures.[1,2] Transverse fracture pattern being the commonest pattern disrupts the knee extension mechanics due to displacement of fragments.[3] Joint incongruity or the displacement >3mm warrants surgical management.[4] Conservative management can be tried in case of minor displacements or undisplaced fractures with restriction to mobilisation. The gold standard procedure yet is osteosynthesis with Kirschner wires (K-wires) and tension band wiring, obtaining good functional outcomes.

High number of implant related complications occurred in most cases reaching upto 40%.[63] Delayed wound healing, postoperative adhesions, knee stiffness, and prolonged work disability are all associated complications.[5,6]K-wire usage produced wire breakage and migration, with subsequent painful and prominent hardware in the knee.[7]

To reduce these aforementioned complications, newer techniques were pursued in the following years. K-wires were replaced by cannulated screws with excellent results.[8] In addition, cerclage wiring was substituted with other implants, without invalidating the figure-of-eight tension band construct.

High-resistance sutures came into light in this scenario by reducing the previous hardware related complication associated both to K-wires or cannulated screws.[70] Plate fixation has also shown promise in patellar fractures.[9]

AIM OF THE STUDY

The aim of this study is to evaluate clinical and radiological functional outcome of patients who underwent open reduction and internal fixation (ORIF) using a novel trans-osseous tunnel technique with a high resistance non-absorbable suture material.

ANATOMY

ANATOMY OF PATELLA

The patella bone is unique in nature because it's a sesamoid bone and also the largest sesamoid in the body. The proximal border forms the base and the distal or the inferior rounded border forms the apex.Patella is situated below the fascia lata embedded in the tendon of the rectus femoris.[10]The articular cartilage covers the proximal part of the patella only and not the distal part. Patella ossification starts in the 2nd year of life.[10]Odd facet is a small medial area situated along the medial border of the patella and is defined by the second vertical ridge. The lateral facet is usually the largest of all the facets but there is considerable variation in the size and shape of patellar facets.

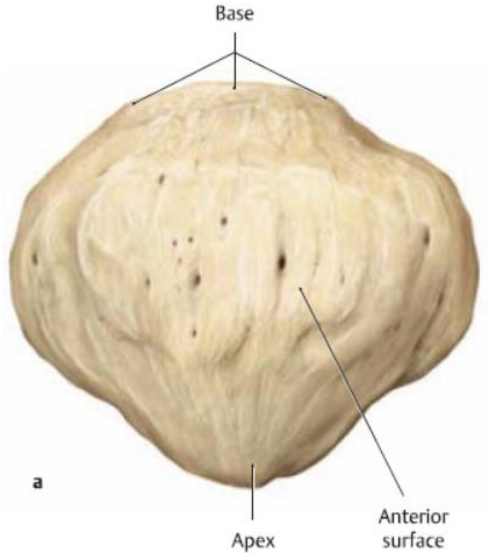

Fig. 1. Anterior surface of the patella.

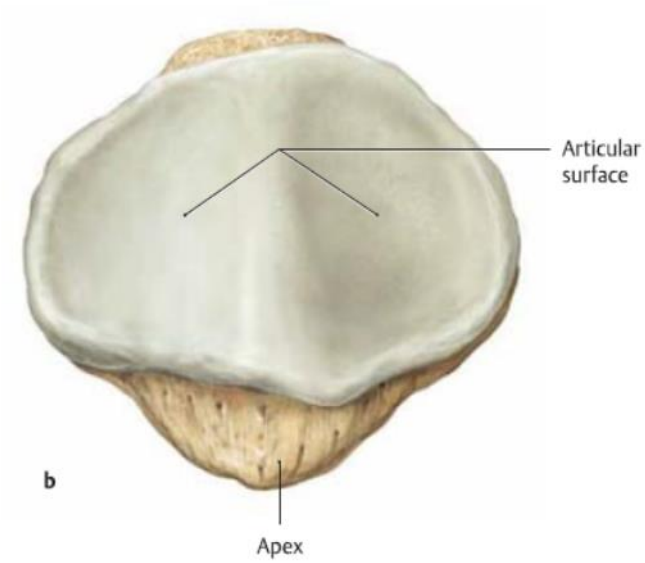

Fig. 2. Posterior (articular) surface of the patella.

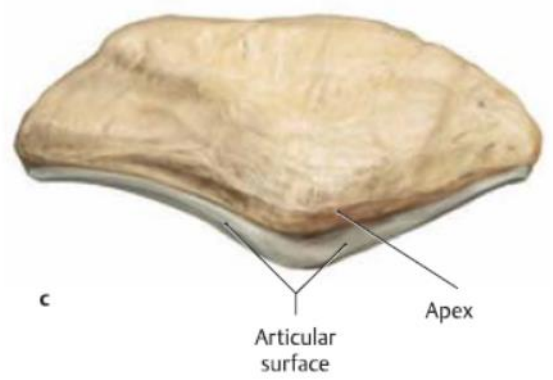

Fig. 3. Inferior surface of patella.

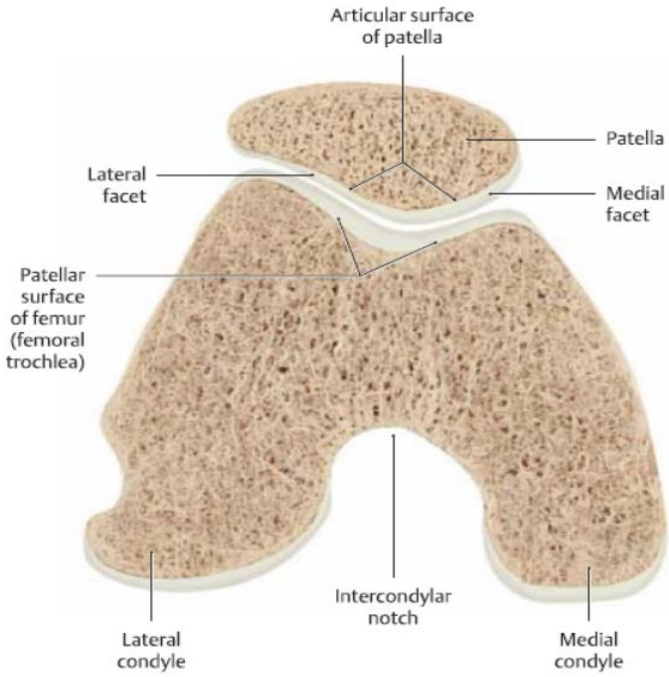

Fig. 4 Cross-section through the femoral condyles and the patella.

Wiberg[11]classification of types of patella

- Type I: Medial and lateral facets are both concave and approximately equal in size
- Type II: The medial, concave facet is smaller than the lateral facet
- Type III: The medial, convex facet is smaller than the lateral facet

Varying degrees of medial facet dysplasia were further defined by Baumgartl[12]

Type II and III patellas have a small, flat medial facet,

- Type IV: patellas have a small, steeply sloped medial facet with a medial ridge.
- Type V: No medial facet or vertical ridge.[12]

Fig.5. Anteroposterior view of a bipartite patella.

BLOOD SUPPLY OF THE PATELLA

The vast array of dorsal plexus vessels supply the patella. The vascular supply has networks both inside and outside the bone. In total, six separate arteries form the vascular plexus, maintain the vascularity of the fractured fragments even in the setting of comminution.[13,14] The superior most geniculate artery begins at the level of Hunter's canal from the Superficial femoral artery. There current anterior tibial arterybegins distal to the proximal tibiofibular joint from the anterior tibial artery. The superior aspect of the plexus lies superficial to the quadriceps tendon, while the inferior aspect lies below the patellar tendon in the fat pad. Scapinelli[13] concluded that the primary intraosseous blood supply of the patella bone enters the middle third of the anterior aspect of body and the distal pole, and the perfusion occurs in a distal to proximal direction. The retrograde blood flow is an important reason for bone necrosis after an injury to the patella especially fractures. The inferior division of the medial and lateral geniculate arteries supply the patellar tendon through its deep branches. The superficial surface of the patellar tendon is nourished by retinacular vessels that arise from the inferior medial geniculate and recurrent tibial arteries.[14]

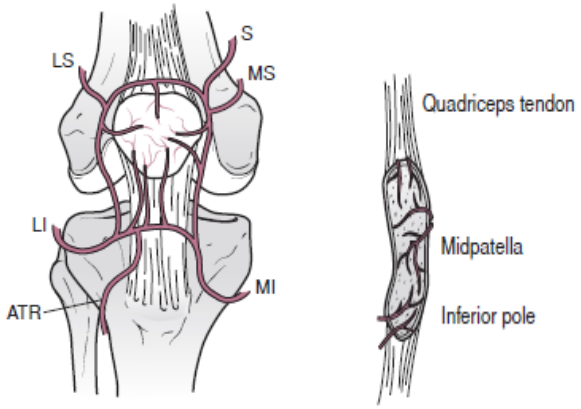

Fig. 6. Arterial blood supply of the patella.

A: Extraosseous geniculate arterial system. S, supreme geniculate; MS, medial superior geniculate; MI, medial inferior geniculate; ATR, anterior tibial recurrent; LI, lateral inferior geniculate; LS, lateral superior geniculate. B: Intraosseous arterial supply.

Soft Tissue Anatomy of the Patella:

The quadriceps tendon contains the patella within itself firmly embedded. The extensor mechanism constitutes the medial and lateral patellar retinaculum, quadriceps muscle tendon, patella bone, and patellar tendon. The vastus lateralis, vastus medialis, rectus femoris, and vastus intermedius altogether form the quadriceps muscle. The vastus lateralis begins in the femur and ends on the patella at a 30-degree angle relative to the longitudinal axis of femur. The lateral part stays on the lateral aspect of the patella which finally ends in the lateral retinaculum and the

iliotibial tract.[10,15] The superolateral aspect of the patella provides the insertion site for the medial part of the vastus lateralis. Femoral nerve supplies the vastus medialis. Intervening fascia seperates the muscle into 2 parts. The vastus medialis longus (VML) and the vastus medialis obliquus (VMO) are the two parts. Their angle of insertion onto the patella varies considerably with the latter having a more oblique course of insertion. The rectus femoris muscle occupies the mid-portion in the quadriceps muscle complex. The rectus fibers run at an angle of 7 to 10 degrees medial to the long axis of the femur.[10,15] Base of the patella is the point where the vastus intermedius inserts itself lying below the superficial rectus muscle.

The rectus femoris lies superficial followed by the medialis and lateralis in the center and the intermedius lying deepest to all of them forming a three-layered arrangement. Before inserting onto the patella, all the four components blend together. Extension of the knee is also assisted by the patellar retinaculum and iliotibial band. The deep layer of fascia lata and the aponeurotic fibres of the vastus medialis and lateralis give rise to the retinaculum. The retinacula get inserted into the proximal tibia. This insertion can help inactive knee extension even when there is a patellar fracture.[16]

The Vastus medialis obliqus gives rise to the medial patellofemoral ligament (MPFL).It originates from the superior border of the patella and inserts just in front to the medial collateral ligament.[17,18]Lateral patellar displacement is primarily prevented by the medial patellofemoral ligament. MPFL is fan-shaped and it inserts into the femur near the adductor tubercle.

Cadaveric dissections have revealed the ligament to be 58.8 +/- 4.7 mm in length, 12 +/-3.1 mm in width, and inclined 15.9 +/- 5.6 degree proximally.[18] Apex of the patella gives rise to the patellar tendon whereas the tendon ends in the tibial tubercle. It measures 5 cm in length. The central fibers of the rectus femoris tendon forms the patellar tendon.

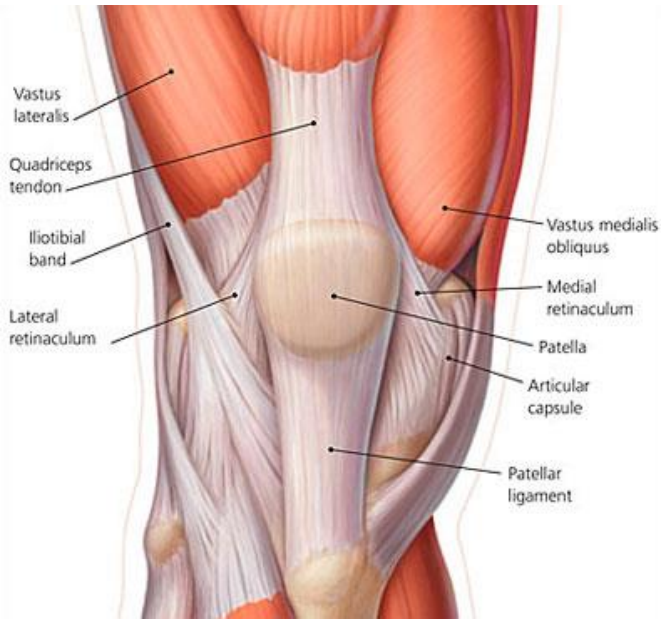

Fig. 7. Soft tissues around the patella.

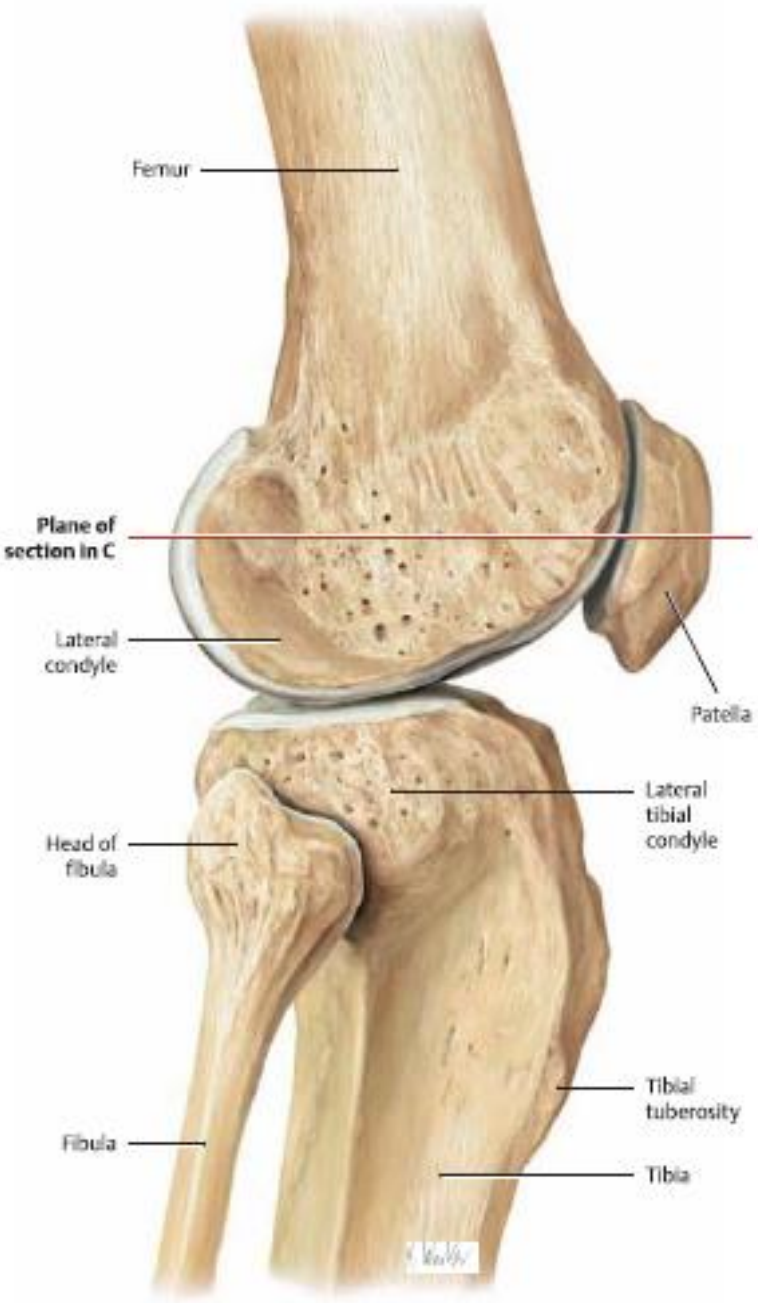

Fig. 5. Lateral view of the knee joint.

Biomechanics in knee extension:

Extension of the knee is brought about by the extensor apparatus of the knee. Gravity is overcome by the normal extension apparatus and hence helps in the activities of daily living significantly.[19,20] Biomechanically, linking and displacement are the two important functions provided by the patella.[19]Linkage is between quadriceps tendon and the patellar tendon during initial extension from full flexion. Forces across the patella can measure upto 7000N in young individuals which is upto eight times the body weight.[21] At 135 degree of flexion, contact between the trochlea and the patellar facets provide the linkage. At 135 – 45 degrees range the odd facet engages with the tibial surface of the medial femoral condyle.[22] At angles less than 45 degrees the displacement function of the patella comes into play. At angles less than 15 degrees twice the amount of torque is needed for full extension than what is needed from full flexion to 15 degrees.[15] Patella displaces the tendon away from the centre of rotation of the knee and this displacement action provides additional 60% of the torque needed for the final 15 degrees of terminal extension.[19] High patellofemoral contact forces are produced because of the higher torques generated. It is estimated that three to seven times the body weight compressive forces are produced during the daily activities like squatting or climbing up the stairs. However, the patellofemoral articulation in

itself is smaller and explains why the contact forces generated here are the greatest.[23,24] Contact zones on the patella with the femur varies significantly with the varying angles of the knee flexion. As the knee progresses through varying angles of flexion, the articulating surface of the patella shifts proximally and in the femur it shifts distally.[22,25]

PATELLA FRACTURES – AN OVERVIEW

Patella fractures

Approximately 1% of all the skeletal fractures are patellar fractures. The mechanism of injury is variable.[3]It can be a direct injury to the patella as in a blow to the patella which happens commonly in the injury to the knee because of the more superficial location and the meagre soft tissue cover over the patella. Direct injuries can be low or high energy depending upon the mechanism involved. Fall from a sitting or standing height are the examples of low energy injury. Impact on the dashboard produces high energy injuries. These high energy direct injuries usually produce comminuted fractures. High energy mechanism injuries are almost always associated with other fractures in the ipsilateral limb which should always be looked out for. Indirect forces are the forces generated across the extensor mechanism, typically resulting from forceful contraction of the quadriceps with the knee in a flexed position.

The high quadriceps contracture forces across the patella results in the dissipation of forces across the adjacent retinaculum and hence producing a higher degree of retinacular disruption. Active knee extension is most often affected. The degree of displacement of fragments is directly

proportional to the occult damage to the adjacent soft tissues. Most of the transverse fractures are a result of indirect mechanism of injury. Others factors influencing the fracture pattern are the patient age, bone quality and degree of knee flexion. Usually the mechanism of injury is a combination of all the mechanisms. Majority of the patella fractures happen as a result of excessive tensile forces across the extensor mechanism. When a partially flexed knee is subjected to a substantial direct force it produces a vertical fracture. If the retinaculum is intact and if the extensor mechanism is not disrupted, the fragments are usually non-displaced. When a direct force onto the knee produces an impaction of the patella onto the femoral condyles, it produces a typical comminuted and stellate fracture patterns.

Associated Injuries with Patellar Fractures

If the mechanism of injury involved in producing the patella fracture is a high energy injury, it most often presents with associated injuries.[26] Two separate case series of patella fractures studied by Bostrom[3] and Noble and Hakek[27]showed associated injury rates at 15% and 28.1% respectively. This rate goes upto 80% if the patella fracture is an open fracture. These injuries are usually found in the ipsilateral lower limb. Thus it is essential for the attending surgeon to look out for the associated

injuries in the ipsilateral lower extremity especially if the mechanism involved is of high energy.

Signs and Symptoms of Patellar Fractures

Patient presents with a typical history of injury after a direct trauma to the knee or fall from a height or forceful contraction of the quadriceps. The mechanism of injury usually gives a hint about the fracture pattern, associated soft tissue damage and also the possibility of associated musculoskeletal injuries in the ipsilateral side. Patient presents with knee pain, swelling and inability to flex or extend the knee. On physical examination, acute hemarthrosis are seen and a palpable defect is usually felt particularly if the fracture fragments are displaced. If the effusion is substantially low, then the retinacular tears has to be suspected. Straight leg raising test can be done to evaluate if the extensor mechanism is intact or not. If the hemarthrosis is large, aspiration of hemarthrosis can be done under local anaesthesia. However, if the patient extends the knee, it does not rule out a patella fracture, it just indicates the extensor mechanism is intact.

Lacerations may be found in the open fractures. If a suspicious wound is found over the fracture site, the communication of the wound with the joint can be established by doing the saline loading test.[28] The test is done

by infusing about 150 ml of saline through a 18 gauge needle inserted into the joint. If the wound is communicating with the joint, the infused saline will egress from the wound. Methylene blue can also be used for easy identification. Immediate wound exploration and debridement should be done for open fractures.

Classification of Patellar Fractures

Various factors influence the classification of patella fractures such as fracture pattern, degree of displacement, or mechanism of injury. Orthopaedic Trauma Association (OTA) classification is based upon the degree of articular involvement and the number of fracture fragments. The clinical usefulness of the classification remains uncertain. For clinical research though, the OTA classification is widely used.[29-32]Basic form of classification of patella fractures is as displaced or nondisplaced. Displaced patellar fractures are those in which fracture fragments are separated by more than 3 mm or articular incongruity is more than 2 mm. Further classification of patella fractures can be based upon the morphology of the fracture. It can be transverse or horizontal, vertical or longitudinal, apical or marginal, stellate or comminuted, and osteochondral. Another distinct entity are the patellar sleeve fractures which occur in the skeletally immature patients in which a distal pole

fracture with a large part of the articular surface seperates from the patella.[33,34]

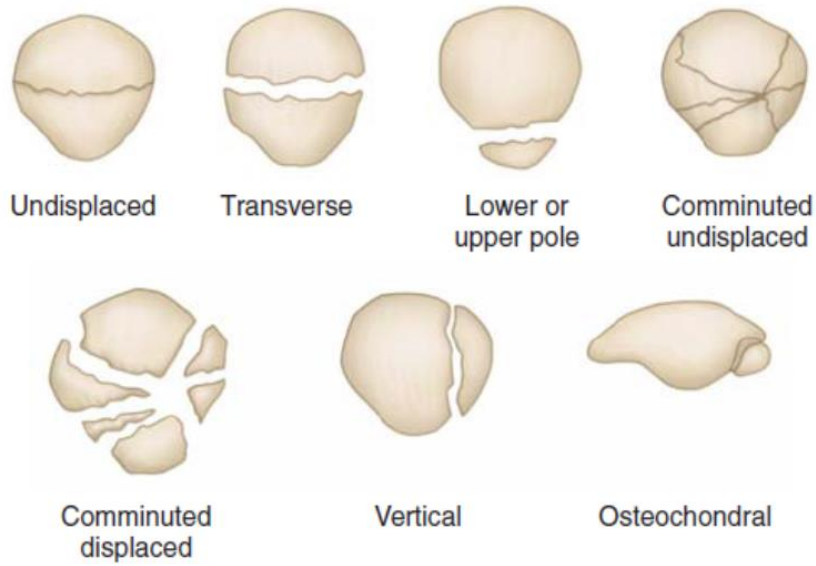

Fig.8. Classification of patella fractures.

Nondisplaced Fractures

Transverse.

35% of transverse patellar fractures are nondisplaced.[3,35]The indirect, longitudinal forces that produce transverse fractures of the patella are insufficient to tear the medial and lateral patellar retinacula. So the patellar retinacula is intact, which in turn presents with an intact extensor mechanism. Reduction is maintained by the intact soft tissue cover.

Majority of these fractures occur in the middle third or the lower third of the patella.[36]

Stellate.

Direct blow injuries to the patella with the knee in a partially flexed position typically produce a stellate fracture. Most fractures are nondisplaced.[3,37] Extensor mechanism is intact and hence knee extension is preserved since the medial and lateral patellar retinacula are usually intact in these injuries. Osteochondral lesions, patella and femoral articular surface damages may all happen and hence high index of suspicion has to be kept in mind and also if needed MRI can be taken for further evaluation.

Vertical.

Longitudinal fracture pattern accounts for 12% to 22% of patellar fractures.[36,38,39] Lateral facet is most commonly involved found dividing the middle and lateral third of the patella. Boström concluded that 75% of these fractures are due to lateral avulsion.[3]Dowd implied that direct compression of the patella in a hyperflexed knee is the mechanism behind this pattern.[39] Extension is possible because of the intact medial and

lateral retinacula. This fracture pattern warrants an axial view, otherwise most of these fractures are missed in AP view.

Displaced Fractures

Transverse.

52% of transverse patella fractures are displaced.[29,30]

Un-displaced

Transverse Lower or upper pole

Multi-fragmented un-displaced

Multi-fragmented displaced

Vertical Osteochondral

Extensor mechanism injury and retinacular injury are very common in the vertical osteochondral fractures. As a result, the chances of fracture fragment separation is high. Active knee extension and retinacula are intact in a subset of these fractures. These patients can be treated conservatively as explained by Bostrom[3]. McMaster showed that there is increased chances of non union in these groups treated conservatively.[41]

Stellate.

Stellate fractures with high degree of comminution and displacement happens when a high energy direct force impacts at the knee. Anteriorly, soft tissues damage is very common.

Transverse fracture lines

Transverse fractures usually involve the retinaculum and particularly in the setting of extensive comminution this becomes common. Hence extensor mechanism is commonly affected in this type.

Pole Fractures.

Pole fractures are usually avulsion fractures involving the pull of either the quadriceps or the patellar tendon. Proximal pole fractures contribute to 4% of the patella fractures.[3,42] They are caused by the avulsion of the proximal pull of the quadriceps mechanism. The lateral radiograph usually shows the patella placed at a lower point. Active knee extension is still possible because the retinaculum is intact.

Distal pole fractures are caused by the pull of the patellar tendon. They contribute to 11.5% of the patella fractures.[3,42] Knee extension is almost

always affected because of the associated retinacular injury. The lateral radiograph shows a high placed patella.

Masqueraders.

Incomplete fusion of the ossification centers can present as a bipartite or tripartite patella. These are normal anatomical variants of patella. They are often misdiagnosed as a fracture. A well-corticated fragment present in the superolateral aspect of the patella is usually visible in a bipartite patella. It is usually bilateral in nature and the usual incidence is 8%.[43,44] Whenever a bipartite patella is suspected it is imperative to take a radiograph of the other side to confirm the diagnosis.

REVIEW OF LITERATURE

- The mangaement of patella fractures has come a long way over the years. A lot of fixation strategies have been proposed for the operative treatment of patella fractures.
- Initial treatment of patella fractures was mostly conservative with splinting the knee in extension.[45]
- *Hey-Groves and Watson-Jones* came up with the conclusion that quadriceps function was reduced by patella and hence removing it will be beneficial.[46]
- *Blodgett and Fairchild, Thompson, and Seligo* all advocated patella excision based on their good results but failed to demonstrate good functional outcome paricularly important for the knee joint. All the conservative methods established nonunion, pain and disability at a very high rate.[47]
- *Cohn and Kelly et al* explained that degeneration of the articular surface of the femur had set in after removal of the patella further lowering the satisfactory levels of the patients and higher disability rate.[48]

- *Haxton* and his associates demonstrated the importance of patella in the biomechanical functionong of the knee and hence proved the importance of preserving patella.[49]
- *Malgaigne* discovered a claw-like plate to fix the patella fractures and gave the term “griffe metallique” to the plate.[50]
- Open reduction and internal fixation of patella was first performed by *Sir Hector Cameron in 1877*. He used interfragmentary screws for the fixation.[51]
- *Lister and Trendelenburg* used wires through the drill holes. Though various new methods of fixation were created over a period of time stable fixation remained the most difficult thing to achieve. Various implants like percutaneous pins, xenografts and plates were tried.[52]
- The breakthrough in the fixation strategies of patella fracture came with the anterior tension band technique described by *Muller et al*.[53]
- Modified tension band fixation was later advocated by Arbeitsgemeinschaft für Osteosynthesefragen/Association for the Study of Internal Fixation (AO/ASIF) subsequently which has become the gold standard in the fixation of patella fractures thereafter.

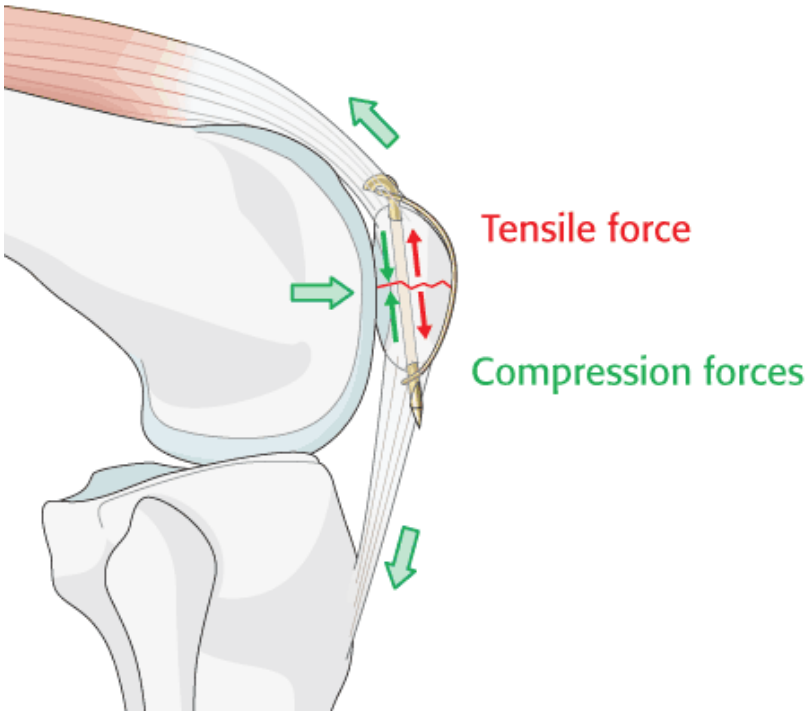

Fig. 9.Tension band wiring - AO

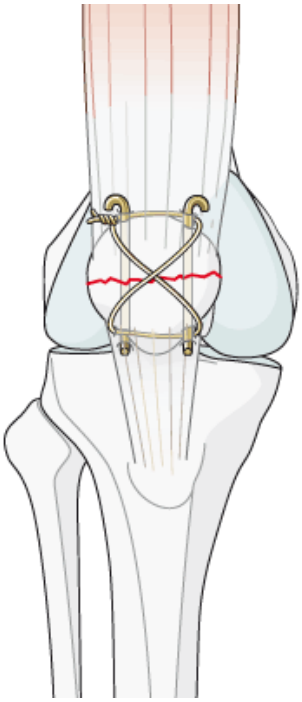

Fig. 10.Tension band wiring – AO

- *Weber et al*. showed that the modified anterior tension banding technique with retinacular repair is far superior and biomechanically stronger for transverse patella fractures when compared to fixation with interfragmentary screws. Further, numerous studies supported the above finding.[54]
- Three surgical procedures currently widely performed for the patella fractures are.

1. Modified anterior tension banding using wires or cannulated screw technique

2. Partial patellectomy

3. Total patellectomy

The choice of the procedure varies from individual to individual because it depends on a variety of factors including fracture morphology and the functional requirements of the patient post-operatively. The selection of patients hence play a very important role in the outcome of the fracture fixation.

The principles adhered to in the fixation of patella fractures are:

- Restoration of the extensor mechanism with full strength
- Maintaining the congruity of the articular surface
- Maximal preservation of the bone

BIOMECHANICAL PROPERTY

Fiberwire

Fiberwire is one of the high resistance suture materials available. Fiberwire is made of a central core of very high molecular weight polyethylene surrounded by a layer of braided polyester. This property makes it extremely resistant to shear and abrasive forces. It has been widely used in variety of orthopaedic procedures like ACL reconstruction, quadriceps and patellar tendon repair, Achilles tendon injuries and rotator cuff repair. It has advantages of having a high strength and a soft handling characteristic making it easy for intra-operative handling and lessens the operating time.[55] When compared to stainless steel both of which establish the biomechanical advantage of fiberwire in the use as an alternative in orthopaedic procedure.

The 5-ethibond and 5-TiCron are the other non absorbable suture materials which have already been studied for the treatment of patella fractures and have demonstrated good results. So far the fibertape and fiberwire have not been widely studied for the treatment of patellar fractures. But in vitro experimental and biomechanical studies have demonstrated superior characteristics of fiberwire over other available non absorbale high resistance suture materials.

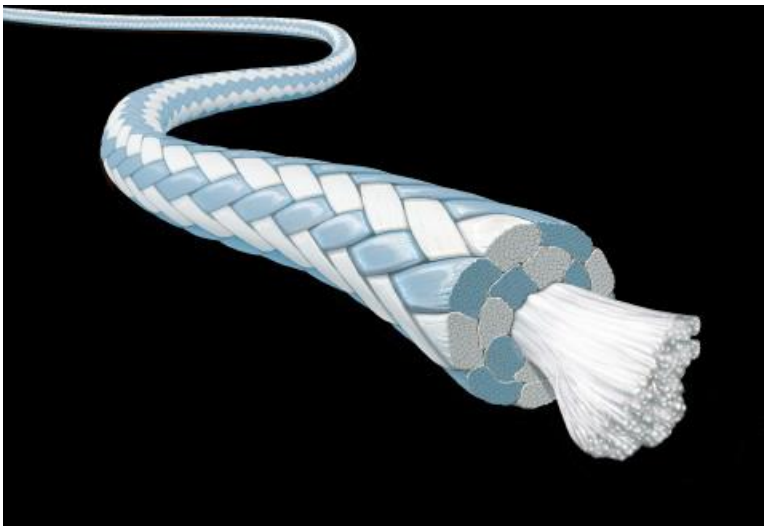

Fig. 11. Cross-sectional appearance of fiberwire.

Salient properties of fiberwire:

■Strength

Fiberwire is being studied in a variety of tests and majority of them show superior strength and knot capabilities over the available high resistance suture materials.

■Biocompatibility

The use of fiberwire in the orthopaedic surgery is so widespread because the suture material exhibits biocompatibility similar to that of the available high resistance suture materials.

■Tie Ability and Knot Profile

Having a superior strength means while applying knots, the fiberwire demonstrates high loop security and the strength of the knot that is multi-

fold increased and the prominence of the knot is also decreased. These properties make the fiberwire very desirable. It can also be employed in arthroscopic techniques where sliding knot techniques can be easily done.

■Resistance to wear

Fiberwire exhibits extraordinary resistance to wear particularly in procedures which involve the procedures which create sharp edges, sharp tunnel ends and at joint surfaces where the abrasive forces are high and where other suture materials can wear easily over a period of time.

■Variable sizes

The FiberWire has a range of sizes available from 4-0 to 5. Each size is appropriate for the site and the purpose the fiberwire does. In our study, we used # 5 Fibertape.

It is a tape which has 5 numbers of # 5 fiberwire integrated in the centre region of the suture material that provides it with high resistance power and also a broad surface area for the compression.

Fibertape:

Fibertape is the next generation variant of fiberwire. Its structure is very much like that of the fiberwire. There is a variant in which stripes are given for easy intraoperative identification which is the tigertape. These

2mm wide tapes provide a wide surface area over the bones and hence provide the compression across the fracture site the most. Tissue cut through resistance is also higher and hence making it an ideal candidate for the patella fractures fixation.

Fig.12. FiberTape used in the study. (17 N)

Fig.13. Fibertape 17” working length

The four anterior tension band constructs tested included

(A) a stainless steel with two compression twists,

(B) a single-strand FiberWire tied with a slidingknot,

(C) a double-strand FiberWire tied with individual sliding knots, and

(D) a double-strand FiberWire tied with a modified Wagoner’s Hitch.

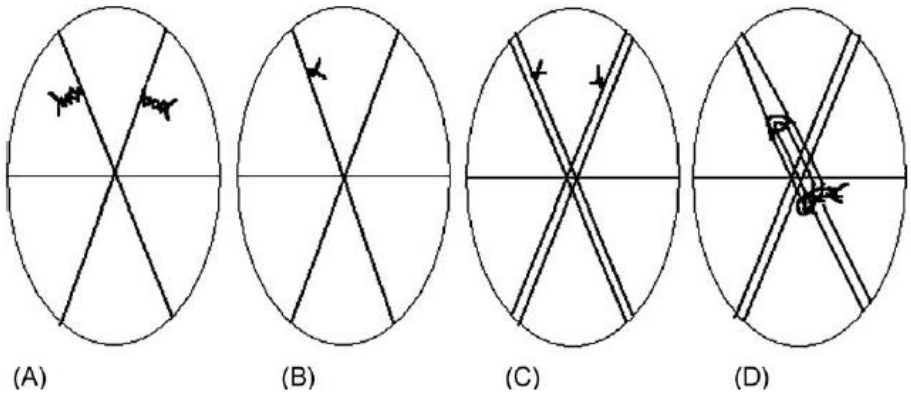

Fig.14.Tensile strengths: D>C>A>B (in decreasing order)

MATERIALS AND METHODS

Type of study: Prospective study of patientswith patellar fractures who underwent fracture fixation with suture material,

Study place: Department of Orthopaedics, Government Kilpauk Medical college and Hospital, Kilpauk, Chennai.

Study period: April 2016 to September 2017.

Study duration: 1 years 6 months.

Inclusion criteria:

1. Age more than 18 years
2. Fresh fractures (i.e. trauma to surgery within 2 days)
3. Minimum follow-up of at least 10 months.

Exclusion criteria:

1. Age less than 18 years,
2. Evidence of an active infection,
3. Previous metal implantation,
4. Patients in whom a knee surgery was done prior to the recent trauma, and
5. Patients with other comorbidities like head injury which affects the rehabilitation.

Operative technique:

The patient was positioned supine in the operating table. Tourniquet was not applied as a routine. A midline longitudinal incision was used for all the cases. Before inspecting the fracture per se, the medial and lateral retinaculum were visualized and inspected for any tears associated with the trauma and which may need to be repaired. Then fracture site is visualized. Fracture hematoma is let out. Blood clots were removed from the fracture ends. The knee joint proper was inspected for any intra-articular loose fragments. Then preliminary fracture visualization is done under direct vision using reduction clamp. The patella articular surface is inspected for any incongruity. The fracture reduction is achieved after attaining perfect joint congruity. Then two guide wires were inserted in the medial and lateral aspect of the patella. Then tunnels were created over the guide wires using the cannulated drill bit while the initial reduction is still maintained by the reduction clamps. The guide wires were then removed. No 5 Fibertape is fed onto the bead pin and introduced in the medial tunnel in a distal to proximal fashion and on its exit in the medial proximal end it is brought across to the lateral distal end and then using the bead pin the Fibertape finally arrives at the lateral proximal end and the high resistance suture material is then tied with the knot placed in the postero-superior aspect. Care must be taken to bury the knot under sufficient soft tissue cover to protect the superficial tissues

from irritation and subsequent patient discomfort. The reduction clamp can be removed after the application of the knot. The fracture reduction is visualized for any step and the articular surface is inspected for any residual incongruity. The reduction was further checked with the help of C-arm. If found satisfactory, the retinacular repair can be done if its present. Knee flexion and extension is checked on table for the stability of the fracture reduction. Wound wash given thoroughly. Drain kept when necessary. Wound closed in layers. Sterile dressing done.

STEPS IN THE PROCEDURE

Patient positioning

Midline longitudinal incision

Fracture hematoma let out and fracture edges identified

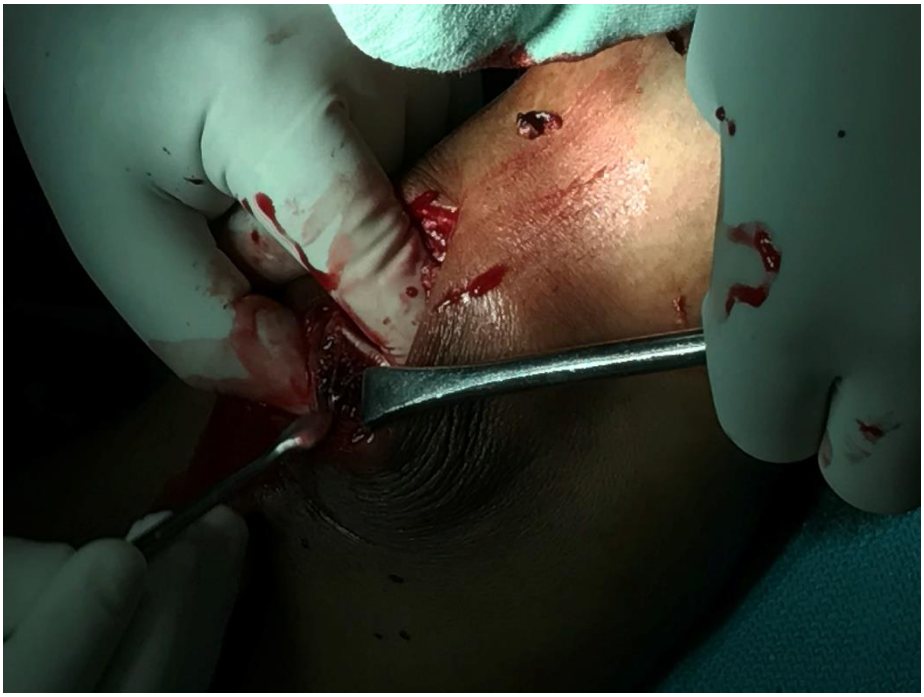

Fracture ends being cleared of soft tissues

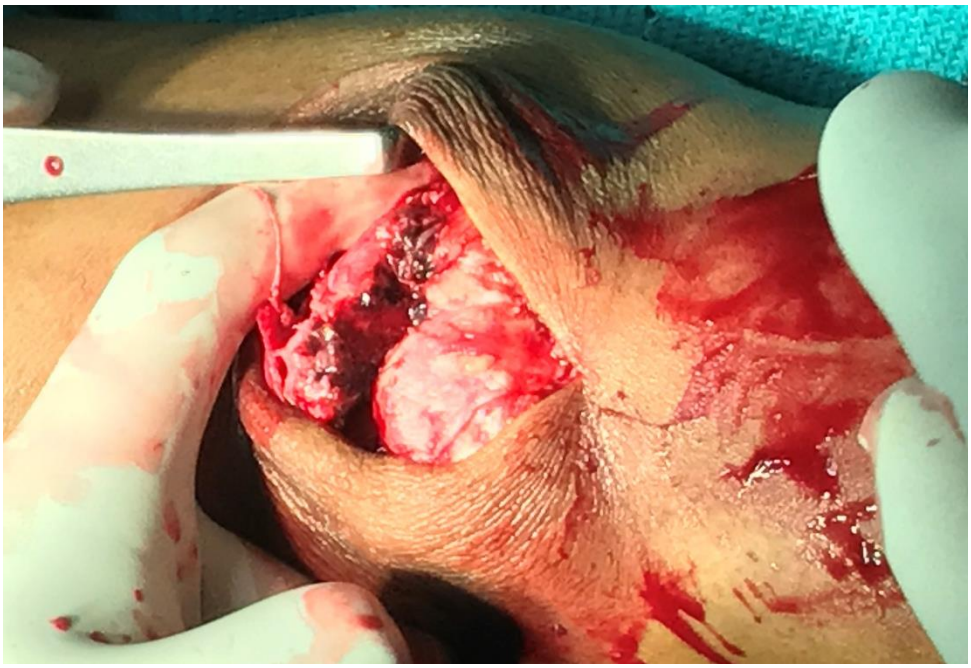

Fracture ends made clearly visible

Fracture ends approximated

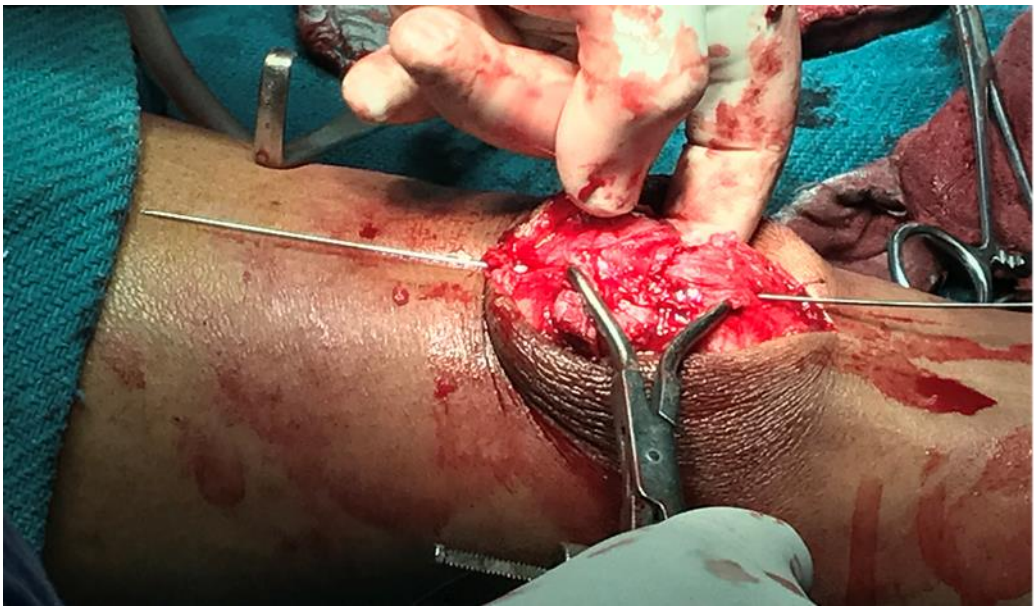

First guide wire introduced

Both guide wires introduced

Creating Tunnel using cannulated drill bit

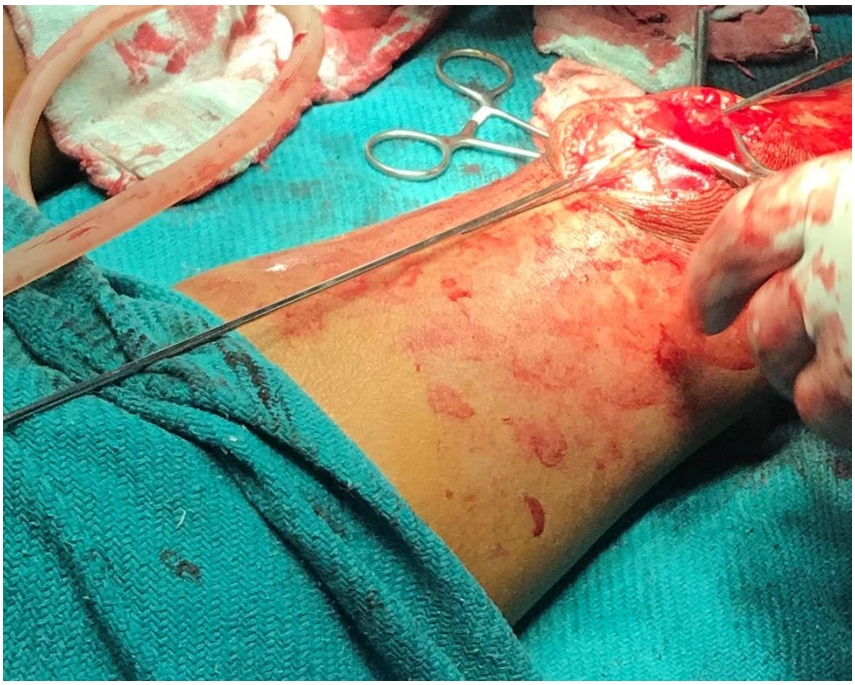

Introduction of bead pin with FiberTape

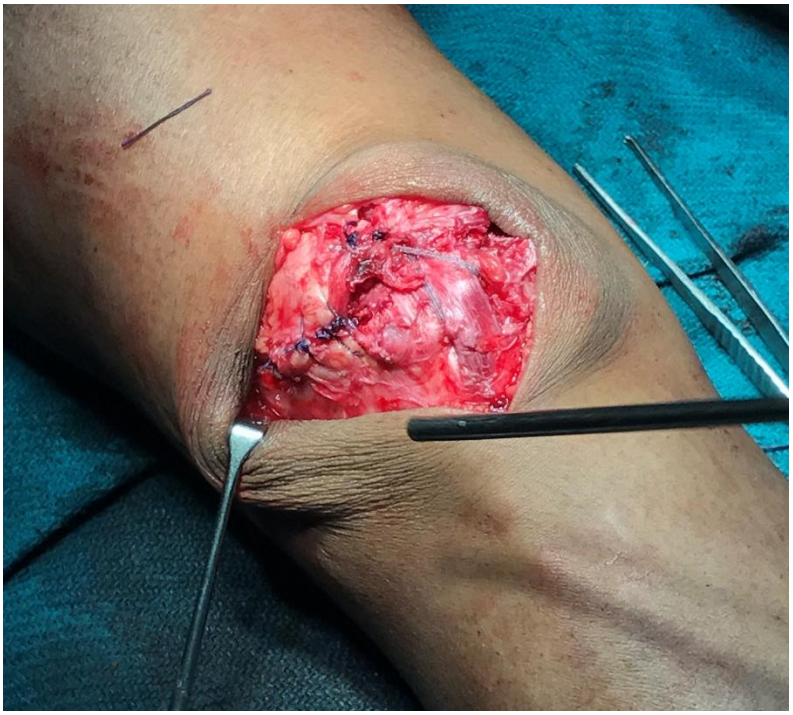

Final figure-of-eight construct

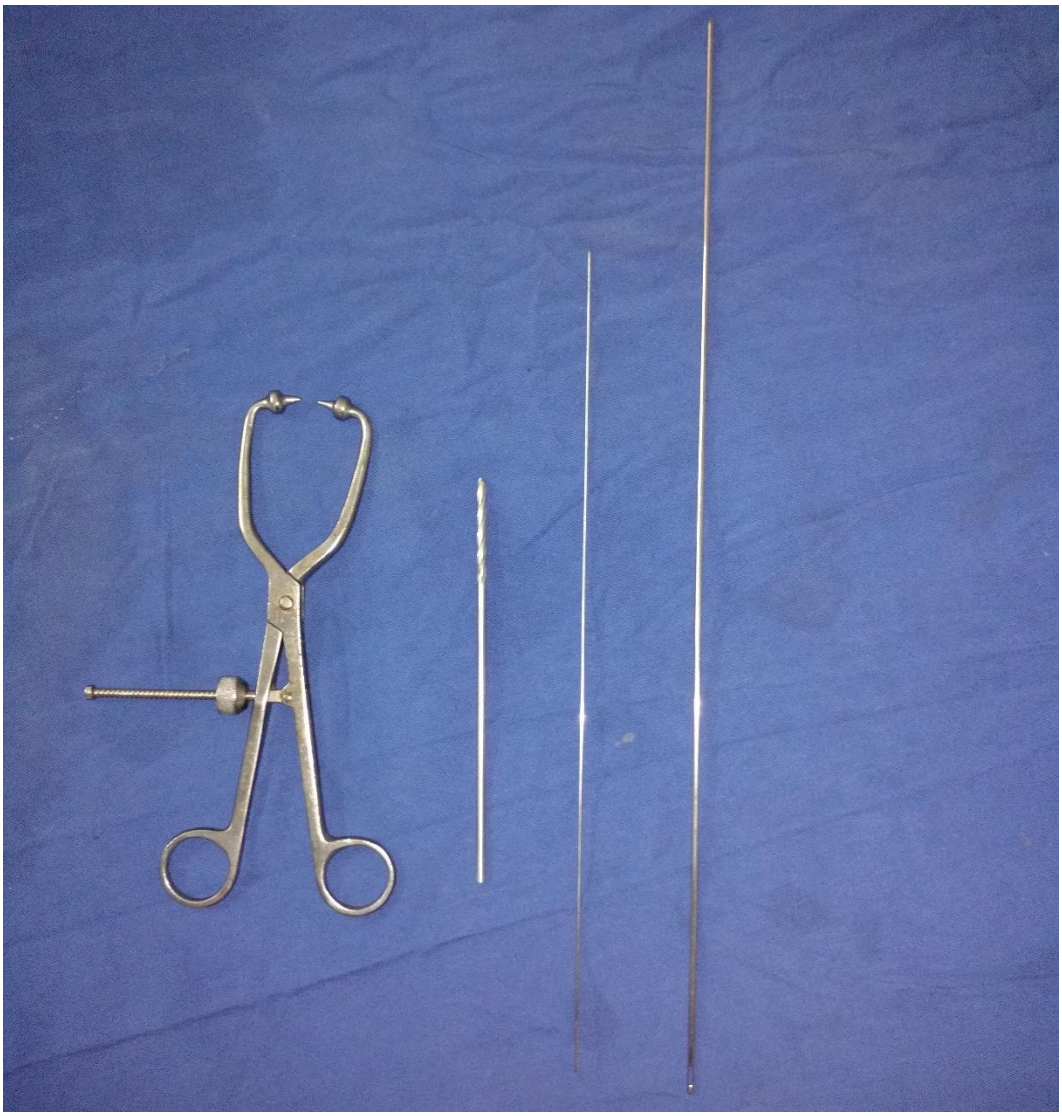

Instruments used in the procedure:

1. Reduction clamp
2. Cannulated drill bit
3. Guide wire
4. Bead pin (with eye at the end to feed the fiber tape)

FOLLOW UP

1. Minimum follow up period of 10 months.
2. Time to radiological union.
3. Range of motion recovery.
4. Extensor lag if any.
5. Knee scores – Lysholm and Bostman scores.
6. Fracture displacement (>4mm) if any.

Tegner Lysholm Knee Scoring Scale

During the past 4 weeks

SECTION 1 - LIMP

I have no limp when I walk. (5)

I have a slight or periodical limp when I walk. (3)

I have a severe and constant limp when I walk. (0)

SECTION 2 - USING CANE OR CRUTCHES

I do not use a cane or crutches. (5)

I use a cane or crutches with some weight-bearing. (2)

Putting weight on my hurt leg is impossible. (0)

SECTION 3 - LOCKING SENSATION IN THE KNEE

I have no locking and no catching sensation in my knee. (15)

I have catching sensation but no locking sensation in my knee. (10)

My knee locks occasionally.(6)

My knee locks frequently. (2)

My knee feels locked at this moment. (0)

SECTION 4 - GIVING WAY SENSATION FROM THE KNEE

My knee gives way. (25)

My knee rarely gives way, only during athletics or vigorous activity. (20)

My knee frequently gives way during athletics or other vigorous activities. In turn I am unable to participate in these activities. (15)

My knee frequently gives way during daily activities. (10)

My knee often gives way during daily activities.(5)

My knee gives way every step I take. (0)

SECTION 5 – PAIN

I have no pain in my knee. (25)

I have intermittent or slight pain in my knee during vigorous activities. (20)

I have marked pain in my knee during vigorous activities. (15)

I have marked pain in my knee during or after walking more than 1 mile. (10)

I have marked pain in my knee during or after walking less than 1 mile. (5)

I have constant pain in my knee. (0)

SECTION 6 – SWELLING

I have swelling in my knee. (10)

I have swelling in my knee on1y after vigorous activities. (6)

I have swelling in my knee after ordinary activities. (2)

I have swelling constantly in my knee. (0)

SECTION 7 – CLIMBING STAIRS

I have no problems climbing stairs. (l0)

I have slight problems climbing stairs. (6)

I can climb stairs only one at a time. (2)

Climbing stairs is impossible for me. (0)

SECTION 8 – SQUATTING

I have no problems squatting. (5)

I have slight problems squatting. (4)

I cannot squat beyond a 90deg. Bend in my knee. (1)

Squatting is impossible because of my knee. (0)

Scoring:

<65 – poor

65-83 – fair

84-90 – good

>90 – excellent

BOSTMAN SCORING SYSTEM:

Variable	Points
Range of movement (ROM)	
Full extension and the ROM >120° or within 10° of the normal side	6
Full extension, movement 90° to 120°	3
Pain	
None or minimal on exertion	6
Moderate on exertion	3
In daily activity	0
Work	
Original job	4
Different job	2
Cannot work	0
Atrophy, difference of circumference of thigh 10 cm proximal to the patella	
<12 mm	4
12 to 25 mm	2
>25 mm	0
Assistance in walking	
None	4
Cane part of the time	2
Cane all the time	0
Effusion	
None	2
Reported to be present	1
Present	0
Giving way	
None	2
Sometimes	1
In daily life	0
Stair-climbing	
Normal	2
Disturbing	1
Disabling	0
Total score	
Excellent	30 to 28
Good	27 to 20
Unsatisfactory	<20

CLINICAL CASES

CASE - 1

A 45 year old male, sustained road traffic accident.

Type 1 compound fracture known case of diabetes on treatment

Pre-op

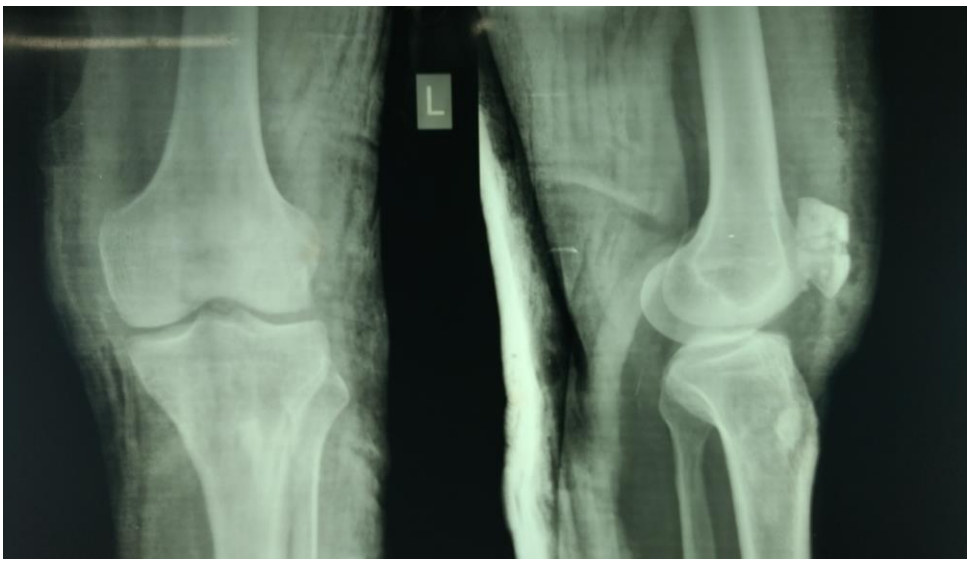

1 month follow up

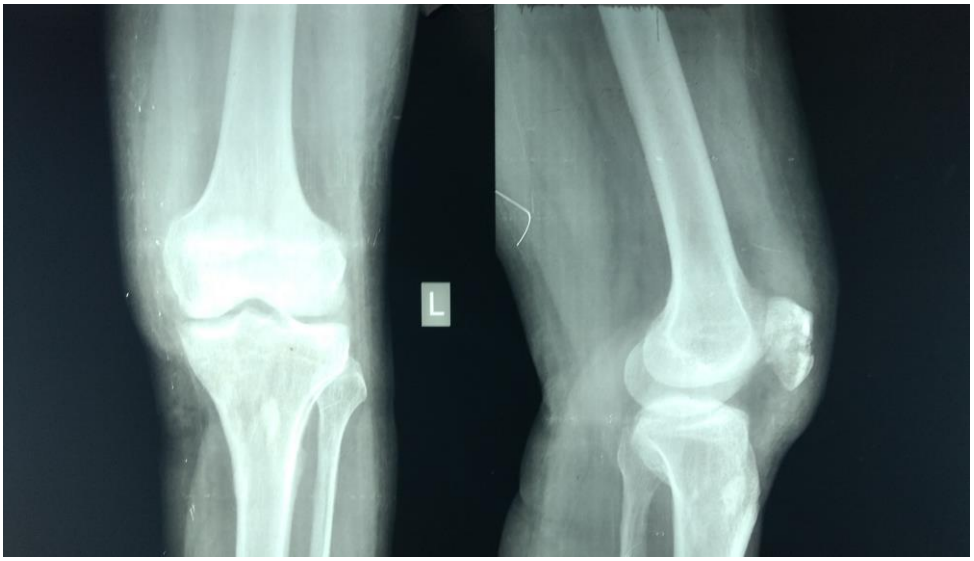

3 months follow up

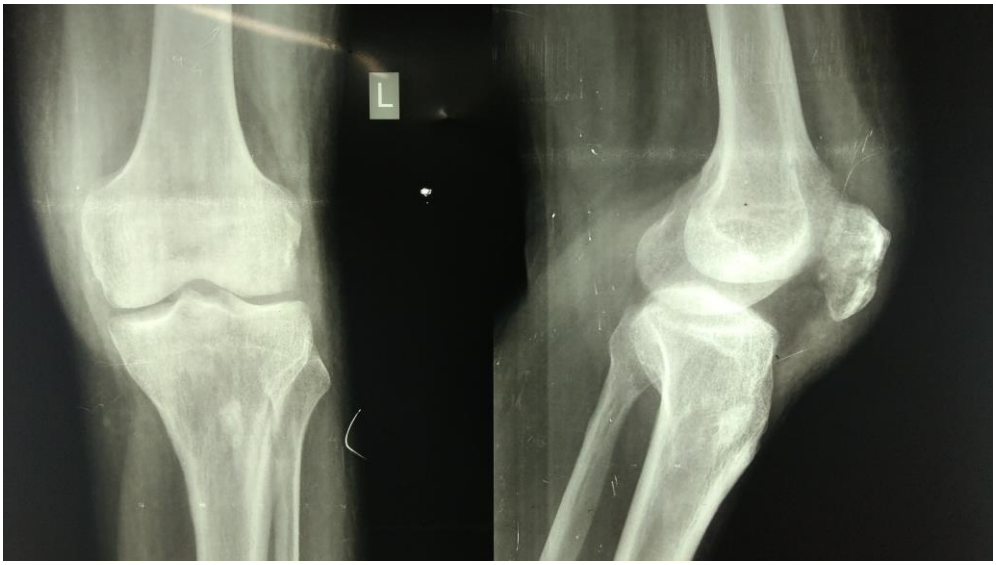

6 months follow up

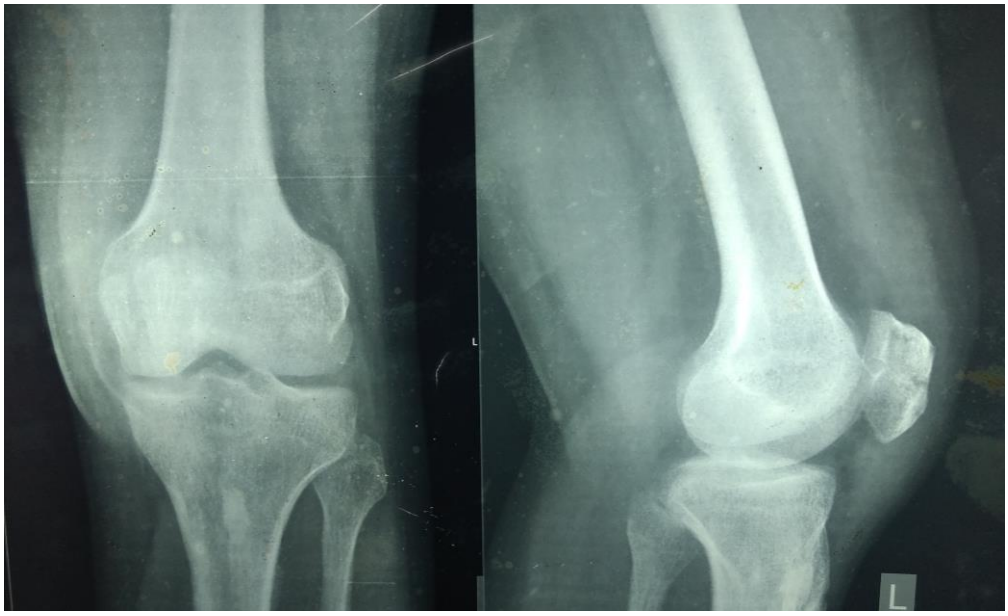

9 months follow up

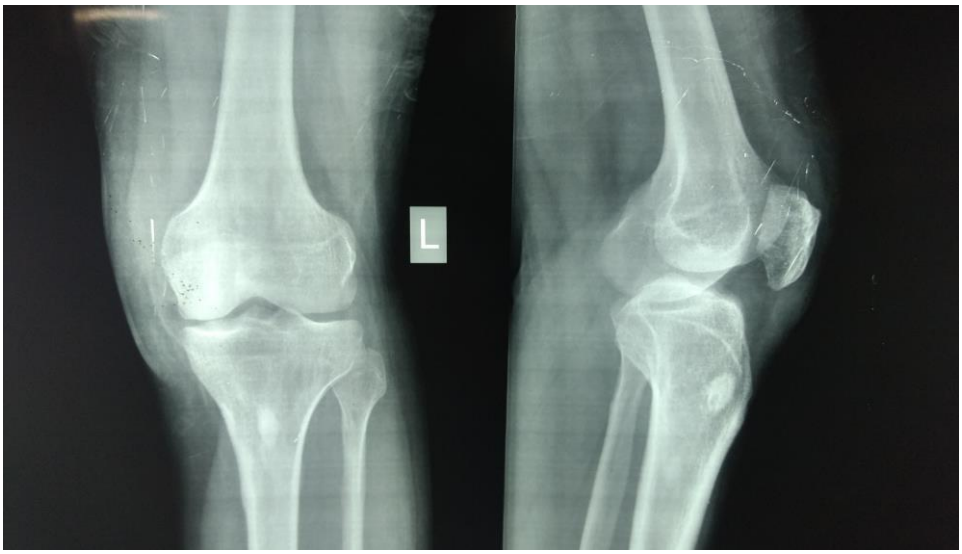

1 year follow up

Extension

Flexion

Post-operative wound

CASE - 2

65 year old female, sustained trauma with history of self fall. Patient was not able to extend the knee at presentation.

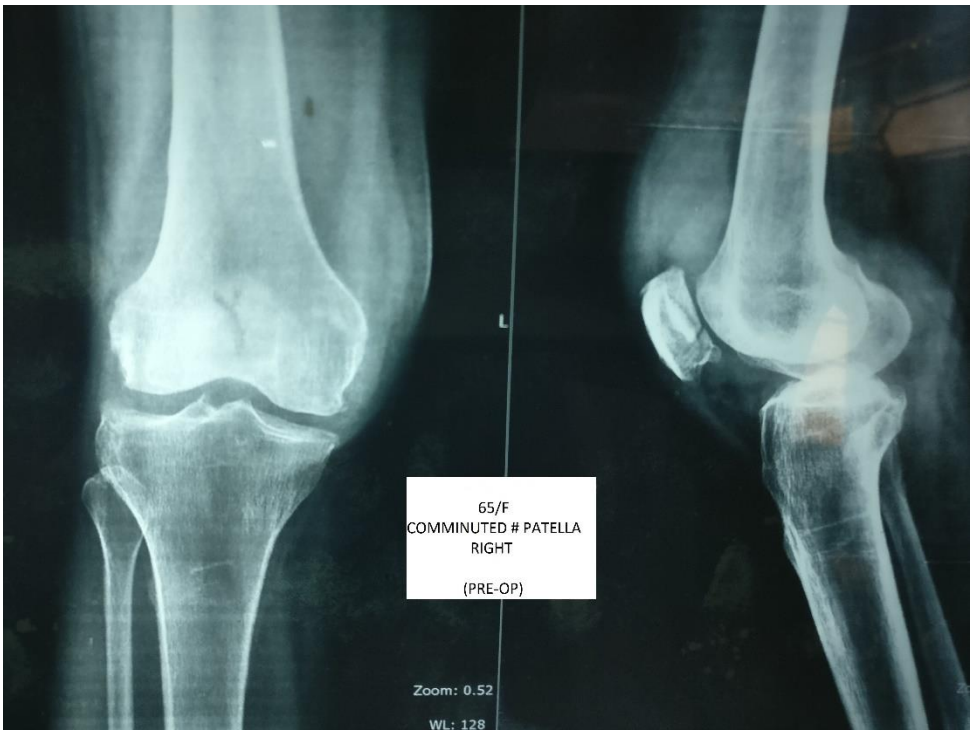

PRE-OP KNEE X-RAY

DIAGNOSIS: COMMINUTED FRACTURE RIGHT PATELLA

LONGITUDINAL FRACTURE

POST-OP X-RAYS

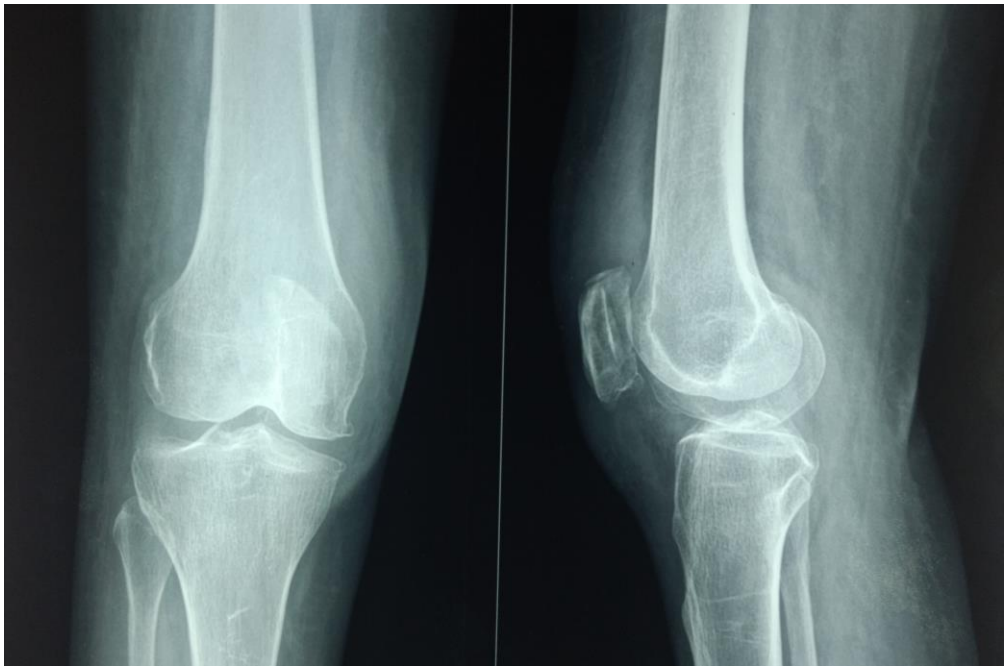

3 months post-op

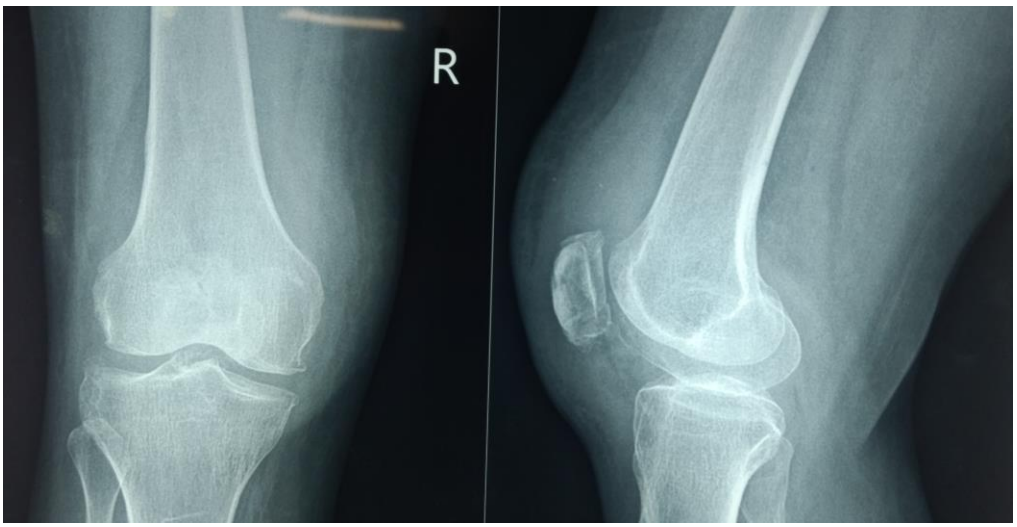

6 months follow-up

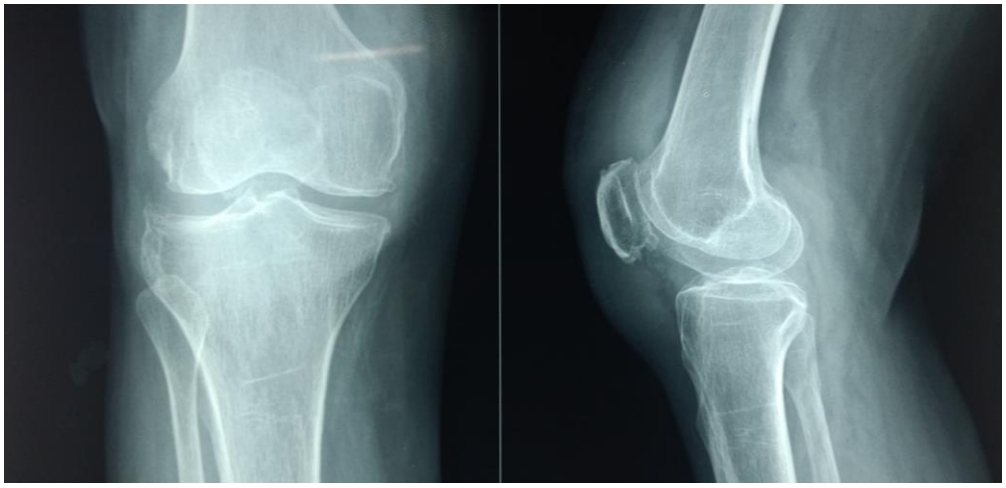

9 months follow-up

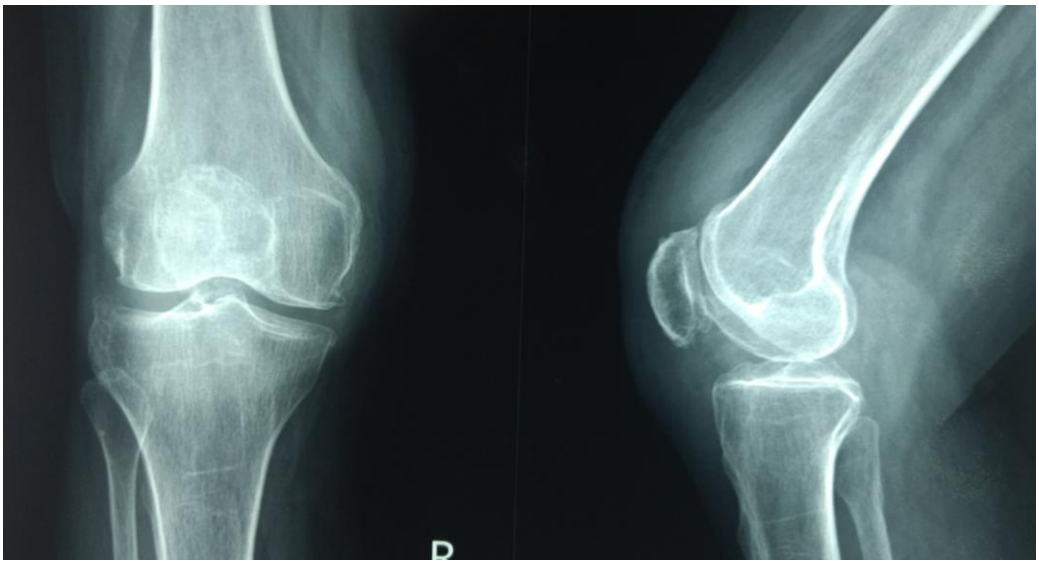

1 year follow-up

Extension

Flexion

Post-op wound picture

CASE - 3

56 year old male with comminuted fracture patella

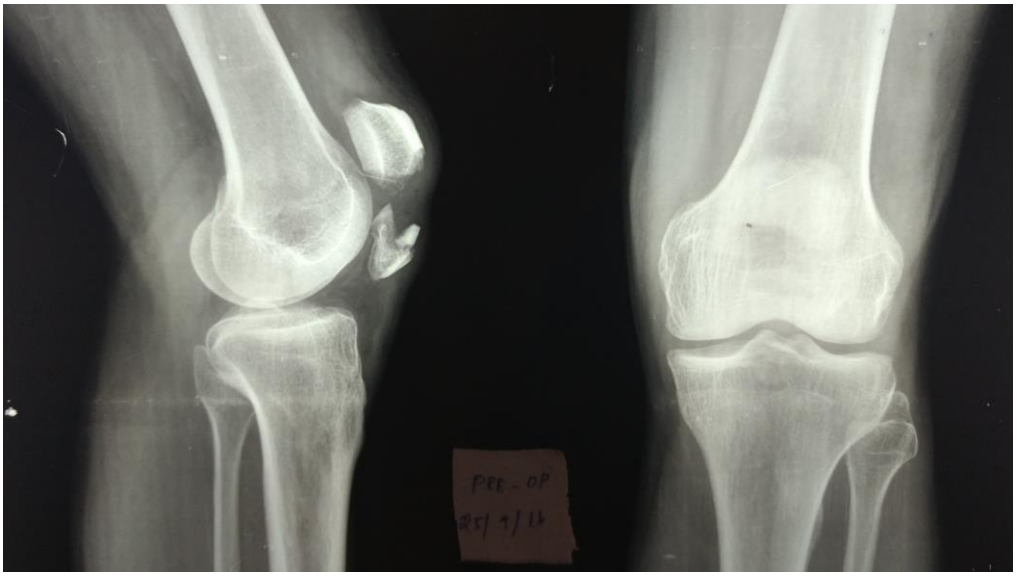

Pre-op

Immediate post-op

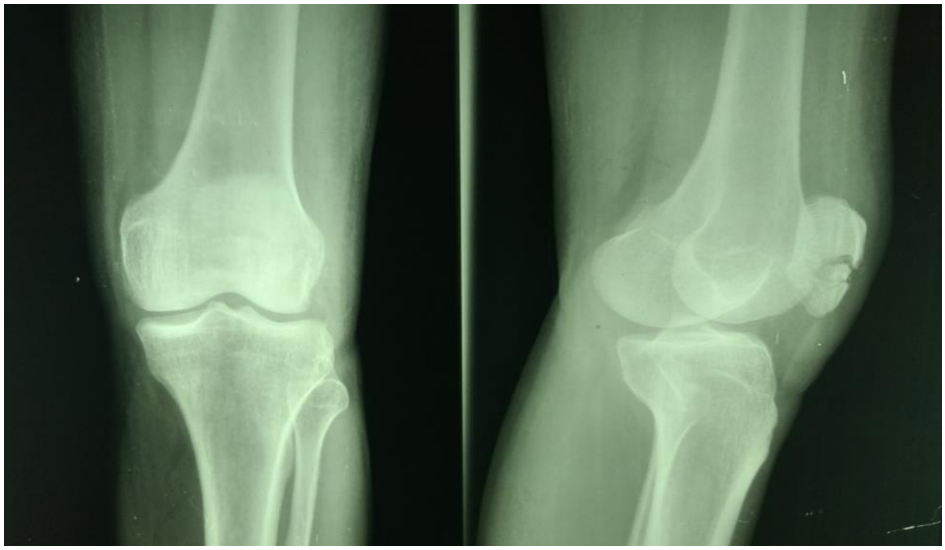

1 month post-op

3 months post-op

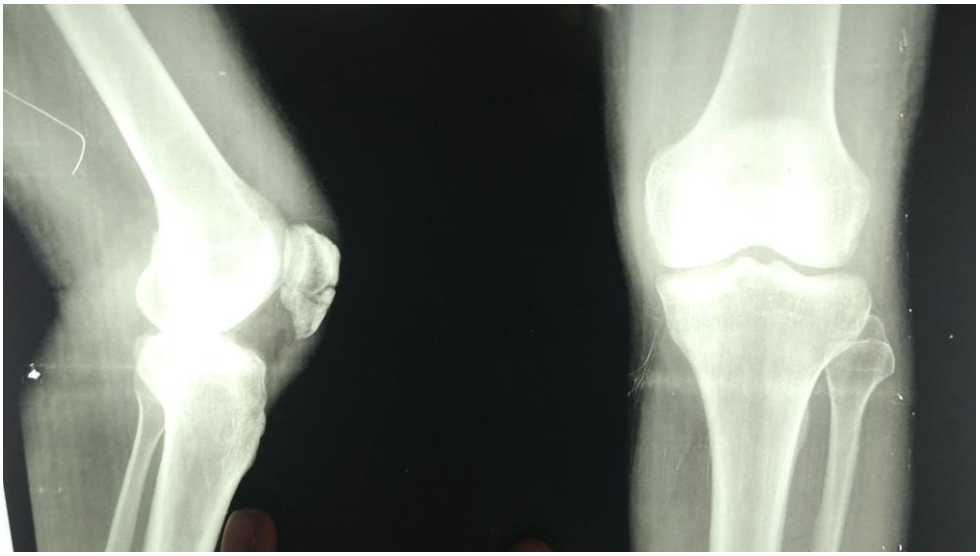

6 months post-op

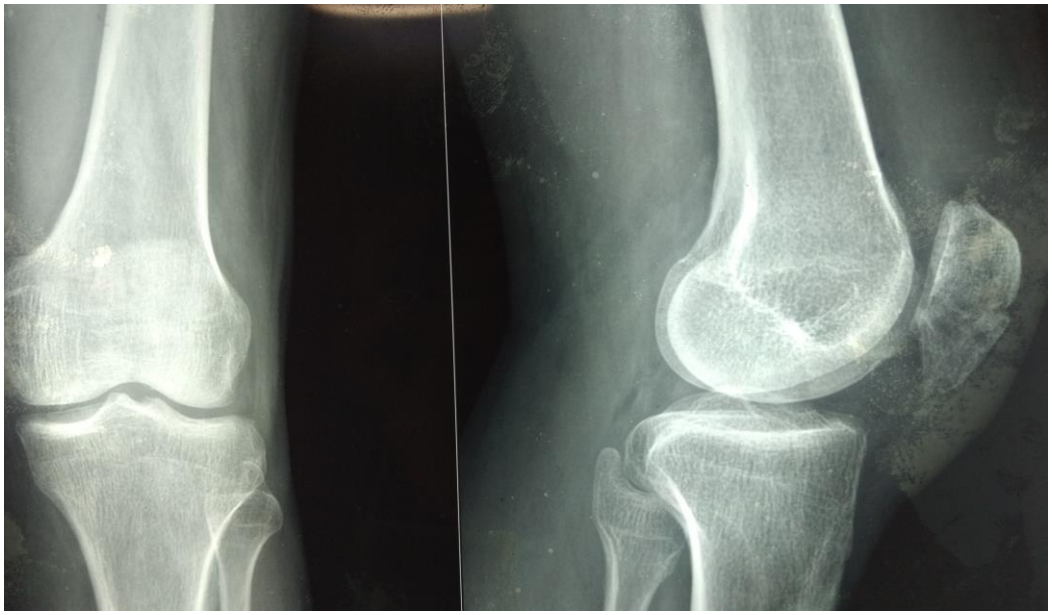

1 year follow up

1 year 3months follow up

Flexion

Extension

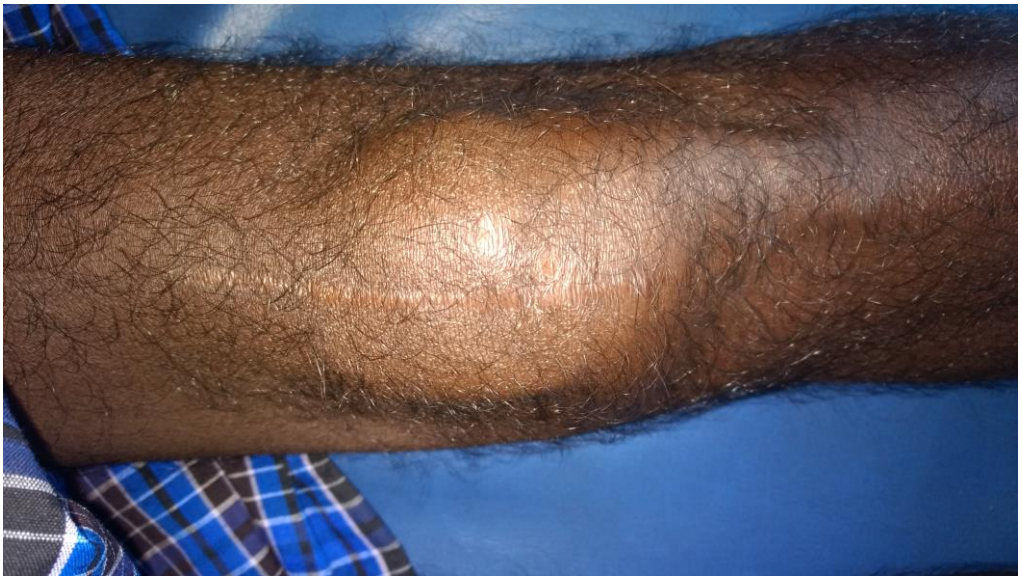

Post-op wound photo

CASE - 4

34 year old male with road traffic accident

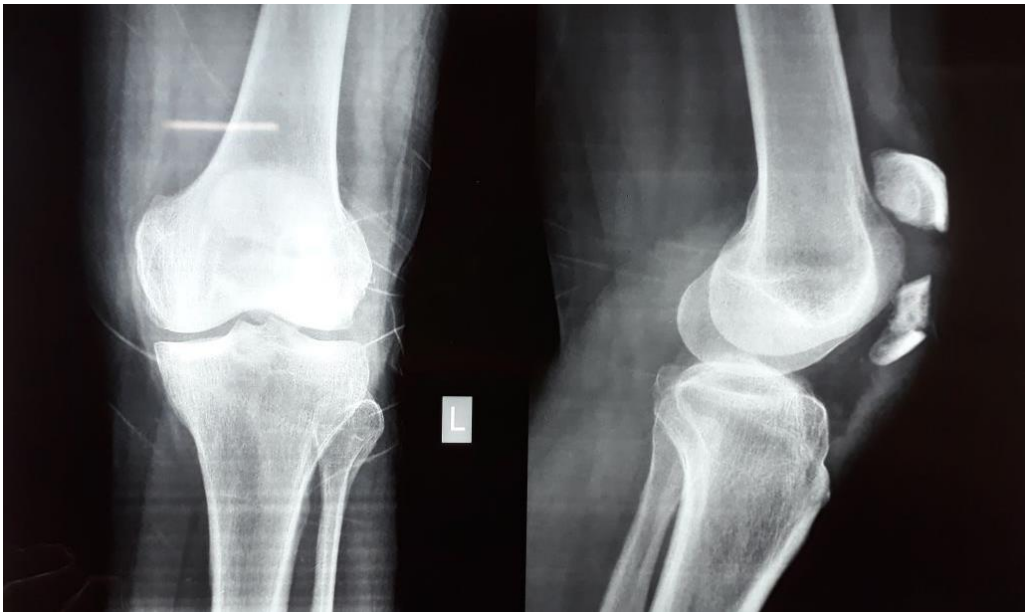

Pre-op

Immediate post-op

1month post-op (patient presented with H/o. fall at 1 month with displacement)

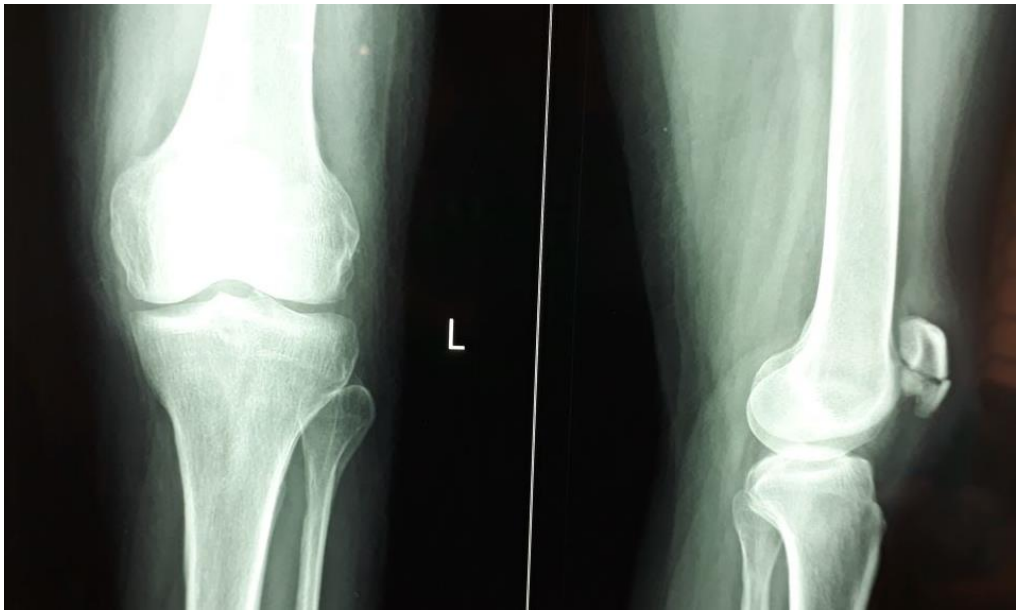

2 months post-op

2 months 15 days post op

Eventually the fracture united and the patient did not have any complications

DISCUSSION

The use of Fiber-Tape for the fixation of patella showed that the functional outcome of the cases were good. The scores evaluated for the functional outcome study was bostman and lysholm score. Average bostman score is 27. Average lysholm score is 90.6. There was no hardware related complications encountered in the course of the study. These are the most important results of the study.

Minor complications like superficial infection, anterior knee pain, displacement<4mm were noted in the study. Among the 24 patients who were included in the study, 1 patient presented with post-operative superficial infection which settled with intravenous antibiotics for 5 days. The patient was clinically normal and did not present with any further complications. The final scores of the patient were lysholm score – 88, bostman score – 27. All the patients presented with good union at the end of the follow up. Though 1 patient presented with post-operative fixation failure with fracture displacement of <4mm, it eventually united and did not influence the final union. Scores of the patient were Lysholm score – 85; bostman score – 25.

Patella fractures have been treated by various methods over the past century. The gold standard technique followed till now is the application of stainless steel wire figure of eight configuration anterior tension band placed anteriorly after inserting two axial K-wires through the patella.[53]

Table 1: Association between type of fracture and functional outcome

Type of fracture	**Outcome –N (%)**			**Chi square**	**P-value**
	Excellent	**Good**	**Fair**		
1. Transverse	10(71.4)	4(28.6)	0	5.476	0.242
2. Comminuted	4(57.1)	1(14.3)	2(28.6)		
3. Inferior pole	2(66.7)	1(33.3)	0		

There is no association between type of fracture and functional outcome by chi square test (p=0.242). Type of fracture did not influence the eventual functional outcome of the study. All fractures united by a mean duration of 3 months 8 days.

Table 2: Association between Age and functional outcome

Functional outcome	Mean age	Mean Rank	P value
1. **Excellent**	47.8	11.09	0.362
2. **Good**	58.0	15.83	
3. **Fair**	52.5	13.75	

There is no association between age and functional outcome by Kruscal Wallis test (p=0.362). Functional outcome and hence union is not influenced by the age of the patient.

A more comminuted fracture may demand the use of two cannulated cancellous screws instead of K-wires which also provides a stable construct.[56]The problem, however, with stainless steel wire is that, it is difficult to handle and maneuver it through the soft tissues and it may result in failure of fracture fixation.[57]

The number of implant related metallic complications were very high in these patients as there was a high incidence of K-wire migration and the stainless steel wire knots that were not buried properly produced skin irritation, ulcers and infections. These complications ranged from 0-60

%.[58,59] All these factors played an important role in influencing the removal of the implant.

LeBrun et al. reported in a case series of 27 patients with a mean follow up of 6.5 years, the hardware removal rate was 52%.[60] Hoshino et al made a retrospective study in the patella fractures that were operated and showed that elective implant removal was done in 37% of patients with K-wires and 23% of patients with cannulated screws.[61] Based on these results a number of authors proposed the use of non-metallic implants like high resistance non absorbable suture materials.[62,63,64]The significant finding common in all of these studies in the lower incidence of postoperative complications compared to conventional studies.

The main obstacle in the use of suture technique is the uncertainty that prevailed over the concept of rigid fixation. To establish the tensile strengths of various suture materials various authors studied the biomechanical properties of the non absorbable suture materials. Chatakondu et al. established that stainless steel wire had significantly higher tensile strength when compared to TiCron non absorbable suture materials(34.91 vs 14.80 kg).[57] McGreal et al. subjected the cadaveric patella for 20,000 cycles of alternating flexion and extension cycles and concluded that the braided polyester suture material is an effective

alternative to stainless steel wire in tension-band fixation of patella.[65]Patel et al., in his study concluded that while comparing stainless steel with that of high resistance non absorbable polyester suture materials, the results showed equal strength in both the materials in terms of quality of fixation.[66]Later studies were made for the new materials like FiberWire evaluating their strength when compared to that of stainless steel for patella fracture fixation: Wright et al. demonstrated biomechanically that a double-stranded Fiber-Wire presents with a significantly higher initial load to failure than the stainless steel wire. The biomechanical test also established that FiberWire maintained its initial stiffness until failure.[67] This was confirmed by our study: Using a FiberTape patella fixation, we found no significant fracture displacement following knee mobilization. These findings were evident in our study due to the fact that the FiberTape that was used in the study did not yield any fracture displacement following post operative knee mobilization. Among the 24 patients in our study, one patient presented with mild loss of reduction post surgery(<4mm). This could be attributed to the fact that there may be adhesion and adjustment of the suture material through the surrounding peripatellar soft tissue which can happen even during simple application of load such as during quadriceps muscle contraction. Any significant loss of reduction, linked to FiberTape breakage or failure, did

not occur in the study. This clearly establishes the effectiveness of suture material. In addition, all treated fractures healed at an average of 3 months 8 days postoperatively. The study therefore establishes the fact that the high resistance non-absorbable suture material can act as a stable safe and highly efficient alternative to the conventional method of fixation.

Kumar et al., analysed a case series of 63 patella fractures who were treated by the conventional methods of fixation to elaborate on the findings of implant related complications. During the study, it was found that nearly one third of the patient required implant removal due to implant related complications and the rate went upto 40% for young individuals with age < 60 years. All these factors resulted in implant removal and re-surgery in these patients eventually. The timing of implant removal was a mean of 11 months (range 3-20).[68] However no cases in our present study with suture material needed re-surgery due to implant related complications or failure. Kumar's study reiterated the necessity for developing a new treatment strategy for surgical management of patellar fractures that eliminates the implant-related complications and hence the need for revision surgeries.[68]The common doubt with the use of suture material fixation of patella fractures is the effectiveness and sturdiness of the suture material in holding the fracture fragments together post-operatively when high loading forces are

transmitted across the patella. Wright et al., conducted a biomechanical study to solve this issue. He compared the strengths of double and single-stranded fiberwire with that of the routine 1.8mm stainless steel wire used for the tension band wiring of patella. The study demonstrated that FiberWire, both single- or double-strand, is more resistant than the stainless steel and that an in vivo study is justified and will result in greater patient satisfaction and decreased reoperation rates.[67] The limitation of the study is that the study was primarily conducted in the transverse fractures, however, these findings can be extrapolated to comminuted fractures as well. In line with the previous studies, no cases presented with fracture displacement due to implant failure in our series. In this present study, the implant used is superior in strength to the one used by Wright et al., in their study and hence produced excellent outcomes without exhibiting any material failure. Few studies evaluated the combined use of metallic implants like K-wire and cannulated screws with that of the high resistance sutures in place of stainless steel wires.[53,66,69] The studies gave good functional outcomes, but the rate of implant removal was still on a higher side. Gosal et al., performed a study comparing two groups for patella fracture fixation, one metallic group and the other a non-metallic group and concluded that the metallic group had higher infection and morbidity rates when compared to the non-metallic group and hence the study supported the use of non-metallic implants for patella fractures.[70]

Mao et al., conducted a study where he demonstrated better results with the use of nonmetallic material.[71]A retrospective study demonstrated comparable results between suture repair and fixation with metal implants for surgical management of inferior pole patella fractures.[72]Based on the above studies and results, we went ahead with the fixation strategy of using the FiberTape as a sole material in the construct with good functional results comparable to that of the conventional metallic fixation. The study included both the transverse and comminuted fractures into account. This implant did not present discomfort and did not need second surgeries for implant removal.

Limitations of the study that must be taken into account are this study is a single-center study with a relatively small sample of patients. Minor complications were observed (pain, knee stiffness) were observed during the course of the studyand all of them were conservatively treated and unrelated to the type of osteosynthesis performed. None of the patients presented with symptoms of discomfort secondary to implant that required re-surgery. Another limitation is there is no control group in the study. The total number of patients included in the study were 24. Among those, males were 16 and females were 8. According to fracture classification, tranverse were 14, comminuted were 7 and inferior pole

were 3. According to the age, number of patients above 50 were 12 and below 50 were 12.

SEX DISTRIBUTION

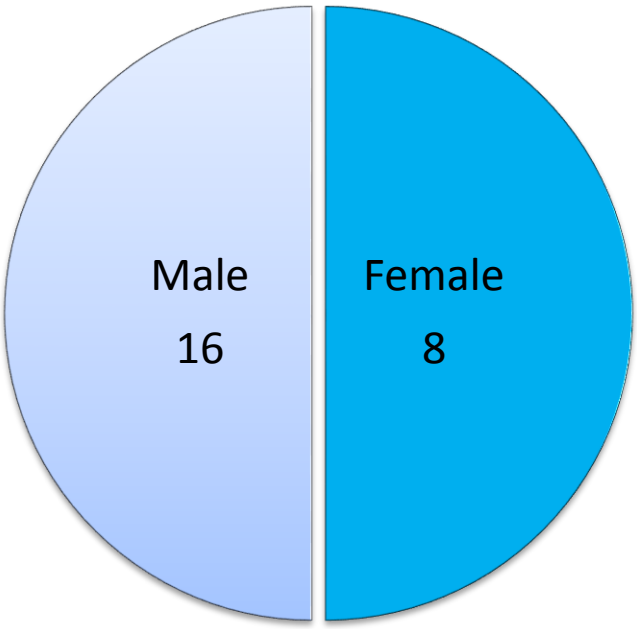

FRACTURE TYPE

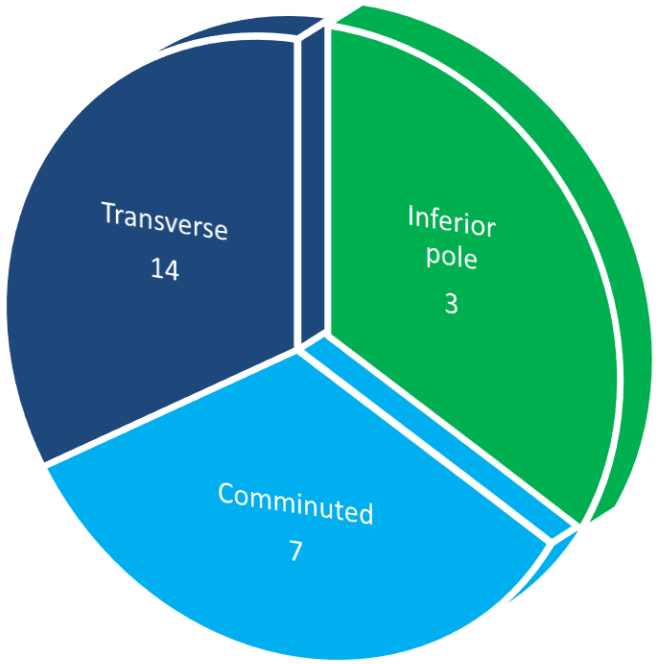

AGE DISTRIBUTION

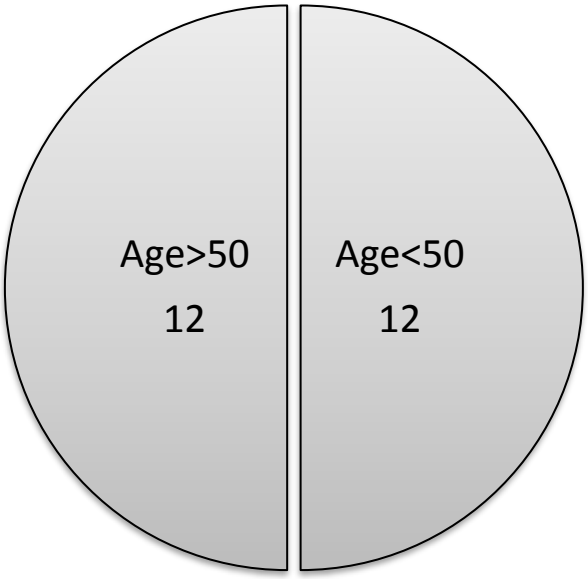

CONCLUSION

- The above study clearly demonstrates that the high resistance suture materials can be used as a potential alternative or may even be better to the existing prevalent fixation of patella fractures with stainless steel and wires.[62,63,64]
- Fibertape fixation presents a lot of advantages over the traditional stainless steel and wire fixation.[67]Biomechanically, fibertape has demonstrated tensile strength and stiffness equal to stainless steel and in certain specific parameters proved even more stronger than the stainless steel.[67]
- Intraoperatively, lesser soft tissue dissection is needed for the patella fractures fixed with fibertape. Hence, this procedure significantly reduces the intraoperative blood loss and also reduces the operative procedure time.[63]
- The complete non-metallic fixation rules out the most important complication of metallic fixation, which is the symptomatic hardware. It also brought down the reoperation rates and the infection rates post-surgery considerably.[63]

- Using a non-absorbable suture material also precludes the possibility of a second surgery needed for the implant exit.
- Hence, these high resistance suture materials like FiberWire and FiberTape can be used for efficient non-metallic fixation of patella on par with that of traditional metallic fixation with reduced complications and re-surgery rates.

BIBLIOGRAPHY

1. Bulchoz RW, Heckman JD. Rockwood & Green's Fracturesin Adults. Spanish 5th ed. Madrid, Spain: Marban Libros;2007:1776.

2. Galla M, Lobenhoffer P. Patella fractures. Chirurg.2005;76:987-997

3. Boström A. Fracture of the patella. A study of 422 patellar fractures. Acta Orthop Scand 1972;143(suppl):1–80**.**

4. Catalano JB, Iannacone WM, Marczyk S, et al. Open fractures of the patella: long-term functional outcome. J Trauma 1995;39:439-44.

5. Appel MH, Seigel H. Treatment of transverse fractures of the patella by arthroscopic percutaneous pinning. Arthroscopy 1993;9:119-21.

6. Smith ST, Cramer KE, Karges DE, Watson JT, Moed BR.Early complications in the operative treatment of patella fractures. J Orthop Trauma 1997;11:183-87.

7. Gardner MJ, Griffith MH, Lawrence BD, Lorich DG.Complete exposure of the articular surface for fixation ofpatellar fractures. J Orthop Trauma 2005;19:118-23.

8. Chiang CC, Huang CK, Chen WM, Lin CF, Tzeng YH, LiuCL. Arthroscopically assisted percutaneous osteosynthesis of displaced transverse patellar fractures with figure-eight wiring through paired cannulated screws. Arch Orthop Trauma Surg 2011;131:949-54.

9. Wild M, Thelen S, Jungbluth P, et al. Fixed-angle plates in patella fractures—a pilot cadaver study. Eur J Med Res 2011;16:41-46.

10. Reider B, Marshall J, Koslin B, et al. The anterior aspect of the knee joint. J Bone Joint Surg Am 1981;63(A):351–56.

11. Wiberg G. Roentgenographic and anatomic studies on the femoropatellar joint. Acta Orthop Scand 1941;12:319–410.

12. Baumgartl F. Das Kniegelenk. Berlin: Springer-Verlag; 1964.

13. Scapinelli R. Blood supply of the human patella. Its relation to ischaemic necrosis afterfracture. J Bone Joint Surg Br 1967;49-B:563–70.

14. Shim SS, Leung G. Blood supply of the knee joint: A microangiographic study inchildren and adults. Clin Orthop Relat Res 1986;208:1196.

15. Lieb F, Perry J. Quadriceps function. J Bone Joint Surg Am 1968;50-A:1535–48.

16. Bushnell BD, Byram IR, Weinhold PS, et al. The use of suture anchors in repair of the ruptured patellar tendon: A biomechanical study. Am J Sports Med 2006;34:1492–99.

17. Arendt EA, Fithian DC, Cohen E. Current concepts of lateral patella dislocation. Clin Sports Med 2002;21:499–519.

18. Nomura E, Inoue M, Osada N. Anatomical analysis of the medial patellofemoral ligament of the knee, especially the femoral attachment. Knee Surg Sports Traumatol Arthrosc 2005;13:510–15.

19. Kaufer H. Mechanical function of the patella. J Bone Joint Surg Am 1971;53:1551–60.

20. Sears FW, Zemansky MW. University Physics. Massachusetts, MA: Addison-Wesley; 1970.

21. Huberti HH, Hayes WC, Stone JL, et al. Force ratios in the quadriceps tendon and theligamentum patellae. J Orthop Res 1984;2:49–54.

22. Goodfellow J, Hungerford DS, Zindel M. Patello-femoral joint mechanics and pathology. 1. Functional anatomy of the patello-femoral joint. J Bone Joint Surg Br 1976;58(B):287–90.

23. Carpenter J, Kasman R. Fractures of the patella. J Bone Joint Surg Am 1993;75(A):1550–61.

24. Benjamin J, Bried J, Dohm M. Biomechanical evaluation of various forms of fixation with transverse patella fractures. J Orthop Trauma 1987;1:219–22.

25. Aglietti P, Insall JN, Walker PS, et al. A new patellar prosthesis. Design and application. Clin Orthop Relat Res 1975;107:175–87.

26. Anand S, Hahnel JCR, Giannoudis PV. Open patellar fractures: High energy injuries with a poor outcome? Injury 2008;39:480–84.

27. Noble H, Hakek M. Boutonniere-type deformity of the knee following patellectomy and manipulations. J Bone Joint Surg Am 1984;66-A:137–38.

28. Nord RM, Quach T, Walsh M, et al. Detection of traumatic arthrotomy of the knee using the saline solution load test. J Bone Joint Surg Am 2009;91:66–70.

29. Böstman O, Kiviluoto O, Nirhamo J. Comminuted displaced fractures of the patella. Injury 1981;13:196–202.

30. Böstman O, Kiviluoto O, Santavirta S, et al. Fractures of the patella treated by operation. Arch Orthop Trauma Surg 1983;102:78–81.

31. Chiroff RT. A new technique for the treatment of comminuted, transverse fractures ofthe patella. Surg Gynecol Obstet 1977;145(6):909–912.

32. Stern R, Harwin S. Spontaneous and simultaneous rupture of both quadriceps tendons. Clin Orthop Relat Res 1980;147:188–89.

33. Gupta RR, Johnson AM, Moroz L, et al. Patellar sleeve fractures in children: A case report and review of the literature. Am J Orthop (Belle Mead NJ) 2006;35:336–38.

34. Houghton GR, Ackroyd CE. Sleeve fractures of the patella in children: A report of three cases. J Bone Joint Surg Br 1979;61-B:165–68.

35. Andrews JR, Hughston JC. Treatment of patellar fractures by partial patellectomy. South Med J 1977;70:809–13.

36. Nummi J. Operative treatment of patellar fractures. Acta Orthop Scand 1971;42:437–38.

37. Ashby M, Shields C, Karmy J. Diagnosis of osteochondral fractures in acute traumaticpatellar dislocations using air arthrography. J Trauma 1975;15:1032–33.

38. Black JK, Conners JJ. Vertical fractures of the patella. South Med J 1969;62:76–77.

39. Dowd GS. Marginal Fractures of the Patella. Injury 1982;14:287–91.

40. Lotke PA, Ecker ML. Transverse fractures of the patella. Clin Orthop Relat Res 1981;158:180–84.

41. McMaster PE. Tendon and muscle ruptures: Clinical and experimental studies on the causes and location of subcutaneous ruptures. J Bone Joint Surg 1933;15:705–22.

42. Seligo W. Fractures of the patella. Reconstr Surg Traumatol 1971;12:84–102.

43. Oetteking B. Anomalous patellae. Anat Rec 1922;23:269–78.

44. Adams JD, Leonard RD. A developmental anomaly of the patella frequently diagnosed as fracture. Surg Gynecol Obstet 1925;41:601–4.

45. Brooke R. The treatment of fractured patella by excision. A study of morphology and function. Br J Surg 1937;24:733–47.

46. Groves, Ernest Hey W. A note on the extension apparatus of the knee-joint. Br J Surg 1937;24:747-8.

47. Blodgett W, Fairchild R. Fractures of the patella. Results of total and partial excision of the patella for acute fractures. JAMA 1936;106:2121–25.

48. Kelly D, Godfrey K, Johanson P, et al. Quadriceps rupture in association with the roentgenographic “tooth” sign: A case report. Orthopedics 1980;3:1206–8.

49. Haxton H. The function of the patella and the effects of its excision. Surg Gynecol Obstet 2008:389–95.

50. Malgaigne JF. Dennis System of Surgery. Philadelphia(PA): Lea Brothers; 1895.

51. Cameron JC. Transverse fracture of the patella. Glasgow Medl J 1878;10:289–94.

52. Lister J. A new operation for fracture of the patella. Br Med J 1877;2:850.

53. Muller ME, Allgower M, Schneider R, et al. Manual of Internal Fixation. Techniques Recommended by the AO Group. Berlin: Springer-Verlag; 1979:248–53.

54. Weber M, Janecki C, McLeod P, et al. Efficacy of various forms of fixation of transverse fractures of the patella. J Bone Joint Surg Am 1980;62(A):2150-20.

55. Camarda L. FiberWire tension band for patellar fractures. J Orthopaed Traumatol 2016;17:75-80.

56. Carpenter JE, Kasman RA, Patel N, Lee ML, Goldstein SA. Biomechanical evaluation of current patella fracture fixation techniques. J Orthop Trauma 1997;11:351–56.

57. Chatakondu SC, Abhaykumar S, Elliott DS The use ofnon-absorbable suture in the fixation of patellar fractures: a preliminaryreport. Injury 1998;29:23–27.

58. Carpenter JE, Kasman R, Matthews LS Fractures of thepatella. Instr Course Lect 1994;43:97–108.

59. Melvin JS, Mehta S Patellar fractures in adults. J AmAcad Orthop Surg 2011;19:198–207.

60. LeBrun CT, Langford JR, Sagi HC Functional outcomes after operatively treated patella fractures. J Orthop Trauma 2012;26:422–26.

61. Hoshino CM, Tran W, Tiberi JV et al., Complications following tension-band fixation of patellar fractures with cannulated screws compared with kirschner wires. J Bone Joint Surg Am 2013;95:653–59.

62. Hughes SC, Stott PM, Hearnden AJ, Ripley LG. A new and effective tension-band braided polyester suture technique for transverse patellar fracture fixation. Injury 2007;38:212–22.

63. Qi L, Chang C, Xin T et al., Double fixation of displaced patella fractures using bioabsorbable cannulated lag screws and braided polyester suture tension bands. Injury 2011;42:1116–20.

64. Yotsumoto T, Nishikawa U, Ryoke K, Nozaki K, Uchio Y. Tension band fixation for treatment of patellar fracture: noveltechnique using a braided polyblend sutures and ring pins. Injury 2009;40:713–17.

65. McGreal G, Reidy D, Joy A, Mahalingam K, Cashman. The biomechanical evaluation of polyester as a tension band for the internal fixation of patellar fractures. J Med EngTechnol 1999;23:53–56.

66. Patel VR, Parks BG, Wang Y, Ebert FR, Jinnah H. Fixation of patella fractures with braided polyester suture: a biomechanical study. Injury 2000;31:1–6.

67. Wright PB, Kosmopoulos V, Cote RE, Tayag TJ, Nana AD. FiberWire is superior in strength to stainless steel wire for tension band fixation of transverse patellar fractures. Injury 2009;40:1200–03.

68. Kumar G, Mereddy PK, Hakkalamani S, Donnachie NJ. Implant removal following surgical stabilization of patella fracture. 2010 Orthopedics 12:33.

69. Melvin JS, Mehta S. Patellar fractures in adults. J Am Acad Orthop Surg 2011;19:198–207.

70. Gosal HS, Singh P, Field RE. Clinical experience of patellar fracture fixation using metal wire or nonabsorbable polyester—a study of 37 cases. Injury 2001;32:129–35.

71. N Mao et al. Comparison of the Cable Pin System With Conventional Open Surgery for Transverse Patella Fractures. Clin Orthop Relat Res 2011;471 (7):2361-66.

72. Egol K, Howard D, Monroy A, et al. Patella fracture fixation with suture and wire: you reap what you sow. Iowa Orthop J 2014;34:63–67.

INSTITUTIONAL ETHICS COMMITTEE
GOVT. KILPAUK MEDICAL COLLEGE,
CHENNAI-10
Protocol ID. No.06/2016 Meeting held on 14/12/2016
CERTIFICATE OF APPROVAL

The Institutional Ethical Committee of Govt. Kilpauk Medical College, Chennai reviewed and discussed the application for approval "FUNCTIONAL OUTCOME OF PATELLA FRACTURE FIXATION USING HIGH RESISTANCE SUTURE MATERIAL" submitted by Dr.R.JayGanesh., Post Graduate in M.S.Ortho.,Govt.Kilpauk Medical College & Hospital, Chennai.

The Proposal is APPROVED.

The Institutional Ethical Committee expects to be informed about the progress of the study any Adverse Drug Reaction Occurring in the Course of the study any change in the protocol and patient information /informed consent and asks to be provided a copy of the final report.

DEAN
Govt. Kilpauk Medical College,
Chennai-10.

MASTER CHART

S.NO.	AGE	SEX	TYPE OF FRACTURE	TIME TO UNION (IN MONTHS)	FINAL ROM	FOLLOW UP PERIOD	SCORES		COMPLICATIONS	EXTENSOR LAG	OUTCOME
							LYSHOLM	BOSTMAN			
1.	45	M	TRANSVERSE	3m	0-130°	1yr 6m	94	28	-	-	Excellent
2.	65	F	COMMINNUTED	3m	0-130°	1yr 2m	92	28	-	-	Excellent
3.	58	M	COMMINNUTED	3m	0-130°	1yr 3m	96	29	-	-	Excellent
4.	69	M	INFERIOR POLE	3m 12d	0-120°	10m	90	28	-	-	Good
5.	34	M	TRANSVERSE	3m 8d	0-120°	11m	85	25	Displacement<4mm	-	Good
6.	44	F	TRANSVERSE	3m 15d	0-130°	1yr 3m	93	28	-	-	Excellent
7.	28	M	COMMINNUTED	3m	0-130°	1yr	93	28	-	-	Excellent
8.	74	M	TRANSVERSE	3m 8d	0-130°	1yr 2m	82	25	-	-	Good
9.	54	M	TRANSVERSE (TYPE 1 COMPOUND)	3m 12d	0-120°	1yr 4m	94	29	-	-	Excellent
10.	49	F	TRANSVERSE	4m	0-130°	1yr 5m	88	27	Superficial infection	-	Good
11.	66	F	INFERIOR POLE	3m 10d	0-130°	1yr 2m	95	30	-	-	Excellent
12.	77	M	TRANSVERSE (TYPE 2 COMPOUND)	3m	0-130°	1yr	86	25	-	-	Good
13.	45	M	COMMINNUTED	4m	0-120°	11m	87	26	Anterior knee pain	-	Good

S.NO.	AGE	SEX	TYPE OF FRACTURE	TIME TO UNION (IN MONTHS)	FINAL ROM	FOLLOW UP PERIOD	SCORES		COMPLICATIONS	EXTENSOR LAG	OUTCOME
							LYSHOLM	BOSTMAN			
14.	55	M	TRANSVERSE	3m	0-130°	10m	93	28	-	-	Excellent
15.	33	F	TRANSVERSE	3m	0-130°	1yr	94	28	-	-	Excellent
16.	41	M	TRANSVERSE (TYPE 1 COMPOUND)	3m	0-130°	1yr 1m	91	28	-	-	Excellent
17.	68	M	TRANSVERSE	3m 11d	0-130°	1yr 5m	93	29	-	-	Excellent
18.	29	F	COMMINNUTED	3m 8d	0-130°	1yr 4m	92	28	-	-	Excellent
19.	19	F	TRANSVERSE	3m	0-110°	1yr 2m	95	29	-	-	Excellent
20.	36	M	COMMINNUTED	3m 25d	0-120°	1yr	80	21	-	-	Fair
21.	75	M	INFERIOR POLE	3m 10d	0-130°	1yr 5m	96	30	-	-	Excellent
22.	28	M	TRANSVERSE	3m	0-130°	11m	95	29	-	-	Excellent
23.	57	M	TRANSVERSE	3m	0-130°	1yr 3m	92	28	-	-	Excellent
24.	69	F	COMMINNUTED	4m 5d	10-130°	1yr	79	20	Extensor lag	10°	Fair

Average time to union – 3months 8days. Average scores: lysholm – 96, bostman – 27. Complications – 4 (minor).