Dissertation on

A PROSPECTIVE ANALYSIS COMPARING STOPPA'S REPAIR WITH CONVENTIONAL REPAIR IN COMPLEX BILATERAL AND RECURRENT INGUINAL HERNIAS.

submitted in partial fulfillment of requirements of

MS DEGREE BRANCH I
GENERAL SURGERY

Of

THE TAMILNADU
Dr.M.G.R. MEDICAL UNIVERSITY
CHENNAI.

MADRAS MEDICAL COLLEGE AND RESEARCH INSTITUTE
CHENNAI – 600 003.

MARCH 2008

CERTIFICATE

This is to certify that the dissertation titled **"A PROSPECTIVE ANALYSIS COMPARING STOPPA'S REPAIR WITH CONVENTIONAL REPAIR IN COMPLEX BILATERAL AND RECURRENT INGUINAL HERNIAS"** is the original work done by **Dr.ANIRUDHAN. A.,** postgraduate in the department of general surgery, Madras Medical College, Government General Hospital, Chennai – 600 003 to be submitted to The Tamilnadu Dr.M.G.R Medical university, Chennai – 600 032, towards the partial fulfillment of the requirement for the award of M.S. Degree in General Surgery, March 2008.

Prof.V.Palani M.S.,
Addl.Prof
Department of General surgery
Madras Medical College
Chennai – 600 003.

Prof.N.Dorairajan
M.S,FRCS,FICS,FACS,FICA,
Professor and HOD,
Department of General Surgery
Madras Medical College
Chennai – 600 003.

Prof.T.P.Kalaniti M.D
THE DEAN
Madras Medical College and Govt.General Hospital
Chennai – 600 003.

ACKNOWLEDGEMENT

I am grateful to **Dr.Kalaniti M.D.,** The Dean, Madras Medical College and Government General Hospital, Chennai and **Prof.N.Dorairajan M.S., FRCS, FICS, FACS, FICA,** Head of the Department of Surgery for permitting me to utilize the clinical material in the Government Hospital, during the period of my Study.

I am greatly indebted to my chief **Prof.V.Palani M.S.,** for his valuable gidence and contribution in this study and for his constant encouragement during the study period.

I am thankful to my assistant Professors **Dr.Nagaraj M.S., Dr.Manivannan M.S., Dr.Periasamy M.S.D.O., Dr.Vijayakumar M.S.,** who have guided me through the study period and put forth their efforts to make this study a complete one.

I sincerely thank my family, my colleagues and my fellow post graduates for their help and support. Last but not the least I thank all my patients for their kind co-operation in carrying on this study successfully.

CONTENTS

On November 17, 1892, William s. Halstead of The Johns Hopkins School of Medicine read his classical paper, "The Cure of Inguinal Hernia in the Male". It begun as follows:

Shuh said, "if no other field were offered to the surgeon for his activity other than herniotomy, it would be worth while to become a surgeon and to devote an entire life to this service"……

INTRODUCTION

The reconstruction of the posterior barrier of the groin represents one of the major objectives in groin hernia repair. There are 2 primary methods used to achieve this objective: “tissue repair technique” and “tension-free repair”. Recently, tension-free repair has become the gold standard procedure for repairing inguinal hernias. Many techniques have been described by different authors. Tension-free repair involves the use of synthetic prosthetic materials for rebuilding the posterior inguinal wall. The prosthetic materials, now disposable, have a well tolerated bioreactivity, allow efficient fibroplasia, diminish postoperative pain, and significantly reduce the recurrence rate and convalescence period. The Stoppa procedure, or giant prosthetic reinforcement of the visceral sac (GPRVS), is performed by wrapping the lower part of the parietal peritoneum with prosthetic mesh. The mesh contributes to a physiological healing process that creates a special bilateral anatomical reinforcement in the inguinal region, which effectively prevents inguinal hernia recurrence. The procedure’s rationale is based on an elegant surgical and anatomical prosthetic placement that occludes the myopectineal ostium of Fruchaud. The GPRVS procedure requires wide dissection of the subfascial preperitoneal space. As a corollary, the GPRVS operation calls for the use of suction drainage. Sometimes this drainage procedure is responsible for longer hospitalization that may be as long as 9.7 days11. Since the description of GPRVS procedure, many surgeons have reported good outcomes;

Review of literature

The Evolution of Hernia Repair

Hernia (known as *breuk* in Dutch, *rompure* in French, *keal* in Greek and rupture in English) has plagued humans throughout recorded history, and descriptions of hernia reduction date back to Hammurabi of Babylon and the Egyptian papyrus (Figures 5 and 6).



Figure 5. Plates of ancient healing. Various trusses for containment of groin hernias.

Figure 6. Plates of ancient healing. Taxis for reduction of an incarcerated hernia.

Much of modern surgical technique results from the contributions of early surgeons (Tables 2 and 3), but it was not until the late 19th century that hernia surgeon Edoardo Bassini -- considered the father of modern day hernia surgery -- experienced any measurable degree of success in repairing hernias.

Table 3. Milestones in Hernia Repair: The Listerian Era

Marcy (1871)	Publication of original paper on antiseptic herniorrhaphy ("A New Use of Carbolized Catgut Ligature")
Czerny (1876)	Described ligating and excising the indirect peritoneal sac through the external ring
Kocher	Twisted and suture-transfixed the peritoneal sac in the

	lateral muscles. through the external ring
MacEwen (1886)	Reefed the peritoneal sac into a plug to block the internal ring.
Lucas-Championniere	Opened the external oblique aponeurosis to expose the entire inguinal canal.

Bassini: The Father of Modern Day Hernia Surgery

Bassini's aggressive approach was to perform "a radical cure of inguinal hernia," (the title of his presentation to the Italian Surgical Society in Genoa, in 1887). He reported only 8 failures in 206 hernia repairs during a 3-year period. His results were monumentally important, considering that before his work, failure rates ranged between 30% and 40% in the first postoperative year and almost 100% after 4 years.

Bassini's operation epitomized the essential steps for an ideal tissue repair.[7] He opened the external oblique aponeurosis through the external ring, then resected the cremasteric fascia to expose the spermatic cord. He then divided the canal's posterior wall to expose the preperitoneal space and did a high dissection and ligation of the peritoneal sac in the iliac fossa. Bassini then reconstructed the canal's posterior wall in 3 layers. He approximated the medial tissues, including the internal oblique muscle, transversus abdominus muscle and transversalis fascia to the shelving edge of the inguinal ligament with interrupted sutures. He then placed the cord against that newly constructed wall and closed the external oblique aponeurosis over it, thereby restoring the step-down effect of the canal and reforming the external inguinal ring (Figure 7).

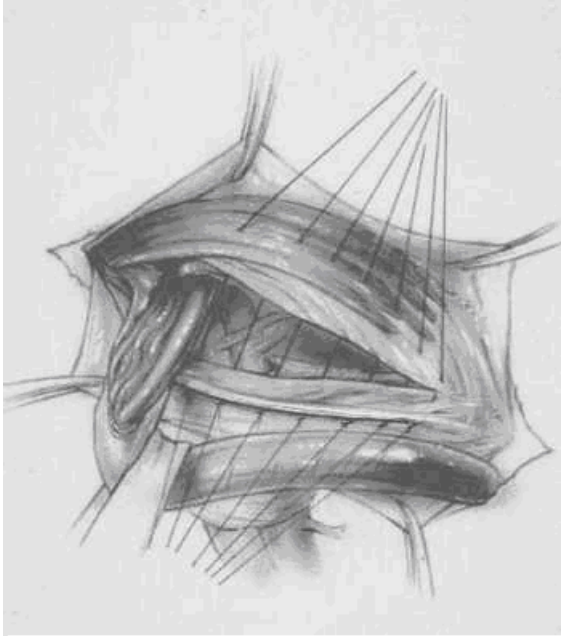

Figure 7. Original Bassini operation. The canal's posterior wall is opened and the deep epigastric vessels are exposed.

There have been numerous modifications of Bassini's original technique, although many of the less detailed renditions have yielded poor results. Those that avoided opening the posterior wall, for example, resulted in suture-line tension between tissues at the most medial part of the inguinal canal just cephalad to the pubic bone. Some help was afforded to the Bassini technique and other tissue repairs by the introduction of relaxing incisions by surgeons such as Wolfer, Halsted, Tanner, and McVay. (Figure 8).

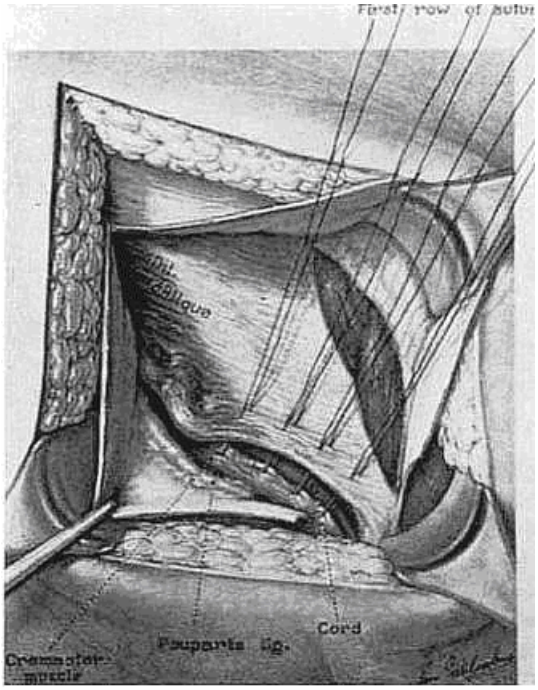

Figure 8. Relaxing incision. Required for most tissue repairs to reduce tension on suture line.

Many other innovative surgeons have contributed to improved outcomes in hernia repair.[8-11] Annandale[12] described a posterior approach to groin hernia repair in 1876, although it failed to gain favor among surgeons. In 1920, Cheatle revitalized the use of the posterior approach.[13] He used a preperitoneal approach to repair abdominal wall defects, initially, through a lower midline incision, and later through a Pfannenstiel incision. Cheatle advocated this approach for indirect hernias and described dividing the peritoneal sac, and leaving the distal part of the sac in the cord. The proximal peritoneum was closed, and the defect of the widened internal ring was tightly sutured to prevent reherniation through it.

This technique was not well received until Henry[14] and, later, McEvedy[15] began using it for femoral hernias. More recently, US surgeons Nyhus, Condon, and Harkins[16] adapted the preperitoneal approach to repair direct

and indirect groin hernias (Figure 9). In their procedure, abdominal wall defects were repaired with sutures and in some cases, mesh.

Figure 9. Preperitoneal suturing. The tranversus arch is sutured to the iliopubic tract.

Stoppa and colleagues[17] used the posterior approach to implant an impermeable barrier around the entire peritoneal bag, demonstrating that permanent repair of groin hernias does not require closure of the abdominal wall defect per se. Without having stated it, their repair used a tension-free technique (Figure 10). Wantz[18] furthered Stoppa's work by using it for unilateral hernia repair (Figure 11). Essential to these and all subsequent tension-free repairs is the application of a barrier prosthesis, usually a permanent mesh.[2] In Stoppa's approach, the mesh is held in place by intra-abdominal pressure, an application of Pascal's principle (Figure 12).

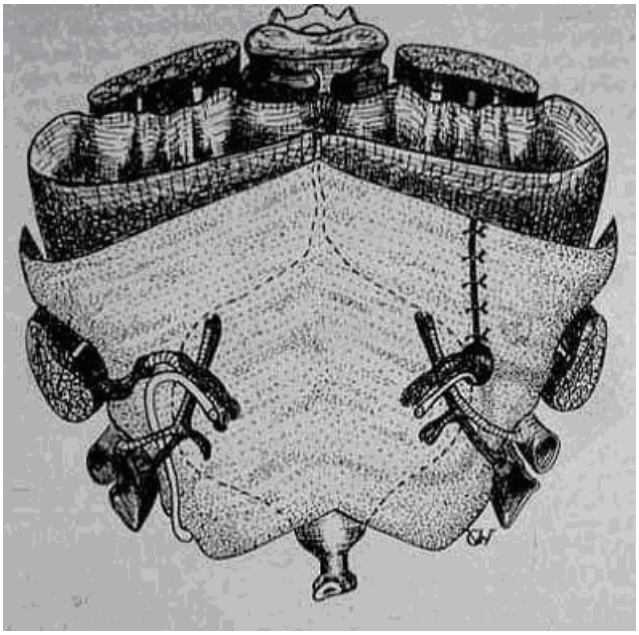

Figure 10. Stoppa procedure. The entire peritoneal bag is wrapped with a mesh graft. Expanding intra-abdominal pressure hold the graft in place without suture fixation.

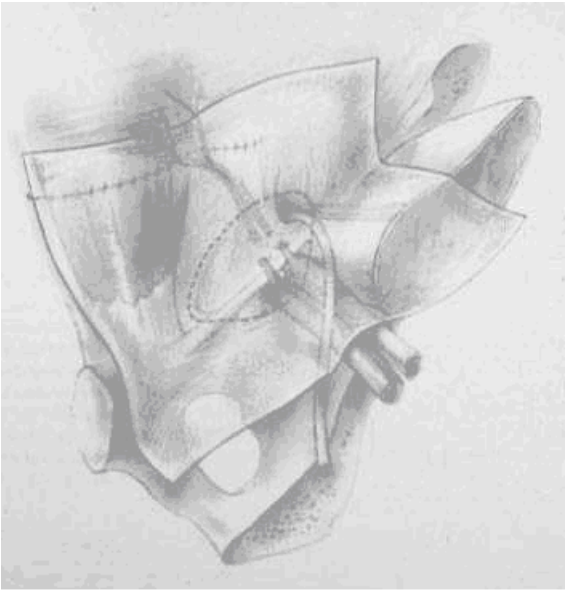

Figure 11. Wantz procedure. Mesh draped between the peritoneum and the myopectineal orifice for unilateral stoppa's repair.



Figure 12. Bathtub drawing. Water pressure in the tub holds the stopper in the drain.

Contemporary Classical Repairs

Among the most notable contemporary classic hernia repairs are the Bassini, Halsted, Shouldice and, McVay (Cooper Ligament) repairs.

Modified Bassini. Bassini's original repair yielded outstanding results for a pure tissue technique, but, as noted above, problems occurred when surgeons failed to open the posterior wall. This operation became known as the "modified" or "North American" Bassini (Figure 13). By not opening the posterior wall, the wall tissue was damaged in its most medial portion by sutures placed under tension, and recurrences resulted, primarily in the pubic tubercle area. Thus, the failure of this operation in its first year was more likely due to an overlooked second hernia or to poor surgical technique, rather than a metabolic or tissue defect that might predispose to recurrent hernia.

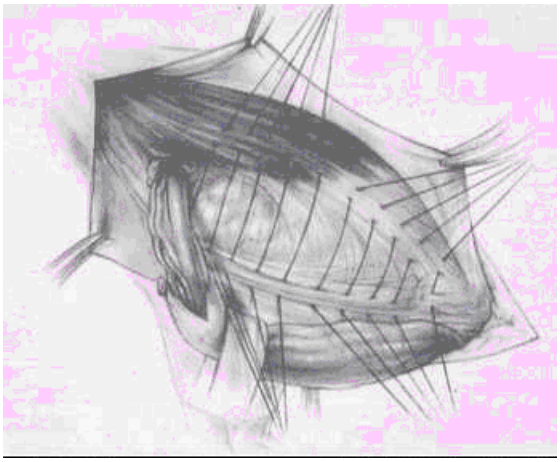

Figure 13. Modified Bassini. The posterior wall is not opened. Sutures placed between the transversus arch and the inguinal ligament create tension on the tissues approximated.

The Halsted operation. Halsted, a contemporary of Bassini, published multiple generations of his operations for hernia repair, each one attempting to correct a flaw in the previous version.[8] Like Bassini, Halsted opened the canal's posterior wall to do a high dissection and ligation of the peritoneal sac in the iliac fossa. He made a point to thin the cord as much as possible and then did a 4-layer repair of the canal's posterior wall (Figure 14).

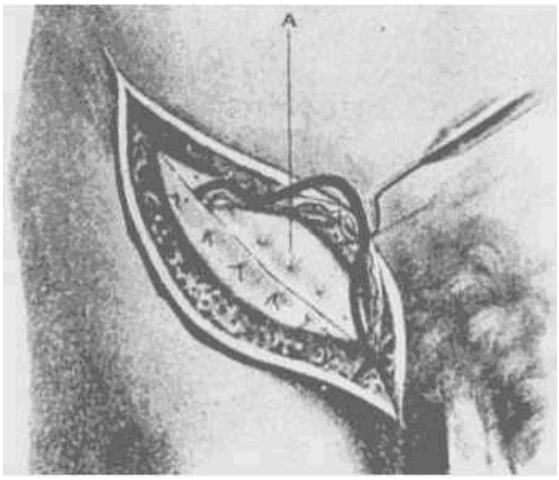

Figure 14. Halsted operation. The external oblique aponeurosis is closed under the spermatic cord thereby sacrificing the step-down effect of the canal.

Using the external oblique aponeurosis to reinforce the natural tissues of the posterior wall, Halsted's repair did not restore the step-down effect of the inguinal canal. This resulted in many recurrent indirect hernias and also produced an inordinately high incidence of postoperative hydroceles and atrophic testes. In a second version of his procedure, Halsted placed the cord against the posterior wall and sutured the transversus abdominus and internal oblique muscles over it for fortification. Although neither of these procedures is favored by surgeons today, Halsted made many other important contributions to surgery. Perhaps his most useful contribution to the advancement of hernia surgery was his demonstration that hernia repair could routinely be performed under local anesthesia.

Cooper ligament repair. Cooper was the first to describe the superior pubic ligament, although he never used it to surgically repair a groin hernia. The first Cooper ligament repair was done in 1897 by the Austrian surgeon, Georg Lotheissen, who used the superior pubic ligament in 2 patients who had lost their inguinal ligaments in the course of prior unsuccessful hernia repairs.[19]

McVay and Anson[20] revived Lothiessen's operation in 1942 (Figure 15). They considered the superior pubic ligament to be the ideal structure for reconstructing the posterior wall of an inguinal hernia, since it shares the same tissue plane and is derived from the same tissue origin as the transversus aponeurosis and the transversalis fascia. However, many surgeons who attempted this procedure found that it was sometimes difficult

to approximate the transversus arch to the Cooper ligament. Doing so frequently resulted in considerable suture-line tension -- enough to require one or more relaxing incisions. Patients complained of considerable and prolonged postoperative pain, and failure rates became unacceptable. This procedure has, however, had value to surgeons by demonstrating the strength of the superior pubic ligament and showing its utility in large and difficult hernia repairs, including incisional hernias. It is a reliable structure to which prosthetic material can be fixed when a large defect must be spanned.

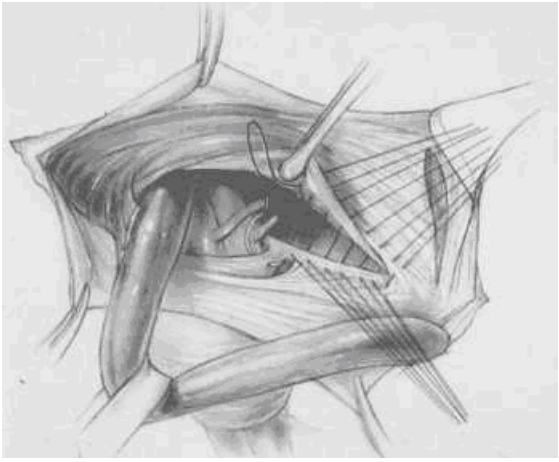

Figure 15. Cooper ligament repair. Approximation of the transversus arch to the superior pubic ligament creates more sutureline tension than any other pure tissue repair. A transition stitch must be used to avoid injury to the femoral vein.

Shouldice repair. Canadian surgeon E.E. Shouldice contributed substantially to hernia surgery in the second half of the 20th century. He founded a clinic that has since become a hospital devoted exclusively to the treatment of abdominal wall hernias. The Shouldice operation for hernia repair revitalizes Bassini's original technique.[21] It applies the principle of an imbricated posterior wall closure with continuous monofilament suture. At

the Shouldice hospital, continuous stainless-steel wire is used for all layers of the repair, including the ligatures used in the subcutaneous layer (Figure 16). Local anesthesia is routinely used and bilateral hernias are usually repaired separately, 2 days apart. Patients walk to and from the operating room, begin exercise therapy on the day of surgery, and resume their usual activities within a reasonable time after the operation.

Figure 16. Shouldice repair. The posterior wall is imbricated to reconstructed and reinforced in 4 layers.

An unusual feature of the procedure is the routine sacrifice of the lateral cremasteric bundle, a structure that contains the external spermatic vessels and the genital branch of the genitofemoral nerve. Shouldice surgeons have not reported any ill effects related to this step. In fact, before using this technique, pubic tubercle recurrences were unacceptably high. The minor sensation loss that results from dividing that nerve has not proven to be a substantial or longstanding disability. However, when the lateral flap of the cremasteric fascia is sacrificed, ptosis of the testicle will occur. This can be prevented by fixing the distal pedicle of the cremasteric fascia to the external oblique when the canal is restored.

The Shouldice Hospital's specialized approach to hernia repair includes close patient follow-up. Because the Shouldice group believes that weight represents a critical factor in the success of all hernia surgery, the hospital often defers surgery until an overweight patient reaches an individualized, target weight.

The Shouldice repair has been considered the gold standard of hernia repairs for the last 4 decades, although its use has declined since the introduction of various tension-free prosthetic repairs. The Shouldice repair remains an excellent option, however, and has produced the best and most enduring results of any other pure tissue repair.

Use of Prosthetics in Hernia Repair

The need for a satisfactory prosthesis for hernia repair has been recognized for more than a century. Various materials, including autografts (the patient's own tissue), have been tried. The most successful of the autografts is fascia lata, which has been used as suture material, a pedicle graft, and as a free transplanted graft. However, in addition to requiring a second operation to harvest it, fascia lata weakens and fails over time and dissolves in the presence of infection.

Artificial prostheses. Many authors have attempted to define characteristics of the ideal prosthetic material for hernia repairs (Table 4), although attempts to achieve this "ideal" have met with varying degrees of success (Tables 5 and 6). No currently available prosthesis is perfect or free of problems, and the choice of material thus requires compromise.[18] Surgeons do, however, have a large array of products from which to choose.

Table 4. Characteristics of an Ideal Prosthesis

The ideal prosthetic mesh should:
Not be physically modified by tissue fluids
Be chemically inert
Not excite inflammatory or foreign body reaction
Be non carcinogenic
Not produce allergy or hypersensitivity
Be capable of resisting mechanical strain
Be capable of being fabricated in the form required, and constructed in a way such that sutures or cutting will not cause the mesh to unravel or fray
Be sterilizable[21,22]
Be permeable and allow tissue in growth within it
Stimulate fibroblastic activity to allow incorporation into tissue rather than sequestration or encapsulation
Be sufficiently pliable so as not to cause stiffness or to be felt by the patient
Strong enough to resist bursting by the maximum forces that can be created by intra-abdominal pressure or from an outer force

Table 5. Metal Prosthetic Graft Material

Silver filigree mesh (1900)	Became brittle and fractured and eventually extruded causing multiple sinuses and fistulas.
	Fractured and caused sinus formation.
Toilinox (stainless steel)	Set up electrolyte reactions between ingredients if composition varied.

Table 6. Nonmetal Synthetic Prosthesis

Nylon (1944)	Replaced rubber, metals and animal products. Initially used for sutures, later knitted or woven into patches for hernia repair; disintegrates in tissue and loses most of its tensile strength within 6 months.
Polyethylene mesh (1958) Polypropylene mesh (1962)	High-density polyethylene mesh (*Marlex*, 1958) resistant to chemicals and sterilizable, but unraveled after being cut. Modified to polypropylene mesh (1962). Available under various trade names (*Hertra-2, Marlex, PROLENE, Surgipro, Tramex, Trelex*). Available as a flat mesh as well as 3-dimensional devices (*Altex, Hermesh3, PerFix Plug, PROLENE Hernia System*).[23]
Polyester mesh (*MERSILENE*) (1984)	Composed of polyester fiber with the characteristics of filigree; can be inserted into narrow spaces without distortion.[16]
Expanded polytetrafluoroethylene	Teflon product; produces minimal adhesions when placed intraperitoneally.[22,24] Does not allow significant fibroblastic or angiogenic ingrowth; must be removed if infection occurs.
Polyglycolic acid mesh (*Dexon*) Polyglactin 910 mesh (*Vicryl*)	Absorbable mesh; loses strength after 8 -12 weeks; should not be used as a sole prosthesis for the repair of abdominal or groin hernias

Complications related to the use of prosthetics. Materials composed of polypropylene and polyester insight a prompt and strong fibroblastic tissue response with minimal inflammation. This response consists of macrophages and giant cells, most of which eventually disappear. Fibroblastic activity allows rapid integration of the prosthesis into tissues; however, contraction of the enveloping scar tissue creates undesirable deformation of unsecured pieces of the monofilament; its free margins tend to curl, and small pieces roll up. There also have been some reports in the literature of freeform and preformed prosthetic mesh products migrating.

Serum or blood that accumulate in dead spaces surrounding any prosthesis becomes an excellent media for infection. Suction drainage is therefore advisable to eliminate dead space as well as to remove serum collections. Intestinal obstruction and fistula formation are serious complications and often require removal of the mesh/prosthesis. When a prosthesis is placed inside the peritoneal cavity, various degrees of visceral adhesions form depending upon the type of material used. When this is unavoidable, omentum or an absorbable prosthesis should be interposed between the mesh and the bowel.

Treatment of infection involves the application of basic surgical principles. Although most infections occur acutely, delayed infections involving nonabsorbable prostheses can occur months or years later. In the case of an acute infection of a groin hernia repair, it is advisable to quickly and widely open the wound (including the subcutaneous layer down to the external oblique) to avoid chronic sinus formation. A specimen should be taken for culture and sensitivity, irrigation and antibiotics started and healing observed

by secondary intention. Frequent wound check to remove accumulated fluid is advisable.

If a prosthetic mesh had been used in the repair, it can usually be left in place if the above measures are employed promptly. If the wound closes, but a sinus continues to drain, it is likely that the mesh and all old suture material will need to be removed. Unlike early infection, when the mesh can be salvaged, late infection involving mesh requires the complete removal of the unincorporated material, although the incorporated mesh may be left undisturbed.

If the surgeon encounters an inflammatory granuloma in the course of repairing a recurrent inguinal hernia, it is prudent to avoid using a new prosthesis. Gram staining of the inflammatory granuloma at the time of surgery is not sufficiently reliable to exclude subsequent infection. In most cases of persistent infection related to a prior prosthetic repair, the culprit is the nature of the suture material rather than the graft itself. Multifilament and braided sutures, such as silk and cotton should be avoided.

Tension-Free Hernia Repair

The most important advance in hernia surgery has been the development of tension-free repairs. In 1958, Usher described a hernia repair using *Marlex* mesh. The benefit of that repair he described as being "tension-eliminating" or what we now call "tension-free" (Figure 17). Usher opened the posterior wall and sutured a swatch of *Marlex* mesh to the undersurface of the medial margin of the defect (which he described as the transversalis fascia and the conjoined tendon) and to the shelving edge of the inguinal ligament. He

created tails from the mesh that encircled the spermatic cord and secured them to the inguinal ligament.[22]

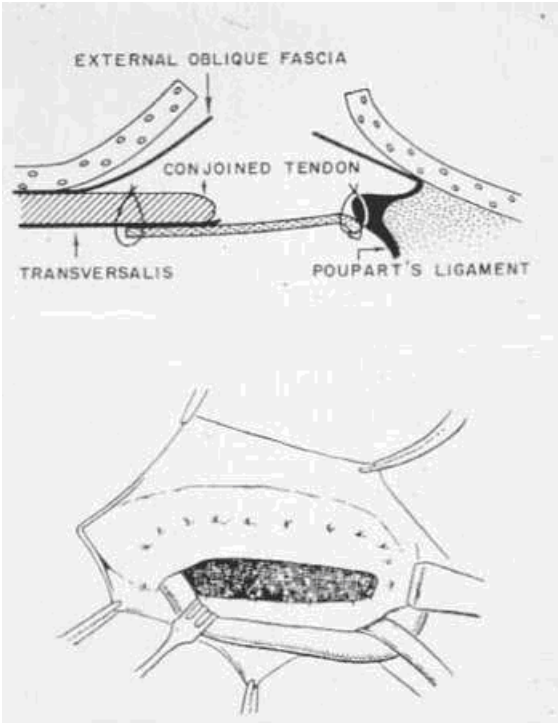

Figure 17. Usher's repair. The mesh is sutured from the transversalis fascia and conjoined tendon medially across the defect to the shelving edge of the inguinal ligament establishing a "tension-eliminating" repair.

Every type of tension-free repair requires a mesh, whether it is done through an open anterior, open posterior, or laparoscopic route. The most common prosthetic open repairs done today are the Kugel patch repair, the Lichtenstein onlay patch repair, the *PerFix* plug and patch repair, and the *PROLENE Hernia System* bilayer patch repair (Figures 18-21).

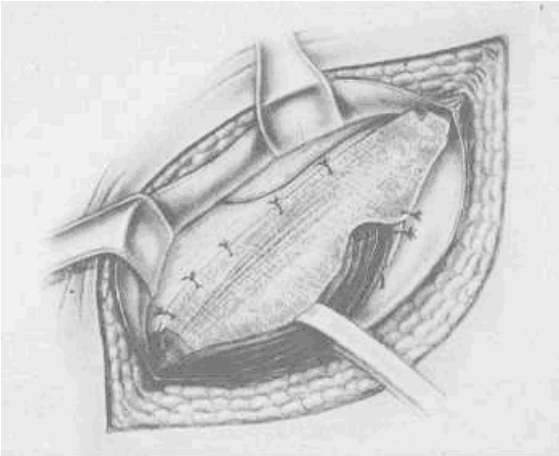

Figure 18. Lichtenstein onlay patch. Mesh is sutured from the transversus arch to the shelving edge of the inguinal ligament creating a "tension-free" repair.



Figure 19. *Perfix* Plug. Flower-shaped polypropylene mesh plug with multiple petals, and onlay graft with slit to accommodate the spermatic cord.

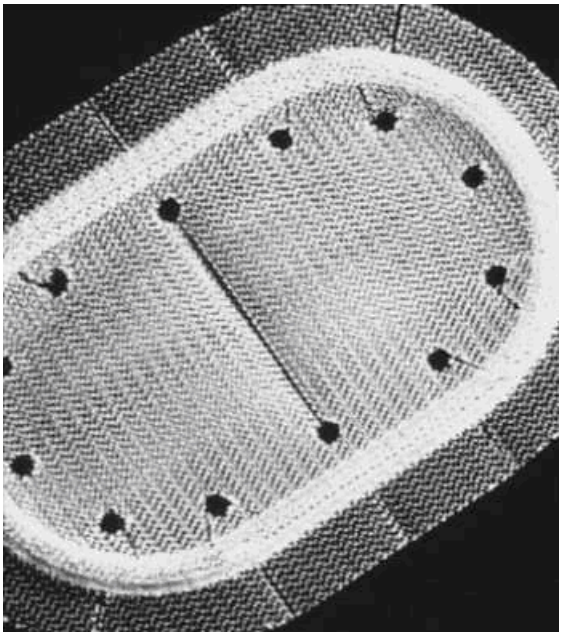

Figure 20. Kugel Patch. "Race-track" oval shaped polypropylene mesh graft with pocket for insertion and larger gauge polypropylene ring to hold graft's flat shape.

PROLENE Hernia System (PHS) bilayer patch repair. Bilayer polypropylene mesh. Three-in-one device with round disc for properitoneal repair, plug effect of connector, and oblong shaped onlay component.

The Stoppa-Rives giant prosthetic repair of the visceral sac is also an important tension-free technique done through an open posterior approach[17] (Figure 10). It has been described as "the ultimate weapon" to repair recurrent hernias. In this procedure, the surgeon uses a large sheet of Mersilene mesh to separate the peritoneal bag and its contents from the defect(s) in the abdominal wall. The defects in the abdominal wall are left unsutured.

Newman introduced a less complicated tension-free repair procedure in which the posterior wall is invaginated and *Marlex* mesh is sutured as an onlay graft to the transversus arch superiorly, the inguinal ligament inferiorly, and the pubis medially. The tails are crossed lateral to the cord and fixed to the inguinal ligament lateral to the internal ring. This technique does not require opening the posterior wall, and the mesh acts more like a lid than a stopper. Newman performed the procedure on 1600 patients and gifted this operation to Lichtenstein, who popularized it to become the most frequently done hernia repair in the United States and possibly worldwide.

The *PerFix* Plug repair of direct and indirect hernias is an adaptation of Gilbert's free-formed umbrella-shaped plug, which was initially used as a plug in the internal ring for treatment of indirect inguinal hernias (Figure

22). Currently, the *PerFix* Plug is manufactured and placed in the internal ring and fixed with sutures to the surrounding tissues. When a direct hernia is present, the *PerFix* Plug is used in a similar fashion. When pantaloon or unusually large direct hernias are present, multiple plugs are sewn together to repair the defect. In addition to the plugs, an onlay patch is provided, which can be used with or without sutures over the posterior wall and around the spermatic cord lateral to the internal ring.

Figure 22. The *PerFix* plug repair of direct and indirect hernias. It adapts Gilbert's free-formed umbrella-shaped plug, which was initially used as a plug in the internal ring for treatment of indirect inguinal hernias.

The Kugel patch is a polypropylene, oblong-shaped mesh with a thickened polypropylene thread that encourages the mesh to flatten. The Kugel approach is through a small incision above the internal ring. The preperitoneal space is entered and dissected free. An indirect sac is retracted or transsected, and the threshold of the internal ring is thereby freed of the peritoneal sac. The prosthesis is inserted and fixed in place with a single suture and then held in place by the natural intra-abdominal forces (Pascal's principle) (Figure 23). In this procedure, the spermatic cord anterior to the interior ring is not handled. This approach is designed to protect the internal ring and posterior groin wall as well as the femoral canal.

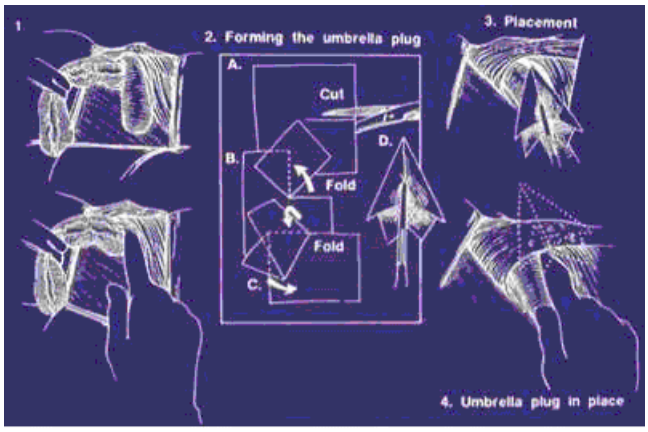

Figure 23. A cork in a barrel works more effectively than a cork outside the barrel.

The *PROLENE Hernia System* bilayer patch device (Figure 21) has a combined onlay graft (like a Lichtenstein repair) and underlay graft (like a Stoppa or Kugel patch); these are held together by a connector (like a plug). The external oblique aponeurosis is opened through a 5-cm groin incision, the spermatic cord is elevated, and an anterior space is created for placement of the onlay component of the device (Figure 24). If an indirect hernia sac is present, it is invaginated through the internal ring. If a posterior wall hernia is present (direct hernia), the defective tissue is circumscribed. In either case, the preperitoneal space (space of Bogros) is dissected free with a 4 x 4 sponge (Figure 25).

Figure 24. Finger dissection of the anterior space is best done when first reaching this tissue plane.

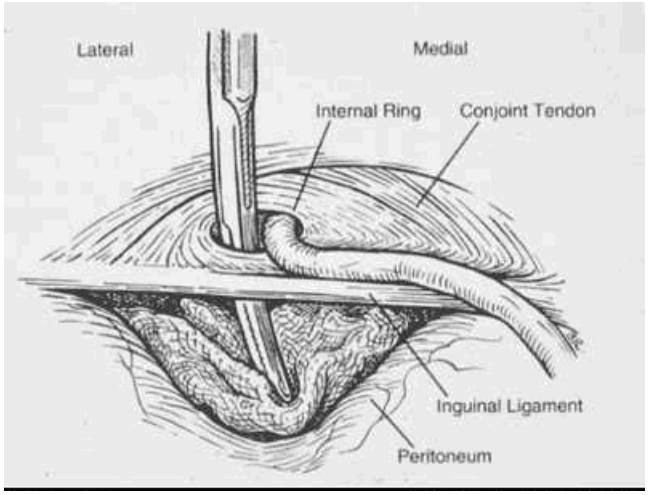

Figure 25. Sponge dissection, posterior space. Sponge traction in the properitoneal space is more effective in creating the space than is the gloved finger of the surgeon.

The head, neck, and shoulders drawing in Figure 26 illustrates the concept of dissecting the shoulders of the peritoneal sac. Separating the peritoneum from the transversalis fascia develops the shoulders. The *PROLENE Hernia System* is inserted through either of these defects. If a pantaloon hernia exists, the deep epigastric vessels are divided, and the two defects are converted to a single defect. The entire *PROLENE Hernia System* is inserted through the posterior wall defect or internal ring. The underlay component is deployed so that the edge of the graft is at complete distraction from the connector (Figure 27). The lateral portion of the underlay graft descends caudad to the Cooper ligament, thereby protecting the femoral canal. The onlay graft is extracted and placed against the posterior wall into the anterior space beneath the external and internal oblique muscles and laid against the transversus arch down to and over the pubic tubercle. A few sutures are placed in the onlay graft. At minimum, one is placed at the pubic tubercle,

one at the mid portion of the transversus arch, and one at the mid portion of the inguinal ligament. The spermatic cord is accommodated with a central or lateral slit in the onlay component.

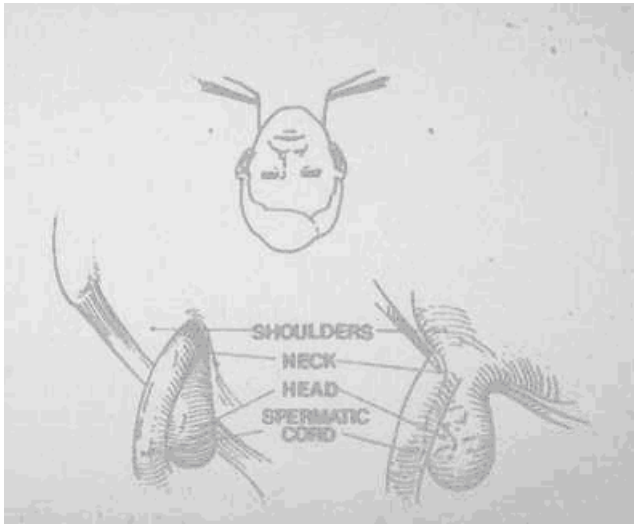

Figure 26. Freeing the shoulders of the sac creates the optimum space.

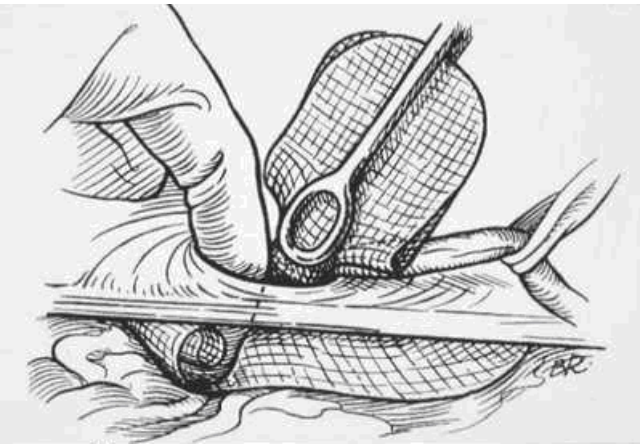

Figure 27. The forefinger unfurls the underlay component of the *PROLENE Hernia System* device.

Classification of Groin Hernias

Classifications in science and medicine are important communication tools.[23] As such, effective groin hernia classifications provide the following:

- serve as an anatomic blueprint for the dissection and functional evaluation of the canal and its contents
- assist in determining the most appropriate repair for the particular problem
- help correlate postoperative symptoms, duration of convalescence, and degree of disability
- allow correlation of postoperative results and long-term follow-up with the original problem.

Many hernia classifications have been proposed in the last 4 decades, which meet these criteria to varying degrees. The most popular classifications are described below.

Casten[24] divided hernias into 3 stages:

- Stage 1: an indirect hernia with a normal internal ring
- Stage 2: an indirect hernia with an enlarged or distorted internal ring
- Stage 3: all direct or femoral hernias

The Halverson and McVay[25] classification divided hernias into 4 classes:

- Class 1: small indirect hernia
- Class 2: medium indirect hernia
- Class 3: large indirect hernia or direct hernia
- Class 4: femoral hernia

Ponka's[26] system defined 2 types of indirect hernia:

(1) uncomplicated indirect inguinal hernia and (2) sliding indirect inguinal hernia and three types of direct hernias: (1) small defect in the medial aspect of Hesselbach's triangle near the pubic tubercle; (2) diverticular hernia in the posterior wall with an otherwise intact inguinal floor; and (3) a large diffuse direct inguinal hernia of the entire floor of Hesselbach's triangle.

Gilbert[23] designed a classification for primary and recurrent inguinal hernias done through an anterior approach (Figure 28). It is based on evaluating 3 factors:

1. presence or absence of a peritoneal sac
2. size of the internal ring
3. integrity of the posterior wall of the canal

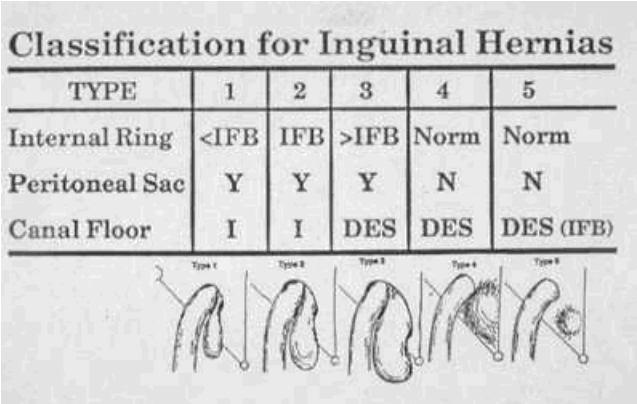

Classification for Inguinal Hernias

TYPE	1	2	3	4	5
Internal Ring	<IFB	IFB	>IFB	Norm	Norm
Peritoneal Sac	Y	Y	Y	N	N
Canal Floor	I	I	DES	DES	DES (IFB)

Figure 28. Gilbert classification. Five types of primary and recurrent inguinal hernias.

Types 1, 2 and 3 are indirect hernias; types 4 and 5 are direct.

- Type 1 hernias have a peritoneal sac passing through an intact internal ring that will not admit 1 fingerbreadth (ie,<1 cm.); the posterior wall is intact.

- Type 2 hernias (the most common indirect hernia) have a peritoneal sac coming through a 1-fingerbreadth internal ring (ie, </=2 cm.); the posterior wall is intact.
- Type 3 hernias have a peritoneal sac coming through a 2-fingerbreadth or wider internal ring (ie, >2 cm.).
- Type 3 hernias frequently are complete and often have a sliding component. They begin to break down a portion of the posterior wall just medial to the internal ring.
- Type 4 hernias have a full floor posterior wall breakdown or multiple defects in the posterior wall. The internal ring is intact, and there is no peritoneal sac.
- Type 5 hernias are pubic tubercle recurrence or primary diverticular hernias. There is no peritoneal sac and the internal ring remains intact. In cases where double hernias exist, both types are designated (eg, Types 2/4). Descriptors such as *L, Sld., Inc., Strang. Fem*. are used to designate lipoma, sliding component, incarceration, strangulation and femoral components.

In 1993, Rutkow and Robbins[27] added a type 6 to the Gilbert classification to designate double inguinal hernias and a type 7 to designate a femoral hernia.

Nyhus[28] developed a classification designed for the posterior approach based on the size of the internal ring and the integrity of the posterior wall. According to this scheme

- Type 1 is an indirect hernia with a normal internal ring;
- Type 2 is an indirect hernia with an enlarged internal ring;
- Type 3a is a direct inguinal hernia;

- Type 3b is an indirect hernia causing posterior wall weakness;
- Type 3c is a femoral hernia;
- Type 4 represents all recurrent hernias.

Of these and other classifications that have been proposed, a recent survey indicated that the most commonly used classifications by members of the American Hernia Society are the classical Indirect/Direct designation, that of Nyhus, and that of Gilbert/Rutkow and Robbins. Most recently, Zollinger[29] proposed a unified classification of groin hernias that combines one of the most commonly used individual classifications and is applicable to the anterior and posterior approaches. The principal feature of Zollinger's combined classification is the recognition that a large indirect hernia defect also imposes on the posterior wall, and in effect becomes a combined defect.

Groin Hernia

Groin hernias are the most common type of hernias. Several risk factors have been implicated in the development of groin hernias, including obesity, pregnancy, and perhaps most importantly, aging, which studies suggest, contributes significantly to the breakdown of tissues resulting in the development of some groin hernias.[30] Today, when the average life expectancy is 74 years, the incidence of direct hernias is 40% compared with 5% at beginning of the 20th century, when life expectancy was 47 years.[31]

Symptoms

A burning sensation in the groin occasionally precedes the development of a palpable hernia. Patients with hernia commonly report discovering a mass in the groin. Typically, the patient notes that the mass is gone when he awakens in the morning, but it reappears on arising. A dull sensation may be

experienced as the day progresses and the patient has been upright for many hours. Patients may also have difficulty getting into or out of an automobile, and some note a gas bubble in the groin. Changes in work or leisure activities to accommodate the discomfort are common.

Coughing or severe straining as occurs with constipation or prostatism frequently precipitates the clinical appearance of the hernia. Any sudden increase in the size of the mass suggests incarceration or the development of a sliding component. Direct hernias are usually easier to reduce and are less prone to incarcerate or strangulate than indirect hernias. Sliding hernias more commonly are indirect, but when any part of the urinary bladder protrudes through a direct defect, it too is considered a sliding hernia (Figure 29).

Treatment

Most groin hernias are clinically important and should be repaired electively, before they begin to enlarge. Hernia enlargement is associated with higher surgical failure rates and adjusted lifestyle. This holds true for all indirect, femoral, recurrent, and most direct hernias. When a hernia does begin to enlarge or is no longer reducible, repair should be planned promptly.

Today, most hernia surgery is performed on an outpatient basis under regional or local anesthesia (see below), generally with adjunctive sedation managed by an anesthesiologist. Only patients who refuse a regional anesthetic or those undergoing laparoscopic surgery receive general anesthesia. As a result, factors such as very young or old age, obesity, and coexisting cardiac, respiratory, or malignant disease are no longer considered contraindications to elective hernia repair. In addition, extensive

or elaborate preoperative laboratory testing is no longer routine and is only done when specifically indicated or required by hospital regulations. Young, healthy adults can usually have a hernia repair performed with minimal preoperative laboratory work, provided they have a normal preoperative history and physical examination.

Risks of Delayed Surgery

The risks of delaying surgery can be considerable, with the most important concern being the chance of incarceration with strangulation. If this occurs, emergency surgery must be performed, regardless of the patient's medical status, comorbid medical conditions, or concomitant medications, including the use of anticoagulants. Although trusses (Figure 30) have been used to defer or obviate surgery, they are often used incorrectly, adding to scar formation, which must be managed when the repair is eventually done. Scarring is associated with increased bleeding, postoperative swelling, testidynia, and prolonged testalgia, all of which could negatively affect an ideal result.

Wound Healing and Systemic Implications of Groin Hernia

Whether the hernia repair involves tissues alone, or a prosthetic graft, the normal healing process involves a cascade of activities. Platelets are released and surround the traumatized tissue. Macrophages and neutrophils move in to clean the area of debris and bacteria, and to elaborate soluble substances vital to the healing process. A fibrin matrix is deposited that becomes polymerized and oriented into an ideal cross-linking configuration forming reliable collagen. Work by Peacock and Madden[32] on defective cross-

linking and the imbalance of collagen metabolism, as well as the observations by Read[33] regarding the correlation of groin hernia disease with arterial aneurysm and nicotine consumption in smokers suggest that some metabolic factors, including collagenolysis and elastase, contribute to the clinical eventuality of a direct inguinal hernia.

Anesthesia

The use of anesthesia in hernia surgery has changed dramatically in recent years. Many surgical procedures such as hernia repair, previously done on inpatients under general anesthesia, are now routinely performed on an outpatient basis using local or regional anesthesia.

Local anesthesia. Local infiltration can be performed on virtually any inguinal hernia, but it is usually reserved for patients of average weight with a primary unilateral hernia. Surgery for recurrent hernias, bilateral hernias, and hernias in obese patients are generally performed with either a subarachnoid or epidural block. The local anesthetic is usually a combination of a rapid-acting anesthetic, such as lidocaine or chloroprocaine, and a longer-acting agent, such as bupivacaine, which also provides several hours of postoperative pain relief.

Addition of sodium bicarbonate to buffer local instillation decreases the pain at the injection site and accelerates the onset of the anesthetic effect. Addition of epinephrine may provide some hemostasis and prolong the effects of local anesthetics. Many surgeons, however, prefer to observe bleeding points at the time of surgery, rather than risk a postoperative hematoma, when the effects of the epinephrine wear off.

The local infiltration technique consists of specific, layered infiltration (Figure 31). The most sensitive areas are the skin, the external oblique aponeurosis, and the neck of a hernia sac or a lipoma. Once the external oblique aponeurosis is reached, a small area of it should be exposed and infiltration through it should be accomplished. When the external oblique is opened, infiltration can be performed around the obvious nerves, over the symphysis, and where the cord structures are adherent to an indirect sac at the internal ring -- an area that is almost always sensitive during dissection.

Use of local anesthesia allows the patient to cough and strain during the procedure to identify additional hernias, as well as test the competency of the repair at the end of the surgery. An anesthesiologist is present to monitor the patient's vital signs and provide intravenous sedation (eg, midazolam, propofol). Other advantages of local anesthesia include fewer side effects, such as nausea, and the ability of the patient to walk and void immediately after surgery.

Regional anesthesia. Subarachnoid block or spinal anesthesia has been used as an anesthetic for more than 90 years. It is generally simple for the anesthesiologist to carry out and is almost always effective. Major disadvantages of spinal anesthesia are occasional hypotensive episodes, which may occur after the patient leaves the hospital. Spinal headaches are also a problem in younger patients, as is occasional urinary retention in the older age group. Skinny needle technique has greatly reduced the incidence of spinal headaches.

Segmental epidural block provides an excellent option for repair of inguinal hernia. It can be done either with a single injection or with a continuous-flow catheter, so that additional anesthetic can be added as needed. The latter option is especially useful in bilateral hernia repairs, when the total duration of the surgery may not be known preoperatively. Generally, the patient is able to cough and help the surgeon during the procedure and can usually ambulate earlier postoperatively than when a subarachnoid block is used.

However, a satisfactory epidural block is more difficult to perform than a spinal anesthetic, especially in older patients, when the epidural space may be difficult to locate (Figure 32). In trained hands, the incidence of inadvertent subarachnoid or intravascular injection is minimal. Epidural block has good patient acceptance, and most people who have had this type of anesthesia for a prior hernia repair request it if they require a second repair.

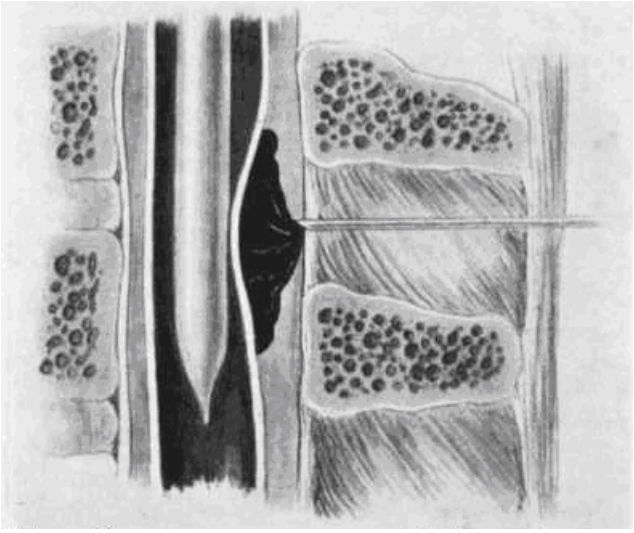

Figure 32. Epidural and spinal injections. Anesthetic is injected into the epidural or the subarachnoid space.

The fear that some patients may have of undergoing surgery while they are conscious (albeit sedated), limits the use of local or regional anesthesia to some degree. However, sensitive preoperative counseling by the surgeon and the anesthesiologist will usually allay the patient's fears. Performing regional anesthesia requires the development of tactile skill techniques. As a result, in less experienced hands, inadequate regional anesthesia may occur. In such cases, the surgeon and anesthesiologist must decide between local infiltration and general anesthesia to complete the operation.

Other options. Other techniques, such as caudal anesthesia or paravertebral block, are used less commonly for inguinal hernia repair because of the general acceptance of the above techniques. General anesthesia provides complete relaxation and calms the patient's fears. When carried out by a well-trained anesthesiologist, the risks posed by general anesthesia are not appreciably greater than with caudal or spinal anesthesia.[34] There is no question, however, that general anesthesia causes more postoperative nausea. Several studies have also shown a greater need for postoperative pain medication with general anesthesia, compared with local or spinal anesthesia.[35]

Although field blocks (ie, blocking the iliohypogastric and ilioinguinal nerves) are described in most anesthesiology textbooks, they are not used very often in general practice. A field block requires additional time for the anesthetic to become effective as well as supplemental injections during the surgery to block the genital femoral nerve and other sensitive areas encountered during the procedure. Except that the initial injection is done 10 to 15 minutes before beginning the procedure, field block is indistinguishable from local infiltration.

In all cases, the surgeon should make the choice of anesthesia after carefully discussing the situation with the patient. The decision should reflect the patient's preferences and medical and health status as well as whether the hernia is unilateral or bilateral, primary or recurrent. Leaving the "choice" of anesthetic to the anesthesiologist or the patient may not allow the surgeon to take advantage of the ideal anesthetic technique for the specific repair procedure.

Femoral Hernia

Increased intra-abdominal pressure as occurs with pregnancy, obstructive pulmonary disease, constipation, prostatism, and so forth, has been implicated in the etiology of femoral hernia. Glassow[36] estimated that 15% to 45% of femoral hernias were directly related to prior inguinal hernia repair, more often direct or recurrent herniorrhaphies than primary indirect type. This may be explained by the unusual tension placed on the inguinal ligament at the prior suture repair.

The most common type of femoral hernia (98.5% of cases) is the easiest to repair (Figure 33). Prevascular and retrovascular femoral hernias are extremely difficult to repair but fortunately they present infrequently. Successful repairs have been done through the anterior and posterior approaches. When strangulation is suspected, the posterior approach is advised to allow intraperitoneal inspection and bowel resection if necessary. In other cases, an anterior approach allows repair of the defect with various prosthetic devices, such as a freehand rolled mesh plug (Lichtenstein), a prosthetic umbrella, the *PerFix* Plug and the *PROLENE Hernia System*. Pure

tissue repair of femoral hernias carries a high failure rate compared with the use of prosthetic devices.

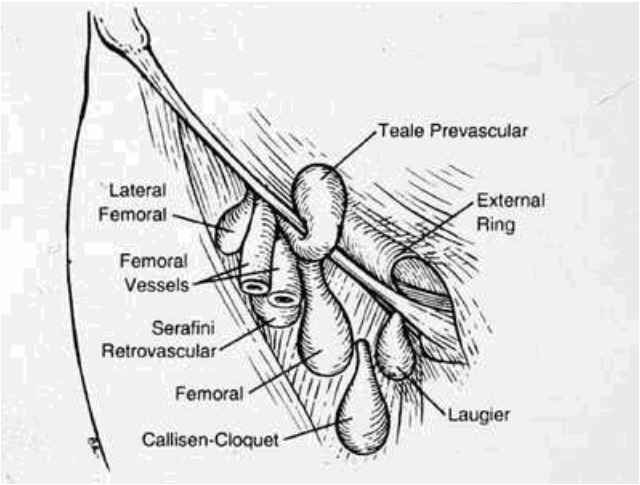

Figure 33. Various presentations of femoral hernias.

Triple Triangles of the Groin

Understanding the "triple triangles of the groin" is important to the management of femoral interstitial and recurrent indirect inguinal hernias (Figure 34). The inguinal ligament anteriorly and the iliopubic tract posteriorly separate the femoral triangle from the medial and lateral triangles. When the femoral triangle is viewed from an anterior approach, it is bounded by the inguinal ligament superiorly, the pectineus fascia posteriorly, and the iliopsoas muscle laterally.

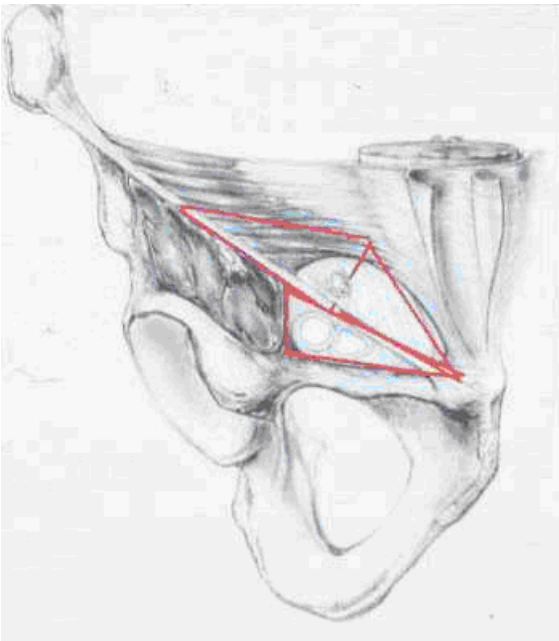

Figure 34. Triple triangles of the groin.

The medial triangle (Hesselbach's, Hessert) is bounded by the inguinal ligament, the lateral border of the rectus muscle and the deep epigastric vessels. The lateral triangle is bounded by the deep epigastric vessels medially, and by the inguinal ligament laterally to a variable point approximately halfway between the deep inguinal ring and the anterior iliac spine (the lowest point on the inguinal ligament that the internal oblique and tranversus abdominus muscles are fused). The superior boundary is a line connecting that point on the inguinal ligament to the medial reach of the deep epigastric vessels.

Surgery performed for primary hernia in any one of these triangles carries important implications for all 3 triangles. Thus, when placing an impermeable prosthetic mesh patch or mesh device to repair the presenting hernia, the surgeon must consider the imbalance of resistance created on the surrounding tissues of the other triangles.

Pediatric Inguinal Hernias

Inguinal hernias in the pediatric age group are almost always indirect, the result of persistent patency of the processus vaginalis. The processus vaginalis is an out-pouching of the peritoneal cavity that follows the inguinal canal down into the scrotum or the labium majora. The natural tendency of this processus in the male is to become obliterated, forming a fibrous tract within the spermatic cord. More distally, this area is called the tunica vaginalis of the testicle and the canal of Nuck in females.

The processus vaginalis is still open in most newborns. It normally becomes fibrosed during infancy, and by age 2 most are completely obliterated. The persistent processus in itself does not indicate the presence of a hernia. Bowel or other intra-abdominal contents must come into the processus for it to clinically become a hernia. The processus may close inconsistently, leading to a funicular hernia, a scrotal hernia, or, if it remains open distally, a hydrocele (Figure 36).

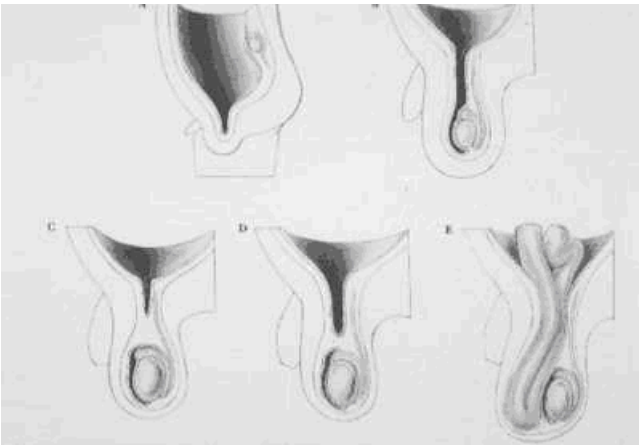

Figure 36. Various degrees of closure of the processus vaginalis.

The persistence of the processus vaginalis seems to be more common on the right side, which explains why right-sided hernias are twice as common as left sided hernias. Although persistence of a processus is much less common in females than in males, it does occur and is usually bilateral.

Diagnosis

Diagnosis of inguinal hernias in children can be difficult unless there is an obvious scrotal hernia. Often the mother discovers the hernia when the child is coughing or crying. Confirming the presence of a hernia is difficult through the inguinal canal because of its small size, and the diagnosis is often made by history rather than by physical examination.

Once the diagnosis of an inguinal hernia is made in a child it should be repaired. Although some authors disagree as to the advisability of operating on very young, premature infants, there may be a higher incidence of incarceration or strangulation in these young children. In general, the rule is to operate as soon as the clinical diagnosis is made. The question as to exploration of the contralateral side is also somewhat controversial. If there is an obvious clinical hernia on the opposite side, then there is no debate. Experts disagree, however, when no hernia is clinically evident. Proponents of bilateral exploration (and those who favor laparoscopy) point to the significant incidence of contralateral hernias that are found on exploration. Opponents of this view believe that the risk of injury to the vas deferens or testicular vessels contraindicate routine second-side exploration.[38,39]

Repair of Pediatric Hernias

Repair of most pediatric hernias requires ligation of the true neck of the sac through the internal ring. The sac should be examined to rule out the presence of a sliding component. This is especially important in female patients, as it may contain a Fallopian tube or ovary that could inadvertently be ligated. In such cases, the sac should be freed, its excess removed, and the entire remaining sac reduced into the abdomen. Since there are no cord

structures in female patients, the internal ring can be closed. Occasionally, in male patients with a very dilated internal ring, suturing the transversalis fascia at the ring will narrow the ring.

Although they rarely occur, hematoma and infection can complicate repair of pediatric hernias. Occasionally, an acute recurrence of a hernia occurs because the sac has not been ligated at its true neck. High dissection and ligation of the sac are essential to prevent recurrence. While initial repair of pediatric hernia usually remains successful, it is not uncommon for patients in mid or later life to develop direct recurrent hernias.

In general, prosthetics should not be used in small children. However, hernias in full-grown teenagers can be safely repaired with mesh. As in all patients, incarcerated or strangulated hernias in children are true surgical emergencies. A gentle attempt should be made to reduce the hernia, although this often is unsuccessful. If the incarcerated hernia cannot easily be reduced, the patient should have surgery promptly. Of special concern with incarcerated hernias in girls is that the ovary and tube may have a tendency to infarct. In boys, if the hernia is associated with a undescended testicle, both the hernia repair and the orchidopexy should be done at the same time, since hernia repair alone will cause scarring and make subsequent orchidopexy difficult to perform.[40,41]

Complications Associated With Hernia Surgery

Infection

Before the use of prosthetics, hernia repair was considered a clean, low-risk operation that did not require prophylactic antibiotics. Because the use of prosthetics later was erroneously associated with increased infection risk,

many surgeons believed that antibiotic prophylaxis would be beneficial and cost-effective. In fact, poor results with infection following mesh repairs were not related to the mesh but almost always to the use of multifilamented suture material, such as silk or cotton.

In a multicenter study of more than 2000 hernia repairs, the use of antibiotics did not significantly affect the rate of infection for primary or recurrent hernias, whether or not mesh was used.[42] Considering the setup requirements of personnel and material in addition to the cost of the antibiotic, the cost for routine antibiotics in hernia surgery is considerable. It has been demonstrated, however, that infection rates increase in patients older than 60 years. As a result, the authors recommend a single perioperative dose of antibiotic in that group of patients.

Seroma

A seroma is a collection of serum in a surgical wound (Figure 37). It contains leukocytes and may also contain some red blood cells. The size of the collection relates to the amount of dissection done between tissue planes and the amount of dead space remaining in the wound. Seromas form in herniorrhaphy wounds done without mesh but with greater frequency following mesh repairs, due to both tissue trauma and foreign body reactions.[43] Tissue trauma causes a reabsorption imbalance of fluid that escapes from damaged venous and lymphatic capillaries. The foreign body reaction can be measured by histologic examination for macrophages and giant cell formation.

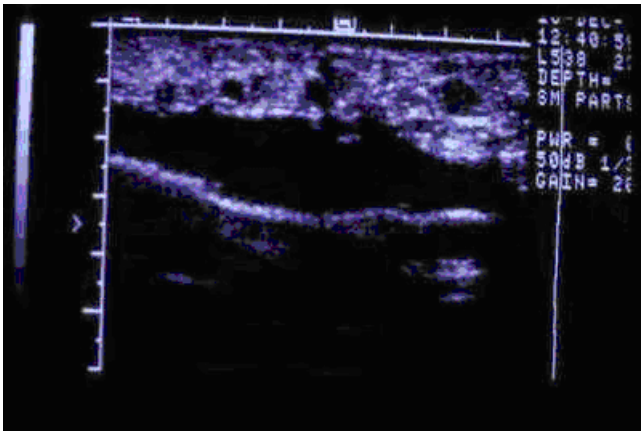

Figure 37. Seroma collection in a patient 4 months after incisional hernia repair.

Typically, a seroma presents on the third or fourth postoperative day. The patient calls frantically worried that a hernia has abruptly recurred. When examined, the wound appears raised but is not inflamed or tender. The mass is fluctuant and the fluid ballotable. Ultrasonography confirms the clinical diagnosis. Treatment consists primarily of observation and expectation. Aspiration is rarely necessary, and in most cases the seroma will completely reabsorb in 2 to 3 weeks. Early aspiration is futile, as the fluid will reaccumulate within a day or 2, and each needle puncture risks the chance of introducing infection into the culture-rich medium. Conflicting reports exist as to whether mesh increases the incidence of seroma formation.

Hematoma

Opening the wound, evacuating the hematoma, and allowing it to close by secondary intention best treats bleeding into the wound. If the bleeding occurs into the scrotum, however, drainage is more difficult. Blood gets into the many tissue levels of the scrotum and is much more difficult to evacuate. A common postoperative phenomenon is ecchymosis, or "bruising" of the skin around the incision, at the base of the penis and the skin of the scrotum.

Strangely, bruising occasionally occurs away from the incision, including settling on the opposite side. The explanation for this phenomenon remains unclear

Postoperative Neuralgia

An estimated 15% to 20% of patients who undergo hernia repair experience some degree of postoperative neuralgia, parasthesias, neuropraxia, or hypesthesia for up to 6 months after their surgery.[44]

Symptoms of neuralgia include pain or a burning sensation in the inguinal region, which may radiate to the genitalia and the upper thigh. It may be aggravated by activity and relieved by hip flexion. Tinel's sign helps in identifying a trigger point causing the problem. If localized anesthetic blocks confirm the diagnosis of a specific postoperative neuralgia, and the patient is willing to accept some area of numbness, remedial operations are available. However, before surgery is performed for postoperative neuralgia, the patient should have a multidisciplinary evaluation that includes preoperative psychological testing and counseling.

The remedial procedures entail resection of the nerve trunk carried as far proximal as possible. Starling advises resecting the offending nerve and removing any prosthetic mesh that was previously implanted. The incidence of postoperative neuralgia appears to be the same whether or not mesh was used in the previous repair.

Earlier claims that laparoscopic hernia repair would reduce postoperative neuralgia have not been borne out.[45]

Many patients who opted for laparoscopic repair suffer with incapacitating neuralgia of the lateral femoral cutaneous nerve. There are also a few reported cases of ilioinguinal neuralgia following laparoscopic herniorrhaphy.[45]

Laparoscopic Hernia Repair

In light of the huge benefit gained by the laparoscopic approach to cholecystectomy -- and the rapid acceptance of that technique by most surgeons -- much interest was given to the concept of laparoscopic hernioplasty, which was introduced widely around 1990. However, many surgeons who explored this approach to hernia repair found the learning process to be longer and more challenging than that seen for laparoscopic cholecystectomy or open herniorrhaphy.[46-48] For this and other reasons, the optimal and most appropriate use of the laparoscopic technique remains a subject of debate among general surgeons.[49]

Laparoscopic herniorrhaphy requires general rather than local anesthesia, takes more time, costs more,[50,51] and carries the potential for more significant surgical complications than those encountered with open techniques.[48] As a result, at least one large trial has concluded that laparoscopy should remain the province of specialists, with open procedures the approach of choice for most general surgeons,[47] although it is unclear exactly what proportion of hernia repairs are performed laparoscopically, most current estimates are around 15%. Still, proponents note, this approach adheres to the concept of the tension-free repair and has excellent long-term results with minimal risks when employed by those surgeons skilled in advanced laparoscopic techniques.

Of interest, though not well known, is the fact that the laparoscopic approach to hernia repair actually predated the laparoscopic cholecystectomy. In 1982, Ger reported the repair of inguinal hernias in 13 patients with a stapling device; the 13th patient in this series underwent a laparoscopic repair, the earliest recorded attempt utilizing this technique.[52] This patient, who underwent the procedure in 1979, was free of recurrence at the time of the report. Later, Ger and colleagues reported the use of a "herniostat," a prototypical stapling device to close the neck of the hernia sac in beagle dogs.[53]

Bogojavalensky initially presented the use of a prosthetic biomaterial in this repair in 1989.[54] He placed a roll of polypropylene mesh into indirect hernias of female patients, followed by a closure of the back of the hernia sac with sutures. This repair received little attention but was revisited by Shultz.[55] Preliminary results from these repairs were promising, but later follow-up of these patients revealed that a recurrence rate of 16%-20% could be expected.[56] This incidence of failure of this repair resulted in its abandonment.

Various techniques have been devised for laparoscopic herniorrhaphy. Initially, the approach involved a simple ring closure, but this technique failed because the deeper aponeurotic tissues could not be approximated without tension in the repair.[40] The plug-and-patch technique also failed to match the results of its open counterpart.[41,42] This was followed by the development of the intraperitoneal onlay mesh technique (IPOM).[57,58]

The IPOM technique focused on the placement of an intra-abdominal piece of a prosthetic biomaterial (usually a polypropylene or expanded polytetrafluoroethylene fixed with some type of stapling device); the repair

did not involve the dissection of the peritoneum. The advantages of this repair were the lack of significant dissection of the preperitoneal space and the rapid placement of the prosthesis. The recurrence rate, however, was somewhat higher that that of the more widely adopted repairs developed later.[59]

The IPOM was largely rejected because of the potential for the mesh anchored to the peritoneum to slip into the hernia defect, resulting in bowel adhesions and/or intestinal obstruction.[43-45] It was believed that proper fixation of the biomaterial could only be insured by its placement in direct contact with the fascia of the transversalis muscle. This led to the development of the transabdominal preperitoneal (TAPP) repair method. (Figure 42). In this approach, the preperitoneal tissue is removed from the fascial layer by directly entering the intra-abdominal cavity. This is similar to the IPOM approach, except that TAPP involves more dissection of the preperitoneal space. With TAPP, which became very popular among laparoscopists, the prosthesis is placed into the preperitoneal space following dissection, fixed with a stapling device or a spiral tacking device, and covered.[60] The preperitoneal tissue is secured into its original position at the completion of the procedure. The first reported use of the TAPP approach was by Schultz,[55] who, in an initial series, used a portion of polypropylene mesh placed over the defect to cover the myopectineal orifice. The surgeon closed the peritoneum with clips to cover the prosthetic biomaterial.

.

Some surgeons believed that the dissection required by the TAPP method could be accomplished without entry into the abdominal cavity and would

minimize the potential for injury to the intra-abdominal organs while eliminating the exposure of the bowel to the prosthetic biomaterial. This repair, the totally extraperitoneal approach (TEP), has been increasingly favored among experienced laparoscopists[46] (Figure 43) and appears to be the most commonly used laparoscopic repair today.[62] Experience also has shown that use of a larger prosthesis decreases the recurrence rate.[63]

.

The TEP approach generally employs a preperitoneal dissection balloon that is introduced via a subumbilical incision. The balloon is inflated, creating the preperitoneal space for the hernia repair. Once this is completed, the laparoscope is inserted to visualize the working area. Two or 3 additional working ports are then placed to complete the necessary surgical dissection in which to adequately expose the inguinal floor and the myopectineal orifice.

Once the hernia defects are visualized, a polypropylene or expanded polytetrafluoroethylene biomaterial is then inserted and secured to the transversalis fascia and/or Cooper's ligament with tacks or staples. The material is of a size that completely covers the myopectineal orifice. This represents an advantage of the laparoscopic technique over anterior mesh or plug alone, in that it will cover all areas that are at risk of inguinal or femoral herniation. The results of this method have compared favorably with the open tension-free repair.[64] The reported recurrence rate in over 10,000 hernia repairs was 0.4%.

There is continuing and vigorous debate over the relative clinical and economic pluses and minuses of laparoscopic and open hernia repair techniques. Several dozen studies in the past 2 years alone have not settled this controversy.[65,66] There is general agreement that the costs of the laparoscopic approach are greater than those associated with open procedures,[50,51] although some studies have found those higher costs can be reduced significantly with experience.[67] Controlled trials and case series reported in the literature to date have reached variable conclusions when comparing clinical outcomes; a number found laparoscopy superior to open repairs in certain patients in terms of morbidity, patient satisfaction, return to work, and return to normal activity.[48,68,69] Some found overall clinical results comparable.[70-72] A number of others found open repairs equal or superior to laparoscopy when a variety of outcome measures were taken into account.[48,49,73,74]

Ongoing trials, including one large series still under way, may bring more clarity to this debate. Many consider this to be an ideal repair of the hernia recurrence or for the repair of bilateral inguinal hernias. Others deem the risks and costs of this procedure to be too great to justify its use for any patient. Open repair remains the clear choice of the majority of general surgeons who perform this procedure. But proponents of the laparoscopic approach note that this procedure will find its place within the surgical armamentarium and, as with most general surgical operations, will be most appropriately used by those clinicians with the technical skills necessary to perform it optimally.

Aim of the study

1) To evaluate Stoppa's (giant prosthetic reinforcement of the visceral sac) repair as a treatment for complex and B/L inguinal hernias.

2) To compare the operation time, immediate post op events and mean duration of hospital stay between the Stoppa's and the conventional bilateral hernia repair group.

3) To compare the risk of recurrence, if any, between the two groups.

4) To study the cost effectiveness of the Stoppa's repair over the conventional bilateral hernia group.

Patients and methods :

Fifty patients, of ASA I or II, attending the Govt.GH Chennai in our surgical unit large bilateral inguinal hernias or recurrent hernias or complex groin hernias are prospectively studied over a period 2 years from sep 2005 – sep 2007. Twenty five patients, mostly with recurrence and large bilateral hernias underwent Stoppa's procedure and the other twenty five with mostly bilateral hernias and that associated with hydrocele underwent bilateral conventional hernia repairs.

The following parameters are studied:

- Pre operative diagnosis and the procedure done.

- Mean duration of the operation (calculated from the time of incision to wound dressing after closure)

- Mean rate of wound infection (reported when frank pus discharge or showing positivity in culture and sensitivity)

- Mean rate of seroma collection (noted clinically as pink non purulent discharge or collection)

- Duration of stay in the hospital

- Local recurrence if any

The patients are followed up in the 6th month and 1 year post operatively for any event of recurrence. The patients who are discharged early are advised to report immediately in case of wound infection or seroma collection.

Materials :

A (6” x 6”) monofilament poly propelene mesh (undyed) is used on each side for a conventional hernia repair and due to non availability of big size mesh the same are fashioned in to a single mesh according to the pelvic measurements of the patient and thus are individualized.

A CASE OF RIGHT COMPLEX GROIN HERNIA
(POST APPENDICECTOMY INCISIONAL HERNIA AND RT INDIRECT INGUINAL HERNIA)

TUBE DRAINS USED ROUTINELY IN STOPPA'S REPAIR
THIS IS A CASE OF UNILATERAL GPRVS

Observations

Preoperative diagnosis and the procedure done

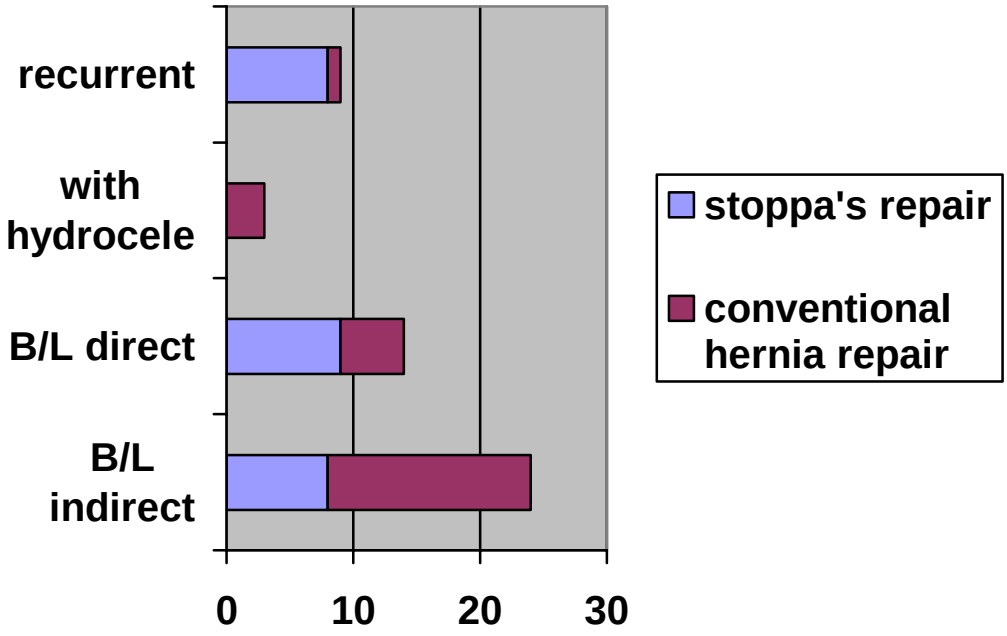

Comparison of mean operation time in minutes

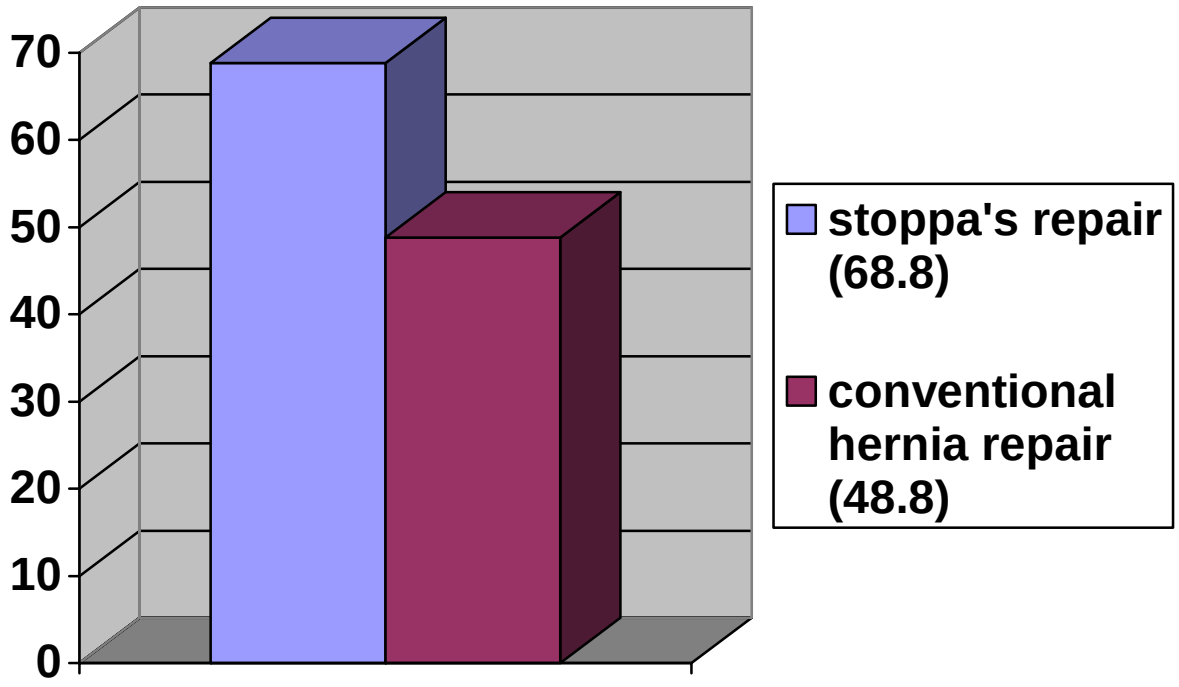

Comparison of mean duration of hospital stay in days

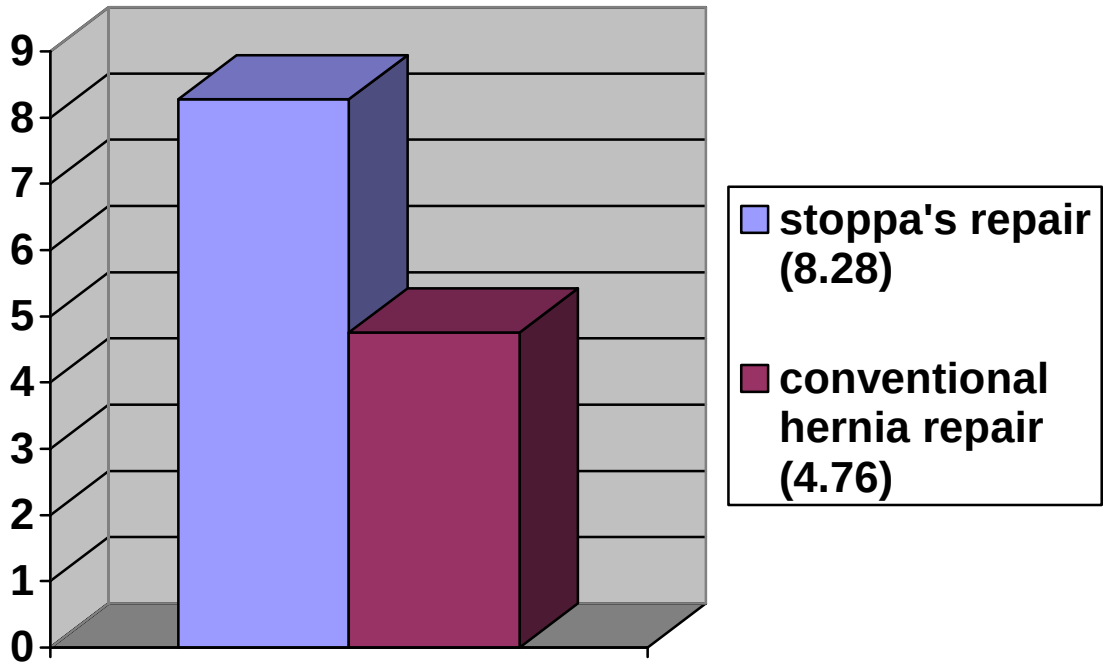

Comparison of mean rates of wound infection

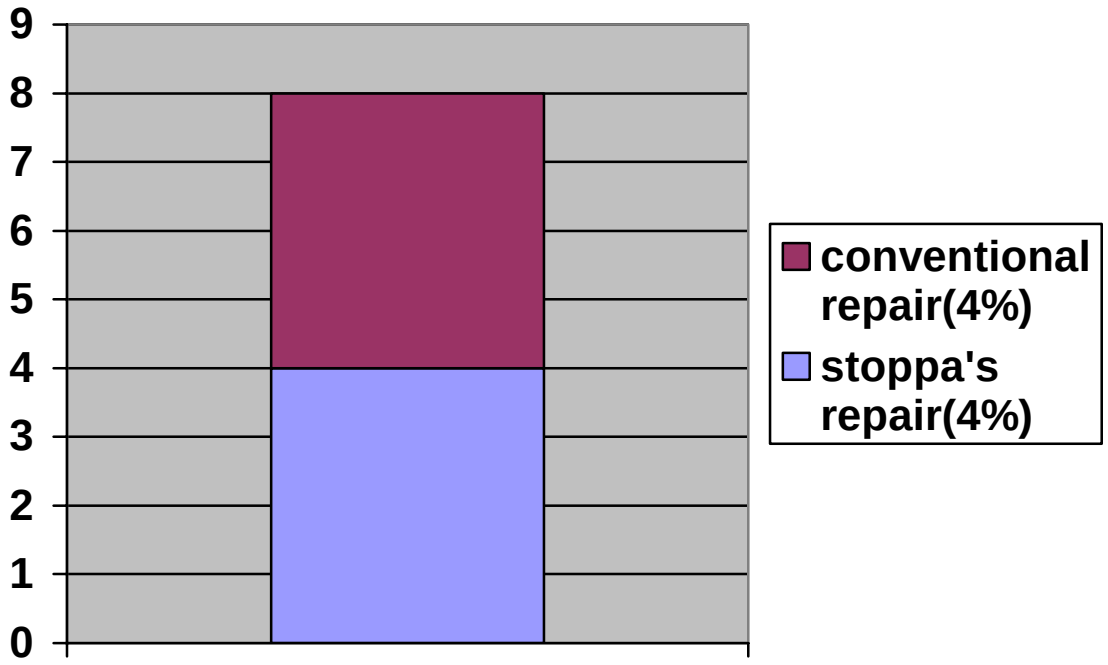

Comparison of mean rates of seroma collection

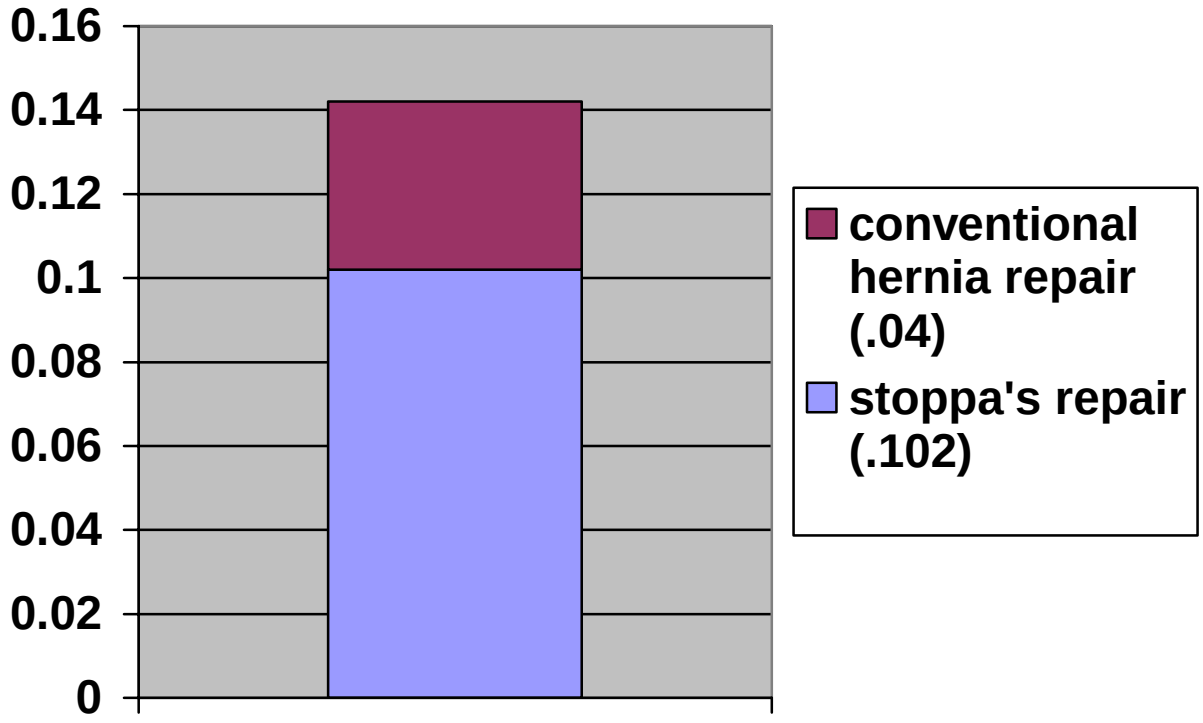

Comparison of mean recurrene rate

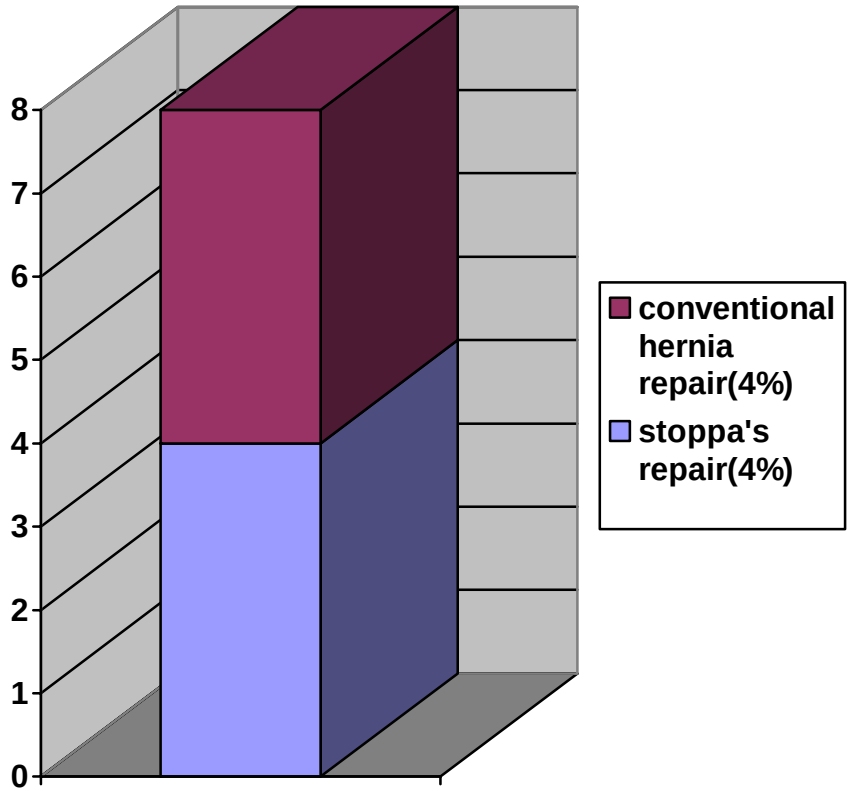

Results

1. In cases of only bilateral indirect inguinal hernias – in 75% of cases surgeons sorted conventional procedures and in 25% of cases stoppa's repair being done. In bilateral direct inguinal hernias – in 65% of cases stoppa's repair being preferred and conventional repair in 35% of cases. However, in recurrent and complex groin hernias 90% of the times stoppa's repair is done and in only 10% of cases conventional repair sorted to. In hernias associated with hydrocele always conventional procedure is preferred.

2. The mean operation time for stoppa's repair is 68.8 minutes and that of the conventional bilateral repair usually started simultaneously is 48.8 minutes. There is a significant difference in the mean operation time of up to 20 minutes.

3. Wound infection is uncommon in both the groups except for 1 case in each group leading to an infection rate of 4%.

4. Seroma collection in stoppa's repair group is 12% and the conventional group is 4%. Thus seroma collection is three times more common in the stoppa's repair group.

5. The mean duration of hospital stay in stoppa's repair group is 8.28 days and that in the conventional hernia repair group is 4.76 days. A significant difference in the duration of hospital stay of up to 3.52 days.

6. Recurrences are uncommon in either group with one case in each group leading to a recurrence rate of 4%.

Discussion

1) The pre operative diagnosis influenced the decision made for the type of procedure. From the observations made, it is seen that recurrent hernias are often treated with Stoppa's repair.

Recurrent Hernias

An estimated 25% of all hernia recurrences present within a year of the hernia repair. Another 25% will become evident by the fifth postoperative year. The remaining 50% of recurrences occur more than 5 years after the surgical repair.[37]

- In recurrent hernias, the anatomy of the inguinal canal is altered due to fibrosis.

- An understanding of the causes of failed hernia repairs is essential for successful second repairs. Since the widespread use of anterior onlay mesh repairs and plugs, recurrences occur more commonly around the internal ring, and lateral to it (Gilbert-types 2 and 3, and interstitial). Where plugs alone are used for primary repairs, recurrences present both medially and laterally to the plug.

- Failures after sutured onlay graft repairs usually relate to using a graft that is too small or short-changing the tails of the graft around

the spermatic cord. When the onlay graft is used in a sutureless manner, recurrences frequently appear at the pubic tubercle by lifting the graft at its medial angle.

Keeping in consideration, the above reasons, it is difficult to sort to conventional hernia repair for poor delineation of anatomy, medial and lateral recurrences and enormous B/L hernias making the repair difficult.

The advantages of (stoppa's) pre peritoneal approach is

- clear understanding of the hernial lesions,
- direct access to posterior inguinal structures,
- ability to place a large mesh behind the weak groin area

Hence, the pre peritoneal approach is perfectly convenient for large bilateral, multi recurrent and prevascular hernias.[17]

2) The mean operation time for stoppa's repair is 20 minutes more than that of conventional repair. But it is to be noted that the conventional repairs are usually started simultaneously and the operating team is double than that of the stoppa's repair.

3) Wound infection – reported as 4% in each group and is negligible. It is unrelated to the type of mesh and technique. It is majorly dependant on the co-morbid factors and use of poly filament suture materials. Thus there is no significant difference between the two groups in rates of wound infection.

4) Seroma collection – more common with the mesh repairs is about three times as common in the Stoppa's repair group than the conventional group.

This is due to wide creation of tissue planes and using a pfanensteil incision in Stoppa's repair. However this can be over come by lower midline approach, strict hemostasis and use of suction drains.

5) Duration of stay in the hospital – the mean duration of stay is increased by 3.5 days in the stoppa's repair group is 3.52 days. This is mainly due to the placement of suction drains and the fear of seroma collection which can be easily over come more precise technique and experience.

6) Recurrence – it is an untoward incident in the natural course of any hernia repair. The recurrence rates are 4% in each group and there is no significant difference between the two groups in rates of recurrence.

Conclusions

1) Stoppa's repair is a better procedure for complex bilateral and recurrent hernias than the conventional repair due to its pre peritoneal approach, clear delineation of anatomy and vast size of mesh.

2) The mean operation time increased by 20 minutes ($p<.05$ significant) in Stoppa's repair, but the operating team lessened by half.

3) There is no difference in the wound infection rates (4%) between the two groups.

4) The mean seroma collection rates in stoppa's repair (12%) is thrice that of the conventional group (4%) ($p<.05$% significant), but can be overcome with strict hemostasis, suction drains and experience.

5) There is no difference in the recurrence rates (4%) between the two groups at 1 year follow up. A bigger sample size and more years of follow up are necessary.

6) Our study correlates well with – "GPRVS for complex bilateral and recurrent inguinal hernias" by Thapar V et al JPGM apr – jun 46;2, 80 – 2.

Bibliography

References

1. Gilbert AI. Inguinal hernia repair: biomaterials and sutureless repair. Perspect Gen Surg. 1991;2:113-129.
2. Gilbert AI. Sutureless repair of inguinal hernia. Am J Surg. 1992;163:331-335.
3. Nyhus LM, Condon RE. *Hernia.* 3rd ed. Lippincott; 1989:263-64.
4. Lichtenstein IL. *Hernia Repair Without Disability*. St. Louis, Mo: Ishiyaku Euroamerica Inc; 1986.
5. Hessert W. Some observations on the anatomy of the inguinal region, with special reference to absence of the conjoined tendon. Surg Gyneclol Obstet. 1913:566-568.
6. Nyhus LM. An anatomic reappraisal of the posterior inguinal wall. Surg Clin North Am. 1964;44:1305.
7. Read RC. The centenary of Bassini's contribution to inguinal herniorrhaphy. Am J Surg. 1987;153:324-326.
8. Halsted WS. The radical cure of hernia. Johns Hopkins Hosp Bull. 1889;1:12-13.
9. Andrews E. A method of herniotomy utilizing only white fascia. Ann Surg. 1924;80:225-237.
10. Ferguson AH. Oblique inguinal hernia: typical operation for its radical cure. JAMA. 1899;33:6-14.
11.. Russell RH. The saccular theory of hernia and the radical operation. Lancet. 1906;2:1197-1203.

12. Annandale T. Case in which a reducible oblique and direct inguinal and femoral hernia existed on the same side and were successfully treated by operation. Edinburgh Med J. 1876;27:1087.
13. Cheatle GL. An operation for the radical cure of inguinal and femoral hernia. Br Med J. 1920;2: 68.
14. Henry AK. Operation for femoral hernia by midline extraperitoneal approach: with a preliminary note of the use of this route for reducible inguinal hernia. Lancet. 19361:531-533.
15. McEvedy PG. Femoral hernia. Ann R Coll Surg. 1950;7:484-496.
16. Nyhus LM, Condon RE, Harkins HN. Clinical experiences with preperitoneal hernia repair for all types of hernia of the groin. Am J Surg. 1960;100:234-244.
17. Stoppa RE, Rives JL, Walaumont CR, Palot JP, Verhaeghe PJ, Delattre. The use of Dacron in the repair of hernias of the groin. Surg Clin North Am. 1984;64;2:269-285.
18. Wantz GE. Prosthetics: Their Complications and Management, Part I. In: Bendavid R, ed. *Prosthesis in Abdominal Wall Hernias.* Austin, Tex: RG Landes Co: 1994:326-329.
19. Lotheissen G. Zur operation der schenkelhernie, keuxieme congres de la societe internationale de chirurgie. Bruxelles. 1908;1:399. Proces-verbaux et discussions.
20. McVay CB, Anson BJ. A fundamental error in current methods of inguinal herniorrhaphy. Surg Gynecol Obstet. 1942;74:746.
21. Welch DR, Alexander MA. The Shouldice repair. Surg Clin North Am. 1993;73;3: 451-470.
22. Usher FC, Cogan JE, Lowry TI. A new technique for the repair of inguinal and incisional hernias. Arch Surg. 1960;81:187-194.

23. Gilbert AI. An anatomic and functional classification for the diagnosis and treatment of inguinal hernia. Am J Surg. 1989;157:331-333.
24. Casten DF. Functional anatomy of the groin area as related to the classification and treatment of groin hernias. Am J Surg. 1967;114:894-899
25. Halverson K, McVay CB. Inguinal and femoral hernioplasty: a 22-year study of the author's methods. Arch Surg. 1970;101:127-135.
26. Ponka JL. Surgical management of large bilateral indirect sliding inguinal hernias. Am J Surg 1966 Jul;112(1):52-7
27. Rutkow IM, Robbins AW. "Tension-free" inguinal herniorrhaphy: a preliminary report on the "mesh plug" technique. Surgery. 1993;114:3-8.
28. Nyhus LM. A Classification of Groin Hernia. In: Arregui ME, Nagan RF, eds. *Inguinal Hernia: Advances or Controversies?* New York, Radcliffe Medical Press; 99-102.
29. Zollinger RM Jr. Unified Classification for Inguinal Hernias. Hernia. 1999;3:195-200.
30. Abramson JH, Gafin J, Hopp C, et al. The epidemiology of inguinal hernia: A survey in western Jerusalem. J Epidemol Commun Health. 1978;32:59.
31. National Vital Statistics Digest. December 13, 1999;47(28).
32. Peacock EE, Jr., Madden JW. Some studies on the effect of beta-aminopropionitrile on collagen in healing wounds. Surgery. 1966;60:7.
33. Read RC. Metabolic factors contributing to herniation: a review. Hernia. 1998;2:51-55.
34. Wantz GE, Fisher E. Is high ligation of the indirect hernia sac essential in inguinal hernioplasty? Hernia. 1998;2:131-132.

35. Young DV. Comparison of local, spinal, and general anesthesia for inguinal herniorrhaphy. Am J Surg. 1987;153:560-563.
36. Glassow F. Femoral hernia: review of 2,105 repairs in a 17 year period. Am J Surg. 1985;150:353-356.
37. Postlethwaite RW. Recurrent inguinal hernia. Ann Surg. 1985;202:777-779.
38. Rathauser F. Historical overview of the bilateral approach to pediatric inguinal hernia. Am J Surg. 1985;150:527.
39. Solomon JR. The practice and implications of contralateral exploration of children with unilateral inguinal hernias. Aust NZ J Surg. 1967;37:125.
40. Lobe TE., Schropp KK. Inguinal hernias in pediatrics. Initial experience with laparoscopic exploration on the contralateral side. J Laparoendoscopic Surg. 1992;2:135-140.
41. Rowe WI. Marchildon MB. Inguinal Hernia and Hydrocele in Infants and Children. Surg Clin North Am. 1981;61:1137-1145.
42. Gilbert AI, Felton LL. Infection in inguinal hernia repair considering biomaterials and antibiotics. Surg Gynecol Obstet. 1993;177:126-130.
43. Bendavid R. Seromas and prostheses, Part I. In: Bendavid R, ed. *Prostheses and Abdominal Wall Hernias.* Austin, Tex: RG Landes Co; 1994:367-369.
44. Starling JA, Harms BA. Ilioinguinal, iliohypogastric and genito-femoral neuralgia. In: Bendavid R, ed. *Prostheses and Abdominal Wall Hernias.* Austin, Tex: RG Landes Co; 1994:351-356.
45. Gilbert AI, Graham MF. *Technical and Scientific Objections to Laparoscopic Herniorrhaphy: Problems in Surgery.* Summer 1995;12:2. Lippincott Raven.

46. Aeberhard P, Klaiber C, Meyenberg A, Osterwalder A, Tschudi J. Prospective audit of laparoscopic totally extraperitoneal inguinal hernia repair: a multicenter study of the Swiss Association for Laparoscopic and Thoracoscopic Surgery (SALTC). Surg Endosc. 1999;13:1115-1120.
47. The MRC Laparoscopic Groin Hernia Trial Group. Laparoscopic versus open repair of groin hernia: a randomised comparison. Lancet. 1999;354:185-190.
48. Beets GL, Dirksen CD, Go PM, Geisler FE, Baeten CG, Kootstra G. Open or laparoscopic preperitoneal mesh repair for recurrent inguinal hernia? A randomized controlled trial. Surg Endosc. 1999;13:323-327.
49. Velanovich V. Laparoscopic vs open surgery: a preliminary comparison of quality-of-life outcomes. Surg Endosc. 2000;14:16-21.
50. Wellwood J, Sculpher MJ, Stoker D, et al. Randomised controlled trial of laparoscopic versus open mesh repair for inguinal hernia: outcome and cost. BMJ. 1998;317:103-110. Published erratum appears in BMJ. 1998;317:631.
51. Johansson B, Hallerback B, Glise H, Anesten B, Smedberg S, Roman J. Laparoscopic mesh versus open preperitoneal mesh versus conventional technique for inguinal hernia repair: a randomized multicenter trial (SCUR Hernia Repair Study). Ann Surg. 1999;230:225-231.
52. Ger R. The management of certain abdominal herniae by intra-abdominal closure of the neck of the sac. Ann R Coll Surg Engl. 1982;64:342-344.
53. Ger R, Monro K, Duvivier R, et al. Management of inguinal hernias by laparoscopic closure of the neck of the sac. Am J Surg. 1990;159:370-373.

54. Bogojavalensky S. Laparoscopic treatment of inguinal and femoral hernia (video presentation). 18th Annual Meeting of the American Association of Gynecological Laparoscopists. Washington, DC, 1989.
55. Schultz L, Graber J, Pietrafitta J, et al. Laser laparoscopic herniorrhaphy: a clinical trial, preliminary results. J Laparoendosc Surg. 1990;1:41-45.
56. Corbitt J. Laparoscopic herniorrhaphy: A preperitoneal tension-free approach. Surg Endosc. 1993;7:550-555.
57. Salerno GM, Fitzgibbons RJ, Filipi C. Laparoscopic inguinal hernia repair. In: Zucker KA, ed. *Surgical Laparoscopy*. St. Louis, Mo: Quality Medical Publishing, 1991;281-293.
58. Toy FK, Smoot RT. Toy-Smoot laparoscopic hernioplasty. Surg Laparosc Endosc. 1991;1:151-155.
59. Toy FK, Smoot RT. Laparoscopic hernioplasty update. J Laparoendosc Surg (United States). 1992;2:197-205.
60. Fitzgibbons RP. Laparoscopic inguinal hernia repair. In: Zucker KA, ed. *Surgical Laparoscopy Update*. St. Louis, Mo: Quality Medical Publishing; 1993:373-934.
61. Arregui ME. Preperitoneal repair of direct inguinal hernia with mesh. Presented at: Advanced Laparoscopic Surgery: The International Experience. Indianapolis, Ind: May 20-22, 1991.
62. Phillips EH, Carroll BJ, Fallas MJ. Laparoscopic preperitoneal inguinal hernia repair without peritoneal incision: technique and early clinical results. Surg Endosc. 1993;7:159-162.
63. McKernan JB, Laws HL. Laparoscopic repair of inguinal hernias using a totally extraperitoneal prosthetic approach. Surg Endosc. 1993;7:26-28.

64. Tetik C, Arregui ME, Dulucq JL, et al. Complications and recurrences associated with laparoscopic repair of groin hernias: A multi-institutional retrospective analysis. Surg Endosc. 1994;8:1316-1323.
65. Crawford DL, Phillips EH. Laparoscopic repair and groin hernia surgery. Surg Clin North Am. 1998;78:1047-1062.
66. Bax T, Sheppard BC, Crass RA. Surgical options in the management of groin hernias. Am Fam Physician. 1999;59:893-906.
67. Ferzli G, Sayad P, Huie F, Hallak A, Usal H. Endoscopic extraperitoneal herniorrhaphy. A 5-year experience. Surg Endosc. 1998;12:1311-1313.
68. Juul P, Christensen K. Randomized clinical trial of laparoscopic versus open inguinal hernia repair. Br J Surg. 1999;86:316-319.
69. Carbajo MA, Martin del Olmo JC, Blanco JI, et al. Laparoscopic treatment vs open surgery in the solution of major incisional and abdominal wall hernias with mesh. Surg Endosc. 1999;13:250-252.
70. Ramshaw BJ, Esartia P, Schwab J, et al. Comparison of laparoscopic and open ventral herniorrhaphy. Am Surg. 1999;65:827-831; discussion 831-832.
71. Memon MA, Feliu X, Sallent EF, Camps J, Fitzgibbons RJ. Laparoscopic repair of recurrent hernias. Jr Surg Endosc. 1999;13:807-810.
72. Chung RS, Rowland DY. Meta-analyses of randomized controlled trials of laparoscopic vs conventional inguinal hernia repairs. Surg Endosc. 1999;13:689-694.
73. Chari R, Chari V, Eisenstat M, Chung R. A case controlled study of laparoscopic incisional hernia repair. Surg Endosc. 2000;14:117-119.
74. Picchio M, Lombardi A, Zolovkins A, Mihelsons M, La Torre G. Tension-free laparoscopic and open hernia repair: randomized

controlled trial of early results. World J Surg. 1999;23:1004-1007; discussion 1008-1009.

STOPPA'S repair group

Post operative events

S.n	Name, age, sex I.P no.	Diagnosis	Operation time	Wound infection	Seroma collection	Duration of stay	Recurrence
1	Boopathy, 50,m (851326)	B/L indirect inguinal hernia	60 min	---	---	10 days	---
2	Ganapathy, 34m(14098)	Rt direct , Lt indirect inguinal hernia	75 min	---	---	10 days	---
3	Durai ,55,m (004134)	B/L direct inguinal hernia	75 min	---	---	11 days	---
4	Saravana kumar,24, m (047225)	B/L direct inguinal hernia	60 min	---	---	7 days	---
5	Sounder rajan, 38 , m (051076)	B/L indirect inguinal hernia	75 min	---	---	10 days	---
6	Krishnan, 56 m (052761)	B/L indirect inguinal hernia	80 min	---	++	8 days	---
7	Govindraj , 57 m (56645)	B/L indirect inguinal hernia	90 min	---	---	9 days	---

8	Subburayan , 60 m (759206)	Rt indirect with Lt recurrent inguinal hernia	90 min	---	---	10 days	---
9	Perumal 59 m (777017)	B/L direct inguinal hernia	80 min	---	---	8 days	---
10	Munuswamy, 36 m (785442)	B/L direct inguinal hernia	60 min	---	---	9 days	---
11	Selvarathinam 59 m (65012)	Rt pantaloon hernia with Lt indirect inguinal hernia	60 min	---	---	8 days	---
12	Krishnan 45 m (65714)	Rt recurrenct inguinal hernia with Lt pantaloon hernia	60 min	---	---	7 days	---
13	Kannan 65 m (833376)	B/L direct inguinal hernia	60 min	---	---	7 days	---
14	Ponnuswamy 53 m (833404)	B/L direct inguinal hernia	60 min	---	---	8 days	---

15	Subramani 51 m (017046)	B/L indirect inguinal hernia	75 min	---	---	8 days	---
16	Abdul kareem 61 m (044746)	Recurrent Rt inguinal hernia with Lt bubonocele	80 min	---	++	12 days	---
17	Balasubra maniyan 35 m (48467)	B/L indirect inguinal hernia	75 min	---	---	6 days	---
18	Mohan, 54 m (63210)	Lt recurrent with Rt direct inguinal hernia	60 min	---	---	7 days	---
19	Raheem, 45 m (48447)	B/L indirect inguinal hernia	60 min	++	++	14 days	+++
20	Riyadh 60 m (15320)	Rt recurrent hernia with Lt bubonocele	75 min	---	---	6 days	---
21	Selvam, 50 m (64013)	B/L direct inguinal hernia	70 min	---	---	6 days	---
22	Narayana moorthy 40	B/L indirect inguinal	60 min	---	---	7 days	---

	m (14222)	hernia					
23	Lakshmana kumar 56 m (13121)	Lt recurrence with Rt direct inguinal hernia	60 min	---	---	7 days	---
24	Murugan 45 m (17884)	B/L direct inguinal hernia	60 min	---	---	6 days	---
25	Balu 50 m (850804)	B/L direct inguinal hernia	60 min	---	---	6 days	---

Conventional B/L hernia repair group

Post operative events

s.no	Name, age, sex	Diagnosis	Operation time	Wound infection	Seroma collection	Duration of stay	Recurrence
1	Krisnamoorthy,65m(001344)	B/L indirect inguinal hernia	45 min	---	---	4 days	---
2	Krishnan,60 m (001325)	B/L indirect inguinal hernia	45 min	---	---	4 days	---
3	Balaraman, 50 m (760370)	B/L indirect inguinal hernia	40 min	---	---	5 days	---
4	Kumar, 48 m (779243)	Rt recurrent inguinal hernia with Lt bubonocele	60 min	---	---	6 days	---
5	Periyaswamy , 55 m (794110)	B/L indirect inguinal hernia	50 min	+++	---	6 days	+++
6	Sivaraman 37 m (797421)	B/L indirect inguinal hernia with Lt hydrocele	60 min	---	---	6 days	---

7	Karuppaiyah 35 m (797449)	B/L direct inguinal hernia	50 min	---	---	6 days	---
8	Sundaram 57 m (807317)	B/L indirect inguinal hernia with B/L hydrocele	50 min	---	---	5 days	---
9	Gajendran 40 m (814416)	B/L direct inguinal hernia with B/L hydrocele	60 min	---	---	5 days	---
10	Annamalai 51 m (836660)	B/L indirect inguinal hernia	60 min	---	++	5 days	---
11	Vellaiyan 60 m (59234)	B/L indirect inguinal hernia	50 min	---	---	4 days	---
12	Baskar 22 m (850803)	B/L indirect inguinal hernia	45 min	---	---	5 days	---
13	Anbazhagan 54 m (857688)	B/L direct inguinal hernia	50 min	---	---	4 days	---
14	Raja 38 m (12141)	B/L indirect inguinal hernia	50 min	---	---	4 days	---
15	Kaiyoom 55 m (12095)	B/L indirect inguinal hernia	45 min	---	---	5 days	---
16	Lourdusamy 60 m	B/L indirect inguinal hernia	45 min	---	---	4 days	---

	(15333)						
17	Lakshmanan , 76 m (17894)	B/L direct inguinal hernia	50 min	---	---	4 days	---
18	Subramaniya m 57 m (58585)	B/L indirect inguinal hernia	45 min	---	---	5 days	---
19	Devarajulu 70 m (22125)	B/L indirect inguinal hernia	50 min	---	---	4 days	---
20	Kamaludeen 57 m (050512)	B/L indirect inguinal hernia	45 min	---	---	5 days	---
21	Vijayalaksh mi 31 f (30459)	B/L direct inguinal hernia	40 min	---	---	4 days	---
22	Narayanan 58 m (35821)	B/L indirect inguinal hernia	40 min	---	---	5 days	---
23	Kannaiyan 57 m (43110)	B/L indirect inguinal hernia	50 min	---	---	5 days	---
24	Murugesan 35 m (43830)	B/L indirect inguinal hernia	50 min	---	---	5 days	---
25	Durai 60 m (37772)	B/L direct inguinal hernia	45 min	---	---	4 days	---