STUDY OF HOLLOW VISCUS INJURY IN BLUNT INJURY ABDOMEN

By

DR S RAJKUMAR .,

Dissertation Submitted to the

TAMILNADU DR MGR MEDICAL UNIVERSITY

In partial fulfilment

Of the requirements for the Degree of

MASTER OF SURGERY

in

GENERAL GURGERY

Under the guidance of

PROF P RAGUMANI .,M S ., PROFESSOR

DEPARTMENT OF GENERAL SURGERY

MMC & RGGGH

DEPARTMENT OF GENERAL SURGERY

MADRAS MEDICAL COLLEGE AND RGGGH

CHENNAI – 600 003

DECLARATION BY THE CANDIDATE

I hereby declare that this dissertation **"STUDY OF HOLLOW VISCUS INJURY IN BLUNT INJURY ABDOMEN"** is a bonafide and genuine research work carried out by me under the guidance of **PROF P RAGUMANI., M S.,** Professor, Department of General Surgery , MMC & RGGGH , CHENNAI.

DATE:

PLACE: **DR S RAJKUAMR**

PG IN GENERAL SURGERY

MMC & RGGGH

CERTIFICATE BY THE GUIDE

This is to certify that the dissertation entitled

"STUDY OF HOLLOW VISCUS INJURY IN

BLUNT INJURY ABDOMEN"

is a bonafide

research work done by Dr. S RAJKUMAR in partial

fulfilment of the requirement for the degree of

Master of Surgery in General Surgery.

Date :

Place :

PROF P. RAGUMANI .,M S .,
PROFESSOR
DEPT. OF GENERAL SURGERY
MMC & RGGGH

ENDORSEMENT BY

THE HEAD OF THE DEPARTMENT AND DEAN

This is to certify that the dissertation entitled

"STUDY OF HOLLOW VISCUS INJURY IN

BLUNT INJURY ABDOMEN"

is a bonafide research work done by Dr. S RAJKUMAR under the guidance of PROF P RAGUMANI., M S., Professor, Department of General Surgery , MMC & RGGGH , CHENNAI.

PROF. S. DEIVANAYAGAM
Hod, Dept. Of General Surgery
MMC & RGGGH , Chennai.

Date :

Place :

PROF. V. KANAGASABAI
THE DEAN,
MMC & RGGGH

Date :

Place :

ACKNOWLEDGEMENT

I express my deep sense of gratitude and indebtedness to my respected teacher and guide, **PROF P . RAGUMANI .,** Professor , Department of General Surgery , MMC & RGGGH, whose valuable guidance and constant help have gone a long way in the preparation of this dissertation.

I acknowledge my sincere and heartfelt thanks with gratitude to **PROF. S. DEIVANAYAGAM**., Professor and Head , Department of General Surgery, MMC & RGGGH for his constant help , advise and management .

I express my sincere and heartfelt gratitude to my former chiefs PROF A. PERIASAMY M S., for his clinical classes and lectures and whose valuable guidance and constant help have gone a long way in the preparation of this dissertation.

I am also thankful to Assistant professors ,DR. MADHIVADHANAM., DR. N.SELVARAJ, DR. PARIMALA, DR. ABDUL RAHIM , DR. KOPERUNDEVI., for their timely suggestions.

I express my thanks to the DEAN , Madras Medical College and RGGGH , CHENNAI , for allowing me to utilise the resources of the college and hospital for this study.

I express my thanks to all of the staff members of Department of General Surgery , and all my postgraduate colleagues and friends for their help during my study and preparation of this dissertation.

I always remember my family , for their everlasting blessings and encouragement.

Lastly , I express my thanks to my patients without them this study would not have been possible.

DATE **DR S RAJKUAMR**

PLACE: PG IN GENERAL SURGERY

MMC & RGGGH

LIST OF ABBREVIATIONS

ARDS - Acute respiratory distress syndrome

CBD - Common bile duct

CHD - Common hepatic duct

CPR - Cardiopulmonary resuscitation

CT - Computed tomography

CUSA - Cavitron ultrasonic surgical aspirator

CVP - Central venous pressure

DPL - Diagnostic peritoneal lavage

ERCP - Endoscopic retrograde cholangiopancreatography

GCS - Glasgow coma scale

ICS - Intercostal space

ICU - Intensive care unit

IVC - Inferior venacava

KUB - Kidney, ureter, bladder x ray film

MRI - Magnetic resonance imaging

PCN - Percutaneous nephrostomy

USG - Ultrasonography

ABSTRACT

BACKGROUND AND OBJECTIVES

To evaluate the impact of blunt abdominal trauma on the hollow visceras, various modes of presentation in early diagnosis. and evaluate various modalities of treatment and common complications.

Blunt abdominal trauma is one of the most common injuries caused mainly by road traffic accidents. They are usually not obvious. Hence, often missed, unless, repeatedly looked for. In view of increasing number of vehicles and consequently road traffic accidents, this dissertation has been chosen to study the cases of blunt abdominal trauma.

METHODOLOGY

Patients coming with blunt injury abdomen due to RTA or TTA or Fall from height or Fall of heavy object to Department of General surgery in Rajiv Gandhi Govt. General hospital between June 2011 to December 2013 are taken up for study.

RESULTS

Males are predominantly affected. It is mostly seen in the age group of 21-30 years which form the young and productive group. Road traffic accident forms the most common mode of injury. The most common injured viscera in the present study is small bowel and they were managed by simple suturing. Mesenteric injury is the second most common injury and majority of them were managed by simple repair.

INTERPRETATION AND CONCLUSION

Serial clinical examination plays the main role in diagnosing the hollow viscous injury in blunt trauma abdomen. CECT abdomen is the sensitive investigation to diagnose the injury. Operative management remains the main stay of treatment. Early presentation have good prognosis than late presentation.

KEY WORDS: Hollow viscous injury , blunt injury abdomen

CONTENTS

LIST OF TABLES

INTRODUCTION

Abdominal trauma is one of the most common causes among injuries caused mainly due to road traffic accidents. The rapid increase in motor vehicles and its velocity has caused rapid increase in number of victims to blunt abdominal trauma. Motor vehicle accidents account for 75 to 80 % of blunt abdominal trauma. Blunt injury of abdomen is also a result of fall from height, assault with blunt objects, sport injuries, industrial mishaps, bomb blast and fall from riding bicycle.

Blunt abdominal trauma is usually not obvious. Hence, often missed, unless, repeatedly looked for. Due to the inadequate treatment of the abdominal injuries, most of the cases are fatal. The knowledge in the management of blunt abdominal trauma has progressively increasing due to the in-patient data gathered from different parts of the world. In spite of the best techniques and advances in diagnostic and supportive care, the morbidity and mortality remains at large. The reason for this could be due to the interval between trauma and hospitalization, delay in diagnosis, inadequate and lack of appropriate surgical treatment, post-operative complications and associated trauma especially to head, thorax and extremities.

In view of increasing number of vehicles, rampant increase in construction work and consequent road traffic accidents, this dissertation has been chosen to study the cases of blunt abdominal trauma, its different modes of presentation and to study

the different modalities of its management with reference to the patients presenting at Rajiv Gandhi Govt. General Hospital & Madras Medical College, Chennai – 3.

AIM AND OBJECTIVES OF THE STUDY

- 1.To study the relation between mechanism of injury and operative finding and subsequently operative management
- 2.To study the various presentations of hollow viscus injury in blunt injury abdomen.
- 3. To evaluate the various modalities to diagnose the hollow viscous injury at the earliest .
- 4. To compare morbidity and mortality between early and late interventions.

REVIEW OF LITERATURE

HISTORICAL ASPECTS:

Blunt injury as causes of intra abdominal injuries have been recognized since historical times. Aristotle was the first to record visceral injuries from blunt trauma. Hippocrates and Galen are said to have given correct description of the condition.

By 1500 BC distinct triage and surgical protocol had been developed in Babylonia under the rule of Hammurabi as said by Edwin Smith Papyrus.

In 1580 Ambriospare made a reference of traumatic herniation of stomach through diaphragm.

The first operative repair of gastric injury was reported by Nollesan in the 18th century, and

The first case of gastric injury, as well as resultant fistula, is credited to Schenk in the 16th century.

The ancient Chinese used a sharp blow on the region of the spleen as a method of assassination.

Trausse in 1827 presented fracture of body of pancreas in blunt trauma

Von Reckiling Hausen described artery thrombosis occurring as a result of blunt trauma.

Prior to 1900, the mortality resulting from colonic injuries and bladder injuries was nearly 100%.

In 1906 Solomon performed peritoneal lavage for the first time.

Tran section of stomach resulting from blunt trauma was first described by Plancaslillin. Barily reported 32 cases of rupture of spleen during the period 1894-1924.

In 1934 Aenhium used puncture of abdominal wall as a diagnostic procedure in abdominal injuries. Branch in 1938 reported 2 cases of liver laceration treated by resection of left lobe.

Synthetic grafts was first used by Voorhees in 1952 and widely employed by Hughes (1954) and Spencer (1955).

The development of emergency medical service is an important milestone in the history of clinical and surgical practice of trauma. Greeks required physicians to be present during the battle and Romans established the hospitals close to the battlefield.

Cincinnati General Hospital first instituted the ambulance system in 1865.

In 1965 Root first described the flushing of sterile solution through the peritoneal cavity to obtain peritoneal contents.

Advanced imaging techniques like spiral CT scan and MRI has made early detection of blunt abdominal injuries easier.

ANATOMY OF ABDOMINAL CAVITY:

Abdominal cavity extends just below the nipple in lower chest to deep into the pelvis. It has number of organs, some solid and other hollow viscus. Abdominal organs are protected anteriorly only by muscles except those organs/parts lying under the lower ribs and in the pelvis. The abdominal cavity is bounded anteriorly by the rectus abdominis, laterally by external, internal and transverse abdominis and more inferiorly, the iliac muscles and posteriorly by the vertebral columns and psoas major, minor and quadratic lumborum.

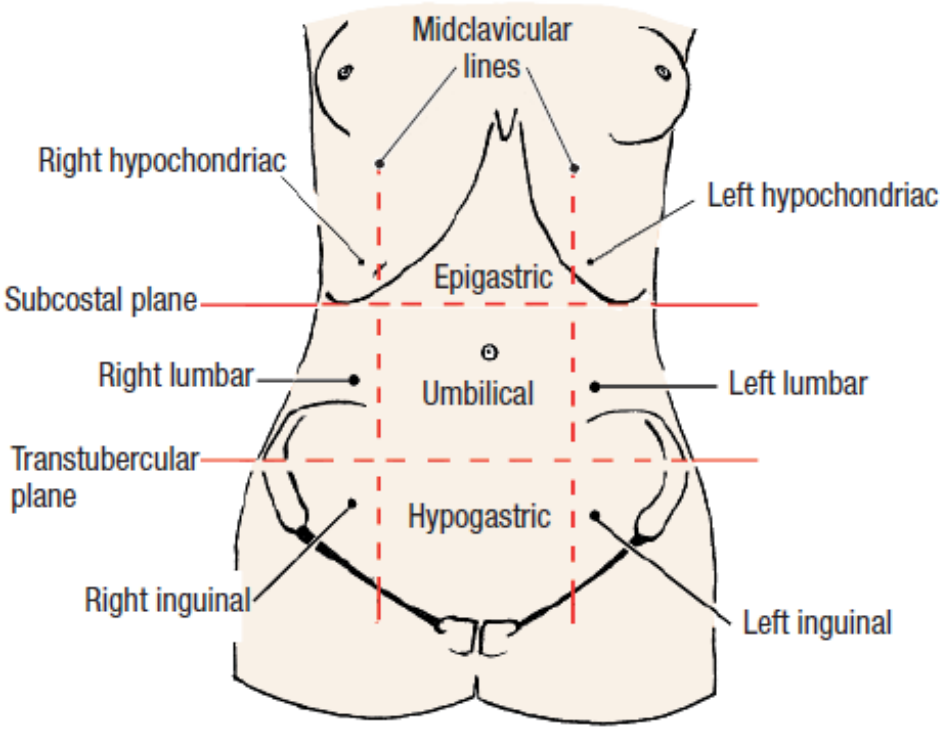

NINE REGIONS

It is divided into nine regions for the descriptive purpose by two horizontal lines and two vertical arbitrary lines. The horizontal lines are transpyloric, at the level of pylorus of stomach or passes through the tip of the ninth costal cartilage and that passing through the intertubercle of the ileum. The two vertical lines are from midclavicle downwards. The resulting quadrants are right and left hypochondriac, middle epigastric, right and left lumbar, middle umbilical, right and left iliac, middle hypo gastric.

Peritoneal cavity:

The peritoneal cavity is a potential space between the parietal peritoneum lining the body wall and visceral peritoneum covering the abdominal organs. The peritoneal cavity is a serous sac, similar to the pleural and pericardial cavities. The retroperitoneal space is behind the peritoneum of the posterior abdominal wall.

Gastrointestinal tract:

Stomach: The stomach is a seromuscular organ located in the intra-thoracic position of the abdomen and is well protected from injury by the overlying rib cage. In addition to these attachments, it is relatively fixed at the gastro-esophageal junction and the retroperitoneal duodenum. It communicates with the esophagus at the cardiac orifice and the small intestine by the pyloric orifice. The anterior

surface is related to the diaphragm, left lobe of the liver and left

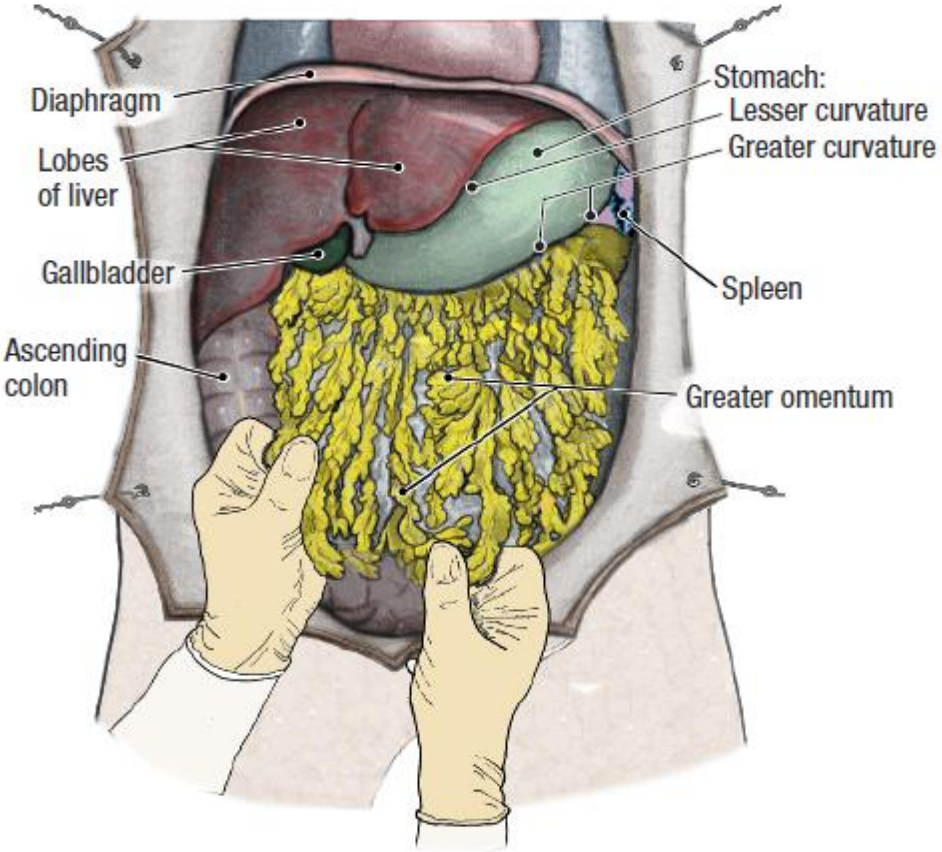

PERITONEAL CAVITY

rectus sheath. The posterior surface of the stomach is related to the structures forming the bed such as the diaphragm, left suprarenal gland, left splenic artery, pancreas, transverse mesocolon and the spleen would also be included but it is separated from the stomach by the cavity of the greater sac.

The gastric wall is made up of an external serosal layer followed by three layers of smooth muscle- an outer longitudinal layer, a middle circular layer, and an inner oblique layer. A strong sub mucosal layer is followed by a mucosal layer with a rich capillary network. The thickness and strength of the stomach wall are factors that contribute to the rarity of blunt gastric rupture. The stomach is supplied by four major nutrient arteries with extensive collateral circulation between the

vascular beds. They are left gastric, right gastric, left gastro-epiploic and the right gastro-epiploic arteries.

Duodenum: It extends from the pylorus, to the duodeno-jejunal flexure. It is roughly C-shaped and is about 25cm long. It is a unique piece of small intestine because of its deep anatomic location, retroperitoneal fixation, and connection to the secretory ducts of the liver and pancreas.

The blood supply is from the coeliac and superior mesenteric vessels. This blood supply is shared with the head of the pancreas; this common arterial input may complicate management of both pancreatic and duodenal injuries. It is divided into four parts. The first portion of the duodenum is intra-peritoneal and somewhat mobile. The remainder of the duodenum is retroperitoneal owing to the fusion of the posterior parietal peritoneum with the duodenum. The second and right half of the third portions of the duodenum may be easily mobilized through this bloodless fusion plane, a Kocher maneuver. The ligament Trietz is a fibro muscular band that suspends and supports the duodeno-jejunal flexure.

Small intestine:

The small bowel measures about 6 meters and extends from the ligament of Trietz to the caecum. It is freely moveable on its mesentery. The upper two fifth's is jejunum, and the lower three fifth's is ileum. The adult small bowel measures about twice the body height. The fan shaped mesentery suspends the small bowel and extends from the left side of the second lumbar vertebra downwards to the right sacroiliac joint, traversing the transverse duodenum, aorta, inferior vena cava, right gonadal vessels, and right ureter. The superior mesenteric artery supplies the

jejunum and ileum, arising from the aorta approximately 2 cm below the coeliac trunk. After crossing the uncinate process, it enters the root of the mesentery, giving off branches to pancreas, right colic, and numerous intestinal vessels before it terminates at the medial aspect of the caecum. Importantly, there are no named vessels connecting the root of the mesentery and the retro-peritoneum. This allows mobilization of the right and entire small bowel cephalad to the inferior aspect of the pancreas.

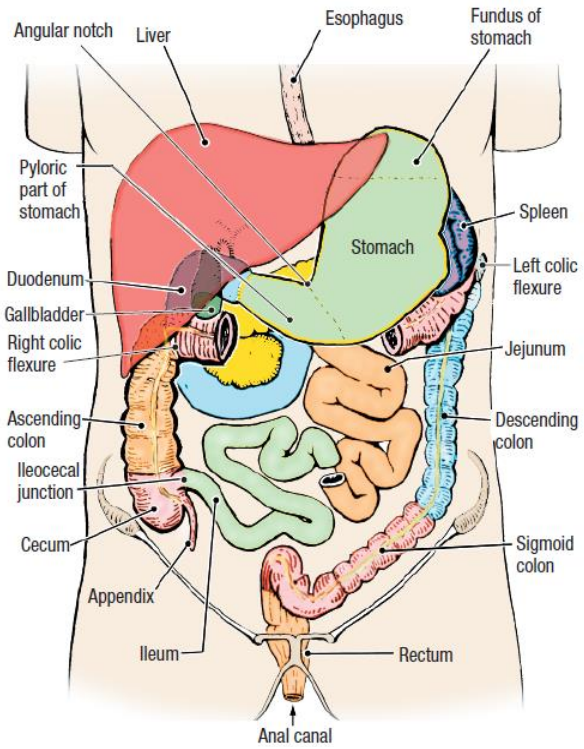

Large intestine:

The large intestine measures about 1.5 mtrs in length and extends from the ileocaecal junction to the anus. It is divided into appendix, caecum, ascending colon, transverse colon, descending colon, sigmoid colon, rectum and anal canal. The ileum opens into the large intestine by a longitudinal slit, the ileocaecal orifice guarded by the ileocaecal valve. Below the orifice, the appendix opens into the

caecum. The longitudinal muscle of caecum forms three ribbon like structures called the taenia coli which converge at the base of the appendix proximally and distally, they spread out on the sigmoid colon to become continuous with the longitudinal muscle coat of the rectum.

Gall bladder:

Gall bladder is situated in the inferior surface of the right lobe of the liver. It is pyriform in shape which acts as a reservoir for bile. The fundus of the gall bladder usually protrudes beyond the liver and is covered by the peritoneum. It is in contact with the anterior abdominal wall at the 9th costal cartilage. The gall bladder is divided into three parts:

Fundus,Body.Neck. The cystic duct drains into the CBD. The cystic artery, a branch of right hepatic artery, supplies the gall bladder.

Bladder:

Urinary bladder is a reservoir of urine. It is a muscular structure which is lined by transitional epithelium. It lies in the anterior part of the pelvic cavity. An empty bladder is tetrahedral in (full bladder is ovoid) in shape and has an apex directed forwards, a base or fundus, directed downwards and a neck, the lowest and most fixed part of the bladder. It has three surfaces, a superior and two inferolateral and four borders, two lateral, an anterior and posterior. As the bladder fills, the inferolateral surfaces form the anterior surface of the distended bladder, which is covered by peritoneum only in its upper part. The lower uncovered part (about 5 cm of the suprapubic region) of the bladder can be approached extra-peritoneally.

PATHOPHYSIOLOGY:

Several pathophysiological processes will take place in a case of blunt abdominal injury. Understanding the mechanism of injury is important in the management of a patient with blunt abdominal trauma; injuries can be classified as high energy or low energy.

1. Blunt trauma over the abdomen causes damage from a combination of compression and shearing ,bursting forces. Sudden, pronounced increase in intra abdominal pressure caused by outward forces can cause rupture of the hollow viscera or can cause burst injury of solid organs.

2. Compression of abdominal viscera between applied force to the abdominal wall and the posterior thoracic cage of the vertebral column can produce a severe crush injury.

3. Abrupt shearing forces can cause tear of organs or vascular pedicles.

4. Oblique forces and deceleration injury can cause shearing of viscera where anchored, such as at site of the duodenojejunal flexure and peritoneal attachments of the bowel.

5. Deceleration injuries occur in high speed vehicular accidents and also in falls from great heights. On impact, the organs continue to move forward at terminal velocity, tearing the organs at their sites of attachment.

CLINICAL EXAMINATION

History and physical examination:

When a patient presents to casualty with a history of blunt abdominal trauma, the first priority should be to treat the immediate life threatening conditions such as airway, circulation, pneumothorax and to arrest the internal bleeding. After the resuscitation, a brief but detailed history extracting as much information as possible obtained from the paramedics/ police/bystanders.

Motor vehicle accident is a common cause of blunt abdominal injury. Mechanism of injury and the position of the victim should be sought to know the probable intra abdominal injuries. Whether it was auto pedestrian accident or if it was head on vehicular collision, position of the victim, (driving or rear seat passenger) should be enquired. Type of accident: frontal impact, side impact, and sideswipe, rear impact or rollover type of accidents; whether the victim was wearing seat belts etc should be noted. Patient's level of consciousness at the site of accident, whether the patient was under the influence of alcohol should be sought. If the patient is conscious h/o regarding his medications, past medical history and allergic to drugs are noted.

Systemic examination:

The major factor that determines the survival and functional outcome in most cases of blunt trauma of abdomen is the presence of the head injury. The systemic examination of the patient with blunt abdominal injury starts from assessing the level of consciousness and associated injuries to chest which may hinder the

respiration. The severity of head injury can be rapidly assessed by determining three factors:

1. Level of consciousness.
2. Pupillary symmetry.
3. Lateralized weakness of the extremities.

Level of consciousness is best assessed by GCS score (Glasgow Coma Scale), a system that evaluate eye opening, best motor response and verbal response. The GCS is determined by taking the best response in each category and totaling them. It ranges from 3 to 15 (mild: 13-15, Moderate: 9-12, severe $\leq$ 8). The presence of any of the following criteria suggests serious injury.

1. A GCS score less than 10.
2. A decrease in the GCS score by 3 of more regardless of the initial GCS score.
3. Pupillary inequality greater than 1mm regardless of the GCS score.
4. Lateralized extremity weakness regardless of the GCS score.
5. Markedly depressed skull fractures.
6. Open cranial wounds with brain exposed.

Haematomas, bleeding lacerations, tenderness or any deformities should be looked for. The gaping wound should be sutured to control bleeding. Nasopharynx bleed should be controlled by passing a Foley's catheter and inflating the bulb in the nasopharynx. Blood at the internal auditory meatus is a definitive presumptive evidence of basilar skull fracture.

Visual examination and signs for any trauma should be looked for. Nose and throat should be examined for adequacy of airways. Distended neck veins suggest cardiac tamponade, cardiac contusion. Tenderness on the cervical spine suggests fracture especially associated with maxillo facial trauma.

Chest: The patient should be derobed completely. Careful inspection of the thorax should be done noting shape, size, symmetry corresponding movements of hemithorax should be noted. Any abrasions, contusions, external wounds, dilated veins, retraction or bulging of the intercostal spaces, movements of both hemithorax any communicationg wounds with the peritoneal cavity should be noted. Trachea should be palpated for trail's sign. On percussion, hyperresonant note indicates pneumothorax. Dull note indicates hemothorax. Cardiac dullness and liver dullness area should be carefully noted as enlargement denotes significant injury in blunt abdomen patients.

Respiratory system should be auscultated for type of respiration, type of breath sounds (vesicular/bronchial/bronchovesicular) and for added sounds like crepitations. The cardiovascular system should be auscultated for the heart sounds and any abnormal sounds like murmurs. In early cardiac tamponade distant or muffled heart sounds may be the early clue. The voluntary muscle guarding will disappear on expiration. The muscle guarding usually corresponds to the area of tenderness. Tenderness may be due to parietal hematoma, contusions or due to intra-abdominal injuries. Rebound tenderness indicates peritoneal irritation. Generalized distension of the abdomen is a late feature of generalized peritonitis. The flanks should be palpated and the iliac crest and symphysis pubis compressed

to establish the possibility of a pelvic fracture. The hip joints should also be internally and externally rotated. Absence of discomfort on performing these maneuver usually excludes a major pelvic fracture. On rectal examination sphincter tone, integrity of rectal wall and the presence of blood should be looked for. The presence of high riding or non-palpable prostate supports the diagnosis of postmembranous disruption of the urethra. Testis and external genitalia should be examined carefully for tenderness, laceration. The presence or absence of blood at the penile meatus should be noted.

Percussion: Liver dullness, splenic dullness should be elicited. Presence of free fluid in the peritoneal cavity is determined by eliciting shifting dullness. When the patient is on his back the fluid gravitates down to the flanks and the intestine floats on the center of the abdomen, which will be resonant, and the flanks dull.

Auscultation: Auscultation of the abdomen offers little in the trauma patient. However presence of bowel sound in the chest means diaphragmatic rupture. The silent abdomen (absent bowel sound) is a pathagnomonic feature of silent/diffuse peritonitis.

Pelvis: External genitalia and rectum should be examined for any injury. On rectal examination sphincter tone, integrity of bowel wall and presence of blood should be noted. High riding prostate indicates post membranous rupture of urethra.

Vascular system: All the major arterial sites should be looked for hematomas and bleeding due to disruption. Distal pulses should be palpated. Four quadrant aspiration will reveal blood if there is hemoperitoneum. Commonest organs injured (international series).

The most common organ to be involved is the spleen. The following table shows the frequencies with which different abdominal organs are injured in a blunt abdominal trauma, according to international series.

Organ	Relative incidence (%)
Spleen	46
Liver	33
Mesentery	10
Renal	09
Pancreas	09
Small bowel	08
Colon	07
Duodenum	05
Vascular	04
Stomach	02

CARE OF THE VICTIM AT THE ACCIDENT SITE:

Aim: Resuscitation and emergency transportation to trauma handling center as quickly as possible. Paramedical staff accompanying the ambulance unit should be well trained to resuscitate and shift the patient to regionalized trauma center as quickly as possible. However one should try to move the injured patient to the nearest possible competent hospital, where resuscitation and definite care can be started immediately. Mortality can be lowered if the patient is diagnosed and operated as early as possible.

At the site of accident, the following measures should be taken to stabilize the patient. Goal of first aid at the accident site would be to prevent second accident; hypoxia and circulatory failure.

1. Ensure normal airway and ventilation with endotracheal intubation.
2. Stop or arrest external bleeding.
3. Intravenous fluids.
4. Pneumatic antishock garments.
5. Protect spine.
6. Splint fractures.

INITIAL RESUSCITATION OF PATIENTS AT CASUALITY:

Injured patient may have multiple organs involved.

The goals of management are in the order of priority.

1. To save life

2. To save limb.

3. To minimize disability.

4. Cosmetic care.

There are four categories of injury depending on seriousness of injury.

1. **Exigent-** the most life threatening conditions, requiring instantaneous intervention (eg: laryngeal fracture with complete upper airway obstruction and tension pneumothorax)

2. **Emergency-** those conditions requiring immediate intervention, certainly within the first hour. (eg: ongoing hemorrhage and intracranial mass lesions)

3. **Urgent-** those conditions requiring intervention within first few hours (eg: ongoing hemorrhage and intracranial mass lesions)

4. **Deferrable-** those conditions that may or may not be immediately apparent but will subsequently require treatment. This group is composed primary of patients who have sustained blunt trauma to the abdomen that may or may not require surgical intervention and in whom the exact nature of the injury is not apparent.

Adequate airway:

This is the first and foremost important emergency measure of a severely injured patient. It may be obstructed in coma, trauma to head, face or neck, foreign body

like clots, food, vomitus and laryngeal edema. Maintain airway by chinlift, jaw thrust, oral airway (in unconscious patients) and nasal airway. Protect airway from foreign bodies. Provide airway by endotracheal intubation or surgical intervention- needle cricothyroidectomy and tracheostomy. An emergency room should always have a laryngoscope and cuffed endotracheal tubes of various sizes. Endotracheal intubation is the most rapid method of obtaining an adequate airway. This is connected to an ambu bag for positive pressure breathing.

Breathing:

This implies normal ventilation, perfusion and pulmonary circulation. It will be disturbed in rib cage injuries, pleural space collections, tracheobronchial injuries or in lung contusions, metabolic disturbances and ARDS. Provide supplemental oxygen- by mask or nasal catheter at a rate of 8 liters/ min. Stabilize chest defects. Assist ventilatory effort to maintain normal rate, rhythm and arterial blood oxygen and co2. Evacuate pleural space collections like air or blood by aspiration or intercostal drains connected to underwater sealed containers.

Circulation:

Generalized hypoperfusion (fatal if persistent) may result from oligemic, cardiogenic, endotoxic and neurogenic shock. Local limb hypoperfusion may result from injured blood vessels and may lead to tissue destruction and death of affected organ. Prevent further blood loss by direct pressure. Replace fluid losses- trendelenberg position, auto transfusion, whole blood transfusion. Resuscitate by IV sodium chloride or ringer lactate. Correct acidosis. If required (ph <7.25) inject sodium bicarbonate. Monitor sensorium, urine output, pulse rate, ECG and data

from CVP line (if facilities are available). Shock is usually controlled while the patient's airway is cleared by another person. Internal hemorrhage will require immediate surgical intervention. Hypovolemic shock is best prevented or controlled by starting intravenous infusion in atleast 2 extremities. A balanced solution like Ringer's lactate is usually started until blood is available. Blood for typing and cross matching is also drawn. Response to therapy is monitored by skin perfusion, urine output and CVP readings.

Exposure for complete examination:

After having treated for most life threatening injuries, the next step is to re-examine the patient for the purpose of diagnosing other injuries. Complete physical examination is typically done in a head to toe manner and includes ordering and collecting data form appropriate laboratory and radiological investigation, for the placement of additional lines, catheter (nasogastric, Foley's) and monitoring devices. The current diagnostic techniques in assessing abdominal injury are discussed below.

DIAGNOSTIC METHODS

The following are the useful diagnostic methods in blunt abdominal trauma.

1. Four quadrant abdominal tap.

2. FAST

3. Plain radiography and contrast studies.

4. Ultrasound of the abdomen.

5. Abdominal CT scan.

6. Angiographic studies.

7. Radionuclide imaging.

8. Laparoscopy.

1. Four quadrant abdominal tap:

Simple needle aspiration has been used for a long time to diagnose abdominal injuries. Aspiration by a large bore needle (18G) is done in right and left hypochondrium and right and left iliac fossa. The accuracy is about 80% but it is argued to have inherent risk of causing visceral injuries. But this has been disproved at large. Aspiration of even a drop of blood that does not clot is diagnostic of hemoperitoneum. But a negative tap does not rule out hemoperitoneum.

2. FAST:

As quality ultrasound machines have become portable there is an increasing trend of their application in the initial evaluation of blunt abdominal trauma. Ultrasound can demonstrate the presence of free intraperitoneal fluid as well as the extent and precise location of solid organ hematomas.

- FAST sensitivity of 85% for detection of any intraabdominal injury.
- only intra abd surgical injury can be missed is mesenteric injury.
- Of the other missed injuries, extraperitoneal
- FAST in the hypotensive patient is an effective screening tool

Advantages: No use of radiation or contrast media.

Widely available.

Disadvantage:

Difficult to scan in presence of lower rib fracture, extensive skin lesions, soft tissue injuries and dressings. Studies have shown DPL was superior to ultrasound scan in assessing the need for surgical intervention.

Conclusion: Ultrasound of the abdomen can be used as complementary to DPL in the evaluation of blunt injury of abdomen.

3. Plain radiography and contrast studies:

Radiological procedures in a stable patient with blunt abdominal injury may be helpful especially when physical examination and lab investigations are inconclusive. Plain x ray abdomen should be done before other invasive tests such as paracentesis, in order to avoid confusion in detection of free air in the peritoneal

cavity. Should include AP view chest, supine abdominal and erect abdominal or left lateral decubitus view, if the patient cannot stand.

Chest radiograph will help in detecting thoracic and diaphragmatic injuries. Air under the diaphragm will be found in patients with gastric, duodenal, small intestine and colonic perforations. Presence of rib, pelvic, vertebral body and transverse spinous process fractures can be made out. General findings in case of blunt trauma would be:

a. Displaced bowel loops.

b. Enlargement or displacement of the viscera.

c. Presence of fluid where these should be made out.

d. Examination with water-soluble contrast reveals extravasation secondary to rupture, displacement and mucosal thickening due to edema and obstruction due to hematoma or incarceration.

e. Splenic outline can be made out.

f. Free intraperitoneal air is defined with horizontal beam films and is seen sub diaphragmatically on erect films and sub hepatic space on left lateral decubitus. Retroperitoneal air remains more localized and is not altered greatly with the change in the position of the patient. It is commonly associated with retroperitoneal rupture of duodenum. Also occurs with tears of retroperitoneal portion of the colon or rectum. The air has a streaky appearance over the psoas muscle and can extend to outline kidney and pancreas.

g. At least 800ml of intraperitoneal blood is required to be evident on plain abdominal radiograph. The following supporting signs may be observed.

The flank stripe sign: is a fluid dense zone separating the ascending or descending colon from the distinctly outlined lateral peritoneal wall and the colon is displace medially.

The dog ear sign: results from the accumulation of blood that gravitate between the pelvic viscera and the sidewalls of each side of the bladder.

The hepatic angle sign: is loss of definition of the usually clearly defined inferior and right lateral borders of the liver as blood accumulates between the hepatic angle and the right peritoneal wall.

Hemoperitoneum causes small bowel to shift towards the centre of the abdomen with the production of ground-glass appearance.

Diaphragmatic trauma: Plain x ray abdomen shows:

Malposition of the nasogastric tube is often the first sign of a ruptured left diaphragm.

Mediastinal shift to the side opposite of the injury, bowel loops above the diaphragm are seen.

In duodenal rupture both intra and retroperitoneal x ray studies are diagnostic. Free air or retroperitoneal air will be demonstrated as water soluble contrast will delineate the site. Intramural hematomas at the duodenum can be diagnosed by plain and contrast films.

4.Ultrasound of abdomen[1]:

As quality ultrasound machines have become portable there is an increasing trend of their application in the initial evaluation of blunt abdominal trauma. Ultrasound

can demonstrate the presence of free intraperitoneal fluid as well as the extent and precise location of solid organ hematomas.

Advantages: No use of radiation or contrast media.

Widely available.

Disadvantage: Immediate availability of an experienced

Ultrasonographer.

Difficult to scan in presence of lower rib fracture, extensive skin lesions, soft tissue injuries and dressings. Studies have shown DPL was superior to ultrasound scan in assessing the need for surgical intervention.

Conclusion: Ultrasound of the abdomen can be used as complementary to DPL in the evaluation of blunt injury of abdomen.

5. Computarized tomography of abdomen (CT scan): This can provide important diagnostic information on abdominal injuries. It plays an important role in the evaluation of blunt abdominal trauma when applied in appropriate setting.

Four groups of patients are particularly suitable for CT scanning:

1. Patients with delayed (<12hours) presentation who are hemodynamically stable and do not have overt signs of peritonitis.

2. Patients in whom tapping results are equivocal and the results of repeated physical examination are unreliable.

3. Patients in whom tapping is difficult to perform (eg: morbid obesity, late term pregnancy or multiple previous laparotomies); peritoneal adhesions pose a technical problem to catheter placement.

4. Patients at risk for retroperitoneal injuries .

Advantages:

It is an excellent means to diagnose intraperitoneal hemorrhage. It gives excellent views of spleen and liver permitting precise anatomic diagnosis of solid viscus injury. It is also the best in diagnosis of retroperitoneal injury. Stomach, duodenum, pancreas can be diagnosed with high degree of accuracy. Intravenous contrast permits excellent imaging of the kidneys and ureters.

Disadvantages:

The retroperitoneal colon injury is rarely delineated.

Requires a proper set up and proper interpretation of films. Scanning abdomen takes a minimum of 45-60 minutes and it is difficult to monitor the patient during the investigation. In hemoperitoneum more than 100ml of blood in the cavity will be detected.

6. Radionuclide imaging:

This non-invasive nature of isotope studies makes them attractive as a screening procedure. The reduced radiation dosage permits repeat and follow up studies with safety. But the obvious disadvantages are, they are not freely available in most centers and are dependent on the availability of an expert radiologist.

7. Arteriography:

Arteriography was main tool prior to CT scan and ultrasound. Its use is now limited for the evaluation of solid intra abdominal and pelvic arterial bleeding in patients with pelvic fractures. Therapeutic embolization can be carried when

needed. Abdominal aortography or selective visceral arteriography is useful in the diagnosis and management of intra abdominal bleeding after laparotomy for trauma. Contraindications to do arteriography is obvious need for laparotomy, unstable patient or allergic to the contrast agent. The primary advantage is to prevent negative laparotomy.

8. Laparoscopy or diagnostic laparotomy:

It is the final court of appeal in diagnosing blunt abdominal trauma. It has distinct advantage over a paracentesis because it provides visualization of the site and extent of bleeding.

Enzymes studies: Amylase and alkaline phosphatase levels of the effluent from DPL when equal or greater than the serum level is suggestive of injury to bowel, liver or pancreas.

Routine investigations: Hemoglobin, hematocrit, blood grouping and Rh typing, serum amylase and alkaline phosphatase, urinalysis, blood urea, serum creatinine, blood sugar, chest x ray and ECG are to be done.

MANAGEMENT OF INDIVIDUAL ORGAN INJURIES

STOMACH

Blunt gastric injuries most commonly occur after motor vehicle or motor pedestrian accidents. Injuries have also been reported after cardiopulmonary resuscitation, falls and direct violence particularly involving child abuse.

The most common mechanism of injury is a sudden increase in intraluminal pressure resulting from a direct blow to a full stomach in which case the rupture occurs along the anterior surface of the stomach or the greater curvature. In CPR, the injury is due to compression of the stomach against the vertebral column. Shearing of the walls of the stomach with rapid deceleration occur at the gastro esophageal junction, gastric necrosis due to avulsion of gastro epiploic vessels.

Diagnosis: A nasogastric tube placed during the resuscitation phase, serves both diagnostic and therapeutic functions. The return of gross blood on nasogastric aspirate is suggestive of an upper gastrointestinal injury. The NG tube also serves therapeutic function by decompressing the stomach. Patients may present with signs of peritoneal irritation or shock. Gas under the diaphragm in plain x ray abdomen is seen, but is not a constant finding. Peritoneal lavage is usually positive for blood or gastric contents. Contrast studies or computed studies are rarely needed.

Management:

Perioperative antibiotics prophylaxis should be instituted and is continued for 12 to 24 hours after operation. On opening the abdomen with a midline incision, control of hemorrhage is the first priority, followed by containment of enteric spill.

Priority is given to management of other intra abdominal injuries in case they are found, as gastric injuries are rarely life threatening. Enteric spill from gastric injuries is controlled by Babcock and figure of eight stitch temporarily.

When exploring the abdomen, the entire stomach should be examined carefully with special attention to gastro esophageal junction, greater curvature at the omental and splenic attachment, lesser curvature at the gastrohepatic ligament, posterior wall of the stomach.

Most of the blunt injuries of the stomach can be managed by simple debridement and repair. Partial or complete transection and devascularization injuries though rare may need resection. Repair is accomplished by two layer inverting closure. Inner layer is a continuous absorbable using chromic catgut or polyglycolic acid suture. Care should be taken not to narrow the gastric lumen . Consideration may be given to performing a pyloroplasty in wounds involving the pylorus. A gastric drainage procedure should also be performed for injuries along the lesser curvature when damage to the vagal nerves has occurred.

Repairs in other areas of the stomach are rarely difficult because of the mobility of the stomach and its rich blood supply. These injuries generally heal rapidly and without complication. Drainage of these wounds is not indicated. Before closure of the abdomen, the peritoneal cavity should be irrigated to remove gross

contamination. Gastric decompression, through nasogastric suction is maintained until bowel function returns.

Complications: are intraperitoneal abscesses, disruption of gastric repair, fistula formation, missed injuries, hemorrhage and obstruction of gastro esophageal junction or pylorus.

DUODENUM:

Blunt duodenal injuries are rare since it is a deep seated retroperitoneal organ in the abdomen. It is associated with high mortality and morbidity due to difficulty in initial assessment and establishment of diagnosis. A force that impacts the duodenum against the vertebral column would produce a crushing injury, i.e a direct blow to the abdomen by the steering wheel.

A bursting injury results when the intraluminal pressure exceeds the bowel wall strength. This injury occurs as a closed loop obstruction, with a seat belt harness acting as the obstructing point.

A shearing force can also cause rupture of the intramural duodenal blood vessels with accumulation of blood in the sub mucosal layer commonly seen in children, alcoholics and patients with coagulopathies and in child abuse.

Estimated from literature, duodenal injuries occur in 4.3%of all patients with abdominal injuries. Mortality in patients with duodenal injuries ranges from 13 to 28%. Morbidity of the duodenal wound is measured primarily as the incidence of duodenal fistula.

Usually associated injuries are present. The second portion of the duodenum is more commonly affected and pose greater technical difficulty for surgical

management. The small thin walled duodenum has marginal blood supply shared with pancreas. Therefore it is not amenable to sound technical closure and parts of it are very difficult to respect.

It is also fixed at two points, the portal triad and ligament of Trietz, there by subjecting it to deceleration injuries. Pancreas is invariably affected when duodenum is involved by crush injuries. High volume and high toxicity of duodenal contents account for disastrous effect when break in the duodenal wall occurs. The incidence of fistula following repair ranges from 2 to 14%.

Diagnosis: a high index of suspicion is required when evaluating patients with history of blow to upper abdomen especially in a patient with steering wheel injury to abdomen. Abdominal discomfort may be out of proportion to physical signs. May be associated with late signs of rebound tenderness, abdominal rigidity, referred pain in the back can occur.

Investigations:

1. Serum amylase is sensitive but non specific for duodenal injuries, is elevated in 50% of patients with duodenal injuries.

2. Needle paracentesis or lavage will often be positive for blood, bile or bowel contents. A negative peritoneal lavage does not exclude all duodenal injuries.

3. X ray erect abdomen may show intraperitoneal air, retroperitoneal air around kidney, or air in the biliary tree.

4. An emergency upper gastrointestinal series with water soluble material (gastrograffin) is a good way to exclude a duodenal injury.

5. CT scan with contrast may demonstrate small amounts of retroperitoneal gas and extravasated intestinal contrast material.

Grading system (mild and severe) has been designed to characterize duodenal injuries, which basically includes the parameters like:

1. Agent: blunt or penetrating injury.

2. Size: the involved circumference of the duodenum.

3. Character of the injury (simple laceration or destruction of the duodenal wall).

4. Associated injuries to the biliary tract, pancreas or major vascular structure.

Evaluation of the severity of the injury:

Mild Severe

Agent Stab Blunt or missile

Size <75% of wall >75% of wall

Site D3, D4 D1, D2

Injury-repair interval (hr) <24 or >24

Adjacent injury No CBD injury CBD injury

Treatment:

The duodenum must be adequately explored to exclude injuries if there is a retroperitoneal hematoma in the right upper quadrant. Other signs requiring exploration include crepitus or bile staining along the lateral margin of the duodenum, retroperitoneal edema, petechiae or fat necrosis in the retroperitoneum or right mesocolon, retroperitoneal phlegmon and discoloration. If these signs are present, the duodenum should be completely mobilized using Kocher maneuver

and reflection of the right colon mesentery, if necessary, to see the third and fourth portions of the duodenum. Duodenorrhaphy or simple repair will be successful in 70-85% of these wounds. A one or two layer closure can be used. A one layer closure with a Weinberg stitch may be particularly helpful in avoiding luminal narrowing in the pyloric channel area.

Simple small laceration of the duodenum can be repaired primarily in two layers, inner continuous absorbable sutures 2-0 and outer non absorbable 3-0 silk. It should be closed transversely. The periduodenal area should be drained.

The addition of tube decompression to simple closure remains controversial. Tube duodenostomy can be accomplished directly through the duodenal wall in proximity to the site of injury, by placement of a transnasal sump tube through the pylorus onto the duodenum or by retrograde insertion of a sump tube through a Witzel tunnel jejunostomy.

Large injuries of the duodenum are more difficult to repair. Injuries involving more than 50% of the duodenum should not be primarily closed, because it could compromise the lumen. If duodenum has been transected edges should be trimmed and two layer primary anastamosis done provided transection is not in proximity to the ampulla of vater.

Large injuries of duodenum can also be treated with a jejunal patch by bringing a jejunal loop and laying it on the area of injury so that the serosal of jejunum buttress the duodenal repair. If duodenum alone has been injured, a rare occurrence, the patient has to undergo a duodenojejunostomy to the defunctional Rou-en Y limb of jejunum. If there are associated injuries to pancreas or biliary

tract pancreatico duodenectomy may be necessary and the necessary pancreatic, gastric and biliary anastamosis to be done. When pancreatic injury is associated, raising the concern of digestive action of pancreatic enzyme on the repair, pyloric exclusion is done to defunctionalise the duodenum and protect the repair from activated pancreatic enzyme. The procedure involves, antrectomy, oversewing of the duodenal stump, tube decompression at the duodenum and biliary tract and gastro jejunostomy to restore gastro intestinal continuity.

Intramural duodenal hematoma: the treatment is usually non operative. The first step is excluding a perforation. Once this is done, the patients are placed on nasogastric suction, intravenous fluids and possibly intravenous hyperalimentation. Most of the patients are improved by 5 days. Surgery is appropriate for cases that are still obstructed after 7 to 10 days of treatment or that have evidence of perforation.

Small bowel injuries:

Owing to the large volume of peritoneal cavity occupied by the small bowel, it is the intra abdominal organ most frequently injured with penetrating trauma and it is the third most frequently injured organ (following the liver and spleen) in blunt trauma. Small intestinal injury occurs in 5-15% of cases in blunt abdominal trauma but the incidence varies according to socioeconomic status and geographic location. Three mechanisms involved in causing small bowel injuries are crushing, shearing and bursting injuries.

Small bowel injury scale is as follows:

Grades Injury description

I Hematoma Contusion or hematoma without devascularisation

Laceration Partial thickness, no perforation

II Laceration Laceration<50% of circumference

III Laceration Laceration>50% of circumference without transection

IV Laceration Transection of small bowel

V Laceration Transection of the small bowel with segmental

Tissue loss or Devascularized segment.

Diagnosis: the diagnosis of blunt injury to the small intestines is often difficult due to lack or late appearance of physical signs. It may take several hours before classical signs of peritonitis are evident, given the typically slow leakage of intestinal contents, which are minimally irritant to the peritoneum. Impaired sensorium due to head injury may add to the difficulty.

Pain abdomen following blunt injury, tenderness, guarding, and rigidity of varying grade should arouse the suspicion of small gut injury till not proved otherwise by various diagnostic tests. An upright chest x ray will demonstrate gas under the diaphragm in 20-50% of cases.

Management: Midline incision is preferred. The entire small intestine must be carefully examined from the ligament of Trietz to ileocecal valve, including all mural surfaces and mesenteric attachements.

Perforations: most perforations are closed by primary repair. Edges are debrided till it bleeds and two layers closure done. i.e inner layer of absorbable and outer layer of silk. When there are multiple perforations in a close area or the closure of

large laceration results in narrowing, resection anastamosis is done. Resection anastamosis should not be performed in last 15cms of ileum due to precarious blood supply. Rather end to side ileocolic anastamosis is preferred. Peritoneal cavity must be liberally irrigated with warm saline and particulate matter removed. Drains are optional.

Mural damage without perforation: the management of contusions and intramural hematomas of the small intestines require assessment for consideration of resection and anastamosis verses leaving the intestines in situ and opting for observation and second look surgery. Clinical judgement by observing the involved segment for signs of intestinal viability such as active peristalsis and color through out the procedure is important. Small mucosal hematoma (<1cm), nonexpanding may be turned in by a series of interrupted sutures. For larger mucosal hematoma transmural debridement/ segmental resection should be done whenever there is doubt regarding viability.

Mesenteric hematoma: assessment should be done to define the size, stability, i.e. is it expanding or non expanding, contained or has ruptured the mesenteric folds. Exploration is required for large, expanding and uncontained hematoma.

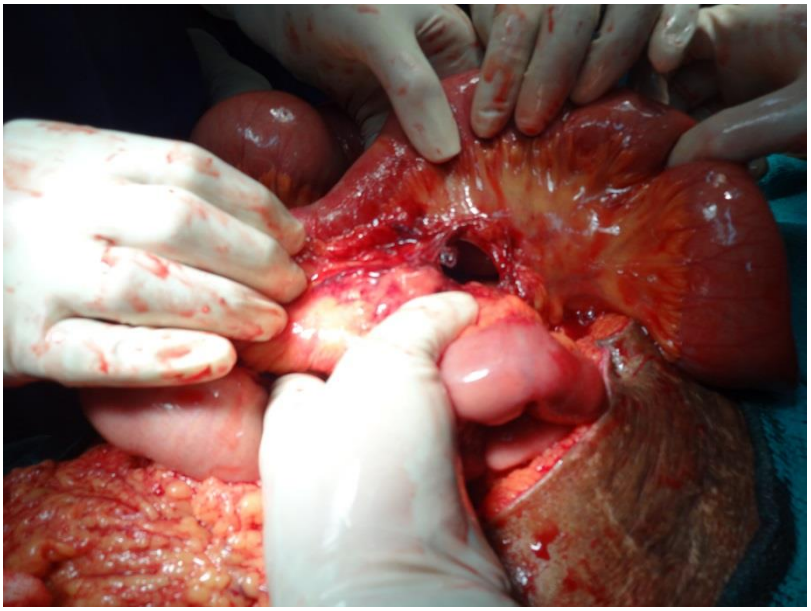

MESENTRIC TEAR

At exploration, the involved mesentery proximal to the hematoma (towards the base) should be examined and if possible site of vascular control defined. Manual compression is then applied to that hematoma, bisecting it. Following careful evacuation of clot, bleeding points are individually controlled with silk sutures. Viability of intestine distal to the area of vascular damaged must be determined and accordingly dealt with.

Injuries to the base of mesentery associated with large hematoma may cause severe bowel ischemia to the entire length of small bowel. Collateral flow is often inadequate to maintain viability. Resection under these circumstances is unsuccessful and vascular repair by interposition or patch graft of the involved vessels is mandatory. When large areas of ischemic bowel are in question one may opt for second look surgery/ re laparotomy.

Complications: post operative complications are missed injury, bleeding, suture line leak, anastomotic disruption, fistula formation, obstruction and abscess.

Missed injuries can be avoided if one carefully screens the whole intestine from ligament of Trietz to ileocecal junction. One should be careful towards the mesenteric border of the intestines where small perforation may be missed.

Hemorrhage: intraluminal blood loss may occur at suture lines, anastamosis, or areas of bowel contusion. Hemoglobin may fall, tachycardia may be present and patient may have malena or hematochezia depending on the amount of blood loss. If the patient does not respond to conservative treatment reexploration should not be delayed.

Colon and rectal injuries:

Colon and rectal injuries: blunt abdominal trauma to the colon is rare and constitutes about 4-6% of all blunt abdominal injuries usually caused by road traffic accidents. The injury involves more than one organ system.

Mechanism of injury: the bowel may be compressed against vertebral column or burst by a sudden blow against a distended loop. Sudden deceleration may tear the bowel or disrupt its mesentery. Crush injury may damage the colon or rectum in two ways. Pelvic fracture may produce perforation of the rectum by bone spicules, and occasionally, an explosion injury associated with valsalva at the time of crush may occur. Mortality rate ranges from 3-10%.

The extra peritoneal rectum is usually injured in association to the pelvis. This portion of the rectum is more or less fixed to the pelvis; thus may sustain severe

injury in common with pelvic fracture. The site of trauma in intra peritoneal injury to the large bowel is usually near the junction of the mobile and fixed portion such as junction of the sigmoid and descending colon. Injury may be to the bowel or mesentery. Injuries to the mesentery results in hemorrhage; if to the bowel; it results in contusion, intra mural hematoma or laceration (partial or complete). Most of the injuries will be recognized and dealt as acute problem. Few may manifest later as colocutaneous fistula and post traumatic stenosis.

Injuries to extra peritoneal rectum are due to:

1. Fractured pelvis lacerating the rectum by a bony spicule.

2. Avulsion at the rectum as a result of tremendous bursting force. Avulsion may be partial or complete. Organ injury scale for colon and rectum is as follows.

Colon injury scale:

Grade Injury description

I Hematoma Contusion or hematoma without devascularisation

Laceration Partial thickness, no perforation

II Laceration <50% of circumference

III Laceration >50% of circumference without transection

IV Laceration Transection of the colon

V Laceration Transection of the colon with tissue loss

Advance one grade for multiple injuries upto grade III

Rectum injury scale:

Grade Injury description

I Hematoma Contusion or hematoma without devascularization

Laceration Partial thickness laceration

II Laceration <50% of circumference

III Laceration >50% of circumference

IV Laceration Full thickness with extension into the perineum

V Laceration Devascularized segment

Diagnosis of the injuries:

Following injury varying intensity of pain in abdomen is present. Tenderness, guarding and rigidity may or may not be present. Shock is due to blood loss as a result of other associated injuries and not due to colonic injuries. Occasionally, symptoms of peritonitis may take few hours or days to develop. There may be blood on finger on per rectal examination or tenderness in pelvic peritoneum may be noticed. When bleeding is present per rectal examination should be followed by proctoscopy and rigid sigmoidoscopic examinations. Plane x ray may show gas under the diaphragm. USG abdomen may not contribute much. Enema with water soluble contrast CT scan in selected cases may be done where the symptoms are minimal and the diagnosis is doubtful. High index of suspicion and repeated clinical examination is mostly rewarding. Clinical deterioration in the patient's status, increased abdominal tenderness, an evolving pattern of sepsis, and development of paralytic ileus or mechanical obstruction are common findings in patients with either a missed injury or delayed perforation. And majority of colon injuries are diagnosed intra operatively.

Surgical options available are:

1. Primary closure without colostomy.

2. Primary closure with de functioning colostomy.

3. Resection and anastamosis.

4. Exteriorisation of injured colon/colostomy.

5. Exteriorised repair.

A number of factors have been identified which contribute to postoperative complications and influence the choice of procedure.

Risk factors:

Shock, fecal contamination, associated injuries, interval from injury to repair, mechanism of injury, severity of colon injury and location of injury.

Methods of repair:

Primary repair (simple suture): simple suture is resumed for clean low velocity injuries that require debridement and involve less than 25% of the colon circumference. The criteria are minimum blood loss, minimum fecal contamination, within 8 hours of injury.

Accepted contraindications for primary closure are:

• Prolonged or persistence hypotension

• Greater than 6 hour delay between injury and surgical intervention

• Gross fecal spillage

• Extensive damage to abdominal or retroperitoneal muscle

• Significant hemoperitoneum

• Multiple coexistence visceral injuries

• Devitilization of more than one fourth of the colon wall

• Impairment of blood supply to the injured segment

• Colon injury grade 3 or more

Most of the authors report primary repair in 50-65% of their patients. The technique involves thorough and meticulous debridement of the wound edges followed by a standard two layer closure (an inner layer of running or interrupted absorbable sutures followed by an outer layer of interrupted silk Lembert sutures). Prior to facial closure, the abdomen is liberally irrigated with saline and all particulate matter is removed. Drains are normally not indicated. The skin and subcutaneous tissue may be closed primarily with or with out a subcutaneous drain/ or by delayed primary method.

Primary resection and anastamosis: this procedure is ideal when there are extensive wounds of the right colon. Right hemicolectomy with ileocolic anastamosis can be accompanied with reasonable dispatch and an acceptable rate in the majority of patients. Hemodynamically unstable patients should have ileostomy, if, taking time for anastamosis will jeopardize their survival. Primary anastamosis may be performed in the left colon following resection of extensively damaged portion but it should be protected by a proximal colostomy.

Colostomy: indications for colostomy are: when the condition of the patient precludes taking the time to make a repair or anastamosis; when a distal anastamosis may be tenuous, when extensive distal destruction of the colon would require a low rectal anastamosis. It may be accomplished by:

1. Exteriorization.

2. Defunctioning colostomy

3. End colostomy and Hartmann procedure.

Exteriorization of the colon: it is the most rapid method available for managing a colon injury. Even in the fixed portions of the colon, mobilization can be accomplished quickly. If exteriorization is selected as an option, a small lateral incision is made and the two limbs of the mobilized colon are brought out as a double barreled colostomy.

Defunctioning colostomy: it is performed by separating the limbs and bringing each out as a single stoma.

Exteriorized repair: this procedure should be reserved for the rare patient on whom primary repair is in question. It is usually done when there is anti mesenteric injury from the mid ascending colon down to the sigmoid.

Rectal injuries:

Blunt injury to rectum is typically a crushing or compressive force applied to the pelvis or lower abdomen, as would occur when the victim has been struck or run over by a motor vehicle. Patients with massive blunt pelvic trauma should be viewed with a strong index of suspicion. Abdominal x ray should be obtained to see for retroperitoneal air. Procto sigmoidoscopy is done for direct visualization of the injury.

Peritoneal irritation, gross blood on rectal examination or full thickness injury noted on proctosigmoidoscopy is indication for operation. Patients with an

expanding abdominal girth or gross positive peritoneal lavage should be operated on.

Management:

Early definitive surgical management is indicated in any patient with following condition:

• Endoscopically visualized anorectal injury, regardless of associated injuries.

• A possible anorectal injury; clinically suspected but not identified.

• Open pelvic fracture, whether or not anorectal injury has been identified.

Management of rectal injury rests on the three D's:

• Diversion

• Debridement

• Drainage

Diversion: this is the most important step in the management of the injured rectum. A total diverting loop colostomy is adequate. Some surgeons use diverting colostomy, only when the injury is above the levators or dentate line. For anorectal injuries, below the dentate line, routine colostomy is not indicated.

Debridement and suturing: if anorectal injury is readily accessible to transanal approach, wound approximation using a single layer of running 3/0 absorbable suture may be attempted. If the sphincter mechanism has been injured, muscle approximation is performed using interrupted horizontal mattress 3/0 absorbable sutures. The anal mucocutaneous junction is left open for drainage purposes.

Rectal injuries can be closed relatively easily through the abdominal incision by opening the peritoneum and freeing the upper rectum as is done in elective resection. Repair of intraperitoneal rectal injury may be undertaken using the same criteria as in colon injury.

Drainage: should be presacral and through the perineum by penrose type drains or suction drainage and should be brought out just anterior to the coccyx.

Distal wash out: is accomplished by irrigating the distal colostomy stoma with dilute povidone solution through dilated anus until effluent is clear.

Bladder injuries: Urinary bladder is located deep within the bony pelvis and hence blunt trauma to bladder is rare. It commonly occurs following application of blunt external force to a fully distended bladder and usually associated with fracture pelvis. Classically described as intraperitoneal or extraperitoneal injury; depending on the site of injury. Extraperitoneal injuries occur in 75% of the cases and are generally in association with fractures of the pelvis. About 8 to 10% of pelvis fractures cause bladder injury due to laceration by the bony fragments. Intraperitoneal injury to the bladder occurs in about 25% of cases and follows application of blunt force to a fully distended bladder or in motor cycle accidents or fall from height.

Clinical features: Presentation of bruising over the lower abdomen, tenderness which is not well localized. Extravasation of urine and inability to void urine or hematuria may be present.

Diagnosis: Plane X ray pelvis confirms presence of fracture pelvis and the position of the fracture fragments. Cystogram is diagnostic. 250-300 ml of sterile contrast

material is used to distend the bladder. Free flow of contrast in the peritoneal cavity is classical, highlighting the bowel loops in intraperitoneal rupture. Drainage films with empty bladder will establish presence of residual extravasation of urine in extraperitoneal rupture of the bladder.

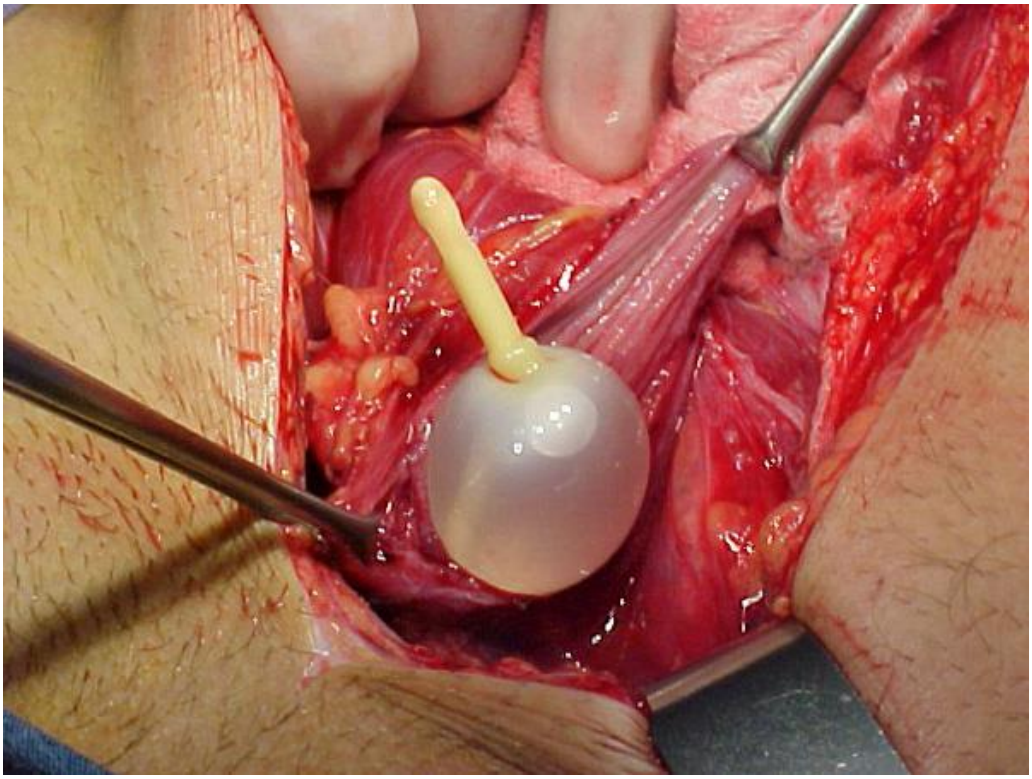

Management:

Extraperitoneal rupture: Open primary repair of the bladder in one or two layers with absorbable sutures is preferable.

Intraperitoneal rupture: Open primary repair of the bladder in one or two layers with absorbable sutures is preferable. It allows for inspection of the abdominal viscera for associated injuries which can also be taken care of. Supra pubic bladder catheter is kept and perivesical space is drained. 10-14 days later a cystogram is done to look for any leak.

MATERIALS AND METHODS

SOURCE OF DATA:-

This study is a retroprospective study of Patients coming with blunt injury abdomen due to RTA or TTA or Fall from height or Fall of heavy object to Department of General surgery in Rajiv Gandhi Govt. General hospital between June 2011 to December 2013

METHODS OF COLLECTION OF DATA: -

Data were collected from the patients by their clinical history, clinical examination with appropriate investigations on those patients who were admitted. Post operative follow up was done to note for complications. After initial resuscitation of the trauma victims, a careful history was taken to document any associated medical problem. Routine blood and urine tests were carried out in all the patients. Documentation of patients, which included, identification, history, clinical findings, diagnostic test, operative findings, operative procedures, complications during the stay in the hospital and during subsequent follow-up period, were all recorded on a proforma specially prepared. Demographic data collected included the age, sex, occupation and nature and time of accident leading to the injury.

After initial resuscitation and achieving, hemodynamic stability, all patients were subjected to careful examination, depending on the clinical findings; decision was taken for further investigations such as four-quadrant aspiration, diagnostic peritoneal lavage, x ray abdomen and ultrasound.

The decision for operative or non operative management depended on the outcome of the clinical examination and results of diagnostic tests.

Patients selected for conservative management were placed on strict bed rest, were subjected to serial clinical examination which included hourly pulse rate, blood pressure, respiratory rate and repeated examination of abdomen and other systems. Appropriate diagnostic tests especially ultrasound of abdomen was repeated as and when required.

OBSERVATIONS AND RESULTS

Patients coming with blunt injury abdomen due to RTA or TTA or fall from height or fall of heavy object to Department of General surgery in Rajiv Gandhi Govt General hospital between June 2011 to December 2013. 60 patients were taken up for study.

A) AGE INCIDENCE:

AGE GROUP (yrs)	NO.OF PATIENTS	PERCENTAGE (%)
11-20	12	20
21-30	21	35
31-40	15	25
41-50	6	10
>50	6	10

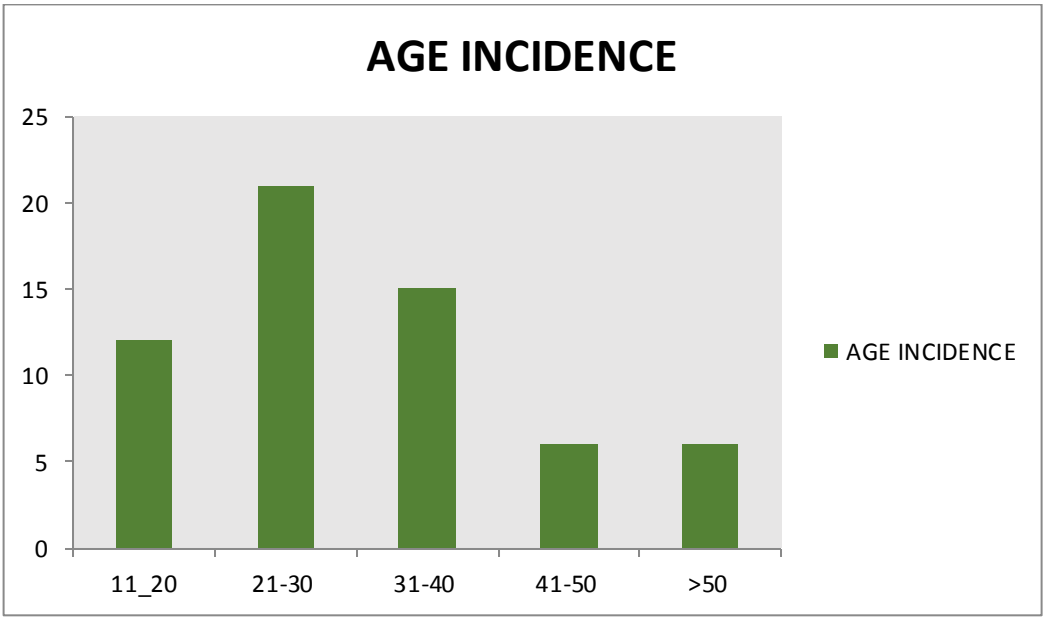

In this series, the majority of the patients belonged to 21-30 years age group, followed by 31-40 years age group.

B) **SEX INCIDENCE:-**

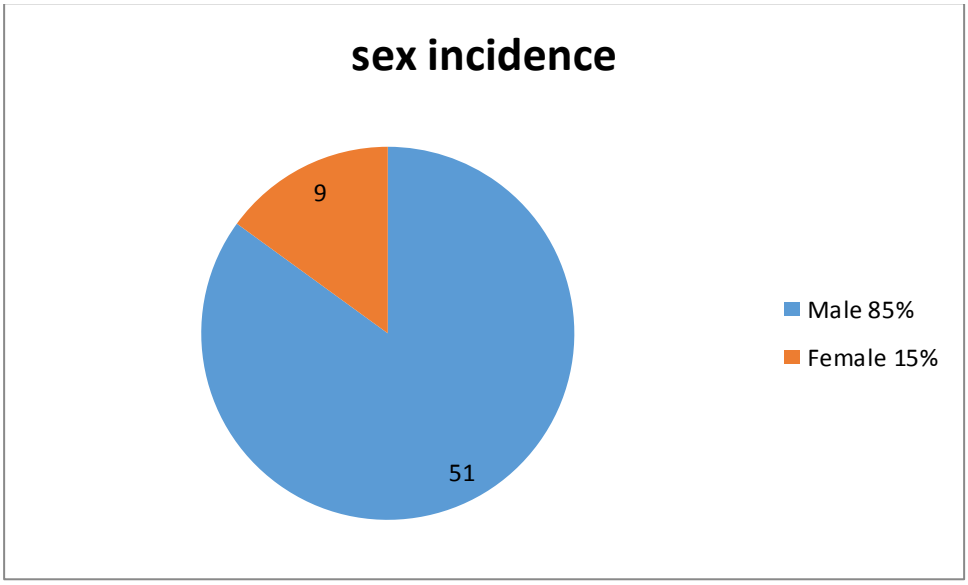

In the 60 cases studied, 51 cases were males, with females accounting for only about 9 cases.

GENDER	NO OF PATIENTS	PERCENTAGE
Male	51	85%
Female	9	15%

C) MODE OF INJURY:

CAUSATIVE AGENT	NO.OF CASES	PERCENTAGE (%)
Road traffic accident	36	60
Train traffic accident	4	7
Fall from height	13	23
Blow to abdomen with blunt objects	7	10

Road traffic accident was responsible for 60% of blunt abdominal trauma cases, while fall from heights accounted for 23% of cases and blow with blunt object was responsible for 7% of injuries.

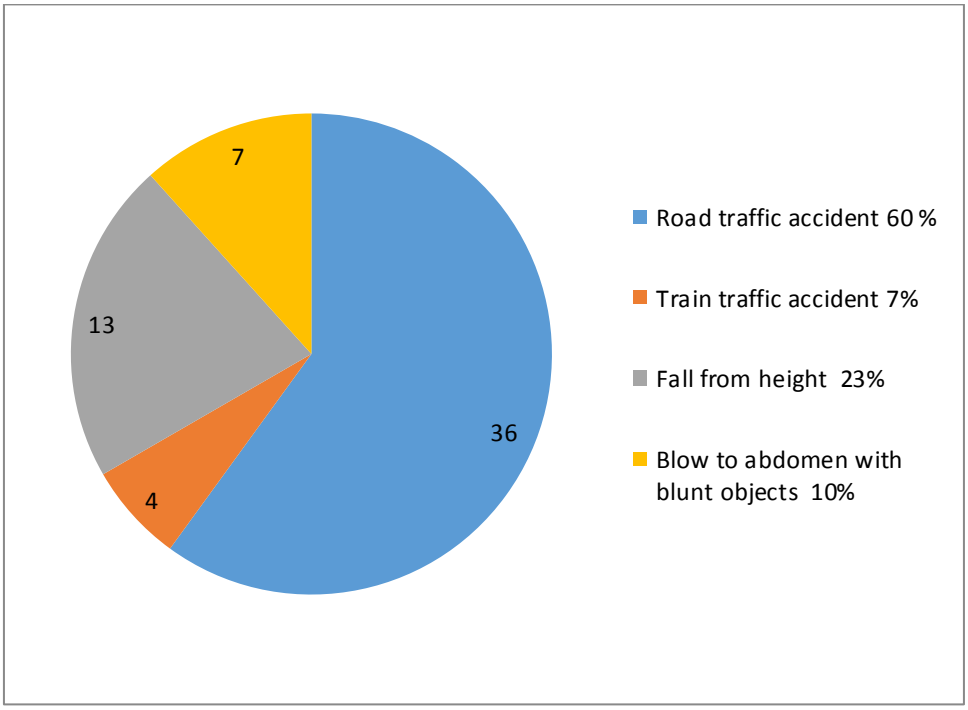

MODE OF INJURY

E) <u>SYMPTOMS AND SIGNS:-</u>

The following fig. shows the incidence of various symptoms and signs

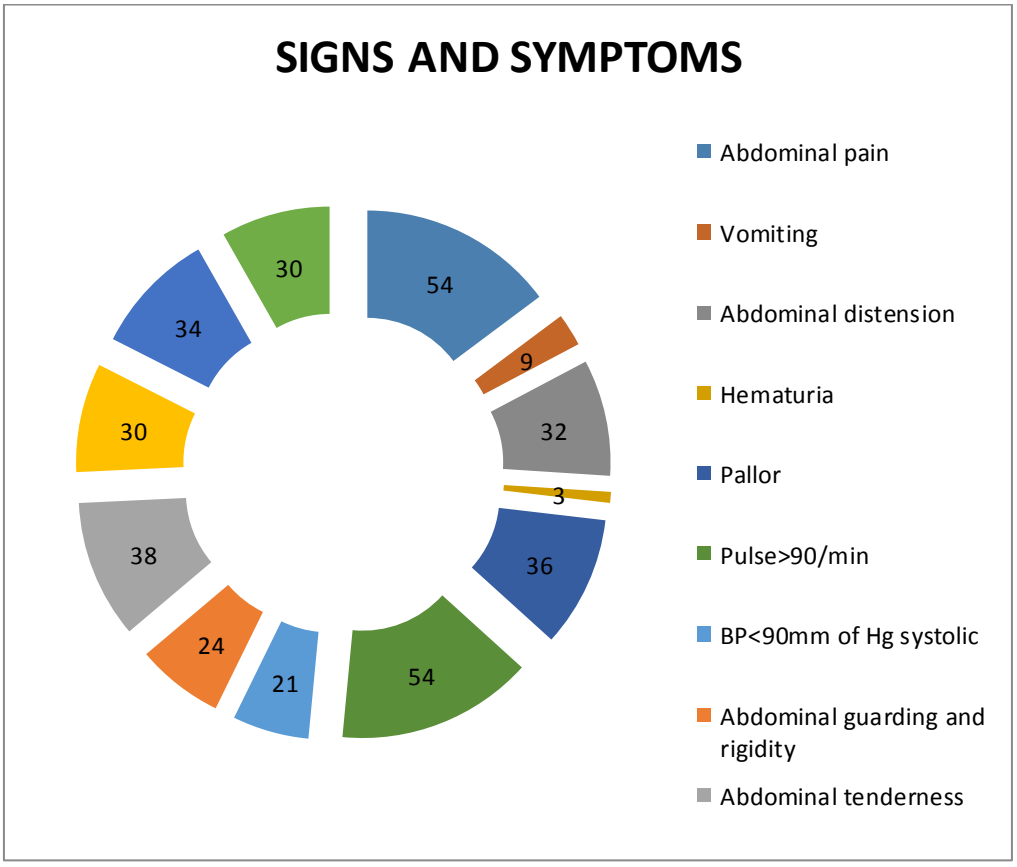

SYMPTOMS AND SIGNS	NO OF PATIENTS
Abdominal pain	48
Vomiting	9
Abdominal distension	32
Hematuria	3
Pallor	36
Pulse>90/min	54
BP<90mm of Hg systolic	21
Abdominal guarding and rigidity	24
Abdominal tenderness	38
Rebound tenderness	30
Free fluid	34
Absent bowel sounds	30

Majority of the patients presented with abdominal pain (90%) and abdominal tenderness (63%).

LATENT PERIOD:-

Latent period is the interval between the time of injury to the time of surgery.

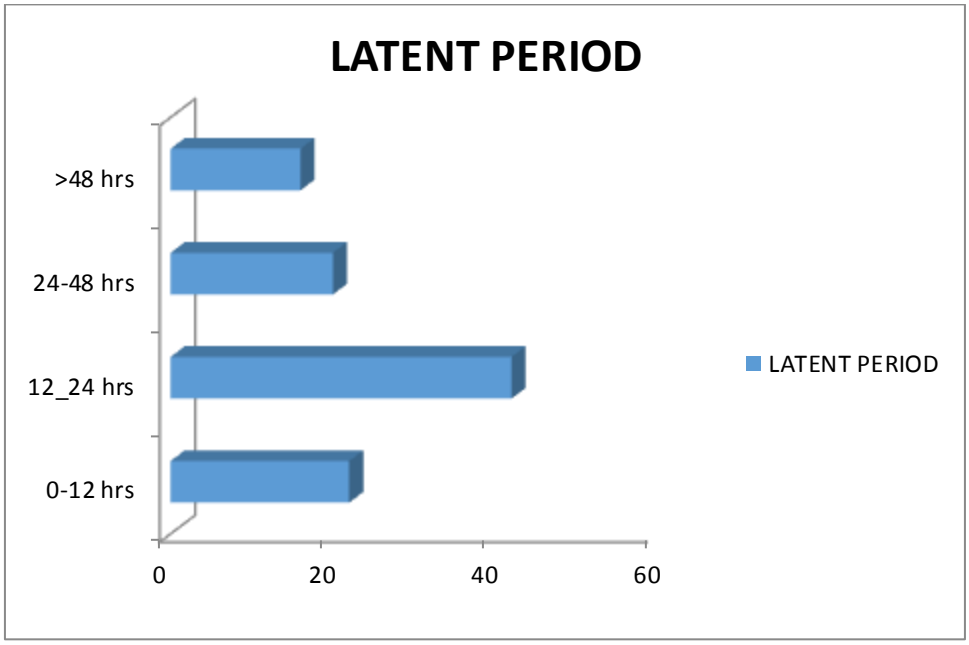

HOURS	NO OF CASES	PERCENTAGE
0-12	13	22
12-24	25	42
24-48	12	20
>48 hrs	10	16

Average latent period seen in the present study is between 12-24 hours. Majority of patients (40%) were taken for surgery between 12-24 hours of latent period.

ASSOCIATED INJURIES:

INJURIES	No of Pts	Percentage
Head	7	12%
Thoracic	3	5%
Orthopedic	12	20%
Polytrauma	12	20%

Associated extra abdominal injuries were found in 34 (57%) cases. The common extra abdominal injuries were chest injuries including rib fractures, extremity fractures, pelvic fractures and head injuries. Of these associated injuries, there were 3 cases of rib fractures with considerable amount of hemopneumothorax which was managed by insertion of water sealed inter costal drainage tube to avoid pulmonary complications. 2 cases of fracture of ethmoid bone and fracture of frontal bone were met and managed satisfactorily in consultation with ENT and facio maxillary specialties.

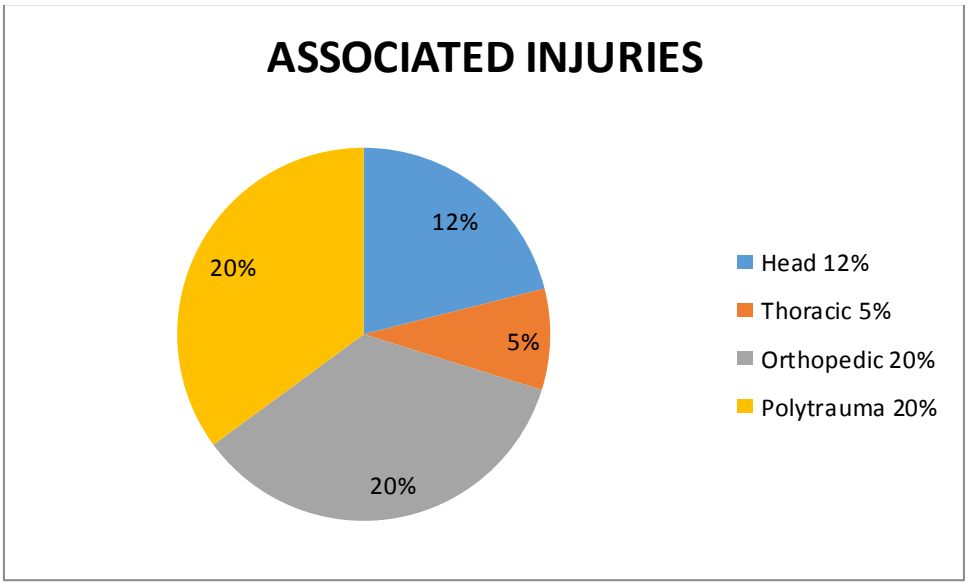

INVESTIGATIONS:

Most of the patients diagnosed with X–ray or CECT abdomen and remainder of patients diagnosed and taken up for surgery by X ray & USG findings and serial clinical examination.

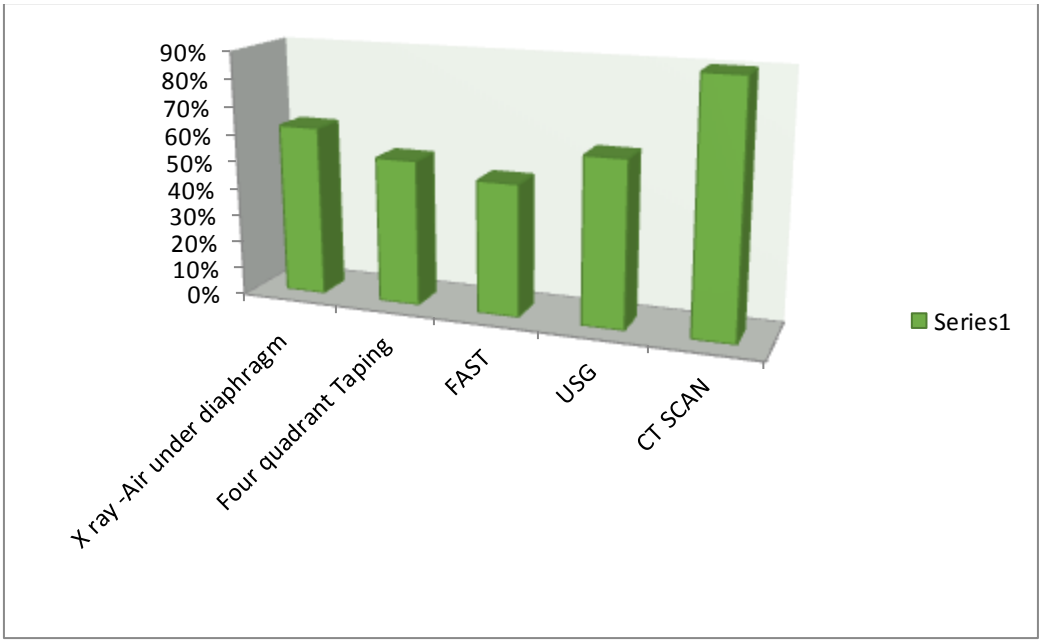

INVESTIGATIONS	NO. OF PATIENTS DIAGNOSED	PERCENTAGE
X ray -Air under diaphragm	37	62%
Four quadrant Taping	32	53%
FAST	29	48%
USG	36	60%
CT	23	90%

A CT was considered positive for HVI if there was presence of bowel wall thickening, bowel perforation, free intraperitoneal air, free fluid without solid organ injury, and mesenteric laceration or hematoma.

OPERATIVE FINDINGS:

ORGAN INJURED	NO. OF PATIENTS	PERCENTAGE
Gastric injury	6	10%
Small bowel injury	31	52%
Large bowel injury	5	8%
Mesenteric injury	18	30%
Bladder injury	3	5%
a/w solid organ injury	18	30%

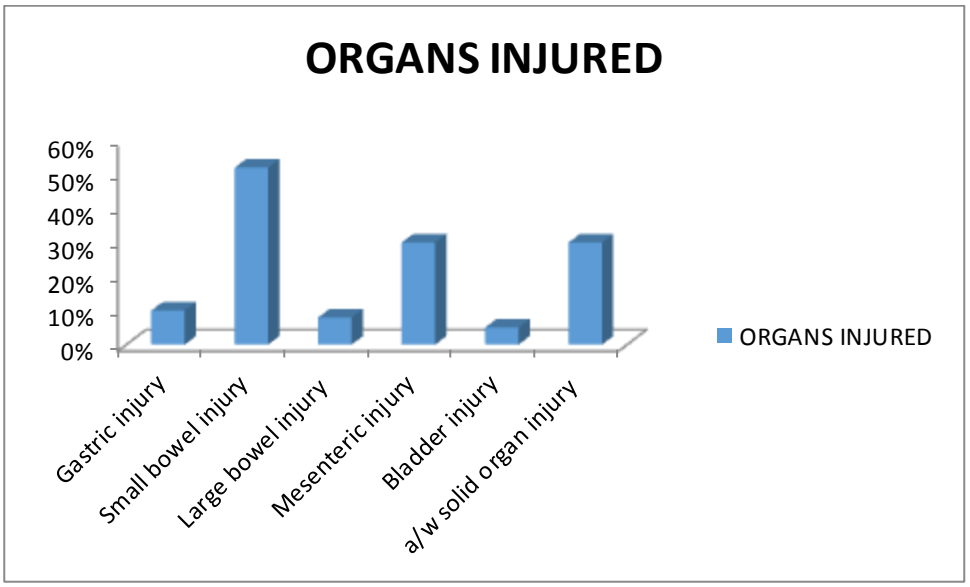

Most common injury is the small bowel injury accounts for 52 % of patients . Followed by next most common finding is the mesenteric injury .

OPERATIVE PROCEDURES:

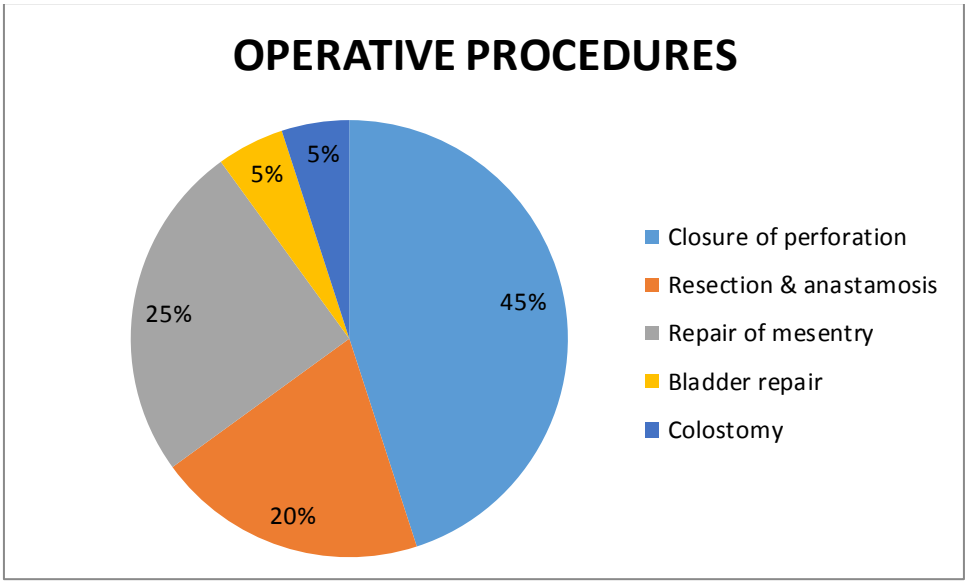

PROCEDURE	NO. OF PATIENTS	PERCENTAGE
Closure of perforation	27	45%
Resection & anastomosis	12	20 %
Repair of mesentry	15	25%
Bladder repair	3	5%
Colostomy	3	5%

The above table shows the various operative procedures carried out among the patients who underwent exploratory laparotomy. Bowel perforations were treated with 2 layered closure, with 12 patients requiring resection and anastamosis. Omental and mesenteric injuries were treated by simple suturing and ligating the

bleeding points. Bladder injuries were repaired by 2 layered closures under the supervision of Urologist.

In the present series of 60 cases, one case of duodenal perforation was found which was simple and was closed by 2 layered closures. We could not find any case of disruption of the biliary tract and pancreatic injury in this series.

POST OPERATIVE COMPLICATIONS:

The following table shows the postoperative complications and their relative incidences in patients who underwent exploratory laparotomy.

POST OPERATIVE COMPLICATION	NO. OF CASES	PERCENTAGE
Wound dehiscence	5	8%
Wound infection	7	11%
Respiratory complication	4	6%
Intra abdominal collection	6	10%

MORBIDITY AND MORTALITY:

The mean range of stay of patients in the hospital ranged from 11-20 days (15 days). The range varied from 2 days to 60 days.

The following table shows the duration of stay of patients with blunt abdominal trauma including those who died.

DURATION OF HOSPITAL STAY

DURATION OF HOSPITAL STAY(days)	NO. OF PATIENTS	PERCENTAGE
1-10	17	28%
11-20	27	45%
21-30	8	13%
31-40	5	8%
41-50	2	4%
51-60	1	2%

MORTALITY:

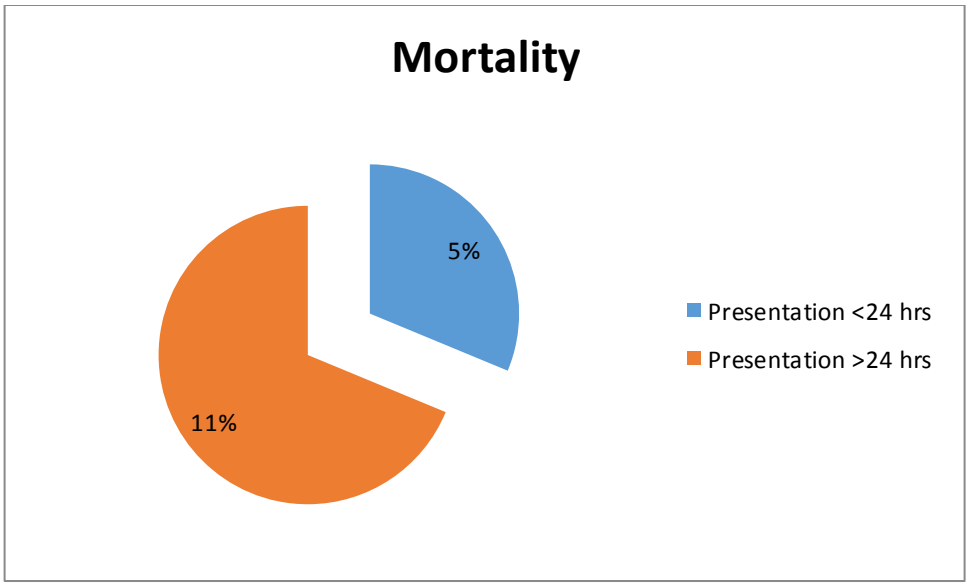

A total of 10 patients died in the present study. 9 patients belonged to operative group and died in the post operative period, majority of them due to peritonitis and septicemia. One patient died before surgery due to severe head injury.. This shows the disadvantages of delayed presentation due to missed injuries causing delayed treatment. Therefore the mortality in the present study is 16%.

Mortality	No of patients	Percentage
Presentation <24 hrs	3	5%
Presentation >24 hrs	7	11%

Mortality	No of patients < 24 hrs	No of patients >24 hrs
Small bowl injury		2
Mesenteric injury with severe hemoperitoneum	1	
Large bowel injury	1	4
Due to associated injury	1	1

DISCUSSION

AGE INCIDENCE:

The following table compares the incidence of blunt abdominal trauma in various age groups in the present series to that of the Davis et al

In this series, the majority of the patients belonged to 21-30 years age group,

AGE GROUP (yrs)	PRESENT STUDY (%)	DAVIS ET AL
11-20	20	19
21-30	35	24
31-40	25	15
41-50	10	13
>50	10	9

followed by 31-40 years age group comparable with davis et al study. Therefore it can be concluded that the young and the productive age group people are the usual victims of blunt abdominal trauma.

SEX INCIDENCE:

GENDER	PRESENT STUDY	DAVIS ET AL
Male	85%	70%
Female	15%	30%

From the above table, it can be seen that the males are the more common victims of blunt abdominal trauma. When compared to other studies the incidence of males is much more than those of the females, as, in India males are the chief bread earner for the family and are involved in outdoor activities most of the times.

MODE OF INJURY:

CAUSATIVE AGENT	PRESENT STUDY	DAVIS ET AL	KHANNA ET AL
Road traffic accident	60%	70%	57%
Train traffic accident	7%		
Fall from height	23%	6%	15%
Blow to abdomen with blunt objects	10%	17%	33%

The above table clearly depicts that the road traffic accident is the most common mode of injury. This is due to the rapid development in technology, in all fields including automobile industry where the first priority has been given to speed rather than safety.

SIGNS AND SYMPTOMS:

In the present study, abdominal pain was the most common presenting complaint accounting for 80% and abdominal tenderness was the most common sign accounting for 63% of cases. But the signs and symptoms in abdominal injuries are

notoriously unreliable and are often masked by concomitant head injuries, chest injuries and pelvic fractures. Significant injuries to the retroperitoneal structures may not manifest signs and symptoms immediately and be totally missed even on abdominal x rays. In Davis et al study, 43% of patients had no specific complaints and no signs or symptoms of intra abdominal injury when they first presented to the emergency room. But 44% of those patients eventually required exploratory laparotomy and 34% of patients had an intra abdominal injury. This emphasizes the importance of careful and continuing observation and repeated examination of individuals with blunt abdominal trauma.

LATENT PERIOD:

Latent period is the interval between the time of injury to the time of surgery. Average latent period seen in the present study is between 12-24 hours. Majority of patients (40%) were taken for surgery between 12-24 hours of latent period. 2 patients were taken for surgery after 5 days of injury as they were initially put on conservative management. Since their condition deteriorated on repeated clinical examinations, they had to be taken up for delayed exploratory laparotomy.

ASSOCIATED INJURIES:

INJURIES	PRESENT STUDY	**DAVIS ET AL**	**KHANNA ET AL**
Head	12%	9%	12%
Thoracic	5%	27%	24%
Orthopedic	20%	15%	27%
Polytrauma	20%	6%	

Associated extra abdominal injuries were found in 34 cases. The common extra abdominal injuries were extremity fractures, pelvic fractures, head injuries and chest injuries including rib fractures. The above table shows the comparison of the present study incidences of associated injuries with other studies.

INVESTIGATIONS:

FOUR QUADRANT ASPIRATION:

32 cases were found to be positive and 28 cases were negative. Therefore the sensitivity of this investigation in the present study is 53%. Correct results (positive or negative), as determined by subsequent laparotomy, were obtained in 86% of cases in Davis ET al study.

PLAIN X RAY ABDOMEN:

Gas under diaphragm was found in 37 cases out of 42 bowel perforations detected at laparotomy. So the sensitivity of plain x ray abdomen in detecting the pneumoperitoneum is 88% in the present study. Davis et al reported that in their

series, abdominal x ray showed air under diaphragm in 21% of cases in ;most common injury missed is the mesenteric injury and diagnosed by CT scan of abdomen and serial cinical examination .

ULTRASOUND EXAMINATION:

A total of 60 patients were subjected for ultrasound examination, out of which 36 patients had scan detected abnormal findings that includes solid organ injuries and free fluid without solid organ injuries. Therefore ultrasound is more reliable in detecting solid organ injuries and free fluid in the abdomen. In Yoshi H et al study, the sensitivity of ultrasound in detecting injuries in blunt abdominal injury patients is about 94.6%.

ORGANWISE INJURY:

ORGAN INJURED	PRESENT STUDY	WOLFMAN ET AL	KHANNA ET AL
Gastric injury	10%	4%	
Small bowel injury	52%	34%	57%
Large bowel injury	6%		
Mesenteric injury	30%	26%	47%
Bladder injury	5%	4%	
A/w solid organ injury	30%	40%	61%

The above table compares the incidences of the organs involved in blunt abdominal trauma in the present study to that of the international series. Small bowel was involved in 52% of cases, followed by mesentric injury.

OPERATIVE PROCEDURES:

Bowel perforations were treated with 2 layered closure, with 12 patients requiring resection and anastamosis. Omental and mesenteric injuries were treated by simple suturing and ligating the bleeding points. Bladder injuries were repaired by 2 layered closures under the supervision of Urologist.

In the present series of 60 cases, one case of duodenal perforation was found which was simple and was closed by 2 layered closures. We could not find any case of disruption of the biliary tract and pancreatic injury in this series.

MORTALITY:

A total of 10 patients died in the present study. 7 patients died in group which presented more than 24 hrs. This shows the disadvantages of delayed presentation due to missed injuries causing delayed treatment. Therefore the mortality in the present study is 16%. This is comparable with other series published in our country (Khanna et al). The mortality rate in Davis et al study is 13.3%, Di Vincenti et al study (1968) was 23%. Cox et al study reports a mortality rate of 10%.

Mortality	Present study	Davis et al study	Di Vincenti et al study
Presentation <24 hrs	16%	13.3%	23%.

SUMMARY AND CONCLUSION

This was a retroprospective study of 60 cases of blunt abdominal trauma in Rajiv Gandhi Govt General hospital between June 2011 to December 2013. From this study, the following conclusions can be made.

1. Males are predominantly affected. It is mostly seen in the age group of 21-30 years which form the young and productive group. These patients are usually from lower socio economic income group.

2. Road traffic accident forms the most common mode of injury. Hence measures should be taken to prevent these accidents and care of the victims at the accident site. Well established trauma care centers should be established at least at every District hospital. Measures for early transport of the patients from the accident site to the trauma center should be undertaken.

3. A thorough and repeated clinical examination and appropriate diagnostic investigations lead to successful treatment in these patients.

4.In bowel injury, operative management remains the main stay of treatment.

5. Plain erect x ray abdomen is a valuable investigation taken for gastrointestinal injuries.

6. Ultrasound examination gives a clear picture of solid organ injury and free fluid. Four quadrant aspiration is a simple and an important tool for diagnosis.

7.Most of the patients diagnosed with CECT abdomen and remainder of patients diagnosed by X ray & USG findings and serial clinical examination.

8. The most common injured viscera in the present study is small bowel and they were managed by simple suturing.

9. Mesenteric injury is the second most common injury and majority of them were managed by simple repair. Few of them were managed by resection anastomosis due to unviable bowel.

10.Bladder injury was seen in a small proportion of patients associated with pelvic fracture. They are repaired under supervision of urologist.

12. Multiple organs were involved in most of the cases rather than an isolated organ injury.

13. Associated extra abdominal injuries like head, thoracic and orthopedic injuries were found in 34 cases in the present study. These greatly influenced the morbidity and mortality of the patients.

14. Post operative complications like wound infection, dehiscence, respiratory infections and fecal fistula are common in blunt abdominal trauma.

15.Among the total mortality of 10 pts, 7 patients died in group which presented more than 24 hrs. This shows the disadvantages of delayed presentation due to missed injuries causing delayed treatment. The mortality in the present study is 16%.

BIBLIOGRAPHY

1. Sabiston's Text book of surgery: 18th edition: vol 1:
2. Decker, G.A.G.,Lee McGregor's Synopsis of Surgical Anatomy, Bristol; John Wright and Sons LTD, 1986
3. Surgery of the liver and biliary tract: L.H. Blumgart: vol 1: 3rd edition: 2000: 1277-1318p
4. Hamilton Bailey's Emergency surgery: 13th edition: 2000: p446-471
5. Joe Jack Davis, Isidore Cohn, Francis C. Nance; Diagnosis and management of Blunt abdominal trauma. Ann, Surg, June 1976: vol 183: No 6; p672-678
6. R. Khanna, S Khanna, P Singh, Puneet and A K Khanna; Spectrum of blunt abdominal trauma in Varanasi; Quarterly J Surg Sciences; vol 35, No 1 & 2, March & June 1999; p25-28.
7. Cusheri A, Giles G. R., Moosa A. R: Essential Surgical Practice; Butterworth International Ed. 1998: p263-304
8. Cox, Everard F; Blunt abdominal trauma: A 5 year Analysis of 870 patients requiring Celiotomy; Ann, Surg; April 1984 vol 199; p467-474
9. Diagnosis and management of blunt small bowel injury: a survey of the membership of the American Association for the Surgery of Trauma. 2000 Mar: 48 (3): 402-7.

10. DiVincenti FC, River JD, Laborde EJ, et al: Blunt abdominal trauma. J Trauma 8: 1004, 1968.
11. Donald D. Trunkey, Tom Shires, Robert McClelland; Management of Liver Trauma in 811 consecutive patients. Ann Surg. May 1974: vol 179: No 5; p722-728
12. Eddy H Carrillo, Christopher Wohltmann, J. David Richardson, Hiram C. Polk; Evolution in the treatment of complex blunt liver injuries; current problems in surgery. Mosby; vol 38 No 1, January 2001, p1-60.
13. Erwin R. Thal; Abdominal trauma, Surgical clinics of North America: vol,70/No 3: June 1990, W.B. Saunders Company.
14. Feliciano D: Diagnostic modalities in abdominal trauma; peritoneal lavage, ultrasound, computed tomographic scan and arteriography, Surg. Clinics North America: 1991; 71:241.
15. Goins. A, Rodriguez, Brathwaite, Colin E.M et al; Retroperitoneal Hematoma after Blunt Trauma
16. Gupta, Roshan Lall, Ed., Recent Advances in surgery (no. 6), New Delhi, Jaypee Brothers; 1998, p140-148
17. Jani PG, Abdel-Aziz IS, Yajnik KN: Duodenal perforation following Blunt abdominal trauma; case report; East African Medical Journal. Vol 75 (11): 669-70, 1998 Nov.
18. Corriere Jn Jr and Sandler EN. Management of the ruptured bladder: 7 years of experience with 111 cases J Trauma. 1986: 26: 830.

19. Bailey and Love's short practice of surgery: 25th edition: 2004: 286-287p, 1069p

20. Associated injuries in blunt solid organ trauma: implications for missed injury in nonoperative management. J Trauma. 2002 Aug: 53 (2): 238-242.

21. Blunt upper abdominal trauma : evaluation by CT. Nell T.Wolfman, Robert E.bechtold, Eric S.Scharing and J.Wayne Meredith.

PROFORMA

BLUNT INJURY ABDOMEN

A. NAME

B. AGE

C. SEX

D. IP NUMBER

E. RELIGION

F. ADDRESS

G. TIME AND DATE OF INJURY

H. DATE OF ADMISSION

I. TIME AND DATE OF OPERATION

J. LATENT PERIOD

K. DATE OF DISCHARGE

PRESENTING COMPLAINTS (SYMPTOMS)

1. MODE OF INJURY

- Road Traffic Accidents
- Fall From Height
- Bull Gore
- Assault
- Industrial & Others

2. SITE AND NATURE OF INJURY

3. PAIN: Present/ Absent

1. If present: Site:

Character:

Duration:

Radiation:

Aggravating/reliving factors:

4. VOMITING:

Bilious

Non bilious

Hematemesis

5. PASSED:

Urine

Stools

Flatus

6. HISTORY OF:

Hematuria

Hematochezia

Malena

7. OTHERS

C. PAST HISTORY:

- Diabetes Mellitus
- Tuberculosis
- Epilepsy
- Malaria
- Previous Surgery
- Jaundice
- Cirrhosis

D. PERSONAL HISTORY:

- Smoker
- Alcoholic
- Drug Addiction

E. INITIAL ASSESMENT OF PATIENT:

1**.** ***VITAL SIGNS****:*

Pulse

Blood Pressure

Respiratory rate

Temperature

Level Of Consciousness

Signs and degree of shock

Urine output

2. ***GENERAL SIGNS:***

Pallor

Cyanosis

Ieterus

F. ASSESMENT OF ABDOMINAL INJURIES:

INSPECTION:

Contusion

Abrasion

Lacerations

Bleeding present/ absent

Discoloration of abdominal wall

Renal angle fullness

PALPATION:

Tenderness

Guarding and Rigidity

Mass

Renal angle tenderness

Peritonitis signs

PERCUSSION:

Free fluid present/ absent

Liver dullness

Splenic dullness

Renal angle dullness

Any other area of dullness

AUSCULTATION:

Bowel sounds

PRE RECTAL EXAMINATION:

Bleeding

Tenderness

PRE VAGINAL EXAMINATION:

Bleeding

Tenderness

Discharge

G. SPECIAL SIGNS:

Spleen

Liver

Kidney

Pancreas

H. ASSOCIATED INJURIES:

Head and neck / ENT

Spine

Chest

- External genitalia and pelvis
- Extremities
- Others

I. ASSOCIATED CONDITIONS:

- Psychosis
- Pregnancy
- Other Medical Conditions

L. OTHER SYSTEMS:

- CARDIOVASCULAR SYSYTEM
- CENTRAL NERVOUS SYSTEM
- MUSCULAR SKELETAL SYSTEM

CLINICAL DIAGNOSIS :

INVESTIGATIONS

A. HB%

B. GROUPING AND TYPING

C. BLEEDING TIME/ CLOTTING TIME

D. PCV

E. HBS AG HIV

F. ECG

G. URINE

i. Rbc

ii. Albumin

iii.. Sugar

H. BLOOD

i. RBS

ii. Blood urea

iii. Creatinine

iv. Amylase

I. FOUR QUADRANT ASPIRATION

J. PLAIN ERECT X RAY OF ABDOMEN

K. CHEST X RAY PA VIEW

L. ABDOMEN ULTRASONOGRAPHY - FAST

M. ULTRASONOGRAPHY

N. CT SCAN

PRE-OPERATIVE DIAGNOSIS:

OPERATIVE PROCEDURE:

ANESTHESIA:

INCISION:

SURGICAL PROCEDURE:

INTRA OP FINDING:

POST OPERATIVE PERIOD/ COMPLICATIONS:

a. Fever

b. Jaundice

c. Wound Infection/ dehiscence

d. Intra peritoneal collections

e. Ileus

f. DVT

g. Others

FOLLOW UP:

MASTER CHART

S.No.	NAME/ IP No.	Age/ Sex	Mode of injury	IP In hrs	ASSOCIATED INJURIES	Hb	PLAIN X RAY Abdomen	USG	4 QT	CT	Clinical diagnosis	Laprotomy findings	Operative procedure	Post procedure outcome
1.	Jitendar sharma 99588	21,M	RTA	8	-	10.7	N	FF	+ ve	Pneumoperitoneum Bowel wall thickening FF	BIA with HVI	Ileal perforation	Perforation closure	Complete recovery
2.	Sodalaiyandi 104250	45,M	RTA	22	polytrauma	11.1	AUD	FF	+ ve	Not done	BIA with HVI	Jejunal perforation	R & A	Complete recovery
3.	Subramani 111843	45, M	RTA	15	Head injury	9.8	AUD	FF	+ ve	Not done	BIA with HVI	Gastric and jejunal perforation	Perforation closure	Pelvic collection
4.	Gandhi 111791	40 M	RTA	24	Left hemothorax	10	N	FF	+ ve	Hemoperitoneum Grade I splenic injury	BIA	Mesenteric tear	Closure of mesenteric tear	Respiratory complications
5.	Harikrishnan 116644	24 M	RTA	4	-	10.8	N	FF	- ve	Not done	BIA	Jejunal perforation	Perforation closure	Wound infection
6.	Mariyappan 122722	M	BWB	17	-	9.6	AUD	N	- ve	Not done	BIA with HVI	Jejunal perforation	Perforation closure	Complete recovery
7.	Chitra 123435	48 F	FFH	23	-	11.2	N	FF	+ ve	Solid organ normal	BIA	Mesenteric tear	Closure of mesenteric tear	Wound dehiscence

MASTER CHART

8.	Sundar 118967	26M	RTA	13	Head injury	9.6	AUD	FF	+ ve	Not done	BIA with HVI	Ileal perforation	Perforation closure	Complete recovery
9.	Veeramani 121907	32, M	TTA	57	-	8.9	AUD	N	- ve	Not done	BIA with HVI	Ileal perforation	Perforation closure	Complete recovery
10	Kannan 121333	75 M	FFH	21	polytrauma	10.1	N	N	- ve	FF	BIA	Mesenteric tear	Closure of mesenteric tear	Complete recovery
11	Chandrasekar 1687	24M	RTA	5	-	11.4	N	N	- ve	N	BIA	Mesenteric tear	Closure of mesenteric tear	Wound infection
12	Sivanathan 116697	32M	RTA	18	-	12.1	AUD	FF	+ ve	Not done	BIA with HVI	Descending colon perforation	colostomy	death
13	Devi 117682	33, F	RTA	28	-	8.2	AUD	N	- ve	Not done	BIA with HVI	Ileal perforation	R & A	Respiratory complications
14	Ramesh 121313	29 M	BWB	60	Rt humerus #	9.3	AUD	N	- ve	Not done	BIA with HVI	Gastric perforation	Perforation closure	Complete recovery
15	David 120943	34, M	FFH	20	-	11.1	AUD	FF	+ ve	Not done	BIA with HVI	Ileal perforation	R & A	Pelvic collection

MASTER CHART

16	Vijaya 118646	37, F	RTA	26	Rt hemothorax	7.9	AUD	FF Liver laceration	+ ve	Not done	BIA with HVI with liver injury	Jejunal perforation with liver laceration	Perforation closure	Complete recovery
17	Ravichandran 117806	25, M	TTA	5	Head injury	9.4	N	N	- ve	N	BIA	Mesenteric tear	Closure of mesenteric tear	Complete recovery
18	Kamalakannan 118657	29, M	FFH	65	polytrauma	10.3	AUD	FF Liver injury	+ ve	Not done	BIA with HVI with liver injury	Jejunal perforation with grade 1 liver injury	Perforation closure	Pelvic collection
19	Balaji 119980	52, M	RTA	26	Lt lateral malleolar #	9.9	AUD	N	- ve	Not done	BIA with HVI	Transverse colon perforation	colostomy	Death
20	Siva 128790	23, M	RTA	38	-	9.6	N	FF	- ve	FF	BIA	Mesenteric tear	Closure of mesenteric tear	Wound infection
21	Kanna 101345	55, M	RTA	54	-	9.2	AUD	N	- ve	Not done	BIA with HVI	Ileal perforation	Perforation closure	Death
22	Ramar 102123	21, M	RTA	7	polytrauma	10.1	N	N	- ve	Pneumoperitoneum Bowel wall thickening FF	BIA	Gastric perforation	Perforation closure	Pelvic collection

MASTER CHART

23	Arivalagan 102786	14, M	RTA	15	Head injury	11.2	N	FF	+ ve	FF	BIA	Mesenteric tear	Closure of mesenteric tear	Complete recovery
24	Raja 103767	26, M	FFH	19	Temporal lobe contusion	9.6	AUD	FF	+ ve	Not done	BIA with HVI	Ileal perforation	R & A	Complete recovery
25	Karthikeyan 105387	28, M	RTA	27	polytrauma	9.6	N	FF	+ ve	FF	BIA	Mesenteric tear	Closure of mesenteric tear	Wound infection
26	Kumar 6956	35, M	RTA	15	Lt hemothorax	10.6	AUD	FF	+ ve	Not done	BIA with HVI	Jejunal perforation	R & A	Complete recovery
27	Muthusamy 7893	67, M	RTA	72	-	8.9	AUD	N	- ve	Not done	BIA with HVI	Descending colon perforation	Lt hemicolectomy	death
28	Dhanapal 8234	28, M	BWB	8	-	8.6	N	N	- ve	FF	BIA	Mesenteric tear	Closure of mesenteric tear	Complete recovery
29	Kantha 104279	52 F	RTA	20	Lt ulnar #	9.5	N	N	- ve	Pneumoperitoneum Bowel wall thickening	BIA with HVI	Gastric perforation	Perforation closure	Complete recovery
30	Ravi 105678	39, M	FFH	30	-	9.4	AUD	FF	+ ve	Not done	BIA with HVI	Ileal perforation	Perforation closure	Pelvic collection

MASTER CHART

31	Jeeva 106234	46, M	RTA	72	Rt Parietal lobe contusion	10.6	AUD	Ff	+ ve	Not done	BIA with HVI	Jejunal perforation	Perforation closure	death
32	Paneer 107564	23, M	BWB	17	-	9.7	AUD	FF	+ ve	Not done	BIA with HVI	Jejunal perforation	Perforation closure	Wound infection
33	Bhuvaneshwari 106712	32, F	RTA	19	-	7.6	N	N	- ve	FF	BIA	Mesenteric tear	Closure of mesenteric tear	Wound dehiscence
34	Gopal 67325	57M	FFH	6	polytrauma	10.8	N	N	- ve	FF	BIA	Mesenteric tear	Closure of mesenteric tear	Complete recovery
35	Thanigaimalai 69647	26M	RTA	27	Rt fibular #	11.2	AUD	N	- ve	Not done	BIA with HVI	Gastric perforation	Perforation closure	Complete recovery
36	Chinnasamy 72343	29, M	FFH	13	Lt calcaneal #	11.6	AUD	N	- ve	Not done	BIA with HVI	Jejunal perforation	R & A	Complete recovery
37	Murugesan 76858	45,M	TTA	3	Head injury	9.5	AUD	N	- ve	Not done	BIA with HVI	Ileal perforation	Perforation closure	death
38	Annamalai 74503	26, M	BWB	66	Pelvic #	10.9	AUD	FF	+ ve	Intraperitoneral rupture of bladder	BIA with HVI	Sigmoid colon perforation with Bladder injury	Colostomy with bladder repair	death
39	Dilli 74364	13M	RTA	20	-	11.6	N	FF	+ ve	FF	BIA	Mesenteric tear	Closure of mesenteric tear	Complete recovery

MASTER CHART

40	Loganathan 97054	37, M	RTA	20	-	9.5	AUD	FF	- ve	Not done	BIA with HVI	Jejunal perforati on	Perforat ion closure	Pelvic collection
41	Vathchala 99067	21,F	FFH	22	-	11.5	AUD	FF	+ ve	Not done	BIA with HVI	Jejunal perforati on	Perforat ion closure	Complete recovery
42	Jesu prabhakar 82059	24M	RTA	32	-	8.6	AUD	N	- ve	Not done	BIA with HVI	Jejunal perforati on	Perforat ion closure	Complete recovery
43	Palani 89268	40 M	FFH	8	polytrauma	9.6	AUD	N	- ve	Not done	BIA with HVI	Ileal perforati on	Perforat ion closure	Respirato ry complicat ions
44	Shankar 94593	35 M	RTA	16	-	10.3	AUD	N	- ve	Not done	BIA with HVI	Mesente ric tear with ileal perforati om	R & A ol ileum	Complete recovery
45	Sathya 17468	20 F	BWB	22	polytrauma	11.8	N	FF	+ ve	FF	BIA	Mesente ric tear	Closure of mesent eric tear	death
46	Karthikeyan 87602	39,M	RTA	50	Rt humeral #	9.4	AUD	FF	- ve	Not done	BIA with HVI	Mesente ric tear with jejunal perforati on	R & A of jejunum	Wound infection

MASTER CHART

47	Jeyaraj 96834	38, M	FFH	9	-	9.9	N	N	- ve	Pneumoperitoneum Bowel wall thickening	BIA	Ileal perforation		Wound dehiscence
48	Damodharan 97250	18, M	TTA	13	Both bone rt leg #	7.6	AUD	FF	+ ve	Not done	BIA with HVI	Ileal perforation	Perforation closure	Complete recovery
49	Devendran 98300	48, M	RTA	28	polytrauma	10.5	AUD	FF	+ ve	Not done	BIA with HVI	Jejunal perforation	Perforation closure	Death
50	Nataraj 99382	27, M	RTA	39	-	10.8	AUD	FF	+ ve	Not done	BIA with HVI	Gastric perforation	Perforation closure	Complete recovery
51	Lakshmi 85356	25 F	FFH	7	polytrauma	10.1	AUD	FF	+ ve	Not done	BIA with HVI	Jejunal perforation		Complete recovery
52	Ponnambalam 88984	18, M	RTA	18	-	10.7	AUD	N	- ve	Not done	BIA with HVI	Ileal perforation	Perforation closure	Wound dehiscence
53	Periyasamy 90534	19, M	RTA	11	-	11.5	AUD	FF	+ ve	Not done	BIA with HVI	Jejunal perforation	Perforation closure	Complete recovery
54	Velu 98765	37, M	RTA	25	Rt shaft of femur #	10.4	AUD	FF	+ ve	Not done	BIA with HVI	Transverse colon perforation	R & A	Death

MASTER CHART

55	Surendran 101792	15,M	RTA	40	polytrauma	9.5	N	FF	+ ve	FF Fat stranding	BIA	Mesenteric tear with jejumal gangrene	R & A of jejunum	Complete recovery
56	Murali 104073	14,M	RTA	62	-	8.8	N	FF	+ ve	FF	BIA	Mesenteric tear	Closure of mesenteric tear	Wound dehiscence
57	Stephen 104125	19, M	RTA	5	Pelvic #	11.8		FF	+ ve	Intraperitoneral rupture of bladder	BIA with HVI	Bladder injury	Bladder repair	Complete recovery
58	Mohan 106703	M, 15	BWB	23	polytrauma	8.9	AUD	N	- ve	Not done	BIA with HVI	Jejunal perforation	Perforation closure	Complete recovery
59	Senthil 114285	17, M	RTA	80	Lt clavicle #	8	N	FF	+ ve	hemoperitoneum	BIA	Mesenteric tearwith ileal gangrene	R & A of ileum	Respiratory complications
60	Amudha 10382	27 F	FFH	13	Pelvic #	9.8	N	FF	+ ve	Intraperitoneral rupture of bladder	BIA with HVI	Bladder injury	Bladder repair	Wound infection

LIST OF ABBREVIATIONS

ARDS - Acute respiratory distress syndrome

CBD - Common bile duct

CHD - Common hepatic duct

CPR - Cardiopulmonary resuscitation

CT - Computed tomography

CUSA - Cavitron ultrasonic surgical aspirator

CVP - Central venous pressure

DPL - Diagnostic peritoneal lavage

ERCP - Endoscopic retrograde cholangiopancreatography

GCS - Glasgow coma scale

ICS - Intercostal space

ICU - Intensive care unit

IVC - Inferior venacava

KUB - Kidney, ureter, bladder x ray film

MRI - Magnetic resonance imaging

PCN - Percutaneous nephrostomy

USG - Ultrasonography

Turnitin

file:///C:/Users/sony/Desktop/Turnitin.htm

Rajkumar SUBRAMANIUM | User Info | Messages | Student | English | What's New | Help | Logout

Class Portfolio | Peer Review | My Grades | Discussion | Calendar

NOW VIEWING: HOME > THE TAMIL NADU DR. M.G.R. MEDICAL UNIVERSITY

Welcome to your new class homepage! From the class homepage you can see all your assignments for your class, view additional assignment information, submit your work, and access feedback for your papers.

Hover on any item in the class homepage for more information.

Class Homepage

This is your class homepage. To submit to an assignment click on the "Submit" button to the right of the assignment name. If the Submit button is grayed out, no submissions can be made to the assignment. If resubmissions are allowed the submit button will read "Resubmit" after you make your first submission to the assignment. To view the paper you have submitted, click the "View" button. Once the assignment's post date has passed, you will also be able to view the feedback left on your paper by clicking the "View" button.

Assignment Inbox: The Tamil Nadu Dr. M.G.R. Medical University

	Info	Dates	Similarity	
Medical	ⓘ	Start 13-Nov-2013 12:50PM Due 31-Dec-2013 11:59PM Post 13-Nov-2013 3:00PM	12%	Resubmit View

11:19
23-12-2013