

**DISSERTATION ON  
CLINICO PATHOLOGICAL STUDY OF  
MULTINODULAR GOITRE**

*Submitted in partial fulfillment of the  
Requirements for the Degree of*

**M.S GENERAL SURGERY  
(BRANCH I)**



**Kilpauk Medical College  
The Tamilnadu Dr. M.G.R Medical  
University Chennai**

**APRIL - 2013**

## **CERTIFICATE**

This is to certify that this dissertation entitled “**CLINICO PATHOLOGICAL STUDY OF MULTINODULAR GOITRE**” is the bonafide record work done by **Dr. A.VIJAYANAND** submitted as partial fulfillment for the requirements of **M.S. Degree Examinations Branch I, General Surgery, April 2013.**

**Prof P.N.ShanmugaSundaram M.S**

Head of the Department,  
Dept Of General Surgery,  
Govt Kilpauk Medical College

**Prof K.Kuberan M.S**

Dissertation guide and Unit Chief  
Dept Of General Surgery,  
Govt Royapettah Hospital.

**PROF . P.RAMAKRISHNAN MD DLO**

**DEAN**

**Kilpauk medical college,Chennai-10**

## **DECLARATION**

I **Dr. A.VIJAYANAND** solemnly declare that the dissertation submitted on the topic “**CLINICO PATHOLOGICAL STUDY OF MULTINODULAR GOITRE**” is a bonafide work done by me from July 2010 to August 2012, towards partial fulfillment of the requirements of M.S Degree examinations, General Surgery, April 2013.

Chennai

**Dr.A.VIJAYANAND**

Date

## **ACKNOWLEDGEMENT**

I sincerely thank **DR. P.RAMAKRISHNAN M.D; D.L.O** , The Dean, Kilpauk Medical College for granting me permission to carry out and successfully complete my dissertation work.

I consider it a privilege to have done this study under the supervision and guidance of **PROF. K. KUBERAN M.S**, who was a constant source of inspiration and guidance.

I am indebted to **PROF. K. RAMASUBRAMANIAN M.S AND PROF. S. UDAYAKUMAR M.S** for helping me through the process of completing my dissertation. Their invaluable advice has helped me complete the study on time.

I would also like to thank Dr. **S. THIRUNAVUKKARASU M.S, DR. S. MANISELVI M.S AND DR. SELVAKUMAR M.S**, for their valuable support and encouragement throughout the period of study.

I would like to thank my fellow postgraduates for their suggestions and ideas and finally I would like to thank our patients for their gratitude and co-operation in this study.

## CONTENTS

<b>SL.NO</b>	<b>TOPIC</b>	<b>PAGE NO.</b>
<b>I</b>	<b>INTRODUCTION</b>	1
<b>II</b>	<b>AIMS AND OBJECTIVES</b>	2
<b>III</b>	<b>REVIEW OF LITERATURE</b>	3
	<b>a.</b> History	3
	<b>b.</b> Development of thyroid gland	8
	<b>c.</b> Surgical anatomy	9
	<b>d.</b> Physiology of thyroid hormones	16
	<b>e.</b> Epidemiology	19
	<b>f.</b> Aetiology of Multinodular goitre	21
	<b>g.</b> Pathogenesis of thyroid nodules	29
	<b>h.</b> Complications of Multinodular goiter	36
	<b>i.</b> Approach to Multinodular goitre	37
	<b>j.</b> Investigations	39
	<b>k.</b> Treatment	63
<b>IV</b>	<b>MATERIALS AND METHODS</b>	79
<b>V</b>	<b>OBSERVATION AND RESULTS</b>	81
<b>VI</b>	<b>DISCUSSION</b>	92
<b>VII</b>	<b>SUMMARY AND CONCLUSION</b>	96
<b>VIII</b>	<b>BIBLIOGRAPHY</b>	
<b>IX</b>	<b>ANNEXURES</b>	

## LIST OF TABLES

<b>SL.NO.</b>	<b>TABLES</b>	<b>PAGE NO.</b>
1.	Age and sex incidence	82
3.	Duration of swelling	83
4.	Progression of thyroid swelling	84
5.	Incidence of pain in thyroid swelling	85
6.	Incidence of pressure symptoms	86
7.	Incidence of toxicity	87
8.	Situation of lower border of thyroid swelling	88
9.	Incidence of tracheal shift	88
10.	FNAC findings of thyroid	89
11.	HPE of thyroidectomy specimen	90
12.	Complications of thyroid surgery	91

## LIST OF FIGURES

<b>SL. NO.</b>	<b>NO. FIGURES</b>	<b>PAGE NO.</b>
1.	Thyroid gland (anterior view)	9
2.	Histological features of different thyroid disorders	48-50
3.	Operative photos of thyroid surgery	76-78

Turnitin Document Viewer - Mozilla Firefox  
 https://www.turnitin.com/dv?o=291116339&u=1014644562&cs=&student\_user=1&lang=en\_us

TNMGRMU APRIL 2013 EXAMINAT... Medical - DUE 31-Dec-2012 What's New

Originality GradeMark PeerMark

clinicopathological study of multinodular goitre  
 BY VIJAYANAND 22101118 M.S., GENERAL SURGERY

turnitin 11% SIMILAR -- OUT OF 0

### INTRODUCTION

The thyroid gland is an endocrine gland situated in the lower part of front and the sides of the neck. Its main function is regulation of the basal metabolic rate, stimulates somatic and psychic growth and plays important role in calcium metabolism. The term thyroid is derived from Greek, which means shield (Thyros –shield, eidos – form). Normal thyroid gland is impalpable. Thyroid gland enlargement is the most common manifestation of the thyroid disease. The enlargement may be either generalized or localized, which again may be, toxic or nontoxic. The nontoxic goitre is further divided on etiological basis as endemic goitre and sporadic goitre. The endemic goitre is defined as one where more than 10% of population shows thyroid enlargement. Diseases of thyroid gland especially multinodular goitre due to deficiency of iodine

#### Match Overview

1	surgery.4t.com Internet source	2%
2	Taylor, S.. "THE" Publication	1%
3	Submitted to Mahidol U... Student paper	1%
4	R. A. Conard. "Thyroid..." Publication	1%
5	Y. Nakai. "Vestibular ..." Publication	1%
6	"ENDEMIC GOITRE IN" Publication	<1%
7	"Retrosternal goitre", ... Publication	<1%
8	Yoon Y. Tee. "Fine-Nee..." Publication	<1%

PAGE: 7 OF 114

Text-Only Report



## INTRODUCTION

The thyroid gland is an endocrine gland situated in the lower part of front and the sides of the neck. Its main function is regulation of the basal metabolic rate, stimulates somatic and psychic growth and plays important role in calcium metabolism. The term thyroid is derived from Greek, which means shield (Thyros –shield, eidos – form). Normal thyroid gland is impalpable. Thyroid gland enlargement is the most common manifestation of the thyroid disease. The enlargement may be either generalized or localized, which again may be, toxic or nontoxic. The nontoxic goitre is further divided on etiological basis as endemic goitre and sporadic goitre. The endemic goitre is defined as one where more than 10% of population shows thyroid enlargement.<sup>1</sup> Diseases of thyroid gland especially multinodular goitre due to deficiency of iodine are prevalent in India. Though exact incidence of nodular goitre is not available, WHO, in 1958, estimated that goitre was present in 200 million, which represented 7% of World's population at that time. Nodular goitres are more common in women than in men and the nodularity increases with increasing age. Multinodular goitres (MNG) can become malignant but it is rare.

## **AIMS AND OBJECTIVES**

- TO STUDY AGE AND SEX DISTRIBUTION
  
- TO KNOW VARIOUS MODES OF CLINICAL PRESENTATION
  
- TO COMPARE AND CORRELATE THE FINDINGS OF INVESTIGATIONS WITH THE HISTOPATHOLOGY OF RESECTED SPECIMEN
  
- TO KNOW THE INCIDENCE OF MALIGNANCY IN MULTINODULAR GOITRE
  
- TO STUDY THE PRINCIPLES AND MANAGEMENT OF MULTINODULAR GOITRE

## **REVIEW OF LITERATURE**

### **HISTORY<sub>2,3</sub>**

The thyroid gland was previously referred to as a laryngeal gland and was subsequently named thyroid by Wharton in 1645, because of thyroid cartilage with which it is closely associated. Existence of thyroid gland was known to Galen (2 A.D), who thought that it provided fluid for lubrication of larynx. Sir Astley Cooper (1768-1841) said it has the function of secretion. Thyroxine (T<sub>4</sub>) was isolated by Kendall in 1965 and it was synthesized by the Harrington and Banger in 1927. In 1953 the important discovery of 3, 5, 3 Tri-iodothyronine was made by Cross and Pitt-rivers and by Roche, Liesitsky and Michel simultaneously. This was proved to be more effective than thyroxine itself. With the introduction of radioactive iodine in 1934, it was possible for the clear understanding of thyroid physiology. In 1886 Bouman discovered Iodine in considerable amount in thyroid gland. Iodine was first identified by French Chemist Courtois in 1812 who found it in ash of burnt seaweed. But Chatin during 1850-1876 was the first to conclude iodine deficiency as a principle cause of goitre. Experimental goitre was produced by Chesney (1888) by John Hopkins University in Rabbits, by feeding them with cabbage and established, cabbage as one of the goitrogenic agents. Potassium

thiocyanate was found to produce goitre, in some of the hypertensive patients. Paracelsus (1492-1541) showed relationship between endemic goitre and cretinism. In 1850 Curling, a Surgeon at London hospital gave account of cretinism in two children and recorded complete absence of thyroid gland at postmortem in both the cases. Gull in 1874 described cretinoid change in adults. In 1878 Ord suggested the term Myxoedema to describe the condition occurring after total or partial thyroidectomy.

### **EARLY OPERATIONS:**

The first credible account of thyroid surgery was given in 1170, by Roger Frugardi of Salerno, in the Bamberg manuscripts. Goitres which failed to respond were removed by finger dissection, insertion of setons, ligation en masse, and application of caustic powder. All such procedures were liable to major complications and increased mortality. The first well-documented partial thyroidectomy was undertaken in Paris in 1791 by Pierre Joseph Desault (1744-1795), during the terror of French Revolution. Guillaume Dupuytren (1777-1835) also in Paris, undertook total thyroidectomy in 1808 for a Goitre weighing 1.2 kgs, but the patient died. In 1821, Johann Hedenus (1760-1836) of Dresden, successfully removed six “suffocating goitre”, by dissection and ligation of all the arteries. This achievement was not equalled for next forty years. The

results of most thyroid operations were disastrous until the second half of 19th century. Bleeding, which could not be controlled, and sepsis, cause of which was not known, often proved fatal.

By the 19th century the usual indications for surgery were suffocation and dysphagia. The overall mortality was over 40% and many surgeons advised against operating on goitres and considered it as one of the most thankless, most perilous undertakings. The advances, which followed the advent of general anaesthesia (1840's), antisepsis (1860's) and haemostasis (1870's), enabled surgeons to undertake more thyroid operations, and devise new ones, with greatly reduced mortality. Between 1850 and 1977, the world wide operative mortality fell to around 20%.

The leading thyroid surgeons at this time were Theodor Kocher (1841-1917) and Theodor Billroth (1829-1894). Both of them performed thousands of thyroidectomies, with progressively better results. By 1883, operative mortality had fallen to 12% and by the end of the century to 3%. Theodor Kocher was Professor of Surgery in Berne, Switzerland. Kocher operated on more than 500 patients. He advocated gentle meticulous surgery that spared yet to be discovered parathyroid glands and anatomical appreciation of recurrent laryngeal nerve. With application of these principles mortality of thyroid surgery decreased

from more than 59% to approximately 0.2%. Even more important was the discovery by Kocher that total thyroidectomy was followed by development of myxoedema and he demonstrated that this complication could be prevented by subtotal thyroidectomy. For this work in medical understanding and care in diseases of thyroid gland Kocher was awarded Nobel Prize in 1909. THEODER KOCHER IS REGARDED AS FATHER OF THYROID SURGERY. Because operations were now safe, many goitres were removed mainly for cosmetic reasons. Usually general anaesthesia with ether or chloroform was used; but local anaesthesia with cocaine was sometimes used. The Collar incision introduced by Tules Boeckel (1848-1927) of Strasbourg was adopted widely. Europe was the Cradle of thyroid Surgery in 19th century. In 1890's American Surgeons visited the main European centres and began to make important contributions in the early twentieth century. Notable among these were Halsted, Charles Mayo (1865-1939) and George Crile (1864-1943). The indications of operation were extended to include the prevention of complications, especially in patients with thyrotoxicosis and thyroid cancer. The latter was sometimes an unexpected discovery after operation. For this reason total lobectomy with removal of the isthmus and pyramidal lobe came to be used. This reduced the need for further operations when malignancy was found. The first transplantation of

thyroid was recorded by Payr in 1906. He transplanted a portion of the thyroid gland from a woman into the spleen of her myxoedemic daughter.

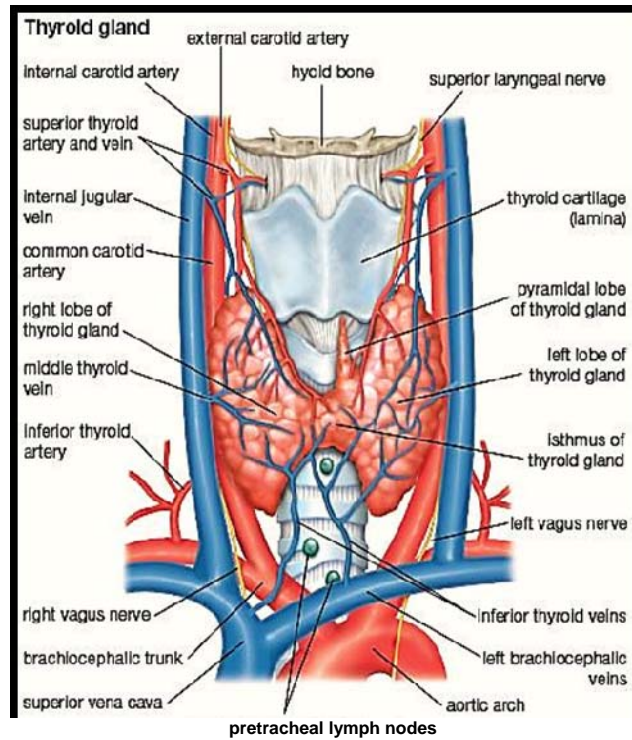
Following the development of non-surgical measures to manage most cases of hyperthyroidism and colloid goitre due to availability of radioactive iodine, antithyroid drugs and iodination of salt, surgical attention was directed to nodules, both benign and malignant but with emphasis on the latter. In the 1940's and 1950's, attempts were initiated to determine the frequency of carcinoma producing thyroid nodules and criteria for operation for thyroid nodules. Thyroid scans using  $I^{131}$  became available and assumed a frequently used role in identifying hypo functional nodules. However it soon became evident that this procedure was of little help in separating the malignant from the numerous benign thyroid nodules. With the development of techniques such as FNAC and ultrasound, the performance of thyroidectomy has become selective, unlike in the past when surgery was recommended for nearly all multinodular goitres.

## **DEVELOPMENT OF THYROID GLAND <sub>1</sub>**

Thyroid gland is developed from median endodermal thyroid diverticulum, which grows down in front of the neck from the floor of “primitive pharynx”, just caudal to tuberculum impar. The lower end of the diverticulum enlarges to form the gland. The rest of the narrow part of the diverticulum is known as thyroglossal duct, most of which disappears. The site of origin of diverticulum is seen as a depression called foramen caecum<sup>4</sup> and the lower end often persists as pyramidal lobe. Thyroid is the earliest glandular structure to appear. It becomes functional during the third month of development of fetus.



## SURGICAL ANATOMY OF THYROID GLAND<sup>5,6,7,8,9</sup>



The thyroid gland is composed of two lobes connected by an isthmus and appears butterfly shape. The lobular extension is from the middle of thyroid cartilage to the sixth ring of trachea. The gland lies against 5th, 6th, 7th cervical and 1st thoracic vertebrae and the isthmus covers 2nd, 3rd and 4th tracheal rings. Rarely, aberrant and ectopic thyroids are found in stomach and ovaries.

## **WEIGHT AND DIMENSIONS**

Thyroid gland averagely weighs 20-25 Gms. It is larger in females than in males and increases further during pregnancy and menstruation.

Each lobe measures 2x1x1 inches and isthmus 1x1 inch.

## **THYROID CAPSULES**

Two capsules surround the gland namely true and false capsule. Peripheral condensation of connective tissues of the gland is the true capsule and false capsule is derived from pretracheal layer of deep cervical fascia. These two capsules are pierced by blood vessels of the thyroid and ramify to form dense plexus immediately beneath, the true capsule. Arterial and venous trunks traverse the space between the two capsules. So during surgery of the gland, these main vessels are secured between the two capsules, taking care not to damage true capsule. So the thyroid gland is removed with its true capsule.

## **ANATOMICAL RELATIONS OF THYROID GLAND<sub>5</sub>**

Each thyroid is conical in shape with an apex, base, two borders – anterior and posterior, three surfaces – superficial, medial and posterolateral. Apex is directed laterally and upwards and is limited by the attachment of sternothyroid on thyroid cartilage. Base is at the level

of 5th or 6th tracheal rings; anterior border is thin and is related to branches of superior thyroid artery. Posterior border is thick and rounded 9 and is related to the inferior thyroid artery, parathyroid gland and thoracic duct on the left side. Superficial surface is covered by sternothyroid, sternohyoid and superior belly of omohyoid and anterior border of sternomastoid overlapping it inferiorly. The surface is convex. Two tubes, trachea and oesophagus, two muscles, inferior constrictor and cricothyroid and two nerves, External laryngeal and recurrent laryngeal nerves are related to the medial surface of thyroid gland. Posterior surface is related to carotid sheath and overlaps the common carotid artery. The isthmus has two surfaces and two borders. Occasionally it may be absent. Anterior surface of isthmus is covered by sternothyroid, sternohyoid muscles and anterior jugular vein. The upper border is related to the anastomotic branches of the two superior thyroid arteries. At the lower border inferior thyroid vein leaves the gland. A small portion of the gland substance often projects upwards from the isthmus, generally to the left of the midline, as the pyramidal lobe. Separate masses of thyroid tissue called accessory thyroid gland are often found near the hyoid bone, in the tongue, in the superior mediastinum, or anywhere along the path of descent of the thyroglossal duct.

## **BLOOD SUPPLY OF THE THYROID GLAND**

It is supplied by two arteries which carry sympathetic fibres with them and is drained by three veins.

### **ARTERIAL SUPPLY**

The thyroid gland is supplied by superior thyroid, inferior thyroid and sometimes with an arteria thyroidea ima.<sup>6</sup> The superior thyroid artery, first branch of external carotid artery descends downwards and forwards in intimate relation with external laryngeal nerve. It enters the gland superficially. After piercing the pretracheal fascia, it divides into anterior and posterior branches. The anterior branch runs along the upper border of isthmus to anastomose with the fellow of the opposite side. The posterior branch descends along the posterior border to anastomose with ascending branch of inferior thyroid artery. The superior thyroid supplies upper 1/3 rd of lobe and upper 1/2 of isthmus. The inferior thyroid artery is a branch of thyrocervical trunk, which in turn is a branch of subclavian artery. It is related to the posterior surface of gland. During the course it passes behind the carotid sheath and middle cervical ganglion but in front of the vertebral vessels. Its terminal part is intimately related to recurrent laryngeal nerve. It divides into 4 to 5 branches and one ascending branch anastomoses with posterior descending branch of superior thyroid artery.

The inferior thyroid artery supplies the lower 2/3rd of the lobe and lower ½ of isthmus with parathyroid glands. This makes a major share in thyroid blood supply. The thyroidea ima artery enters the lower part of the isthmus and arises from the arch of aorta, or brachiocephalic trunk, or right common carotid artery and supplies the isthmus.

### **VENOUS DRAINAGE**

From a venous plexus on the surface of the gland the superior thyroid vein follows superior thyroid artery and runs along the outer border of omohyoid to terminate in internal jugular vein. The middle thyroid vein is a short channel, which leaves the gland at its middle, crosses the common carotid artery to enter into internal jugular vein. It bleeds torrentially if torn during surgery due to its shortness. The inferior thyroid vein leaves the isthmus at its lower border, runs down in front of trachea to end in the innominate vein of same side. Sometimes both inferior thyroid veins may join the left innominate vein.

### **LYMPHATIC DRAINAGE**

Thyroid is richly drained by lymphatics. It has extensive intraglandular and intralobar lymphatics that encircle the thyroid follicle. The capsular lymphatics may cross –communicate with isthmus and that

of the opposite lobe. The gland is drained by two sets of medial and lateral channels. The medial ascending channels leave the upper border of isthmus and drain to the gland on the cricothyroid membrane that is, the prelaryngeal lymph nodes. The ascending lateral vessels leave the upper pole of the gland and run with superior thyroid artery to the deep cervical nodes. Descending lateral vessels pass from deep surface of the gland to small nodes placed on recurrent laryngeal nerve, called nodes of recurrent chain.

### **NERVE SUPPLY**

Sympathetic nerves are mainly derived from middle cervical ganglion and partly from superior and inferior cervical ganglion which accompany the thyroid arteries.

### **MICROSCOPIC ANATOMY**

The thyroid consists essentially a mass of more or less rounded follicles containing varying amounts of colloid. These follicles are lined by a single layer of cuboidal epithelium, which form the walls of the follicles. These follicles are arranged in subunits of 20-40 lobules each being supplied by an individual arteriole. These cells secrete Thyroxine ( $T_4$ ) and tri-iodothyronine ( $T_3$ ). The parafollicular or 'C cells lie in between the follicles, which secrete calcitonin, which in turn promotes deposition of calcium salts in the skeleton. <sup>12</sup>

## **NERVES RELATED TO THE THYROID GLAND**

Two nerves, the external branch of superior laryngeal nerve and recurrent laryngeal nerve are in intimate relation with thyroid gland. So protection of these nerves is very important in thyroid surgery. The external laryngeal nerve, which supplies inferior constrictor and cricothyroid muscle, is in real danger while ligating the superior thyroid artery. The nerve descends just deep to the artery. The best way to avoid injury to the nerve is to ligate the upper pole of the gland with the vessel as close to the gland as possible. The recurrent laryngeal nerve is related to the posterior surface of the gland in intimate relation with inferior thyroid arteries. The nerve can be identified in a triangle formed by common carotid artery laterally, trachea medially, and thyroid lobe superiorly, which lies in between trachea and larynx.

## **VARIATIONS IN POSITION OF RECURRENT LARYNGEAL NERVE<sub>5</sub>**

1. The nerve penetrates and traverses through the gland which is a dangerous position.
2. The nerve courses through the area of greatest adherence of the gland to larynx i.e ligament of Berry – Not in the gland but very near to it.

3. Nerve situated safely in tracheo-oesophageal groove.
4. The nerve passes posterior to the joint between inferior cornu of thyroid cartilage and the cricoid cartilage.
5. Right nerve may not be recurrent in some cases, arising directly from vagus above the level of cricoid cartilage. These are associated with anomalous origin of right subclavian artery.

### **PHYSIOLOGY OF THYROID HORMONES <sup>10,11</sup>**

The primary function of thyroid gland is the production of sufficient thyroid hormones for proper regulation of cellular metabolism throughout the body.

### **IODINE METABOLISM**

Iodine is taken in the form of Iodides sea fish; egg and milk are good dietary source of iodide. Dietary iodide is absorbed from upper gastrointestinal tract and carried as inorganic iodide in plasma. Normally thyroid, salivary glands and kidney compete for iodide but thyroid and kidney are the principal organs that compete for iodide. The adult man requires 0.14 mg of iodide per day and an adult female requires 0.10 mg. Growing children, pregnant and lactating women require more. The daily



requirement is met by balanced diet and drinking water, exception being hilly areas where food and water may be deficient in iodine.

## **SYNTHESIS AND SECRETION OF THYROID HORMONES<sub>12</sub>**

The synthesis of thyroid hormones is divided into four steps:

### a) Iodine trapping

The thyroid traps the plasma iodine in the inorganic form. It is essentially an active process and stimulated by TSH. It is competitively inhibited by Thiocyanates and perchlorates.

### b). Iodine binding

The inorganic iodide is oxidized to inorganic iodine at the thyroid follicular cells with the help of an enzyme peroxidase. Iodine combines with amino acid tyrosine in the globulin molecule within the follicular cells to form monoiodotyrosine and diiodotyrosine (MIT and DIT). This process is inhibited by Thiouracil group of antithyroid drugs and by PAS and chloroquine.

### c). Coupling

Thyroxine ( $T_4$ ) is formed by coupling of two molecules of DIT and Triiodothyronine ( $T_3$ ) by coupling of one molecule of each MIT and DIT.

The coupling reaction occurs at the Thyroglobulin molecule. They are oxidative reactions and need peroxidase enzyme.

d). Hormonal release

Thyroglobulin is first taken up by thyroid follicular cells. Under the influence of TSH a protease acts on thyroglobulin to release  $T_4$ ,  $T_3$ , MIT and DIT. MIT and DIT are de-iodinated within the cell and iodine is reutilized for iodinating globulin. From the follicular cells  $T_4$  and  $T_3$  directly enters the circulation. On entering the circulation the thyroid hormones are largely bound to specific protein called thyroxine-binding globulin (TBG), thyroxine binding albumin and thyroxine binding prealbumin (TBPA). This protein has got more affinity to Thyroxine than to the tri-iodothyronine. The protein bound iodine (PBI), which is about 4-8  $\mu\text{g}$  per 100 ml mainly, reflects plasma  $T_4$  level. A small amount of hormone remains free in the serum in equilibrium with the protein bound hormone and is biologically active. The free hormone is physiologically active and protein bound fraction acts as a reserve. Thyroid hormones are disposed by de-iodination 80% and 20% excreted in the stools. About 40% of circulating  $T_4$  is converted to  $T_3$  peripherally called "Reverse  $T_3$ ". This is inhibited by propranolol and glucocorticoids.

## **DIFFERENCES BETWEEN T<sub>3</sub> AND T<sub>4</sub>**

T<sub>3</sub> has quicker onset of action and is effective in very small doses. The onset of action of T<sub>3</sub> is within 6-8 hours and that of T<sub>4</sub> is 4-14 days. After cessation of therapy the hormonal effect lasts for several days with T<sub>4</sub> but vanishes quickly with T<sub>3</sub>. T<sub>3</sub> is the more important physiological hormone and is also produced in the periphery by conversion from T<sub>4</sub>. Reverse T<sub>3</sub> is an inactive form of T<sub>3</sub>. Mechanism of action of thyroid hormones – (Sterling)<sup>13</sup>. In normal levels, the thyroid hormones act at chromatin of molecules and stimulate synthesis of mRNA molecules. These later synthesize protein molecules including enzymes at cytoplasm, which has anabolic, growth promoting, and calorogenic actions. But in unphysiological higher concentrations they act at mitochondria and uncouple oxidative phosphorylation. Thus oxygen consumption and heat production is increased.

## **EPIDEMIOLOGY<sub>3</sub>**

The distribution of nodular goitre is worldwide. It has been estimated that atleast 200 million people have goitre in the world (Selvyn Tailor 1968). It occurs in all races in all climates and at all inhabitable altitudes. It occurs both endemically and sporadically and most of the endemic areas are mountainous. In India, it is said that about 9 million

people suffer from goitre. There is a goitre belt along the northern border of India extending from Kashmir and Jammu-eastwards along the southern valleys and foothills of Himalayas into Assam. The reputation for goitre is more formidable in this region than in any other regions in the world. Gilgit and Ladock area of Kashmir, the districts of Thehri, Kasauly, Ambala and Dehradun of Himachal Pradesh and low lying planes of UP (Districts of Barailly, Gunmdal, Baster and Gorakpur), the districts of Muzafarpur of Bihar and most of the areas of Assam and Nagahill area come under the above mentioned goitre belt, including the state of Rajasthan, along the banks of Narmada river and in M.P and Orissa (Ranchi and Surgia districts). The endemic goitre is prevalent in Southern India. There is an endemic area at Coimbatore and Nilgiri hills and some parts of Arcot in Chennai state. Hilly areas of Coorg are considered to be endemic in Karnataka. Conclusion of goitre subcommittee of the Medical Research Council of Great Britain on the mechanism of simple goiters is failure of the thyroid gland, to obtain a supply of iodine, sufficient to maintain its normal structure and function. The failure is usually brought about by an absolute environmental deficiency of iodine. It may be caused by factors, which interfere with availability of dietary iodine, in turn imposing an abnormal demand on the thyroid gland.

## **AETIOLOGY OF MULTINODULAR GOITRE**

Marrine, a trained pathologist did brilliant studies on goitre. One of the most classical experiments in public health shows iodine as a prophylactic supplement. The recent introduction of tracer methods, urinary radioactive iodine and of technique of chromatography has provided fresh opportunities for an understanding of the aetiology and pathogenesis of nodular goitre. Marrine demonstrated an inverse relationship between iodine contents of the given gland and the degree of epithelial hyperplasia. Vanfallenberg and Mac lendon demonstrated an inverse relationship between the level of iodine in food and drinking water on one hand and the incidence of goitres on the other. The next phase of work on the iodine deficiency hypothesis relates to experimental production of thyroid lesion in animals. Identical with that of endemic goitre under conditions in which deficiency of iodine is the only etiological factor. Several diets consisting of natural food stuffs deficient in iodine have been shown to lead to hyperplasia of thyroid acini. The most recent phase in the study is with the use of radioactive iodine. The pioneering study of Stanburg in Argentina and followed by similar studies in India, Holland, Finland in Congo have yielded results, which are consistent with iodine deficiency hypothesis.

## **GOITROGENS**

There is evidence that, two classes of goitrogenic compounds, Thiocyanates and Thiouracil like substances exist in food habitually consumed by man and domestic animals. Thiocyanates inhibit the concentration of iodine and synthesis of thyroid hormones. Clement was of the opinion that plant goitrogens are unlikely to be significant etiological factors.

## **FACTORS OTHER THAN IODINE DEFICIENCY**

There are two outstanding well-documented epidemics on which the observed features do not fit in with the iodine deficiency hypothesis. Clement has shown that school children in Southern Tasmania develop seasonal goitre even though they have preceding large iodine supplement.

This seasonal increase appears to coincide with the spring flush of postures and weeds. Strong evidence was presented to suggest that a goitrogen in milk from cow fed on such postures was the cause of thyroid enlargement. Boys and girls are equally affected unlike in epidemics where girls predominate. Italy's Coster showed another exception to iodine deficiency hypothesis when he observed in several epidemics that iodine may be normal or elevated, PBI level within the normal range and

water and urinary iodine values, no different from non-endemic region. There is yet no explanation for this, but Coster stated that some strong ties were observed between endemic and epidemic goitres in this region.

### **Thyroid nodule in children following therapy with I<sup>131</sup>**

The development of thyroid nodule several years after treatment with I<sup>131</sup> for hyperthyroidism has been described in 256 patients treated between 1943-53 in California Hospital. Thyroid nodules were discovered in 8 patients from 5 to 30 years, 6 patients were less than 18 years at the time of radio iodine administration and 2 were 25 and 30 years. Thus younger the patients, greater the chance of thyroid nodules developing from radioiodine therapy for thyrotoxicosis. At the time of development of nodules none had hypothyroidism, none received thyroxine. Nodules are originated in the focal hyperplastic and regenerated portions of lobules apparently due to prolonged TSH stimulation on the tissues still able to react. Pathogenic changes in the thyroid gland were found in number of marshalled people of Rongelap Island who were accidentally exposed to radioactive fallouts in 1954. Definite thyroid nodules were noted in all people, minor changes in 5 others and hyperthyroidism in 2. All but one case occurred in most heavily exposed population who received 175 rads of whole body

radioactive burns of the skin of the fallout products and internal absorption fission products. In 200 individuals of control group, not exposed, no such abnormalities were found. In 55 children less than 10 years of age, thyroid nodules developed. Radiation etiology of these cases appears to be certain, in view of the following facts.

Thyroid gland received a substantial dose of radiation from radioiodine and external gamma radiation. The incidence of nodule was high in exposed group and absent in unexposed group and the control population living in the same island. Increased sensitivity of children's thyroid gland in the development of nodules from radiation exposure has been amply demonstrated.

### **FAMILIAL GOITRES**

1. Defect in iodine transport
2. Defect in organification failure to form organic iodine
3. Deficiency of enzymes
  - Lack of iodine peroxidase – complete block
  - Lack of iodine transferase – incomplete block, relatively common



More than 150 cases reported with consistent association of goitre with deaf mutism. Pendred's syndrome is generally limited to single generation.

4. Coupling defect – Failure to couple iodotyrosines uncommon – 6 cases reported, more common in females.
5. Iodotyrosine deiodinase defect - uncommon.
6. Abnormal serum iodinated polypeptides – rare.

### **Childhood Goitre**

The presence of nodule or nodules in the thyroid gland in a child raises the strong possibility of malignancy, more likely to be malignant in a child than in an adult. Likelihood of malignancy increases when the nodule is single, hard and does not concentrate radioiodine (cold nodule). It has been examined at Mayo clinic from 1908 to 1955, that, of 130 children with nodular enlargement, 68 had adenoma, 46 had carcinoma, 8 had lymphocytic thyroiditis, 5 had goitrous cretinism, and 3 had congenital goitre. Thus carcinoma accounted for 35.4% of patients with nodular goitre. The nature of the diseases that produce the nodular enlargement in a child cannot be determined in most instances, except by histology. Thyroid hormones are required for female reproductive

functions. Physiological variations in hormones during menstruation, pregnancy and lactation contribute to the development of goitre, more common in females than males.

## **CLASSIFICATION OF THYROID NODULES**

There is no universally accepted classification, as the aetiology of the nodular goitre is presumptuous and pathological appearances are often difficult to correlate with clinical features (Alan Newton, 1950).

Any classification must be workable and usable to clinician and pathologist and simple to avoid confusion, so admissible to change and revisions made by the newer concepts. (Warren and Meissner 1953).

## **WHO CLASSIFICATION**

### **Stage Clinical findings**

0-A No goitre

0-B Goitre detectable only by palpation and not visible even when the neck is fully extended

1 Goitre palpable, but visible only when the neck is fully extended

2 Goitre visible with the neck in normal position

3 Very large goitre which can be recognized at a considerable distance

## **CLASSIFICATION OF TYPES OF GOITRE IN INFANCY AND CHILDHOOD**

I Thyroid enlargement resulting from compensating action of impaired hormonopoiesis.

1. Familial iodine induced goitre secondary to metabolic inborn errors.

- Iodine transport defect

- Organification defect

- Lack of iodine peroxidase

- Lack of iodine transferase (Pendred's syndrome associated with congenital nerve deafness).

- Coupling defect

- Iodothyrosine deiodinase defect.

- Abnormal iodinated polypeptides

- Resulting from defects in intrathyroidal proteolysis of thyroglobulin.

Abnormal plasma binding, preventing use of thyroxine by peripheral cells.

2. Endemic goitre resulting from iodine deficiency.

3. Goitre due to drugs or naturally occurring goitrogens

• Inhibitors of hormone synthesis<sup>27</sup>

Thiourea  Thiouracil  Propyl thiouracil  Methimazole

Sulphonamides  Para aminosalicylates  Phenyl butazone  
Methylxanthine

• Inhibitors of iodine accumulation

Perchlorates  Thiocyanates  Nitrates

• Natural goitrogens

Cabbages  Turnips  Soyabeans

• Miscellaneous

Cobalt  Resorcinal  Dihydroquinine

II. Thyrotoxic goitre

- Neonatal
- Childhood

### III. Goitre in Thyroiditis

Acute, Subacute (Dequervains), Chronic thyroiditis ,Riedel's thyroiditis

### IV. Nodular goitre

- Cysts
- Benign and malignant neoplasms

## **PATHOGENESIS OF THYROID NODULES**

Thyroid nodules whether toxic, simple or malignant seem to arise as a result of thyroid follicles losing their dependence of thyroid stimulating hormone, a breakdown suggested that the nodules in the nontoxic goitre are initially little foci of hyperthyroidism. He traced the origin of thyroid nodules back to the stage of simple hyperplasia. It is at this stage that the goitre is preventable.

## **AUTO RADIOGRAPHIC STUDIES**

This method of study consists of a slice of the thyroid gland exposed to a photographic film, which becomes black when the tissue

contains radioactive material. Thus it makes possible for comparison of any area of thyroid with its capacity to concentrate and bind iodine to protein, in other words to synthesize thyroid hormones. By this study the evolution of the nodular goitre is divided into five stages (**Selwyn Taylor Hypothesis**).

**Stage I:** The diffuse enlargement of thyroid gland, which shows increased vascularity, a large uptake of radioiodine and with uniform blackening of auto radiograph. This is typical of puberty goitre but many persist for years.

**Stage 2:** Discrete focal areas of hyperplasia with corresponding blackening of autoradiograph. There are very few patients in whom all the functioning thyroid tissue is concentrated in a single area. Rawson described this very aptly as a toxic nodule in a nontoxic gland. Patient presents with erythroid state in this stage.

**Stage 3:** Lobules become increasingly hyperplastic and vascular.

This stage is typified by disruption and haemorrhage. The blood supply in the nodules is carried by this walled tortuous dilated vessels, which bleed easily producing haemorrhagic necrosis by compression of surrounding tissue, fibrous pseudo capsule is formed around part of the

nodule with obliteration of small vessel and formation of Arteriovenous shunt. These perinodular shunts also adversely affect blood supply of nodule. Therefore, bleeding and necrosis in the nodule is common.

**Stage 4:** Nodules undergo resolution in one or two ways, either a large, lace of colloid fills it and this is found to be free of iodine or mass of new follicles grow to supercede it and again their colloid does not take up radioiodine.

**Stage 5:** The Multinodular goitre is brought about by continued repetition of the process described above, with the result that most of nodules are inactive and incapable to metabolize iodine but among them are few active foci, which are currently supplying normal body requirement. In the hypothesis of Selwyn Taylor, the functioning nodule was a stage in the evolution of all nodular goitre is questioned by Scintiscan studies to determine the function of solitary or dominant thyroid nodule. It has been demonstrated in autonomous micro or macro nodules in the same thyroid gland suggesting that small nodules function in this manner from their origin. Auto radiographic studies with gross autonomous functioning nodule have demonstrated similar functioning micronodules.

Transition from functioning to non-functioning nodule may occur through degenerative change or possibly by simple loss of functional

capacity of follicles. Autonomous micronodules from the very early stage suggest partial loss of trophic control. The finding of functioning micronodule in the same gland with similar macro nodules strongly suggests that large nodules were functioning through the period of growth. High levels of monoiodotyrosine and diiodotyrosine are found in cold nodules and low in hot nodules.

### **HISTOPATHOLOGY OF MULTINODULAR GOITRE** <sup>14, 15</sup>

The initial stage of nodular goitre is a simple goitre. With the passage of time due to repeated involution and hyperplasia, multiple nodules appear gradually. These nodules increase with advancing years. The thyroid acini are divided into three types depending upon the stage.

**Resting stage:** The acini are large, lined by flattened cells and filled with dense homogenous colloid.

**Secretory Stage:** Acini are lined by cuboidal epithelium and their colloid does not stain intensely.

**Response Phase:** Acini are lined by columnar cells and contain highly stained vacuolated colloid. As the simple goitre changes to nodular goitre the histological appearance vary according to the stage.



## **I. Stage of hyperplasia**

It is due to increased TSH, which is secreted in response to low levels of circulating thyroid hormones.

### **HISTOLOGY**

Here the acini are hyperplastic and distorted by ingrowths and invagination of epithelium. The acini are lined by tall columnar cells. The colloid is less in amount. This phase will slowly change into colloid goitre.

## **II. Colloid Phase**

It cannot be differentiated from hyperplastic gland clinically.

### **Histology**

Here the gland is a mixture of hyperplasia with colloid acini. The acini are lined by cuboidal cells. The concentration of iodine is less than normal gland. When the supply of iodine increases, the gland undergoes involution. Both hyperplastic and colloid goitre are associated with euthyroidism.

### **III. Nodular Phase**

It is an irreversible stage of a simple goitre and is due to repeated stimulation of the gland. The process of hypertrophy, hyperplasia and involution follow repeatedly. Faulty areas of involution associated with colloid distension will compress the normal glandular tissue. This with newly formed fibrous tissue causes the nodule to become encapsulated. Macroscopically the nodules may be single or multiple. The nodules may be pale yellow pink and opaque in appearance. Dissolution of follicle lead to cyst formation and cyst may contain cholesterol crystals and colloid material.

#### **Histology**

Microscopically nodular goitre appears as colloid goitre. It consists of poorly defined fibrous capsule containing colloid filled acini, which are lined by low cuboidal epithelial cells.

#### **Retrosternal goitre**

Most retrosternal goitres arise from lower pole of a nodular goitre. Very few retrosternal goitre arise from ectopic thyroid tissue. If the neck is short and pretracheal muscles are strong in men, negative intrathoracic pressure tends to draw these nodules into superior mediastinum. A

retrosternal goitre is often symptomless and is discovered on a routine chest radiograph. It receives its blood supply from inferior thyroid vessels. Retrosternal goitre may be

1. **Substernal** – commonest type, lower border of thyroid is behind the sternum.
2. **Intrathoracic** – No thyroid is seen in the neck. Diagnosis is by radioiodine scan.
3. **Plunging type** – when intrathoracic pressure raises as when the patient coughs, lower border is seen in the neck.

A retrosternal goitre however can cause severe symptoms.

- Dyspnoea – particularly at night with cough and stridor, due to pressure on trachea.
- Dysphagia – due to pressure on oesophagus.
- Pressure on great veins at thoracic inlet gives rise to enlargement of veins on neck and front of chest.
- In severe cases there may be obstruction of superior venacava.

A retrosternal goitre may be toxic or malignant. A chest radiograph in case of retrosternal goitre shows widened soft tissue shadow in superior mediastinum sometimes with calcification and often causing deviation and compression of trachea.

## **COMPLICATIONS OF MNG**

The complications of MNG are as follows:

### **1. Secondary thyrotoxicosis**

Its incidence is difficult to estimate but figures as high as 30% are reported.<sup>16</sup> In most cases of toxic nodular goitre the nodules are inactive and the internodular tissue is over active which is due to a family of IGG immunoglobulins which bind with TSH receptor sites (TRABS) and activates TSH receptors on follicular cell membrane. They have a more protracted action than TSH (16-24 hours versus 1.5 to 3 hours). However in few cases one or more nodules are overactive.

### **2. Tracheal compression**

It may be due to gross displacement of trachea in lateral or anteroposterior plane. It is commonly due to haemorrhage into a nodule and in retrosternal goitre.

### **3. Malignant change**

It is one of the most controversial subjects which is still not settled. It is an uncommon complication. The incidence of carcinoma in MNG has been reported as 5-10%.<sup>3</sup> In this view Sokal has reported that 4% to 17% of nodular goitre develop thyroid cancer<sup>18, 19</sup>. The malignancy is usually of follicular type.

### **APPROACH TO MULTINODULAR GOITRE<sup>20, 21</sup>**

The thyroid nodule may be palpable or hidden and symptomatic or asymptomatic. The thyroid nodules of less than 1-2 cms are not palpable. The gland may be normal or abnormal in structure and function.

### **CASE HISTORY**

The symptoms are important evidence to know whether hyper or hypo thyroidism is associated with goitre. The patient and family members may have noticed alteration in mental activity irritability or excitability. The patient may give history regarding alteration in temperature tolerance, perspiration and change in weight, bowel habits and appetite or eye changes or palpitation. Pressure symptoms like dysphagia, hoarseness of voice, or dyspnoea may occur with goitre. A history regarding diet, ingestion or goitrogenic foods like cabbage,

soyabeans and drugs should be elicited. History of having stayed in endemic area and family history of similar swelling should be recorded.

## **GENERAL PHYSICAL EXAMINATION**

Here the signs of hyper or hypothyroidism are to be recorded. Tachycardia during sleep and loss of weight in hyperthyroidism, whereas bradycardia and weight gain are seen in hypothyroidism. The extremities will be hot and moist in hyperthyroidism and cold and dry in hypothyroidism. Tremors of hand and tongue are seen in hyperthyroidism. Eye signs are characteristic of primary thyrotoxicosis and these include Stelwag's sign, Van Graef's sign, Joffroy's sign and Moebius sign. In secondary thyrotoxicosis the eye signs are not the characteristic feature.<sup>22</sup>

## **LOCAL EXAMINATION**

### **Inspection**

It is the most important part of examination. It provides lot of information and thyroid gland is confirmed by movement with deglutition. To know the retrosternal extension of the goitre, one must look for the lower border of the gland.

## **Palpation**

The gland is palpated both from behind and in front of the patient, for better palpation of localized nodules. During palpation consistency and type of enlargement of the gland is noted. The surface is bosselated with gross varying of consistency in MNG, where as in thyroid carcinoma the consistency is hard, with indistinct margin and irregular surface. If lower border of the gland is not felt, it suggests retrosternal goitre. Examination of regional lymph nodes, carotid pulsation and position of trachea must be done routinely. For simple nodular goitre thyroid function tests are not required as normal thyroid function is maintained. Stippled calcifications may be noted on x-ray of the neck in MNG. Now-a-days FNAC has changed the management of MNG and has helped to plan for surgery in advance, but has 5% to 30% of both false positive and false negative results. Iodine131 scan differentiates thyroid nodules into cold, warm and hot nodules.

## **INVESTIGATIONS FOR MNG**

### **Diagnostic tests of thyroid function and structure**

Now-a-days varieties of tests that provide objective evidence of the status of thyroid function and to assess the thyroid lesions are increasing constantly. No single test or procedure consistently yields a reliable result

for diagnosis, but each test has a specific indication. Most frequently the results of tests combine to provide a correct overall assessment of thyroid function and structure.

## **I. Tests for thyroid function**

1. Thyroid hormones ( $T_4$  and  $T_3$ ) assay
2. Tests of thyroid binding proteins
3. Free thyroid hormone indices
4. Free thyroid hormone measurements ( $FT_4$  and  $FT_3$ ).
5. Pituitary thyroid axis (TSH) assay
6. Hypothalamic – pituitary axis (TRH test)

## **II. Imaging studies of the Thyroid**

1. Radionuclide Imaging

$I^{123}$

$I^{131}$

Tc99m pertechnetate



### **III. Assessment of thyroid anatomy**

- Ultrasound scan
- Computerised tomography (CT)
- Nuclear magnetic resonance imaging (NMRI).

### **IV. Tissue diagnosis**

- FNAC

### **V. Measurement of thyroid autoimmunity**

- Anti-thyroglobulin antibodies
- Antimicrosomal antibodies
- Long acting thyroid stimulator (LATS)
- Thyroid stimulating immunoglobulins (TSI)

### **VI. Miscellaneous tests**

- X-ray of the neck – AP and lateral views, X-ray of the chest - PA view
- Indirect laryngoscopy, Thyroglobulin assay, Calcitonin assay

## **ULTRASOUND SCAN**

Ultrasonography has occupied a definite place in the management of diseases affecting various parts of the body, ever since its introduction to the medical field. Its part in diagnostic approach of thyroid diseases has not been well defined, but it represents the first modality that has made it possible to establish the physical state of thyroid lesion before surgery. The thyroid nodularity evaluation with normal or enlarged volume can be performed with a much higher sensitivity by high-resolution ultrasonography when compared with palpation. Alderson, summer and Seigal reported that approximately 36% of clinically diagnosed solitary nodules were multiple on scan. By ultrasound, solid cystic and mixed solid cystic nodules can be differentiated. Among the solid nodules, those of high or normal echogenicity can be distinguished from those with reduced echogenicity by comparison with normal thyroid and the neighbouring muscular tissue. This may be helpful in determining the nodules to be investigated further by FNAC to exclude or confirm malignancy, but it has to be emphasized that the sonomorphological appearance of a nodule per se does not exclude malignancy. Ultrasound also cannot differentiate between functioning and non-functioning nodules.

## **FINE NEEDLE ASPIRATION CYTOLOGY (FNAC)**

For the last 15-20 years, there is a remarkable change in the approach to diagnose thyroid nodules. FNAC involves establishing a tissue diagnosis by needle aspiration cytology. FNAC has occupied a definite place in the investigation and management of thyroid nodules. The most common approach is to use a smaller needle (Gauge 23-25) and G 10-20 ml syringe. This technique provides material for cytological rather than histological interpretation.

### **PROCEDURE**

The patient is put in supine position with a pillow under the shoulder to push the thyroid nodule more anteriorly. The nodule is mobilized between the fingers and thumb of one hand and the needle is inserted using firm pressure with the other hand, to help stabilize the syringe and the needle. Now suction is obtained in the syringe to create a negative pressure. Then the needle is moved back and forth in the nodule in different directions, with the negative pressure maintained. As soon as the material is seen in the barrel of the syringe, pressure is released to re-establish atmospheric pressure in the syringe. The syringe is disconnected with the needle still in situ. The syringe is filled with air and reattached to the needle and then removed with the needle. Now, the tissue drop is

gently expressed on to a glass slide. One half of the slide is placed as quickly as possible in 95% alcohol (fixative), the remainder is dried in air. The immersed part is stained using Papanicolou or an equivalent stain, the air dried part with Wright's stain, which demonstrates colloid. There are four broad categories into which the results fall, malignant, benign, suspicious and inadequate. In the last case, the aspirate should be repeated. Papillary carcinoma, medullary carcinoma, anaplastic carcinoma and thyroiditis can be diagnosed with confidence using FNAC. Follicular adenoma cannot be differentiated from follicular carcinoma on cytological features alone, since identification of capsular and vascular invasion is important for diagnosis of follicular carcinoma. Ashcraft and Van Herle in an extensive review of the literature found that the overall accuracy of the procedure has around 90%, false positive rate around 3-8% and false negative rate around 5%. When FNAC report comes as follicular adenoma or suspicious of malignancy, surgery has to be undertaken to confirm the pathology.

M. A. Tabaqchali et al <sup>23</sup>, in a study conducted in U.K. concluded that FNAC is invaluable and minimally invasive procedure, for the preoperative assessment of patients with a dominant thyroid nodule. FNAC predicted neoplasia with a sensitivity of 86.8%, a specificity of 67.0%, negative predictive value of 87.5% and a positive predictive value

of 65.5%, malignancy was predicted by FNAC with a sensitivity of 88.9%. M. Serralva <sup>24</sup> et al in a study in Portugal concluded that FNAC is a reliable thyroid lesions diagnostic method with an elevated accuracy, sensitivity and specificity. However one of its limitations is its inability to differentiate between benign follicular tumour from the malignant.

## **CYTOLOGICAL AND HISTOLOGICAL FEATURES OF DIFFERENT THYROID DISORDERS** <sup>15</sup>

### **1. Normal thyroid:**

Small clusters and sheets of epithelial cells with small amount of thin colloid, C cells, cartilage, tracheal epithelium and skeletal muscle may be found.

### **2. Nodular colloid goitre:**

Diagnostic criteria are as follows

- Abundant colloid of both thick and thin types
- Follicular cells in sheets and clumps, fragile feathery cytoplasm,
- numerous bare nuclei
- Foamy cells
- Degenerating erythrocytes
- Hyalinized stroma

### **3. Grave's disease: (Primary Thyrotoxicosis)**

- Blood stained smear with little colloid
- Moderate amount of epithelium and some follicular and ring structures
- Enlarged cells with more abundant vacuolated cytoplasm, variation in nuclear size
- Fire flares/ colloid suds/ marginal vacuoles are the features in this disorder

### **4. Hashimoto's thyroiditis:**

- Presence of Ashkenazy cells
- Moderate number of lymphocytes mainly of small mature type and scattered plasma cells
- Small multinucleate giant cells, epitheloid histiocytes
- Thyroid follicles disrupted and the follicular basement membrane is damaged with enlarged epithelial cells with characteristic oxyphilic change in the cytoplasm

### **5. Multinodular goiter:**

Microscopically there will be normal to hyperplastic foci of thyroid tissue, large areas of colloid, haemorrhage, fibrosis and calcification, variable amounts of lymphocytic infiltration can also be seen.

## **6. Follicular adenoma:**

These are 3 types, according to their architecture, cellularity and amount of colloid. They are fetal colloid, embryonal and Hurthle cell types. Hurthle cell lesions contain cells that are markedly eosinophilic and whose cytoplasm contains abundant mitochondria.

## **7. Follicular carcinoma:**

These may be non-invasive (minimally invasive) or invasive (angio and capsular invasion). In few cases Hurthle cells are present which show aggressiveness of the tumour.

## **8. Papillary carcinoma:**

Presence of colloid filled follicles with papillary projections. In some cases calcified lesions are found which are called Psammoma bodies, which is diagnostic feature of papillary carcinoma. In few cases, presence of orphan eyed nuclei (Orphan Annie) with a pale empty nuclei may be seen.

## **9. Medullary carcinoma:**

Dispersed cell pattern, cuboidal cells with oval, eccentric pleomorphic nuclei and well defined gray blue cytoplasm, spindle cell forms with elongated cytoplasm, red cytoplasmic granularity and

presence of amyloid material in the background are the characteristic features.

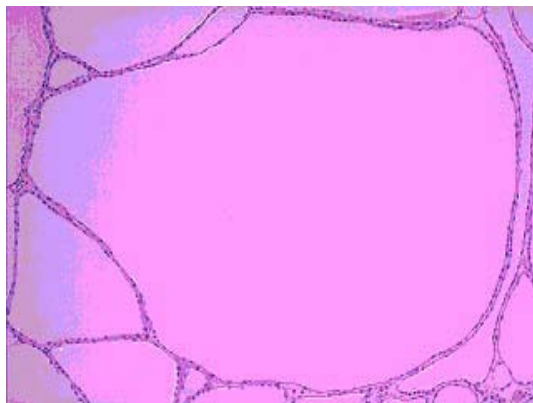
#### **10. Anaplastic carcinoma:**

Bizarre, large malignant cells with macrophage like appearance, multinucleate malignant cells, and malignant spindled cells with mesenchymal appearance and necrotic cell fragment debris with a dirty background are the features.

#### **11. Lymphomas:**

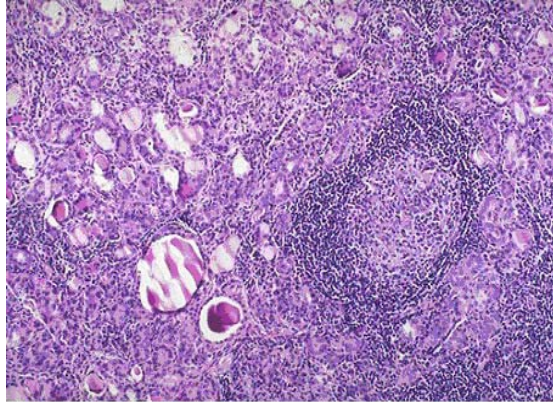
Shows mixed cell population resembling reactive processes like elsewhere in the body.

### **HISTOLOGICAL FEATURES OF DIFFERENT THYROID DISEASES:**

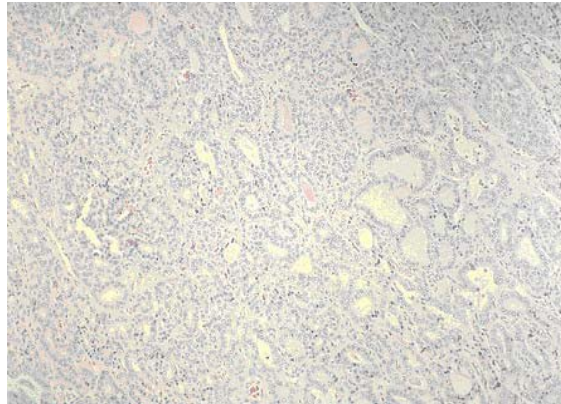


SLIDE 1: COLLOID GOITRE

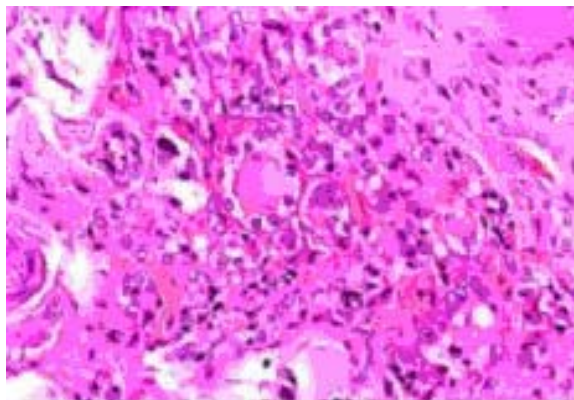




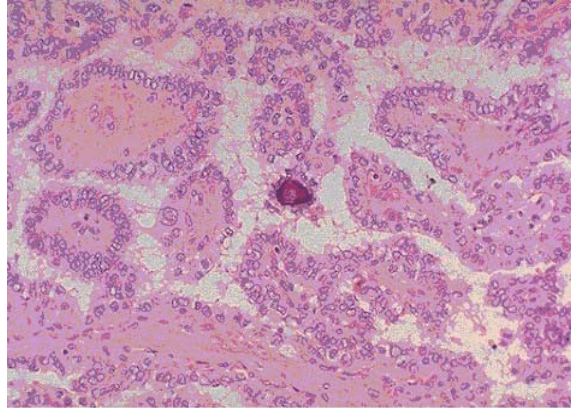
SLIDE 2: HASHIMOTOS THYROIDITIS



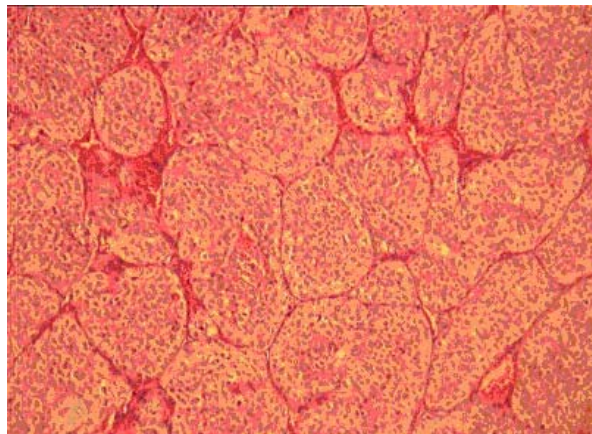
SLIDE 3: FOLLICULAR ADENOMA



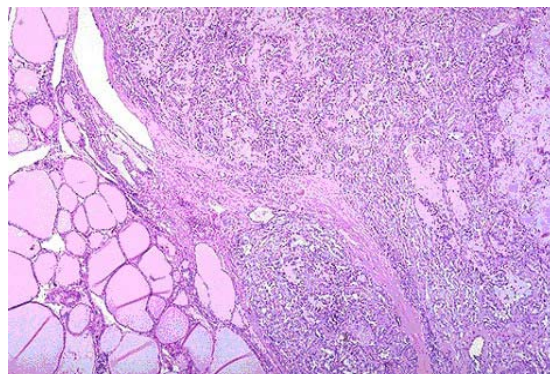
SLIDE 4:FOLLICULAR CARCINOMA



SLIDE 5: PAPILLARY CARCINOMA



SLIDE 6: ANAPLASTIC CARCINOMA



SLIDE 7: MEDULLARY CARCINOMA

## **RADIOIODINE UPTAKE AND THYROID SCAN**

In 1951, Cassen and his co-workers were among the first to use automatic radioisotope scanning for diagnosis of diseases in body organ. They selected thyroid gland naturally as the first organ for studying. The remarkable avidity of the thyroid gland for radioiodine permitted visualization even with the primitive scanning equipment available at that time.

### **RADIOIODINE UPTAKE**

This is tested by giving a known amount of radioactive iodine to the patient and measuring the percentage taken by the thyroid by an external counting device. Radionuclide iodine used are  $I^{123}$  and  $I^{131}$ . The radionuclide is given by mouth either in capsule form or as liquid form and the measurement is made at a known time after ingestion. The 24 hour uptake is most useful;

The uptake measurement depends on the function of the thyroid gland and the size of the iodine pool or more precisely the plasma inorganic iodine. Originally the test was used in differentiating normal people from hyperthyroid and hypothyroid patients. But it was subsequently found that there are many conditions associated with low uptake of radioiodine and the patient can be clinically hyperthyroid,

euthyroid or hypothyroid. Also high uptake can be due to many causes apart from hyper thyroidism. Hence, uptake measurement cannot be used to determine thyroid functional states. It has to be defined clinically and by measurement of thyroid hormone preferably FT<sub>4</sub>, FT<sub>3</sub> and TSH.

### **Causes of increased radio iodine uptake**

1. Hyperthyroidism Graves disease, Toxic adenoma, Toxic MNG
2. Iodine deficiency
3. Recovery form thyroiditis
4. Dysharmonogenesis except trapping defect
5. After stopping anti-thyroid drugs
6. in neonates

### **Causes of decreased radioiodine uptake**

1. Iodine load Dietary, Radiographic contrast agents, Medicines with inorganic iodine
2. Thyroxine or other thyroid medication – factitious thyroiditis
3. Hypothyroidism

4. Ectopic thyroid
5. Radio nuclide capsules not ingested or digested
6. after severe exercise
7. Technical error.

The two main indications for the tests are

1. To differentiate those patients with hyperthyroidism and high uptake from those with low uptake
2. The test is a prerequisite to treating a patient with radioiodine.

It is important to ensure before making an uptake measurement that the patient is not taking any thyroid or antithyroid medications, and not been on any recent radiographic contrast injections or intake of iodine containing medicines. Thyroxine has to be stopped 4 weeks before and T3 for 2 weeks before doing the test. TC99m as per technate can be used for uptake measurement. It is normally used in a range of 0.2% to 3.0%. It is highly useful in situations where it is essential to establish the diagnosis of hyperthyroidism urgently. Technetium uptake can confirm this within minutes. The main clinical problem with its use could be

severe toxicity, fever, tachycardia confusion and obtundation in a patient with goitre.

## **THYROID SCINTIGRAPHY**

### **a) Routine Scintigraphy**

Thyroid Scintigraphy as volume test became possible with the development of the rectilinear scanner by Casson. Now imaging is done by using camera with a pinhole collimator. The radionuclide  $I^{123}$  is given by mouth as a capsule and scintigrams are obtained 3-6 hours later. Now a days Technetium 99m (TC99m) which is normally taken up by thyroid, like iodine, is used.

The usefulness of scan has been for:

1. Determining the size of the gland
2. Determining if a nodule concentrates the radioiodine or (TC99m) or not i.e, hot or cold or warm (normal). The risk of malignancy in cold nodule is around 20%, Hot or warm nodule (<5%)
3. Determining if a retrosternal shadow on chest radiograph is due to thyroid.

4. Determining if a lump in the tongue or track of thyroglossal duct containing functioning thyroid and ectopic thyroid.
5. For evaluation of toxic MNG

Normally more thyroid scans are obtained to determine whether the nodule is hot or cold than for any other reason. This is because malignancy is extremely rare in MNG and thyroid cancers are often cold on scan. The principle value of isotope scanning is in a toxic patient, with a nodule or nodularity of thyroid. Localization of over activity in the gland will differentiate between toxic nodule with suppression of remainder of gland and toxic Multinodular goitre with several areas of increased uptake with important implications for therapy. Routine isotope scanning in thyroid swelling is unnecessary.

b) Whole body Scintigraphy for thyroid metastases

Whole body Scintigraphy is designed to provide information about the presence or absence of functioning metastases from differentiated thyroid cancer. The test is of no value in anaplastic or medullary cancer. It should be done only after total thyroidectomy because if it is done in the presence of significant amount of normal thyroid tissue, the radioiodine localizes preferentially in that site and metastases are not

visualized. Autoradiographic studies have shown that metastatic thyroid cancer have about 1% of the uptake of normal thyroid. Most nuclear physicians use 1 or 2 mci of  $I^{131}$ , whole body Scintigram should be delayed for about 4 weeks from the time of surgery to allow endogenously secreted thyroid hormones to be metabolized and TSH to raise. Blood is drawn for TSH and thyroglobulin before the dose of  $I^{131}$  is administered. A whole body scan is obtained 48-72 hours after the radioiodine dose is administered. This delay allows background activity to fall to very low level, and it allows sufficient time for metastases to trap iodine. An anterior and a posterior whole body images as well as pin hole images of the thyroid are obtained. Functioning metastases take up radio iodine and appear on the scan. Normal uptake is expected in residual salivary gland, stomach, colon and bladder. The main drawback of this scan is that about 10% of differentiated thyroid cancers do not concentrate radioiodine.

Sometimes false positive results occur. Eg. Bronchitis and bronchiectasis cause positive uptake in lungs. Uptake in the lesions can be calculated so that the dose of radioiodine required to ablate the metastases can be made.



## **MISCELLANEOUS RADIOLOGICAL STUDIES**

### **Computerized Tomography (CT)**

There is no place for a CT scanning in routine evaluation of patients with thyroid disease. The following are the indications for CT.

1. Substernal goitre not concentrating iodine.
2. Thyroid malignancy to rule out infiltration to adjacent structures.

## **HORMONAL ASSAY**

### **TOTAL THYROID HORMONES**

Total T4 and T3 are measured by specific radioimmunoassay. Since they are highly protein bound, their values depends on the levels of the binding proteins in the serum. Most patients with hyperthyroidism with normal levels of protein have high T4 and T3 less commonly only T3 is high (T3 toxicosis) and this is more characteristic of hyperthyroidism due to a functioning autonomous nodule, early Grave's disease or those replacing after stopping anti-thyroid drugs. The normal total plasma T4 level is approximately 8 micro g/dl and plasma total T3 level is 0.15micro g/dl.<sup>12</sup>

## **CAUSES OF HIGH LEVEL OF THYROID HORMONES**

- Hyperthyroidism
  
- Increased binding proteins
  - Pregnancy  Oral contraceptive  Active hepatitis  Hereditary
  
  - Porphyrin  New born
  
- Acute psychiatric illness
  
- Acute medical illness
  
- Antibody to thyroid hormones
  
- Pituitary resistance to thyroid hormones

## **CAUSES OF LOW LEVELS OF THYROID HORMONES (TOTAL)**

- Hypothyroidism
  
- Decreased binding proteins
  - Androgens  Nephrotic syndrome  Hereditary  Glucocorticoids
  
  - Cirrhosis of liver  Non thyroidal illness  Low T3 syndrome

- Low T3 and low T4 (sick euthyroid)

## **TESTS OF THYROXINE BINDING PROTEINS**

For estimation of TBG and TBPA there are specific radioimmunoassay tests. Because TBG is the most important protein, carrying 70-80% of the hormone, it is usually measured alone. Thyroxine binding capacity (TBC) can be measured indirectly by quantitating the capacity of binding sites in serum, which are not carrying hormone. This is done using the T<sub>3</sub> resin uptake test (T<sub>3</sub>RU) and usually it is in the range of 25% to 35%. If there are a lot of unoccupied binding sites on the proteins, the tracer will bind there and the T<sub>3</sub>RU is low and vice versa. Knowledge of T<sub>4</sub>, T<sub>3</sub> and T<sub>3</sub>RU values makes it possible to determine if the problem is due to thyroid diseases, or to a binding protein abnormality. If both the tests are abnormal in the same direction, the thyroid is at fault, Eg. If T<sub>4</sub> and T<sub>3</sub>RU are both high, hyperthyroidism is diagnosed. In contrast if one test is high and the other low, the defect is due to carrier proteins.

## **FREE THYROID HORMONE INDICES (BY CALCULATION)**

This is obtained by the formula:

$$FT_4 I = \frac{\text{Total } T_4}{T_3RU} \times 100$$

$$FT_3 I = \frac{\text{Total } T_3}{T_3RU} \times 100$$

These tests have gained widespread acceptance in practice because the two tests used for its derivation are simple and are robust.

Free thyroid hormone ( $FT_4$ ) measurement  $FT_4$  can be measured by two methods, Equilibrium dialysis or radioimmunoassay. It is generally accepted that the dialysis method is the gold standard, however it is restricted to research laboratories. Radioimmunoassay is sensitive and specific.  $FT_4$  measurement provides excellent index of thyroid status in almost any clinical situation with the few exceptions, which are very rare. E.g. Heparinized patients and in acute psychiatric illness. This test is not influenced by abnormalities in the thyroid binding proteins.

### **Pituitary Thyroid axis – TSH**

TSH radioimmunoassay became available in 1965. When TSH is above normal and  $T_4$  and  $T_3$  are normal, it is called subclinical hypothyroidism. But older assay could only differentiate TSH levels of 1

$\mu\text{u/ml}$  or  $2 \mu\text{u/ml}$  and since many euthyroid individuals have TSH levels of  $0.5\mu\text{u/ml}$  to  $2.0 \mu\text{u/ml}$ , assay could not separate suppressed values from normal values, but with the introduction of immunoradiometric assay (IRMA) and amplified enzyme linked immunoassay (AEIA), TSH levels less than  $0.3$  micro units/ml can be detected. TSH is an extremely valuable diagnostic aid, hypothyroid patients have high levels and hyperthyroids have low levels, provided pituitary insufficiency is excluded. When thyroid hormones are at normal level and TSH is undetectable it is called subclinical hyperthyroidism. Hypothalamic pituitary axis (TRH Test)

Thyrotrophin releasing hormones was isolated characterized and synthesized in 1968 and soon became available for clinical use. This is tested by injecting TRH intravenously and evaluating the response of the pituitary to secrete TSH. A normal response is a rise in TSH, which is maximal at 20-30 minutes with return to normal by 60-90 minutes. In hyperthyroidism the pituitary is suppressed by thyroid hormone and there is no rise in TSH after injection of TRH. This test was of great value in understanding the physiology and pathophysiology of the hypothalamic pituitary thyroid interaction and it was valuable clinically in the diagnosis of borderline hyperthyroidism. Because of the development of sensitive TSH measurement, which shows suppressed levels in hyperthyroidism,

the TRH test is superfluous in this role. Patients with primary hypothyroidism have an elevated TSH by definition; therefore TRH test is also superfluous in this situation.

## **MISCELLANEOUS INVESTIGATION**

- **X-ray of neck** –AP and lateral views to assess the position of trachea and to determine tracheal compression or displacement in anteroposterior or lateral plane, tracheal calcifications, tracheomalacia and scabbard trachea.

- **X-ray of chest** – PA view to see for widened mediastinal shadow in case of retrosternal goitre.

- **Indirect laryngoscopy** – To record asymptomatic recurrent laryngeal paralysis being of medico legal importance.

- **Recording of sleeping pulse rate** in the diagnosis of thyrotoxicosis and its severity is based on the pulse rate as follows:

- Mild -- 90-100 beats/ minute
- Moderate -- 100-110 beats/ minute
- Severe -- >110 beats/ minute

## **TREATMENT OF MULTINODULAR GOITRE**

When treatment of MNG is considered the patient's overall health and comorbidities required critical assessment. The aetiology and co-existent thyroid diseases associated with MNG often direct the ultimate type of treatment. Toxic and nontoxic MNG should be addressed separately, and the type of treatment should be directed at each of these types of MNG, as well as the issues related to the success of each treatment option. Treatments include non-surgical and surgical approaches. Regional trends often influence the management of MNG. In general, surgery is necessary in extremely large MNG for cosmetic appearance, suspicion of malignancy, tracheal or esophageal symptomatology, substernal extension, vocal cord paralysis and rapid growth otherwise consideration should be given to medical or radioiodine treatment. Development of goitre is usually due to iodine deficiency, which causes the gland to hypertrophy due to TSH stimulation, so measures to prevent iodine deficiency are taken.

## **PROPHYLAXIS**

Endemic goitre is one where 10% or more population living in an area shows signs of thyroid enlargement. Iodine is used as a preventive measure in endemic region. This is achieved by iodinating the table salt.

The concentration used is potassium iodide 1 part in 10,000. In most of endemic areas like Switzerland, Argentina, parts of USA, the incidence of endemic goitre is decreasing due to iodination of the table salt.

### **PLAN OF ACTION IN INDIA** <sup>25</sup>

The Government of India launched a National Goitre Control Programme.

The objectives of the programme are as follows:

- a) Survey of goitre suspected area to identify goitre endemic region.
- b) Production and supply of iodinated table salt to endemic area.
- c) Resurvey after 5 years of continuous supply of iodinated salt in endemic area to assess the impact of control programme.

The UNICEF has donated iodinated plants; they are working at Howrah, Hharghoda, Sambhar lake and Gauhati. Their main aim is production and supply of iodinated salt to all endemic areas Intramuscular injection of iodized oil is used in preventing endemic goitre in areas where iodized salt cannot be consumed. Iodized poppy oil in a dose of 1-2 ml for adults and smaller doses for infants and children and repeated once in every 3 years.



## **FACTS FOR ROUTINE REMOVAL OF MNG (SOKAL) <sup>19</sup>**

- a. Statistics from various centres throughout the world indicate that 4%-17% of nontoxic goitres are malignant.
- b. Nodular goitre, is usually benign but is likely to become malignant later, and therefore should be removed as a cancer prophylaxis.

No author recommends prophylactic thyroidectomy but some mention thyroidectomy in nodular goitre on the basis that nodules are likely to be malignant than becoming malignant.

### **1. Surgery for simple MNG**

Nodular stage of simple goitre is irreversible. Most patients of MNG are asymptomatic and do not require operation. Operation may be indicated on cosmetic grounds, if the goitre is unsightly. Retrosternal goitre with actual or incipient tracheal obstruction is an indication of operation, as in the presence of a dominant area of enlargement, which may be neoplastic.

There is a choice of surgical treatment:

Total thyroidectomy with immediate and lifelong replacement of

thyroxine.

## **2. Surgery for toxic MNG <sup>28</sup>**

Patients with toxic multinodular goitre should be treated with anti thyroid drugs to bring the patient to euthyroid state before surgery. The curative treatment for toxic MNG is total thyroidectomy.

## **3. Treatment of retrosternal goitre (RSG)**

Resection of retrosternal goitre can almost always be performed from the neck and a midline sternotomy is hardly even necessary. The cervical part of the goitre should first be mobilized by ligation and division of the superior thyroid vessels and ligation and division of middle thyroid veins and inferior thyroid vessel. RSG can then be delivered by traction and finger mobilization. Bleeding is rarely a problem because the goitre takes its blood supply with it from the neck. Prof. M. H. Wheeler <sup>29</sup> of Cardiff, UK has suggested that most RSGs can be resected through an entirely cervical approach with a low complication rate. Sternotomy is required for large intrathoracic goitre where the thoracic inlet may be too small for delivery of the gland, for tumour with significant invasion and when uncontrolled bleeding is encountered. The rare truly ectopic intrathoracic gland with its major blood supply derived from intrathoracic vessels also dictates sternotomy. Sonal Pandya <sup>30</sup> Laura, Esemder, Burlington, Massachusetts describe a method where

by a Foley catheter placed beyond the substernal component of goitre with steady traction on inflated balloon has been successfully and safely used in two patients and suggests that this may obviate the need for sternotomy. In the nontoxic MNG, surgery is performed mainly to prevent pressure effect for cosmetic purpose and whenever there is suspicion of malignancy. Although prophylactic surgery to prevent the occurrence of carcinoma is not justified in Multinodular goitre, 4% to 17% of glands removed contain malignant foci. Surgery done is mainly subtotal thyroidectomy.

In toxic Multinodular goitre, surgery is the choice of treatment. Treatment with radioiodine is highly unreliable because blood flow through such goitre is not homogenous or as symmetrical as diffuse goitre. So the uptake of radioiodine by the goitre is irregular and many areas escape effective radiation and the hyperthyroidism continues. For this reason surgery is the treatment of choice for hyperthyroidism due to Multinodular goitre.

After subtotal resection it has been customary to give thyroxine to suppress TSH secretion with the aim of preventing recurrence. Whether this is necessary or effective is uncertain, although the evidence of benefit in endemic areas is better than elsewhere.

## **PREPARATION OF PATIENT PRIOR OF SURGERY** <sup>31, 16, 27</sup>

Patients with various thyroid disorders must be brought to euthyroid state before surgery. Untreated hyperthyroidism may lead to tachycardia and thyroid storm. Uncontrolled hypothyroidism may result in hypotension and respiratory distress. Carbimazole is the most commonly used drug in the treatment of hyperthyroidism. Carbimazole 30-40 mg per day in 3-4 equally divided doses is given. Clinical improvement is apparent only with a latency of 7- 14 days. The drug dose is given at 6 or 8 hours interval, maintaining high concentration of the drug throughout 24 hrs. When the patient attains euthyroid state, the dose may be reduced to 5 mg 8 hourly and the addition of thyroxine may facilitate maintenance of the euthyroid state. The final dose of carbimazole is given on the night before surgery. The untoward reaction of neomercazole is agranulocytosis. The incidence of agranulocytosis is about 7% and usually occurs during the first few weeks of therapy but may occur later. Agranulocytosis is reversible on discontinuation of the drug. Preparation is as an outpatient and only rarely admission to hospital is necessary. A safer preparation is to control the clinical manifestations of the toxic state. Drugs used are Propranolol 40 mg thrice daily or preferably the longer acting Nadolol 160 mg once daily. Clinical response is rapid in beta-blockers. Beta-blockers do not act on the gland itself.

Propranolol inhibits the peripheral conversion of T4 to T3. They do not affect the thyroid hormone synthesis, so during treatment hormones level remain high and for some days after thyroidectomy. So the drugs have to be continued for 7 days postoperatively. Lugols iodine, 5 drops three times daily in milk is claimed to reduce the vascularity of the goitre and make it firmer and easier to handle. Potassium iodide tablets 60 mg three times daily may be used as an alternative.

## **TECHNIQUE**

### **TOTAL THYROIDECTOMY** <sup>32</sup>

A slightly curved transverse skin crease incision is made 2–3 cm above the sternum (it should not be positioned lower than this or the central portion of the scar will hypertrophy). The skin can be marked preoperatively using natural skin crease lines as a guide. Platysma is incised in line with the skin, and the skin and platysma flaps are elevated down to the sternum, and up to the thyroid cartilage. A self-retaining Joll's retractor is then positioned to retract the flaps. The deep cervical fascia is incised vertically in the midline, and the strap muscles retracted laterally. If division of strap muscles is necessary they should be divided high up as their innervation is from below. They are repaired at the end of the procedure. The assistant retracts the strap muscles laterally, and away

from the surface of the gland. Areolar tissue around the gland is divided and the middle and inferior thyroid veins are displayed. These require ligation and division. The deepest of the inferior thyroid veins may be in close proximity to the recurrent laryngeal nerve, and the final ligations in this area may have to wait until the nerve has been identified. Attention is next turned to the superior pole. With gentle traction on the now partially mobilized lobe it should be possible to pass a rightangled forceps behind the superior pole vessels and pass a mounted tie around them. An aneurysm needle is also very useful for this step. The external laryngeal nerve is endangered during this manoeuvre, and it is important to try and find the window medial to the superior pole vessels and stay a few millimetres lateral to the surface of the larynx. The ligature is then tied as low as possible. A second ligature is tied above it, and an artery forceps is placed immediately above this second ligature. The vessels are then divided between the ligatures and a further ligature tied on the superior thyroid pedicle before the forceps is released. Too high a tie of these vessels also endangers the external laryngeal nerve. The lobe is then rotated medially out of its bed. The assistant is now retracting in a deeper plane, and the retractor is drawing the carotid sheath laterally. The inferior thyroid artery and the recurrent laryngeal nerve must now be displayed, and both lie beneath a fascial layer which must be incised. The

inferior thyroid artery is ligated in continuity, but only after the nerve is identified and safeguarded. An aneurysm needle is the easiest method of passing the tie beneath the artery, which is then ligated as lateral as possible to minimize any danger to the nerve. The final dissection of the deep portion of the gland off the recurrent nerve and the parathyroids is the most difficult, and must be performed with great precision. The medial surface of the lobe then separates easily from the trachea, and is finally only attached by the isthmus which is divided close to the contralateral lobe. A haemostatic continuous absorbable suture in the isthmus will control haemorrhage. Similarly other lobe is dissected. Total thyroidectomy done. A deep vacuum drain is placed beneath the strap muscles before they are approximated. The platysma is sutured, and finally the skin is closed using sutures or staples.

## **POSTOPERATIVE COMPLICATIONS**

### **Haemorrhage**

Due to slipping of the superior thyroid artery ligature, tension haematoma develops. Occasionally thyroid remnant or a thyroid vein may be responsible for haematoma. Sometimes it is necessary to open the wound to relieve tension, and the patient is shifted to theatre for haematoma evacuation and ligating bleeding vessel

### **Respiratory obstruction**

Most cases are due to laryngeal oedema. Tension haematoma is the important cause. If the goitre is very large, laryngeal odema develops due to injury to larynx during intubation. Immediate postoperative respiratory obstruction is not due to recurrent laryngeal nerve injury. If airway obstruction is not relieved by releasing tension haematoma, patient should be intubated at once. An endotracheal tube may be left in place for several days; to reduce laryngeal oedema, steroids can be given.

### **Postoperative thyroid crisis**

It is due to inadequate preparation of the patient before surgery. It is characterized by tachycardia, high fever, restlessness and delirium, progressing towards cardiac failure. Supportive treatment is given for dehydration, hyperpyrexia and restlessness. This requires administration of oxygen, intravenous fluids, cooling the patient with icepacks and, digoxin for uncontrolled atrial fibrillation, sedation and intravenous hydrocortisone. Specific treatment –

carbimazole 10-20 mg 6 hourly,

lugol's iodine 10 drops 8 hourly by mouth or

Sodium iodide 1 gm intravenously



Propranolol 40 mg 6 hourly orally will block adverse beta adrenergic effects.

### **PARATHYROID INSUFFICIENCY**

This is due to parathyroid glands removal or trauma to parathyroid end artery. The incidence of this condition is less than 0.5% and most cases will present 2-5 days after operation, but very rarely the onset is delayed for 2-3 weeks or a patient with marked hypocalcaemia is asymptomatic. It is commonly transient in nature and quickly controlled by calcium by mouth. If severe, 20 ml of 20% solution of calcium gluconate is given intravenously i.e, (10 ml of 10% ampoule) and later supplemented with oral calcium.

### **RECURRENT LARYNGEAL NERVE PARALYSIS**

This may be unilateral or bilateral, transient or permanent. Transient paralysis occurs in about 3% of cases and recovers in about 3 weeks to 3 months. Permanent paralysis is rare if the nerve has been identified at operation. If recovery does not take place within this period, organic injury to the nerve should be suspected. This may be due to stretching or bruising of the nerve or to its inclusion in a ligature, it is seldom divided. The prognosis regarding the recovery of function is poor if the nerve is divided. Repair of the nerve may be attempted, but the

results are uncertain. Roberto Berganiaschi et al<sup>33</sup> in a study conducted in France, including 192 thyroidectomies during 50 months with a follow up of 8.56 months gave the following inference regarding complications:

Death – 0.08%, Haematoma-1.6%, Chyle leak – 0.2%, Abscess – 0.5%

- Temporary and permanent hypoparathyroidism – 20% and 4% respectively. Temporary and permanent recurrent laryngeal nerve palsy – 2.9% and 0.5% respectively. Chung Yau Lo et al<sup>34</sup> in a study on 500 thyroidectomies in Hong Kong observed incidence of temporary and permanent recurrent laryngeal nerve palsy as 5.2% and 1.4% respectively.

Garanni Sturniolo et al<sup>34</sup> in a study on 192 thyroidectomies in Italy observed one case (0.5%) of recurrent laryngeal nerve injury due to neoplastic infiltration, one case (0.5%) of unilateral cordal hypo motility and two (1.04%) of bilateral hypo motility with temporary dysphonia, which regressed in 6 months of time.

### **Hypothyroidism**

Hypothyroidism occurs within 2 years, may be delayed for 5 years or more. Hypothyroidism commonly follows after subtotal thyroidectomy

for lymphocytic thyroiditis. The treatment consists of administration of L-Thyroxine 0.1mg to prevent myxedema after analyzing thyroid profile post operatively at 1 week and 1 month.

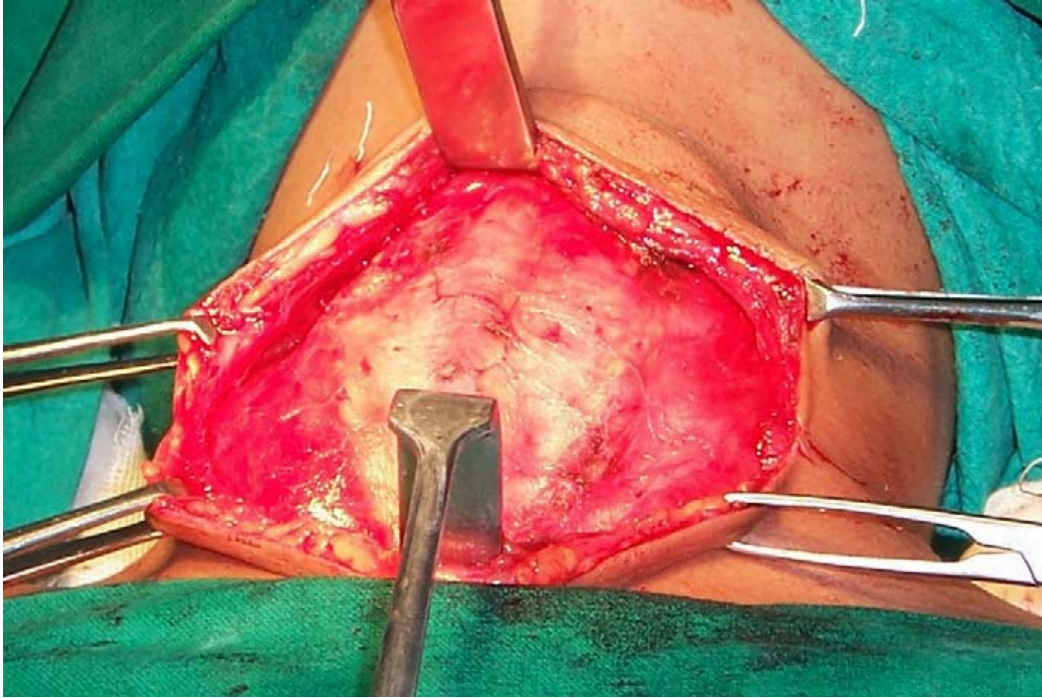
### **Recurrent thyrotoxicosis**

This is due to either removal of inadequate thyroid tissue or to subsequent hyperplasia of the tissue that has been left. It is not uncommon in primary toxic goitre but very rare in the secondary thyrotoxicosis. Further operation should be avoided if possible. The best results are obtained by radioiodine or by the anti-thyroid drugs.

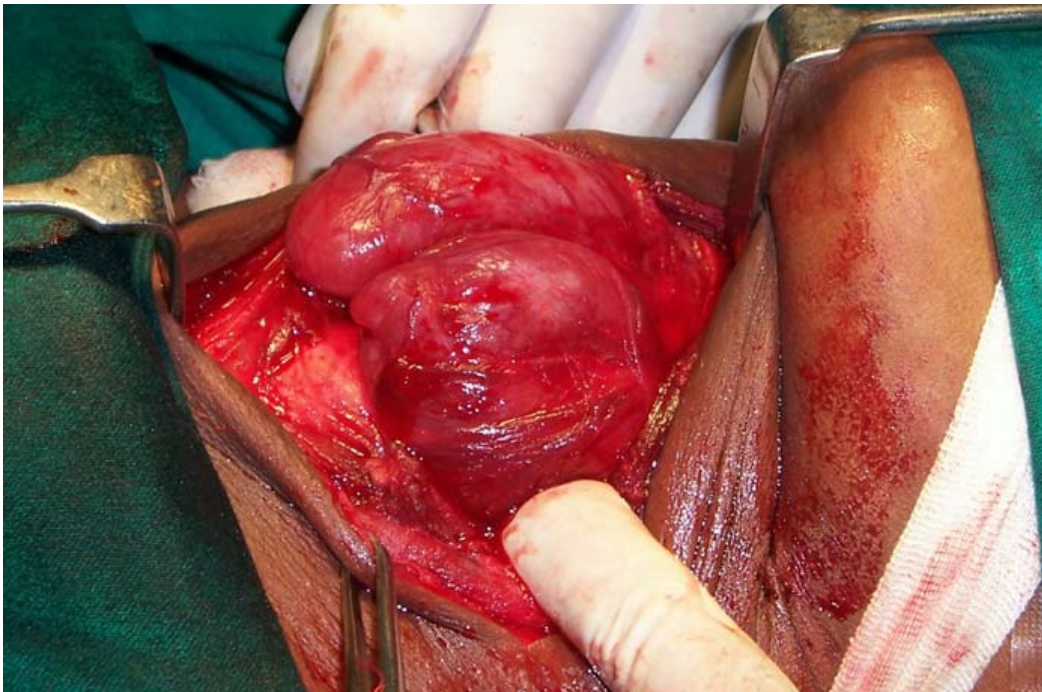
### **Other complications**

These include:

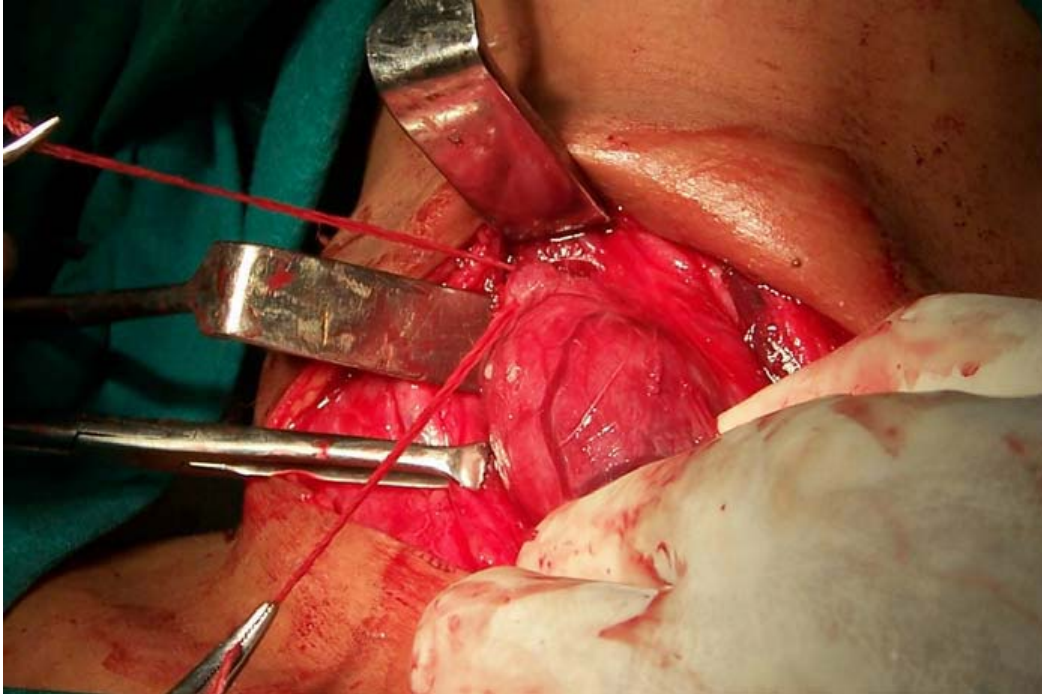
- Wound infection, Hypertrophic or Keloid Scar, Stitch granuloma



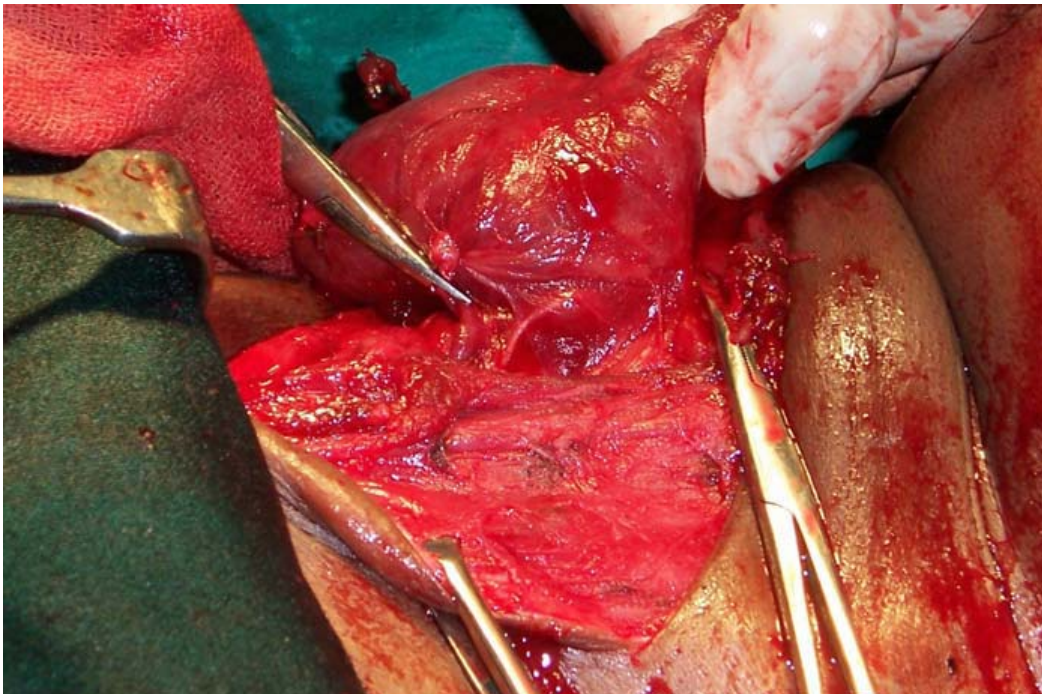
**EXPOSURE OF PRETRACHEAL FASCIA IN FRONT OF THYROID**



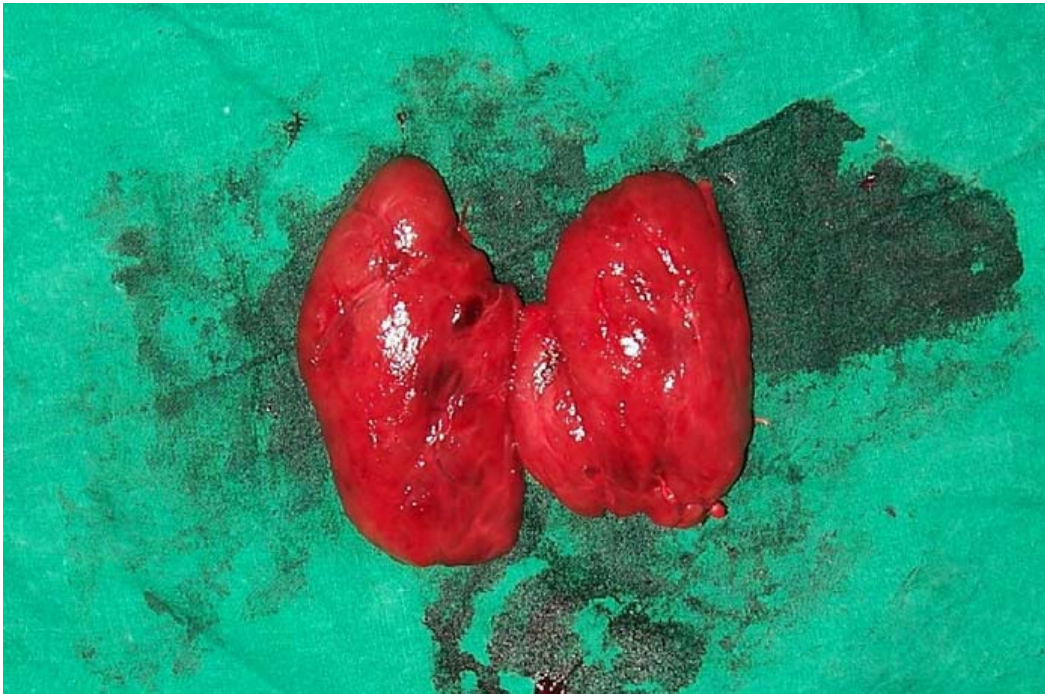**RETRACTING STRAP MUSCLES AND EXPOSING LOBES OF THYROID**



**LIGATION OF SUPERIOR PEDICLE**



**IDENTIFYING RECURRENT LARYNGEAL NERVE**



**TOTAL THYROIDECTOMY-SPECIMEN**

## **MATERIALS AND METHODS**

The material of the present study consists of patients admitted with nodular thyroid swelling from July 2010 to August 2012 at the surgical units of Government Royapettah hospital, Kilpauk medical college. Totally, 50 patients were admitted and treated during this period. Among these, 43 patients were female, and remaining 7 were males. After admission, a detailed history was taken and thorough clinical examination was carried out which was entered in the proforma. The patients were investigated. The investigations included Haemoglobin percentage, urine analysis, blood sugar estimation, blood urea estimation, blood grouping and Rh typing, serum cholesterol, x-ray of the neck-AP and lateral views and chest X-ray and ENT examination. All patients had a Thyroid profile and FNAC done. These patients underwent surgery and all the excised thyroid specimen were sent for histopathological examination. Patients were discharged after removing the sutures and were asked to come for follow up. Post-operative thyroid profile was done on 1st post-operative week and at 1 month. They were advised to take the needful medications accordingly. Only those patients with clinical evidence of multinodular goitre were taken up for the study randomly, excluding malignancies detected preoperatively and the results were compared with other studies.

For all patients whose HPE – Reported as benign were treated with replacement dose of thyroxine and followed up. For one case whose HPE come as malignancy was treated with suppressive dose of thyroxine and followed up with thyroglobulin measurement and radioactive iodine scan.



## **OBSERVATION**

Period of Study: July 2010 to August 2012.

Total Number of cases: 50

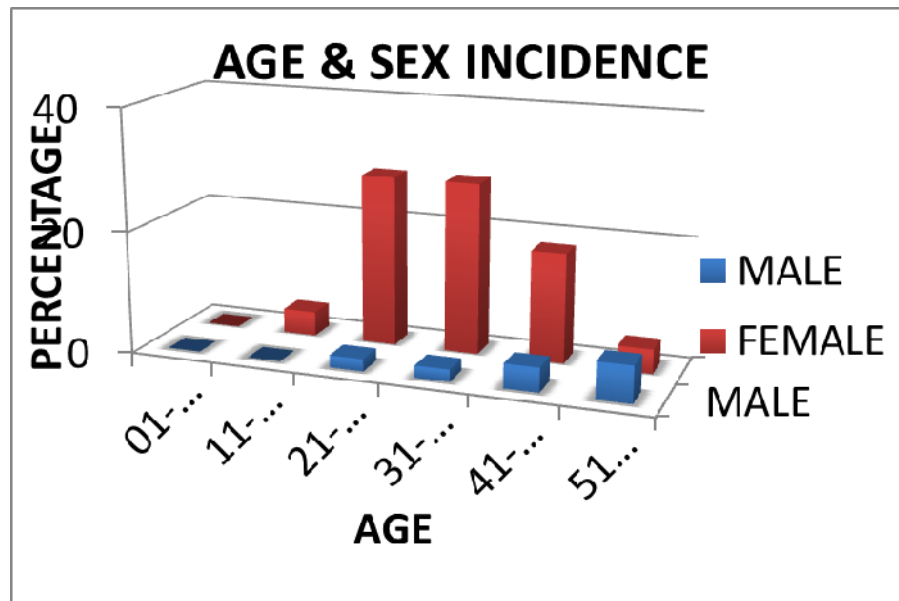
Age group: 17 to 60 years

Average age group of Patient: 35 years.

**TABLE 1**

**AGE AND SEX INCIDENCE**

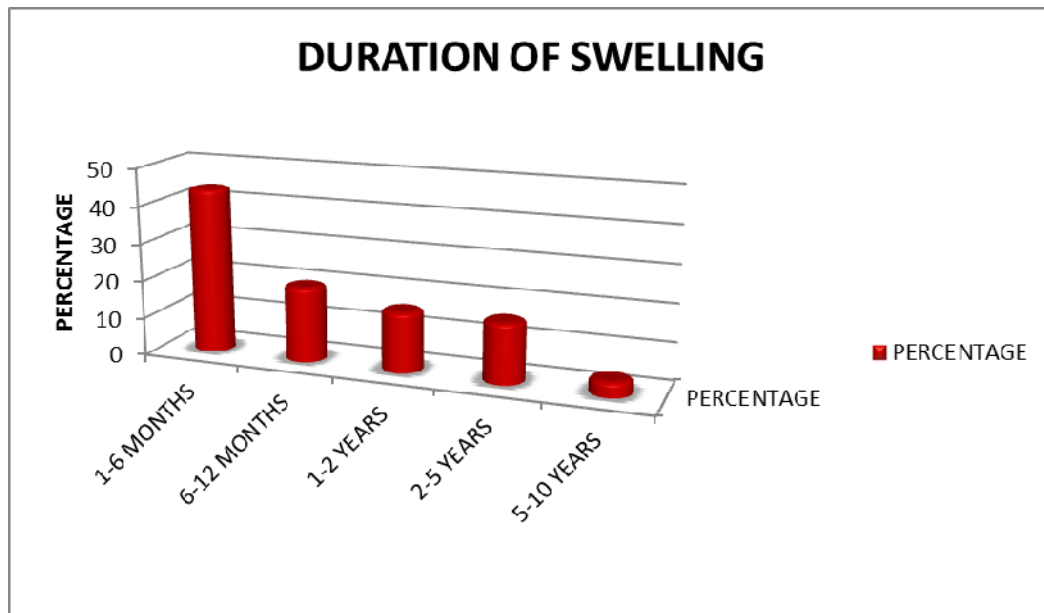
<b>AGE IN YRS</b>	<b>MALE</b>	<b>FEMALE</b>	<b>TOTAL</b>	<b>PERCENTAGE</b>
0-10	00	00	00	00 %
11-20	00	02	02	04%
21-30	01	14	15	30%
31-40	01	14	15	30%
41-50	02	09	11	22%
51 & ABOVE	03	04	07	14%



**TABLE 2**

**DURATION OF SWELLING**

<b>DURATION OF SWELLING</b>	<b>TOTAL NO OF CASES</b>	<b>PERCENTAGE</b>
1-6 MONTHS	22	44 %
6-12 MONTHS	10	20%
1-2 YEARS	8	16%
2-5 YEARS	8	16%
5-10 YEARS	2	4%
TOTAL	50	100%

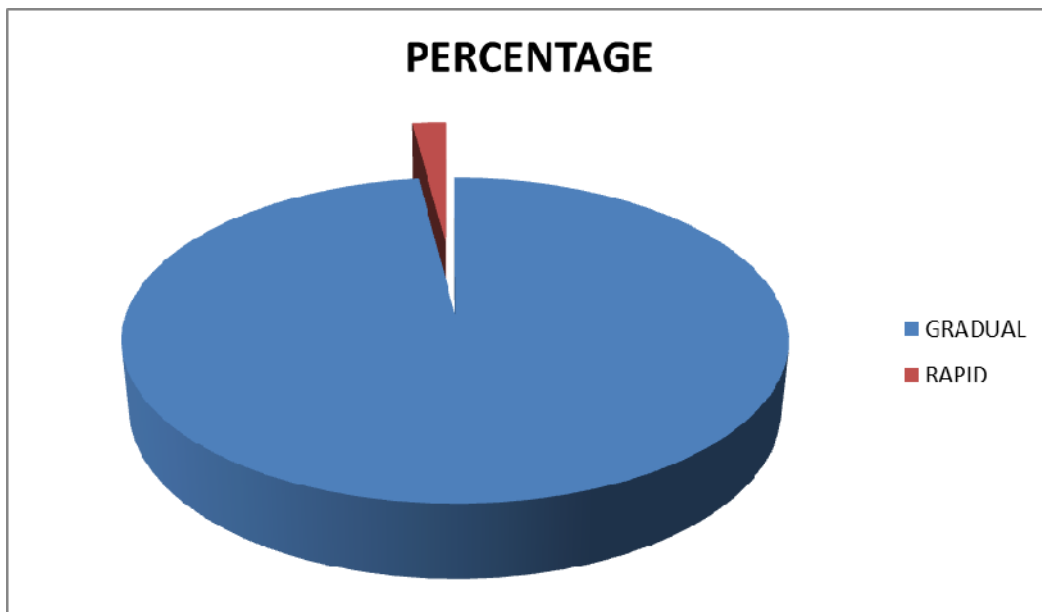


**TABLE 3**

**PROGRESSION OF THYROID SWELLING**

<b>PROGRESSION OF SWELLING</b>	<b>TOTAL NO OF CASES</b>	<b>PERCENTAGE</b>
GRADUAL	49	98%
RAPID	1	2%
TOTAL	50	100%

**PROGRESSION OF SWELLING**

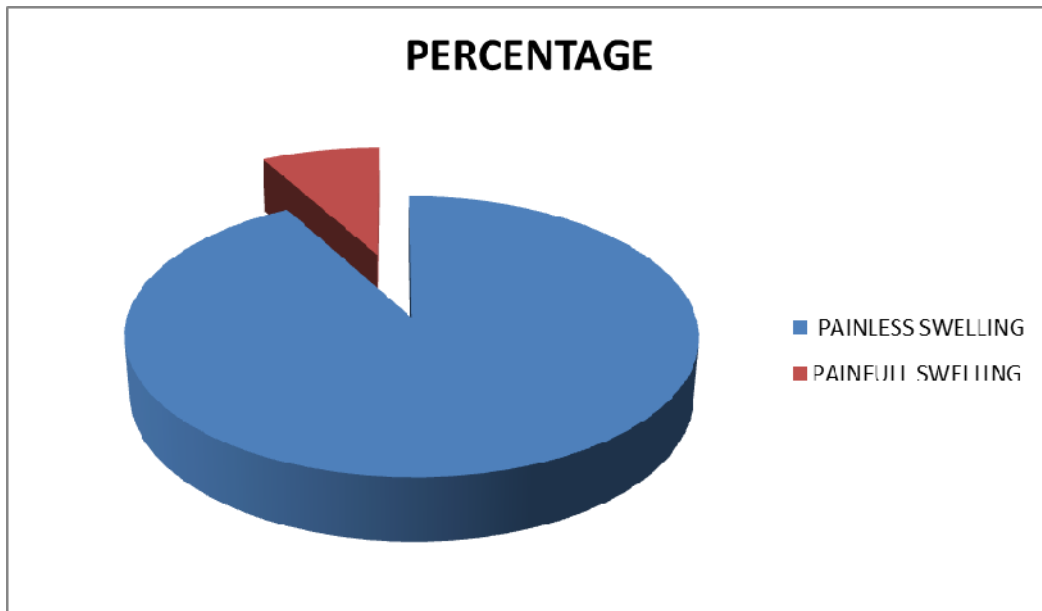


**TABLE 4**

**INCIDENCE OF PAIN IN THYROID SWELLING**

<b>PAIN IN SWELLING</b>	<b>TOTAL NO OF CASES</b>	<b>PERCENTAGE</b>
PAINLESS SWELLING	46	92%
PAINFULL SWELLING	4	8%
TOTAL	50	100%

**INCIDENCE OF PAIN**

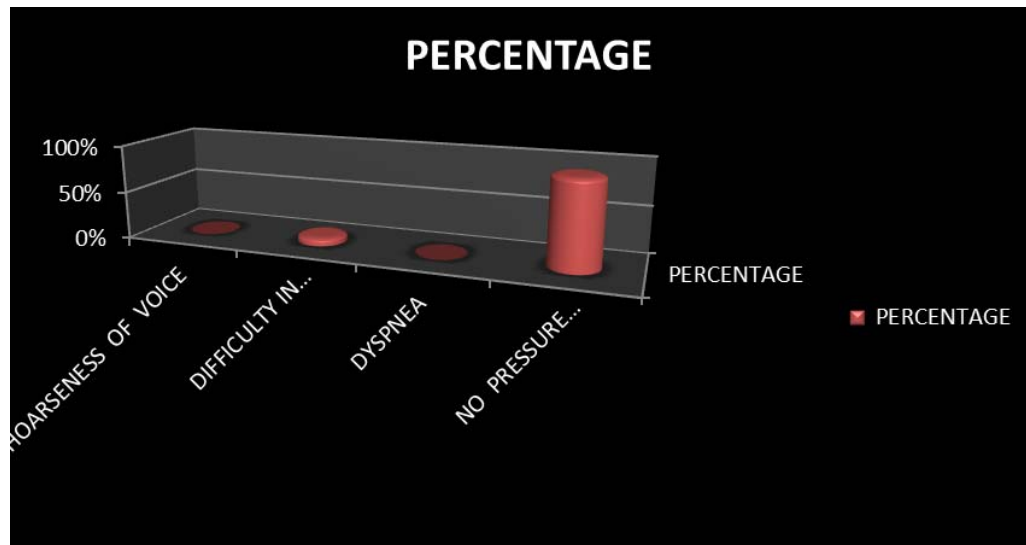


**TABLE 5**

**INCIDENCE OF PRESSURE SYMPTOMS**

<b>SYMPTOMS</b>	<b>TOTAL NO OF CASES</b>	<b>PERCENTAGE</b>
Pressure symptoms		
a)hoarseness of voice	0	00%
b)difficulty in swallowing	4	08%
c)dypsnea	0	00%
No pressure symptoms	46	92%
TOTAL	50	100%

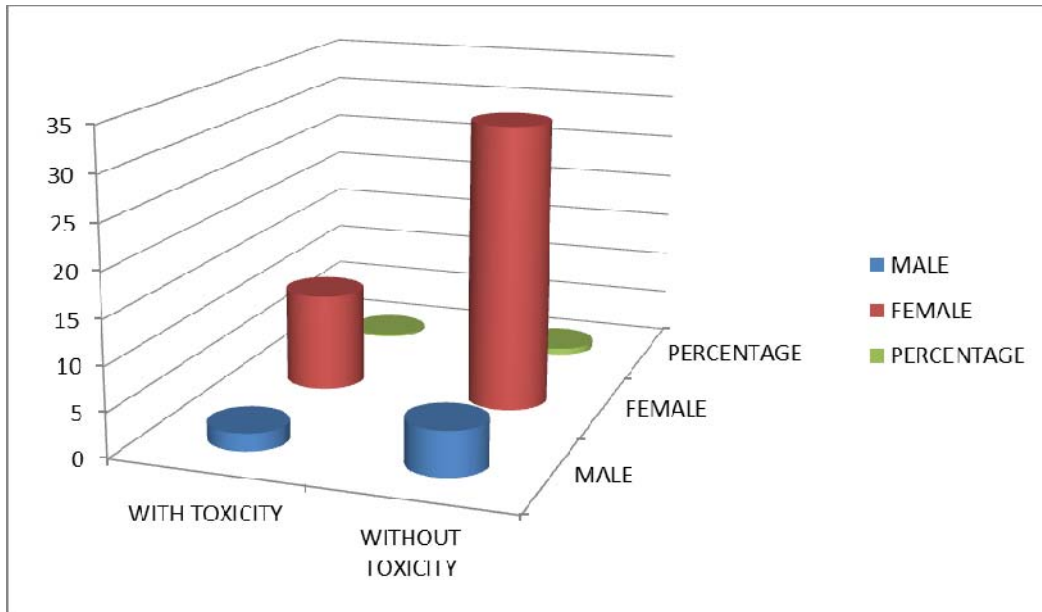
**PRESSURE SYMPTOMS**



**TABLE 6**  
**INCIDENCE OF TOXICITY**

<b>TOXICITY</b>	<b>MALE</b>	<b>FEMALE</b>	<b>TOTAL</b>	<b>PERCENTAGE</b>
With toxicity	2	11	13	26%
Without toxicity	5	32	37	74%

**INCIDENCE OF TOXICITY**



**TABLE 7**

**SITUATION OF LOWER BORDER OF THYROID SWELLING**

<b>LOWER BORDER</b>	<b>TOTAL NO OF CASES</b>	<b>PERCENTAGE</b>
Lower border seen	50	100%
Lower border not seen	00	00%

**TABLE 8**

**INCIDENCE OF TRACHEAL SHIFT**

<b>TRACHEAL POSITION</b>	<b>TOTAL NO OF CASES</b>	<b>PERCENTAGE</b>
Trachea central	48	96%
Trachea shifted to right	2	4%
Trachea shifted to left	0	00%
Total	50	100%

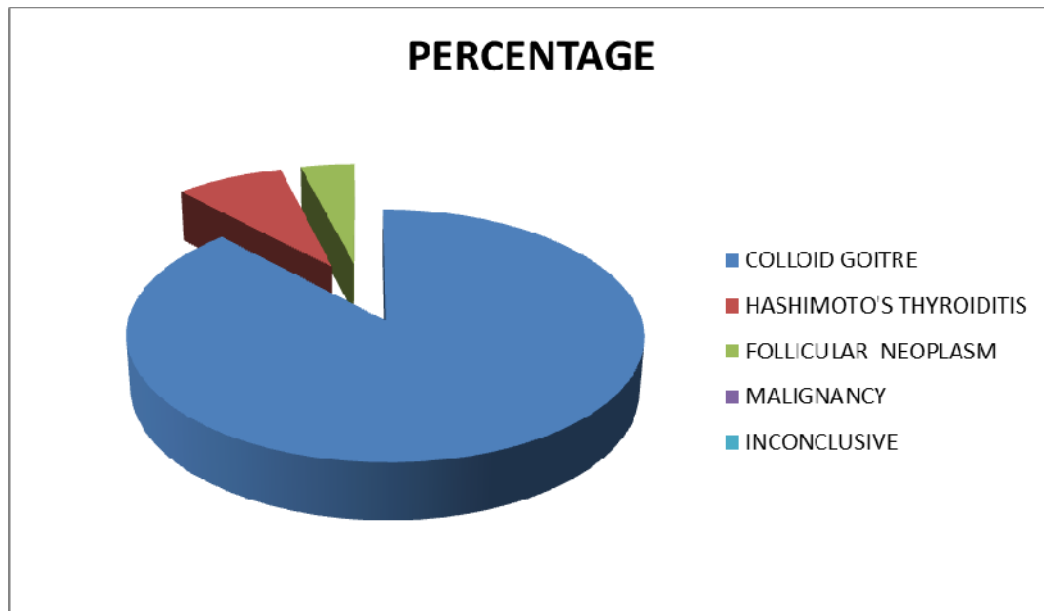


**TABLE 9**

**FNAC OF THYROID SWELLING**

<b>FNAC - REPORT</b>	<b>TOTAL NO OF CASES</b>	<b>PERCENTAGE</b>
Colloid goitre	44	88%
Hashimoto's thyroiditis	4	8%
Follicular neoplasm	2	4%
Malignancy	00	00%
In conclusive	00	00%
<b>TOTAL</b>	<b>50</b>	<b>100%</b>

**FNAC- THYROID**

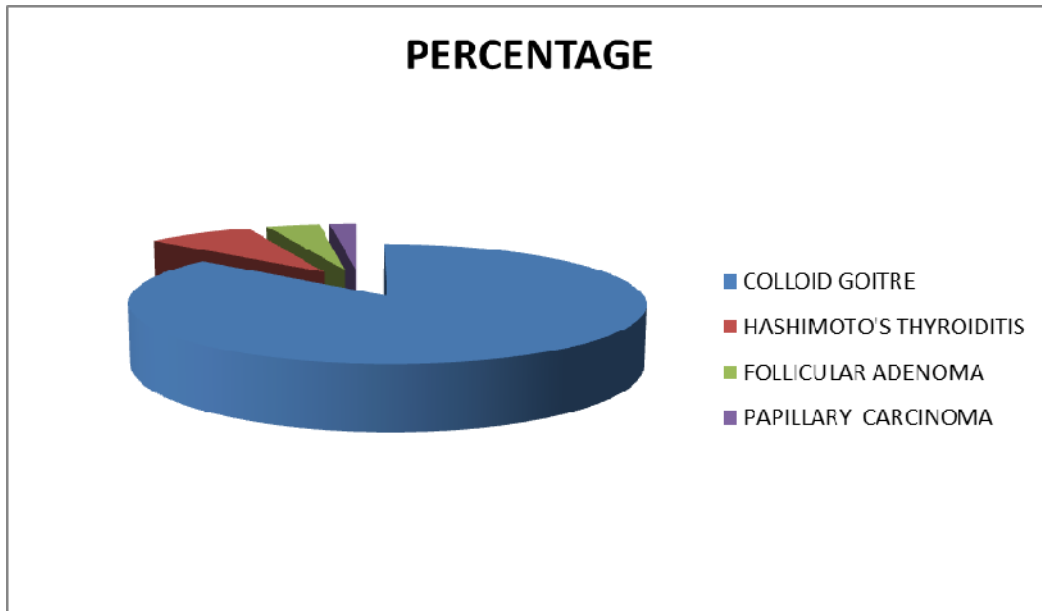


**TABLE 10**

**HISTOPATHOLOGY(HPE) OF THYROIDECTOMY SPECIMEN**

<b>HPE REPORT</b>	<b>TOTAL NO OF CASES</b>	<b>PERCENTAGE</b>
Colloid goitre	43	86%
Hashimoto's thyroiditis	4	8%
Follicular adenoma	2	4%
Papillary carcinoma	1	2%
TOTAL	50	100%

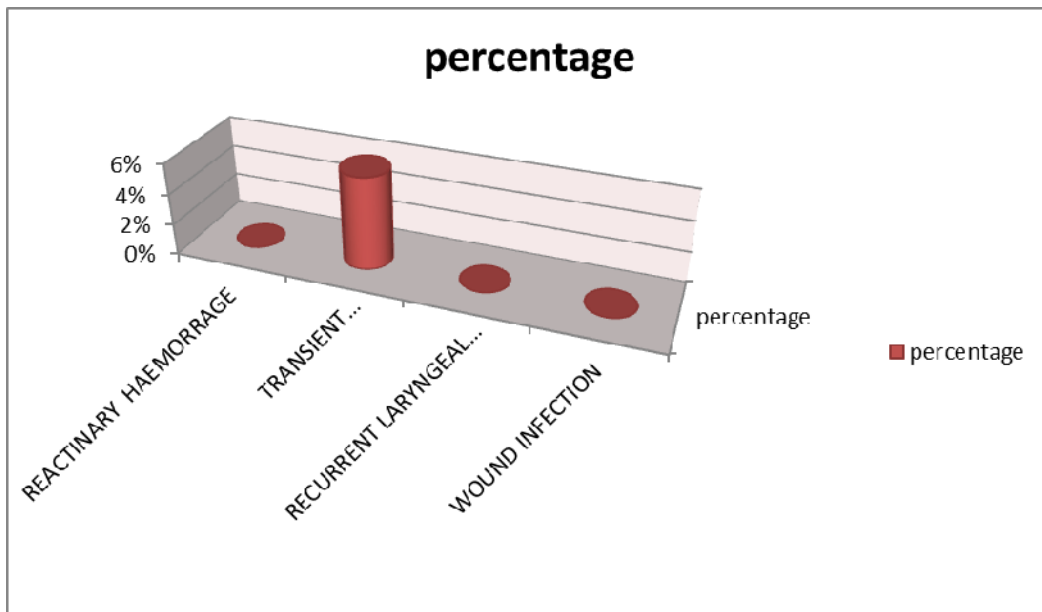
**HPE OF THYROID SPECIMEN**



**TABLE 11**  
**COMPLICATIONS OF THYROID SURGERY**

COMPLICATIONS	TOTAL NO OF CASES	PERCENTAGE
Reactionary haemorrhage	00	00%
Transient hypoparathyroidism	3	6%
Recurrent laryngeal nerve palsy	00	00%
Wound infection	00	00%

**COMPLICATIONS OF SURGERY**



## DISCUSSION

Fifty patients presenting with multinodularity of the thyroid gland without obvious evidence of malignancy were studied and evaluated in terms of history, clinical examination and subjected for relevant investigations, taken up for surgery with prior FNAC and histopathology of operated specimen done post operatively. The results were analysed as depicted in the table 1 to table 12. Of the fifty cases studied, 7 were males (14 %) and 43 were females (86%) with a female to male ratio of 6:1. Antonio Rios et al (2004) showed that 89% were females. In the study conducted in King George Hospital in Vishakapatnam, female to male ratio was 5:1. Table 1 shows the age and sex distribution of the patients studied. 42.8% (3 cases) of the males presented in the age group of 51 years and above. Whereas among females 14 cases presented in the age group of 21 – 30 and 14 female cases in the age group of 31 – 40 years . Majority of the females 56 %, (28 cases) presented in the age group between 21 – 40 years. But in the western literature quoted by “Bremer and Moll Night” in analysis of 1280 cases of multinodular goitre, the age incidence was maximum between 40 – 49 years. Hence the average age incidence in our study is low compared to western series. In our study maximum age of presentation was 57 years and minimum age was 17

years with an average age incidence of 35 Years. During our study period, totally 90 thyroid surgeries were done for various diseases of the thyroid. Multinodular goiter was the commonest indication for surgery with 50 cases. The Chief complaint in our patients (100 %) was swelling in front of the neck. However few patients had associated local symptoms like difficulty in swallowing. Duration of swelling ranged from 1 month to 10 years and 96% (48 cases) were seen in the range of 1 month to 5 years. The size of the swelling increased gradually in 49cases (98%), rapidly in 1 case (2%). The case, which showed rapid increase in size, was not malignant, and did not give rise to any pressure symptoms. Most of the swellings – 46 cases (92%) were not associated with pain and only 4 cases (8%) had pain. Pressure symptoms were seen in 8% (4 cases) as against 29% in Antonio rios et al (2004) study. In our study 4 cases (8 %) presented with difficulty in swallowing. Thus difficulty in swallowing was the commonest pressure symptom. Toxic symptoms and signs were seen in 13 cases (26 %), which included 11 female (22%) and 2 males (4%). Among these 2 female patients had eye signs and 11 patients had tremors of hands and tongues, and tachycardia. Toxic symptoms were seen in 49% of cases in Antonio Rios et al (2004) study.

All thyroid swellings in our study were moving with deglutition. Both lobes were involved in 50 cases. In majority of the patients the size the gland was in stage 2 according to WHO classification i.e. swelling visible with neck in normal position. The clinical features of the nodule were not helpful in the diagnosis of malignancy. There was no correlation between the consistency, duration and size of the nodules and malignancy.

X-ray of neck, AP and lateral views and X-ray of the chest were done in all the cases. There was one case of tracheal shift to right side due to a goitre, mainly involving left lobe of the thyroid. FNAC of the thyroid was done in all the cases and the results compared with histopathological report of operated specimen. Two cases of follicular neoplasms came as follicular adenoma on histopathology. Diagnosis of Follicular carcinoma preoperatively by FNAC was not possible as angioinvasion and capsular invasion, which are features of Follicular carcinoma, were not evident. This shows that FNAC is not 100% accurate in the diagnosis of follicular carcinoma.

The advantages of FNAC are:

1. It is safe and fairly accurate method for establishing whether MNG is a benign or malignant. Surgery can be avoided in many patients with benign disease.

2. Complications of FNAC are negligible and patient acceptance is high.
3. It requires no anaesthesia.

The disadvantages of FNAC are:

1. It is not 100% accurate.
2. It cannot distinguish between benign from malignant follicular neoplasms.

We had 4 cases of MNG with thyroiditis and were operated. The two cases of follicular neoplasms were operated to rule out follicular carcinoma. Total thyroidectomy was done for all 50 cases. In our study postoperative complications were very few. Transient hypoparathyroidism was seen in 3 patients (6%) which was observed during the first post-operative week and all recovered completely with oral calcium and I.V. calcium therapy. There was no permanent hypoparathyroidism. T.A. Day et al (2003) shows that there was 28% of temporary hypocalcemia and 0.9% with permanent hypocalcemia. There was no mortality in our series.

## **SUMMARY AND CONCLUSIONS**

Fifty patients of MNG were evaluated with respect to age, sex, duration of swelling and were investigated with FNAC. Operated specimen subjected to histopathological examination and results were analysed.

1. MNG is the commonest thyroid disease in our hospital.
2. Multinodular goiter is more common in females (Female to male ratio 6:1) majority are in the age group of 21-40 years (56%).
3. The chief complaint in majority of the patients is swelling in front of the neck and few patients with pressure symptoms.
4. In majority (90%) of the patients, duration of the swelling prior to presentation was 6 months to 5 years.
5. Secondary thyrotoxicosis is seen in 26% (13 cases)
6. FNAC is very useful in the diagnosis and management of MNG.
7. Malignancy can still come as a surprise on post-operative histopathological examination, even when there is no suspicion of malignancy clinically and with FNAC.



8. The main indications of surgery in MNG are secondary thyrotoxicosis, risk of MNG turning into malignancy, pressure effect symptoms and cosmetic problem.
9. Total thyroidectomy is the surgery of choice for MNG.

## **BIBLIOGRAPHY**

1. Jameson L. Chassin. Operative Strategy in General Surgery, 2nd edition 1996; pp 796-811.
2. Fielding H. Garrison. An Introduction to History of Medicine, 4th edition, WB Saunders Company; 1960 pp 554-563, 695, 729, 730-872.
3. John B. Hanks. Thyroid Chapter 32, Sabiston Textbook of Surgery, 16th edition. Townsend Jr. et al. Harcourt Asia Pvt. Ltd, India 2001, pp 603-628.
4. Sing Inderbir. Human Embryology. The Pharyngeal Arches. Chapter 9, 6th edition, McMillan India Ltd., 1996, pp 119-122.
5. Decker Gag, Plessus D. J. Du; The thyroid Thymus and parathyroid glands Chapter 17, Lee Mc Gregors Synopsis of Surgical Anatomy; 10th edition, Verghese Publishing House, Bombay, India 1995; pp 198-205.
6. Dyson Mary, Endocrine system – Thyroid gland, Chapter 15, Williams Peter L et al. Gray's Anatomy. 38th edition Churchill Livingstone London, UK 2000, pp 1891-1897.
7. Ellis Herald. The Head and Neck, Parts of Clinical Anatomy; 9th edition, Blackwell Science, UK 1997; pp 284-287.
8. Sinnathambi Chummy S. Head and Neck and Spine. Chapter 6, Lasts Anatomy, 10th edition, Churchill Living stone, London UK 1999, PP 330-332.

9. Williams A.C et al. Thyroid cancer in 1330 cases of sporadic goitre. *Am J Surg*, 1962; 104: 672-676.
10. Guyton Arthur C., Hall John. The Thyroid Metabolic Hormones, Chapter 76, Textbook of Medical Physiology, 10th edition, Harcourt Asia Pvt. Ltd. India, 2001; pp 858-868.
11. Goud G. A. et al. Complications arising in course of Thyroidectomy. *Arch Surg* 1965; 90: 81-85.
12. Ganang William F. The Thyroid Gland, Chapter 18, Review of Medical Physiology, 8th Edition, Prentice Hall International Inc., USA 1987; pp 296-311.
13. Sterling. Thyroid hormone action at cell. *N Engl J Med* 1979; 300: 117, 173.
14. Boydwillium. Textbook of Pathology. Thyroid Chapter 37, 8th edition, Henry Kimpink, London UK 1970, pp 1065-1089.
15. Cotron Ramzi S. et al. The endocrine system thyroid gland; Chapter 25, Robins pathological bases of disease, 5th edition WB Saunders Company 1994; pp 1121-1142.
16. Krukwski Zymunt H. The Thyroid and Thyroglossal Duct. Chapter 44, Russel RCG et al; Bailey and Love's Short Practice of Surgery, 24th edition, Nick Downton London UK 2004; pp 776-804.
17. Sturniolo Givvanni et al. The recurrent laryngeal nerve related to thyroid surgery. *Am J Surg*, June 1999; 177: 485-488.

18. Sokal JE, The problem of malignancy in nodular goitre, *JAMA*, 1959; 170: pp 405.
19. Sokal JE, Incidence of malignancy in toxic and nontoxic nodular goitre. *JAMA*, 1954; 154: 1321-1325.
20. Das Somen. Examination of thyroid gland Chapter 27, Manual of Clinical Surgery, 5th edition, Dr. S. Das, Calcutta, India pp 284-297.
21. Lumley, John S.P. The thyroid and parathyroids. Chapter 17, Hamilton Baileys Physical Signs. 18th edition, Butterworth Heinemann, Oxford UK 1997, pp 223-226.
22. Matheson M. A. Diagnosis of Thyroid Swelling. Recent Advances in Surgery, Russel RCG. Vol 12, Churchill Livingstone, UK 1986; PP 179-197.
23. Tabacqchali MA et al, Thyroid aspiration cytology in New Castle: A six-year cytology/Histology correlation study. *Ann R Coll Surg Eng*, 2000; 82: 149-155.
24. Serralva M et al. Fine needle aspiration cytology of the thyroid gland nodules. A review of 849 cases. *Br J Surg*, June 1997; 84 (Suppl 2): pp 53.
25. Park K. Park's Textbook of Preventive and Social Medicine. Health programmes in India. Chapter 7, M/s. Banarsidas Bhanot, 7th edition, pp 313.

26. Hasleh Christopher et al. Endocrine Disease, Chapter 8, Davidson's Principles and Practice of Medicine, 18th edition, Harcourt Publishers Ltd, UK 1999; pp 559-575.
27. Farwell Alan P., Braverman Lewis C. Thyroid and Anti-thyroid drugs, Chapter 56, Goodman Gillman's 9th edition, Hardman Joel G, Limbird Lee E. Mc Graw Hill, New York, USA 1996, pp 1383-1410.
28. Jerry A. Day, Angela Chu and Khanh Geinhuang. Disorders of Thyroid. The larynologic Clin NA, America, WB Saunders Company Vol. 36, PP 50.
29. Wheeler Malcolm. Thyroid Surgery and recurrent laryngeal nerve Cardiff *BJS* 1999, 291-292.
30. Pandya Sonal, Sanders Lara E. *Am J Surg*, Feb 1998; 175: pp 155-157.
31. Bhansali S. K. Surgery of thyroid gland. *I J Surg*, 1985; 47 (5): 217-228.
32. Johnstone J. M. S. et al Neck mastoid and salivary glands. Chapter 1, Farquarson's Textbook of Operative surgery, 8th Edition, Rintous RF Churchill Livingstone, UK 1995, pp 303-313.
33. Bergiamaschi Robert et al. Morbidity of thyroid surgery. *Am J Surg*, July 1988; 176: 71-75.

34. LO Chang Yau et al. A prospective study of recurrent laryngeal nerve paralysis during Thyroidectomy. *Arch Surg*, Feb 2000; 135: pp 204-207.
35. Tabacqchali MA et al, Thyroid aspiration cytology in New Castle: A six-year cytology/Histology correlation study. *Ann R Coll Surg Eng*, 2000; 82: 149-155.
36. Wheeler Malcolm. Thyroid Surgery and recurrent laryngeal nerve Cardiff *BJS* 1999, 291-292.
37. Williams A.C et al. Thyroid cancer in 1330 cases of sporadic goitre. *Am J Surg*, 1962; 104: 672-676.

# ANNEXURES

## LIST OF ABBREVIATIONS USED

AEIA	--	Amplified enzyme linked immunoassay
CT	--	Computerised tomography
DIT	--	Di iodotyrosine
DMSA	--	Di mercapto succinic acid
FNAC	--	Fine needle aspiration cytology
FT <sub>4</sub>	--	Free thyroxine
FT <sub>3</sub>	--	Free tri iodothyronine
FT <sub>4</sub> I	--	Free thyroxine index
FT <sub>3</sub> I	--	Free tri iodothyronine index
HPE	--	Histopathological examination
IRMA	--	Immuno radiometric assay
LATS	--	Long acting thyroid stimulators
MNG	--	Multinodular goiter
MIT	--	Mono iodo tyrosine
NMRI	--	Nuclear magnetic resonance imaging
PAS	--	Para amino salicylic acid
PBI	--	Protein bound iodine
RAIU	--	Radioactive iodine uptake

RSG	--	Retrosternal goiter
T <sub>4</sub>	--	Thyroxine
T <sub>3</sub>	--	Tri iodo thyronine
TBA	--	Thyroxine binding albumin
TBBA	--	Thyroxine binding pre albumin
TBC	--	Thyroxine binding capacity
T <sub>3</sub> RU	--	Tri iodo thyronine radio iodine uptake
TSH	--	Thyroid stimulating hormone
TRAbs	--	Thyroid receptor antibodies
TRH	--	Thyrotropin releasing hormone
TSAbs	--	Thyroid stimulating antibodies
TSI	--	Thyroid stimulating antibodies
WHO	--	World health organization



## PROFORMA

Name : Age : Sex:

Inpatient No. : Unit/ward: Occupation:

Socioeconomic status :

Address :

Date of Admission :

Date of operation :

Date of Discharge :

Presenting complaints :

1. Swelling in the thyroid region/ duration/ progress.
2. Pain in the swelling.
3. Difficulty in swallowing and breathing.
4. Change in voice.
5. Other symptoms.
6. Toxic symptoms.
  - a) Anxiety/ nervousness.
  - b) Dyspnoea
  - c) Sweating

- d) Intolerance to heat/ cold
- e) Palpitation
- f) Weight loss
- g) Diarrhea
- h) Increase/ decrease of appetite
- i) Menstrual disturbances- menorrhagea/ oligomenorrhea

History of present illness:

Onset    Duration

Progress    Size

Pain    Fever

Dyspnoea    Dysphagia

Change in voice    Symptoms of hyper/hypo features

Any other symptoms

Past history:

1. Whether from endemic area
2. Ingestion of goitrogenic food materials
3. Ingestion of goitrogenic or ATT drugs
4. Irradiation of neck
5. Others.

Family history:

1. History of thyroid swelling in the family.
2. Marital status and children.
3. Diabetes/ hypertension/ malignancies.

Personal history:

1. Diet
2. Appetite
3. Sleep
4. Bowel/ bladder
5. Habits

Treatment history:

History of taking anti thyroid drugs/ thyroxine/ oral contraceptives/ surgery.

General physical examination:

1. Appearance ( anxious, ill etc)
2. Build/ nourishment
3. Anemia
4. Generalized lymphadenopathy
5. Hands – warm/ moist/ cold
6. Tremors – hands/ tongue
7. Vital signs - pulse

- BP

- temperature

- respiratory rate

8. Sleeping pulse rate

9. Eye signs

Local examination:

1. Inspection:

Site of the swelling

Size/ shape/ surface/ extension.

Skin over the swelling/ veins/ pulsations

Borders

Movement with deglutition

2. Palpation:

Site/ size/ shape/ surface/ extension / confirmation of inspectory

findings

Borders

Mobility/ plane/ thrill/ fluctuation/ transillumination/ lower border

Tenderness/ consistency/ local rise of temperature

Palpation of carotid pulsations

Tracheal position

Regional lymph nodes

3. Percussion:

Over manubrium steni for retrosternal extension.

#### 4. Auscultation:

For bruit/ murmurs over the gland.

Examination of other systems:

Cardiovascular system, Respiratory system, Central nervous system ,

Per abdominal examination, Examination for eye signs .

Clinical diagnosis:

Investigations:

HB Blood grouping and cross matching

TC Blood urea

DC Serum creatinine

ESR Serum cholesterol

Blood sugars Serum calcium

Urine routine Thyroid profile- T3, T4, TSH , Chest x ray

Neck x ray- AP and lateral view

ECG , Indirect laryngoscopy , FNAC

Final diagnosis:

Pre operative management:

(Drugs to control toxicity if present/ diabetes mellitus/ hypertension/ heart diseases etc.)

Surgery performed and operative findings:

Post operative complications and their management:

Histopathology report of the excised specimen:

Follow up:

## **KEY TO MASTER CHART**

Age –Age in years, M –Male, F -Female

Mn - Months , D – Days, DIB - Difficulty in breathing

DIS - Difficulty in swallowing, A - Absent, P - Present

N – Normal, C - Central , BL - Both lobes equally involved

IDL - Indirect laryngoscopy, T3 - Tri iodothyronine , T4 - Thyroxine

TSH - Thyroid stimulating hormone

↑ - Increased, ↓ – Decreased

CG - Colloid goiter, HT- Hashimotos thyroiditis

FN - Follicular neoplasm, FA - Follicular adenoma

P CA - Papillary carcinoma, FNAC - Fine needle aspiration cytology,

TT - Total thyroidectomy, MNG - Multinodular goiter

HPE - Histopathological examination report

## MASTER CHART

PARTICULARS OF PATIENT				CLINICAL FEATURES							INVESTIGATIONS										FOLLOW UP
S no	Name	Age/S ex	Ip no	duration	Pa in	D I B	DI S	Change in voice	Lobes involv ed	Toxic featu res	Tracheal position	T3	T4	TS H	I D L	FNAC	Surgery	Complicatio ns	HPE	Post op IDL	
1	Selvi	28/f	975143	5 mn	A	A	A	A	BL	A	C	N	N	N	N	CG	TT	A	CG	N	
2	kamala	32/f	976214	8mn	A	A	A	A	BL	A	C	N	N	N	N	CG	TT	A	CG	N	
3	Eswari	26/f	977153	1yr	A	A	A	A	BL	A	C	N	N	N	N	CG	TT	A	CG	N	
4	Danam	31/f	976853	3mn	A	A	A	A	BL	A	C	N	N	N	N	CG	TT	A	CG	N	
5	Rajeswari	34/f	977134	2mn	A	A	A	A	BL	P	C	↑	↑	↓	N	CG	TT	TETANY	CG	N	
6	Mallika	25/f	978563	6mn	A	A	A	A	BL	A	C	N	N	N	N	CG	TT	A	CG	N	
7	Vani	40/f	978667	7mn	A	A	A	A	BL	A	C	N	N	N	N	CG	TT	A	CG	N	
8	Logeswari	29/f	976859	9mn	A	A	A	A	BL	P	C	↑	↑	↓	N	FN	TT	A	FA	N	
9	Sembagam	23/f	979873	3mn	P	A	A	A	BL	A	C	N	N	N	N	HT	TT	A	CG	N	
10	Kumar	24/m	978123	5mn	A	A	A	A	BL	A	C	N	N	N	N	CG	TT	A	CG	N	
11	Kavipriya	35/f	979811	3yr	A	A	A	A	BL	P	C	↑	↑	↓	N	CG	TT	A	CG	N	
12	Vimala	37/f	976524	4yr	A	A	A	A	BL	A	C	N	N	N	N	CG	TT	A	CG	N	
13	Jeeva	28/f	977568	4mn	P	A	A	A	BL	P	C	↑	↑	↓	N	HT	TT	A	CG	N	
14	Anbarasi	34/f	976541	6mn	A	A	A	A	BL	A	C	N	N	N	N	CG	TT	A	CG	N	
15	Kaliammal	29/f	978975	7mn	A	A	A	A	BL	A	C	N	N	N	N	CG	TT	A	CG	N	
16	Thamarai	32/f	987532	10mn	A	A	A	A	BL	P	C	↑	↑	↓	N	FN	TT	A	FA	N	
17	Muniammal	38/f	987521	5mn	A	A	A	A	BL	A	C	N	N	N	N	CG	TT	A	CG	N	
18	Chitra	40/f	988641	2mn	A	A	A	A	BL	A	C	N	N	N	N	CG	TT	A	P CA	N	
19	Karpagam	27/f	986123	3mn	A	A	A	A	BL	A	C	N	N	N	N	CG	TT	A	CG	N	
20	Saraswathi	25/f	985126	2mn	A	A	A	A	BL	P	C	↑	↑	↓	N	CG	TT	TETANY	CG	N	
21	pushpa	34/f	988651	5mn	A	A	A	A	BL	A	C	N	N	N	N	CG	TT	A	CG	N	
22	Jothi	31/f	987641	1.5yr	A	A	A	A	BL	A	C	N	N	N	N	CG	TT	A	CG	N	
23	Geetha	38/f	986872	4mn	A	A	A	A	BL	A	C	N	N	N	N	CG	TT	A	CG	N	
24	Valliammal	33/f	985438	8mn	A	A	A	A	BL	A	C	N	N	N	N	CG	TT	A	CG	N	
25	Moorthi	55/m	987652	9mn	A	A	A	A	BL	A	C	N	N	N	N	CG	TT	A	CG	N	
26	Dinesh	38/m	986421	8mn	A	A	A	A	BL	P	C	↑	↑	↓	N	CG	TT	A	CG	N	
27	Kalaiselvi	52/f	987512	4mn	A	A	A	A	BL	A	C	N	N	N	N	CG	TT	A	CG	N	
28	Arul	43/m	986987	3yr	A	A	A	A	BL	P	C	↑	↑	↓	N	CG	TT	A	CG	N	
29	Saroja	26/f	985731	3mn	A	A	A	A	BL	A	C	N	N	N	N	CG	TT	A	CG	N	



PARTICULARS OF PATIENT				CLINICAL FEATURES							INVESTIGATIONS										FOLLOW UP
S no	Name	Age/S ex	Ip no	duration	Pa in	D I B	DI S	Change in voice	Lobes involv ed	Toxic featu res	Tracheal position	T3	T4	TS H	I D L	FNAC	Surgery	Complicatio ns	HPE	Post op IDL	
30	Renuka	25/f	985762	5mn	A	A	A	A	BL	P	C	↑	↑	↓	N	CG	TT	A	CG	N	
31	Aarthi	29/f	989123	2mn	A	A	A	A	BL	A	C	N	N	N	N	CG	TT	A	CG	N	
32	Jebasharun	27/f	985743	3mn	A	A	A	A	BL	A	C	N	N	N	N	CG	TT	A	CG	N	
33	Janani	55/f	989431	6yr	A	A	P	A	BL	A	C	N	N	N	N	CG	TT	A	CG	N	
34	Anand	52/m	989534	4yr	A	A	A	A	BL	A	C	N	N	N	N	CG	TT	A	CG	N	
35	Lavanya	58/f	989438	8mn	A	A	A	A	BL	A	C	N	N	N	N	CG	TT	A	CG	N	
36	Rengasamy	46/m	987421	7yr	A	A	P	A	BL	A	R	N	N	N	N	CG	TT	A	CG	N	
37	Gayathri	19/f	986589	3mn	A	A	A	A	BL	A	C	N	N	N	N	CG	TT	A	CG	N	
38	Bhuvaneshwari	17/f	992732	5mn	P	A	A	A	BL	A	C	N	N	N	N	HT	TT	A	CG	N	
39	Noorjahan	42/f	993421	7mn	A	A	A	A	BL	A	C	N	N	N	N	CG	TT	A	CG	N	
40	Elumalai	57/m	994562	3.5yr	A	A	A	A	BL	A	C	N	N	N	N	CG	TT	A	CG	N	
41	Lalitha	49/f	995671	4yr	A	A	P	A	L	A	R	N	N	N	N	CG	TT	A	CG	N	
42	Sarasu	45/f	992871	1yr	A	A	A	A	L	A	C	N	N	N	N	CG	TT	A	CG	N	
43	Shamili	46/f	995648	1.5yr	A	A	A	A	BL	A	C	N	N	N	N	CG	TT	TETANY	CG	N	
44	Ellammal	44/f	996731	2yr	A	A	A	A	BL	A	C	N	N	N	N	CG	TT	A	CG	N	
45	Uma	43/f	102431	3yr	A	A	P	A	BL	P	C	↑	↑	↓	N	CG	TT	A	CG	N	
46	Bharathi	48/f	103482	5yr	A	A	A	A	BL	A	C	N	N	N	N	CG	TT	A	CG	N	
47	Kumari	49/f	104531	2yr	A	A	A	A	L	A	C	N	N	N	N	CG	TT	A	CG	N	
48	Ponni	41/f	102465	1yr	A	A	A	A	BL	A	C	N	N	N	N	CG	TT	A	CG	N	
49	Lakhsmi	53/f	101743	2yr	A	A	A	A	L	A	C	N	N	N	N	CG	TT	A	CG	N	
50	kanimozhi	29/f	108794	3mn	P	A	A	A	BL	P	C	↑	↑	↓	N	HT	TT	A	CG	N	