THE TAMIL NADU
DR.M.G.R. MEDICAL UNIVERSITY
CHENNAI

INDICIDENCE OF MALIGNANCIES IN THYRODIECTOMISED PATIENTS FOR MULTINODULAR GOITRE

A DISSERTATION SUBMITTED FOR

BRANCH – I M.S.(GENERAL SURGERY)

March 2010

ACKNOWLEDGEMENT

It gives the great pleasure to acknowledge those who guided, encouraged and supported in the successful completion of my study.

Foremost I wish to express my sincere gratitude to my unit chief, **Prof. Dr. D. Soundararajan M.S.,** Additional Professor, Dept of Surgery for his valuable support and continued guidance, encouragement throughout the study and for allowing me to utilize the clinical materials for this study.

I express my sincere thank to **Prof.Dr.M.Gopinath M.S,** Head of Department of Surgery for his initiative and guidance to conduct the study.

I wish to thank my Assistant professors **Dr.S.P.Ramanathan M.S., D.N.B., Dr.V.Selvaraj M.S., D.C.H., Dr. K. Saravanan M.S., Dr.S.Shanthi Nirmala M.S., DGO.,** for their valuable guidance and support.

I sincerely thank all unit chiefs and **Assistant Professors,** Department of surgery for their co-operation in allowing me to do my study.

I owe my sincere thanks to all my beloved patients for their kind co-operation inspite of their suffering in completing this study.

Department of Surgery,
Madurai Medical College and
Government Rajaji Hospital
Madurai

Madurai – 20

CERTIFICATE

That is to certify **"INCIDENCE OF MALIGNANCIES IN THYROIDECTOMISED PATIENTS FOR MULTINODULAR GOITRE"** submitted by **Dr.S.GOPINATHAN** to the faculty of General surgery, The Tamil Nadu Dr.M.G.R. Medical University, Chennai in partial fulfillment of the requirement for the award of M.S. Degree in General Surgery is a bonafide work carried out by him during the period May 2007 to Oct 2009 under my direct supervision and guidance.

Professor and Head of the Department of surgery,
Madurai Medical College,
Madurai.

DECLARATION

I, DR.S.GOPINATHAN solemnly declare that the dissertation titled **"INCIDENCE OF MALIGNANCIES IN THYROIDECTOMISED PATIENTS FOR MULTINODULAR GOITRE"** has been prepared by me.

This is submitted to The Tamil Nadu Dr. M.G.R. Medical University, Chennai, in partial fulfillment of the requirement for the requirement for the award of **M.S. Degree in General Surgery** to be held in March 2010.

Place : Madurai **DR.S.GOPINATHAN**

Date :

CONTENTS

INTRODUCTION

Thyroid is the largest and most easily accessible gland. Enlargement of thyroid gland (goitre) is common problem and attracted the attention of surgeons and provides a great deal of work and interest for them.

Multinodular goitre is the subject of interest in this work is an important and difficult problem to approach since wide variety of pathological condition including carcinoma present as multi nodular goitre.

MNG is a benign disorder affects mainly women. The incidence of occult malignancy in MNG varies from 4-17% careful definitive histopathology of the operative specimen is the key for the diagnosis.

The following sections deal with anatomy, physiology pathogenesis of MNG, pathology of various type of carcinoma of thyroid and incidence of carcinoma in MNG who under went total thyroidectomy, based on HPE findings.

AIM OF STUDY

To find out incidence of malignancies in thyroidectomised patient for multinodular goitre based on HPE findings.

HISTORICAL ASPECTS

The thyroid gland, previously referred to as the ‘laryngeal gland’, was so named by Wharton in 1646, because of either its own shield like shape (thyreoeides means shield shaped) or the shape of the thyroid cartilage, with which it is closely associated.

Classical description of hyperthyroidism or exopththalmic goitre were presented by Parry (1825), Graves (1835) and Von Basedow (1840). Hypothyroidism or myxoedema was described by Curling and Gull (1875).

Schiff in the middle of the nineteenth century conducted experiments demonstrating the importance of thyroid gland.

In 1882 Reverdin produced experimental myxoedema by total or partial thyroidectomy. In 1890 Murray and Howitz successfully treated myxoedema with thyroid extract.

Theoder Kocher, who is regarded as the Father of Thyroid Surgery, performed thyroidectomy operations in the late 1800’s over 2000 with only a 4.5 percent mortality. He also described “Cachexia strumapriva” i.e., myxoedema, which he noted as a sequelae in 30 of his 100 thyroidectomies.

In 1909 Nobel prize was awarded to Theodor Kocher for his pioneering efforts in the field of thyroid surgery.

The first successful transplantation of thyroid was reported by Payr in 1906 who transplanted a portion of the gland from a woman into spleen of a myxoedematous daughter with successful rates.

Isolation of thyroxine hormone was accomplished by Kendall in 1914. Medullary carcinoma of thyroid was first described by J.Hazard et al in 1959.

As a resident J.Sipple was asked to see a patient with hypertensive is after Neurosurgical operation. But the patient died. At the autopsy J.Sipple found large bilateral peochromocytomas, thyroid tumors and an

parathyroid gland (MEN II A).

In 1962 D.Copp et al described calcitonin as a new hormone that lowered the blood calcium. They thought calcitonin was secreted from the parathyroid, but 2 years later, it was shown that parafollicular cells (C cells) of the thyroid were the origin of this hormone.

In 1968 E.D.Williams and his group suggested that C cells were origin of Medullary carcinoma thyroid.

EMBRYOLOGY

Begins its development from the fourth week of intra uterinelife. Hormones start secreting from twelfth week.

The thyroid gland develops as an endodermal tubular structure the posterior aspect of the fetal tongue in the region of foramen caecum and grows downwards in front of the developing hyoid and larynx. Primordial cells from the neural crest migrate ventrally and incorporated within the ultimo branchial body. The main body of thyroid is joined by para lateral component pouches, which form the “C” cells.

Diagrammatic representation of Embryology of the thyroid gland.

Diagrammatic view of sagittal (A) and transverse (B) views of the pharyngeal regions of a human embryo during the fifth week of gestation, showing the endodermal pharyngeal pouches and mesodermal pharyngcal

arches. Diagrams show the show the embryonic origin of the thyroid gland. Migration of the thyroid gland (anterior view) is shown in ©. Diagram (D) illustrates various abnormalities which can occur during embryonic development. Each diagram is not drawn to relative scale.

EMBRYOLOGY OF THYROID

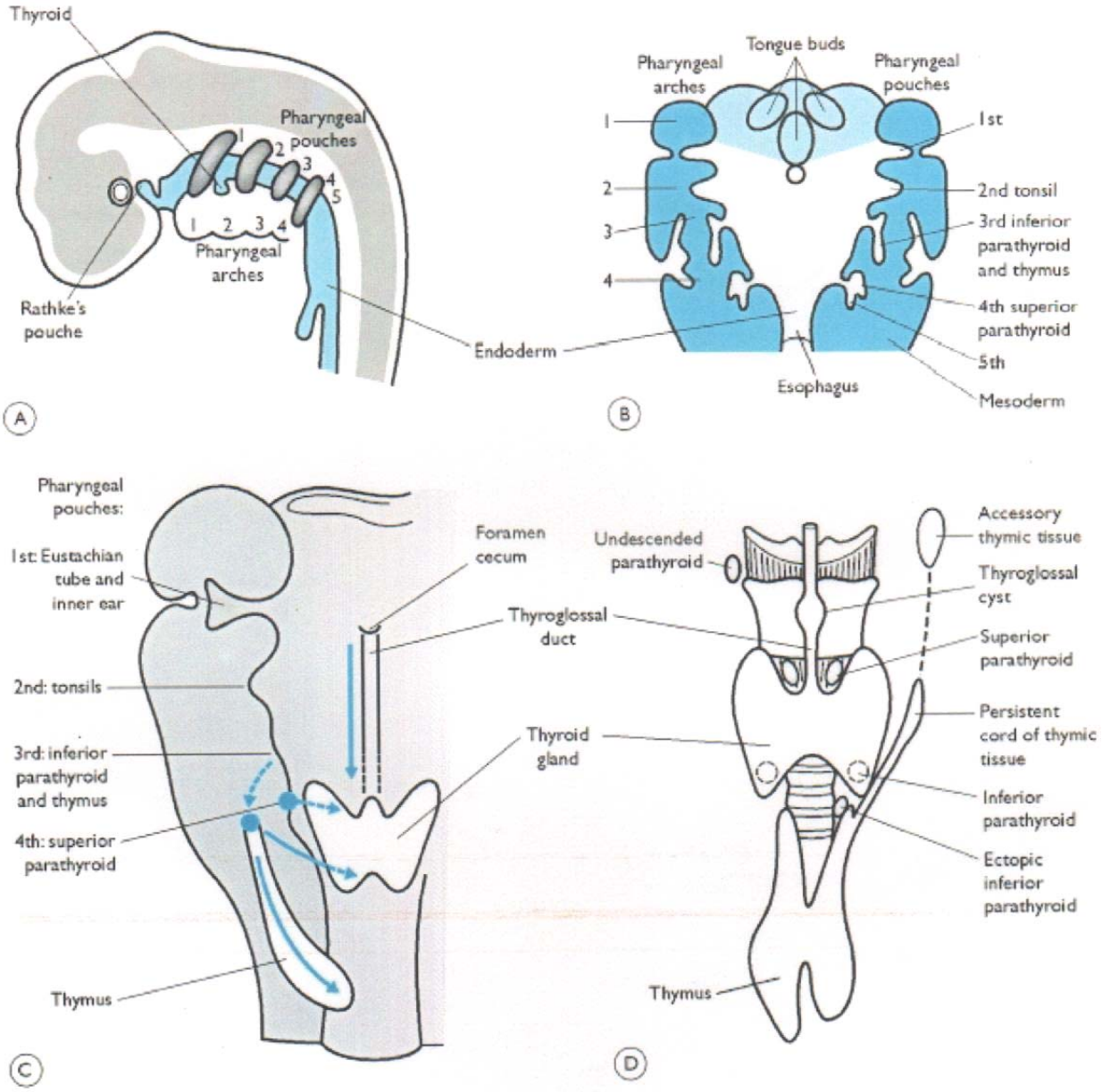

SURGICAL ANATOMY

The thyroid is a brownish-red and highly vascular gland located anteriorly in the lower neck, extending from the level of the fifth cervical vertebra down to the first thoracic. The gland varies from an H to a U shape and is formed by 2 elongated lateral lobes with superior and inferior poles connected by a median isthmus (with an average height of 12-15 mm) overlying the second to fourth tracheal rings. The isthmus is encountered during routine tracheotomy and must be retracted (superiorly or inferiorly) or divided. Occasionally, the isthmus is absent, and the gland exists as 2 distinct lobes. Each lobe is 50-60 mm long, with the superior poles diverging laterally at the level of the oblique lines on the laminae of the thyroid cartilage. The lower poles diverge laterally at the level of the fifth tracheal cartilage. Thyroid weight varies but averages 25-30 g in adults (slightly heavier in women). The gland enlarges during menstruation and pregnancy.

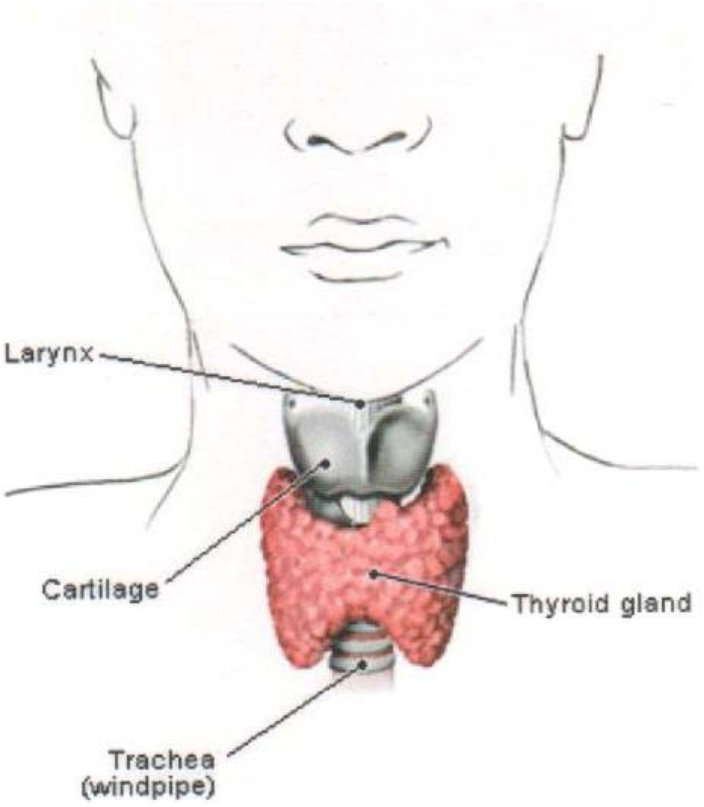

A conical pyramidal lobe often ascends from the isthmus or the adjacent part of either lobe (more often the left) toward the hyoid bone, to which it may be attached by a fibrous or fibromuscular band, the levator of the thyroid gland. Remnants of the thyroglossal duct may persist as accessory nodules or cysts of thyroid tissue between the isthmus and the foramen caccum of the tongue base.

Usually, 2 pairs of parathyroid glands lie in proximity to the thyroid gland.

STRUCTURE

Under the middle layer of deep cervical fascia, the thyroid has an true capsule, which is thin and adheres closely to the gland. Extensions of this capsule within the substance of the gland form numerous septae, which divide it into lobes and lobules The lobules are composed of follicles, the structural units of the gland, consisting of a of simple epithelium enclosing a colloid-filled cavity. This colloid (pink on hematoxylin and eosin [H&E] stain) contains an iodinated glycoprotein, iodothyroglobulin, a precursor of thyroid hormones. Follicles vary in size, depending upon the degree of distention, and they are surrounded by dense plexuses of fenestrated capillaries, lymphatic vessels and sympathetic nerves.

Epithelial cells are of 2 types:

Principal cells (ie, follicular) and parafollicular cells (ie, C, clear, cells). Principal cells are responsible for formation of the colloid (iodothyroglobulin), whereas parafollicular cells produce the hormone calcitonin, a protein central to calcium homeostasis. Parafollicular cells lie adjacent to the follicles within the basal lamina.

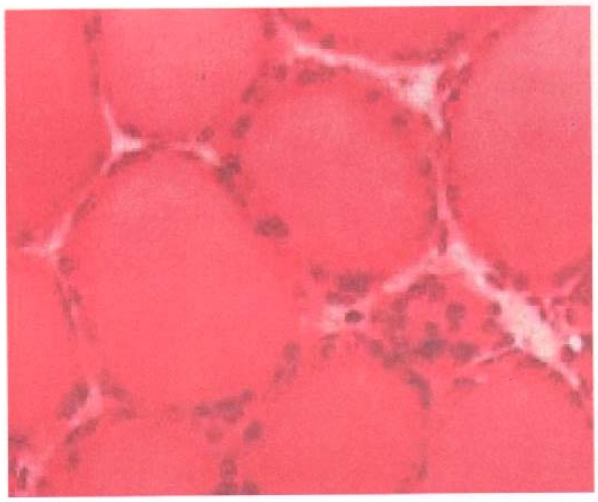

FASCIA AND LIGAMENT:

The thyroid gland is ensheathed by the visceral fascia, a division of the layer of deep cervical fascia, which attaches it firmly to the laryngoskeleton. The anterior suspensory ligament extends from the medial aspect of each thyroid lobe to the cricoid and thyroid cartilage. The posteromedial aspect of the gland is attached to the side of the cricoid cartilage, first and second tracheal ring, by the posterior suspensory ligament (ie, Berry ligament).

The firm attachment of the gland to the laryngoskeletion is responsible for movement of the thyroid gland and related structures during swallowing. On its way to the larynx, the recurrent laryngeal nerve usually passes deep to the Berry ligament or between the main ligament and its lateral leaf. Deep to the ligament, but lateral to the nerve, is a posteromedial portion of the thyroid lobe, which may be overlooked during thyroidectomy.

RELATION WITH STRAP MUSCLES

The lateral surface of the thyroid is covered by the sternothyroid muscle, and its attachment to the oblique line of the thyroid cartilage the superior pole from extending superiorly under the thyrohyoid muscle. More anteriorly are the sternohyoid and superior belly omohyoid muscle, overlapped inferiorly by the anterior border of sternocleidomastoid muscle. The sternohyoid and sternohyroid are joined in the midline by an avascular fascia that must be retract the strap muscle laterally in order to access the thyroid awing thyroidectomy. If strap muscles are to be transected for exposure, do so high in the neck because the motor nerve supply from the ansa cervicalis enters these muscles inferiorly.

VASCULAR ANATOMY AND RELATION WITH LARYNGEAL INNERVATION

The arterial supply to the thyroid gland comes from the superior and inferior thyroid arteries and, occasionally, the thyroidea ima. These arteries have abundant collateral anastomoses with each other, both ipsilaterally and contralaterally. The thyroid ima is a single vessel, which orginates. when present, from the aortic arch or the innominate artery and enters the thyroid gland at the inferior border of the isthmus.

Superior thyroid artery and superior laryngeal nerve

The superior thyroid artery is the first anterior branch of the external carotid artery. In rare cases, it may arise from the common artery just before its bifurcation. The superior thyroid artery descends laterally to the larynx under the cover of the omohyoid and sternohyoid muscles. The artery runs superficially on the anterior border lateral lobe, sending a branch deep into the gland before curving the isthmus where it anastomoses with the contralateral artery.

Distribution of thyroid arteries with associated laryngeal nerve, anterior view

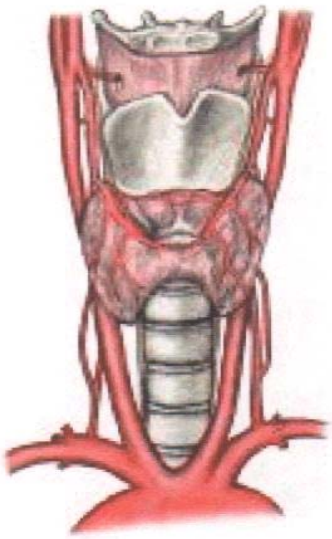

Cephalad to the superior pole, the external branch of the superior laryngcal nerve runs with the superior thyroid artery before turning medially to supply the cricothyroid muscle. High ligation of the superior thyroid artery during thyroidectomy places this nerve at risk of inadvertent injury, which would produce dysphonia by altering pitch regultion. The cricothyroid artery is a potentially bothersome branch of superior thyroid artery, which runs cephalad to the upper pole and runs toward the midline on the cricothyroid ligament. This vessel can be during lacerated emergent cricothyroidotomy.

Inferior thyroid artery and recurrent laryngeal nerve

The inferior thyroid artery arises from the thyrocervical trunk, a branch of the subclavian artery. It ascends vertically and then curves medially to enter the tracheoesophageal groove in a plane posterior to the carotid sheath. Most of its branches penetrate the posterior aspect of the lateral lobe. The inferior thyroid artery has a variable branching pattern is closely associated with the recurrent laryngeal nerve. The latter ascends in the tracheoesophageal groove and enters the larynx between the inferior cornu of the thyroid cartilage and the arch of the cricoid. The recurrent laryngeal nerve can be found after it emerges from superior thoracic outlet, in a triangle bounded laterally by the common carotid artery, medially by the trachea, and superiorly by the thyroid lobe.

Distribution of thyroid arteries with associated laryngeal nerve posterior view

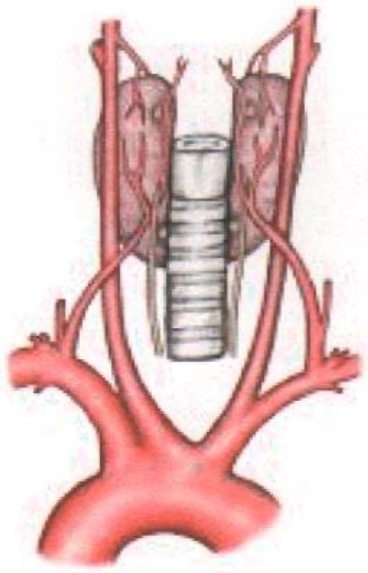

The relationship between the nerve and the inferior thyroid artery is highly, as demonstrated by the classic work of Reed, who in 1943 described 28 variations in this relationship. The nerve can be found deep to the inferior thyroid artery (40%), superficially (20%), or between branches of the artery (35%). Significantly, the relationship between nerve and artery on one side of the neck is similar to that found on the other side in only 17% of the population. Furthermore, at the level of the inferior thyroid artery, branches

of the recurrent laryngeal nerve that are extralaryngeal may be present (5%). Preservation of all those branches is important during thyroidectomy.

Another hint to the location of the recurrent laryngeal nerve is the Zuckerkandl tubercle, an extension of the thyroid, close to the Berry ligament. On rare occasions, the recurrent laryngeal nerve may pass directly from the vagus to the larynx, close to the superior thyroid vessels. This formation is nearly always observed on the right side and is associated with a retroesophageal subclavian artery. This formation can occur on the left side in cases of transposition of the great vessels. The anatomy and innervation of the larynx is discussed more precisely elsewhere in this journal.

VENOUS DRAINAGE

Three pairs of veins provide venous drainage to the thyroid gland. The superior thyroid vein ascends along the superior thyroid artery and becomes a tributary of the internal jugular vein. The middle thyroid vein follows a direct course laterally to the internal jugular vein. The inferior thyroid veins follow different paths on each side. The right passes anterior to the innominate artery to the right brachiocephalic vein or anterior to the trachea to the left

brachiocephalic vein. On the left side, drainage is to the left brachiocephalic vein. Occasionally, both inferior veins form a common trunk called the thyroid ima vein, which empties into the left brachiocephalic vein.

Distribution of thyroid veins

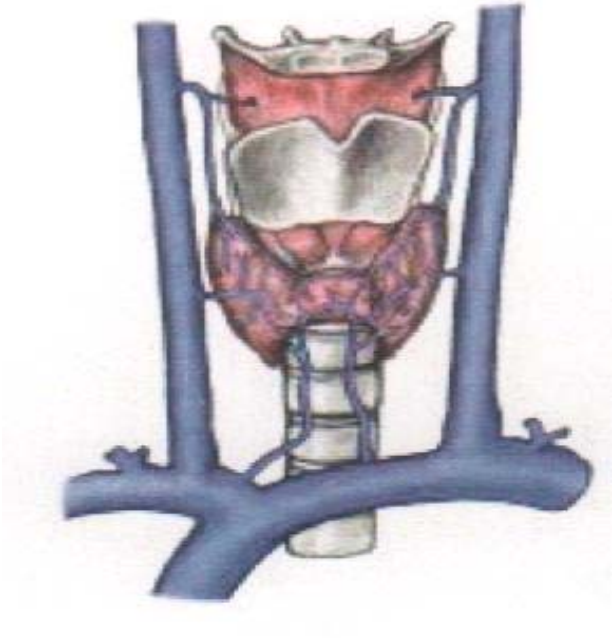

LYMPHATICS

Lymphatic drainage of the thyroid gland is extensive and flows multidirectionally. Immediate lymphatic drainage courses to the periglandular nodes, to the prelaryngeal (Delphian), pretracheal, and

paratracheal nodes along the recurrent laryngeal nerve, and then to mediastinal lymph nodes. Regional metastases of thyroid carcinoma can also be found laterally, higher in the neck along the internal jugular vein. This can be explained by tumor invasion.

INNERVATION OF THE THYROID

Principal innervation of the thyroid gland derives from the autonomic nervous system. Parasympathetic fibers come from the vagus nerves, and sympathetic fibers are distributed from the superior, middle, and inferior ganglia of the sympathetic trunk. These small nerves enter the gland along with the blood vessels. Autonomic nervous regulation of the glandular secretion is not clearly understood, but most of the effect is postulated to be on blood vessels, hence the perfusion rates of the glands.

SURGICAL PHYSIOLOGY

The thyroid, largest endocrine gland in the body produces three hormones.

- Thyroxine (T4),
- Tri-iodo thyronine (T3) and
- Calcitonin.

T4 and T3 are both stored in the colloid consisting primarily of thyroglobulin which is an iodinated glycoprotein. Thyroglobulin stores are dependant on adequate dietary iodine intake, which is essential for T4 and T3 synthesis.

Iodine is derived mainly from milk and dairy products with a smaller proportion from salt, water, fish and Iodised salt. Plasma levels of iodine vary widely, depending on geographical locality. Iodides are absorbed in the stomach and the upper gastrointeslinul tract. approximately two-thirds is excreted via kidneys and one-third is trapped in the thyroid where 90 percent of body stores of iodine are found.

The steps in the synthesis of thyroid hormone are:

1. Concentration of Iodides in the gland

2. Rapid oxidation of iodides to iodine by a peroxidase enzyme system

3. The formation of precursor amino acids, a) 3-mono- iodothyronine(MIT) b) 3,5-di-iodothyronine (DIT)

4. The coupling of this inactive iodothyronines to form the hormonally active iodothyronines, Tri-iodothyroninc & Thyroxine. When iodine transport is defective, because of either pharmacologic inhibitors, spontaneous disease, goitre and/or hypothyrodism result.

The hormonally active T4, T3 and iodothyronines are held in peptide linkage with a specific protein, thyroglobulin which forms the major component of intra follicular colloid.

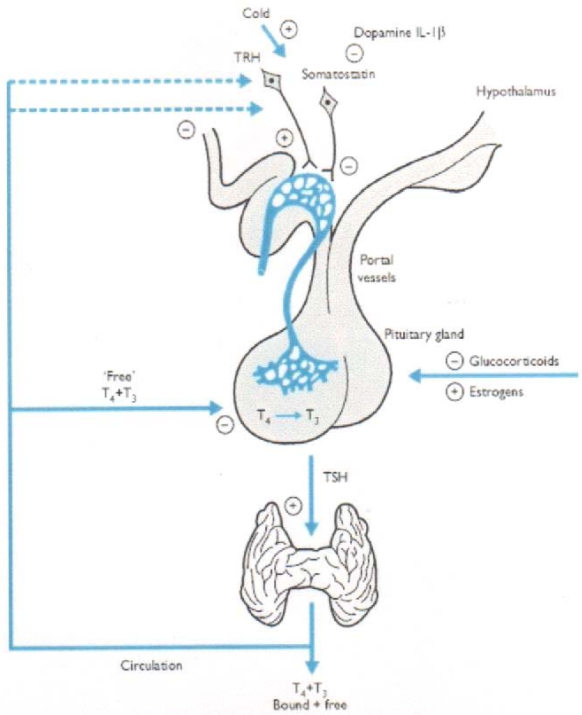

Release of active hormone into circulation involves hydrolysis of the thyroglobulin by proteases and peptidases resulting in T4 and T3. The activity of these enzymes is enhanced by administration of TSH.

Thyroid stimulating hormone produced by the thyrotrophic cells of anterior pituitary control the complex enzymatic reactions that trap iodine, convert it into T4 and T3 and release it into the circulation. When T4 and T3 raises above the normal range, TSH production is shut down by a negative bio-feed back loop.

Release of TSH is regulated by Thyrotrophin Releasing Hormone (TRH) which is produced in the hypothalamus. TRH enters the capillary bed of the stalk median eminence, passing via portal veins and sinusoids to bathe the anteriorpituitary cells. TSH biosynthesis shows a circadian rhythm, its secretion will be maximum in the evening before the onset of sleep, remaining high overnight and falling to a low around mid-day.

The role of calcitonin in normal physiology has not been established in men, bur it may be involved in the regulation of plasma calcium and phosphate metabolism. However, thyroidectomy which removes all parafollicular “C” cells causes no disturbances of calcium homeostasis.

The rise in plasma calcitonin which occurs during pregnancy and lactation appears to have no effect on maternal skeleton but calcium resorption may be prevented by a concomitant increase in the level of circulating cholecalciferol.

PATHOLOGY

The normal thyroid gland is impalpable. The term GOITRE is used to describe generalized enlargement of the thyroid gland.

CLASSIFICATION OF THYROID SWELLINGS:

- SIMPLE GOITRE (EUTHYROID)

Diffhse Hyperplastic (physiological, puberty, pregnancy) Multinodular Goitre

- TOXIC

  Primary

  - Diffuse (Grave's disease)

  Secondary

  - Multinodular

- Toxic Adenoma
- NEOPLASTIC

  Benign

  Malignant

- INFLAMMATORY

Auto immune thyroiditis - Hashimoto's thyroiditis

Granulomatous thyroiditis —De quervian's thyroiditis

Riedel's thyroiditis

- INFECTIVE

  Acute (Bacterial, Viral)

  Chronic (TB, Syphills)

  Sub – acute

- OTHER

  Amyloid

ADENOMA:

Approximately 30 percent of the solitary nodule of thyroid is due to adenoma.

• It’s common in women

• Rarely exceeding 3cm in diameter

• Firm, well defined, smooth swelling

• Encapsulated

• Slow growing

• Commonest site is at the junction of one lobe and the isthmus

• Almost all adenomas are follicular variety

• Rare types are Papillary Cystadenomas, Hurthle cell adenomas

• Microscopically it resembles normal thyroid or may be composed of tightly packed acini or diffuse sheets of epithelial cells, it may contain large colloid filled acini or even be replaced by a single cyst.

• Pressure symptoms may occur, 50 percent of the adenomas are cold nodules and remainder behaves as a normal thyroid or as warm nodule.

CARCINOMA:

Papillary Carcinoma

- Common in adults and children
- Responsible for 80 percent of the thyroid carcinoma occurring below 40years
- More common in women
- It grows slowly, metatstasis to cervical lymph nodes are common
- About 10- 2Opercent may present as only cervical lymph node metastasis. The primary is often occult (Lateral aberrant thyroid). All the lesions below 1.5cm are called as occult.
- Blood spread is unusual
- Prognosis is good, l0 years survival rate is about 70-80 percent.

Histology:

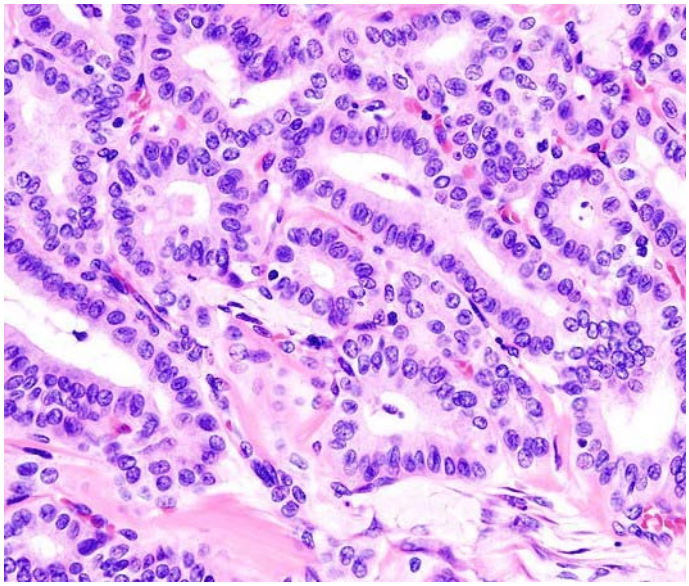

Complicate branching tree like pattern of cells outlined by papilliferous axial fibrovascular stroma. Pale empty nuclei (Orphan annie eyed nuclei) and psammoma bodies are present. Papillary carcinoma is subjected to the influence of pituitary TSH.

Follicular Carcinoma

It's a well differentiated carcinoma of the thyroid but more aggressive than papillary carcinoma. More common in women. Peak incidence occurs in the 5th and 6th decade. Two types of follicular carcinoma are

a) Encapsulated- less common

b) Invasive mass

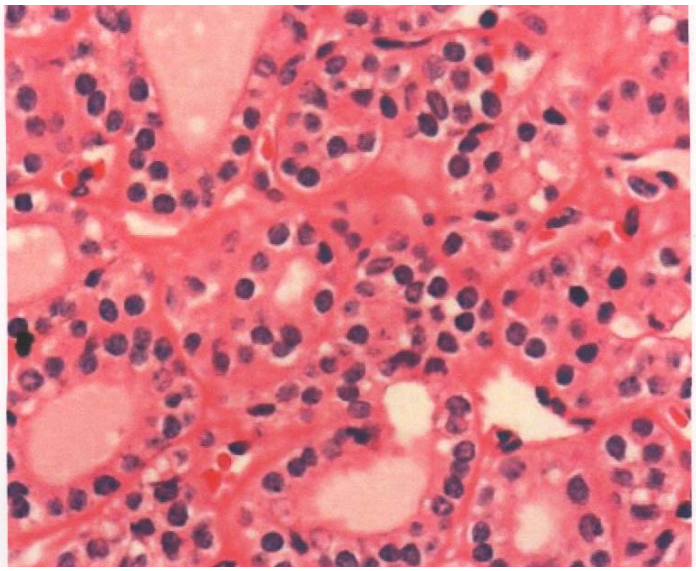

In follicular carcinoma there is invasion of adjacent thyroid parenchyma, blood vessels or capsule with usually uniform cells with absence of nuclear features of papillary carcinoma.

Encapsulated form is called angioinvasive encapsulated carcinoma. Hemorrhages, cystic degeneration and necrosis are common Microscopically, picture is that of adenocarcinoma with considerable change in size and differentiation of glands. Blood spread occurs in 70 percent of cases. Commonest sites are lungs, bones, brain, etc. Regional lymph nodes are involved in only 5percent of cases.

Anaplastic Carcinoma

Usually occurs in 7th and 8th decades of life. It's a rapidly growing, locally infiltrative tumor with very poor prognosis.

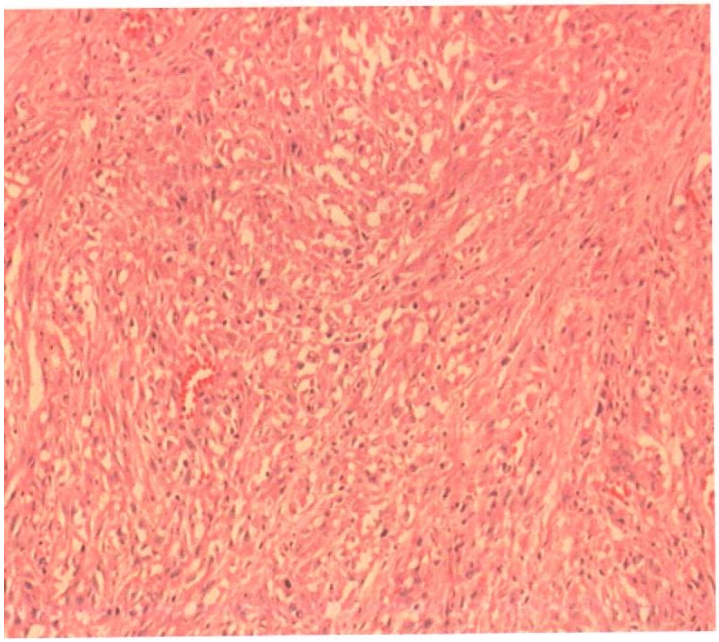

The tumor is solid growing lacking organoid features. Coagulative necrosis is a common finding.

It spreads by lymphatics and by blood stream. Two histological types are small cell carcinoma and giant cell carcinoma. One year survival is about 20 percent.

Medullary Carcinoma

- Derived from parafollicular cells (C Cells). It's an APUDoma. 8Opercent occurs sporadically, usually in adults.
- 10-20percent occurs in children and teenagers with associated symptoms.
- MEN II b: MEN IIa + Mucosal neuroma, marphanoid features, aganglioneurosis.
- 90 percent of patients secrete calcitonin, less frequently histamine, prostaglandins, ACTH and serotonin are secreted.
- It may present as a single nodule or multiple nodules.
- Sporadic forms occur in 5-6 decades, often present in advanced stage. Familial forms present in second decade, associated endocrine abnormalities bring the patient early.

- Diarrhea is present in upto 3Opercent of patients.
- Metastasis is usually to regional nodes (5Opercent), lung, liver and bone.
- Medullary carcinoma is not TSH dependent.
- It does not take Radioiodine.
- Stimulating caicitonin secretion by pentagastrin and calcium infusions can make diagnosis of medullary carcinoma.

MNG

MNG is defined by palpation of nodules in the enlarged thyroid gland (or) nodule in the one lobe of gland with palpable gland on the opposite side.

Pathogenesis

Persistent TSH Stimulation

↓

Diffuse hyperplasia of gland

↓

Later with fluctuation of TSH levels

↓

Mixed areas of active and inactive lobules develop

↓

Active lobules become more vascular and hyperplastic

↓

Haemorhages occur with necrosis in the centre

↓

Nodule Formation

↓

Centre of nodule is inactive and only
Margin is active (i.e.) internodular tissue is active

↓

Formation of many nodules - MNG

Complications

1. Secondary thyrotoxicosis
2. Pressure effects
3. Cosmetic problem
4. Malignant change

Clinical factors

- More common in females
- Age groups Endemic Areas : 20-30 Yrs.

  Sporadic Areas : 30-40 Yrs.
- It is a slow progressive disease with many year of history
- Recent increase in size signifies malignant transformation (or) Haemorrhage.

Treatment

Nodular goiter is a irreversible Stage, so surgery is the treatment of choice.

Treatment options are either near total (or) total thyoidectomy

DIAGNOTIC AIDS

Diagnosing thyroid disease is a process that can incorporate numerous factors, including clinical evaluation, blood tests, imaging tests and biopsies

Clinical Evaluation

A critical part of detecting and diagnosing thyroid disease is the clinical evaluation conducted by a trained practitioner. As a part of a through clinical evaluation, practitioner typically should do the following

Feel (also known a palpating) neck

Test for reflexes

Listen to the thyroid using a stethoscope

Check for heart rate, rhythm and BP

Measure weight, body temp

Examine skin, face, eyes, hair

Thyroid function Tests

There are variety of tests, available to assess the function of thyroid. No single test is diagnostic and therefore a combination of tests are indicated.

Measurement of thyroid Hormones in serum

Total T_4 and T_3 represent total protein bound T_4 and T_3 and are into measurements of free active thyroid hormones. Total T_4 and T_3 are influenced by the Thyroxine binding proteins in the serum. False high levels are seen in pregnancy and those who are taking oral contraceptive pills. False high levels are seen in pregnancy and those who are taking oral contraceptive pills. Falls low values are seen in hypoproteinemic states such as nephritic syndrome. Drugs such as salicylate, pencillin complete with T_3 and T_4 for protein binding. So measurements of free T_3 and T_4 by Radioimmunoassay is specific.

Serum Protein bound Iodine (PBI)

Normal range 3-5.8mg/100ml. It lacks specificity in that it measures non hormonous forms of iodine in the blood. False positive results are seen in pregnancy, persons taking iodides, expectorants containing potassium iodide and in those taking oral contraceptive pills.

Indirect methods of measuring Thyroid hormones

T3 Resin uptake

Patient's serum is incubated with ratio active T3 so that the latter become fixed to unoccupied sites of thyroid binding globulin. Naturally in hyperthyroidism the unoccupied sites are low and in hypothyroidism the unoccupied sites are high. Then a secondary binder, a resin is added to the system. Resin uptake of T3 is more in thyrotoxicosis and low in hypothyroidism. The test serves as indirect measurements of unbound T4 from this free thyroxin index can be calculated.

Free thyroxin index = Serum T4 x T3 uptake %

Measurement of serum TSH

Normal range is upto 5mu/L

Levels over 48mu/L are present in gross thyroid deficiency. The test is invaluable in the early detection of mild degree of hypothyroidism seen after surgery for thyrotoxicosis or after radio iodine. Sensitivity in the range of 0-5mu/L is poor. More accurate assays are now available. Estimation of these low concentration aids the distinction of hyper thyroidism from euthyroidism.

TRH test

When thyroid hormones are high as in hyperthyroidism TSH is suppressed and IV injection of TRH does not result in rise of TSH when thyroid hormones are normal or low, TRH injection increases TSH level.

Serum TSH is estimated at the beginning of the test and again 20 minutes and 60 minutes after injection of 200mg of TRH. In thyrotoxicosis TSH level remains below 2.5 mu/L. in euthyroid TSH level increase just above the basal level. In hypothyroid there is an exaggerated response. This

test is infrequently used but it is useful if thyroid hormones and TSH levels are discrepant, in graves diseases, hypothroidism due to pituitary or hypothalamic diseases.

Radio active iodine uptake test (RAIU)

RAIU indicate rate to thyroid hormone synthesis and release. 5-25 mci of radioiodine I is given orally. Then after 24 hours thyroid content of I is measured by a counter. It is measured after 24 hours because it is convenient to the patient and also the value at 24 hours is usually near it plateau. But in very severe hyperthyroidism, measurement is taken earlier since the uptake and release is rapid.

Increased RAIU

Inference is increased hormones synthesis; causes:

1. Hyperthyroidism (Except T3 toxicosis and increased body iodide)
2. Aberration in hormones synthesis. Eg. ineffectively or inefficiently used iodine.
3. Acute or chronic iodine deficiency.

4. withdrawal of factors that lead to thyroid hormone depletion. Eg.withdrawal of antithyroid drugs, recovery from subacute thyroiditis, withdrawal of exogenous hormones.
5. Compensatory increase in hormone synthesis after hormone loss eg.Nephrosis, chronic diarrhorea, soya beem ingestion.

Decreased RAIU

i. Hypothyroidism
ii. Antithyroid agents
iii. Primary biosynthetic defects of hormones
iv. Hashimoto’s disease
v. Subacute thyroiditis
vi. Exogenous
vii. Increase availability of iodine

External scintiscanning (Thyroid scan)

With appropriate apparatus, isotopically labeled materials, that are differentially accumulated by thyroid issue ca be detected and quantified in situ and the data transformed into a visual display.

Radio isotopes used are 99m TC-per technetate, I131, I125, I123.

99m TC per technetate

Actively concentrated by the thyroid but unlike Iodide undergoes negligible organic binding. Half life is 6 hours. So requires single patients visit. Also it deliveries very low radiation to the thyroid tissue. So it provides information about iodide transport function of thyroid and not about organic binding and retention. Also stay in the thyroid is brief and imaging done early, so that radiation from intravascular sources or from salivary tissues obscure findings. It is inappropriate for metastasis and substernal goitre.

Route: single I.V.Bolus and imaging performed 4-6 hours later. Apparatus used is scintillation camera.

I^{125}

Half life is 60 days. Its low energy emissions preclude scanning from deep sources such as substernal goitre or distant metastasis.

I^{123}

Half life is 13 hours. Radiation to the thyroid tissue is about 1% of that is delivered by I^{131} since there is absence of Beta radiation. So it is the ideal isotope.

I^{131}

Half life 8 days. Useful to find out functioning metastatic lesions of thyroid carcinoma.

Uses of scan

To define areas of increased or decreased function (Hot or cold) relative to the function of the remainder of the gland provided these areas are 1cm of more in diameter. Better visualisation of small nodules can be achieved by oblique or lateral view along with anteroposterior view.

Though majority of non functioning nodules are not malignant, lack of function increases the likelihood of malignancy particularly only one nodule is present. Conversely hot nodules are unlikely to be malignant.

Scintiscans obtained after administration of exogeneous TSH may be useful in documenting the intrinsic functional capability of suppressed thyroid nodules.

Scans performed after exogenous thyroid hormone administration (suppression scans) can reveal autonomous nodules.

They are also useful in detecting retrosternal goiters and ectopic thyroid tissue in the thyroid or ovary.

The most important use is to know metastsis from thyroid carcinoma.

Serum thyroglobulin

Normal value is 10mg/ml. Concentration is higher in females, pregnant woman and newborn.

Elevated levels are found in three thyroid disorders.

1. Those with nontoxic goitre and thyroid hyperfunction
2. thyroid injury and subacute thyroiditis
3. differentiated thyroid tumours

The major clinical use is in the management of differentiated carcinoma. Serum thyroglobulin is increased in both benign conditions and in differentiated carcinoma but it can not differentiate between the two. Following removal of tumours values decreases to normalcy. The residual mass or with metastasis thyroglobulin level increases. So it is a prognostic index rather than a diagnostic tool.

Needle Biopsy

It is a valuable technique for the diagnosis and management of multinodular goitre.

i. Large Bore needle biopsy

In this a core of tissue is removed for histological examination using trucut needle. Even though it yields adequate tissue for histopathological

examination, the disadvantages are pain, haematoma, tracheal damage, recurrent laryngeal nerve palsy. It is now superseded by FNAC.

ii. Fine Needle aspiration biopsy cytology (FNABC)

This technique has been popular in Scandinavia for more than 25 years, but has gained popularity in USA and UK only in recent years.

This has excellent patient compliance, simple and quick to perform in the outpatient department and is readily repeated.

Thyroid conditions that are readily diagnosed by FNAC include colloid nodules, thyroiditis, papillary carcinoma, medullary carcinoma, lymphoma.

FNAC can not distinguish between a benign follicular adenoma and follicular carcinoma as this distinction in dependent not on cytology but on histological criteria which include capsular and vascular invasion.

There has been few false positives with respect to malignancy but there is a definite false negative rte with respect to both benign and malignant neoplasia.

FNAC is les reliable in cystic than in solid swellings often yielding only fluid with macrophages and degenerate cells. After aspiration, further sample is taken from cyst wall.

Taking account of age, sex, cytological appearance on FNAC may increase or decrease the suspicion of malignancy but there is only one certain diagnostic procedure and i.e. excision. Excision entails total lobectomy and isthumectomy. Local excision is absolutely contraindicated.

Ultrasound

This is of limited value in the diagnosis of malignancy but it can differentiate between solid and cystic nodules and will often detect other impalpable nodules.

High resolution sonography using 10 MHz transducer can detect subclinical solid thyroid nodules larger than 2-3 mm in diameter and cysts of 1mm.

C.T. and M.R.I.

Has only a small role to play in the day to day management of thyroid disorders.

Fluorescent scanning

This requires a collimated source to photon radiation (241 Am) which results in characteristic 28.5 Kev x ray emission from any iodine atoms in the filed. The number of xrays detected is proportional to the amount of iodine present.

In solitary nodule, the ration of iodine contact in the nodule compared to opposite to lobe may be used to distinguish benign from malignant lesions.

Thyroid auto antibodies

Auto immunity plays a role in the pathogenesis of Hashimoto's disease and graves diseases. Following antibodies can be detected. Microsomal antibody, thyroglobulin antibody, long acting thyroid stimulator (LATS) gives information in the etiology of thyrotoxicosis.

Tumour Marker

Serum calcitonin is diagnostic of medullary carcinoma

Plain X ray

Xray neck shows soft tissue shadow, calcification and compression of trachea. In retrosternal goiter, soft tissue shadow can be clearly defined by convex lateral margins.

X ray chest may show secondaries.

Miscellaneous Tests

Tests for metabolic indices.

i. BMR

Heat loss is measured by measuring the oxygen consumption under basal condition by indirect method. Hyperfunction is associated with increased oxygen consumption.

Normal value is between -10 and +10.

ii. Serum cholesterol

Normal value 150-240mg%.

INDICATIONS FOR SURGERY

Indications for operation in patients with multinodular goitre are:

1. Proven (or) suspected cancer
2. Obstructive symptoms
3. Patient Anxiety
4. Hyper functioning nodule
5. Cosmesis

MATERIALS AND METHODS

Design

A single institution study done during the period from May 2007 to October 2009 in the department of surgery, Government Rajaji Hospital, Madurai. All the patients admitted in Government Rajaji hospital were examined clinically and patients with multi nodular goitre were selected for the study.

Setting

Teritary Academic referral centre

Patient

One hundred patients who under went total thyroidectomy for multinodular goiter (MNG)

Criteria for selection of patient

A patient with

1. Non toxic – multinodular goitre
2. Toxic MNG

Among 100 multi nodular goitre patients who underwent total thyroidectomy, the incidence of the various types of carcinoma were studied based on Histopatholgical examination.

RESULTS

This is a study of 100 patients who under went total thyroidectomy, as per our norms in Government Rajaji Hospital Madurai from may 2007 to October 2009.

Patients

Of the chosen 100 patients, 85 were female and 15 were male, a striking female preponderence

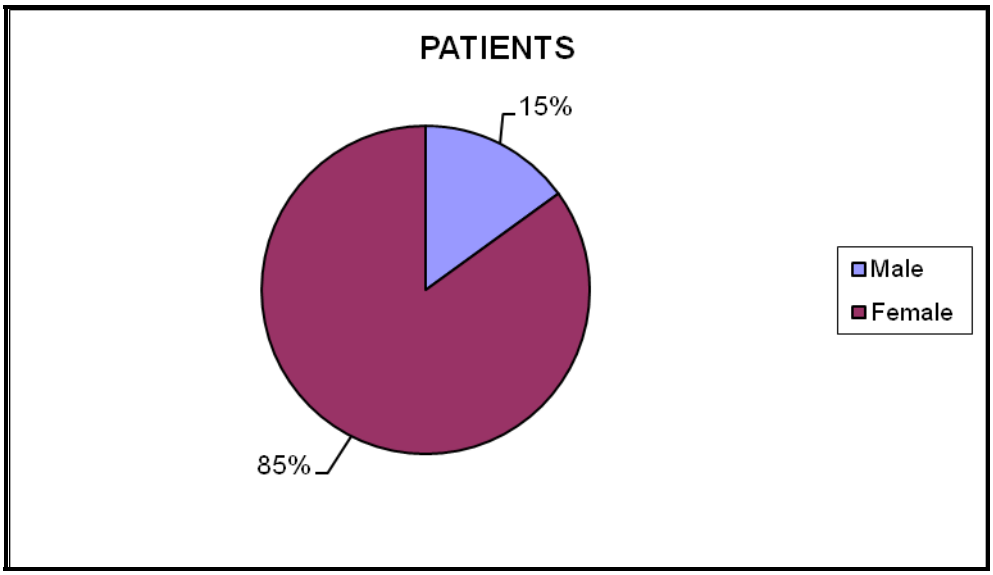

Age

The average age of the patients is 35.82 yrs

The average age of the female patients is 35.19yrs

The average age of the male patients is 39.4yrs

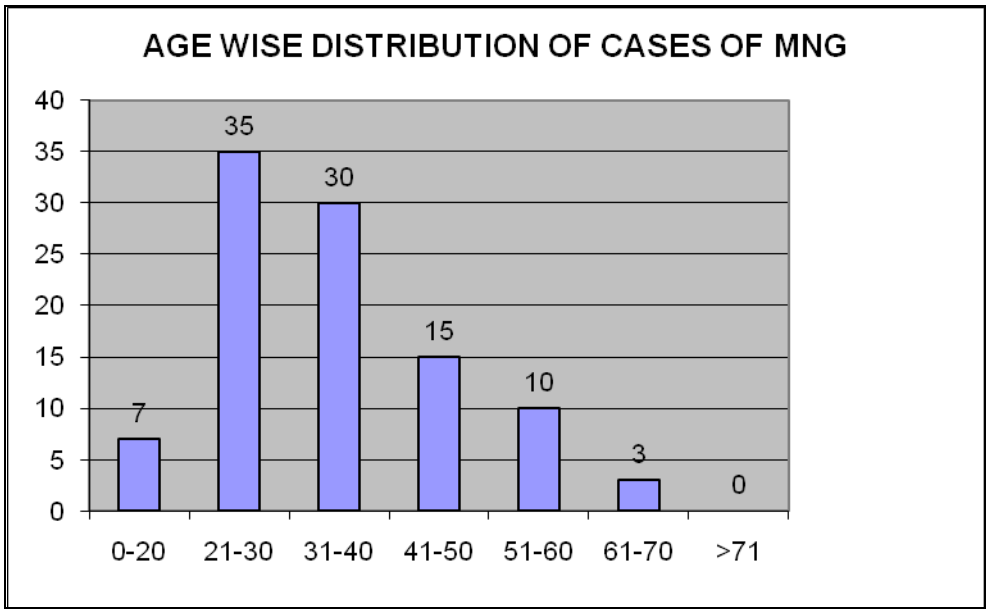

Symptoms

The most common presenting symptoms / complaint is swelling in the neck and the next to follow is features suggestive of hyperthyroidism.

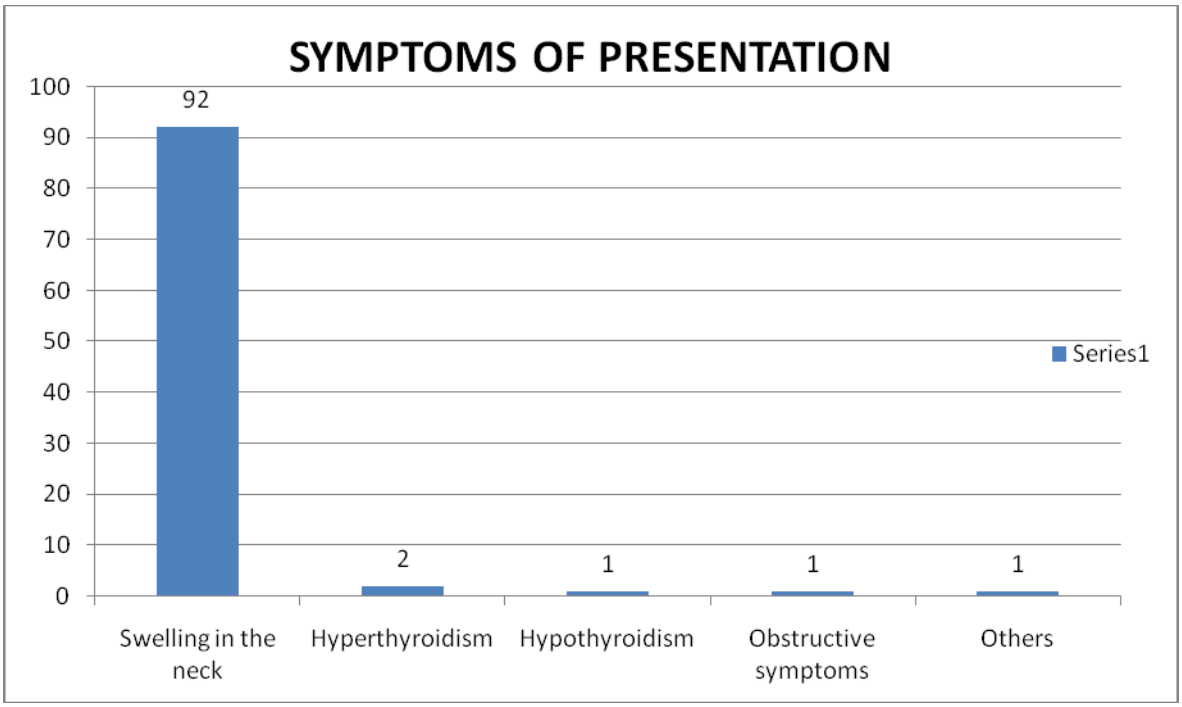

Final Diagnosis

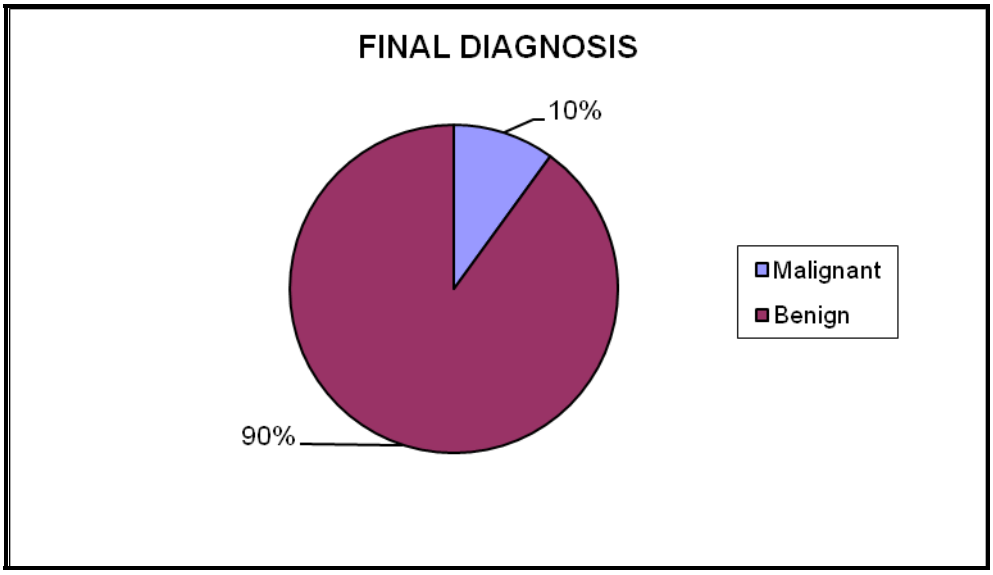

Of the 100 patients under went total thyroidectomy, 90 were benign, 10 were carcinoma thyroid, so the incidence of carcinoma in MNG was 10% in our study.

Age wise distribution of malignancy

Common age group for presentation of carcinoma thyroid was 41-50 yrs in our study.

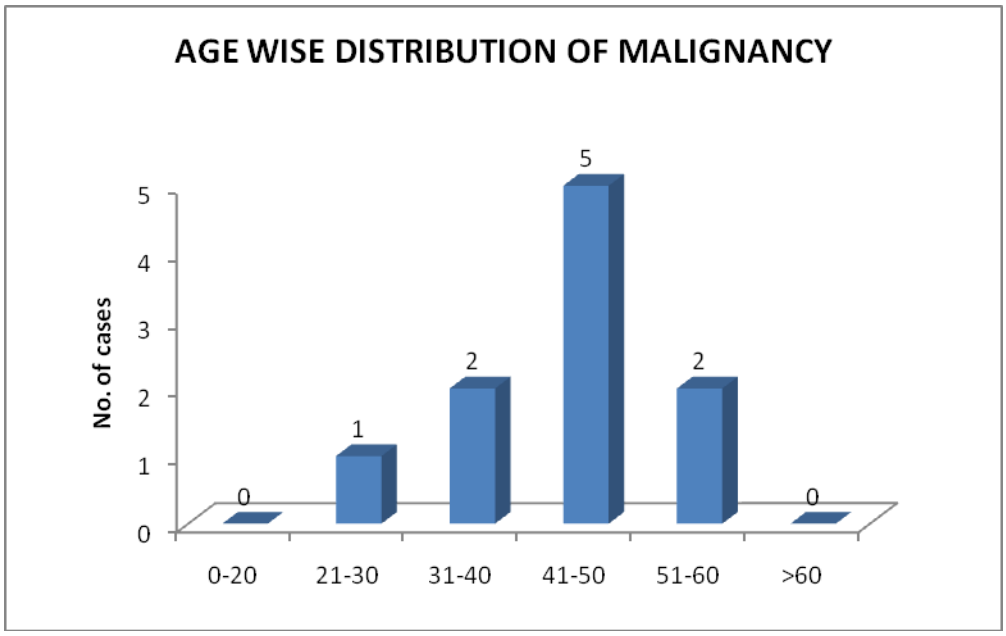

Sex wise distribution of Malignancy

Among 85 female cases, 8 cases of thyroid carcinoma were detected and out of 15 male cases 12 cases of carcinoma detected in our study.

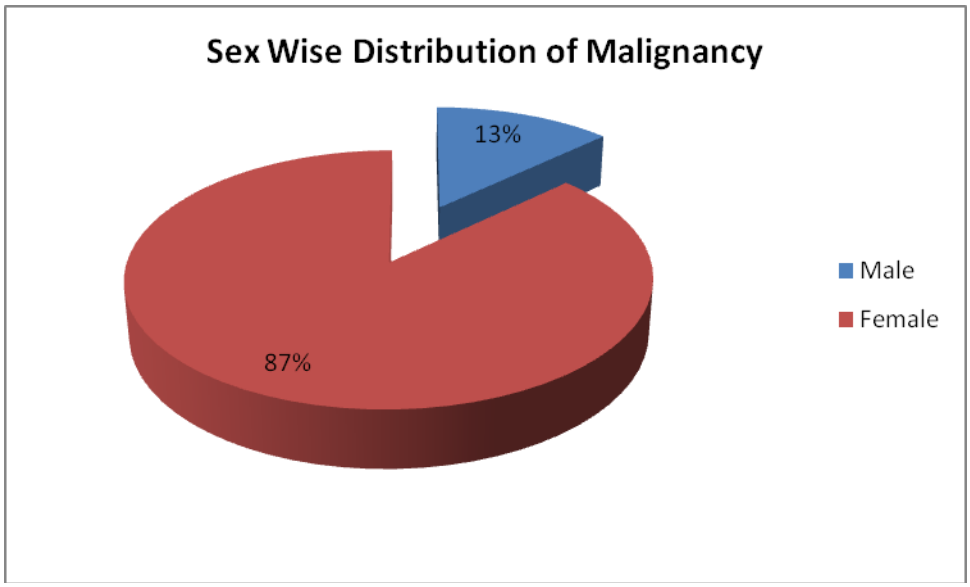

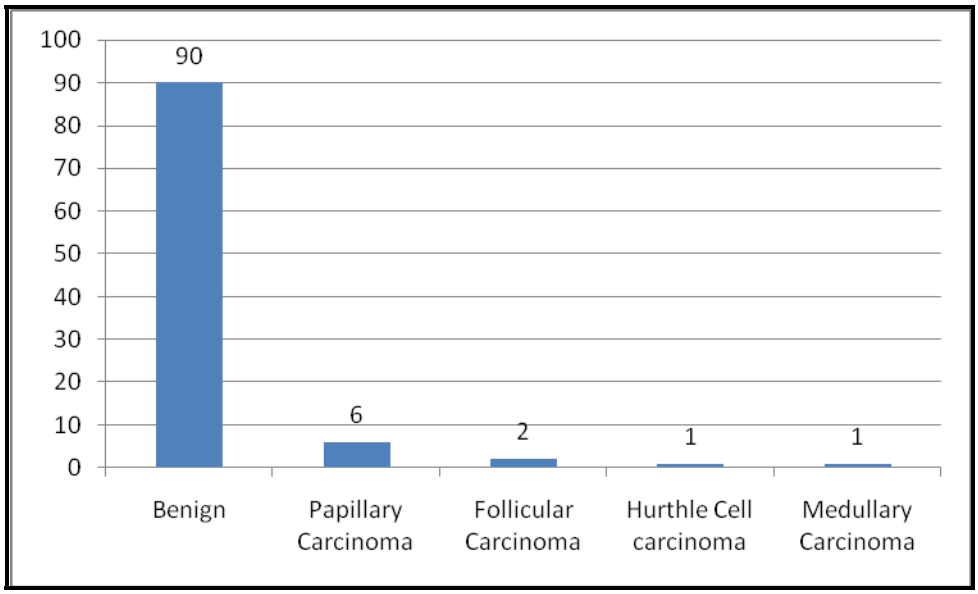

Among 10 carcinoma patients, 6 cases of papillary carcinoma thyroid 2 cases of follicular carcinoma of thyroid, 1 case of Hurthle cell carcinoma, 1 case of medullary carcinoma of thyroid.

	Benign	**Papilary carcinoma**	**Follicular Carcinoma**	**Hurthle Cell Carcinoma**	**Medullary Carcinoma**	**Total**
No. of cases	90	6	2	1	1	100

DISCUSSION

The diagnosis of multinodular goitre is mainly clinical. Surgery offered for cosmesis, compressive symptoms (or) toxi city.

Features increase the suspicion of malignancy in multi nodular goitre.

1. Age less than 20 and more than 70
2. Male gender
3. New onset of swallowing difficulties
4. New onset of Hoarseness
5. H/O external neck irradiation during childhood
6. Firm, Irregular and fixed nodule
7. Presence of cervical lymphadenopathy
8. Previous history of thyroid cancer
9. Nodule that is cold on scan
10. USG shows microcalcification, blurred nodular margins, solid and hypoechoic appearance.

Fine needle aspiration cytology is practically not feasible, in all cases of multinodular goiter. Despite negative fine – needle aspiration cytology, the patient can still harber a malignant focus due to a sampling error with multinodular giotre.

In our study, 100 MNG cases were operated for cosmesis, Toxicity and obstructive symptoms

Among 100 MNG cases, based on HPE findings, 10 cases were found to be (Histological surprise) carcinoma. Among 10 cases papillary carcinoma predominates followed by follicular carcinoma.

In our study, incidence of thyroid carcinoma was more common in females than in males.

Multinodular goitre is traditionally thought to be at low risk for malignancy compare to solitary nodule of thyroid.

As per literature, incidence of malignancy in MNG was 4-17% and common type documented was papillary carcinoma.

Incidence of occult carcinoma in my study is 10% and most commonly being papillary carcinoma.

CONCLUSION

- The risk of malignancy in multinodular goitres should not be under estimated.
- Due to risk of occult carcinoma all the patients with MNG should be followed up carefully based on the HPE findings and appropriate treatment should be advised.
- As per our study, incidence of carcinoma in MNG is 10% and most commonly being papillary carcinoma.

MEDULLARY CARCINOMA

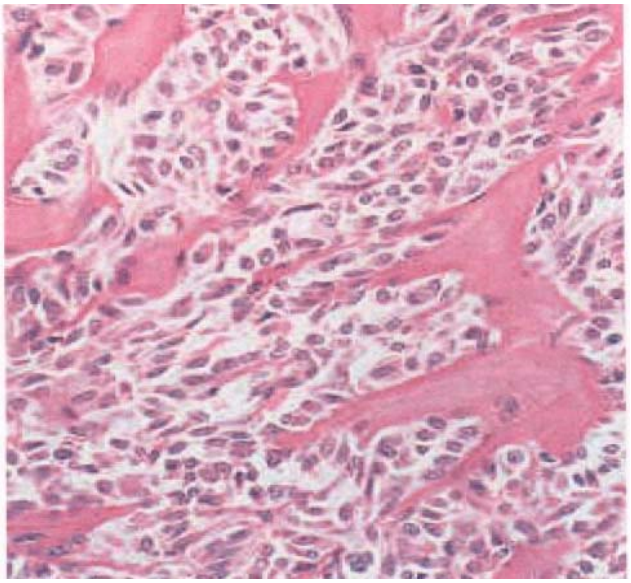

Low – Power microscopic view showing solid pattern of growth and deposition of amyloid.

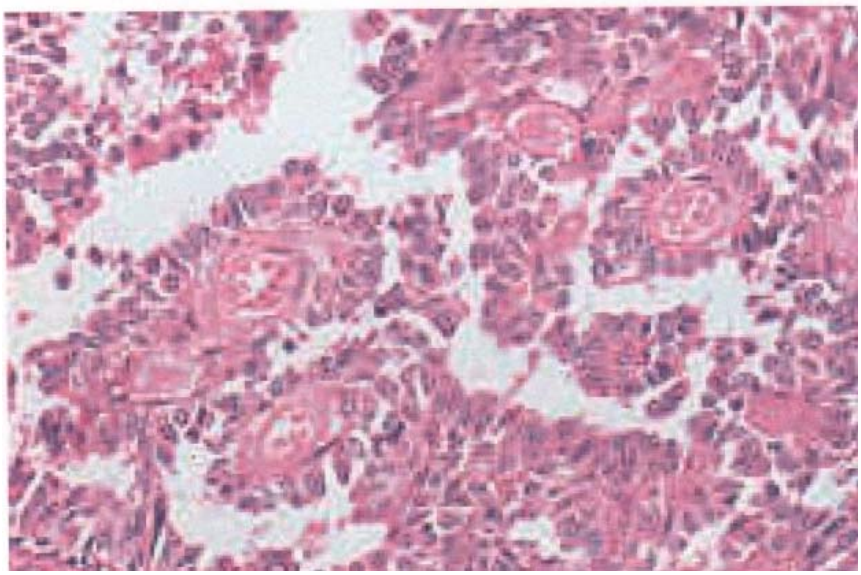

Medullary Carcinoma with pseudopapillary pattern of growth resulting from lack of cohesiveness of tumor cells.

HYPERPLASTIC THYROID

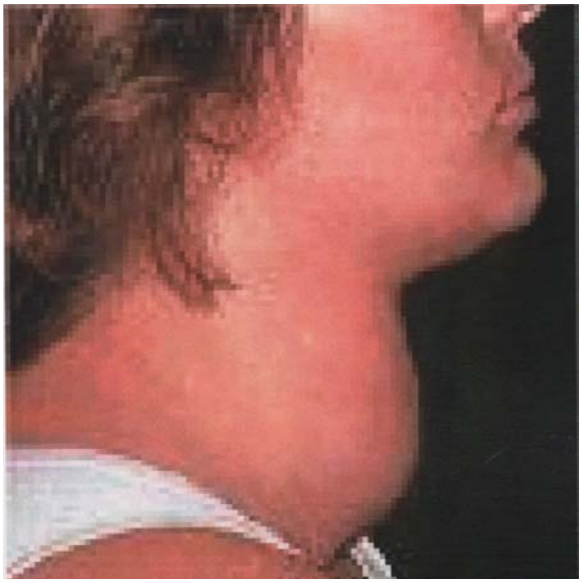

ENLARGED THYROID GLAND

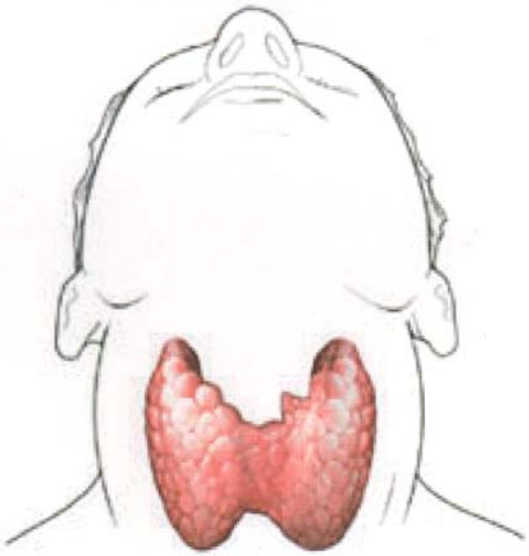

MULTINODULAR GOITRE

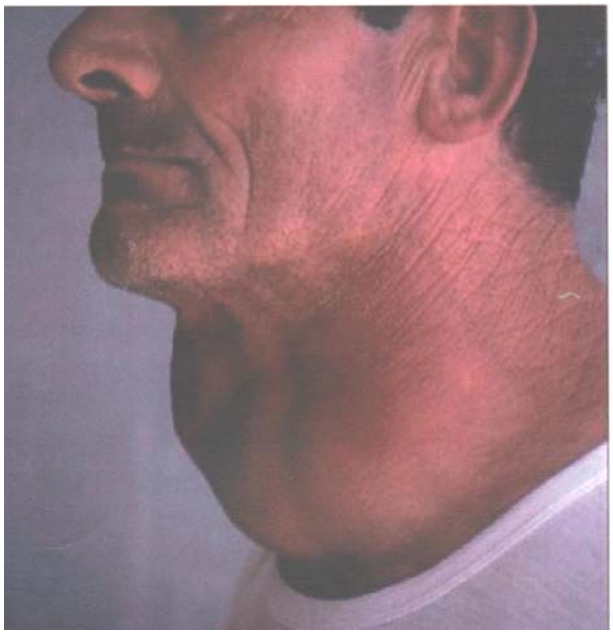

MASTER CHART

S.NO	Name	Age	Sex	IP No.	Soci economic Status	History	Examination	Diagnosis	FNAC	X-Ray	USG Neck	Thyroid Profile	Surgery	HPE report
1	Pandiammal	45	F	722249	Low	Swelling in the Neck - 5 yrs	8x5cm swelling with multiple nodules	MNG	Folicular Epithelial Cells	NAD	MNG	Normal	Total Thyroidectomy	Follicular Adenoma
2	Pondumponnu	42	F	782421	Low	Swelling in the Neck - 3yrs	7x4cm swelling with multiple nodules	MNG	Folicular Epithelial Cells	NAD	MNG	T3,T4 ↑ TSH ↓	Total Thyroidectomy	Follicular Adenoma
3	Indira	40	F	778754	Low	Swelling in the Neck - 3 yrs	7x4 swelling in the thyroid region	MNG	Inconclusive	NAD	MNG	Normal	Total Thyroidectomy	Follicular Adenoma
4	Mary	32	F	789789	Low	Swelling in the Neck - 4 yrs	9x4 swelling in the thyroid region	MNG	Inconclusive	NAD	MNG	Normal	Total Thyroidectomy	Thyroiditis
5	Chinnaponnu	35	F	747787	Low	Swelling in the Neck - 5 yrs	8x5cm swelling with multiple nodules	MNG	Folicular Epithelial Cells	NAD	MNG	Normal	Total Thyroidectomy	Adenoma
6	Rajathi	38	F	75921	Low	Swelling in the Neck - 5 yrs	7x4 swelling in front of neck	MNG	Folicular Epithelial Cells	NAD	MNG	Normal	Total Thyroidectomy	Adenoma
7	Ponni	38	F	62831	Low	Swelling in the Neck - 4 yrs	6x3 swelling in front of neck	MNG	Inconclusive	NAD	MNG	Normal	Total Thyroidectomy	Adenoma
8	Aruna	34	F	619616	Low	Swelling in the Neck - 5 yrs	7x4 swelling in front of neck	MNG	Folicular Epithelial Cells	NAD	MNG	Normal	Total Thyroidectomy	Papillary carcinoma
9	Murugeswari	32	F	84411	Low	Swelling in the Neck -2yrs	10x4cm swelling with multiple nodules	MNG	Inconclusive	NAD	MNG	Normal	Total Thyroidectomy	Adenoma
10	Jeevarathinam	35	M	84812	Low	Swelling in the Neck -2yrs	8x4cm swelling with multiple nodules	MNG	Folicular Epithelial Cells	NAD	MNG	Normal	Total Thyroidectomy	Follicular Adenoma
11	Karupayee	28	F	50537	Low	Swelling in the Neck - 1 yrs	Palpain of multiple nodules	MNG	Inconclusive	NAD	MNG	Normal	Total Thyroidectomy	Follicular Adenoma
12	Vani	24	F	44229	Low	Swelling in the Neck - 2 yrs	5x3cm swelling with multiple nodules	MNG	Folicular Epithelial Cells	NAD	MNG	Normal	Total Thyroidectomy	Follicular Adenoma
13	Senthilakshmi	24	F	35936	Low	Swelling in the Neck - 1 yrs	4x4cm swelling infront of neck	MNG	Folicular Epithelial Cells	NAD	MNG	T3,T4 ↑ TSH ↓	Total Thyroidectomy	Thyroiditis
14	Muthumari	28	F	396729	Low	Swelling in the Neck - 3 yrs	6x3 swelling in front of neck	MNG	Folicular Epithelial Cells	NAD	MNG	Normal	Total Thyroidectomy	Follicular Adenoma
15	Muthulakshmi	29	F	72051	Low	Swelling in the Neck - 2 yrs	5x4cm swelling with multiple nodules	MNG	Inconclusive	NAD	MNG	Normal	Total Thyroidectomy	Papillary carcinoma
16	Velammal	57	F	83426	Low	Swelling in the Neck - 5 yrs	9x7cm swelling in the thyroid region	MNG	Folicular Epithelial Cells	NAD	MNG	Normal	Total Thyroidectomy	Follicular Adenoma
17	Muthu	30	F	44016	Low	Swelling in the Neck - 2 yrs	8x6cmswelling in the thyroid region	MNG	Folicular Epithelial Cells	NAD	MNG	Normal	Total Thyroidectomy	Thyroiditis
18	Malliga	28	F	44052	Low	Swelling in the Neck - 2 yrs	9x4cm swelling in the neck	MNG	Inconclusive	NAD	MNG	Normal	Total Thyroidectomy	Adenoma
19	Solai	29	F	72051	Low	Swelling in the Neck - 3 yrs	5x6cm swelling, nodular, firm	MNG	Folicular Epithelial Cells	NAD	MNG	Normal	Total Thyroidectomy	Follicular Adenoma
20	Amuthu	27	F	51319	Low	Swelling in the Neck - 5 yrs	5x8cm swelling nodular, firm	MNG	Inconclusive	NAD	MNG	Normal	Total Thyroidectomy	Thyroiditis

S.NO	Name	Age	Sex	IP No.	Soci economic Status	History	Examination	Diagnosis	FNAC	X-Ray	USG Neck	Thyroid Profile	Surgery	HPE report
21	Shanthi	29	F	25279	Low	Swelling in the Neck - 5 yrs	8x7cm swelling nodular, firm	MNG	Folicular Epithelial Cells	NAD	MNG	T3,T4 ↑ TSH ↓	Total Thyroidectomy	Follicular Adenoma
22	Vellaiammal	39	F	88121	Low	Swelling in the Neck - 8 yrs	6x5mm swelling in neck	MNG	Folicular Epithelial Cells	NAD	MNG	Normal	Total Thyroidectomy	Adenoma
23	Karmegam	28	F	82121	Low	Swelling in the Neck - 6 yrs	6x5mm swelling in neck	MNG	Folicular Epithelial Cells	NAD	MNG	Normal	Total Thyroidectomy	Adenoma
24	Pothumponnu	29	F	88146	Low	Swelling in the Neck - 7 yrs	8x5cm swelling with multiple nodules	MNG	Inconclusive	NAD	MNG	Normal	Total Thyroidectomy	Adenoma
25	Saroja	32	F	88126	Low	Swelling in the Neck - 7 yrs	5x4cm swelling with multiple nodules	MNG	Folicular Epithelial Cells	NAD	MNG	Normal	Total Thyroidectomy	Papillary carcinoma
26	Sangeetha	38	F	89121	Low	Swelling in the Neck - 8 yrs	6x4cm swelling with multiple nodules	MNG	Folicular Epithelial Cells	NAD	MNG	Normal	Total Thyroidectomy	Adenoma
27	Durga	38	F	92150	Low	Swelling in the Neck - 7 yrs	5x4cm swelling with multiple nodules	MNG	Folicular Epithelial Cells	NAD	MNG	Normal	Total Thyroidectomy	Adenoma
28	Sarasu	34	F	92151	Low	Swelling in the Neck - 8 yrs	8x4cm swelling with multiple nodules	MNG	Inconclusive	NAD	MNG	Normal	Total Thyroidectomy	Thyroiditis
29	shanthi	38	F	92191	Low	Swelling in the Neck - 6 yrs	6x4cm swelling with multiple nodules	MNG	Inconclusive	NAD	MNG	Normal	Total Thyroidectomy	Adenoma
30	Sangari	39	F	98192	Low	Swelling Neck with palpitation	5x4cm swelling with multiple nodules	MNG	Folicular Epithelial Cells	NAD	MNG	Normal	Total Thyroidectomy	Adenoma
31	Kaveri	34	F	98121	Low	Swelling in the Neck - 7 yrs	6x3cm swelling in the thyroid region	MNG	Folicular Epithelial Cells	NAD	MNG	Normal	Total Thyroidectomy	Adenoma
32	Jeyashree	36	F	89111	Low	Swelling in the Neck - 8 yrs	8x3cm swelling infront of nexk	MNG	Inconclusive	NAD	MNG	Normal	Total Thyroidectomy	Adenoma
33	Durga	31	F	88126	Low	Swelling in the Neck - 9 yrs	6x4cm swelling with multiple nodules	MNG	Folicular Epithelial Cells	NAD	MNG	Normal	Total Thyroidectomy	Thyroiditis
34	Archu	49	F	81124	Low	Swelling in the Neck - 6 yrs	6x4cm swelling with multiple nodules	MNG	Folicular Epithelial Cells	NAD	MNG	Normal	Total Thyroidectomy	Adenoma
35	Vijya	55	F	91112	Low	Swelling in the Neck - 2 yrs	5x4cm swelling with multiple nodules	MNG	Inconclusive	NAD	MNG	Normal	Total Thyroidectomy	Adenoma
36	Vijyalakshmi	60	F	94312	Low	Swelling neck with dyephoea for 3 1/2 yr	6x3cm swelling in the thyroid region	MNG	Folicular Epithelial Cells	NAD	MNG	Normal	Total Thyroidectomy	Follicular Adenoma
37	raja	54	M	88129	Low	Swelling in the Neck - 1 1/2 yrs	5x2cm swelling in the thyroid region	MNG	Folicular Epithelial Cells	NAD	MNG	Normal	Total Thyroidectomy	Follicular Adenoma
38	Rajalakshmi	41	F	92121	Low	Swelling in the Neck - 2 yrs	5x4cm swelling infront of neck	MNG	Inconclusive	NAD	MNG	Normal	Total Thyroidectomy	Thyroiditis
39	Shamsathbegam	38	F	91143	Low	Swelling in the Neck - 6 yrs	6x4cm swelling infornt of neck	MNG	Folicular Epithelial Cells	NAD	MNG	Normal	Total Thyroidectomy	Follicular Adenoma
40	Ponnuthai	40	F	72146	Low	Swelling in the Neck - 9 yrs	8x5cm swelling with multiple nodules	MNG	Inconclusive	NAD	MNG	Normal	Total Thyroidectomy	Thyroiditis

S.NO	Name	Age	Sex	IP No.	Soci economic Status	History	Examination	Diagnosis	FNAC	X-Ray	USG Neck	Thyroid Profile	Surgery	HPE report
41	Aruna	46	F	72187	Low	Swelling in the Neck - 4 yrs	7x3cm swelling in the thyroid region	MNG	Folicular Epithelial Cells	NAD	MNG	Normal	Total Thyroidectomy	Follicular Adenoma
42	Kannagi	34	F	71128	Low	Swelling in the Neck - 3 1/2 yrs	6x3cm swelling infront of neck	MNG	Inconclusive	NAD	MNG	Normal	Total Thyroidectomy	Adenoma
43	Rajathi	31	F	76612	Low	Swelling in the Neck - 1 1/2 yrs	8x6 cm swelling in the thyroid region	MNG	Folicular Epithelial Cells	NAD	MNG	Normal	Total Thyroidectomy	Adenoma
44	Rajeswari	49	F	98111	Low	Swelling in the Neck - 6 yrs	6x4cm swelling infront of neck	MNG	Folicular Epithelial Cells	NAD	MNG	Normal	Total Thyroidectomy	Follicular Carcinoma
45	Rakku	48	F	92114	Low	Swelling in the Neck - 4 yrs	4x3cm swelling in the thyroid region	MNG	Inconclusive	NAD	MNG	Normal	Total Thyroidectomy	Thyroiditis
46	Saraswathi	39	F	91124	Low	Swelling in the Neck - 9 yrs	6x3cm swelling with multiple nodules	MNG	Folicular Epithelial Cells	NAD	MNG	Normal	Total Thyroidectomy	Hurthle cell carcinoma
47	Mary	31	F	98129	Low	Swelling in the Neck - 2 yrs	6x4cm swelling infront of neck	MNG	Folicular Epithelial Cells	NAD	MNG	Normal	Total Thyroidectomy	Follicular Adenoma
48	Ponnambalam	40	M	88126	Low	Swelling in the Neck - 1 1/2 yrs	5x4cm swelling in the thyroid region with multiple noc	MNG	Inconclusive	NAD	MNG	Normal	Total Thyroidectomy	Adenoma
49	Murugeswari	31	F	91169	Low	Swelling in the Neck - 1 yr	6x3cm swelling infront of neck	MNG	Folicular Epithelial Cells	NAD	MNG	Normal	Total Thyroidectomy	Adenoma
50	Pankajam	60	F	91616	Low	Swelling in the Neck - 8 yrs	8x4cm swelling with multiple nodules	MNG	Inconclusive	NAD	MNG	Normal	Total Thyroidectomy	Adenoma
51	Muthumeena	36	F	78126	Low	swelling neck for 2 yrs	6x3cm swelling nodular, firm	MNG	Folicular Epithelial Cells	NAD	MNG	Normal	Total Thyroidectomy	Adenoma
52	Perumal	39	M	91233	Low	swelling neck for 1 yrs	7x4cm swelling nodules	MNG	Folicular Epithelial Cells	NAD	MNG	Normal	Total Thyroidectomy	Papillary carcinoma
53	Rajeswari	44	F	81666	Low	swelling neck for 6 yrs	6x5cm swelling thyroid region	MNG	Inconclusive	NAD	MNG	Normal	Total Thyroidectomy	Thyroiditis
54	Parameshwari	41	F	91126	Low	swelling neck for 4 yrs	6x4cm swelling thyroid region	MNG	Folicular Epithelial Cells	NAD	MNG	Normal	Total Thyroidectomy	Adenoma
55	Karpagam	36	F	96211	Low	swelling neck for 3 yrs	6x3cm swelling nodular, firm	MNG	Folicular Epithelial Cells	NAD	MNG	Normal	Total Thyroidectomy	Medullary Carcinoma
56	Rajeswari	31	F	98121	Low	swelling neck for 1 1/2 yrs	6x4cm swelling infront of neck	MNG	Inconclusive	NAD	MNG	Normal	Total Thyroidectomy	Adenoma
57	Saroja	39	F	81216	Low	swelling neck for 3 yrs	5x3cm swelling in the thyroid region	MNG	Folicular Epithelial Cells	NAD	MNG	Normal	Total Thyroidectomy	Adenoma
58	Pillomi	32	F	84646	Low	swelling neck for 5 yrs	6x4cm swelling infront of neck	MNG	Inconclusive	NAD	MNG	Normal	Total Thyroidectomy	Adenoma
59	Vani	40	F	92111	Low	swelling neck for 6 yrs	5x3cm swelling in the thyroid region	MNG	Inconclusive	NAD	MNG	Normal	Total Thyroidectomy	Thyroiditis
60	Senthamari	34	F	91619	Low	swelling neck for 4 yrs	6x3cm swelling in the thyroid region	MNG	Folicular Epithelial Cells	NAD	MNG	Normal	Total Thyroidectomy	Adenoma

S.NO	Name	Age	Sex	IP No.	Soci economic Status	History	Examination	Diagnosis	FNAC	X-Ray	USG Neck	Thyroid Profile	Surgery	HPE report
61	Archana	46	F	61618	Low	swelling neck for 4 yrs	6x4cm swelling in the thyroid region	MNG	Inconclusive	NAD	MNG	Normal	Total Thyroidectomy	Adenoma
62	Arokyam	42	M	66121	Low	swelling neck for 2 yrs	5x3cm swelling in the thyroid region	MNG	Inconclusive	NAD	MNG	Normal	Total Thyroidectomy	Adenoma
63	Mangalam	34	F	66129	Low	swelling neck for 4 yrs	6x3cm swelling with multiple nodules	MNG	Folicular Epithelial Cells	NAD	MNG	Normal	Total Thyroidectomy	Follicular Adenoma
64	Indhu	39	F	68126	Low	swelling neck for 6 yrs	5x4cm swelling in the thyroid region	MNG	Inconclusive	NAD	MNG	Normal	Total Thyroidectomy	Follicular Adenoma
65	Ponnuthai	36	F	42126	Low	swelling neck for 2 yrs	6x2cm swelling in the thyroid region	MNG	Inconclusive	NAD	MNG	Normal	Total Thyroidectomy	Thyroiditis
66	Valli	46	F	68111	Low	swelling neck for 4 yrs	4x3cm swelling infront of the neck	MNG	Folicular Epithelial Cells	NAD	MNG	Normal	Total Thyroidectomy	Follicular Adenoma
67	Rajeswari	49	F	69126	Low	swelling neck for 2 1/2 yrs	5x4cm swelling in the thyroid region	MNG	Folicular Epithelial Cells	NAD	MNG	Normal	Total Thyroidectomy	Follicular Adenoma
68	Sangeetha	40	F	68121	Low	swelling neck for 4 yrs	6x3cm swelling in front of neck	MNG	Inconclusive	NAD	MNG	Normal	Total Thyroidectomy	Follicular Adenoma
69	Kanrupayye	48	F	66126	Low	swelling neck for 4 yrs	5x4cm swelling infront of neck	MNG	Inconclusive	NAD	MNG	Normal	Total Thyroidectomy	Follicular Adenoma
70	senthilakshmi	34	F	69161	Low	swelling neck for 2 yrs	7x3cm swelling in front of neck	MNG	Folicular Epithelial Cells	NAD	MNG	Normal	Total Thyroidectomy	Thyroiditis
71	Tamilarasi	39	F	91126	Low	swelling neck for 4 yrs	8x4cm swelling with multiple nodules	MNG	Folicular Epithelial Cells	NAD	MNG	Normal	Total Thyroidectomy	Papillary carcinoma
72	Pandiselvi	34	F	94121	Low	swelling neck for 2 yrs	6x3cm swelling in the thyroid region	MNG	Inconclusive	NAD	MNG	Normal	Total Thyroidectomy	Adenoma
73	Pandi	39	M	88126	Low	swelling neck for 3 yrs	6x4cm swelling infront of neck	MNG	Folicular Epithelial Cells	NAD	MNG	Normal	Total Thyroidectomy	Adenoma
74	Pandiammal	29	F	92141	Low	swelling neck for 2 1/2 yrs	6x3cm swelling in the thyroid region	MNG	Folicular Epithelial Cells	NAD	MNG	Normal	Total Thyroidectomy	Adenoma
75	Rajarajeshwari	30	F	98126	Low	swelling neck for 1 1/2 yrs	6x4cm swelling in the neck with multiple nodules	MNG	Inconclusive	NAD	MNG	Normal	Total Thyroidectomy	Adenoma
76	Puthuponnu	28	F	92141	Low	swelling neck for 2 yrs	4x3cm swelling in the neck with multiple nodules	MNG	Folicular Epithelial Cells	NAD	MNG	Normal	Total Thyroidectomy	Thyroiditis
77	Rajathi	27	F	94626	Low	swelling neck for 4 yrs	6x4cm swelling infront of the neck	MNG	Inconclusive	NAD	MNG	Normal	Total Thyroidectomy	Adenoma
78	Indira	40	F	94828	Low	swelling neck for 2 1/2 yrs	4x2cm swelling in the thyroid region	MNG	Inconclusive	NAD	MNG	Normal	Total Thyroidectomy	Adenoma
79	pandeeswari	42	F	94626	Low	swelling neck for 4 yrs	4x3cm swelling infront of the neck	MNG	Folicular Epithelial Cells	NAD	MNG	Normal	Total Thyroidectomy	Adenoma
80	Mary	41	F	94828	Low	swelling neck for 2 yrs	5x3cm swelling in the thyroid region	MNG	Folicular Epithelial Cells	NAD	MNG	Normal	Total Thyroidectomy	Adenoma

S.NO	Name	Age	Sex	IP No.	Soci economic Status	History	Examination	Diagnosis	FNAC	X-Ray	USG Neck	Thyroid Profile	Surgery	HPE report
81	Mohamed Hussa	4	M	94161	Low	swelling neck for 2 1/2 yrs	6x3cm swelling infron of neck	MNG	Inconclusive	NAD	MNG	Normal	Total Thyroidectomy	Adenoma
82	chinnathai	31	F	98141	Low	swelling neck for 4 yrs	6x2cm swelling in the thyroid region	MNG	Inconclusive	NAD	MNG	Normal	Total Thyroidectomy	Thyroiditis
83	Pandithurai	34	M	94443	Low	swelling neck for 2 yrs	5x3cm swelling infront of neck	MNG	Folicular Epithelial Cells	NAD	MNG	Normal	Total Thyroidectomy	Adenoma
84	Ponni	36	F	98421	Low	swelling neck for 1 1/2 yrs	6x3cm swelling in the thyroid region	MNG	Folicular Epithelial Cells	NAD	MNG	Normal	Total Thyroidectomy	Adenoma
85	Vaniselvi	34	F	92121	Low	swelling neck for 2 yrs	6x4cm swelling infront of neck	MNG	Folicular Epithelial Cells	NAD	MNG	Normal	Total Thyroidectomy	Adenoma
86	Murugeswari	38	F	94161	Low	swelling neck for 4 yrs	5x3cm swelling in the thyroid region	MNG	Inconclusive	NAD	MNG	Normal	Total Thyroidectomy	Adenoma
87	Mumtaj	34	F	98761	Low	swelling neck for 3 yrs	6x4cm swelling with multiple nodules	MNG	Folicular Epithelial Cells	NAD	MNG	Normal	Total Thyroidectomy	Papillary carcinoma
88	Panchu	36	F	88126	Low	swelling neck for 1 1/2 yrs	5x4cm swelling with multiple nodules	MNG	Folicular Epithelial Cells	NAD	MNG	Normal	Total Thyroidectomy	Adenoma
89	Pandiammal	40	F	91616	Low	swelling neck for 4 yrs	5x4cm swelling with multiple nodules	MNG	Folicular Epithelial Cells	NAD	MNG	Normal	Total Thyroidectomy	Adenoma
90	Rajeswari	39	F	92616	Low	swelling neck for 6 yrs	5x4cm swelling with multiple nodules	MNG	Inconclusive	NAD	MNG	Normal	Total Thyroidectomy	Adenoma
91	Jesuda	46	F	82616	Low	swelling neck for 4 yrs	5x4cm swelling with multiple nodules	MNG	Inconclusive	NAD	MNG	Normal	Total Thyroidectomy	Thyroiditis
92	Pappa	29	F	92424	Low	swelling neck for 1 yrs	5x4cm swelling with multiple nodules	MNG	Folicular Epithelial Cells	NAD	MNG	Normal	Total Thyroidectomy	Adenoma
93	Pappathi	31	F	96886	Low	swelling neck for 1 1/2 yrs	5x4cm swelling with multiple nodules	MNG	Inconclusive	NAD	MNG	Normal	Total Thyroidectomy	Adenoma
94	Prasad	34	M	98421	Low	swelling neck for 2 yrs	5x4cm swelling with multiple nodules	MNG	Folicular Epithelial Cells	NAD	MNG	Normal	Total Thyroidectomy	Adenoma
95	Janani	28	F	94221	Low	swelling neck for 2 yrs	5x4cm swelling with multiple nodules	MNG	Folicular Epithelial Cells	NAD	MNG	Normal	Total Thyroidectomy	Adenoma
96	mamthai	30	F	98426	Low	swelling neck for 2 yrs	5x4cm swelling with multiple nodules	MNG	Inconclusive	NAD	MNG	Normal	Total Thyroidectomy	Adenoma
97	Archna	26	F	98626	Low	swelling neck for 4 yrs	5x4cm swelling with multiple nodules	MNG	Folicular Epithelial Cells	NAD	MNG	Normal	Total Thyroidectomy	Thyroiditis
98	Pandiselvi	29	F	94626	Low	swelling neck for 2 yrs	5x4cm swelling with multiple nodules	MNG	Inconclusive	NAD	MNG	Normal	Total Thyroidectomy	Adenoma
99	Indhu	29	F	98626	Low	swelling neck for 4 yrs	5x4cm swelling with multiple nodules	MNG	Inconclusive	NAD	MNG	Normal	Total Thyroidectomy	Follicular Adenoma
100	Senthamil Selvi	26	F	94881	Low	swelling neck for 1 1/2 yrs	5x4cm swelling with multiple nodules	MNG	Folicular Epithelial Cells	NAD	MNG	Normal	Total Thyroidectomy	Follicular Adenoma

BIBLIOGRAPHY

1. Bailey and love's practice of surgery
2. Sabiston's text book of surgery
3. Schwartz principles of surgery
4. Current surgical diagnosis and treatment
5. Cuschieri's textbook of surgery
6. Chaurasia Human Anatomy
7. Gray's human Anantomy
8. Ganong Medical Physiology
9. Robin's pathological Basis of disease
10. Anderson's Pathology
11. Koh KB, chang KW. Caruhotre in MNG. Br J Surg 1992 : 79: 266:7
12. Mamair, Jdikule J, et al Do long standing nodular goiters result in malignancy Aust. N2 J Surg. 1994:64:180-182
13. Abu – Eshy SA, Khan – A.R., Khan GM et. Al. Thyroid malignancy in MNG. JR coll sugr Edinb 1995 :40:310-312.

14. Cole WH. Incidence of carcinoma in nodular goiter serum surg. On col 1991; 61-3(8)

15. Pelizzo MR, Toniato A, Piotho A, Bernarnte P, cancer on MNG. Am it all Chor 1996; 67: 351-6

16. Bondesean L. Lujenberg O. Occult thyroid carcinoma common at sureden, cancer 1981; 47:319-23(3)