THE TAMILNADU

DR.M.G.R.MEDICAL UNIVERSITY

CHENNAI

A STUDY ON ROLE OF NEAR TOTAL THYROIDECTOMY IN THYROID SWELLINGS

AT GOVERNMENT RAJAJI HOSPITAL, MADURAI

DISSERTATION SUBMITTED FOR

BRANCH - I M.S., (GENERAL SURGERY)

MARCH 2009

BONAFIDE CERTIFICATE

This is to certify that the dissertation entitled **"STUDY ON ROLE OF NEAR TOTAL THYROIDECTOMY IN THYROID SWELLINGS AT GOVT. RAJAJI HOSPITAL, MADURAI"** submitted by **Dr.C.RAJKUMAR** to the Tamil Nadu Dr. M.G.R. Medical University, Chennai in partial fulfillment of the requirement for the award of M.S Degree Branch – I (General Surgery) is a bonafide research work were carried out by him under direct supervision & guidance.

Dr.M.Gobinath, M.S.,
Professor and HOD,
Unit Chief
Govt. Rajaji Hospital
Madurai Medical College
Madurai.

DEAN
Government Rajaji Hospital
Madurai Medical College
Madurai.

DECLARATION

I **Dr.C.RAJKUMAR** declare that, I carried out this work on, **"STUDY ON NEAR TOTAL THYROIDECTOMY IN THYROID SWELLINGS AT GOVT. RAJAJI HOSPITAL, MADURAI"** at the Department of Surgery, Govt. Rajaji Hospital during the period of May 2006 to October 2008. I also declare that this bonafide work or a part of this work was not submitted by me or any others for any award, degree, diploma to any other University, Board either in India or abroad.

This is submitted to The Tamilnadu Dr. M. G. R. Medical University, Chennai in partial fulfillment of the rules and regulations for the M.S degree examination in General Surgery.

Place : Madurai **Dr.C.RAJKUMAR**

Date :

ACKNOWLEDGEMENT

I express my sincere gratitude to the Dean-in-charge, **Dr.S.M.Sivakumar, M.S.,** for allowing me to utilize the clinical materials for this study.

My sincere thanks to my unit chief, **Prof.M.Gobinath M.S.,** Head of the Department of General Surgery for his valuable guidance encouragement and support in completing this study.

I sincerely thank my unit Assistant professors **Dr.Vijayan, M.S., Dr.Nasheer Ahmed Syed, M.S., Dr.T.A.Thara, M.S., D.G.O., Dr.D.Maruthu Pandian, M.S., Dr.R.Ganesan, M.S., Dr.K.Karunakaran M.S.,** for their valuable support and guidance.

I sincerely thank all the unit chiefs and Assistant professors of the Department of General Surgery for their co-operation & guidance.

I owe my sincere thanks to all the patients for their kind co-operation in the study.

CONTENTS

INTRODUCTION

Thyroid is the largest and most easily accessible gland. Enlargement of thyroid gland (Goitre) is a common problem and attracted the attention of surgeons and provides a great deal of work and interest for them.

There are various type of surgical options for the thyroid gland depending on the type of swellings. Even now, there's no general agreement regarding the treatment of thyroid swellings. Long history together with evolving mode of treatment has made it extremely difficult to judge the effectiveness of any single or combined therapeutic approach wherein different view points have been expressed with great amount of convictions on either side.

In this study, much emphasis has been focused on anatomical & physiological aspects of the thyroid gland and the treatment of choice of near total thyroidectomy in both MNG (benign) and malignant thyroid.

AIM OF THE STUDY

To analyse and to establish the role of Near-total thyroidectomy in Multinodular goitre (benign) and malignant thyroid over a period extending from May 2006 to October 2008.

HISTORICAL ASPECTS

The thyroid gland, previously referred to as the 'laryngeal gland', was so named by Wharton in 1646, because of either its own shield like shape (thyreoeides means shield shaped) or the shape of the thyroid cartilage, with which it is closely associated.

Classical description of hyperthyroidism or exopththalmic goitre were presented by Parry(1825), Graves(1835) and Von Basedow(1840). Hypothyroidism or myxoedema was described by Curling and Gull(1875).

Schiff in the middle of the nineteenth century conducted experiments demonstrating the importance of thyroid gland.

In 1882 Reverdin produced experimental myxoedema by total or partial thyroidectomy.

In 1890 Murray and Howitz successfully treated myxoedema with thyroid extract.

Theoder Kocher, who is regarded as the Father of Thyroid Surgery, had performed thyroidectomy operations in the late 1800's over 2000 times with only a 4.5 percent

mortality. He also described “Cachexia Strumapriva” i.e., myxoedema, which he noted as a sequelae in 30 of his first 100 thyroidectomies.

In 1909 Nobel prize was awarded to Theodor Kocher for his pioneering efforts in the field of thyroid surgery.

The first successful transplantation of thyroid was reported by Payr in 1906 who transplanted a portion of the gland fron a woman into the spleen of a myxoedematous daughter with successful rates.

Isolation of thyroxine hormone was accomplished by Kendall in 1914.

Medullary carcinoma of thyroid was first described by J.Hazard et al in 1959.

As a resident J.Sipple was asked to see a patient with hypertensive crisis after Neurosurgical operation. But the patient died. At the autopsy J.Sipple found large bilateral peochromocytomas, thyroid tumors and an enlarged parathyroid gland (MEN II A).

In 1962 D.Copp et al described calcitonin as a new hormone that lowered the blood calcium. They thought calcitonin was secreted from the parathyroid, but 2 years later, it was shown that parafollicular cells (C cells) of the thyroid were the origin of this hormone.

In 1968 E.D.Williams and his group suggested that C cells were the origin of Medullary carcinoma thyroid.

ANATOMY

EMBRYOLOGY:

Begins its development from the fourth week of intra uterinelife. Hormones start secreting from twelfth week.

The thyroid gland develops as an endodermal tubular structure from the posterior aspect of the fetal tongue in the region of foramen caecum and grows downwards in front of

the developing hyoid and larynx. Primordial cells from the neural crest migrate ventrally and become incorporated within the ultimo branchial body. The main body of the thyroid is joined by para lateral component pouches, which form the “C” cells.

Diagrammatic representation of Embryology of the thyroid gland

Diagrammatic view of sagittal Ⓐ and transverse Ⓑ views of the pharyngeal regions of a human embryo during the fifth week of gestation, showing the endodermal pharyngeal pouches and mesodermal pharyngeal arches. Diagrams show the embryonic origin of the thyroid gland. Migration of the thyroid gland (anterior view) is shown in Ⓒ. Diagram Ⓓ illustrates various abnormalities which can occur during embryonic development. Each diagram is not drawn to relative scale.

SURGICAL ANATOMY:

The thyroid is a brownish-red and highly vascular gland located anteriorly in the lower neck, extending from the level of the fifth cervical vertebra down to the first thoracic. The gland varies from an H to a U shape and is formed by 2 elongated lateral lobes with superior and inferior poles connected by a median isthmus (with an average height of 12-15 mm) overlying the second to fourth tracheal rings. The isthmus is encountered during routine tracheotomy and must be retracted (superiorly or inferiorly) or divided. Occasionally, the isthmus is absent, and the gland exists as 2 distinct lobes. Each lobe is 50-60 mm long, with the superior poles diverging laterally at the level of the oblique lines on the laminae of the thyroid cartilage. The lower poles diverge laterally at the level of the fifth tracheal cartilage. Thyroid weight varies but averages 25-30 g in adults (slightly heavier in women). The gland enlarges during menstruation and pregnancy.

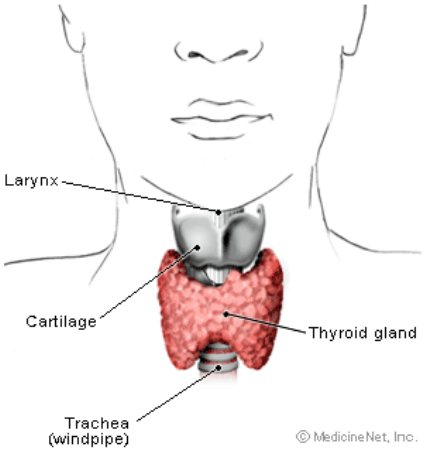

A conical pyramidal lobe often ascends from the isthmus or the adjacent part of either lobe (more often the left) toward the hyoid bone, to which it may be attached by a fibrous or fibromuscular band, the levator of the thyroid gland. Remnants of the thyroglossal duct may persist as accessory nodules or cysts of thyroid tissue between the isthmus and the foramen caecum of the tongue base.

Usually, 2 pairs of parathyroid glands lie in proximity to the thyroid gland.

STRUCTURE

Under the middle layer of deep cervical fascia, the thyroid has an inner true capsule, which is thin and adheres closely to the gland. Extensions of this capsule within the substance of the gland form numerous septae, which divide it into lobes and lobules. The lobules are composed of follicles, the structural units of the gland, consisting of a layer of simple epithelium enclosing a colloid-filled cavity. This colloid (pink on hematoxylin and eosin [H&E] stain) contains an iodinated glycoprotein, iodothyroglobulin, a precursor of thyroid hormones. Follicles vary in size, depending upon the degree of distention, and they

are surrounded by dense plexuses of fenestrated capillaries, lymphatic vessels, and sympathetic nerves.

Epithelial cells are of 2 types:

principal cells (ie, follicular) and parafollicular cells (ie, C, clear, light cells). Principal cells are responsible for formation of the colloid (iodothyroglobulin), whereas parafollicular cells produce the hormone calcitonin, a protein central to calcium homeostasis. Parafollicular cells lie adjacent to the follicles within the basal lamina.

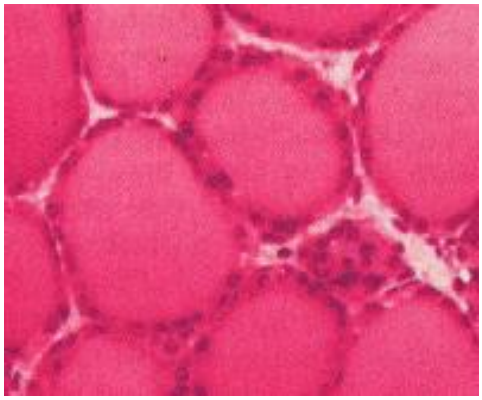

FASCIA AND LIGAMENT:

The thyroid gland is ensheathed by the visceral fascia, a division of the middle layer of deep cervical fascia, which attaches it firmly to the laryngoskeleton. The anterior suspensory ligament extends from the superior-medial aspect of each thyroid lobe to the cricoid and thyroid cartilage. The posteromedial aspect of the gland is attached to the side of

the cricoid cartilage, first and second tracheal ring, by the posterior suspensory ligament (ie, Berry ligament). This firm attachment of the gland to the laryngoskeleton is responsible for movement of the thyroid gland and related structures during swallowing. On its way to the larynx, the recurrent laryngeal nerve usually passes deep to the Berry ligament or between the main ligament and its lateral leaf. Deep to the ligament, but lateral to the nerve, is a posteromedial portion of the thyroid lobe, which may be overlooked during thyroidectomy.

RELATION WITH STRAP MUSCLES

The lateral surface of the thyroid is covered by the sternothyroid muscle, and its attachment to the oblique line of the thyroid cartilage prevents the superior pole from extending superiorly under the thyrohyoid muscle. More anteriorly are the sternohyoid and superior belly of the omohyoid muscle, overlapped inferiorly by the anterior border of the sternocleidomastoid muscle. The sternohyoid and sternothyroid muscles are joined in the midline by an avascular fascia that must be incised to retract the strap muscle laterally in order to access the thyroid gland during thyroidectomy. If strap muscles are to be transected for better exposure, do so high in the neck because the motor nerve supply from the ansa cervicalis enters these muscles inferiorly.

VASCULAR ANATOMY AND RELATION WITH LARYNGEAL INNERVATION

The arterial supply to the thyroid gland comes from the superior and inferior thyroid arteries and, occasionally, the thyroidea ima. These arteries have abundant collateral anastomoses with each other, both ipsilaterally and contralaterally. The thyroid ima is a single vessel, which originates, when present, from the aortic arch or the innominate artery and enters the thyroid gland at the inferior border of the isthmus.

Superior thyroid artery and superior laryngeal nerve

The superior thyroid artery is the first anterior branch of the external carotid artery. In rare cases, it may arise from the common carotid artery just before its bifurcation. The superior thyroid artery descends laterally to the larynx under the cover of the omohyoid and sternohyoid muscles. The artery runs superficially on the anterior border of the lateral lobe, sending a branch deep into the gland before curving toward the isthmus where it anastomoses with the contralateral artery.

Distribution of thyroid arteries with associated laryngeal nerve, anterior view.

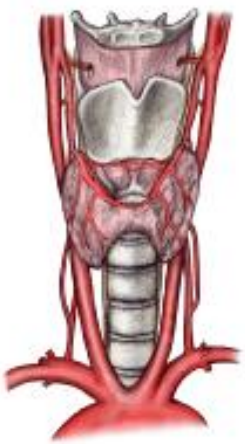

Cephalad to the superior pole, the external branch of the superior laryngeal nerve runs with the superior thyroid artery before turning medially to supply the cricothyroid muscle. High ligation of the superior thyroid artery during thyroidectomy places this nerve at risk of inadvertent injury, which would produce dysphonia by altering pitch regulation. The cricothyroid artery is a potentially bothersome branch of the superior thyroid artery, which runs cephalad to the upper pole and runs toward the midline on the cricothyroid ligament. This vessel can be lacerated during emergent cricothyroidotomy.

Inferior thyroid artery and recurrent laryngeal nerve

The inferior thyroid artery arises from the thyrocervical trunk, a branch of the subclavian artery. It ascends vertically and then curves

medially to enter the tracheoesophageal groove in a plane posterior to the carotid sheath. Most of its branches penetrate the posterior aspect of the lateral lobe . The inferior thyroid artery has a variable branching pattern and is closely associated with the recurrent laryngeal nerve. The latter also ascends in the tracheoesophageal groove and enters the larynx between the inferior cornu of the thyroid cartilage and the arch of the cricoid. The recurrent laryngeal nerve can be found after it emerges from the superior thoracic outlet, in a triangle bounded laterally by the common carotid artery, medially by the trachea, and superiorly by the thyroid lobe.

Distribution of thyroid arteries with associated laryngeal nerve, posterior view.

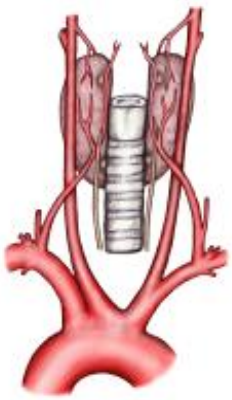

The relationship between the nerve and the inferior thyroid artery is highly variable, as demonstrated by the classic work of Reed, who in 1943 described 28 variations in this relationship. The nerve can be found

deep to the inferior thyroid artery (40%), superficially (20%), or between branches of the artery (35%).[1] Significantly, the relationship between nerve and artery on one side of the neck is similar to that found on the other side in only 17% of the population. Furthermore, at the level of the inferior thyroid artery, branches of the recurrent laryngeal nerve that are extralaryngeal may be present (5%). Preservation of all those branches is important during thyroidectomy.

Another hint to the location of the recurrent laryngeal nerve is the Zuckerkandl tubercle, an extension of the thyroid, close to the Berry ligament. On rare occasions, the recurrent laryngeal nerve may pass directly from the vagus to the larynx, close to the superior thyroid vessels. This formation is nearly always observed on the right side and is associated with a retroesophageal subclavian artery. This formation can occur on the left side in cases of transposition of the great vessels. The anatomy and innervation of the larynx is discussed more precisely elsewhere in this journal.

VENOUS DRAINAGE

Three pairs of veins provide venous drainage to the thyroid gland. The superior thyroid vein ascends along the superior thyroid artery and becomes a tributary of the internal jugular vein. The middle thyroid vein follows a direct course laterally to the internal jugular vein. The inferior

thyroid veins follow different paths on each side. The right passes anterior to the innominate artery to the right brachiocephalic vein or anterior to the trachea to the left brachiocephalic vein. On the left side, drainage is to the left brachiocephalic vein. Occasionally, both inferior veins form a common trunk called the thyroid ima vein, which empties into the left brachiocephalic vein.

Distribution of thyroid veins.

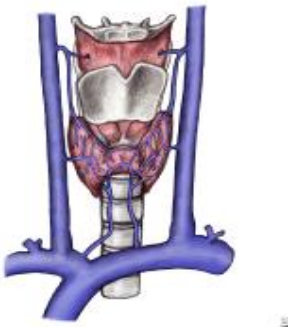

LYMPHATICS

Lymphatic drainage of the thyroid gland is extensive and flows multidirectionally. Immediate lymphatic drainage courses to the periglandular nodes, to the prelaryngeal (Delphian), pretracheal, and paratracheal nodes along the recurrent laryngeal nerve, and then to mediastinal lymph nodes. Regional metastases of thyroid carcinoma can also be found laterally, higher in the neck along the internal jugular vein. This can be explained by tumor invasion.

INNERVATION OF THE THYROID

Principal innervation of the thyroid gland derives from the autonomic nervous system. Parasympathetic fibers come from the vagus nerves, and sympathetic fibers are distributed from the superior, middle, and inferior ganglia of the sympathetic trunk. These small nerves enter the gland along with the blood vessels. Autonomic nervous regulation of the glandular secretion is not clearly understood, but most of the effect is postulated to be on blood vessels, hence the perfusion rates of the glands.

SURGICAL PHYSIOLOGY

The thyroid, largest endocrine gland in the body produces three hormones.

- Thyroxine (T4),
- Tri-iodo thyronine (T3) and
- Calcitonin.

T4 and T3 are both stored in the colloid consisting primarily of thyroglobulin which is an iodinated glycoprotein. Thyroglobulin stores are dependant on adequate dietary iodine intake, which is essential for T4 and T3 synthesis.

Iodine is derived mainly from milk and dairy products with a smaller proportion from salt, water, fish and iodised salt. Plasma levels of iodine vary widely, depending on geographical locality. Iodides are absorbed in the stomach and the upper gastrointestinal tract, approximately two-

thirds is excreted via kidneys and one-third is trapped in the thyroid where 90percent of body stores of iodine are found.

The steps in the synthesis of thyroid hormone are:

1. Concentration of Iodides in the gland
2. Rapid oxidation of iodides to iodine by a peroxidase enzyme system
3. The formation of precursor amino acids, a) 3-mono-iodothyronine(MIT) b) 3,5-di-iodothyronine (DIT)
4. The coupling of this inactive iodothyronines to form the hormonally active iodothyronines, Tri-iodothyronine & Thyroxine. When iodine transport is defective, because of either pharmacologic inhibitors, spontaneous disease, goitre and/or hypothyrodism result.

The hormonally active T4, T3 and iodothyronines are held in peptide linkage with a specific protein, thyroglobulin which forms the major component of intra follicular colloid

Release of active hormone into circulation involves hydrolysis of the thyroglobulin by proteases and peptidases resulting in T4 and T3. The activity of these enzymes is enhanced by administration of TSH.

Thyroid stimulating hormone produced by the thyrotrophic cells of anterior pituitary control the complex enzymatic reactions that trap iodine, convert it into T4 and T3 and release it into the circulation. When T4 and T3 raises above the normal range, TSH production is shut down by a negative bio-feed back loop.

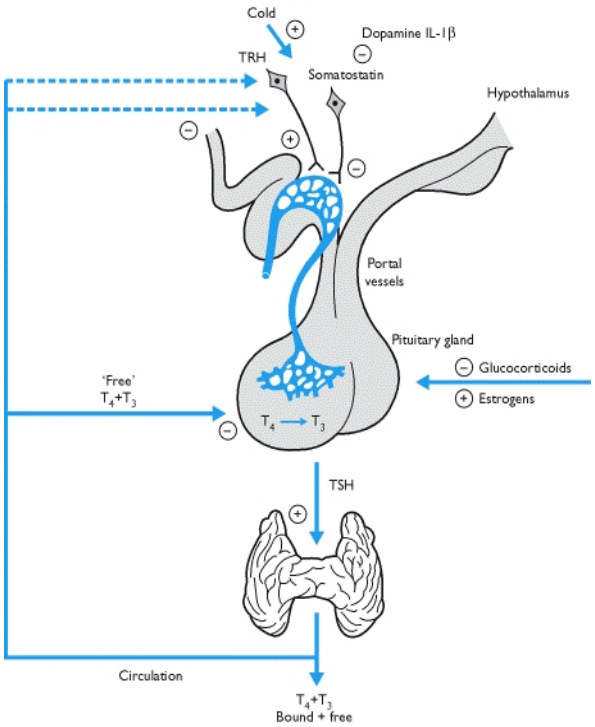

Release of TSH is regulated by Thyrotrophin Releasing Hormone (TRH) which is produced in the hypothalamus. TRH enters the capillary bed of the stalk median eminence, passing via portal veins and sinusoids to bathe the anteriorpituitary cells. TSH biosynthesis shows a circadian rhythm, its secretion will be maximum in the evening before the onset of sleep, remaining high overnight and falling to a low around mid-day.

The role of calcitonin in normal physiology has not been established in men, bur it may be involved in the regulation

of plasma calcium and phosphate metabolism. However, thyroidectomy which removes all parafollicular “C” cells causes no disturbances of calcium homeostasis.

The rise in plasma calcitonin which occurs during pregnancy and lactation appears to have no effect on maternal skeleton but calcium resorption may be prevented by a concomitant increase in the level of circulating cholecalciferol.

PATHOLOGY

The normal thyroid gland is impalpable. The term GOITRE is used to describe generalized enlargement of the thyroid gland.

CLASSIFICATION OF THYROID SWELLINGS:

- SIMPLE GOITRE (EUTHYROID)

Diffuse Hyperplastic (physiological, puberty, pregnancy)

Multinodular Goitre

- TOXIC

  Primary

  - Diffuse (Grave's disease)

  Secondary

  - Multinodular

- Toxic Adenoma
- NEOPLASTIC

  Benign

  Malignant

- INFLAMMATORY

  Auto immune thyroiditis - Hashimoto's thyroiditis

  Granulomatous thyroiditis –De quervian's thyroiditis

  Riedel's thyroiditis

- INFECTIVE

  Acute (Bacterial, Viral)

  Chronic (TB, Syphilis)

  Sub-acute

- OTHER

  Amyloid

FORMATION OF NODULES:

Iodine deficiency or goitrogens or hereditary factors leads to decrease in serum thyroid hormones which are followed by increased TSH which will produce Diffuse Hyperplastic Goitre. Then patient will become euthyroid. Because of normal thyroid hormones, TSH level drops down and goitre disappears usually by 21 years. If it persists after that, it is a Colloid Goitre with inactive follicles. Because of fluctuation of TSH level,

Mixed active and inactive follicles are formed. In active follicles, because of high vascularity, hemorrhage occurs

with central necrosis. These necrosed follicles become inactive nodules in future.

Growth stimulating antibodies are also responsible for multinodular goitre. Patient is usually euthyroid. Firm, painless nodules are palpable. Hardness may be due to calcification. Pain and sudden increase in size may be due to hemorrhage.

ADENOMA:

Approximately 30percent of the solitary nodule of thyroid is due to adenoma.

- It's common in women
- Rarely exceeding 3cm in diameter
- Firm, well defined, smooth swelling
- Encapsulated
- Slow growing
- Commonest site is at the junction of one lobe and the isthmus

- Almost all adenomas are follicular variety
- Rare types are Papillary Cystadenomas, Hurthle cell adenomas
- Microscopically it resembles normal thyroid or may be composed of tightly packed acini or diffuse sheets of epithelial cells, it may contain large colloid filled acini or even be replaced by a single cyst.
- Pressure symptoms may occur, 50percent of the adenomas are cold nodules and remainder behaves as a normal thyroid or as warm nodule.

HISTOLOGICAL CLASSIFICATION:

- Type 1

Embryonic:

The follicles are premature, arranged in the form of cords.

Fetal:

Small follicles are closely packed with abundant connective tissue

Stroma:

A). Simple Follicular

B). Colloid adenoma

- Type 2

Microfollicular

Macrofollicular

Atypical adenoma

Adenomas attain certain size and remain in that because the expansile pressure restricts blood supply.

It may suddenly enlarge and become painful because of hemorrhage. The nodule will become hyperactive.

Adenoma, occasionally have some dependence on TSH. So it regresses after administration of thyroid hormones.

Usually there's no malignant transformation.

CARCINOMA:

Papillary Carcinoma

- Common in adults and children
- Responsible for 80percent of the thyroid carcinoma occurring below 40years
- More common in women
- It grows slowly, metatstasis to cervical lymph nodes are common
- About 10- 20percent may present as only cervical lymph node metastasis. The primary is often occult (Lateral aberrant thyroid). All the lesions below 1.5cm are called as occult.
- Blood spread is unusual
- Prognosis is good, 10years survival rate is about 70-80percent.

Histology:

Complicate branching tree like pattern of cells outlined by papilliferous axial fibrovascular stroma. Pale empty nuclei (Orphan annie eyed nuclei) and psammoma bodies are

present. Papillary carcinoma is subjected to the influence of pituitary TSH.

Follicular Carcinoma

It's a well differentiated carcinoma of the thyroid but more aggressive than papillary carcinoma. More common in women. Peak incidence occurs in the 5th and 6th decade. Two types of follicular carcinoma are

a). Encapsulated- less common

b). Invasive mass

Encapsulated form is called angioinvasive encapsulated carcinoma. Hemorrhages, cystic degeneration and necrosis are common. Microscopically, picture is that of adenocarcinoma with considerable change in size and differentiation of glands. Blood spread

occurs in 70percent of cases. Commonest sites are lungs, bones, brain, etc. Regional lymph nodes are involved in only 5percent of cases.

Anaplastic Carcinoma

- Usually occurs in 7th and 8th decades of life. It's a rapidly growing, locally infiltrative tumor with very poor prognosis.
- It spreads by lymphatics and by blood stream. Two histological types are small cell carcinoma and giant cell carcinoma. One year survival is about 20percent.

Medullary Carcinoma

- Derived from parafollicular cells (C Cells). It's an APUDoma. 80percent occurs sporadically, usually in adults.

- 10-20percent occurs in children and teenagers with associated symptoms.
- MEN II b: MEN IIa + Mucosal neuroma, marphanoid features, aganglioneurosis.
- 90percent of patients secrete calcitonin, less frequently histamine, prostaglandins, ACTH and serotonin are secreted.
- It may present as a single nodule or multiple nodules.
- Sporadic forms occur in 5-6 decades, often present in advanced stage. Familial forms present in second decade, associated endocrine abnormalities bring the patient early.
- Diarrhea is present in upto 30percent of patients.
- Metastasis is usually to regional nodes (50percent), lung, liver and bone.
- Medullary carcinoma is not TSH dependent.
- It does not take Radioiodine.

- Stimulating calcitonin secretion by pentagastrin and calcium infusions can make diagnosis of medullary carcinoma.

THYROIDITIS

Hashimoto's thyroiditis

It's an autoimmune thyroiditis. It's the commonest cause of goitrous hypothyroidism I places where iodine intake is adequate. It's a major cause of non endemic goitre in children. The goitre is due to thyroid growth stimulating immunoglobulins like autoantibodies to thyrotrophin receptors, follicular microsomes, and thyroglobulin.

Thyroid parenchyma is replaced by fibrous tissue because of the infiltration by lymphoid cells, so eventually hypothyroidism develops. Sometimes in the mid course, patient may develop thyrotoxicosis called hashitoxicosis.

More common in women at menopausal age, usually both lobes are involved. Nevertheless one lobe is larger than the other. It's lobulated, rubbery in consistency.

It may be associated with pernicious anemia, vitiligo, rheumatoid arthritis, etc.

Histology:

Excessive replacement of parenchyma by lymphocytes, plasma cells, macrophages and lymphoid germinal centres.

Follicular cells are transformed into easinophilic granular cytoplasmic cells called Hurthle cells (or) Oncocytes (or) Askanazy cells

HASHIMOTO'S DISEASE

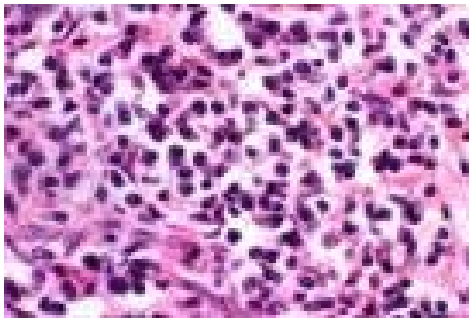

Diagnosis rests on measurement of serum autoantibody, by Radio immuno assay. It's positive in over 85% of cases.

Lymphoma may develop in Hshimoto's thyroiditis.

DIAGNOSTIC AIDS

Diagnosing thyroid disease is a process that can incorporate numerous factors, including clinical evaluation, blood tests, imaging tests, biopsies, and other tests.

CLINICAL EVALUATION

A critical part of detecting and diagnosing thyroid disease is the clinical evaluation conducted by a trained practitioner. As part of a thorough clinical evaluation, your practitioner typically should do the following:

- Feel (also known as “palpating”) your neck.
- Listen to your thyroid using a stethoscope.
- Test your reflexes.
- Check your heart rate, rhythm and blood pressure.
- Measure your weight.
- Measure body temperature.
- Examine your face.
- Examine your eyes.
- Observe the general quantity and quality of your hair.
- Examine your skin.

- Examine your nails and hands.
- Review other clinical signs

THYROID BLOOD TESTS

The blood tests that may be done as part of a thyroid diagnosis include the following:

- Thyroid Stimulating Hormone (TSH) Test
- Total T4/ Total Thyroxine
- Free T4 / Free Thyroxine
- Total T3 / Total Triiodothyronine
- Free T3 / Free Triiodothyronine
- Thyroglobulin/Thyroid Binding Globulin/TBG
- T3 Resin Uptake (T3RU)
- Reverse T3
- Thyroid Peroxidase Antibodies (TPOAb) / Antithyroid Peroxidase Antibodies
- Antithyroid Microsomal Antibodies / Antimicrosomal Antibodies
- Thyroglobulin Antibodies / Antithyroglobulin Antibodies
- Thyroid Receptor Antibodies (TRAb)
- Thyroid-Stimulating Immunoglobulins (TSI)

THYROID IMAGING TESTS

A number of imaging tests are performed for diagnosis of various thyroid conditions. These tests include:

- Nuclear Scan / Radioactive Iodine Uptake (RAI-U) – which can tell whether a person has Graves' disease, toxic multinodular goitre, or thyroiditis.
- CT scan – to help detect and diagnose a goiter, or larger thyroid nodules.
- MRI / Magnetic Resonance Imaging – to evaluate the size and shape of the thyroid
- Thyroid Ultrasound – to evaluate nodules, lumps and enlargement of your gland. Ultrasound can tell whether a nodule is a fluid-filled cyst, or a mass of solid tissue.

THYROID BIOPSY/ASPIRATION

A needle biopsy, also known as fine needle aspiration (FNA) is used to help evaluate lumps or cold nodules. In a needle biopsy, a thin needle is inserted directly into the lump, some cells are withdrawn and they are evaluated for cancer. (Some practitioners use ultrasound while conducting a biopsy in order to ensure that the needle goes into the right

position.) Cancer can be definitively diagnosed about 75 percent of the time from FNA. Evaluation of biopsy results can also show cells indicative of Hashimoto's thyroiditis.

OTHER DIAGNOSTIC TESTS AND PROCEDURES

Practitioners sometimes use other diagnostic tests and procedures to identify thyroid dysfunction. The use of these tests is considered controversial to mainstream practitioners, but many of these tests are well-accepted and in use among alternative, integrative and holistic physicians. These tests include:

- Iodine Patch Tests
- Saliva Testing
- Urinary Testing
- Basal Body Temperature Testing

INDICATIONS FOR SURGERY

Thyroid surgery (thyroidectomy) may be required if there is:

- A lump that could be a malignant tumor (thyroid cancer). This is usually determined by a fine needle biopsy of the lump. Clinical suspicion, including age, male sex, hard texture, fixity, recurrent laryngeal nerve palsy and lymphadenopathy.
- A goitre (enlargement of the thyroid) causing pressure on surrounding organs resulting in symptoms such as difficulty swallowing, difficulty breathing or a persistent cough.
- Growth of your thyroid down into the chest cavity (a retrosternal goitre)

- Excessive activity of the thyroid (hyperthyroidism or thyrotoxicosis)
- Recurrence cyst- A fluid filled (cystic) nodule returns after being drained once or twice
- Cosmetic reasons.
- Patient's wishes.

SURGICAL OPTIONS FOR THYROID GLAND

All thyroid operations can be assembled from three basic elements:

- Total lobectomy
- Isthmusectomy
- Subtotal lobectomy

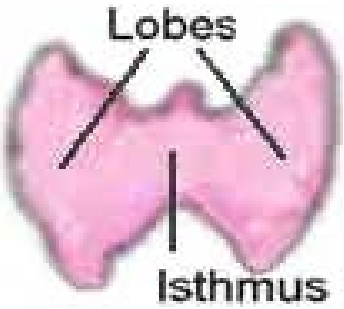

Partial Thyroid Lobectomy.

This operation is not performed very often because there are not many conditions which will allow this limited approach. Additionally, a benign lesion must be ideally located in the upper or lower portion of one lobe for this operation to be a choice.

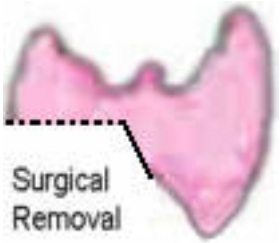

Thyroid Lobectomy.

This is typically the "smallest" operation performed on the thyroid gland. It is performed for solitary dominant nodules which are worrisome for cancer or those which are indeterminate following fine needle biopsy. Also appropriate for follicular adenomas, solitary hot or cold nodules, or goiters which are isolated to one lobe (not common).

Thyroid Lobectomy with Isthmusectomy

This simply means removal of a thyroid lobe and the isthmus (the part that connects the two lobes). This removes more thyroid tissue than a simple lobectomy, and is used when a larger margin of tissue is needed to assure that the "problem" has been removed.

Appropriate for those indications listed under thyroid lobectomy as well as for Hurthle cell tumors, and some very small and non-aggressive thyroid cancers.

Subtotal Thyroidectomy

Just as the name implies, this operation removes all the "problem" side of the gland as well as the isthmus and the majority of the opposite lobe. This operation is typical for small, non-aggressive thyroid cancers. Also a common operation for goiters which are causing problems in the neck or even those which extend into the chest (substernal goiters).

Total Thyroidectomy

This operation is designed to remove all of the thyroid gland. It is the operation of choice for all thyroid cancers which are not small and non-aggressive in young patients. Many (most?) surgeons prefer this complete removal of thyroid tissue for **all** thyroid cancers regardless of the type.

SUMMARY

- Total thyroidectomy = 2 x total lobectomy + isthmusectomy
- Subtotal thyroidectomy = 2 x subtotal lobectomy + isthmusectomy

- Near-total thyroidectomy= total lobectomy+ isthmusectomy+subtotal lobectomy
- Hemi-thyroidectomy = total lobectomy + isthmusectomy

DEFINITION

Terminology for thyroid surgery is inconsistent in the literature.

According to Bailey & Love

Near – total thyroidectomy = total lobectomy + isthumectomy + subtotal lobectomy.

According to Sabiston textbook of surgery,

Near – total thyroidectomy involves complete dissection on one side while leaving a remnant of thyroid tissue laterally on the contralateral side which incorporates the parathyroids.

According to Nyhus Mastery of surgery,

A near – total thyroidectomy leaves less than 1g(1cm) of thyroid tissue on one side of the neck wherein a minute

portion of thyroid is purposely left in situ, in close proximity to the recurrent laryngeal nerve or parathyroid gland, when it is deemed unsafe to do otherwise.

Based on the above definitions, in this study,

Near – total thyroidectomy means removal of almost whole of thyroid gland leaving behind negligible amount of thyroid tissue in order to avoid recurrent laryngeal nerve injury and to preserve atleast one parathyroid.

OPERATIVE PROCEDURE

PREOPERATIVE PREPARATION

Patients with any recent or remote history of altered phonation or prior neck surgery should undergo vocal cord asessment by direct or indirect laryngoscopy prior to thyroidectomy. Prophylactic antibiotics are not used routinely.

CONDUCT OF THYROIDECTOMY

Thyroidectomy is performed under general anesthesia. The patient is positioned supine, with a sandbag between the scapulae. The head is placed on a donut cushion and the neck is extended to provide maximal exposure. A Kocher transverse incision, typically 4 to 5 cm in length, is placed in or parallel to a natural skin crease 1 cm below the cricoid cartilage. Longer incision may be needed in patients with large tumors, in patients with a short, flat neck or whose neck cannot be extended, and in patients with lowlying thyroid glands. The subcutaneous tissues and platysma are incised sharply and subplatysmal flaps are raised superiorly to the level of the thyroid catilage and inferiorly to the suprasternal notch. Towels are placed along the skin edges and a self retaining retractor is also applied. The strap muscles are divided in the midline along the entire length of the mobilized flaps and the thyroid gland is exposed. On the other side to be approached first, the sterohyoid muscles are seperated from the underlying sternothyroid muscle by by blunt dissection until

the internal jugular vein ansa cervicalis nerve are identified.

The strap muscles rarely need to be divided to gain exposure to the thyroid gland. If this maneuver is ncessary, the muscles should be divided high in order to preserve their innervation by branches of the ansa cervicalis. If there is evidence of direct tumor invasion into the strap muscles, the portion of involved muscle should be resected en bloc with the thyroid gland. The sternothyroid muscle is then dissected off the underling thyroid by a combination of sharp and blunt dissection, thus exposing the middle thyroid veins. The thyroid lobe is retracted medially and anteriorly and the lateral tissues are swept posterolaterally using a peanut sponge. The middle thyroid veins are ligated and divided. Attention is then turned to the midline where Delphian nodes and the pyramidal lobe are identified. The fascia just cephalad to the isthumus is divided. The superior thyroid pole is is identified by retracting the thyroid first inferiorly and medially, and then the upper pole of the thyroid is mobilized caudally and laterally. The dissection plane is kept as close to the thyroid as possible and the superior pole vessels are individually identified, skeletonized, ligated and divided low

on the thyroid gland, to avoid injury to the external branch of the superior laryngeal nerve. Once these vessels are divided, the tissues posterior and lateral to the superior pole can be swept from the gland, to reduce the risk of damaging vessels supplying the upper parathyroid. The recurrent laryngeal nerve should be then identified. The course of the right RLN is more oblique than the left RLN. The nerves can be most consistently identified at the level of the cricoid cartilage. The parathyroids can usually be identifeid within 1cm of the crossing of the inferior thyroid artery and the RLN.The upper parathyroid is dorsal to the RLN, whereas the lower parathyroid is anterior to it. If not present in this location, the lower glands may be found in thyrothymic ligament or the upper thymus. The lower pole of the thyroid gland should be mobilized by gently sweeping all tissues dorsally. The inferior thyroid vessels are dissected, skeletonized, ligated, and divided as close to the surface of the thyroid gland as possible, to minimize devascularization of the parathyroids (extracapsular dissection) or injury to the RLN. Any structure that could be the RLN should not be divided. The RLN is most

vulnerable to injury in the vicinity of the ligament of Berry. The nerve often passes through this structure, along with small crossing arterial and venous branches. Any bleeding in this area should be controlled with gentle pressure before carefully identifying the vessel and ligating it. Use of electrcautery should be avoided in the proximity to the RLN. Once the ligament is divided, the thyroid can be seperated from the underlying trachea by sharp dissection. The pyramidal lobe, if present, must be dissected in a cephalad direction to above the level of the notch in the thyroid cartilage or higher in continuity with the thyroid gland. If a lobectomy is to be performed, the isthumus is divided flush with the trachea on the contralateral side and suture ligated. The procedure is repeated on the opposite side for a total thyroidectomy. A near total thyroidectomy leaves less than 1gm (1cm) of thyroid tissue on one side of the neck. It is performed when a minute portion of thyroid is purposely left in situ, in close proximity to the recurrent laryngeal nerve or parathyroid gland.

Parathyroid glands that are located anteriorly on the surface of the thyroid, cannot be dissected from the thyroid with a good blood supply, or have been inadvertently removed during the thyroidectomy, sholud be resceted, confirmed as parathyroid tissue by frozen section, divided into 1-mm fragments, and reimplanted into individual pockets in the sternocleidomastoid muscle. The sites should be marked with silk sutures and a clip. If a subtotal thyroidectomy is to be performed, once the superior vessels are divided and the thyroid lobe mobilized anteriorly, the thyroid lobe is cross-clamped with a Mayo clamp, leaving approximately 4g of the posterior portion of the thyroid. The thyroid remnant is suture ligated, taking care to avoid injury to the recurrent laryngeal nerve. Routine drain placement is rarely necessary. After adequate hemostasis is obtained, the strap muscles are reapproximated in the midline using absorbable sutures. The platysma is approximated in a similar fashion. The skin can be closed with subcuticular sutures or clips.

COMPLICATIONS OF THYROID SURGERY

Possible complications following thyroid surgery are:

- **Bleeding:** may cause tracheal compression
- **Recurrent laryngeal nerve injury:**
  - Innervates all of the intrinsic muscles of the larynx, except the cricothyroid muscle
  - Patients with unilateral vocal fold paralysis present with postoperative hoarseness
  - Presentation is often subacute and voice changes may not present for days or weeks
  - Unilateral paralysis may resolve spontaneously
  - Bilateral vocal fold paralysis may occur following a total thyroidectomy, and usually presents immediately after extubation
  - Both vocal folds remain in the paramedian position, causing partial airway obstruction.
- **Hypoparathyroidism:** the resulting hypocalcaemia may be permanent but is usually transient. The cause of transient hypocalcaemia postoperatively is not clearly understood.

- **Injury to trachea.**
- **Thyrotoxic storm:** is an unusual complication of surgery but is potentially lethal
- **Superior laryngeal nerve injury:**
    - The external branch provides motor function to the cricothyroid muscle
    - Trauma to the nerve results in an inability to lengthen a vocal fold and thus to create a higher-pitched sound
    - The external branch is probably the most commonly injured nerve in thyroid surgery
    - Most patients do not notice any change but the problem may be career-ending for a professional singer.
- **Infection:** occurs in 1-2% of all cases. Pre-operative antibiotics are not recommend for thyroid surgery.
- **Hypothyroidism.**
- **Hypertrophic scar / Keloid scar.**
- **Tracheomalacia.**

LONG TERM FOLLOW UP

After the first preoperative visit, patients with pathologically confirmed benign disease could be returned to the care of their primary care physician and/or their Endocrinologist.

The surgeon often follows the patients with confirmed thyroid cancer every six months for 2 years and then annually thereafter if thyroglobulin, RAI scans, cervical ultrasound and clinical follow-up remain negative for recurrent disease.

Thyroid hormone replacement should aim for a TSH-level within the normal range for patients requiring a suppressive dose for benign disease, less than 0.1mIU/L for low risk patients with thyroid cancer and 0.05mIU/L or slightly lower for all other patients with differentiated thyroid cancer. TSH should be assessed 5 to 6 weeks after a new dose is commenced to ensure the appropriate target level is reached. The pregnant women with a previous total thyoidectomy may require upto 25% more thyroid hormone replacement during pregnancy to achieve these TSH goals. Surgeons caring for patients with thyroid disease should be comfortable with managing the medical and surgical elements of these disease treatment and follow-up.

MATERIALS AND METHODS

DESIGN:

A single institution study done during the period from May 2006 to October 2008 in the Department of Surgery, Government Rajaji Hospital, Madurai. All the patients admitted in Government Rajaji Hospital were examined

clinically and patients with thyroid swellings were selected for the study.The results of the study is compared with complication rates of bilateral subtotal and total thyroidectomy reported in the literature.

SETTING:

Tertiary academic referral centre.

PATIENT:

One hundred patients who underwent near-total thyroidectomy for various thyroid diseases.

CRITERIA FOR SELECTION OF PATIENT

A patient with

- ✓ Non-toxic, non-malignant Multi Nodular Goitre,
- ✓ CA thyroid except anaplastic type.
- ✓ Primary and Secondary Thyrotoxicosis patients.

The efficacy and effectiveness of near total thyroidectomy(NTT) is compared with subtotal thyroidectomy (STT) and total thyrodectomy(TT) by using the incidence of complications as parameters. The following complications are used as parameters:

- Temporary hypocalcemia
- Tempoary recurrentlaryngeal nerve(RLN)injury
- Permanent hypocalcemia
- Permanent RLN injury
- Recurrence

RESULTS

This is a study of 100 patients who underwent NTT ,as per our norms, in Government Rajaji hospital, Madurai from May 2006 to October 2008.

PATIENTS:

Of the chosen 100 patients, 85 were female and 15 were male, a striking female preponderance.

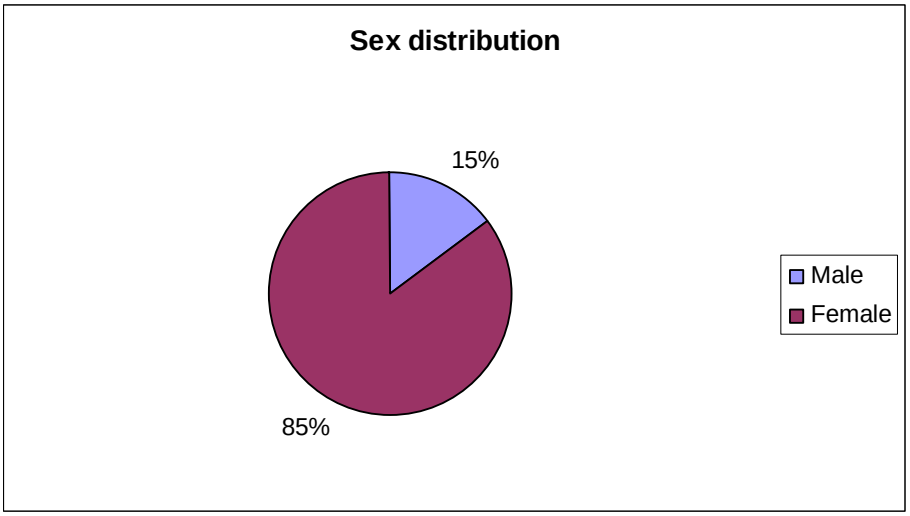

AGE:

The average age of the pt is 35.82 years.

The average age of the female pt is 35.19 years.

The average age of the male pt is 39.4 years.

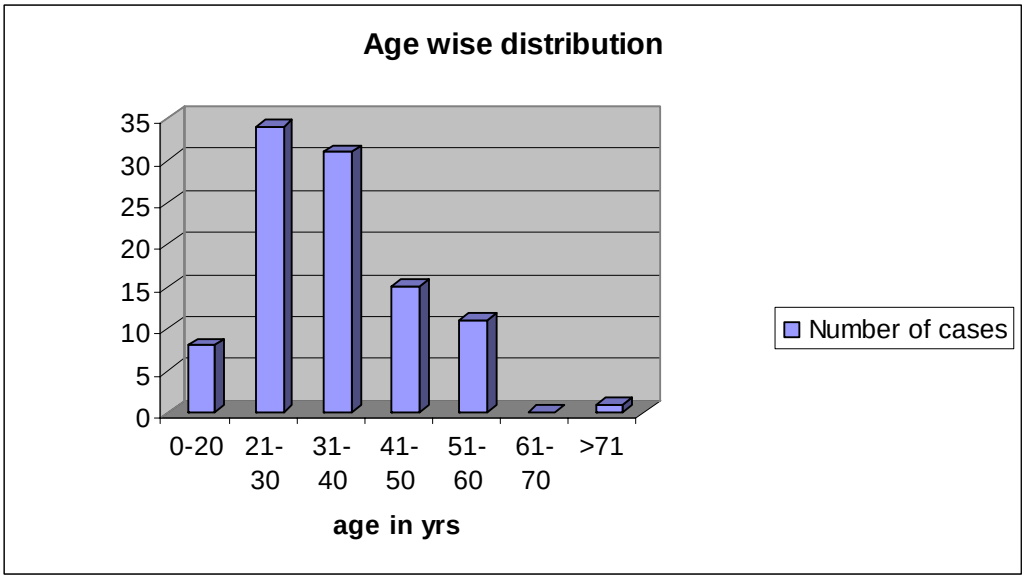
Age wise distribution
35
30
25
20
15
10
5
0
0-20
21-30
31-40
41-50
51-60
61-70
>71
age in yrs
Number of cases

SYMPTOM:

The most common presenting symptom/complaint is swelling in the neck and the next to follow is features suggestive of hyperthyroidism.

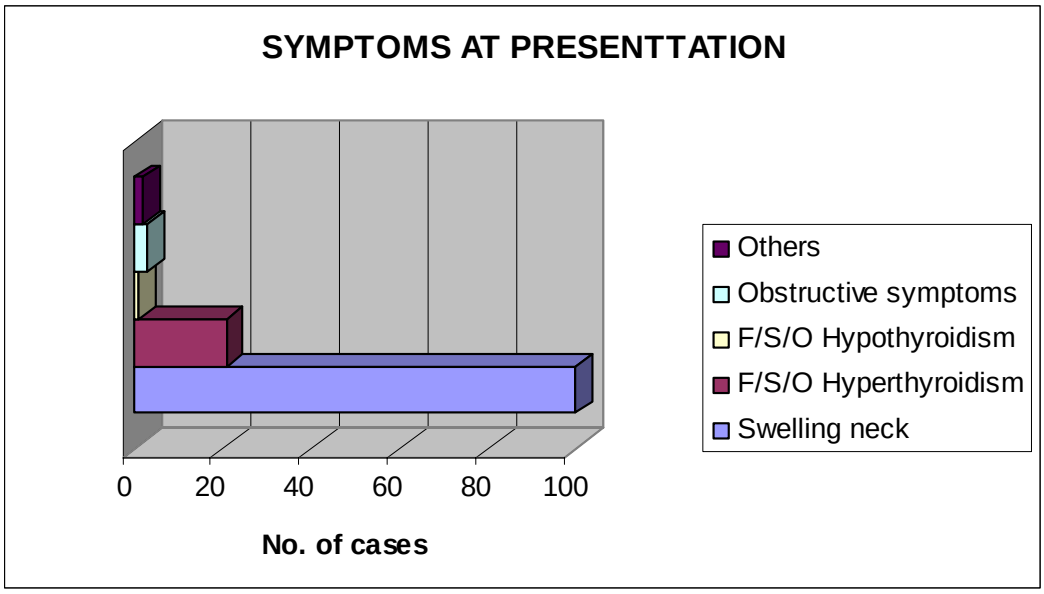

FINAL DIAGNOSIS:

Of the 100 patients, 62 were non-toxic non malignant MNG, 19 were papillary CA thyroid, 17 were MNG with Secondary thyrotoxicosis and 2 were primary thyrotoxicosis .

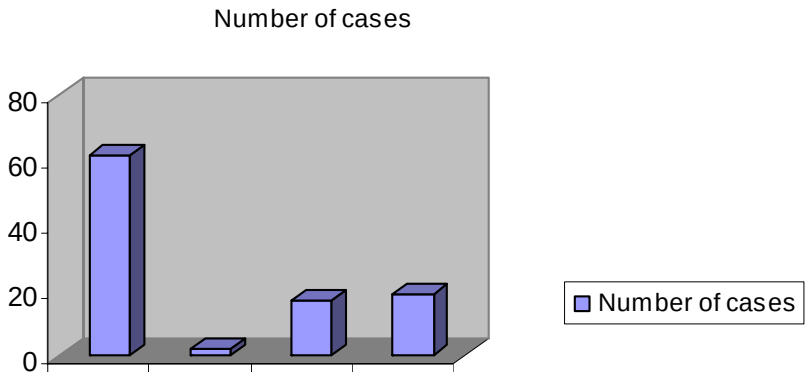

	Non toxic MNG	Primary thyrotoxicosis	Secondary thyrotoxicosis	Papillary Ca

Number of cases	62	2	17	19

SURGERY DONE:

NTT is done in all the 100 pts. Among them in 4 pts , in addition to NTT , MRND type 3 done.

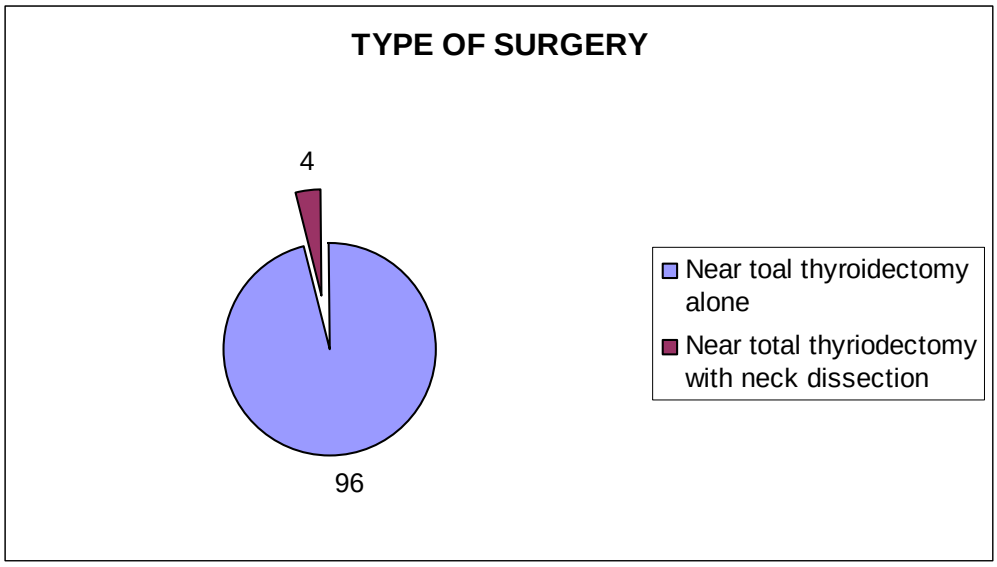

COMPLICATION RATE:

Post operatively , 8% of cases developed temporary hypocalcemia and 4% ofcases developed temporary recurrent laryngeal nerve(RLN) injury and recovered completely. There was no incidence of permanent hypocalcemia and permanent RLN injury. Within our study period, we were not able to find any recurrence.

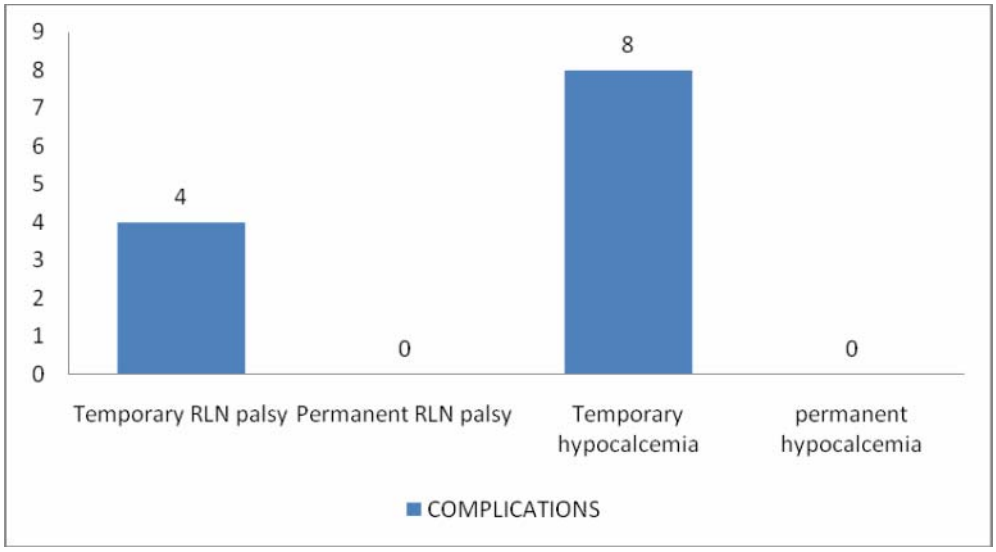

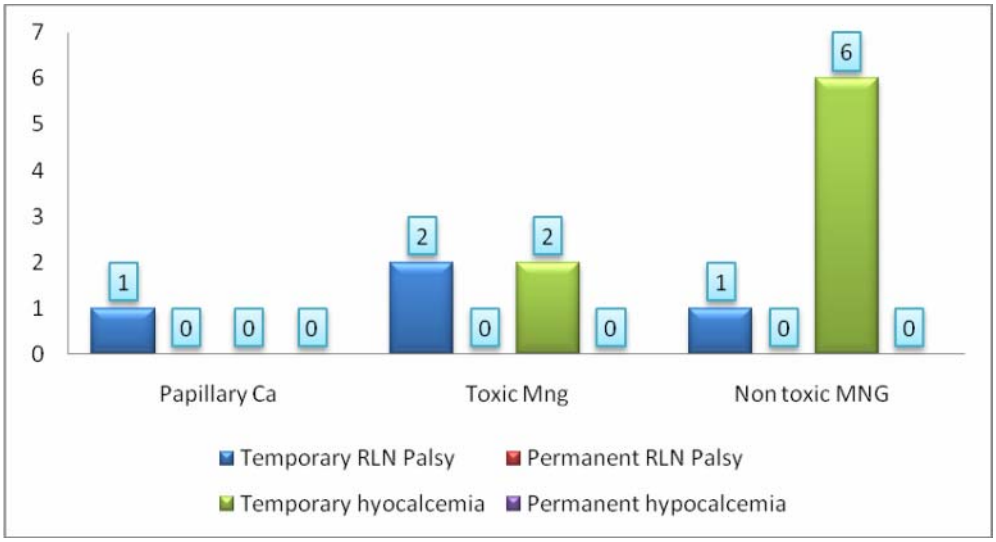

DISCUSSION

1. According to OZBAS et al:

When NTT performed 12.2% of cases developed temporary hyocalcemia and 0.6 % transient voice changes.

When STT performed, temporary hypocalcemia occurred in 8.2% of cases and temporary RLN injury in 2.4% of cases.

When TT performed,30% of cases developed temporary hypocalcemia, 1.9% of cases developed temporary RLN injury, permanent hypocalcemia developed in 0.4% of cases and permanent RLN palsy in 0.6% of cases.

2. According to Zeki Acun et al:

Temporary hypocalcemia occurred in 7.2% of cases and temporaryRLN palsy withrespect to nerves at risk was 3.3% and neither permanent hypoparathyroidism nor permanent RLN injury occurred when NTT performed for benign thyroid diseases . and

3. According to Colak et al:

When STT was performed temporary hypocalcemia occurred in 9.5% of cases and temporary RLN palsy in 1.9% of cases.

When TT was performed temporary hypocalcemia and temporary RLN palsy occurred in 11.4% and 9.3% respectively. No incidence of permanent hypocalcemia but permanent RLN injury occurred in 0.95% of cases.

4. According to Mishra et al :

When TT was performed , temporary hypocalcemia occurred in 32.3% of cases, temporary RLN injury in 4.7% of cases, permanent hypocalcemia in 1.6% of cases and permanent RLN palsy occurred in 0.8% of cases.

5. According to Sarda.A.k. et al:

NTT was performed in 126 patients thyroid cancer. Multicentric foci of tumour were seen in 17.2% of the well differentiated cancers and 25.2% ofcases of well differentiated cancers who underwent NTT developed loco-regional reccurence. In our patients from endemic goitrous area, NTT is the treatment of choice.

6. According to our study:

When NTT was performed, temporary hypocalcemia occurred in 8% of cases and temporary RLN palsy occurred in 4% of cases. No incidence of permanent hypoparathyroidism or permanent RLN injury. Within our limited study period, there was no reccurrence.

		Temporary Hypocalcemia	**Temporary RLN Palsy**	**Permanent Hypocalcemia**	**Permanent RLN palsy**
Ozbas S et al	STT	8.2%	2.4%	0%	0%

(N=750)	NTT	12.2%	0.6%	-	-
	TT	30%	1.9%	0.4%	0.6%
Colak et al (N=200)	STT	9.5%	6.3%	0%	0%
	TT	11.4%	9.3%	0%	0.95%
Mishra et al	TT	32.3%	4.7%	1.6%	0.8%
Zeiki Acun et al	NTT	7.2%	3.3%	-	-
In this study	NTT	8%	4%	0%	0%

NTT - Near total thyroidectomy

STT - Sub-total thryoidectomy

TT - Total Thyroidectomy

CONCLUSION

- NEAR TOTAL THYROIDECTOMY is better than subtotal thyroidectomy as it has very low recurrence rate comparable morbidity and better post op manipulation of thyroid hormone status.

- When compared to total thyroidectomy, NEAR TOTAL THYROIDECTOMY has similar recurrence rate but distinctly better than TT in terms of very low morbidity.

- As per our study, NEAR TOTAL THYROIDECTOMY is the best as it has very low morbidity and very low, literally, no recurrence rate.

PREOPERATIVE PICTURE

INTRAOPERATIVE

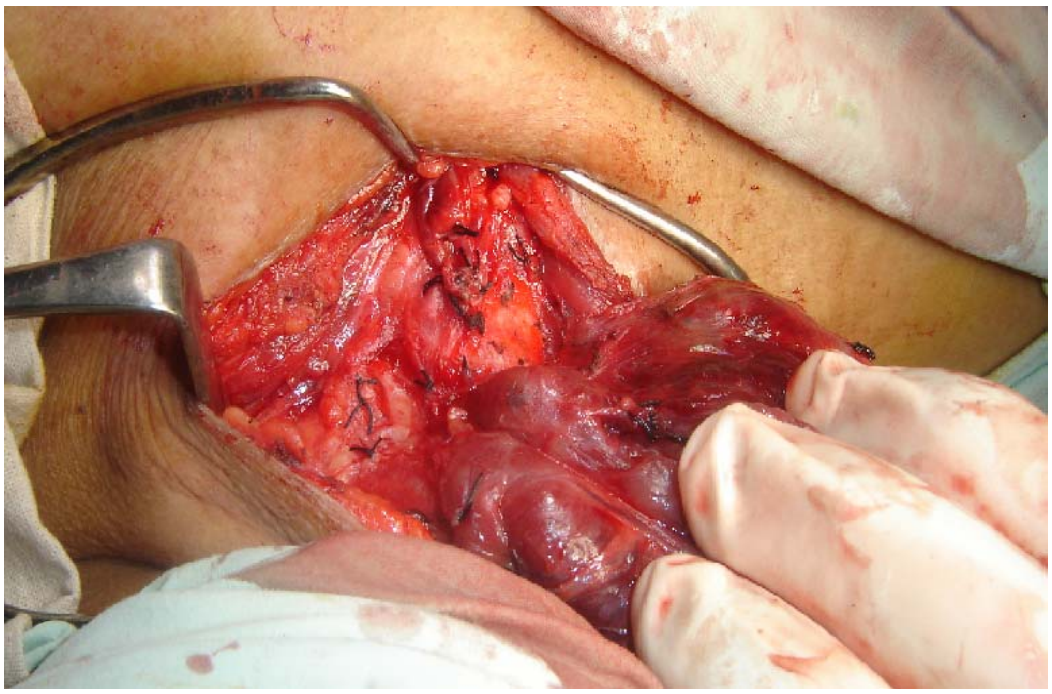

COMPLETION OF NTT

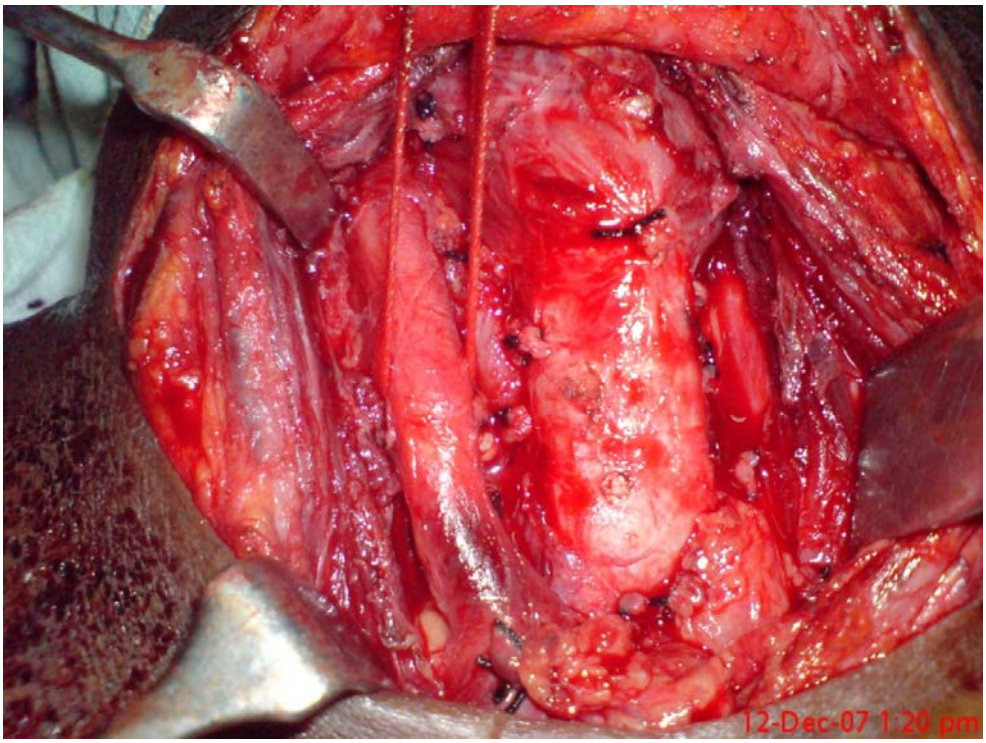

AFTER KEEPING A DRAIN

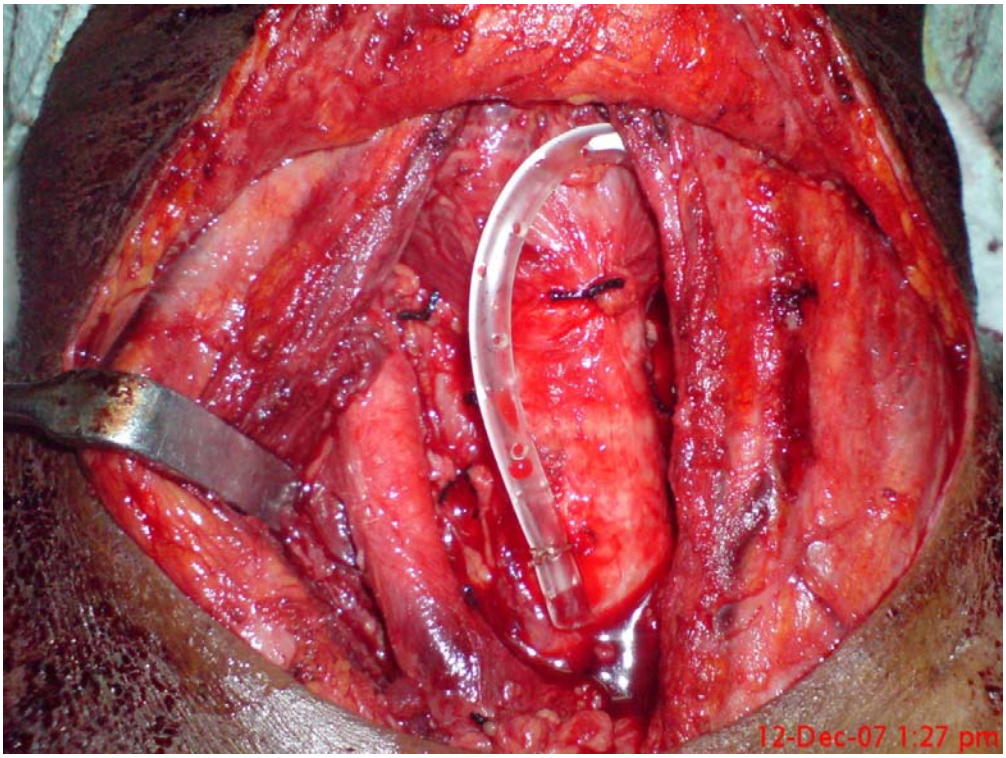

EMBRYOLOGY OF THYROID

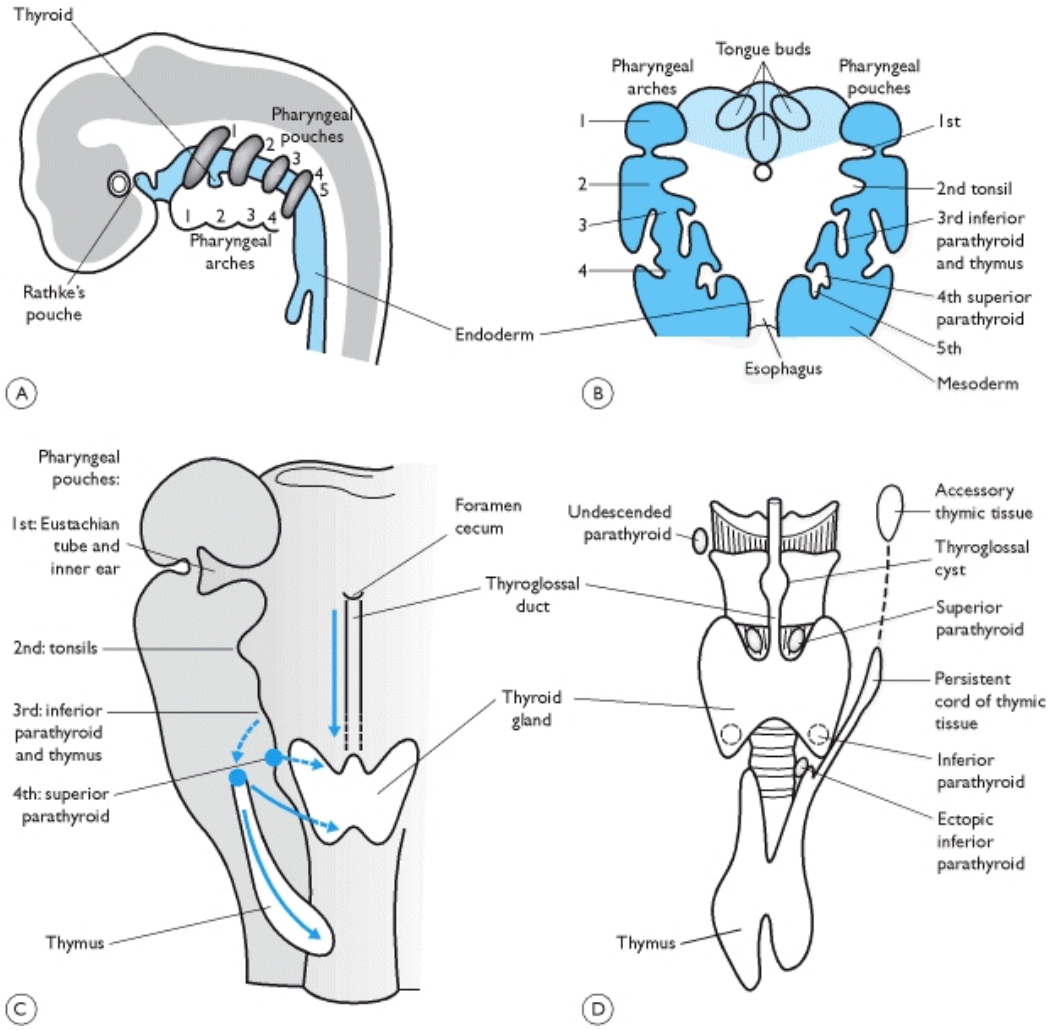

HYPERPLASTIC THYROID

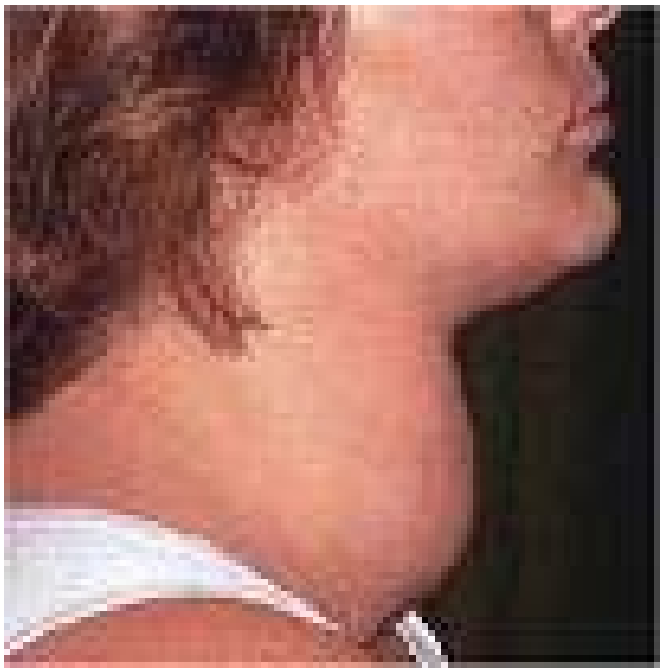

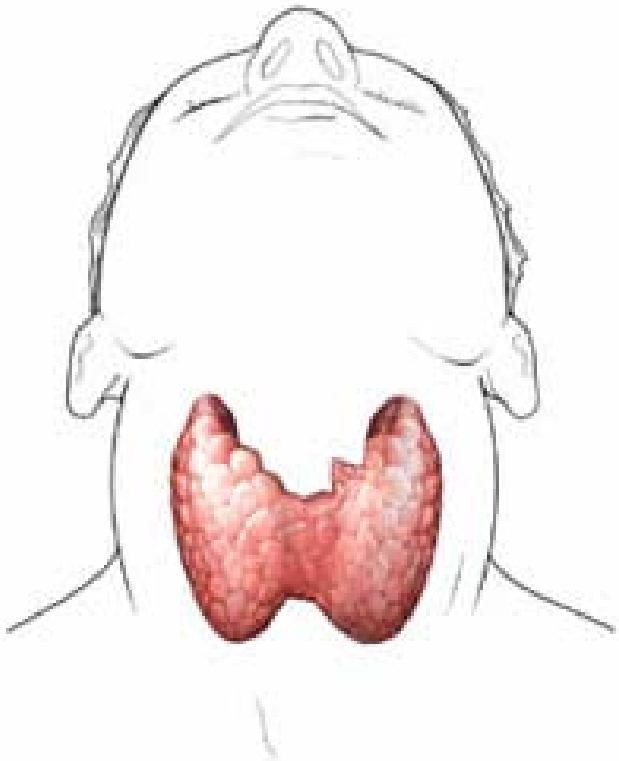

MULTINODULAR GOITRE

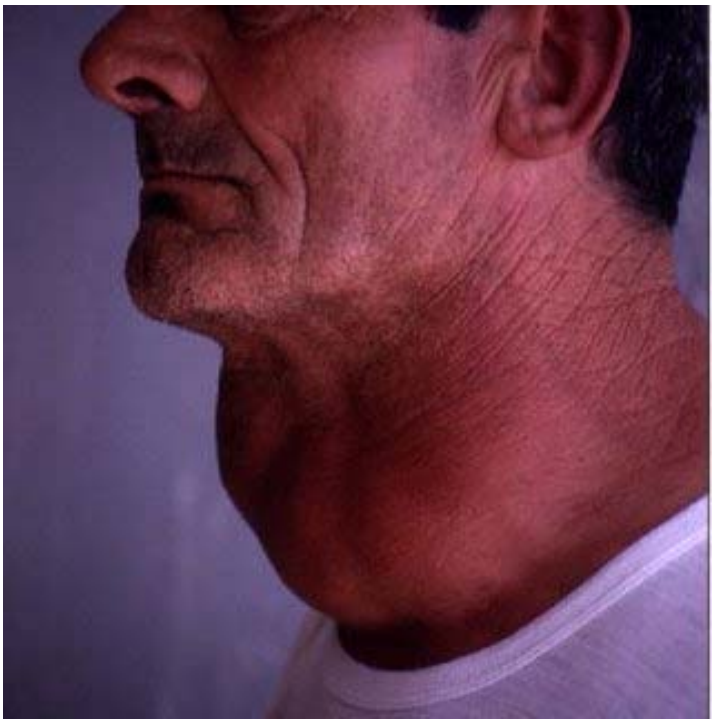

Exophthalmos (bulging eyes)

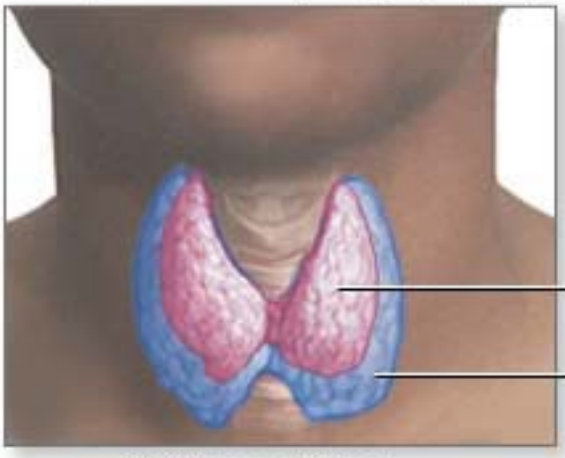

Diffuse goiter

TOXIC ADENOMA

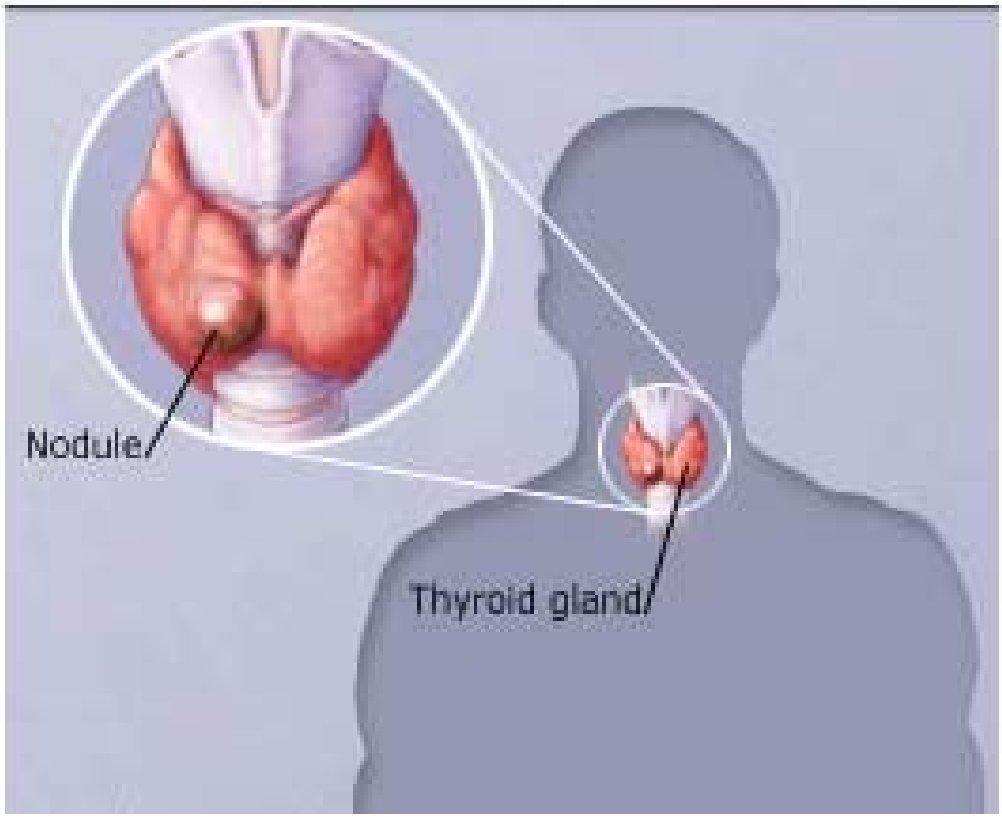

PAPILLARY CARCINOMA

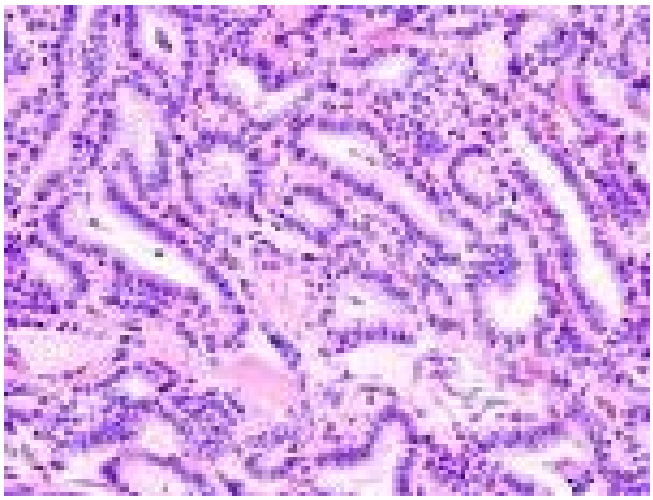

Focally, short papillae lined by cells exhibiting Papillary Ca-

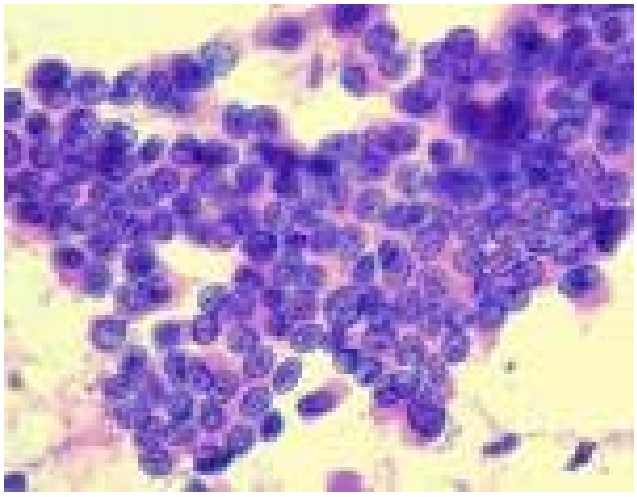

Orphan annie eyed nuclei features of papillary Ca are identified permitting the correct diagnosis to be made.

FOLLICULAR CARCINOMA

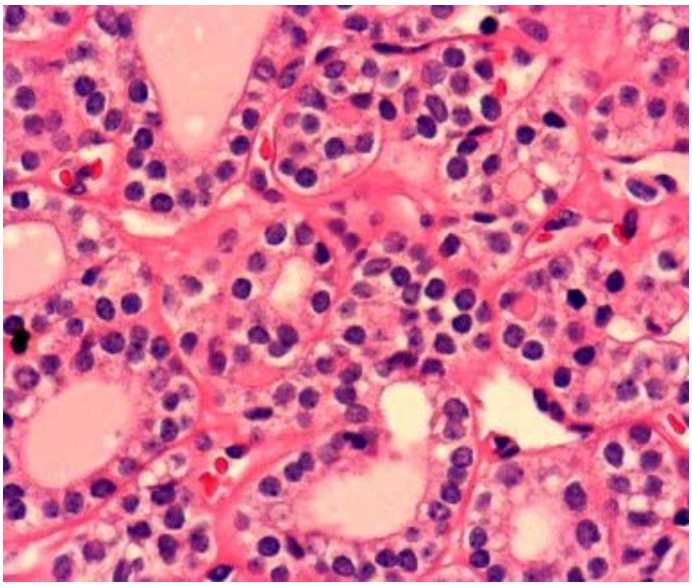

In follicular carcinoma there is invasion of adjacent thyroid parenchyma, blood vessels or capsule with usually uniform cells with absence of nuclear features of papillary carcinoma.

ANAPLASTIC CARCINOMA

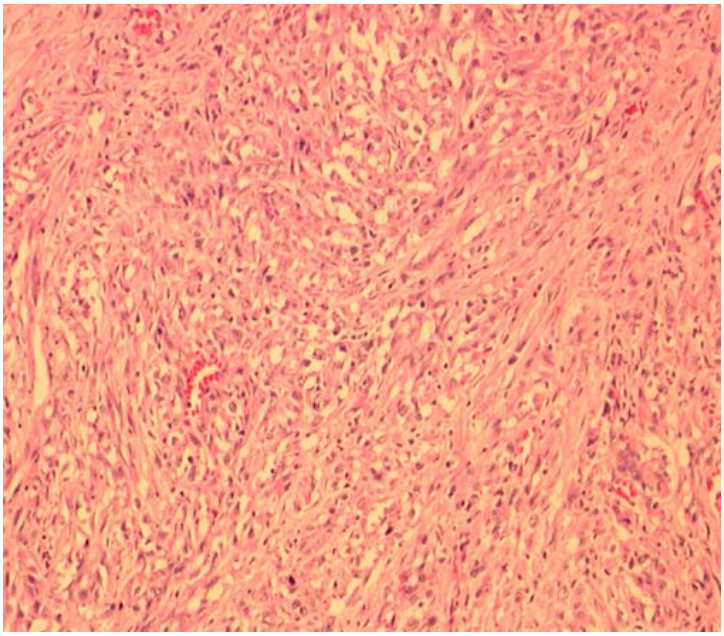

The tumor is solid growing lacking organoid features. Coagulative necrosis is a common finding

MEDULLARY CARCINOMA

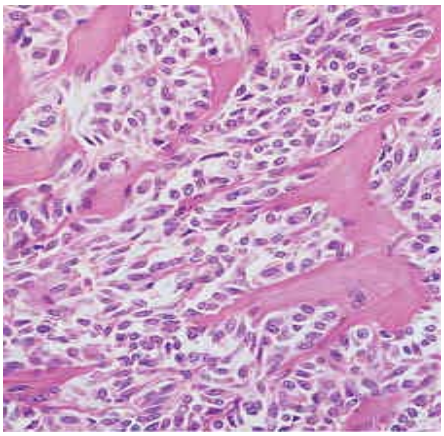

Low-power microscopic view showing solid pattern of growth and deposition of amyloid.

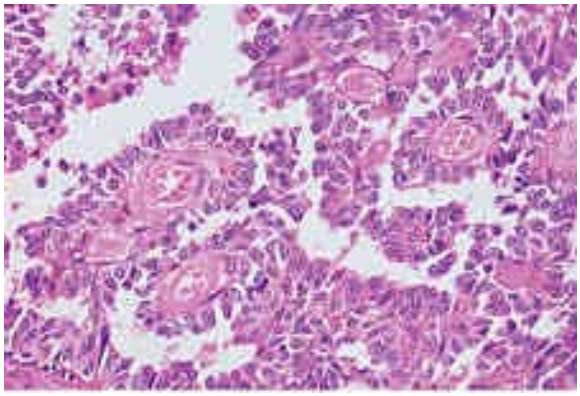

Medullary carcinoma with pseudopapillary pattern of growth resulting from lack of cohesiveness of tumor cells.

BIBLIOGRAPHY

1. Bailey and Love's practice of surgery
2. Sabiston's text book of surgery
3. Schwartz principles of surgery
4. Nyhus and Baker Mastery of surgery
5. Current surgical diagnosis and treatment
6. Farquharson's text book of operative surgery
7. Head and Neck surgery by P.M. Stell A.G.D. Maran
8. Alfred Cuschieri's surgical text book
9. Harrison's internal Medicine
10. Chaursia Human Anatomy
11. Ganong Medical Physiology
12. The clinical chemistry by Joan F.Zilva
13. Anderson's pathology
14. Robin's Pathological Basis of Disease
15. Ca Thryoid Modalities of Therapy, Surgical clinics of North America 169-174. (1973)
16. Ozbas S, et.al., "Comparison of the complications of subtotal, near total and total thyroidectomy in the surgical management of multinudular goiter. "Endocr. J. 2005 Apr; 52(2): 199-205.

17. Colak, Tahsin, Akca, Tamer, Kanik, Arzu, Yapici, Davud & Aydin, Suha (2004) Total versus subtotal thyroidectomy for the management of behign multinodular goiter in an endemic region. ANZ Journal of Surgery 74(11), 974-978.
18. Mishra A, Agarwal A, Agarwal G, Mishra SK. Total thyroidectomy for benign thyroid disorders in an endemic region. World J. Surg 2001. 25, 307-310.
19. Acun A, Cihan A, Ulukent SC, Comert M, Ucan B, Cakmar GK, Cesur A.A randomized prospective study of complications between general surgery residents and attending surgeons in near – total thyroidectomies. Surg Today. 2004;34(12):997-1001.
20. Mishra A, Agarwal G, Agarwal A, Mishra SK. Safety and efficacy of tota thyroidectomy in hands of endocrine surgery trainees. Am J Surg. 1999 Nov; 178(5): 377-80.
21. Jonas Rojdmark, Johannes Jarhult. High long term recurrence rate after STT for nodular goiter. Eur J Surg 1995; 161: 725-727.
22. The American Thyroid association guideline for management of differentiated thyroid cancer <www.liebertonline. com/doi/pdf/10.1089/ thy.2006. 16. ft-1? cookieset=1>
23. 25. Sarda AK, Bal S, Kapur MM. Near-total thyroidectomy for carcinoma of the thyroid. Br. J. Surg 1989; 76:90-92.

24. Acun A, Comert M, Cihan A, Ulukent SC, Ucan B, Cakmar GK. Near total thyroidectomy could be better treatment for thyroid diseases in endemic regions. Arch Surg 2004; 34:444-447.

S. No.	Name	Age	Sex	MR No	Socioeconomic Status	History	Examination	Diagnosis	FNAC	X Ray	USG Neck	TFT	Others	Surgery	Findings	Complications	Final Diagnosis	Follow up
1	Aruna	24	F	442229	Low	Swelling neck x 3yrs;F/S/O hyperthyroidism present	20x15cm swelling,firm,nodular.Right lobe more enlarged than left.	Secondary thyroto xicosis	Inconclusive	NAD	MNG	T3,T4 raised and TSH decreased		Near total thyroidectomy		Hypocalcemia present.Recovered post op	MNG with Toxicosis	Uneventful
2	Vani	25	F	463908	Low	Swelling neck x 2 yrs	2x3cm swelling,nodular,firm	MNG	Inconclusive	NAD	MNG	Normal		Near total thyroidectomy		Hypocalcemia present.Recovered post op	MNG	Uneventful
3	Indira	47	F	478784	Low	Swelling neck	3x2cm swelling,nodular, firm	MNG	Inconclusive	NAD	MNG	Normal		Near total thyroidectomy		Hypocalcemia present.Recovered post op	MNG	Uneventful
4	Jeevarathinam	33	M	496729	Low	Swelling neck	4x2cm swelling,nodular, firm	MNG	Inconclusive	NAD	MNG	Normal		Near total thyroidectomy		Hypocalcemia present.Recovered post op	MNG	Uneventful
5	Senthi Lakshmi	24	F	35936	Low	Swelling neck x 2 yr	5x8cm swelling,nodular,firm	MNG	Follicular epithelial cells	NAD	MNG	Normal		Near total thyroidectomy		Hypocalcemia present.Recovered post op	MNG	Uneventful
6	Murugeswari	31	F	84411	Low	Swelling neck x2yrs;pain ;weight gain	4x3cm swelling	MNG	Follicular epithelial cells	NAD		Normal		Near total thyroidectomy		Hypocalcemia present.Recovered post op	MNG	Uneventful
7	Ponni	25	F	50798	Low	Swelling neck;palpitation and tremor x 45days	10x4cm swelling,more of right lobe;nodular;firm;lid retraction present	Toxic MNG	Follicular epithelial cells	NAD	MNG			Near total thyroidectomy	MNG	Hypocalcemia present.Recovered post op	Toxic MNG	Uneventful
8	Karupayee	28	F	50537	Low	Swelling neck x 1 year	Uniform enlargement of both lobes;variable consistency	MNG	Hashimoto's thyroiditis	NAD	R/O Colloid goiter	Normal		Near total thyroidectomy		Hypocalcemia present.Recovered post op	MNG	Uneventful
9	Muthumari	37	F	89281	Low	Swelling neck x15yrs	8x6 cm swelling;globular;bosellated;firm	MNG	Adenomatous goiter	NAD	Solitary nodule left lobe	Normal		Near total thyroidectomy		None	Papillary Ca	Uneventful

10	Indrani	57	F	71977	Low	Swelling neck x 2months	6x4cm swelling left lobe of thyroid;firm	Ca thyroid	Papillary pattern	NAD	Cyst right lobe;1.1x0.3cm nodule left lobe	Normal		Near total thyroidectomy		None	Papillary Ca	Uneventful
11	Selvaraj	36	M	52936	Low	Swelling neck x 4yrs	6x6cm globular swelling over the isthumus	Adenoma thyroid	Inconclusive	NAD	Mass left lobe			Near total thyroidectomy	Cystic to hard swelling	None	Papillary Ca	Uneventful
12	Anjammal	50	F	53653	Low	Swelling neck x12months	6x4cm swelling left lobe of thyroid;firm	Papillary Ca		NAD				Near total thyroidectomy		None	Follicular variant of papillary carcinoma	Uneventful
13	Muthu	30	F	44023	Low	Swelling neckx1month;primary amenorrhea	6x 5cm irregular swelling;sshort stature;porrly nourished	MNG with ? Turner's syndrome	Inconclusive	NAD	MNG	Normal	USG Abd:Uterus absent.Ovaries normal.	Near total thyroidectomy	4x3cm cyst in the lower pole of right lobe	None	MNG	Uneventful
14	Amudha	29	F	42546	Low	Cervical lymph node biopsy :Papillary Ca	4x3cm swelling in the left lobe of thyroid with enlarged left cervical lymph nodes	Ca thyroid	Inconclusive	NAD	Left lobe enlarged with cervical mets	Normal		Near total thyroidectomy with radical neck dissection		None	Papillary Ca	Uneventful
15	Paandu	75	M	30488	Low	Swelling neck x 8months	6x4cm swelling,irregular,firm,movement restricted,no nodes	Ca thyroid	Suspicious of malignancy	NAD	MNG	Normal		Near total thyroidectomy		None	Ca Thyroid	Uneventful
16	Senthilkumar	25	M	22516	Low	Dyspnoea x 6months,Swelling neck x 1 week,F/S/O hyperthyroidism present	15x4 cn swelling,soft,smooth,eye sighns present,tremors present	Primary thyrotoxicosis		NAD		T3,T4 raised and TSH decreased		Near total thyroidectomy		None	Primary thyrotoxicosis	Uneventful
17	Pandiammal	43	F	59778	Low	Swelling neck x 4months	3x3cm swelling right lobe	MNG	Follicular epithelial cells	NAD	MNG	Normal		Near total thyroidectomy		None	MNG	Uneventful
18	Pandiammal	28	F	77956	Low	Swelling neck x 7months	3x 3 cm swelling right lobe,globular	Solitary nodule right lobe	?Follicular neoplasm	NAD	3.2x1.4x1.5 nodule right lobe	Normal		Near total thyroidectomy		None	Papillary Ca	Uneventful

19	Aadhi Lakshmi	23	F	38248	Low	Swelling neck x 2 months	2x2cm cytic swelling left lobe,smooth surface	Solitary thyroid nodule	Inconclusive	NAD	2.2x1.4cm swelling with cystic degeneration	Normal		Near total thyroidectomy		None	Papillary Ca	Uneventful
20	Noorjehan	40	F	24378	Low	Swelling neck x 2years	6x4.5cm swelling,nodular,firm	MNG	Follicular epithelial cells in colloid background	NAD	MNG	Normal		Near total thyoidectomy		None	MNG	Uneventful
21	Rajeswari	18	F	27164	Low	Swelling neck x 6 months	8x6 cm swelling;nodular;firm	MNG	Follicular epithelial cells	NAD		Normal		Near total thyoidectomy	Tissue left on right side	None	MNG	Uneventful
22	Jeyalaksmi	42	F	21457	Low	Swelling neckx 1yr,Palpitation present	5.5x4cm swelling,smooth,firm	MNG	Inconclusive	NAD	MNG	Normal		Near total thyroidectomy		None	MNG	Uneventful
23	Regina Mary	50	F	21448	Low	Swelling neck x 5 yr.Dyspnoea,difficulty in deglutition and palpitation present	6x5cm swelling ,nodular,firm	MNG	Follicular epithelial cells	NAD	MNG	T3,T4 normal and TSH increased		Near Total thyroidectomy		None	MNG	Uneventful
24	Saroja	45	F	102888	Low	Swelling neck x 3 weeks.F/S/O hyperthyroidism present	6x4 cm swelling,firm,nodular	MNG	Follicular epithelial cells	NAD	MNG	Normal		Near total thyoidectomy		None	MNG	Uneventful
25	Gowri	28	F	97382	Low	Swelling neck x 3 months.Palpitation presnet on and off	4x3cm swelling right lobe;1x1cm nodule in the left lobe;nodular,firm	MNG	Follicular epithelial cells	NAD	2.4x1.8cm nodule right lobe.0.7x0.5cm nodule on the left lobe	Normal		Near total thyroidectomy		None	MNG	Uneventful
26	Soorya	18	F	94495	Low	Swelling neck x 5yrs.F/S/O hypothyroidism present	5x3.5cm swelling,firm,nodular	MNG	Papillary fronds seen	NAD	Multiple nodules on the right lobe.Large nodule on the left side with cystic changes	Normal	CT:Multi nodular follicular adenomatous goiter with degen. Changes	Near total thyroidectomy	Both lobes enlarged ,firm in consistency	None	Hashimoto's thyroiditis with papillary carcinoma	Uneventful
27	Mallika	56	F	91148	Low	Swelling neck x 15days	5x6cm swelling,firm,nodular	MNG		NAD	Right lobe 1.4x2x3.4cm with multiple nodules.Left lobe 2x3.2x4.8cm with multiple nodules	Normal		Near total thyroidectomy		None	MNG	Uneventful
28	Alagumeena	34	F	96503	Low	Swelling neck x4 yrs	3x3cm swelling,firm,nodular	MNG	Papillary fronds seen	NAD	MNG	Normal		Near total thyoidectomy		None	MNG	Uneventful

29	Karpaga selvi	20	F	83396	Low	Swelling neck x 6months.F/S/O hyperthyroidism	7x5cm swelling,firm,nodular.Tremors present.	Toxic MNG		NAD		T3,T4 raised and TSH decreased		Near total thyoidectomy		None	Toxic MNG	Uneventful
30	Rani	18	F	88669	Low	Swelling neck x5months.F/S/O hyperthyroidism	7x5cm swelling,firm,nodular.Tremors present.Exophthalmos present	Toxic MNG		NAD	MNG	T3,T4 raised and TSH decreased		Near Total thyroidectomy	Both lobes enlarged ,nodular	None	Toxic MNG	Uneventful
31	Nagammal	28	F	30436	Low	Swelling neck	4x4cm swelling,hard,nodular	Ca thyroid	Inconclusive	NAD	Heterogenous echo with calcific spots right lobe	Normal		Near total thyroidectomy	Right carotid engulfed by thyroid	None	Papillary Ca	Uneventful
32	Backiam	30	F	89130	Low	Swelling neck	4x5cm swelling,firm,nodular	MNG	Inconclusive	NAD	MNG	Normal		Near total thyroidectomy		None	MNG	Uneventful
33	Lakshmi	18	F	29679	Low	Swelling neck x8months	4x4cm nodule on the left side,firm	Solitary thyroid nodule	Inconclusive	NAD		Normal		Near total thyoidectomy	Cystic lesion on the left lobe	None	Papillary Ca	Uneventful
34	Panchavarnam	43	F	89466	Low	Swelling neck x 2months	6x4.5cm swelling,nodular,firm	MNG	Inconclusive	NAD	Nodule left lobe	Normal		Near total thyroidectomy		None	MNG	Uneventful
35	Kannathal	30	F	81154	Low	Swelling neck	8x7cm swelling,firm nodular.Tremors,tachycardia present	Toxic MNG		NAD		T3,T4 raised and TSH decreased		Near total thyroidectomy		None	Toxic MNG	Uneventful
36	Maylsamy	25	M	55430	Low	Swelling neck x 2yrs	7x5cm swelling in the right lobe	Solitary thyroid nodule		NAD		Normal		Near total thyroidectomy	Right carotid engulfed by thyroid	None	Ca Thyroid	Uneventful
37	Pandiammal	45	F	55430	Low	Swelling neck x 3yrs,palpitation and tremors present	7x5cm swelling,nodular,firm	Secondary thyrotoxicosis	Inconclusive	NAD	Diffuse goiter	T3,T4 raised and TSH decreased	Antimicrosomal antibody: Normal	Near total thyroidectomy		None	MNG with Toxicosis	Uneventful
38	Durai	31	M	31751	Low	Swelling neck x 5yrs;F/S/O hyperthyroidism present	20x15cm swelling,firm,nodular.Right lobe more enlarged than left.	Secondary thyrotoxicosis	Non neoplastic lesion	NAD	MNG	T3,T4 raised and TSH decreased		Near total thyroidectomy		None	MNG with Toxicosis	Uneventful
39	Pandi	26	F	433601	Low	Swelling neck x 2 yrs	6x4.5cm swelling,nodular,firm	MNG	Follicular epithelial cells	NAD	MNG	Normal		Near total thyroidectomy		None	MNG	Uneventful

40	Annamal	27	F	440748	Low	Swelling neck x 3months	2x3cm swelling,nodular,firm	MNG	Inconclusive	NAD	MNG	Normal		Near total thyroidectomy		None	MNG	Uneventful
41	Megala Devi	27	F	440597	Low	Swelling neck	7x5cm swelling,nodular,firm	MNG	Inconclusive	NAD	MNG	Normal		Near total thyroidectomy		None	MNG	Uneventful
42	Pithcaiammal	48	F	443243	Low	Swelling neck x4 yrs	5x5cm swelling,nodular,firm	MNG	Follicular epithelial cells	NAD	MNG	Normal		Near total thyroidectomy		None	MNG	Uneventful
43	Amaravathy	37	F	444934	Low	Swelling neck x 2 months	3x2cm swelling,nodular, firm	MNG	Inconclusive	NAD	MNG	Normal		Near total thyroidectomy		None	MNG	Uneventful
44	Muthuraaku	23	F	447646	Low	Swelling neck x 12 months	4x2cm swelling,nodular, firm	MNG	Follicular epithelial cells	NAD	MNG	Normal		Near total thyroidectomy		None	MNG	Uneventful
45	Raaku	50	F	450035	Low	Swelling neck	7x5cm swelling,nodular,firm	MNG	Inconclusive	NAD	MNG	Normal		Near total thyroidectomy		None	MNG	Uneventful
46	Panjavarnam	35	F	463548	Low	Swelling neck x 2 yrs	4x2cm swelling,nodular, firm	MNG	Follicular epithelial cells	NAD	MNG	Normal		Near total thyroidectomy		None	MNG	Uneventful
47	Chellammal	45	F	464811	Low	Swelling neck x 3months	5x3cm swelling,nodular,firm	MNG	Follicular epithelial cells	NAD	MNG	Normal		Near total thyroidectomy		None	MNG	Uneventful
48	Saraswathi	37	F	464510	Low	Swelling neck x 8 months	5x5cm swelling,nodular,firm	MNG	Follicular epithelial cells	NAD	MNG	Normal		Near total thyroidectomy		None	MNG	Uneventful
49	Easwari	40	F	469498	Low	Swelling neck	10x15cm swelling,firm,nodular.Right lobe more enlarged than left.	MNG	Follicular epithelial cells	NAD	MNG	Normal		Near total thyroidectomy		None	MNG	Uneventful
50	Selvarani	42	F	467963	Low	Swelling neck x 2 yrs	4x2cm swelling,nodular, firm	MNG	Inconclusive	NAD	MNG	Normal		Near total thyroidectomy		None	MNG	Uneventful
51	Velammal	40	F	464303	Low	Swelling neck x 6yrs;F/S/O hyperthyroidism present	10x4cm swelling,more of right lobe;nodular;firm;lid retraction present	Secondary thyrotoxicosis	Inconclusive	NAD	MNG	T3,T4 raised and TSH decreased		Near total thyroidectomy		None	MNG with Toxicosis	Uneventful
52	Pethanachi	29	F	476238	Low	Swelling neck	3x2cm swelling,nodular, firm	MNG	Follicular epithelial cells	NAD	MNG	Normal		Near total thyroidectomy		None	MNG	Uneventful

53	Raghavan	40	M	477563	Low	Swelling neck x 2yrs;F/S/O hyperthyroidism present	7x5cm swelling,firm,nodular.Tremors present.	Secondary thyrotoxicosis	Inconclusive	NAD	MNG	T3,T4 raised and TSH decreased		Near total thyroidectomy		None	MNG with Toxicosis	Uneventful
54	Ramu	33	M	476266	Low	Swelling neck x 2yrs;F/S/O hyperthyroidism present	2x5cm swelling,firm,nodular.Tremors present.	Secondary thyrotoxicosis	Inconclusive	NAD	MNG	T3,T4 raised and TSH decreased		Near total thyroidectomy		None	MNG with Toxicosis	Uneventful
56	Chellappan	60	M	486061	Low	Swelling neck x 8months	3x2cm swelling,nodular, firm	MNG	Follicular epithelial cells	NAD	MNG	Normal		Near total thyroidectomy		None	MNG	Uneventful
57	Vijayalaxmi	24	F	430217	Low	Swelling neck x 3yrs;F/S/O hyperthyroidism present	6x5cm swelling,firm,nodular.Tremors present.	Secondary thyrotoxicosis	Inconclusive	NAD	MNG	T3,T4 raised and TSH decreased		Near total thyroidectomy		None	MNG with Toxicosis	Uneventful
58	Panju	33	F	486957	Low	Swelling neck	3x2cm swelling,nodular, firm	MNG	Inconclusive	NAD	MNG	Normal		Near total thyroidectomy		None	MNG	Uneventful
59	Anand	35	M	487569	Low	Swelling neck x 3yrs;F/S/O hyperthyroidism present	6x5cm swelling,firm,nodular.Tremors present.	Secondary thyrotoxicosis	Follicular epithelial cells	NAD	MNG	T3,T4 raised and TSH decreased		Near total thyroidectomy		None	MNG	Uneventful
60	Papathi	31	F	497497	Low	Swelling neck x 8months	3x2cm swelling,nodular, firm	MNG	Inconclusive	NAD	MNG	Normal		Near total thyroidectomy		None	MNG	Uneventful
61	Malar	35	F	501235	Low	Swelling neck x 2 yrs	7x5cm swelling,nodular,firm	MNG	Follicular epithelial cells	NAD	MNG	Normal		Near total thyroidectomy		None	MNG	Uneventful
62	Manoharan	50	M	502661	Low	Swelling neck x 4yrs;F/S/O hyperthyroidism present	8x5cm swelling,firm,nodular.Tremors present.	Secondary thyrotoxicosis	Follicular epithelial cells	NAD	MNG	T3,T4 raised and TSH decreased		Near total thyroidectomy		None	MNG with Toxicosis	Uneventful
63	Kasturi	40	F	800446	Low	Swelling neck	3x2cm swelling,nodular, firm	MNG	Inconclusive	NAD	MNG	Normal		Near total thyroidectomy		None	MNG	Uneventful
64	Chellammal	55	F	7476	Low	Swelling neck x 6yrs;F/S/O hyperthyroidism present	8x5cm swelling,firm,nodular.Tremors present.	Secondary thyrotoxicosis	Inconclusive	NAD	MNG	T3,T4 raised and TSH decreased		Near total thyroidectomy		None	MNG with Toxicosis	Uneventful
65	Nagammal	60	F	5793	Low	Swelling neck x6months	3x2cm swelling,nodular, hard	Ca thyroid	Inconclusive	NAD	Multiple nodules on the right lobe.Large nodule on the left side with cystic changes	Normal		Near total thyroidectomy		None	Papillary Ca	Uneventful
66	Sundari	42	F	7232	Low	Swelling neck x 2 yrs	7x5cm swelling,nodular,firm	MNG	Follicular epithelial cells	NAD	MNG	Normal		Near total thyroidectomy		None	MNG	Uneventful

67	Jansirani	28	F	9187	Low	Swelling neck x5months	3x2cm swelling,nodular, hard	Ca thyroid	Inconclusive	NAD	Multiple nodules on the leftt lobe.Large nodule on the right side with cystic changes	Normal		Near total thyroidectomy with right side functional neck dissection		None	Papillary Ca	Uneventful
68	Vijayarani	40	F	87808	Low	Swelling neck	7x5cm swelling,nodular,firm	MNG	Inconclusive	NAD	MNG	Normal		Near total thyroidectomy		None	MNG	Uneventful
69	Vijayalaxmi	37	F	10966	Low	Swelling neck x4yrs;F/S/O hyperthyroidism present	8x5cm swelling,firm,nodular.Tremors present.	Secondary thyrotoxicosis	Inconclusive	NAD	MNG	T3,T4 raised and TSH decreased		Near total thyroidectomy		None	MNG with Toxicosis	Uneventful
70	Selvi	20	F	23720	Low	Swelling neck x 1 yr	5x3cm swelling,nodular,firm	MNG	Inconclusive	NAD	MNG	Normal		Near total thyroidectomy		None	MNG	Uneventful
71	Subulaxmi	45	F	24983	Low	Swelling neck x3yrs;F/S/O hyperthyroidism present	3x5cm swelling,firm,nodular.Tremors present.	Secondary thyrotoxicosis	Inconclusive	NAD	MNG	T3,T4 raised and TSH decreased		Near total thyroidectomy		None	MNG with Toxicosis	Uneventful
72	Selvi	20	F	30033	Low	Swelling neck	7x5cm swelling,nodular,firm	MNG	Follicular epithelial cells	NAD	MNG	Normal		Near total thyroidectomy		None	MNG	Uneventful
73	Maladevi	22	F	32303	Low	Swelling neck x7months	6x2cm swelling,nodular, hard	Ca thyroid	Suspicious of malignancy	NAD	Multiple nodules on the leftt lobe.Large nodule on the right side with cystic changes	Normal		Near total thyroidectomy with B/L functional neck dissection		None	Papillary Ca	Uneventful
74	Jayamani	55	F	34503	Low	Swelling neck x 1 yr	8x6cm swelling,nodular,firm	MNG	Follicular epithelial cells	NAD	MNG	Normal		Near total thyroidectomy		None	MNG	Uneventful
75	Mehraj	31	M	38111	Low	Swelling neck x9months	5x3cm swelling,nodular,firm	MNG	Follicular epithelial cells	NAD	MNG	Normal		Near total thyroidectomy		None	MNG	Uneventful
76	Mariammal	57	F	35380	Low	Swelling neck x19months	6x2cm swelling,nodular, firm	MNG	Inconclusive	NAD	MNG	Normal		Near total thyroidectomy		None	MNG	Uneventful
77	Deivamani	27	F	40448	Low	Swelling neck	7x5cm swelling,nodular,firm	MNG	Follicular epithelial cells	NAD	MNG	Normal		Near total thyroidectomy		None	MNG	Uneventful
78	Chinnammal	55	F	43347	Low	Swelling neck x 1 yr	5x3cm swelling,nodular,firm	MNG	Follicular epithelial cells	NAD	MNG	Normal		Near total thyroidectomy		None	MNG	Uneventful
79	Selvi	37	F	41233	Low	Swelling neck	7x5cm swelling,nodular,firm	MNG	Inconclusive	NAD	MNG	Normal		Near total thyroidectomy		None	MNG	Uneventful

80	Panjavarnam	30	F	43362	Low	Swelling neck x4 yrs	10x6cm swelling,nodular,firm	MNG	Follicular epithelial cells	NAD	MNG	Normal		Near total thyroidectomy		None	MNG	Uneventful
81	Amirtham	33	F	43350	Low	Swelling neckx 2yrs	6x3cm swelling,nodular,firm	MNG	Follicular epithelial cells	NAD	MNG	Normal		Near total thyroidectomy		None	MNG	Uneventful
82	Oorkavalan	32	M	43016	Low	Swelling neck	5x4cm swelling,nodular,firm	MNG	Follicular epithelial cells	NAD	MNG	Normal		Near total thyroidectomy		None	MNG	Uneventful
83	Annapoornam	53	F	44730	Low	Swelling neck x 3 yr	7x5cm swelling,nodular,firm	MNG	Inconclusive	NAD	MNG	Normal		Near total thyroidectomy		None	MNG	Uneventful
84	Shanti	30	F	53244	Low	Swelling neck	6x2cm swelling,nodular, hard	Ca thyroid	Inconclusive	NAD	Multiple nodules on the leftt lobe.Large nodule on the right side with cystic changes	Normal		Near total thyroidectomy		None	Papillary Ca	Uneventful
85	Shanti	38	F	52539	Low	Dyspnoea x 6months,Swelling neck x 1 week,F/S/O hyperthyroidism present	10x4 cm swelling,soft,smooth,eye sighns present,tremors present	Primary thyrotoxicosis	Inconclusive	NAD	MNG	T3,T4 raised and TSH decreased		Near total thyroidectomy		None	Primary thyrotoxicosis	Uneventful
86	Kesammal	40	F	56257	Low	Swelling neck x 5 yr	5x4cm swelling,nodular,firm	MNG	Follicular epithelial cells	NAD	MNG	Normal		Near total thyroidectomy		None	MNG	Uneventful
87	Chandra	40	F	57977	Low	Swelling neckx 2yrs	6x3cm swelling,nodular,firm	MNG	Follicular epithelial cells	NAD	MNG	Normal		Near total thyroidectomy		None	MNG	Uneventful
88	Kaveri	30	F	62223	Low	Swelling neck	7x4cm swelling,nodular,firm	MNG	Follicular epithelial cells	NAD	MNG	Normal		Near total thyroidectomy		None	MNG	Uneventful
89	Raamayi	30	F	29172	Low	Swelling neck x 3 yr	5x6cm swelling,nodular,firm	MNG	Follicular epithelial cells	NAD	MNG	Normal		Near total thyroidectomy		None	MNG	Uneventful
90	Meenakshi	38	F	67081	Low	Swelling neck	7x4cm swelling,nodular,firm	MNG	Follicular epithelial cells	NAD	MNG	Normal		Near total thyroidectomy		None	MNG	Uneventful
91	Shakthi	35	F	70925	Low	Swelling neck x 5 yr	7x5cm swelling,nodular,firm	MNG	Inconclusive	NAD	MNG	Normal		Near total thyroidectomy		None	MNG	Uneventful

92	Muthulaxmi	19	F	72051	Low	Swelling neckx 2yrs	5x4cm swelling,nodular,firm	MNG	Inconclusive	NAD	MNG	Normal		Near total thyroidectomy		None	MNG	Uneventful
93	Velammal	57	F	83426	Low	Swelling neck	9x7cm swelling,nodular, hard	Ca thyroid	Inconclusive	NAD	Inconclusive	Normal		Near total thyroidectomy		None	Papillary Ca	Uneventful
94	Muthu	30	F	44016	Low	Swelling neck x 5 yr	5x6cm swelling,nodular,firm	MNG	Follicular epithelial cells	NAD	MNG	Normal		Near total thyroidectomy		None	MNG	Uneventful
95	Malliga	28	F	44052	Low	Swelling neck x 3 yr	9x4cm swelling,nodular,firm	MNG	Follicular epithelial cells	NAD	MNG	Normal		Near total thyroidectomy		None	MNG	Uneventful
96	Solai	55	M	37494	Low	Swelling neck	10x6cm swelling,nodular,firm	MNG	Inconclusive	NAD	MNG	Normal		Near total thyroidectomy		None	MNG	Uneventful
97	Amudha	27	F	51319	Low	Swelling neck x4yrs;F/S/O hyperthyroidism present	7x5cm swelling,firm,nodular.Tremors present.	Secondary thyrotoxicosis	Inconclusive	NAD	MNG	T3,T4 raised and TSH decreased		Near total thyroidectomy		Temporary recurrent laryngeal nerve palsy.Recovered post op	MNG with Toxicosis	Uneventful
98	Shanthi	30	F	53286	Low	Swelling neck x5yrs;F/S/O hyperthyroidism present	8x7cm swelling,firm,nodular.Tremors present.	Secondary thyrotoxicosis	Inconclusive	NAD	MNG	T3,T4 raised and TSH decreased		Near total thyroidectomy		Temporary recurrent laryngeal nerve palsy.Recovered post op	MNG with Toxicosis	Uneventful
99	Mary	40	F	25679	Low	Swelling neck x 2yrs,swelling left parotid x 3 months,difficulty in deglutition	7x4cm swellingirregular,firm.Left upper deep cervical nodes present.L eft parotid enlarge 4 x2.5cm	MNG with Left parotid swelling	Follicular epithelial cells	NAD	MNG	Normal	CT:B/L Warthin's tumor	Near total thyroidectomy	Left recurrent laryngeal nerve injured	Temporary recurrent laryngeal nerve palsy.Recovered post op	MNG	Uneventful
100	Chinnaponnu	30	F	477447	Low	Swelling neck x 8months	6x4cm swelling,irregular,firm,movement restricted,no nodes	Ca thyroid	Suspicious of malignancy	NAD	Multiple nodules on the right lobe.Large nodule on the left side with cystic changes	Normal		Near total thyroidectomy withB/L functional neck dissection		Temporary recurrent laryngeal nerve palsy.Recovered post op	Papillary Ca	Uneventful

ABBREVIATION

MNG	-	MULTINODULAR GOITRE
MRND	-	MODIFIED RADICAL NECK DISSECTION
NTT	-	NEAR – TOTAL THYROIDECTOMY
RLN	-	RECURRENT LARYNGEAL NERVE
STT	-	SUBTOTAL THYROIDECTOMY
TT	-	TOTAL THYROIDECTOMY