**THE TAMILNADU DR. M.G.R. MEDICAL UNIVERSITY**

**CHENNAI**

# MANAGEMENT OF RETROPERITONEAL TRAUMA

**DISSERTATION SUBMITTED FOR**

**BRANCH – I**

**M.S. (GENERAL SURGERY)**

**MARCH - 2007**

# CERTIFICATE

This is certify that dissertation entitled " **MANAGEMENT OF RETROPERITONEAL TRAUMA**" Submitted by Dr.N.Selva kumar to the Tamil Nadu Dr. M.G.R Medical University , Chennai, is in partial fulfillment of the requirement fore the award of M.S degree Branch – I ( General Surgery ) and is a bonfide research work carried out by him under direct supervision and guidance


**Dr. K.V.Maheshwaran M.S.,**
Additional Professor
Department of Surgery
Govt, Rajaji Hospital
Madurai Medical college
Madurai

**Dr. M.Kalyan sundaram M.S., FICS**
Professor and Head of the Department
of Surgery
Govt, Rajaji Hospital
Madurai Medical college
Madurai

# DECLARATION

This is consolidated report on "**MANAGEMENT OF RETROPERITONEAL TRAUMA** " based on 60 cases treated at Govt. Rajaji Hospital, Madurai, during the period July 2004 to September 2006.

This is submitted to the Tamilnadu Dr. M.G.R. Medical University, Chennai in partial fulfillment of the rules and regulations for the M.S. Degree Examination in General Surgery.

Govt. Rajaji Hospital, **Dr. N.SELVA KUMAR**

Madurai Medical College,

Madurai.

## ACKNOLEDGEMENTS

I am greatly indebted to my unit chief Dr. K. V. Maheswaran M.S., Government Rajaji Hospital and Madurai Medical College, Madurai for his supervision, support, help and valuable guidance at every step in successfully completing this dissertation.

I express my sincere gratitude to Prof. Dr.K. Kalyanasundaram M.S., Head of the Department of General Surgery, Government Rajaji Hospital and Madurai Medical College, Madurai for his advice and for permitting me to undertake this study.

I am very greatful to Dr. S. M. Sivakumar M.S, Dean, Government Rajaji Hospital, Madurai for permitting me to utilize hospital materials for this study.

I thank my Assistant Professors Dr. Selvachidambaram M.S., Dr. Balasubramaniyan M.S, Dr. Babu M.S, Dr.Celine Foustina Mary M.S, D.G.O., for their guidance throughout my study.

I extend my thanks to all my patients who submitted themselves for this study.

# CONTENTS

# INTRODUCTION

The evaluation of patients who have sustained retroperitoneal trauma may pose a significant diagnostic challenge to the most seasoned trauma surgeon. Retroperitoneal trauma produces a spectrum of injury from minor, single-system injury to devastating, multi-system trauma. Trauma surgeons must have the ability to detect the presence of retroperitoneal across this entire spectrum. While a carefully performed physical examination remains the most important method to determine the need for exploratory laparotomy, there is little evidence to support this tenet.

In fact, several studies have highlighted the inaccuracies of the physical examination in retroperitoneal injuries. The effect of altered level of consciousness as a result of neurologic injury, alcohol or drugs, is another major confounding factor in assessing retroperitoneal trauma. Due to the recognized inadequacies of physical examination, trauma surgeons have come to rely on a number of diagnostic adjuncts. Commonly used modalities include diagnostic peritoneal lavage (DPL) and computed tomography (CT). Although not available universally, focused abdominal sonography for trauma (FAST) has recently been included in the diagnostic armamentarium. Diagnostic algorithms outlining appropriate use of each of these modalities individually have been established. Several factors influence the selection of

diagnostic testing: (1) type of hospital - i.e., evidence- trauma center vs. “non-trauma” hospital; (2) access to a particular technology at the surgeon’s institution; (3) the surgeon’s individual experience with a given diagnostic modality. As facilities evolve, technologies mature and surgeons gain new experience, it is important that any diagnostic strategy constructed be dynamic.

## ANATOMY OF RETROPERITONEAL SPACE

The retroperitoneum is a complex compartment, the anatomy of which has yet to be fully validated. The retroperitoneum lies between the posterior parietal peritoneum in front and the transversalis fascia behind. It is nominally divided into three spaces by the perirenal fascia: the anterior pararenal space, the perirenal space and the posterior pararenal space. The anterior pararenal space communicates across the midline. Superiorly it extends to the dome of the diaphragm and hence to the mediastinum. Inferiorly it communicates with the pelvis and below the inferior renal cone with the posterior pararenal space. The perirenal space extends across the midline. It abuts the bare area of the liver on the right and the subphrenic space on the left, with mediastinal communication via the diaphragmatic hiatae. In disease the perirenal space is usually closed inferiorly, preventing pelvic spread. Within the fat surrounding the kidney in the perirenal space there is a network of thin septae that contain and direct the spread of fluid. The posterior pararenal space is potentially in continuity anteriorly with the properitoneal fat of the anterior abdominal wall. It is open towards the pelvis inferiorly but limited superiorly by fusion of the posterior perirenal fascia with the fascia of the quadratus lumborum and psoas muscles.

# MECHANISMS OF INJURIES

**Blunt injury:**

**Important questions, time of injury, mechanism of injury, estimated speed of impact, damage to involved vehicles, use and type of restraining device, condition of injured persons.**

Injury to intra-abdominal structures can be classified into 2 primary mechanisms of injury–compression forces and deceleration forces.

Compression or concussive forces may result from direct blows or external compression against a fixed object (eg, lap belt, spinal column). Most commonly, these crushing forces cause tears and subcapsular hematomas to the solid viscera. These forces also may deform hollow organs and transiently increase intra luminal pressure, resulting in rupture. Deceleration forces cause stretching and linear shearing between relatively fixed and free objects. These longitudinal shearing forces tend to rupture supporting structures at the junction between free and fixed segments. Classic deceleration injuries include hepatic tear along the ligamentum teres and intimal injuries to the renal arteries. As bowel loops travel from their mesenteric attachments, thrombosis and mesenteric tears, with resultant splanchnic vessel injuries, can result.

**Penetrating injury:**

Time of injury. Type of weapon (eg., knife length, handgun calibre). Distance from assailant (particularly for shotgun wounds). Number of stab attempts or shots. Amount of blood at scene .

Retroperitoneal organ injury is commonly associated with anterior penetrating abdominal trauma. The main causative factor of retroperitoneal injuries was shotgun , whereas it was stabbing in intra abdominal injuries ($P<0.05$). The number of injured organs and the hospital stay is significantly greater in retroperitoneal organ injuries, and the trauma scores such as the Injury Severity Score ($P<0.001$) and the Penetrating Abdominal Trauma Index ($P<0.001$) were found to be significantly higher.

## AIM OF THE STUDY

To evaluate clinically the retroperitoneal trauma both blunt and penetrating injuries , role of imaging techniques to conform the diagnosis and management of different retroperitoneal injuries both isolated and combined intraperitoneal and extraperitoneal injuries and the results are compared with other series of study

## MATERIALS AND METHODS OF STUDY

This study was conducted from September 2004 to September 2006 at Government Rajaji Hospital, Madurai, Along with history taking and examination of the patient the prescribed proforma is filled with details of name , age , sex , I . P. No., time of accident / incident, mode of injuries, force of violence and weapons used and vital signs.

Paediatric cases, spinal cord injuries, bone injuries have been excluded in this study.

A total no of 98 cases were admitted with following age / sex incidence.

Types of injuries

| Penetrating | Blunt |
|---|---|
| 15 | 66 |

| Retroperitoneal | Combined |
|---|---|
| 64 | 17 |

In our series blunt injuries are mostly caused by road traffic accidents and accidental fall, penetrating injuries are caused by knife, spear heads etc.,

**Abdominal pain**

Pain abdomen either localized or diffuse, dullaching pain. A score of 0 to 3 was used to quantify nil, mild, moderate & severe pain.

**Guarding / rigidity** - Either localized in early cases or diffuse in delayed cases. Rigidity was scored as follows :

0 - no rigidity

1 - mild rigidity/ localized to one quadrant

2 - moderate /involving more than one quadrant

3 - severe & extensive involving all the quadrants of the abdomen

**Haematuria** - Total haematuria on insertion of foley's catheter graded as

0 - no haematuria

1 - presence of haematuria

**Hypotension** – scored as follows :

0 - normal systolic blood pressure(110 – 120 mm hg)

1 - mild hypotension (90 - 110 mm hg ,)

2 - moderate hypotension (70 - 90 mm hg)

3 - severe hypotension ( < 70 mm hg)

A maximal score of 10 was postulated to be RPTS (retroperitoneal trauma score). This score takes into account only clinical parameters and hence is universally applicable.

**Management protocol:**

The trauma victims were received in the trauma ward. Initial survey of the patient done. Resuscitative measures initiated & patient stabilized. Tertiary survey of the patient done with specific reference to the abdomen. The RPTS was evaluated for each of the patients. An overall RPTS of > / = 5 with hypotension score >/= 2 were taken as indications for exploratory laparotomy. An overall score of < 5 were subjected to ultra sonogram of the abdomen & contrast enhanced CT of the abdomen managed conservatively.

**EVALUATION OF RETROPERITONEAL INJURIES**

**PROFORMA**

NAME: AGE: SEX: I. P. NO:

ADDRESS:

DATE OF ADMISSION:

DATE OF DISCHARGE:

MODE OF INJURY:

TYPE OF INJURY: BLUNT PENETRATING

VITAL SIGNS: PULSE BP RESPIRATORY RATE

LIST OF EXTERNAL INJURIES:

INVESTIGATIONS:

BLOOD GROUPING: RENAL FUNCTION TESTS:

BLOOD GAS ANALYSIS: SERUM ELECTROLYTES:

USG CT MRI

TREATMENT: CONSERVATIVE SURGERY

RESULT: DISCHARGED WITH GOOD GENERAL CONDITION

MORBIDITY

MORTALITY

# PRIMARY SURVEY OF THE PATIENT

***INITIAL SURVEY OF THE PATIENT.***

## Hi**story:**

Initially, evaluation and resuscitation simultaneously occur. In general, ascertain the mechanism of injury from bystanders, paramedics, or police. **AMPLE** is often useful as a mnemonic for remembering key elements of the history.**A**llergies, **M**edications, **P**ast medical history, **L**ast meal or other intake, **E**vents leading to presentation

## Physical:

Initial examination:

After appropriate primary survey and initiation of resuscitation, focus attention on secondary survey of the abdomen. For life-threatening injuries requiring emergent surgery, delay comprehensive secondary survey until the patient has been stabilized.

Inspection:

Note injury patterns that predict the potential for intra-abdominal trauma (eg, lap belt abrasions, steering wheel-shaped contusions). Observe the respiratory pattern, since abdominal breathing may indicate spinal cord

injury. Note abdominal distention and any discoloration. Bradycardia may indicate the presence of free intraperitoneal blood in a patient with blunt abdominal injuries. The Cullen sign (ie, periumbilical ecchymosis) may indicate retroperitoneal hemorrhage; however, this symptom usually takes several hours to develop. Flank bruising and swelling may raise suspicion for a retroperitoneal injury. Inspect genitals and perineum for soft tissue injuries, bleeding, and hematoma.

Auscultation:

Abdominal bruit may indicate underlying vascular disease or traumatic arteriovenous fistula.

Palpation:

Carefully palpate the entire abdomen while assessing the patient's response. Note abnormal masses, tenderness, and deformities. Pelvic instability indicates the potential for lower urinary tract injury as well as pelvic and retroperitoneal hematoma. Perform rectal and bimanual vaginal pelvic examinations to identify potential bleeding and injury. Abdominal distention may result from gastric dilation secondary to assisted ventilation or swallowing of air. Signs of peritonitis (eg, involuntary

guarding, rigidity) soon after an injury suggest leakage of intestinal content. Peritonitis due to intra-abdominal hemorrhage may take several hours to develop.

Percussion:

Percussion tenderness constitutes a peritoneal sign.

Lab Studies:

Complete blood count, Serum chemistries, Liver function studies, Amylase, Urinalysis, Obtain serum or urine pregnancy test on all females of childbearing age, Coagulation profile, Blood type, screen, and crossmatch, Arterial blood gas, Drug and alcohol screens .

## SECONDARY SURVEY OF THE PATIENT

## EVALUATION OF RETROPERITONEAL TRAUMA

Further evaluation of abdominal trauma requires the use of one or more of the following diagnostic modalities: Serial Physical Examination (PE), Local Wound Exploration (LWE), Diagnostic Peritoneal Lavage (DPL), Ultrasound (FAST), CT Scan, Laparoscopy, Laparotomy. The decision on which method, or combination of methods, to choose will depend primarily on trauma patient load, access to in-patient beds, availability of in-house surgical teams, access to multislice CT scanners etc.

Whichever decision tree is chosen should be accepted at a hospital-wide level. The algorithm should be routinely audited for missed injuries, effectiveness and use of resources

**Serial Physicial Examination**

Serial physical examination has the best sensitivity and negative predictive value of all modalities for the evaluation of abdominal trauma.

The patient is admitted for observation for 24 hours. During this time the patient is has frequent (hourly), regluar checks of their haemodynamic status. The abdomen is examined routinely for signs of developing peritonitis.

If the patient develops signs of haemodynamic instability or peritonitis during this period of observation, a laparotomy is performed. If the patient is well the following day they start a normal diet, and are discharged once diet is tolerated and they have completed the observation period.

# EVALUATION OF ABDOMINAL TRAUMA

David V. Feliciano, MD, FACS
Grace S. Rozycki, MD, FACS

© 2003 American College of Surgeons
Committee on Trauma
Subcommittee on Publicatons

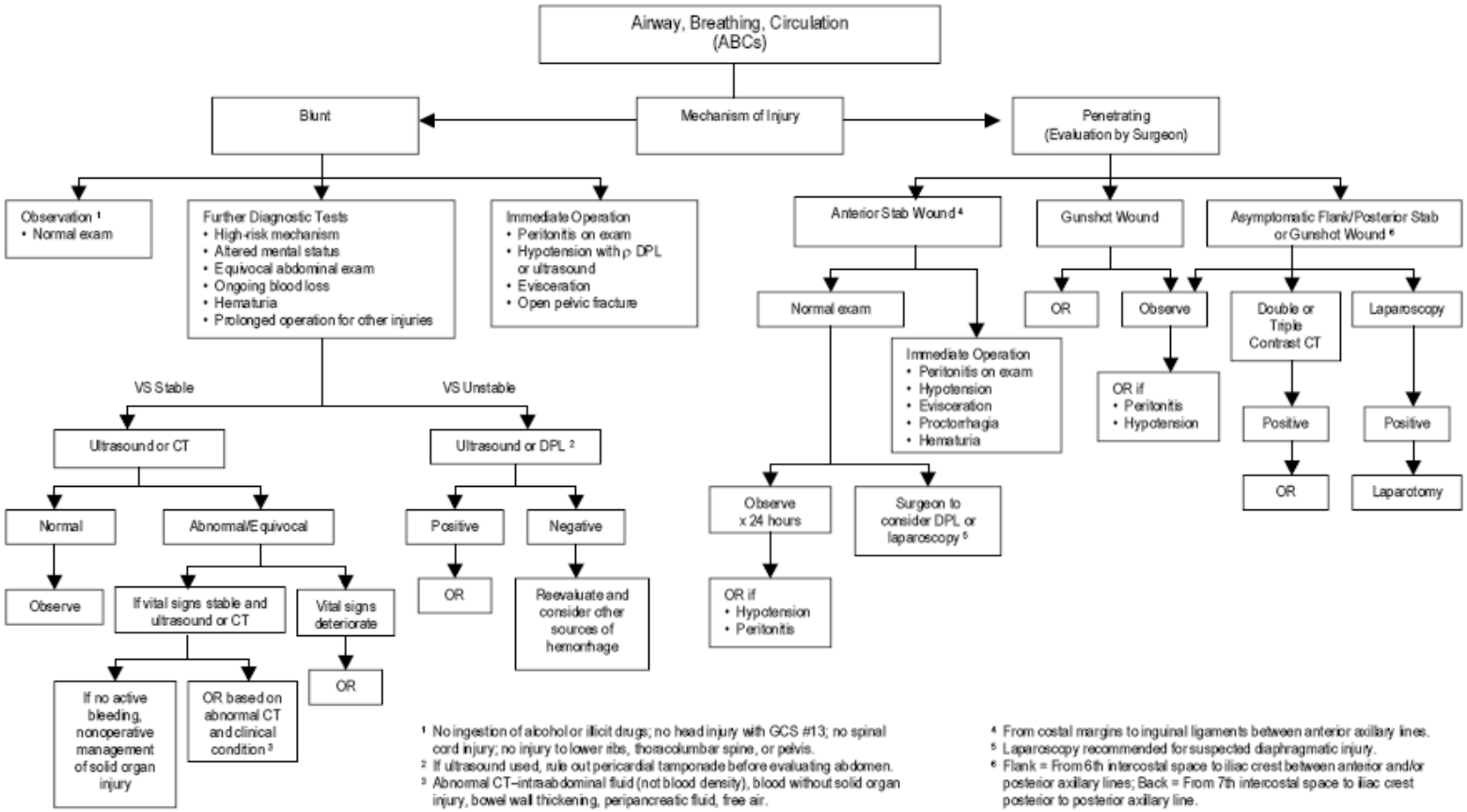


[1] No ingestion of alcohol or illicit drugs; no head injury with GCS #13; no spinal cord injury; no injury to lower ribs, thoracolumbar spine, or pelvis.
[2] If ultrasound used, rule out pericardial tamponade before evaluating abdomen.
[3] Abnormal CT–intraabdominal fluid (not blood density), blood without solid organ injury, bowel wall thickening, peripancreatic fluid, free air.
[4] From costal margins to inguinal ligaments between anterior axillary lines.
[5] Laparoscopy recommended for suspected diaphragmatic injury.
[6] Flank = From 6th intercostal space to iliac crest between anterior and/or posterior axillary lines; Back = From 7th intercostal space to iliac crest posterior to posterior axillary line.

.

| | PE | LWE | DPL | FAST | CT | Laparoscopy | Laparotomy |
|---|---|---|---|---|---|---|---|
| Sensitivity (%) | 95- | 71 | 87 | 46-85 | 97 | 50-100 | - |
| Specificity (%) | 10 | 77 | 52 | 48-95 | 98 | 74-90 | - |
| NPV (%) | 0 92 | 79 | 78 | 60-98 | 98 | 100 | - |
| Requires awake, cooperative patient | + | - | - | - | - | - | - |
| Invasive | - | + | + | - | - | + | ++ |
| Requires admission | + | +/- | - | - | - | + | + |
| Evaluates retroperitoneum | +/- | - | - | - | + | - | + |
| High clinical workload | + | - | - | - | - | +/- | +/- |
| Complication rate | - | + | +/- | - | - | + | ++ |

PE: Physical Exam; LWE: Local Wound Exploration; DPL: Diagnostic Peritoneal Lavage

Patients who do not develop frank peritonitis, but who have persistent local symptoms of pain and tenderness, with perhaps a fever or tachycardia

at 24 hours should be evaluated by another modality: CT Scan, laparoscopy or laparotomy.

**Diagnostic Peritoneal Lavage (DPL)**

DPL was introduced by Root in 1965 as a rapid and accurate method to identify the presence of intra-abdominal hemorrhage following trauma. It has an accuracy rate of 90 – 98 %. A positive DPL, based on microscopic analysis of lavage fluid, has been defined as > 105 RBC/mm3. It has been recommended that patients with RBC counts in the equivocal range (i.e., 25,000 – 75,000 RBC/mm3) undergo additional diagnostic testing, such as CT scanning. In order to avoid sampling the retroperitoneal hematoma, a supra-umbilical approach has been recommended. The advantages of DPL for detection of hollow visceral injuries have been clearly demonstrated, but it does not reliably exclude significant injuries to retroperitoneal structures.

Computed Tomography (CT)

CT requires a cooperative, hemodynamically stable patient. In addition, the patient must be transported out of the trauma resuscitation area to the radiographic suite. CT scanners are now available in most trauma centers and, with the advent of helical scanners, scan time has been

significantly reduced. As a result, CT has become an accepted part of the traumatologist's armamentarium.CT has the unique ability to detect clinically unsuspected injuries. Another advantage of CT scanning over other diagnostic modalities is its ability to evaluate the retroperitoneal structures.

***Focused Abdominal Sonography for Trauma (FAST)***

In recent years, focused abdominal sonography for trauma (FAST) has emerged as a useful diagnostic test in the evaluation of BAT. FAST is noninvasive, may be easily performed and can be done concurrently with resuscitation. In addition, the technology is portable and may be easily repeated if necessary. In most cases, FAST may be completed within 3 or 4 minutes. The test is especially useful for detecting intra-abdominal hemorrhage in the multiply injured or pregnant patient.

In the hands of most operators, ultrasound will detect a minimum of 200 ml of fluid Injuries not associated with hemoperitoneum may not be detected by this modality. In the hemodynamically stable patient with BAT, FAST offers a viable alternative to DPL. In addition, ultrasound has been shown to be more cost-effective when compared to DPL or CT. Surgeons, emergency medicine physicians, ultrasound technicians and radiologists have equivalent result

**Diagnostic laparoscopy (DL)**

As interest in laparoscopic procedures has increased among general surgeons, there has been speculation regarding the role of diagnostic laparoscopy (DL) in the evaluation of BAT. One of the potential benefits postulated is the reduction of non therapeutic laparotomies. With modification of the technique to include smaller instruments, portable equipment and local anesthesia, DL may be a useful tool in the initial evaluation of BAT. Although its ultimate role remains unclear, another modality to be considered in the diagnostic evaluation of BAT is visceral angiography. This modality may have diagnostic value when employed in conjunction with angiography of the pelvis or chest, or when other diagnostic studies are inconclusive.

**LOCAL WOUND EXPLORATION**

Local wound exploration requires a formal exploration of the wound under local anaesthesia. Penetration of the anterior fascia is considered a positive LWE, as penetration of the peritoneum is difficult to identify. A positive LWE leads to either laparotomy or another diagnostic test such as DPL or laparoscopy.

## Exploratory Laparotomy

Even if there is no preoperative sign of retroperitoneal organ injury, an exploratory laparotomy and a meticulous retroperitoneal exploration should also be performed for associated retroperitoneal organ injury.

## PANCREATICO-DUODENAL INJURIES.

---

Duodenal and pancreatic injuries in the setting of trauma is relatively rare. Its retroperitoneal location has protective value. Injury presents a diagnostic challenge, and often, carry multiple associated injuries with substantial mortality & morbidity. The surgical management of these problems can be very challenging and often difficult

### Pancreatic injuries

*Accounts for 1-12% of abdominal injuries, majority of which is caused by penetrating trauma. Most blunt injuries affect the pancreas distal to the neck. Injuries are designated as proximal and distal based on its relation to the mesenteric vessels (tissue and function) Major abdominal vascular injuries are present in >75% of cases (penetrating). Diagnosis: difficult due to its retroperitoneal location; delayed presentation of symptoms due to the need of secretions to be activated. Serum amylase can be persistently elevated. Contrast duodenography may show a widened C-loop. Some injuries may only be identified during follow up CT scans for changing clinical status. Role of DPL is limited. Isolated injuries are rare. Presence of pancreatic duct injury is a key factor in postoperative morbidity. Duct injuries can be studied by intraoperative pancreatography; done either after distal resection or through a duodenotomy. ERP (endoscopic retrograde pancreatography) is difficult; more helpful in delayed diagnosis. Pancreatic duct stents have been attempted: low success rate, no long term results*

**Pancreatic organ injury scale**

| | | |
|---|---|---|
| I | Haematoma | Minor contusion without ductal injury |
| | Laceration | Superficial laceration, no ductal injury |
| II | Haematoma | Major contusion without duct injury |
| | Laceration | Major laceration without duct injury or tissue loss |
| III | Laceration | Distal transection or parenchymal injury with duct injury |
| IV | Laceration | Proximal (to right of superior mesenteric vein) transection or parenchymal injury, *not* involving ampulla |
| V | Laceration | Massive disruption of pancreatic head |

**Management of pancreatic injuries:**

Hematomas are unroofed, evacuated, controlled, and drained. (Grade I-II). Distal pancreatic injuries, especially with ductal injury, are resected +/- splenectomy (Grade III).20% have drainage past 2 weeks. Bury the distal transected end to a roux-en-Y limb. If stable, Roux-en-Y

pancreaticojejunostomy or Whipple**.** When combined with duodenal injury, diverticulization or exclusion can be done.

**Intra-pancreatic CBD injury**

Diagnosis: squeeze the gallbladder and observe the wound If there is bile, then diagnosis is made Perforations are treated with division of the CBD above the first portion of the duodenum and ligating the distal stump then reconstructing with a roux-en-Y choledochojejunostomy Drainage with closed-suction devices (over sump or penrose drains) are associated with fewer infectious complications

**Complications of pancreatic injuries**

Extensive pancreatic head injuries are complicated by fistulization in >40%. Peripancreatic abscess is also a major problem. Most fistulas will close spontaneously if well drained. Somatostatin can be used but results are controversial. Incidence of pancreatitis 8-18%. Pseudocysts are infrequent. Prolonged gastric ileus is common. Feeding jejunostomy should be performed. Late deaths are due to sepsis or multiple organ failure. Mortality ranges from 10-25%, mostly from other injuries (vascular >50%)

## BLUNT DUODENAL INJURIES - Overview

*Occurs more often in children. Typical scenario is an MVC with a blow to the epigastrium by the steering wheel; in children, bicycle crash, hitting the handlebars. Symptoms may be slow to develop & difficult to diagnose. DPL not useful , Contents have neutral pH , Few bacteria +. Often contained by the retroperitoneum. Hyperamylasemia is present in 50% of patients with blunt injury. Radiological evaluation may reveal Scoliosis, Obliteration of the right psoas shadow ,Absence of air in the duodenal bulb , Air in the retroperitoneum outlining the kidney , "coil spring/stacked coin" sign = hematoma. Most common site of blunt injury are D2 (crush or closed loop blowout) and D4 (traction). Duodenal injuries in children can be managed with NGT and TPN. Majority resolve in 7-14 days. New approach: laparoscopic evacuation on day 7 if no improvement in GI function*

## Penetrating injuries of the duodenum

Duodenal injuries that account for ~3-5% of abdominal injuries are mostly penetrating in nature. Most penetrating injuries are grade II-III. Usually accompanied by other intraabdominal injuries. Associated mortality is 12-25%. Complication rate occurs in 35-45%. Most significant complication is duodenal fistula 5-15%. Mortality may reach 30% if lesion missed and not treated within 24 hours. Perforations are not reliably identified by CT scan; use UGI with soluble contrast followed by barium. Timing to surgery plays a major role in determining mortality. If operated on in the first 24 hours, mortality is about 11% vs. 40% if surgery done after 24 h. Due to its retroperitoneal location, risk to adjacent structures is high; This

also makes diagnosis difficult. Organs most likely injured (4.6+/-1.8) alongwith duodenum are: Liver, Colon, Major abd. vessels, Spleen & CBD. Requires a high index of suspicion. Evaluate the duodenum if there is an upper/central retroperitoneal hematoma, air, or bile staining. Exposure provided by Kocher maneuver and mobilization of hepatic flexure. Most injuries 80-85% can be repaired primarily

**Duodenal organ injury scale**

| | | |
|---|---|---|
| I | Haematoma | Involving single portion of duodenum |
| | Laceration | Partial thickness, no perforation |
| II | Haematoma | Involving more than one portion |
| | Laceration | Disruption < 50% of circumference |
| III | Laceration | Disruption of 50 75% of circumference of D2 |
| | | Disruption of 50 100% of circumference of D1, D3 and D4 |
| IV | Laceration | Disruption of > 75% of circumference of D2 |
| | | Involving ampulla or common bile duct |
| V | Laceration | Massive disruption of pancreatico-duodenal complex |
| | Vascular | Devascularisation of the duodenum |

Grade I usually resolve and do not cause symptoms.

Partial thickness lacerations are closed by simple seromuscular closure.

Multisegment hematomas are evacuated by a longitudinal serosal incision along the antimesenteric border. No drainage is necessary unless perforation. D1 injuries, if not repairable, debride and anastomose primarily, pulling stomach down (tension free anastomosis) D3 and D4 have a short mesentery, mobilization risks ischemia. High incidence of fistulization, almost 50%Preferred method is to resect anddo a duodenojejunostomy to the right of the mesenteric vessels Duodenorraphy with or without external drainage, this is the most frequently employed technique. Pyloric exclusion entails closure of the pylorus with a non-absorbable suture and gastrojejunostomy. This technique is used for duodenal injuries involving greater than 50% of the circumference. Triple ostomy: gastrostomy, retrograde tube duodenostomy, antegrade tube jejunostomy Duodenal diverticulization antrectomy, vagotomy, gastrojejunostomy, tube duodenostomy after primary repair, feeding jejunostomy. Jejunal serosal patch, pedicled grafts, segmental resection, Duodenal Diverticulization are rarely indicated.

Pancreatico – duodenal injuries: Common due to their intimate relationship. Risk of duodenal suture line dehiscence and development of a lateral duodenal fistula. Simplest treatment is to repair the duodenal injury and drain the pancreas. Pancreaticoduodenectomy indications include Transection of both intrapancreatic BD and main pancreatic duct at the head, avulsion of the papila of Vater from the duodenum, destruction of the second portion of duodenum.

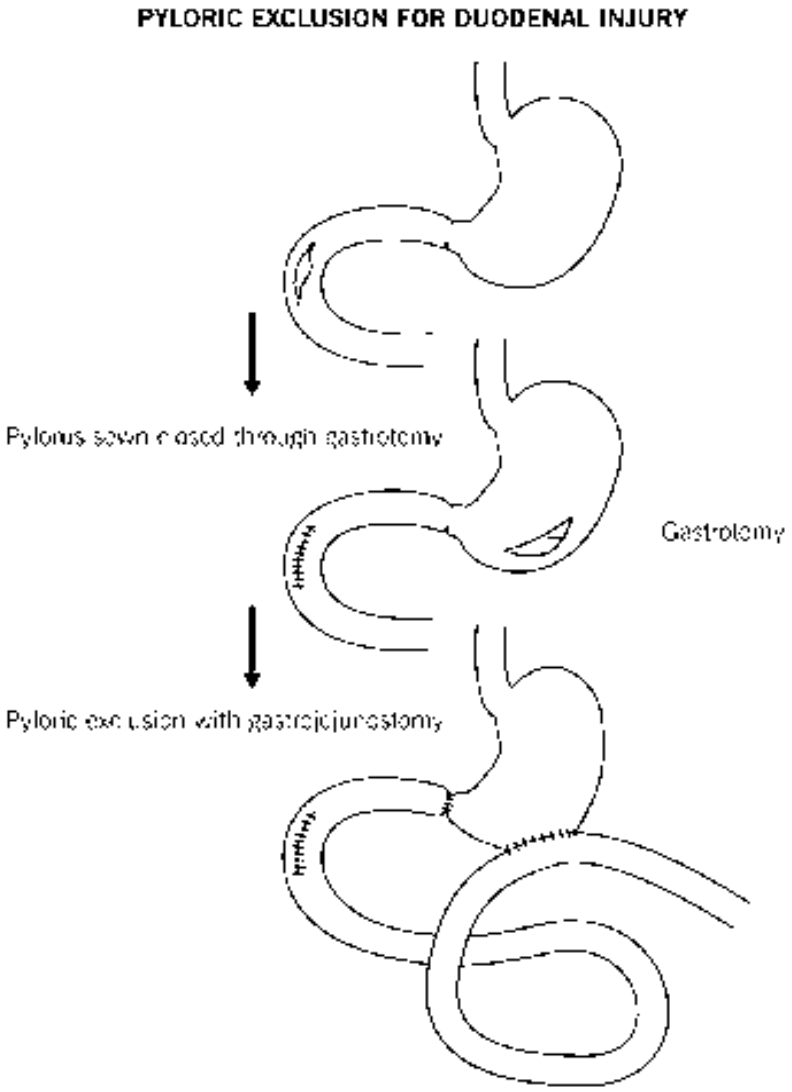


Pyloric exclusion for duodenal injury.

# RENAL TRAUMA

Renal Trauma is present in approximately 10% of all abdominal injuries 90% of renal trauma is due to blunt injury. Major renal trauma is more often associated with penetrating trauma than with blunt trauma (40% vs 15%). Adopt a high level of suspicion for renal injuries in patients with major blunt abdominal trauma, and those with penetrating flank and back wounds.

## Blunt Trauma

Results warranting further radiological investigation: Gross haematuria, Microscopic haematuria and shock

## Penetrating Trauma

*Image all suspected injuries. There is no correlation between the degree of haematuria and the extent of the injury. 14% of major injuries & 10 % of minor injuries have no haematuria.*

## Intravenous Urography

90% accurracy under best of conditions. Poor study in hypotensive patients. Poor grading study. Does not evaluate retroperitoneum. One shot study may be important in unstable patients to identify a contralateral functioning kidney.

**Computed Tomography**

Gold standard. Delineates grade of injury. Shows infarcted segments of kidney. Images whole abdomen and retroperitoneum. Not appropriate for haemodynamically unstable patients

**Angiography**

Delineates vascular injury. Where CT equivocal or unavailable. Invasive. Relative indications for surgery include: A devitalized renal segment in the presence of other abdominal injuries. Persistent extravasation. Loculated collections. Incomplete grading (CT or angiography)

**Classified according to the Organ Injury Scaling (OIS) Committee Scale**

| | | | |
|---|---|---|---|
| **Minor** | **I** | Contusion | Microscopic or gross haematuria, Urological studies normal |
| | | Haematoma | Subcapsular, nonexpanding without parenchymal laceration. |
| | **II** | Haematoma | Nonexpanding perirenal haematoma confined to renal retroperitoneum. |
| | | Laceration | <1cm parenchymal depth of renal cortex without urinary extravasation. |
| **Major** | **II** | Laceration | >1cm depth of renal cortex, without collecting system rupture or urinary extravasation |
| | **I** | | |
| | **IV** | Laceration | Parenchymal laceration extending through the renal cortex, medulla and collecting system. |
| | | Vascular | Main renal artery or vein injury with contained haemorrhage. |
| | **V** | Laceration | Completely shattered kidney. |
| | | Vascular | Avulsion of renal hilum which devascularizes kidney |

9% of kidney injuries will require surgical exploration, and of these there is on average an 11% nephrectomy rate. Most nephrectomies are for haemorrhage, and 61% of nephrectomies are for renovascular Injury.

**Surgical Technique**

Midline laparotomy. Gain proximal control. Debride. Ligate bleeding vessels. Repair collecting system. Close capsule or use omental graft. Retroperitoneal drainage. Proximal control of the renal artery and vein before mobilisation of the colon and opening of Gerota's fascia increases rate of renal salvage . If bleeding occurs on mobilisation of the colon or opening of perinephric fascia, atraumatic vascular clamps may be placed on the renal artery and vein. Warm ischaemia is poorly tolerated, and acute tubular necrosis develops after 20 minutes, though this is usually transient. Partial nephrectomy is often possible. Preserving the capsule of the kidney if possible, devitalised tissue is debrided and bleeders controlled with diathermy or suture. The collecting system is closed with a running absorbable suture. Alternatively, pledgeted matress sutures may be placed across the capsule. If possible the capsule is closed, or an omental flap closed over the defect. Nephrectomy is inidicated in the shattered kidney or renal pedicle injury in an unstable patient. The pedicle vessels are ligated separately, to avoid later arteriovenous fistula formation. The ureter is tied and kidney removed. Retroperitoneal drainage is necessary post partial or total nephrectomy. This should not be in contact with the renal collecting system. If the collecting system has been reparied, a nephrostomy tube

and/or double-J stent should be placed. Injuries to other abdominal organs should be drained separately.

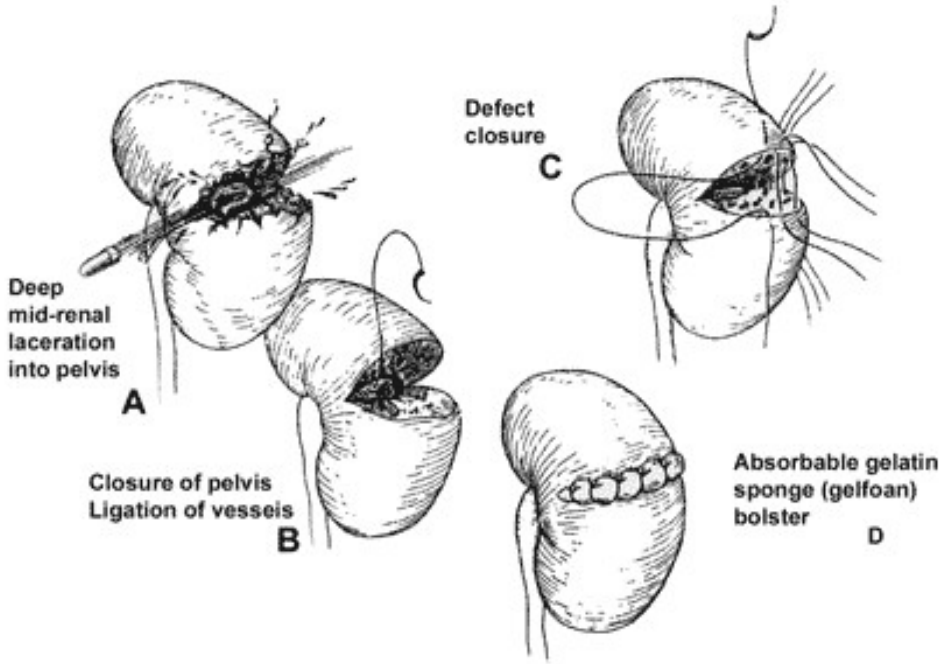


***Figure 5*** *- Technique of renorrhaphy after midpole grade IV injury. (Reprinted with permission from: McAninch JW: Surgery for Renal Trauma. In: Novick AC, Streem SB, Pontes JE (eds.), Stewart's Operative Urology. Baltimore, Williams & Wilkins. 1989; 234-9).*

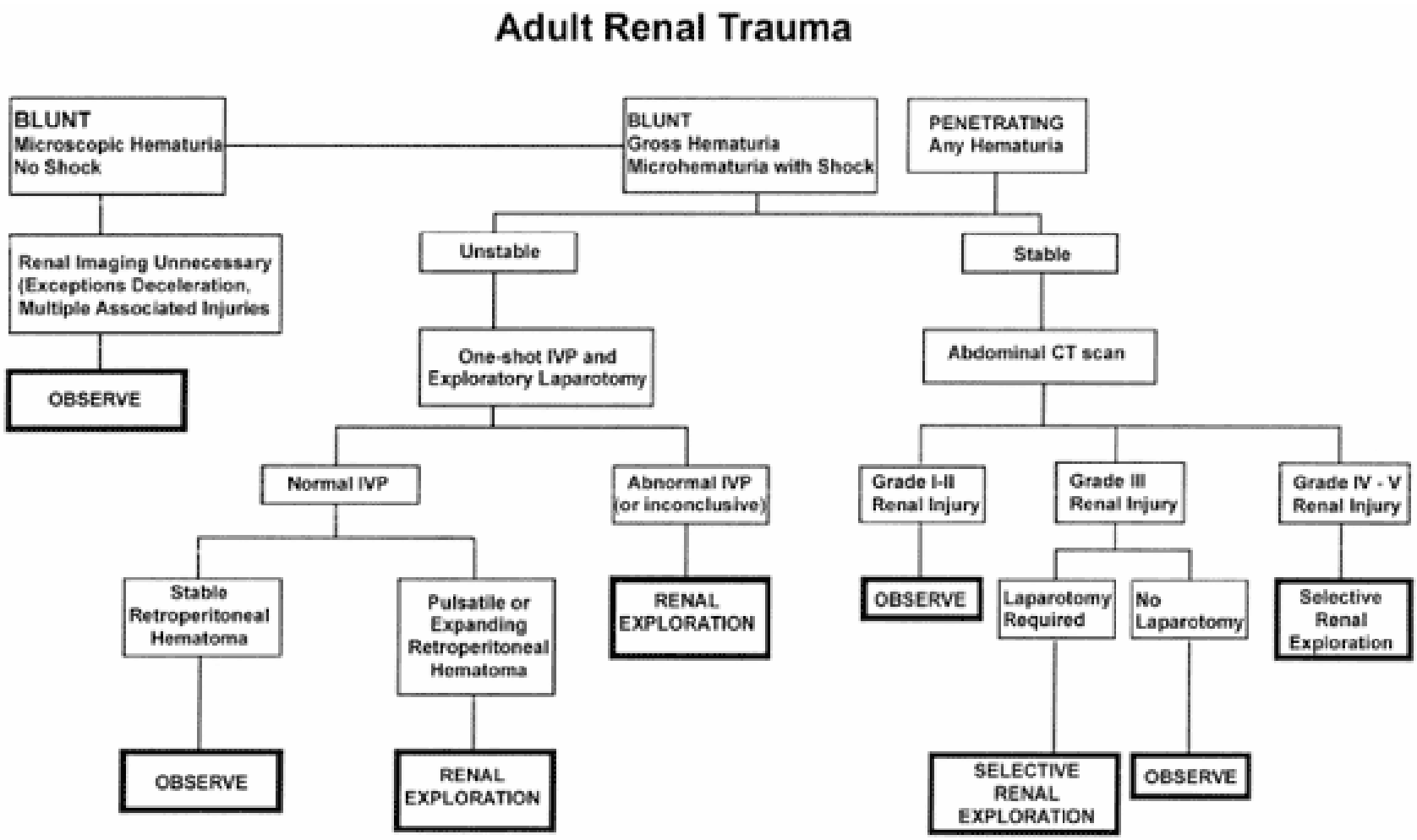


***Figure I*** *- Algorithm for treating patients with renal trauma. (Reprinted with permission from: Meng MV, Brandes SB, McAninch JW. Renal trauma: indications and techniques for surgical exploration. World J Urol. 1999; 17: 71-7).*

# BLADDER INJURIES: EVALUATION AND MANAGEMENT

Presence of hematuria after trauma must be carefully evaluated for kidney,ureteral, bladder, and urethral injury. Usually bladder injury will be implied by the trajectory of the knife or missile wound, and all patients with hematuria at risk for bladder involvement must have formal cystography or intraoperative exploration to rule it out.

## Evaluation

### Local Signs and Symptoms

Lower abdominal pain, tenderness, and bruising are often found in patients with bladder injury. However, these signs and symptoms can be difficult to differentiate from the sequelae of pelvic fracture. Some bladder injuries (usually intraperitoneal) are discovered because a urethral catheter does not return urine. In patients with a delayed diagnosis of bladder injury, fever, absence of voiding, peritoneal irritation, and elevated blood urea nitrogen (BUN) can be present. Any patient with this constellation of signs and symptoms should have formal cystography to rule out bladder injury.

**Blood at the Urethral Meatus**

Inspection for blood at the urethral meatus is mandatory in all trauma patients, as this sign should be present in about half of significant urethral injuries. A significant percentage (10-17%) of patients with bladder injuries will have associated urethral rupture. If findings on urethrography are normal, a Foley catheter is placed; if abnormal, the patient is brought to the operating room for placement of a suprapubic urinary catheter, bladder exploration, and repair of bladder injuries. A large-bore 20-24F Foley or Malecott catheter suprapubically and 16-20F Foley catheter drainage recommended.

**Static Cystography**

Retrograde cystography with plain abdominal x-ray imaging (including drainage films) has proved 100% accurate. Only standard anteroposterior (AP) views of the pelvis are usually needed, although oblique films or fluoroscopy is used in rare cases when standard films are difficult to interpret. The technique has two important aspects: filling the bladder completely; and obtaining a post drainage film.350 ml of 30% contrast (iohexol, Nycomed) is infused by gravity into the urinary catheter.

**Computed Tomography (CT) Cystography**

Because most of these patients already require CT scans to evaluate pelvic fracture or intraabdominal injury, CT cystography saves time. This method involves retrograde infusion of 350 ml (or until patient discomfort) 30% contrast (iohexol, Nycomed), diluted 6:1 with saline. Some have suggested that an adequate CT cystogram can be obtained by clamping the Foley catheter for 20 minutes after injection of intravascular contrast. This relies on urinary excretion of the contrast, followed by bladder extravasation of urine

**Grade***

| | | |
|---|---|---|
| I | Hematoma | Contusion, intramural hematoma |
| | Laceration | Partial thickness |
| II | Laceration | Extraperitoneal bladder wall laceration < 2 cm |
| III | Laceration | Extraperitoneal (³ 2cm) or intraperitoneal (< 2cm) bladder wall laceration |
| IV | Laceration | Intraperitoneal bladder wall laceration ³ 2cm |
| V | Laceration | Intraperitoneal or extraperitoneal bladder wall laceration extending into the bladder neck or ureteral orifice (trigone) |

**Advance one grade for multiple lesions up to grade III*

**MANAGEMENT**

Extraperitoneal ruptures alone constitute 62% of all bladder injuries and are combined with intraperitoneal rupture in another 12%. Extraperitoneal ruptures, are thought to result from direct laceration, usually by bone spicules from the fractured pelvis.

They can most commonly be managed with catheter drainage alone, Open pelvic fracture and rectal perforation are associated with a high risk of serious infection if managed conservatively. Others have suggested that, if clots obstruct the urinary catheter within 48 hours of injury, open repair should be undertaken and a suprapubic tube placed. Careful inspection for associated lower urinary tract injuries is mandatory at open repair so as not to miss urethral disruption, prostate or bladder neck injury, or unexpected intraperitoneal injuries. The bladder is opened at the dome; if desired, the blades of a self-retaining retractor can be used to keep it open. Extraperitoneal lacerations are then closed with absorbable suture in one layer.

**Repair at Open Pelvic Fracture Reduction**

If open plating of the symphysis pubis is planned, the urology team should be alerted and the bladder repaired at the same time, through the same Pfannenstiel incision used by the orthopedic surgeon.

**Follow-up Cystography**

If extraperitoneal rupture has not been repaired, a cystogram is obtained at 10-14 days .Most ruptures 76-87% heal by 10 days, and all by 3 weeks. If the cystogram shows no extravasation, the catheter is removed; otherwise, cystography is repeated at 21 days. If bladder repair has been performed, a cystogram is obtained 7-10 days after surgery.

**COMPLICATIONS**

Acute complications after repair consisted of clot retention and local infection (15); late complications (occurring in 5%) were urethral stricture and frequency/dysuria. In patients managed with catheter drainage, late complications also were more frequent (21%) and consisted of urethral stricture and bladder hyperreflexia. Although urinary frequency is commonly seen after bladder injury, this improves in most patients by 2 months. Persistent frequency is rare (2%).

**RETROPERITONEAL VASCULAR INJURIES**

**Retroperitoneal vascular injury forms one of the most frequent causes of death following abdominal trauma. These wounds usually present with frank intra-abdominal haemorrhage or retroperitoneal haematoma formation. Management is based on both the mechanism of trauma and location of injuries.**

**AAST Abdominal Vascular Organ Injury Scale**

| Grade | Characteristics of Injury | OIS Grade | ICD-9 | AIS-90 |
|---|---|---|---|---|
| I | Unnamed superior mesenteric artery or superior mesenteric vein branches | I | 902.20/902.39 | NS |
| | Unnamed inferior mesenteric artery or inferior mesenteric vein branches | I | 902.27/902.32 | NS |
| | Phrenic artery or vein | I | 902.89 | NS |
| | Lumbar artery or vein | I | 902.89 | NS |
| | Gonadal artery or vein | I | 902.89 | NS |
| | Ovarian artery or vein | I | 902.81/902.82 | NS |
| | Other unnamed small arterial or venous structures requiring ligation | I | 902.90 | NS |
| II | Right, left, or common hepatic artery | II | 902.22 | 3 |

| | | | | |
|---|---|---|---|---|
| | Splenic artery or vein | II | 902.23/902.34 | 3 |
| | Right or left gastric arteries | II | 902.21 | 3 |
| | Gastroduodenal artery | II | 902.24 | 3 |
| | Inferior mesenteric artery, trunk, or inferior mesenteric vein, trunk | II | 902.27/902.32 | 3 |
| | Primary named branches of mesenteric artery (e.g., ileocolic artery) or mesenteric vein | II | 902.26/902.31 | 3 |
| | Other named abdominal vessels requiring ligation or repair | II | 902.89 | 3 |
| III* | Superior mesenteric vein, trunk | III | 902.31 | 3 |
| | Renal artery or vein | III | 902.41/902.42 | 3 |
| | Iliac artery or vein | III | 902.53/902.54 | 3 |
| | Hypogastric artery or vein | III | 902.51/902.52 | 3 |
| | Vena cava, infrarenal | III | 902.10 | 3 |
| IV*† | Superior mesenteric artery, trunk | IV | 902.25 | 3 |
| | Celiac axis, proper | IV | 902.24 | 3 |
| | Vena cava, suprarenal and infrahepatic | IV | 902.10 | 3 |
| | Aorta, infrarenal | IV | 902.00 | 4 |
| V† | Portal vein | V | 902.33 | 3 |
| | Extraparenchymal hepatic vein | V | 902.11 | 3 |

(hepatic

| | | | |
|---|---|---|---|
| | | | vein) 5 (liver + veins) |
| Vena cava, retrohepatic or suprahepatic | V | 902.19 | 5 |
| Aorta, suprarenal and subdiaphragmatic | V | 902.00 | 4 |

Note: This classification is applicable to extraparenchymal vascular injuries. If the vessel injury is within 2 cm of the parenchyma of a specific organ, one should refer to the injury scale for that organ. *Increase grade by I if there are multiple injuries involving > 50% of vessel circumference.

†Reduce grade by I if laceration is < 25% of vessel circumference. AAST = American Association for the Surgery of Trauma; AIS = Abbreviated Injury Scale; ICD = International Classification of Diseases

**Penetrating trauma**

The majority of retroperitoneal vascular injuries are the result of penetrating trauma. By definition, any haematoma formed by a penetrating mechanism is uncontained and requires prompt exploration.

**Initial access and haemostasis:**

At times, vascular injuries present with massive intra-abdominal bleeding and familiarity with the techniques to control such haemorrhage expeditiously and to obtain access to vessels efficiently can be life-saving. Packing at the site of injury with laparotomy pads is always a reliable temporizing option. Often,initial control requires occluding the supracoeliac aorta at the level of the diaphragmatic hiatus using a vascular clamp, a T-bar, or direct pressure. Division of the gastrohepatic ligament and mobilization of the stomach and esophagus can provide access to this section of the aorta. Occasionally, division of the diaphragmatic crus is necessary for more proximal control. Once the proximal aorta has been occluded, definitive identification and repair of vascular injuries require adequate exposure of the involved vessels. Mattox manouevre (left medial visceral rotation) provides excellent access to the aorta, celiac axis, SMA, left renal artery and iliac arteries. A right medial rotation of the viscera (CATELL maneuver) readily exposes the vena cava with a combined KOCHER's maneuver, right renal vessels and iliac veins. The infra renal aorta may also be approached via a Tran peritoneal incision at the base of the mesocolon.

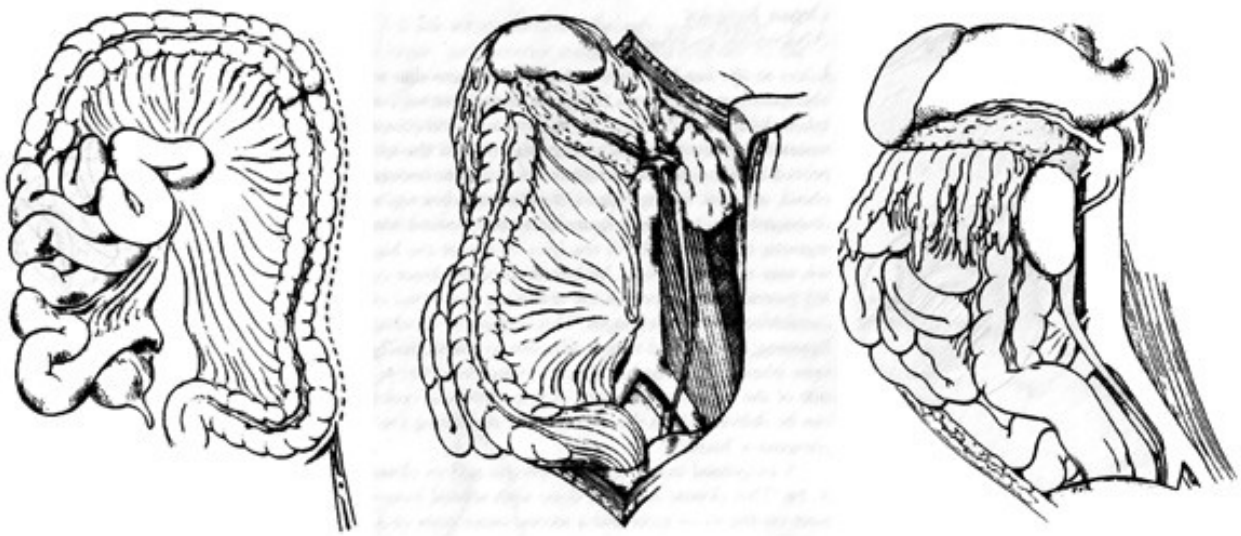

Mattox

Cattell & Braasch

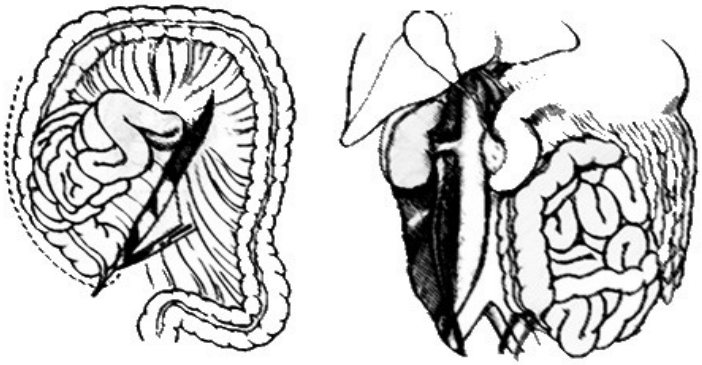

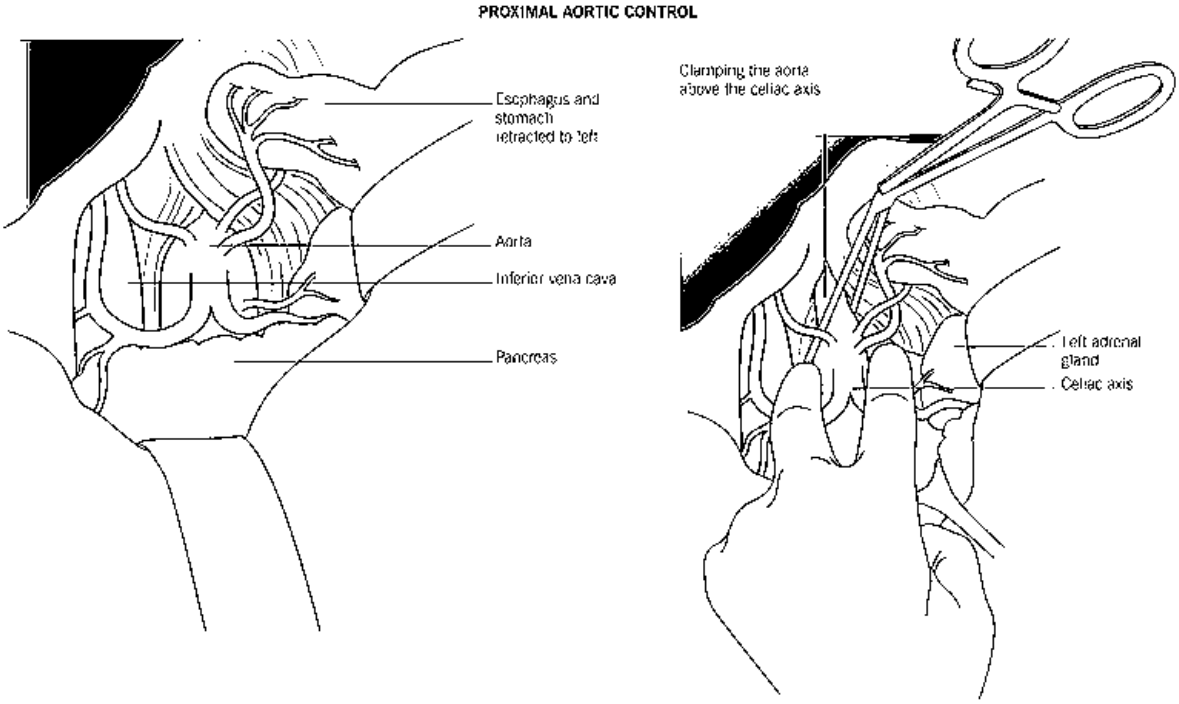
PROXIMAL AORTIC CONTROL
Esophagus and stomach retracted to left
Aorta
Inferior vena cava
Pancreas
Clamping the aorta above the celiac axis
Left adrenal gland
Celiac axis

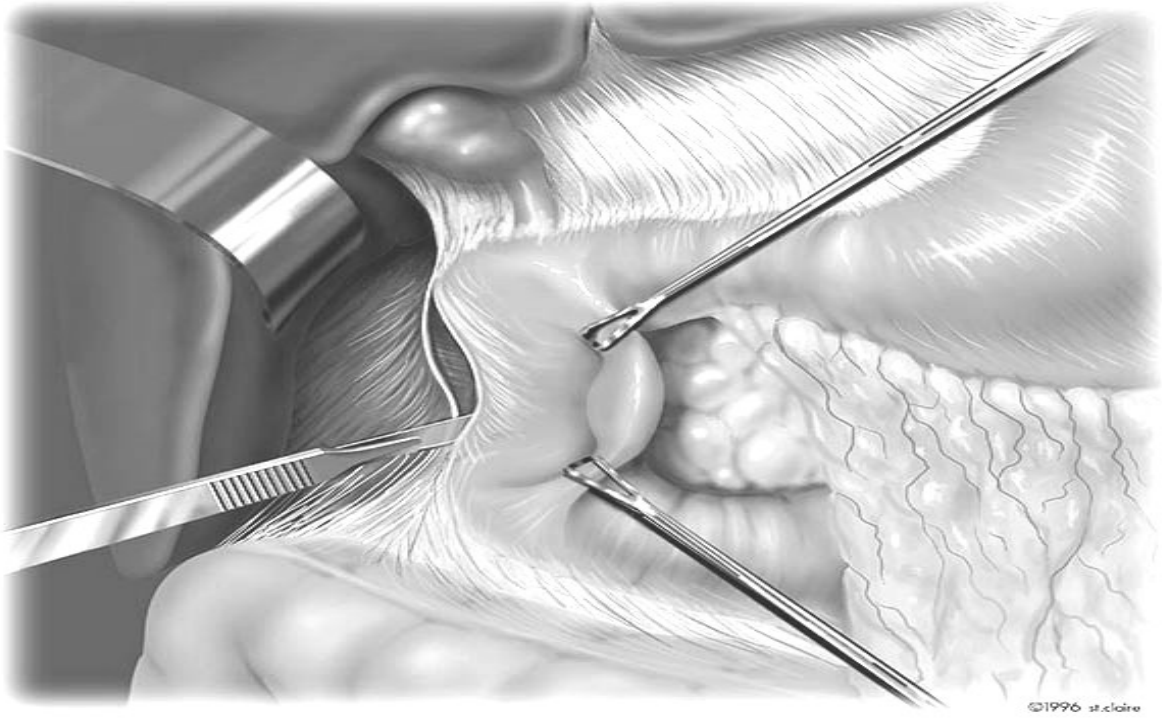
©1996 st.claire

## Blunt trauma

Blunt abdominal trauma can cause retroperitoneal vascular injury with resultant haematoma formation. Often these haematomas are discovered at operative exploration, but are sometimes seen on pre-operative imaging. The character and location of the haematoma determines management. The sources of haemorrhage and natural history of the retroperitoneal haematoma differ considerably depending on the aetiology. A pelvic retroperitoneal haematoma is caused by the loss of blood from sites of fractures, disruption of deep pelvic arteries, which are often distal branches of deep pelvic arteries, which are often distal branches from the internal iliac vessels. The most common cause of midline retroperitoneal haematomas from blunt trauma could be deceleration with avulsion of small branches from the aorta, inferior vena cava, superior mesenteric artery, or portal vein beneath the pancreas. Grey-Turner's sign is usually not present during the first day after injury; it is not helpful in the early diagnosis of the retroperitoneal haematoma. Haematuria with more than 30 RBCs/hpf suggests that CT may be indicated. Should a pelvic fracture be present in a patient with haematuria, a retrograde cystogram/retrograde urethrogram is indicated. Retroperitoneal bleeding is classified according to anatomic zones, which then guide management

Zone 1: Central / midline haematomas

Zone 2: lateral / flank / perirenal haematomas

Zone 3: pelvic haematomas

Zone 4: combination haematomas

Management

Proximal and distal control identify the zone of bleeding (zone 1/2/3/4)

Approach zone to expose and repair vessel. All zone 1 injuries must be Explored. Zone 2 injuries are explored if haematoma is pulsatile or Expanding. Zone 3 injuries are best leftalone unless specific indications for exploration are present.

***ZONE 1 Midline***

Supra mesocolic Access via left medial visceral rotation infra mesocolic. Access by lifting transverse colon superior and small bowel up to the right and divide ligament of Treitz. Superior mesenteric artery - Divided into four zones and management is according to the site of the injury. Zone 1: From its origin to the pancreatico-duodenal artery. Zone 2: From the pancreatico-duodenal artery to the origin of the middle colic artery , should be repaired primarily. Zone 3: From the trunk distal to middle colic should be repaired. Zone 4: Segmental branches – Jejunal,

Ileal, Colic may be ligated. Inferior mesenteric artery - Ligate if colon is not ischaemic.

***ZONE 2: lateral perirenal vessels.***

***ZONE 3: lateral pelvic vessels.***

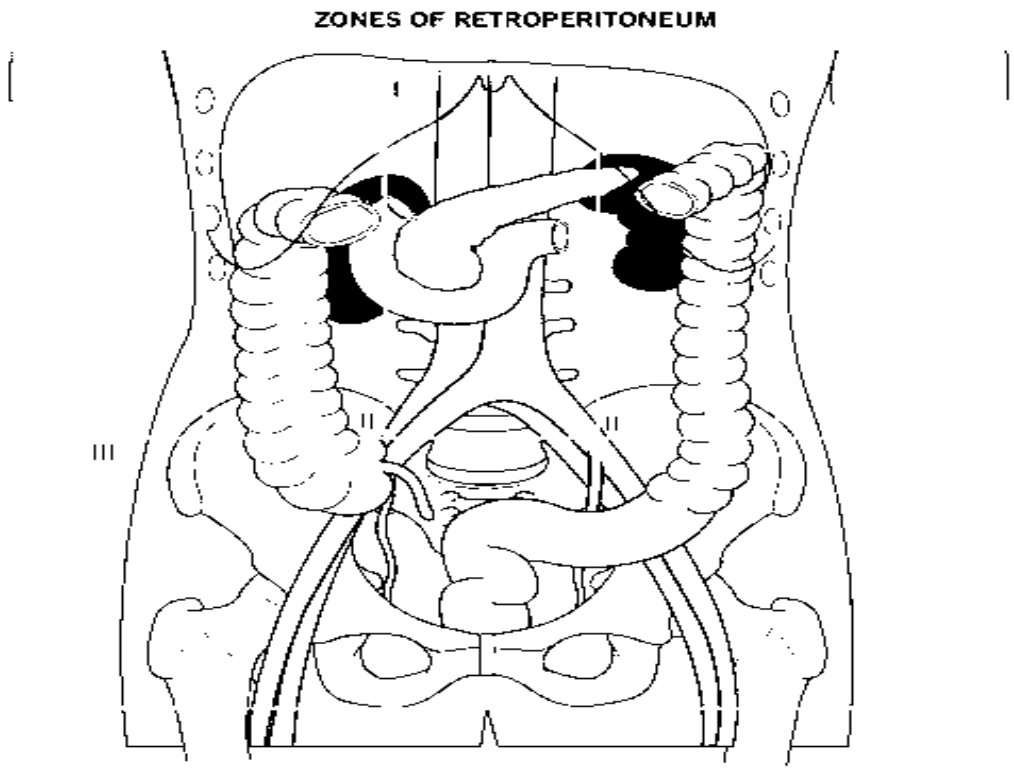

**Zone I supramesocolic**

Coeliac axis - Ligation

SMA (1st & 2nd parts) - repairligation is theoretically possible grafts and temporary shunts have been used. Infrahepatic suprarenal IVC - primarily repair from within the vessel where there has been massive destruction - ligate or use prosthetic graft

**Zone I infra-mesocolic**

SMA (3rd&4th parts)- primarily repair can individually ligate the main jejunal and colic branches of 4th part. Infrahepatic infrarenal IVC - primarily repair, ligating the lumbar veins. Ligation in cases of massive destruction is well tolerated

**Zone II**

Renal arteries

primarily repair *or* resect and replace with graft (prosthetic or autogenous)

Renal veins – repair or ligate

Right renal vein ligation requires right nephrectomy

Left renal vein ligation is better tolerated due to collaterals from left gonadal vein and renolumbar veins

**Zone III**

Often associated colonic and genitourinary injuries with significant contamination. Common iliac arteries - repair use autogenous or prosthetic grafts. Internal iliac arteries – ligation. External iliac arteries – repair. Iliofemoral graft can be performed. Iliac veins - ligation is well tolerated

**Inferior vena cava**

Complications of vena caval repairs or of expectant management of spontaneously tamponaded caval injuries are uncommon

Long term outcome for ligation of infra renal injuries is approximately the same as for repair.

These injuries are associated with a high mortality.

Infra renal IVC can be ligated if repair is not feasible.

Peri renal IVC should ideally be reconstructed.

Retro hepatic IVC haematomas should be left alone.

Endovascular techniques are being developed to stem IVC bleeds

Portal vein – repair/ligate

Should always be repaired in association with hepatic artery damage or when there is destruction of the potential collateral pathways.

## DAMAGE CONTROL SURGERY

Damage control is defined as the rapid initial control of hemorrhage and contamination, temporary closure,resuscitation to normal physiology in the ICU, and subsequent re-exploration and definitive repair.

Philosophy of damage control is “a live patient above all else.”

When to employ damage control ?

Multiple life-threatening injuries. Acidosis (pH < 7.2). Hypothermia (temp < 34°C).Hypotension and shock on presentation.Combined hollow viscus and vascular or vascularized organ injury. Coagulopathy (PT > 19 sec and/or PTT > 60 sec).

Injuries that typically require damage control techniques. Upper abdominal injuries that are not isolated spleen injuries (duodenal, large liver injuries, pancreas, and so forth). Major penetrating pelvic trauma of more than one system. Any retroperitoneal vascular injury.

Damage control is practiced in three phases**:**

1. Primary operation and hemorrhage control.
2. Critical care resuscitation.
3. Planned reoperation.

**Phase 1: Primary Operation and Hemorrhage Control**

Phase 1 of damage control includes 5 distinct steps:

1. Control of hemorrhage.
2. Exploration to determine extent of injury.
3. Control of contamination.
4. Therapeutic packing.
5. Abdominal closure.

Damage control laparotomy.

Rapidly achieve hemostasis. Perform only essential resections or pack solid organs to diminish blood loss.Close or divert all hollow viscus injuries.

Rapidly terminate the procedure to correct hypovolemia,hypothermia, and acidosis to prevent coagulopathy. Perform definitive reconstruction only after the patient has stabilized and can tolerate a prolonged operation. Contamination control also proceeds as injuries are encountered, utilizing clamps, primary repair or resection without reanastomosis. The presence and status of extra-abdominal injuries needs to be taken into consideration when deciding how much physiologic reserve the patient has left.

Therapeutic Packing. Definitive therapeutic packing is based on three basic principles. Pressure stops bleeding. Pressure vectors should recreate tissue

planes (attempt to recreate the pressure vectors created by the capsule of a solid organ or fill the space of that organ, not random pack placement). Tissue viability must be preserved.

**Abdominal Closure.**

Leave the fascia open. Vacuum pack  A silastic sheet or 3-liter IV bag sewnto the skin or fascia, can accomplish abdominal closure in virtually everyinstance.Skin closure is not recommended, but may be quickly accomplished with skin staples, towel clips (reliably stronger), or running monofilament suture. Skin closure may lead to abdominal compartment syndrome.

**Phase 2: Critical Care Considerations**

Physiologic support in the post-op TASC patient is paramount to survival.

**Core rewarming**: warmed resuscitative fluids, blankets, ventilator air, and environment, or commercially available products such as Bair Hugger.

**Reversal of acidosis**: appropriate/aggressive resuscitation with crystalloid, colloid, and blood products.

**Reversal of coagulopathy**: FFP/Cryoprecipitate/fresh blood

## Conduct of Relaparotomy

It is to be presumed that injuries were missed.A complete laparotomy must be performed in search of missed injury.The surgeon must exercise caution and sound judgment before performing full reconstruction of the GI tract because the patient is typically still critically ill and catabolic, making the patient less likely to heal anastomoses and even less likely to tolerate a leak or uncontrolled fistula.Feeding tube placement, either transabdominal or nasoenteric, should be placed at this time.Repacking may be re-employed if other measures fail to control hemorrhage.An abdominal film should be obtained to insure all packs have been removed from the abdomen. Sponge counts should be considered unreliable in this situation.Emergent, unplanned reexploration should be performed in any:

Normothermic patient with unabated bleeding (> 2 units of PRBCs/h).

Patient who develops severe intra-abdominal compartment syndrome.

Patient requiring postoperative transfusion of > 10 units of PRBCs.

Patient with persistent lactic acidosis.

## COLORECTAL INJURIES

The colon is the second most commonly injured organ in penetrating trauma, but injury is rare in blunt trauma (2-5%). However rectal injuries are more common in blunt trauma, especially when associated with pelvic injuries. Diagnosis of these injuries may be difficult - especially in the unconscious or obtunded patient. Maintaining a high degree of suspicion is vital to avoid missing these injuries. Simple, isolated colon injuries are uncommon. Small penetrating wounds can be closed with simple suture. More significant bowel injury should be treated with resection and anastomosis. Repair is with a single-layer, continuous, extra-mucosal, monofilament suture.Primary repair is also cheaper, especially when factoring into account the complications of colostomy closure. Debride wound edges to normal, noncontused tissue.

For complex injuries, strongly consider colostomy/ diversion, especially when associated with:

Massive blood transfusion requirement, On-going hypotension, Hypoxia (severe pulmonary injury), Reperfusion injury (vascular injury), Multiple other injuries, High-velocity injuries, Extensive local tissue damage, Potential breakdown of a repair or anastomosis is highest in the

setting of concomitant pancreatic injury. At the time of formation, a colostomy should be matured.

**Rectal Injuries**

In blunt trauma, rectal injuries are most commonly associated with pelvic fractures. Rectal examination should be performed on all pelvic injuries, looking for blood and bone fragments lacerating the rectal wall. Penetrating rectal injuries may be caused by injuries to the abdomen, thigh or buttock. In case of suspicion, rectum should be fully evaluated with digital examination and proctoscopy/ sigmoidoscopy. Even with these examinations it is possible to miss a significant rectal injury. Findings can be dramatic disruptions of the rectal wall but more commonly are subtle punctuate hemorrhages of the mucosa. All abnormal findings should prompt corrective intervention.

Extraperitoneal rectal injuries should be repaired primarily if possible. The rectum can be mobilised to allow repair, and posterior wall injuries repaired through an anterior wound or colotomy. Some low rectal injuries can be repaired trans-anally.

Where the position of the injury precludes repair a proximal, diverting colostomy should be performed. The options here are loop colostomy, loop with distal soma closed, a colostomy and mucus fistula or a Hartmann's procedure. Consider the traditional 4 "Ds" of rectal injury: **D**iversion, **D**ebridement, **D**istal washout, and **D**rainage.

Fecal contamination of the perirectal space mandates presacral drainage. Drains are placed through the perineum into the retrorectal space.

Washout of the distal rectal stump may reduce faecal load in the rectum, but may also force faecal material out of a rectal laceration

**Colon injury scale**

| Grade | Type of injury | Description | ICD -9 | AIS-90 |
|---|---|---|---|---|
| I | Hematoma | Contusion or hematoma without devascularization | 863.40-863.44 | 2 |
| | Laceration | Partial thickness, no perforation | 863.40-863.44 | 2 |
| II | Laceration | Laceration <50% of circumference | 863.50-863.54 | 3 |
| III | Laceration | Laceration ≥ 50% of circumference without transaction | 863.50-863.54 | 3 |
| IV | Laceration | Transection of the colon | 863.50-863.54 | 4 |
| V | Laceration | Transection of the colon with segmental tissue loss | 863.50-863.54 | 4 |
| | Vascular | Devascularized segment | 863.50-863.54 | 4 |

**Rectal injuries organ injury scale**

| Grade | Type of injury | Description | ICD-9 | AIS-90 |
|---|---|---|---|---|
| I | Haematoma | Contusion or hematoma without devascularization | 863.45 | 2 |
| | Laceration | Partial-thickness laceration | 863.45 | 2 |
| II | Laceration | Laceration < 50% of circumference | 863.55 | 3 |
| III | Laceration | Laceration ≥ 50% of circumference | 863.55 | 4 |
| IV | Laceration | Full-thickness laceration with extension into the perineum | 863.55 | 5 |
| V | Vascular | Devascularised segment | 863.55 | 5 |

Advance one grade for multiple injuries up to grade III.

Rectal injuries above the peritoneal reflection can be treated as colonic injuries and repaired primarily.

# RESULTS

A total of 98 cases were studied,their RPTS evaluated, the methods of management and their prognosis are analysed.

The correlation of the RPTS based on the clinical parameters *viz* abdominal pain, rigidity, haematuria & hypotension with the severity of retroperitoneal injury was studied.

All the patients with blunt and penetrating abdominal trauma presenting to the trauma were included in the study.

Of the total 98 cases taken up for study :

76 male patients and 22 female patients

| Males | females |
|---|---|
| 76 | 22 |
| 77. 55% | 33. 55% |

20 blunt injuries and 78 penetrating injuries

| Blunt | penetrating |
|---|---|
| 20 | 78 |
| 20.40 % | 79. 60 % |

83 road traffic accidents and 15 domestic violence cases

| RTA | Domestic violence |
|---|---|
| 83 | 15 |
| 84 .69 % | 16. 31 % |

**Age distribution of Cases**

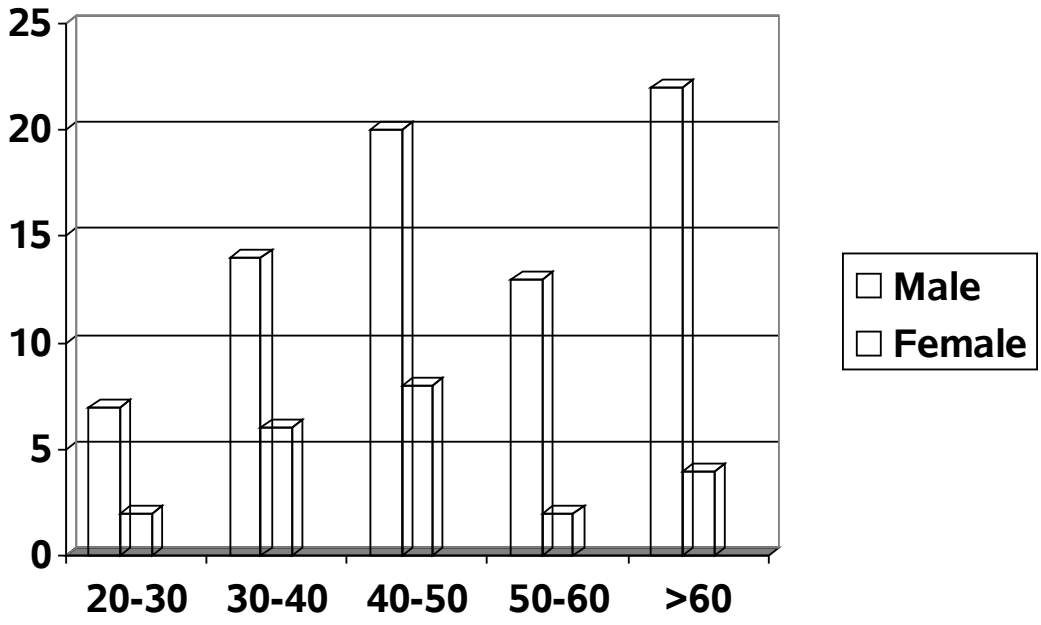


The distribution of individual retroperitoneal organ injuries amongst the traumatized 98 was as follows :

Pancreaticoduodenal injuries – 15, Renal injuries – 12, Bladder injuries – 21, Retroperitoneal vascular injuries -1, Retroperitoneal haematoma - 30, Anorectal injuries – 2, combined retroperitoneal injuries –17

Of the 98 patients taken up for study , a total of 54 cases had a RPTS of >/= 5 and hence were taken up for exploratory laparotomy .Of the 54,

17cases were that of combined retroperitoneal injuries three demonstrating a huge retroperitoneal haematoma associated with a longitudinal tear of size 3 x 0.5 cms in the anterior aspect of the SMV at its confluence with the portal vein as well as a rent in in the dome of the bladder of size 2.5 x 1 cms. The other multi organ injury included a duodenal tear extending onto the terminal CBD associated with a renal laceration.

15 cases were of pancreaticoduodenal injury,12 of renal trauma ,21 cases of bladder injury,1 of retroperitoneal vascular injuries , 2 anorectal , 30 cases of retroperitoneal haematoma and 17 combined injuries .

Pancreaticoduodenal injuries foemed 18. 51% of cases, renal 14. 81%

All of the 51 cases were managed as per the recent AAST guidelines.

The other lot of 30 that had a RPTS of < 5 were managed conservatively Subsequent evaluation of the 12 Patients with contrast enhanced CT revealed no major retroperitonal injury warranting surgical exploration and management.

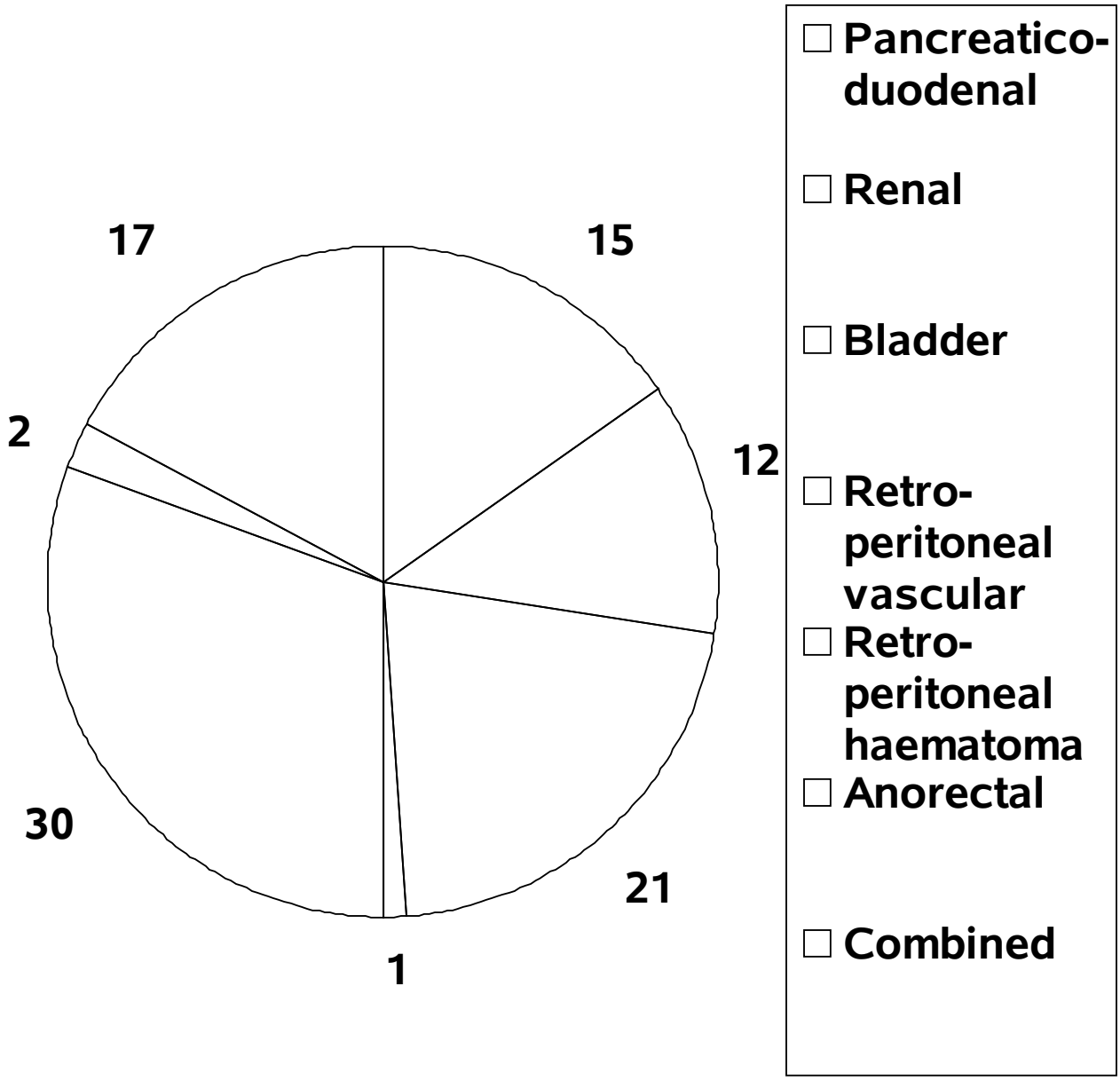
17
15
2
12
30
21
1
Pancreatico-duodenal
Renal
Bladder
Retro-peritoneal vascular
Retro-peritoneal haematoma
Anorectal
Combined

| Type of injury | No of cases | % 0f Cases |
|---|---|---|
| Pancreaticoduodenal | 15 | 15.30 |
| Renal | 12 | 12.24 |
| Bladder | 21 | 21.42 |
| Retroperitoneal vascular | 01 | 1.02 |
| Retroperitoneal haematoma | 30 | 30.61 |
| Anorectal | 02 | 2.04 |
| Combined | 17 | 17.34 |

# CONCLUSION

**1. ISOLATED RETROPERITONEAL INJURIES ARE LESS COMMONER THAN COMBINED INJURIES**

**2. ROAD TRAFFIC ACCIDENT CAUSED INJURIES ARE PREDOMINANT IN OUR SERIES**

**3. CT SCAN IS FOUND TO BE THE BEST MODALITY TO CONFORM THE ORGAN INJURIES**

**4. EARLIER TRANSPORT TO THE TERTIARY CENTRE AND RAPID INVESTIGATION AND INTERVENTION GIVES GOOD PROGNOSIS**

**5 .CONSERVATIVE LINE OF MANAGEMENT IN THE CASES OF MINOR INJURIES GIVES BEST RESULT**

---

# REFERENCES

1. Anatomy of the retroperitoneum ***G J C Burkill, BSc, MRCP, FRCR and J Healy, MRCP, FRCR Imaging 12:10-20(2000).***

2. Abdominal vascular injuries (Trauma Rounds). Lim RC: West J Med 123:321-324, Oct 1975.

3. Evaluation of abdominal trauma David V.Feliciano,MD,FACS,Grace S.Rozycki,MD,FACS American college of surgeons,committee on trauma,subcommittee on publications, 2003

4. Emergency war surgery chapter 17 Abdominal injuries

5Surgical exploration of the injured kidney: current indications and techniques. . METRO, Michael J.; MCANINCH, Jack W. **Int. braz j urol.**, Rio de Janeiro, v. 29, n. 2, 2003.

6. Review of pancreatic trauma. Glancy KE West J Med 1989 Jul; 151:45-51

7. Pancreatic Trauma from a Book Ismail H Mallick1, Muhammed H Thoufeeq JOP. J Pancreas (Online) 2004; 5(4):217-219.

8. Severe duodenal injuries. Treatment with pyloric exclusion and gastrojejunostomy T. D. Martin; D. V. Feliciano; K. L. Mattox; G. L. Jordan, Jr Arch Surg 1983 118: 631-635

9. Retroperitoneal duodenal injury due to blunt abdominal trauma. Talbot WA, Shuck JM. Am J Surg. 1975 Dec;130(6):659–666.

10. Penetrating Duodenal Injuries Analysis of 100 Consecutive Cases RAO R. IVATURY, M.D., F.A.C.S., MANOHAR NALLATHAMBI, M.D., F.A.C.S., JEAN GAUDINO, M.D., F.A.C.S., MICHAEL ROHMAN, M.D., F.A.C.S., WILLIAM M. STAHL, M.D., F.A.C.S. Ann. Surg. * August 1985,153-158.

11. PRACTICE MANAGEMENT GUIDELINES FOR THE VALUATION OF BLUNT ABDOMINAL TRAUMA EAST Practice Management Guidelines Work Group William S. Hoff, MD,1 Michelle Holevar, MD,2 Kimberly K. Nagy, MD,3 Lisa Patterson, MD,4 Jeffrey S. Young, MD,5 Abenamar Arrillaga, MD,6 Michael P. Najarian, DO,7 Carl P. Valenziano, MD8 2001 Eastern Association for the Surgery of Trauma .

12. 'Focused abdominal sonography for trauma (FAST)'. Yeo A, Wong CY, Soo KC Ann Acad Med Singapore 1999; 28:805-809

13. Management of blunt and penetrating colon injuries. Bugis SP, B. N., Letwin ER Am J Surg 1992; 163(5): 547-50

14. Rectal trauma: management based on anatomic distinctions. McGrath V, Fabian TC, Croce MA, Minard G, Pritchard FE Am Surg. 1998;64(12):1136-41

15. The evolution of abdominal stab wound management.' Thompson JS, Moore EE, Van Duzer-Moore S, Moore JB, Galloway AC ' J Trauma. 1980;20:478-84

16. 'Experience with over 2500 diagnostic peritoneal lavages. Nagy KK, Roberts RR, Joseph KT et al ' Injury. 2000;31: 479-82

17. 'Diagnostic laparoscopy in abdominal stab wounds: a prospective, randomized study. Leppaniemi A, Haapiainen R ' J Trauma. 2003;55: 636-45

18. Damage Control - an approach for improved survival in exsanguinating penetrating abdminal injury'. Rotondo MF, Schwab CW, McGonigal MD et al. J Trauma 1993;35: 375-382

19. Consensus statement on bladder injuries Reynaldo G. Gomez, Lily Ceballos, Michael Coburn, Joseph N. Corriere Jr, Christopher M. Dixon, Bernard Lobel, Jack McAninch BJU International 2004 94:1 27

20. Traumatic retroperitoneal hematoma. BAYLIS SM, LANSING EH, GLAS WW Am J Surg. 1962 Apr;103: 477–480