A STUDY OF SURGICAL ASPECTS OF BULL GORE INJURIES

Dissertation submitted for

BRANCH I – M.S., (General Surgery)

MARCH 2007

THE TAMILNADU DR.M.G.R. MEDICAL UNIVERSITY

CHENNAI – TAMILNADU

CERTIFICATE

This is to certify that this dissertation entitled **"A STUDY OF SURGICAL ASPECTS OF BULL GORE INJURIES"** submitted by **Dr. R. BALAJI** to **The Tamil Nadu Dr.M.G.R. Medical University, Chennai,** is in partial fulfillment of the requirement for the award of M.S. degree Branch I (General Surgery) and is a bona fide research work carried out by him under direct supervision and guidance.

Dr. M.N. KAMALUDEEN,
M.S., F.I.C.S, F.A.I.S
Additional Professor,
Department of Surgery,
Govt. Rajaji Hospital,
Madurai Medical College,
Madurai.

Dr.M.KALYANASUNDARAM,
M.S., F.I.C.S
Professor and Head of the
Department of Surgery,
Govt. Rajaji Hospital,
Madurai Medical College,
Madurai.

DECLARATION

I, **Dr. R. Balaji,** declare that I carried out this work on **"A STUDY OF SURGICAL ASPECTS OF BULL GORE INJURIES"** at the Department of General Surgery, Government Rajaji Hospital during the period of December 2005 – June 2006. I also declare this bona fide work or any part of this work was not submitted by me or any other for any award, degree or diploma to any university, board either in India or abroad.

This is submitted to the **Tamil Nadu Dr. M .G .R. Medical University, Chennai** in partial fulfillment of the rules and regulation for the M.S. Degree examination in General Surgery.

Govt. Rajaji Hospital **Dr.R.BALAJI**

Madurai.

ACKNOWLEDGEMENT

I wish to express my sincere gratitude to my chief **Prof.Dr.M.N.Kamaludeen, M.S., F.I.C.S., F.A.I.S.,** Additional Professor, Department of Surgery, Government Rajaji Hospital and Madurai Medical College for his guidance in completing this study successfully.

I wish to express my sincere gratitude to **Prof.M.Kalyanasundaram M.S., F.I.C.S**, Head of the Department of Surgery, Govt. Rajaji Hospital and Madurai Medical College for his excellent guidance and constant encouragement in completing this study.

Dr.M.Murugappan M.S., Dr. Geetha M.S., and Dr.Raja Chandrasekar M.S., Assistant Professors of Surgery of the IV Surgical Unit have always been helpful to me to complete this study.

I wish to express my thanks to the Dean, Government Rajaji Hospital and Madurai Medical College, Tamil Nadu for letting me use the clinical material from this hospital; and last but not the least I am thankful to all the patients who have extended their cooperation and participated in this study.

CONTENTS

INTRODUCTION

Trauma can occur as a result of many causes and have multi various effects. Among these, in a country like ours, where agriculture is the main occupation for the large majority of the population, contact with cattle is to be expected in some degree and as a result of this contact, injuries are bound to occur. Coupled with this, the bull taming festival that is held every year during the harvest season in the month of January, contributes in a huge way to the occurrence of bull gore and associated injuries that are unique to this part of the country.

The majority of these are managed at the primary care level but a substantial number of victims are still referred to the tertiary care centers. They may take the form of abdominal, thoracic, orthopedic or commonly, soft tissue injuries. So far there have been no studies that have attempted to analyze these injuries.

This study was undertaken with this in mind so that the various types of injuries and the age and sex distribution, hospital stay, in hospital outcome, mortality and morbidity and other factors can be analyzed to some extent. The study was conducted among the patients admitted with bull gore injuries in the Govt. Rajaji Hospital, Madurai in the time period December 2005 to June 2006.

DIAGNOSTIC MODALITIES

The history of the traumatic event is particularly important in determining the likelihood of the organ injured. Upon arrival to the hospital, history and physical examination are usually accurate in determining intra-abdominal injury in the awake and responsive patient, although the limitations of the physical examination are significant. The test of choice depends on the hemodynamic stability of the patient and the severity of associated injuries.

Patients with isolated penetrating abdominal trauma who are admitted hypotensive, in shock, or with peritoneal signs should go to the operating room despite the mechanism of injury. Stab wound victims without peritoneal signs, evisceration, or hypotension benefit from wound exploration and DPL.

Thoracic injuries suggestive of tension pneumothorax, cardiac tamponade etc. should have ICD insertion even before X rays are taken. Orthopedic injuries are managed with the resuscitation of the patient in mind and then the requisite radiographs ordered.

PLAIN RADIOGRAPHS

The chest x-ray is a useful test to reveal pneumoperitoneum, abdominal contents in the chest (ruptured hemidiaphragm), or lower rib fractures. This later sign increases the probability of splenic and hepatic injuries. In cases of orthopedic injuries preliminary X rays are taken after the initial resuscitation of the patients.

An intravenous pyelography and a retrograde cystogram are useful tests in the evaluation of a trauma patient with hematuria. Occlusive views are useful in case of suspected maxillary or mandibular injuries.

X rays of the skull, lumbo sacral spine and cervical spine lateral view provide necessary information in patients presenting in an unconscious state following a fall from height in bull gore injuries or after being thrown by the bull.

ULTRASOUND

Ultrasound has been used more frequently in recent years. The objective of ultrasound evaluation is to search for free intraperitoneal fluid. It can be done expeditiously, and it is as accurate as DPL in detecting hemoperitoneum. It can also evaluate the liver and the spleen once free fluid is identified; however, that is not its main purpose. Portable machines can be used in the

resuscitation area or in the emergency department in the hemodynamically unstable patient without delaying the resuscitation. Another advantage of ultrasound over DPL is its noninvasiveness. No further work-up is necessary after a negative ultrasound in a stable patient. CT scan of the abdomen usually follows a positive ultrasound in a stable patient. The sensitivity ranges from 85 to 99%, and the specificity from 97 to 100%. USG can also be useful in determining effusion/ hemarthrosis of the joints following the injury.

Advantages and Disadvantages of Ultrasound

ADVANTAGES

Noninvasive

Does not involve use of radiation

Useful in the resuscitation room or emergency department

Can be repeated

Used during initial evaluation

Low cost

DISADVANTAGES

Examiner dependent

Obesity

Gas interposition

Lower sensitivity for free fluid <500 ml

False-negatives: retroperitoneal and hollow viscus injuries

CT SCAN

The retroperitoneum is best evaluated by CT scan. The drawback of CT scan is that the patient needs to be transported to the radiology department and it is expensive compared with other tests. CT scan also evaluates solid organ injury and in the stable patient with a positive ultrasound, it is indicated to grade organ injury and to evaluate contrast extravasation. If contrast extravasation is seen, even in minor hepatic or splenic injuries, an exploratory laparotomy or, more recently, angiography and embolization are indicated. Another indication for CT scan is in the evaluation of patients with solid organ injuries initially treated nonoperatively who are seen with a falling hematocrit. The most important disadvantage of CT scan is its inability to reliably diagnose hollow viscus injury. Usually, the presence of free fluid on CT scan without solid organ injury should raise the suspicion of mesenteric, intestinal or bladder injury, and an exploratory laparotomy is often warranted. The accuracy of CT scan ranges from 92 to 98% with low false-positive and false-negative rates.

In cases of spinal injuries CT scan and MRI play an important role. CT scan of the brain may be needed to rule out intracranial bleed following a fall sustained by the bull gore. Similarly CT scan of the facial bones etc. may come in useful in the management of those patients with severe facial lacerations to find out if any fractures of the bony skeleton have occurred.

In patients with thoracic injuries once the acute stage has been managed, the CT scan may have a role to identify areas of lung contusion, parenchymal and mediastinal involvement. It assumes importance in the localization of loculated collections or abscesses that may be drained under image guidance or by marking the site and later intercostal drainage may be done as appropriate.

Advantages and Disadvantages of Abdominal Computed Tomography Scan

ADVANTAGES

Adequate assessment of the retroperitoneum

Non operative management of solid organ injuries

Assessment of renal perfusion

Noninvasive

High specificity

DISADVANTAGES

Specialized personnel

Hardware

Duration: helical versus conventional

Hollow viscus injuries

Cost

Radiation Exposure

MAGNETIC RESONANCE IMAGING

Though not of much use in the acute care setting, the role of MRI is invaluable in the management of patients with spinal injuries when they have been thrown to some distance by the bull. It may also have a role in defining deep hematomas but is hardly likely to be used for such a purpose. Retroperitoneal collections can be easily identified but CT provides the same information much faster and is cheaper too.

ADVANTAGES

Good soft tissue resolution

No radiation

Can be used in pregnancy

DISADVANTAGES

High cost

Time factor

Patient claustrophobia

Pacemaker and other implants in patients

OTHER DIAGNOSTIC MODALITIES

The use of diagnostic laparoscopy in the trauma patient is very limited. It is an invasive and expensive method and does not seem to be superior to other methods used for decision making. Missed small bowel, splenic, and retroperitoneal injuries have been reported. It seems that laparoscopy is the best method to evaluate diaphragmatic injuries after thoraco abdominal penetrating injuries. Angiography is used to evaluate renal artery thrombosis, to manage pelvic hemorrhage in patients with pelvic fractures, and bleeding from minor hepatic and splenic injuries.

While the investigations to make the diagnosis and those affecting the treatment are being carried out, it must be borne in mind that the basic blood investigations and the rest must also be simultaneously done and the patients' co-morbid conditions may warrant further investigations as dictated by the circumstances.

REVIEW OF LITERATURE – PATHO PHYSIOLOGY AND MANAGEMENT

GRADING OF HEPATIC INJURIES[31] (Liver injury scale 1994 revision) *advance one grade for multiple injuries up to grade III

LIVER INJURIES[25,31]

Liver is frequently injured in both blunt and penetrating trauma. Because of its size, injuries sufficient to lacerate liver are associated with injuries to other organs in about 80% cases. 85% of liver injuries are not bleeding at the time of laparotomy and patients tolerate these injuries very well[25]. Most liver injuries will in fact require only documentation and no drainage. The minority of liver injuries therefore require definitive surgical care. The history of injury is helpful in that, any penetrating injury to the right rib cage or upper abdomen and a patient, being in shock at the scene following blunt trauma abdomen; should be suspected of having a major liver injury.

After resuscitation of the patients, plain x-ray abdomen should be taken. It may show altered liver border, hemoperitoneum and associated rib fractures. Abdominal paracentesis is positive, if a large amount of blood is present in the peritoneal cavity. DPL is

diagnostic of minimal hemo peritoneum, but not specific for liver injury. CT is the investigation of choice in the multiply injured patient, provided the patient is hemodynamically stable. Radionuclide scans are rarely done to document the location of biliary fistula after the repair of hepatic injuries.

TREATMENT[31]

I. NON OPERATIVE MANAGEMENT

It is indicated in

1. Hemodynamic stability
2. Normal mental status
3. Absence of a clear indication for laparotomy such as peritoneal signs
4. Low grade liver injuries (grade 1 to 3) and
5. Transfusion requirements of less than 2 units of blood.

These patients were followed by serial hematocrit and vital signs. During observation if the patient shows signs of bleeding, angiography and selective embolisation can be done.

Indications for laparotomy during observation are

1. Continuing need for blood transfusion
2. Deteriorating vital signs
3. Peritoneal signs

4. Progressive expansion of hematoma and
5. Hematoma thought to represent a septic focus.

II. OPERATIVE MANAGEMENT[25,31]

(A) Simple Techniques of repair

1. Drainage of non bleeding injuries is rarely performed nowadays
2. **Compression:** Small cracks in the capsules can be treated by compression for 5 to 10 minutes to stop bleeding.
3. **Topical agents**: The application of gel foam, microcrystalline collagen pad or fibrin glue is used when avulsion of Glisson's capsule is present. After application of topical agent to the raw hepatic surface, compression is applied with pads for 5 minutes. After removal of pads, electrocautery can be used for any bleeders.
4. **Suture hepatorrhaphy:** Horizontal mattress sutures with 1-0 vicryl or simple continuous suturing with 1/0 vicryl can be done - with these measures most of the bleeding stops.

(B) Advanced Techniques of Repair:

1. Extensive hepatorrhaphy:

If simple suturing fails to stop the bleeding, multiple horizontal mattress sutures can be placed; but bleeding from the

intra lobar branches of the hepatic artery, portal vein or hepatic vein is not controlled by this method.

2. Hepatotomy with selective vascular ligation:

It is indicated when bleeding vessels are situated deeply. Hepatotomy is done with ***finger fracture*** technique. Bleeding vessels and biliary radicals are identified and ligated.

3. Omental Pack:

In 1975 Stone and Lamb first described the use of viable pedicle of omentum placed into deep lobar lacerations to control hemorrhage at the base. Viable omentum separated from the transverse colon can be placed over liver lacerations to control bleeding, especially in the bare area of liver.

4. Resection & debridement with selective vascular ligation:

It is indicated whenever there is friable and partially devascularised hepatic tissue on the edge of liver or in a hepatic laceration. It is used in preference to anatomic segmentation or lobectomy, as these techniques frequently sacrifice larger amounts of normal hepatic tissue.

5. Resection:

It is indicated in the case of total disruption of a lobe or segment in the form of lobectomy or segmentectomy.

6. Selective hepatic artery ligation:

When selective vascular ligation fails, ligation of the hepatic artery is an alternative. It may produce dramatic hemostasis without subsequent liver failure, but this should be done as close to liver as possible and only as a last resort.

7. Peri hepatic packing:

This technique involves the insertion of laparotomy pads or rolls of gauze around the injured liver but not into the hepatic laceration. Packs can be removed 12 hrs after packing. Re-bleeding and sepsis are common complications.

8. Drainage:

Open Penrose drainage has been used after operative treatment but incidence of intra abdominal sepsis is common.

Complications:

Significant complications following liver injury include

1. Pulmonary complications
2. Coagulopathy
3. Hypo glycemia
4. Jaundice
5. Biliary fistulas
6. Haemobilia and

7. Sub diaphragmatic and intra parenchymal abscess formation

Splenic injuries[25,31] :

In penetrating trauma, wound of entry in the left chest, flank or left upper abdomen should arouse suspicion of splenic injury. The clinical picture of splenic injury includes left upper quadrant abdominal pain, signs of blood loss and pain in the left shoulder (Kehr's sign).

Management

The management of splenic injuries has been the subject of major re-examination over the past decade. The recognition of fatal pneumococcal septicemia in patients undergoing splenectomy has led to an interest in splenic salvage.

Plain abdominal films may show

1. Enlargement of splenic shadow
2. Elevation of left hemi diaphragm
3. Medial displacement of splenic shadow or stomach and/or
4. Widening of the space between the splenic flexure and peritoneal pad of fat.

Peritoneal lavage should be performed when there is possibility of splenic injury. If positive, it indicates the need for laparotomy. Ultrasound, CT scanning and radionuclide scan can reveal the grade of significant splenic injury.

Grading of splenic injury[31] Spleen injury scale (1994 revision)

Grade*	Type of Injury	Description of injury
I	Hematoma Laceration	Subcapsular, <10% surface area Capsular tear <1cm parenchymal depth
II	Hematoma Laceration	Subcapsular 10-50% surface area Intra parenchymal <5cm in diameter Capsular tear, 1 to 3 cm parenchymal depth that does not involve a trabecular vessel.
III	Hematoma Laceration	Subcapsular >50% surface area or expanding/ruptured sub capsular or parenchymal hematoma. >3 cm parenchymal depth
IV	Laceration	Laceration involving segmental or hilar vessels producing major devascularization (>25% of spleen)
V	Laceration Vascular	Completely shattered spleen Hilar vascular injury that devascularizes spleen

* - Advance one grade for multiple injuries up to Grade III

I Non operative management[4,31]

More than 70% of all stable splenic injuries are being treated by a non operative approach.

Criteria for non operative management of splenic injury are

1. Hemodynamic stability
2. Negative Peritoneal signs

3. Absence of contrast extravasation on CT
4. Absence of other clear indications for exploratory laparotomy or associated injuries requiring a surgical intervention and
5. Absence of associated health conditions that carry an increased risk of bleeding (coagulopathy, hepatic failure, use of anticoagulants) and grade 1 to 3 injuries.

The risks of non operative management are missed injury to other viscera and delayed rupture of sub capsular hematomas. Patients are usually admitted in ICU and serial abdominal examination and hematocrit are done during the initial 48 to 72 hours. The patient should be followed sequentially with CT scan.

II Spleen conserving surgery[4, 22, 31]

During the course of laparotomy the spleen in evaluated for hemorrhage. The repair is not attempted if

1. It is a multiple injury case,
2. Patient is in shock (systolic pressure <90mmHg) or
3. There are medical contraindications to prolonged surgery. (bleeding disorder, cardiac, pulmonary or hepatic disease)

If the patient's condition is favorable the decision to repair is based on the state of the spleen. Generally, Grade IV and Grade V

injuries are not suitable for repair whereas it can be attempted in Grade I, II and III.

Splenorhaphy[4, 22, 31]

The following are the techniques for splenic repair.

1. Local hemostatic agents:

Gelatin foam, surgical cellulose, microfibrillar collagens, thrombin, cyanoacrylate & autologous fibrin glue can be used for superficial tears which are not bleeding actively. But often pressure alone may be sufficient. Non bleeding tears are best left alone.

2. Suture repair:

Deep parenchymal tears are managed by this technique. After removal of the clot and loose devitalized tissue, the wound is inspected, arterial bleeders are controlled and the parenchyma is approximated using deep mattress sutures- vertical or horizontal- including the fibrous capsule using absorbable suture materials.

3. Partial splenectomy:

Polar injury which is grade IV can be managed by segmental devascularization and debridement by ***finger fracture technique*** at the line of demarcation. Additional security to the suture line after suture repair or partial splenectomy can be achieved by omental wrap.

4. Heterotopic auto transplantation of the splenic tissue:

If the patient's condition permits, the splenic function can be preserved even after splenectomy by auto transplantation at sites like gastrocolic omentum, rectus sheath and anterior abdominal wall. To be effective in preserving adequate splenic function approximately one third of the original spleen must remain and be nourished by an adequate circulation.

III Splenectomy[4,31]

It is indicated in

1. Shattered or avulsed spleen
2. Severely hypotensive patients
3. Association with other severe injuries
4. Undue delay in attempting to repair the spleen

Complications of splenectomy

1. Early transient thrombocytosis, which resolves spontaneously over 1-3 months.
2. Acute dilatation of stomach
3. Injuries to the fundus of the stomach
4. Pancreatic fistula
5. Delayed hemorrhage
6. Pancreatitis

7. Sub phrenic abscess
8. Left lower lobe atelectasis and pleural effusion
9. Fatal pneumococcal septicemia (OPSI – Overwhelming Post Splenectomy Infection)

GASTRIC INJURIES[25,31,35]

Injuries of the stomach are common in penetrating trauma but very rare in blunt trauma. The stomach is intra thoracic, partially protected by rib cage and any penetrating wound in this area should be suspected of causing injury to stomach. After resuscitation, a nasogastric tube is placed that serves both diagnostic and therapeutic functions. The return of gross blood on nasogastric aspirate is suggestive of an upper gastrointestinal injury.

Haematemesis or bright red blood per nasogastric tube was present in 45% of gunshot wounds and 37% of stab wounds in series of patients with gastric injuries treated at Parkland memorial hospital[25]. The nasogastric tube also serves a therapeutic function by decompressing stomach.

OPERATIVE MANAGEMENT

The intra operative evaluation of stomach injury includes good visualisation of the hiatus, evaluation of the anterior portion of the

stomach, division of gastrocolic ligament and complete visualization of the posterior aspect of the stomach. Penetrating wounds are debrided and primary closure is performed. Injuries with major tissue loss may best be treated by gastric resection. Post operative complications include

1. Bleeding – usually from the submucosal vessels,
2. Intra abdominal abscess and more rarely
3. Gastric fistulae

DUODENAL INJURES[25, 31]

The majority of duodenal injuries are caused by penetrating trauma. The incidence of duodenal injuries varies from 3% to 5%. Most of duodenal injuries are accompanied by other intra abdominal injuries.

DIAGNOSIS OF DUODENAL INJURIES

Serum amylase is sensitive but unfortunately not specific for duodenal injuries. Needle paracentesis or lavage will often be positive for blood, bile or bowel contents.

Plain films of the abdomen shows

1. Mild scoliosis
2. Obliteration of the right psoas shadow
3. Absence of air in the duodenal bulb and/or

4. Air in the retroperitoneum outlining the kidney.

Other investigations include gastrografin upper gastrointestinal series and CT of the abdomen.

Grade*	Type of Injury	Description of injury
I	Hematoma Laceration	Involving single portion of duodenum Partial thickness, no perforation
II	Hematoma Laceration	Involving more than one portion Disruption <50% of circumference
III	Laceration	Disruption 50% to 75% of circumference of D2. Disruption of 50% to 100% of circumference of D1, D3 or D4.
IV	Laceration	Disruption of >75% of circumference of D2 involving ampulla or distal common bile duct.
V	Laceration Vascular	Massive disruption of duodeno pancreatic complex Devascularisation of duodenum

* – Advance one grade for multiple injuries up to Grade III.

Treatment[31, 33, 35]

Intra operative evaluation of the duodenum requires an adequate mobilization of the duodenum by means of a Kocher's maneuver. 80 to 85% of duodenal wounds can be primarily repaired. The remaining 15 to 20% are severe injuries that require more complex procedures.

In minor injuries (Grade I & II) diagnosed within 6 hours of injury, a simple primary repair is suitable. After 6 hours, the risk of

leak increases and some form of duodenal decompression like transpyloric nasogastric tube, tube jejunostomy, tube duodenostomy is advisable.

Grade III injuries are best treated by primary repair, pyloric exclusion and drainage; or alternatively Roux-en-Y duodenojejunostomy.

Grade IV injuries are treated by primary repair of the duodenum, repair of the common bile duct and placement of T-tube with a long transpapillary limb or a choledochoenteric anastomosis can be performed.

Grade V injuries are best treated by pancreatico duodenectomy. The most common complication after duodenal injury is the development of a duodenal fistula.

PANCREATIC INJURIES [25, 31]

Pancreatic injuries are rare accounting for 10% to 12% of all abdominal injuries. The great majority of such injuries are caused by penetrating injuries. Major abdominal vascular injuries are present in more than 75% of cases of penetrating pancreatic trauma. Fistula, pseudocyst, pancreatitis, anastomotic leak and intra

abdominal abscess occur in 1/3rd of the patients and account for the late mortality. Mortality rates ranges 10 to 25% mostly due to associated intra abdominal injuries.

GRADING OF PANCREATIC INJURY[31]

Grade*	**Type of Injury**	***Description of injury***
I	Hematoma Laceration	Minor contusion without duct injury Superficial laceration without duct injury
II	Hematoma Laceration	Major contusion without duct injury or tissue loss Major laceration without duct injury or tissue loss
III	Laceration	Distal transection or parenchymal injury involving ampulla
IV	Laceration	Proximal transection or parenchymal injury involving ampulla
V	Laceration	Massive disruption of pancreatic head

* – Advance one grade for multiple injuries up to Grade III

Diagnosis of pancreatic injuries

1. Increased level of serum and urinary amylase after blunt injuries is not diagnostic, but a persistent elevation suggests pancreatic injury.
2. Contrast duodenography may reveal widening of the 'C' loop.

3. Abdominal CT scans are currently reported as having a sensitivity and specificity in excess of 80% (Jeffrey RE et al, 1983)[19].
4. ERCP is the most useful investigation in pre operative delineation of ductal anatomy in patients with delayed presentation or missed injuries .

Treatment

Pancreatic injuries are divided into proximal & distal according to the location on the right and left of the superior mesenteric vessels, respectively.

1. Penetrating wounds to the right of the superior mesenteric vein should be treated with debridement and direct suture ligation of areas of bleeding.
2. Extensive injuries to the pancreatic head or to the right of superior mesenteric vessels are best treated by external drainage.
3. Severe trauma to the duodenum and head of pancreas may be treated with debridement of the pancreas, closure of the duodenal wound and pyloric exclusion with external drainage.

4. Most distal pancreatic injuries with suspected ductal injuries are treated by distal resection with or without splenectomy.

The most common complications after pancreatic trauma are pancreatic fistula and peripancreatic abscess.

SMALL BOWEL INJURIES

Injuries of small bowel are present in approximately 25 to 30% of the patients who require laparotomy after penetrating trauma (Cuschiere, Moosa et al) [1]. In most patients who sustain stab wounds, the small bowel is spared because the mobility of small bowel afforded by the redundant mesentery, allows the intestine to slide away from an offending knife blade[20].

EVALUATION AND DIAGNOSIS[31, 35]

Although history and physical examination are valuable in the diagnosis of small bowel injury following penetrating trauma, investigations may help.

1. Plain films of the abdomen may reveal free air
2. Any patient who has peritoneal signs or is hemodynamically unstable, proceeds promptly to exploratory laparotomy. In equivocal cases ***Diagnostic Peritoneal Lavage*** is employed. Indicators of hollow visceral injury include
    a. presence of bacteria, food fibers or bile and other criteria like
    b. amylase greater than 200 units/L,

c. WBC >500/mm^3 of fluid and

d. RBC>100,000/mm^3 of fluid.

Treatment

At laparotomy, a careful examination of the entire small bowel should be performed. Bleeding should be initially controlled and clamps or sutures should be applied to prevent further leakage of intestinal contents into the peritoneal cavity.

Small tears are closed primarily while extensive lacerations, devascularised segments or multiple lacerations in a short segment of bowel are better treated by resection and reanastomosis.

Complications include

1. Intra abdominal abscess,
2. Anastomotic leakage,
3. Entero cutaneous fistula and
4. Intestinal obstruction.

COLONIC INJURIES[25, 31, 35]

Colon injuries are usually the result of penetrating trauma. The colon is the second most frequently injured organ in gunshot injuries and the third most frequently injured organ in stab wounds to the abdomen. Morbidity rates after colonic injuries vary from 20% to 35% and mortality rates from 3% to 15%.

Treatment

General criteria for primary repair include

1. Early diagnosis (within 4 to 6 hrs)
2. Absence of prolonged shock or hypotension
3. Absence of gross contamination of the peritoneal cavity
4. Absence of associated colonic vascular injury
5. Less than 6 units of blood transfusion
6. No requirement for the use of mesh to permanently close the abdominal wall.

Stab and low velocity wounds to the colon with minimal contamination and hemodynamic stability can be managed by primary repair.

High risk colon injuries and those associated with severe injuries will benefit from resection and colostomy.

Post operative complications

1. Abscess formation
2. Anastomotic leak
3. Para stomal hernia
4. Morbidity and mortality associated with colostomy closure

RENAL INJURIES[32]

Penetrating trauma accounts for 84% of renal injuries. Stab wounds to the kidney are associated with a high incidence of non renal injuries. The overt mechanism of renal injury from penetrating trauma is the obvious tissue disruption to the parenchyma, collecting system and vasculature.

Diagnosis

History is very important. A high index of suspicion should be there- flank pain and hematuria warrant evaluation regardless of the apparent location of trauma. Ground glass densities in the flank suggest urinary extravasation or hematoma or pre existing mass such as hydronephrosis or tumor. Infusion pyelography identifies approximately 80% renal injuries.

Renal injury is suggested by the following radiological findings[31, 32]

a. Decreased excretion of contrast
b. Obliteration of psoas shadow or renal outline
c. Scoliosis away from the injury
d. Extravasation of the contrast.

A normal IVU with hematuria in a trauma patient suggests minor renal contusion and rules out major renal injury. Incomplete or poor visualisation of a portion of kidney suggests major renal trauma, including deep laceration, avulsion or vascular occlusion.

Non visualisation of a kidney on pyelography requires immediate arteriography whenever possible. CT is very useful investigation helpful in the non operative management.

Treatment[32]

Surgical exploration of all penetrating renal injuries is recommended because of the high incidence of associated intra abdominal injuries.

- Penetrating wounds causing small parenchymal injuries are generally treated with debridement, primary repair and drainage.
- More extensive wounds may require partial or even total nephrectomy.
- Injuries involving the hilum are seldom repaired primarily and in most circumstances a total nephrectomy is necessary.
- Renal vein laceration may be repaired by venorrhaphy. Renal arterial trauma may require a variety of repairs viz. lateral arteriorrhaphy, arterial resection and repair by primary reanastomosis or autologous vein repair.

URETERIC INJURIES[31, 32]

The following classification of ureteral injury helps in organizing the management of ureteral injury

1. Site: upper, middle and lower third
2. Time of recognition: immediate or delayed

3. Nature of injury: blunt trauma with laceration or avulsion, penetrating trauma
4. Presence of concomitant injuries

Injury to the ureter is uncommon and occurs mostly after penetrating trauma. The presence of hematuria in ureteral injury is an exception rather than the rule.

Diagnosis of ureteral injury

In the majority of cases, intra venous pyelography will confirm the diagnosis. In 15% to 20% of ureteral injuries a retrograde ureterography will be required to confirm the diagnosis. In hemodynamically unstable patients the diagnosis of ureteral injury may be made at the time of laparotomy by intravenously injecting 5ml of methylene blue. CT scan is more accurate in detecting the extravasation preoperatively.

Management[31, 32]

The principles of ureteral repair are

1. Adequate debridement,
2. Tension free repair,
3. Spatulated anastomosis,
4. Watertight closure,
5. Ureteral stenting and
6. Drainage.

Uretero pelvic junction disruption and major ureteral injuries (greater than 2cm laceration) are best treated by nephrostomy and stent after repair with fine chromic catgut sutures. Drainage should be provided.

Lower ureteral injuries usually require tunneled reimplantation into the bladder; if this is not possible then a flap should be turned cephalad for reconstruction (Boari and Ockerland's flap). When major ureteral loss is present or when it is necessary not to have any ureteral leakage post operatively, one may ligate the ureter and perform nephrostomy either at that time or per cutaneously within 24 hours, then later doing a transuretero – ureterostomy. Alternatively one may choose substitution of a segment of tapered or non tapered ileum for the ureter.

Nephrectomy may be the procedure of choice when there is simultaneous injury to the colon, ureter and iliac artery or aorta.

RETROPERITONEAL HEMATOMA[25, 31]

The exact incidence of retroperitoneal hematoma in patients who have suffered penetrating abdominal injuries is usually not recorded, as the hematomas are simply a manifestation of a major vascular injury.

In general, trauma surgeons recognize retroperitoneal hematoma in five locations viz.

1. Midline suprarenal.
2. Midline infra renal.
3. Lateral peri renal.
4. Lateral pelvic and
5. Portal.

Anemia and hematuria are constant findings in patients with retroperitoneal hematoma from pelvic fractures, while hematuria is much less common in patients with hematomas caused by penetrating wounds involving vascular structures. In contrast to

the management of retroperitoneal hematoma with blunt abdominal trauma, all five retroperitoneal hematomas previously listed are opened in patients with penetrating wounds. In each instance, proximal vascular control and if possible, distal vascular control should be done before entering the hematoma.

THORACIC INJURIES

Thoracic trauma forms about 10% of all trauma cases. Associated orthopedic injuries and head injuries are common. In most accidents, the patient is caught unawares. Medical relief is rarely available. Even if it is available, it may not be any more than just first aid. Also the centre where the patient is first taken is usually not equipped to handle profuse bleeding, respiratory failure etc.

Chest trauma patients are likely to deteriorate due to the effects on respiratory function with secondary associated cardiac dysfunction. The aim of treatment in chest trauma cases is restoration of cardio respiratory function to normal, control of bleeding and prevention of sepsis. This statement is simple but requires several steps to be taken. Unfortunately deaths are due, in

many cases, to airway obstruction and disturbances in physiology due to hemothorax, pneumothorax with or without flail chest.

About 15% of patients need surgical intervention, whereas measures to relieve hemo pneumothorax offer life saving benefits. Recognition of the need for ventilatory support in such patients is delayed in the receiving centres where it is vitally required. A tube thoracostomy and Ambu bag breathing kit may save many patients.

Management

Management of chest injury begins at the site of injury. Breath sounds when diminished or absent, denote lung injury, pneumothorax or hemothorax. Bowel sounds, if heard, generally exclude intestinal injury. Bruises over left upper part of abdomen, if present, denotes splenic injury. For central nervous system the site of injury, bleeding from ears, unequal pupils, inability to move limbs, consciousness etc. must be examined. The spine should be checked for injury. If the abdomen is distended, a Ryle's tubeis inserted. X-ray chest should be taken to check for fractured ribs, hemothorax or pneumothorax. Intravenous fluid therapy must be started.

In case of pneumo or hemothorax, it is life saving to insert an intercostal drainage tube. It can be done using a tube of any size,

connected to any bottle with an under water seal. One can use an IV set also. One can measure blood loss, at hourly intervals and replace the same with appropriate blood transfusion. If blood loss is large, it should be measured every half hour and the amount drained provides information for further steps to be taken. Surgical intervention is indicated to control bleeding if the patient is having persistent haemoptysis leading to flooding of lungs.

FLAIL CHEST:

Flail chest is usually evident if there is:

1. Fracture of 4 or more ribs anteriorly and posteriorly
2. Bilateral anterior rib fractures
3. Sternal and rib fractures
4. Fracture of 7 to 8 ribs antero laterally
5. Costochondral fracture of 4-5 ribs

The effects of flail chest can be immediate or delayed like

1. Paradoxical movement
2. Hypotension
3. Retained secretions
4. Atelectasis
5. Mediastinal flutter

Flail chest management should include

1. Strapping/sand bag support,
2. External fixation with towel clips/ pulley and traction,
3. Internal fixation with wires/plates &
4. Positive pressure ventilation

General measures in all forms of chest injuries include:

1. Analgesics and antibiotics
2. Oxygen by mask; if patient is hypoxic, manual ventilation must be considered
3. **Appropriate intercostal drainage tubes**
4. Arterial blood gas measurements
5. Intercostal block/ epidural block
6. **Chest physiotherapy**
7. Repeated bronchoscopic suction
8. Mini tracheostomy

Indications for ventilatory support are:

1. Tachypnoea
2. Shock
3. Cyanosis
4. $PaO_2 < 60mm\ Hg$
5. $PaCO_2 > 50mm\ Hg$

Ventilatory support is indicated in patients with Lung contusion, Hemo or pneumothorax, Flail chest with falling blood pressure, increasing pulse rate, low PO2 and rising PCO2. Manual ventilation is sometimes beneficial in such patients.

Morbidity and mortality depend on:

(1) Severity of the chest injury

(2) Condition of the underlying lung

(3) Associated head injury

(4) Associated abdominal injury

(5) Long bone fracture/fat embolism.

Mortality rate varies from 20-80%, mostly as a result of associated injuries.

Complications of prolonged ventilation include:

1. Infection/bed sores/deep vein thrombosis
2. Baro trauma/persistent pneumothorax
3. Thoracic trauma
4. Ventilator dependency
5. Tracheostomy
6. Tracheal stenosis

If chest injury is the only injury present – one must look for

(1) Cardiac tamponade,

(2) Injury to great vessels and

(3) Injury to bronchi and esophagus

Cardiac Tamponade

It is more common in penetrating injury. **Beck's triad** (low BP, increasing JVP, muffled heart sounds) is noticed in <30% of cases. X-ray chest may show enlarged cardiac shadow. Clinical suspicion, Echocardiography and pericardiocentesis are useful.

Surgery:

Surgical intervention/exploration is required if the penetrating injury is close to the heart, great vessels, with persistent bleeding and suspicion of cardiac tamponade. Median sternotomy and left Anterolateral Thoracotomy are the preferred approaches. Delayed surgical intervention is required for removing clotted blood from pleural cavity or clotted hemothorax and empyema. Usually (in about 70% of patients) conservative management is sufficient to save life.

Chest trauma, though a major entity, can be managed, if altered physiology consequent to the injury is understood. As in all trauma cases, interval from time of injury to reaching medical aid is vital. Oxygen supply to the lung and inter costal drainage are of vital importance. Comprehensive examination of injured person for physical status and associated organ injuries is vital. Stabilization of chest wall is essential.

AIM OF THE STUDY

a. To find out the ***pattern of surgical injuries*** in victims of bull gore injuries

b. To analyze the ***characteristics of the injured population*** with regard to

1. Age
2. Sex
3. Duration of Stay
4. Nature of the injured
5. Organs Injured
6. Type of injury
7. Management

c. To assess the ***in hospital outcome*** of these injuries

d. To assess the ***mortality & morbidity***

MATERIALS AND METHODS

This study was conducted in the Govt. Rajaji Hospital from December 2005 to June 2006 and included all cases of bull gore injuries admitted to the trauma ward of our hospital during the above time period.

On admission, the case history viz. name, age, sex and mode of injury were elicited. The patient was then subjected to appropriate investigations. Hemoglobin estimation, urinalysis, blood grouping & typing and hematocrit measurement were done. Renal parameters like blood urea and serum creatinine were measured. Appropriate radiographs were taken and USG, CT or MRI were done later as dictated by the need of the particular case.

The patients were grouped with regard to their injuries which were classified as 1 - Skin & soft tissue injuries, 2- chest injuries, 3 - abdominal injuries, 4 – Orthopedic injuries and 5 – others with the injury coding being assigned to each case.

Soft tissue abrasions were cleaned and dressing applied, while lacerations were thoroughly washed and then primarily closed by vertical mattress sutures in most areas except in face where simple sutures were used. Contusions were managed expectantly while

hematomas were aspirated. Extensive lacerations were allowed to granulate and later grafted.

Patients with thoracic injuries had a radiograph of the chest PA view after a good clinical examination.

Criteria for ICD Insertion:

1. Hemothorax
2. Pneumothorax
3. Flail Chest
4. Multiple rib fractures

Cases with isolated rib fractures without any evidence of pleural breach and blunt injuries to the chest were managed expectantly with analgesics & observed without ICD insertion.

ICD removal was done after complete re expansion as monitored by serial radiographs. If the need arose CT chest was done to drain loculated collections.

All patients with an injury coding 3 i.e. abdominal injuries were evaluated with plain XRays of the chest and abdomen and USG & CT if required.

Indications for laparotomy:

1. Abdominal guarding, rigidity & other signs of peritonitis,
2. Hemodynamic instability,

3. Bowel evisceration,
4. Peritoneal breach,
5. Pneumoperitoneum,
6. Moderate or large fluid collection on USG,
7. Solid organ injuries suspected or proved by imaging.

Wounds that did not involve a peritoneal breach were suture closed after exploration under local anesthesia and observed and if any of the above signs appeared then laparotomy was done.

During laparotomy, small bowel lacerations were closed primarily, with resection being reserved for cases that had multiple lacerations in short segments or where there was vascular compromise. Colonic injuries were closed primarily unless there was gross contamination of peritoneal cavity or vascular compromise. Liver lacerations were approximated by mattress sutures using absorbable suture materials with/ without an omental patch. In cases of evisceration of bowel without any other organ injury, the prolapsed bowel was washed and after a thorough laparotomy the same was returned to the abdomen. Retroperitoneal hematomas were left alone during surgery unless they were expanding.

Among orthopedic injuries, closed undisplaced fractures were managed by POP application. External fixation was done if they were communited or of the open type. Fractures of the femur were treated with pin traction initially and a definitive procedure was done at a later date. Clavicle fractures were managed with figure of eight bandage application while pelvic fractures were managed expectantly. Spine stabilization was done for all cases suspected of having spinal injuries.

The operative findings were recorded and the patient was followed up till his discharge from the hospital. The occurrence and type of complications was duly noted. In case of death the post mortem findings were obtained. The above were recorded in the pro forma prepared for this study. The data that was gathered in this fashion was then analyzed with regard to various parameters and the results were thereby obtained.

OBSERVATION & RESULTS

A total of 105 patients were admitted with injuries sustained directly or indirectly as a result of bull gore in the Govt. Rajaji Hospital, Madurai during the period of study. The data was analyzed with regard to various parameters viz. age & sex distribution, type of injury, organs injured, duration of stay, management and outcome.

AGE DISTRIBUTION

The analysis revealed that most of the injured were in the productive age group with 41% of persons being in their twenties. Among the rest 17% were in their teens and 16% in their thirties with about 26% beyond forty years of age.

SEX DISTRIBUTION

Not surprisingly there was a predominance of males among those injured with females accounting for only about 6% of cases. This is primarily because bull gore injuries occurred in the course of bull taming festivals and only males participate in this event.

Sex	Distribution	Percentage
Male	99	*94*
Female	6	*6*

NATURE OF INJURED

The data showed that about 59% of the studied population were directly involved in the bull fighting event and thereby got injured while the rest were either spectators or they were injured in isolated instances in the course of their agrarian pursuits.

Nature of Injured	Numbers	Percentage
Participant	61	***59***
Spectator	44	***41***

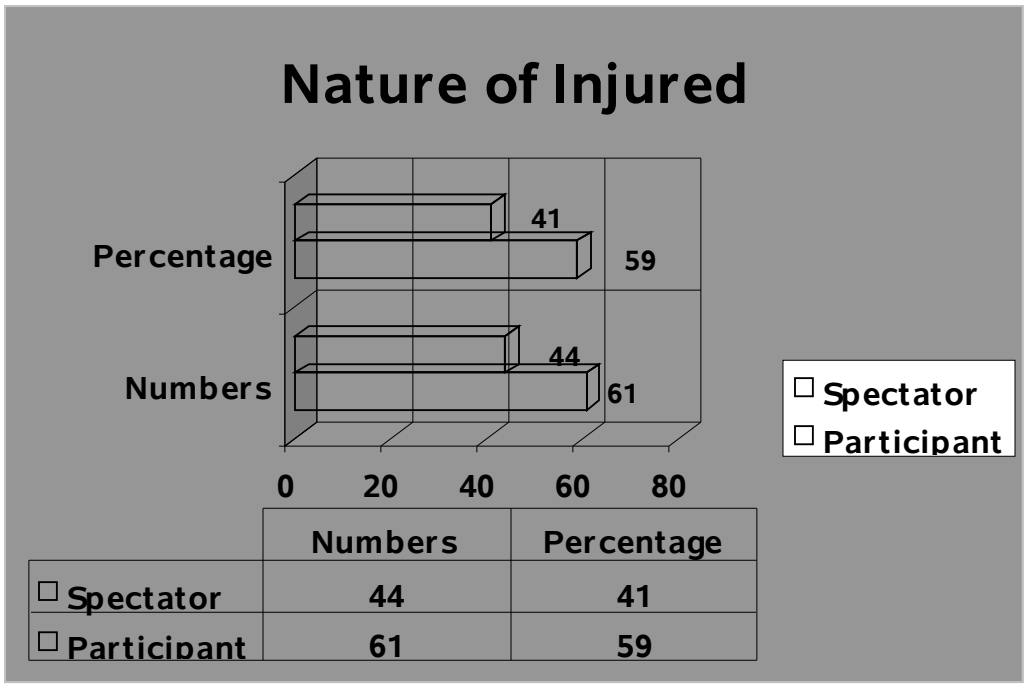

TYPE OF INJURY & INJURY CODING

The patients were studied with regard to their injuries which were grouped as **1 – Skin & soft tissue injuries, 2– chest injuries, 3 – abdominal injuries, 4 – Orthopedic injuries and 5 – Other Injuries,** with injury coding being as mentioned above. Skin & soft tissue injuries were the commonest accounting for 35% of cases, with thoracic injuries accounting for 22% of cases. Abdominal and orthopedic injuries accounted for about 15% each. Though soft tissue injuries were the main cause of admissions they were the least morbid of the injuries.

Type of Injury	Numbers	Percentage
Soft Tissue	**37**	***35***
Chest	23	***22***
Abdomen	16	***15***
Orthopedics	13	***13***
Others	16	***15***

Among the abdominal injuries large bowel injuries constituted 31% with three ascending colon injuries, one transverse colon injury and one in the sigmoid. There were two small bowel injuries (one in the ileum and the other in the jejunum). There were four cases of parietal wall injury with all organs and viscera being normal. There was one liver injury and in four cases, the mesentery or omentum was involved.

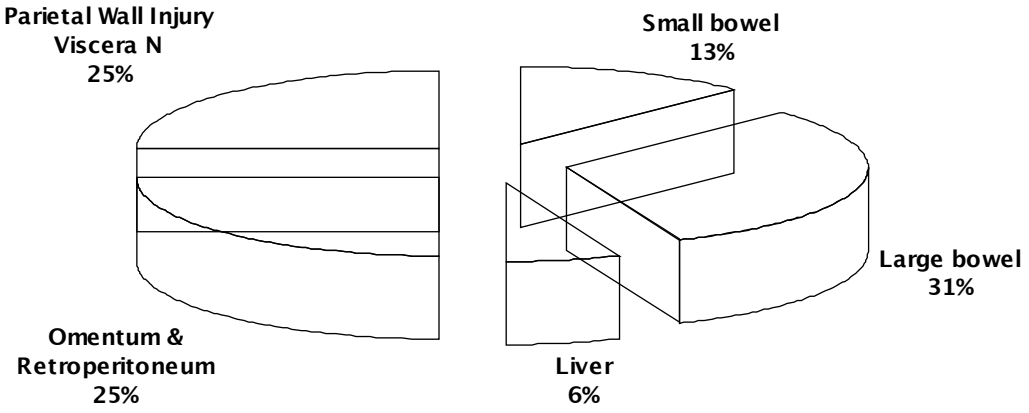

The thoracic injuries were primarily in the form of rib fractures with hemo/ pneumothorax. Out of the 23 chest injuries,

11 cases needed an ICD for their management while the rest were blunt injuries that were expectantly managed.

Fractures involving the femur accounted for 4 cases of orthopedic injuries, those of the legs for 3 cases while the upper limb, the spine and the pubic rami were fractured each in one case.

Among the other injuries there were six cases that needed plastic surgical suturing, two scrotal lacerations, two dental and two vascular injuries.

DURATION OF STAY

Of the 105 admitted patients, 69 (66%) were discharged within a week, 17 (16%) people within two weeks while 19 (18%) had a hospital stay beyond 14 days. Of these not surprisingly five people with bowel injuries and six with orthopedic injuries had a stay of 3 weeks or beyond, while those with ICD tubes had to be inpatients beyond 1 week while their lungs recovered enough for the removal of the drainage tubes. One case underwent an SSG for a huge raw area and stayed for 30 days as an inpatient.

Weeks of Stay	Numbers	Percentage
<= 1 week	**69**	**66**
1-2 weeks	17	16
2-3 weeks	7	7
3-4 weeks	3	3
> 4 weeks	9	8

MANAGEMENT

Among those admitted 61 cases (57%) were managed expectantly, with suturing, antibiotics and analgesics being the only therapy needed. There were two scrotal lacerations that were repaired primarily. Among the thoracic injuries 11 cases (50%) needed an ICD as part of their management while the others were either blunt injury chest wall or simple lacerations with no abnormality in the X ray.

There were two small bowel perforations, two ascending colon perforations, one transverse colon perforation and one caecal tear all of which were repaired primarily with no need of a protecting colostomy. In one case there was a sigmoid tear which was suture closed and the bowel exteriorized and returned to the abdomen at a

later date. An inguinal laceration was explored, herniorrhaphy done and then closed. Four abdominal wall lacerations were suture closed and observed with good results, as there were no signs of peritoneal breach. There were three cases of bowel and omental prolapse that were explored and reduced, with other organs being normal. One case had a non expanding retroperitoneal hematoma and there was one liver laceration which was sutured primarily with an omental patch. Gastric wall laceration with prolapse occurred in one case that was sutured primarily.

Among the orthopedic injuries, three clavicle fractures were treated with a figure of eight bandage, while those of the leg were managed by POP application, with one communited fracture needing external fixation for management. Three cases of fracture of vertebra succumbed to their injuries while 4 cases of femur fracture were treated initially with upper tibial pin traction and later on by intra medullary nailing for fractures of the shaft or by DHS for trochanteric fractures. Upper limb factures in the form of both bone fractures of the forearm were managed by POP application. There was a single case of pubic ramus fracture which was managed conservatively. SSG was done in one case with a pure soft tissue injury.

There was one basilic vein repair and one case of popliteal artery transection which was grafted with native saphenous vein and femoro popliteal bypass was done. Dental extraction was needed in three cases because of fractured teeth and plastic eyelid suturing was needed in one case. Hemarthrosis aspiration was done in one case and a tracheostomy was needed for one case where there was laceration in the neck with exposed thyroid cartilage and an air sucking wound.

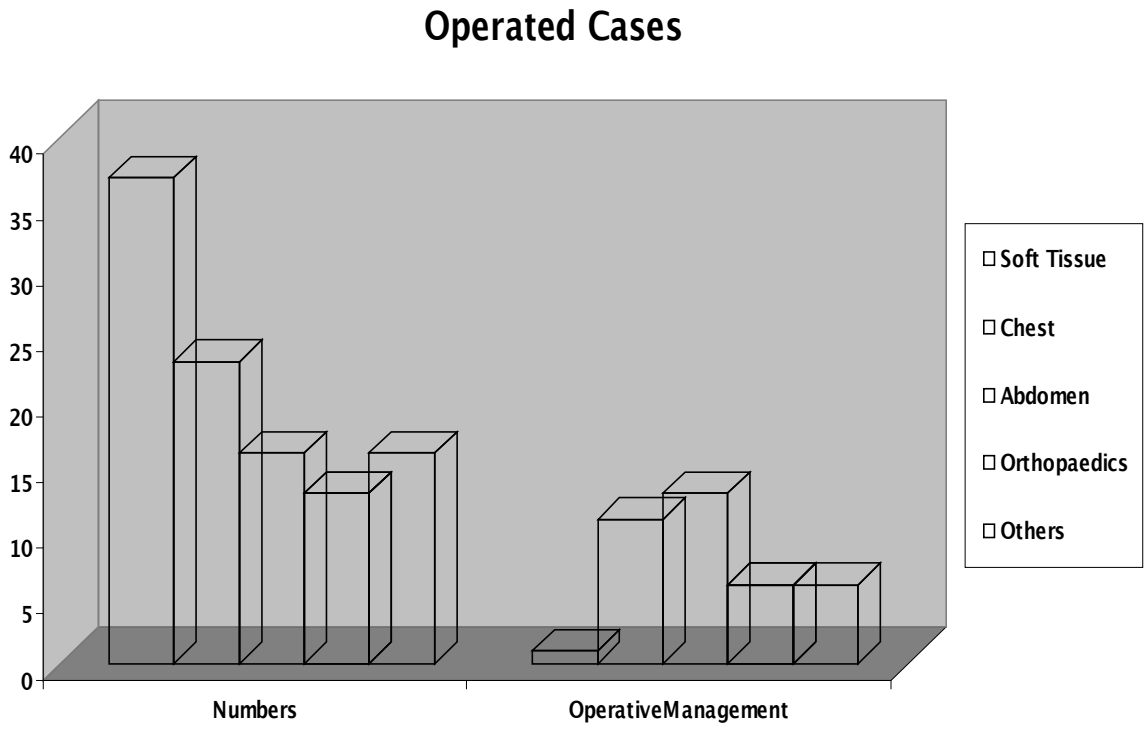

COMPLICATIONS

There were few complications associated with the operated cases, taking the form of surgical site infections (SSI) in five patients with abdominal injuries that were managed conservatively and four SSI in the orthopedic group, again managed conservatively. Only one soft tissue injury case had secondary suturing for a wound infection. Generalized sepsis occurred in one case with an ascending colon perforation who succumbed to the same. In the eleven cases needing an ICD, two later had infection of the tract that needed debridement and antibiotics for treatment.

Among the other injuries, the patient with vascular repair of the popliteal artery and the one that underwent a cubital fossa exploration had post op edema that responded to limb elevation and anti inflammatory drugs, while the case where an inguinal exploration with herniorrhaphy had a sinus from the prolene material that was later removed. All other cases had uneventful recovery and were discharged in due course.

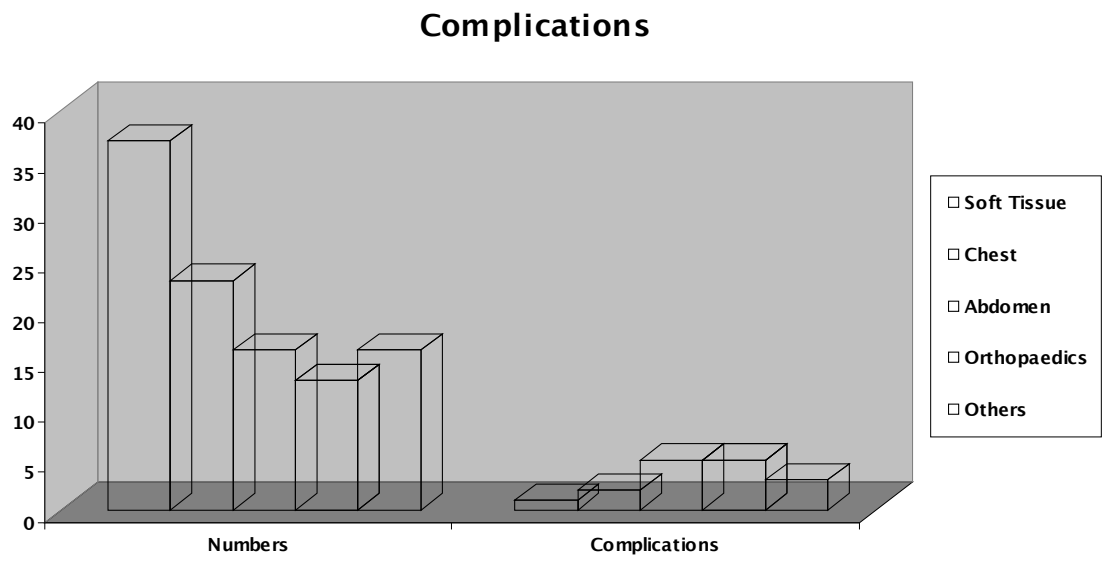

MORTALITY & MORBIDITY

There were six deaths in the study group, three of which were due to injuries to the spine as a result of indirect violence secondary to falls sustained during the event, one death in a case of ascending colon perforation secondary to sepsis and two deaths due to thoracic trauma. All other cases were discharged after the requisite treatment was provided.

Though the mortality was low, the morbidity was high in cases with abdominal, thoracic and orthopedic injuries with long duration of stay and loss of quality of life during the period when they were bed ridden.

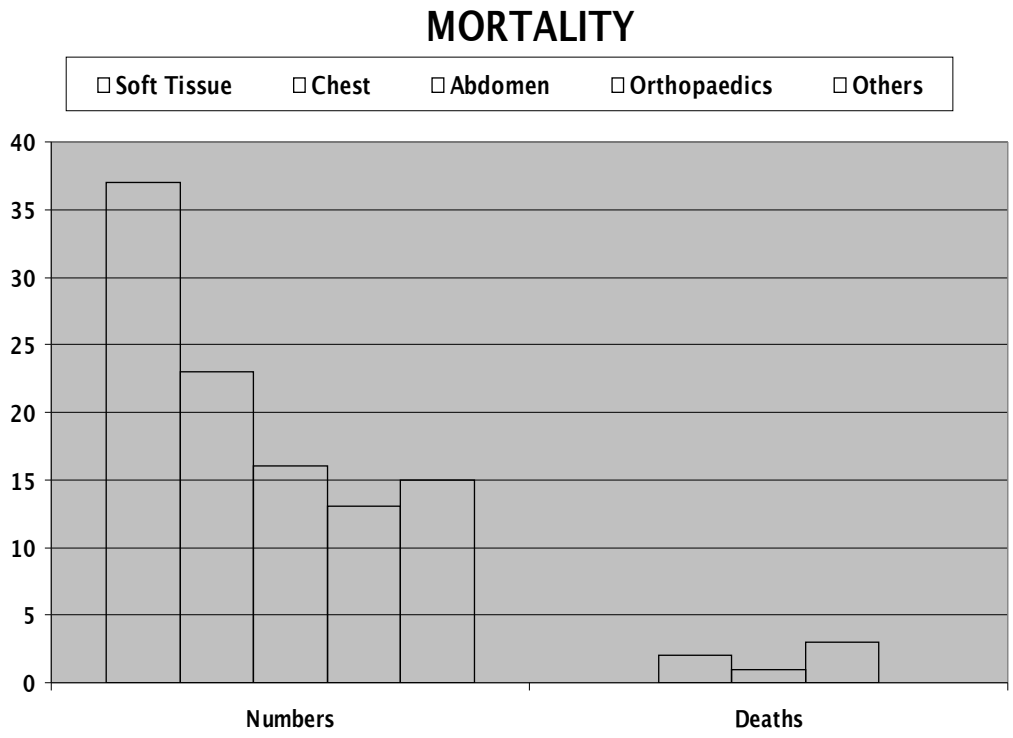

Temporal clustering

Seventy four cases occurred during the month of January (70%) with a few scattered cases occurring in December (9%) and February (14%). This was not surprising, considering the fact that the main cause of bull gore injuries was the bull fighting event that is held during the harvest season in the month of January with a few scattered events in February and December. The other months witnessed the occurrence of sporadic cases due to the odd injuries sustained during farming and agricultural activities as a result of contact with domesticated cattle.

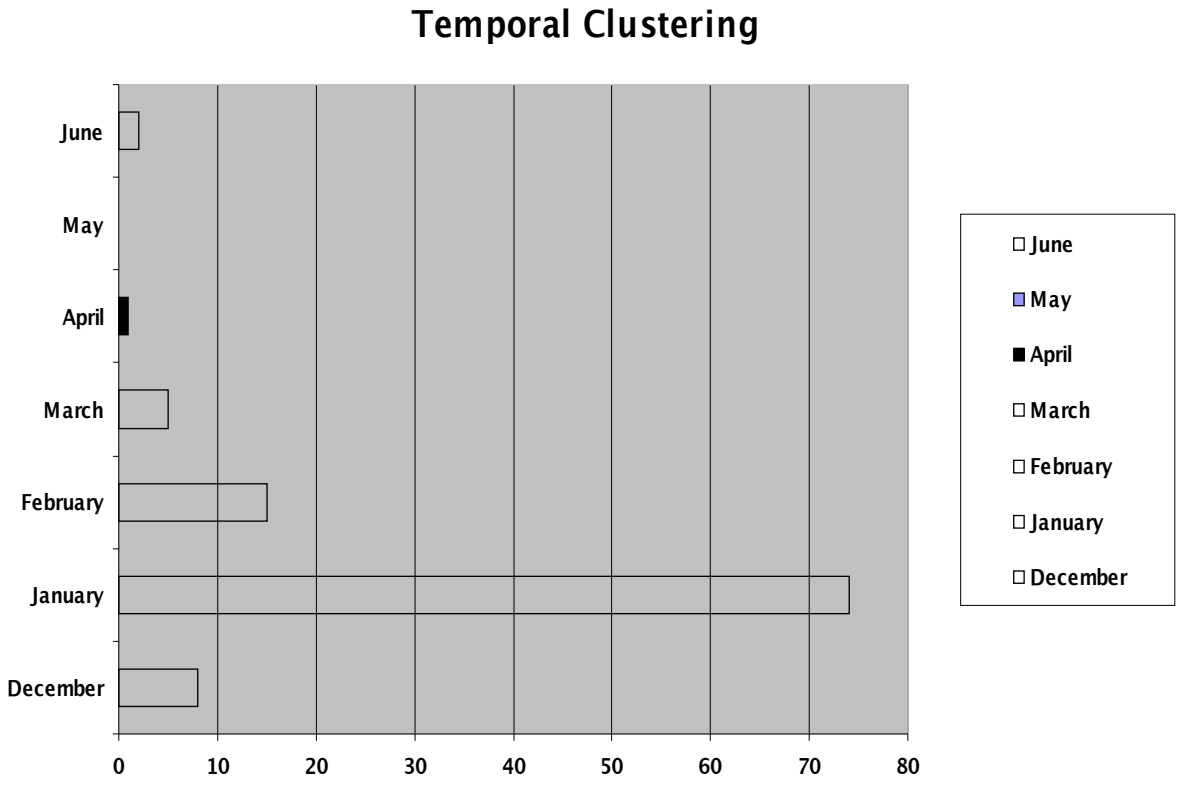
Temporal Clustering
June
May
April
March
February
January
December
0
10
20
30
40
50
60
70
80
June
May
April
March
February
January
December

CONCLUSION

- Males outnumbered females in the number of people injured by a ratio of about 16:1
- Participants were more likely to be injured than spectators/ other types, by a ratio of about 3:2
- Soft tissue injuries were the commonest type accounting for 35% of cases
- The people in their twenties and thirties formed more than 50% of the affected population
- The mortality due to bull gore injuries was about 6% in this study
- People with orthopedic and abdominal injuries were the ones with hospital stay period $\geq$ 3 weeks
- Spine fractures leading to shock was the commonest cause of death (50% of cases)
- Most of the cases(70%) showed a clustering during the month of January
- An operative management was needed in 37 cases(35%) while the rest of the cases were managed expectantly

BIBLIOGRAPHY

1. Sir Alfred Cuschieri's – Essential surgical practice – 4th edition
2. Berne CJ, Donovan AJ, White EJ et al: Duodenal "diverticulization" for duodenal and pancreatic injury. Am.J.surg 127:503-507, 1974.
3. Blaisdell FW, Trunkey DD Trauma Management, Volume 1 Abdominal trauma. New York, Thieme – Stratton, 1982.
4. Butain WL, Lynn HB; Splenorrhaphy, Changing concepts for traumatized spleen: Surg 86: 148 1979
5. Carlton CE: Jr. Injuries of the kidney and ureter. In Harrison, JH et al (Eds): Campbell's Urology. Vol I 5th Edition.
6. Coghill TH, Moore EE, Jurkovich GJ et al, severe hepatic injuries J.Trauma 28 et al, 1988
7. Corton CE, Scot RJ, Guthirie AG. The initial management of Ureteral injuries.
8. David Richardson, Franklin GA, Lukan JK, et al, Evolution in the management of hepatic Trauma, Ann Surg 232, 2000.
9. Demetriade SD, Murray JA, Chant et al. Penetrating colon injuries requiring resection. J.Trauma 50, 2001.

10. Flint LM, McCoy M, Richardson JD et al: Duodenal injury: Analysis of common misconceptions in diagnosis and treatment Ann Surg 191(6): 697-702, 1980.
11. Feliciano DV: Patterns of injury, Mattox KL, Moore EE, Feliciano DV: Trauma, I edt. Norwalk, CT Appleton & Lange, 1988.
12. George SM, Fabian TC, Voeller GR et al, Primary repair of colon wounds Ann Surg 209 1989.
13. Graham JM, Mattox KJ, Jordon GL: Traumatic injuries of the pancreas. Am J Surg: 136(12): 744-749, 1978.
14. Grieco J Perry J - Retroperitoneal hematoma following trauma. J Trauma 20: 733, 1979.
15. Hol Croft JW, Trunkey DD et al: Renal trauma and retroperitoneal hematoma - indications for exploration J trauma 15:1045 1975.
16. Ivatuary RR, Nallathambi M, Gaudino J et al Penetrating duodenal injuries: Analysis of 100 consecutive cases. Ann Surg 202(2): 153-158, 1985.
17. Ivatuary RR, Cayton CG, Textbook of penetrating trauma 1996.
18. Jones RC: Management of Pancreatic trauma: Ann Surg 187 (5) 555-564, 1978.
19. Jeffrey RE, Federle MD, Craess RA. Computed tomography of pancreatic trauma, Radiology 147(5): 491-494, 1983.

20. Jurkovich GJ, Surgical clinics of North America Vol 70; No.3, June 1990.

21. Kelly G, Norton L, Moore G et al: The continuing challenge of duodenal injuries J. Trauma 18(3) 160-165, 1978.

22. King H, Shumacker HB: Splenic studies, Ann surgery136-239, 1952.

23. Last RJ. Anatomy 10th edition.

24. Levison MA, Peterson SR, Sheldon GF et al: Duodenal trauma experience of a trauma center. J. Trauma 24(6): 475-480, 1984.

25. Maingot. R. in Maingot's Abdominal operations 10th edition.

26. Mcaninch JW, Carrol PR: Renal trauma. Kidney preservation through improved vascular control-A refined approach. J. Trauma. 22:285, 1982.

27. Moore EE, Shacford SR, Pachter HL, et al: Organ injury scaling: spleen, liver and kidney J. Trauma 29: 1664, 1989.

28. Ochsner JL, Crawford ES, Debakey ME: Injuries of the vena cava caused by external trauma. Surgery 49:397-405, 1961.

29. Oxford's Text book of surgery – 2nd Edition

30. Patel J, Williams JS, Shmigel B et al, Preservation of splenic functions by auto transplantation of spleen in man. Surg 90:683, 1981.

31. Sabiston's Text book of surgery – 17th edition.

32. Sagalowsky I, and Paul C. Peters. Genito urinary trauma. Campbell's urology 8th Edition

33. Schwartz's – Principles of surgery – Eighth edition.

34. Shannon FL, Moore EE, Primary Colon repair – a sage alternative, surgery, 1985.

35. Snder WH III et al: The Surgical Management of duodenal trauma, Arch Surg: 115:422-429, 1980.

36. Steichen FM, Dargan EL et al: The management of retroperitoneal hematoma secondary to penetrating injuries Surg gynecol obstet 123:581 1966.

37. The New Aird's companion in surgical studies – 3rd edition.

38. Touloukiann R. Splenic preservation in children World. J Surg 9:214:1985.

39. Vaughu Gg, Frazier OH, Graham D, et al the use of pyloric Exclusion at the management of severe duodenal injuries AM J.Surgery 134,1977.

40. Weigelt AJ. Duodenal Injuries. SCNA. Vol.70 No.3, 1990.

41. Whitney RF, Peterson NE – Penetrating renal injuries.

42. An unusual case of bull gore injury with orbital injury; Aust N Z J Ophthalmol. 1986 Nov; 14(4):377-9. Singh RI, Thomas R, Alexander TA.

43. A detailed examination of injuries to the head and neck caused by bullfighting, and of their surgical treatment; the role of the cervico-facial surgeon; Rev Laryngol Otol Rhinol (Bord). 2003; 124(4):221-8, Chambres O; Giraud C; Gouffrant JM; Debry C Hôpital de Hautepierre, Service d'Oto-rhino-lnryngologie et de Chirurgie Cervico-faciale, Strasbourg, France

44. Intercosto diaphragmatic hernia secondary to a bull gore injury: a delayed detection; Indian J Chest Dis Allied Sci. 2002 Jul-Sep;44(3):187-9. Nabi G, Seenu V, Misra MC.,Department of Surgical Disciplines, All India Institute of Medical Sciences, Delhi

45. Mechanisms of head injury in bull riders with and without the Bull Tough helmet--a case series; J Okla State Med Assoc. 2005; 98(12):591-5 (ISSN: 0030-1876) Brandenburg MA; Archer P,Trauma Emergency Center, St. Francis Hospital, Tulsa, USA.

46. Urethrorectal fistula by bull horn injury; J Indian Med Assoc. 2002; 100(1):47 (ISSN: 0019-5847) Pal DK; Bora V; Bisoi SC; Dwivedi US; Division of Urology, Institute of Medical Sciences, Banaras Hindu University, Varanasi

PRO FORMA

1. Name **2. *Age*** **3. *Sex***

4. I.P. Number **5. Address**

6. Date of Admission **7. Date of Discharge** **8. *Days of Stay***

9. *Participant/ Spectator*

10. Condition on Admission

- **i. Pulse**
- **ii. BP**
- **iii. RR**
- **iv. GCS**

11. List of Injuries **12. *Organs Involved*** **13. *Injury Code***

14. *Operative/ Conservative Management* **15. *Management***

16. Per operative findings

17. *Complications* **18. *Outcome***

19. Cause of Death

20. Post mortem findings