Application of Smartphone photography and 3G Wireless Internet Technology in Free Flap Monitoring: a Prospective Study

A dissertation submitted to the M.G.R. Medical University, Tamil Nadu: in partial fulfillment of the requirement for the M.S. Branch I (General Surgery) examination held in April 2015.

Certificate

This is to certify that the dissertation entitled "Application of Smartphone photography and 3G Wireless Internet Technology in Free Flap Monitoring: A Prospective Study" is a bonafide work done by Dr. Akhila.S, postgraduate resident in Masters of General Surgery 2012-2015 at the Christian Medical College, Vellore, towards partial fulfillment for the MS General Surgery Branch I final examination held in April 2015.

Signature:

Guide:	**Head of the Department:**	**Principal:**
Dr. Pranay Gaikwad	Dr. Benjamin Perakath,	Dr. Alfred Job Daniel,
Professor,	Professor,	Professor,
Dept. of Surgery Unit I,	Dept. of Surgery Unit II,	Dept. of Orthopedics
Christian Medical College	Christian Medical College	Christian Medical
Vellore-632004	Vellore- 632004	College,
		Vellore-632004

Turnitin

https://turnitin.com/s_class_portfolio.asp?r=93.8533659247184&svr=3&lang=en_us&aid=80345&cid=8539677

221211452.ms General Surgery AKHILA S | User Info | Messages | Student | English | Help | Logout

turnitin

Class Portfolio | Peer Review | My Grades | Discussion | Calendar

NOW VIEWING: HOME > THE TAMIL NADU DR.M.G.R.MEDICAL UTY 2014-15 EXAMINATIONS

Welcome to your new class homepage! From the class homepage you can see all your assignments for your class, view additional assignment information, submit your work, and access feedback for your papers.

Hover on any item in the class homepage for more information.

Class Homepage

This is your class homepage. To submit to an assignment click on the "Submit" button to the right of the assignment name. If the Submit button is grayed out, no submissions can be made to the assignment. If resubmissions are allowed the submit button will read "Resubmit" after you make your first submission to the assignment. To view the paper you have submitted, click the "View" button. Once the assignment's post date has passed, you will also be able to view the feedback left on your paper by clicking the "View" button.

Assignment Inbox: The Tamil Nadu Dr.M.G.R.Medical Uty 2014-15 Examinations

	Info	Dates	Similarity	
TNMGRMU EXAMINATIONS	ⓘ	Start 01-Sep-2014 11:27AM Due 15-Aug-2015 11:59PM Post 15-Aug-2015 12:00AM	20%	Resubmit View

6:17 PM
10/10/2014

ACKNOWLEDGEMENT

This study would not have been completed without the help of many people. First and foremost is my Guru and Guide Dr.Pranay Gaikwad, he is the Mastermind behind this work.

Dr. Rajinikanth J and Dr. Amit Jiwan Tirkey who have helped make this work meaningful.

My inspiration of life, my father, late Mr.Sridhara Murthy A.V. who is solely responsible for what I am.

I would like to thank my mother Mrs.Poornima Murthy and family and friends for being with me whenever I needed them.

My special thanks to Dr. Cecil Thomas, who helped me, starting from patient recruitment till data analysis.

Am grateful to Dr. Mark Ranjan, my mentor, who has supported me all through and made me stronger. Thank you Sir.

Special acknowledgement to M/s Siemens Technology Services Pvt. Limited, Bangalore who sponsored and helped us start and persue this project.

Acknowledgements to all my friends who helped me in data collection and analysis, Aditya, Irwin, Srujan, Rahul, Sohet, Ajit, Anila, Niveditha and Nandu. Thank you so much.

Thanks to my batch mates Abhilash, Joshua, Zeeshan, Augustin, Sumit, Suraj and Jyothsna, who have supported me always.

My special thanks to Dr. Suhas Bajgur, my best friend who helped me starting from attending my PG entrance exams to Literature review of this study, till date and taken care of me and my dissertation.

Acknowledgements to our Secretary Mrs. Manjula K.V and Mr. Kantha Rao, and all our P2 ward nursing staff, who have been of great help.

Thanks to my statistician Dr. Antonysami, Mrs. Gowri and Mr.Janakiraman for their guidance.

Above all is God Almighty without whom nothing is possible.

TABLE OF CONTENTS

ABSTRACT

Title of the abstract: Application of Smartphone photography and 3G Wireless Internet Technology in Free Flap Monitoring: A Prospective Study

Department: General Surgery, Unit I, CMC, Vellore

Name of the candidate: Dr. Akhila.S

Degree and Subject: M.S. General Surgery

Name of the guide: Dr.Pranay Gaikwad

Aims:

1. To study the role of Smartphone photography and 3G wireless technology for monitoring free flap.

Objectives:

1. To study the feasibility of Smartphone photography in free flap monitoring.
2. To study the feasibility of Smartphone photography and 3G wireless internet technology in monitoring free flaps.

Materials and methods:

The feasibility of using Smartphone technology and 3G wireless internet technology as an adjunct in free flap monitoring in patients with oral cavity malignancy who have undergone microvascular free flap reconstruction with a visible skin paddle for post excisional defects was studied . A prospective study was conducted from November 2012 to September 2014. A standardized color card was used for the assessment of photographs. The principal investigator (P.I) was involved in taking photographs every six hours and send it to three surgeons using 3G wireless internet technology. The three surgeons: the Operating Surgeon(OPS), who was monitoring the free flaps using clinical data and photograph of the flap; the Observing Surgeon1(ObS1), who monitored using photographs only; and the Observing Surgeon 2(ObS2), who monitored using only the clinical data of the free flap.

Inter-observer variability and accuracy rate of each observer in the assessment of the free flap status was used for analysis. The decision on re-exploration of the free flap was made by the operating surgeon although the input from the other two surgeons (ObS1 &ObS2) was provided to the OPS if the free flap viability was questionable.

Results:

A total of 18 cases were analyzed from January 2013 to September 2014, with 100% free flap survival rate. Five patients were re-explored and salvaged completely. The indication for operation was neck hematoma in 4 patients and venous thrombosis in 1 patient. In the last patient, venous congestion was identified by photograph and later on clinical grounds. The accuracy rate with the use of photographs was 100%.

Conclusion:

In this study, the Smartphone photography with 3G internet technology prove to be a useful adjunct in free flap monitoring with a success rate of 100%. There was no free flap failure during the study period. The technique was useful in identifying a potential venous thrombosis which helped in decision tore explore and revise the microvascular anastomosis. The incorporation this technique in the current protocols of free flap monitoring may help identify impending flap failures even before the assessment by the senior team member.

INTRODUCTION

Oral cavity malignancy is one of the most common malignancies in India(1). Head and neck malignancy is one of the leading causes of death in India(2). There has been an increase in the number of younger population including females affected by oral malignancy(3)(4). There are multiple risk factors and premalignant lesions for oral malignancies. Most common histology is squamous cell carcinoma. There has been a change in the profile of personal habits with excessive use of tobacco in all forms-cigarette smoking, chewing tobacco in the form of gutkha, khaini, paan or other forms of smokeless tobacco. All these are proven risk factors for oral malignancy(5).

RISK FACTORS: Tobacco in any form, especially chewing tobacco in any form, smoking, alcohol consumption, sharp tooth and Human Papilloma Virus (HPV) infection are the risk factors for oral cavity malignancies(6).

PREMALIGNANT LESIONS: Leukoplakia, Erythroplakia, Submucous fibrosis, Oral candidiasis are some of the premalignant conditions. HPV infection causes dysplasia, which later on leads to metaplasia. Oral Lichen planus has also been associated with higher incidence of transformation into malignancy.

PATHOGENESIS: The pathogenesis of oral cavity malignancy starts with dysplasia following a primary insult with the use of tobacco, which later on leads to de differentiation, and finally leading to malignant transformation. Dysplastic lesions on long follow up in the continuous presence of risk factors, lead to malignant transformation. These are squamous cell carcinoma and the mode of metastasis is mostly lymphatic to the regional lymph nodes and then pericapsular and hematogenous. The extent of metastasis determines the severity and further management.

CLINICAL PRESENTATION: Patients commonly present with an ulcer or a proliferative growth in the oral cavity. They may have bleeding from the ulcer, halitosis. Carcinoma of the alveolus presents with loose tooth and would have noticed after dental extraction. They have difficulty in speech and swallowing. They may present with associated regional lymphadenopathy. On examination they may have trismus with an ulcer with surrounding indurated margins, with fixity to the underlying structures. Tongue protrusion may be difficult. On examination of the neck, they may have cervical lymph node enlargement which decides the stage and the type of neck node dissection. Rarely patients may present with cervical lymph nodes infiltrating the major vessels in the neck causing blow out.

DIAGNOSIS: Clinical examination helps in the diagnosis using TNM Staging and histopathology of the lesion confirms the diagnosis. Wedge biopsy from the edge of lesion including the normal tissue will be taken. Usually the edges are taken for biopsy as the number of actively dividing cells are maximum at the margins and the center of the lesions may have necrosis, which may miss the diagnosis of malignancy. In presence of cervical lymph nodes, fine needle aspiration cytology has been useful in confirming the diagnosis.

Imaging modality help in further assessment and helps in extent of resection of the affected site. Computed Tomography Scan of the head and neck region helps assessment of the extent of bony involvement. MRI has been utilized for greater details on adjacent soft tissue perineural invasion, intracranial extension and accurate delineation of tongue lesions. Role of PET CT is limited to the diagnosis of metastasis and occult primary while patients present with cervical lymphadenopathy. Nasopharyngolaryngoscopy may be done to rule out synchronous primary or second primary malignancies.

STAGING: TNM staging system has been used for all oral cavity malignancies, based on the 7th Edition of AJCC (American Joint Committee for Cancer) Classification.

TREATMENT:

Based on NCCN Guidelines (2014), Stage I and II have been grouped as early stage disease. Radiotherapy and surgery can be offered, however surgery is the preferred mode of treatment. Radiotherapy is reserved for recurrent lesions, tumor at inaccessible sites.

Stage III and IVA have been grouped under advanced stage, multimodality treatment is offered(7). Surgical excision and reconstruction with or without selective lymph node dissection is decided based on the stage of disease. Based on the final histopathology report, plan is made on adjuvant therapy. Adjuvant radiotherapy includes 60-70 Gy in 5 fractions every week according to the conventional schedule. When the surgical resection margins are involved by carcinoma cells, adjuvant chemotherapy along with radiotherapy will be advised. Commonly administered chemotherapy agents are cisplatin, 5 fluorouracil and drugs of taxane group, based on patient selection.

Following surgical resection, significant tissue defect is created which needs to be filled. There have been various modifications in the way of reconstruction for the soft tissue defects created after the excision for oral cavity malignancies. Special considerations for mucosal continuity, functional preservation for speech and swallowing and cosmesis also needs to be taken care of. Size of the defect created and location of the tumor determines the type of reconstruction.

SURGICAL RESECTION AND RECONSTRUCTION: Oncological clearance for resection margins recommended by NCCN guidelines (2014) is 1.5 to 2 centimeter from the induration. The defect thus created needs to be filled using a robust flap cover, which addresses both the functional and cosmetic aspects. Surgical resection in oral cavity malignancies has many components. It consists of skin, mucosa, soft tissue and underlying bone. Based on the extent of resection the type of flap differs. When the soft tissue defect is large and bony defect does not affect the function of the organ, a robust myocutaneous flap is considered. Whenever there is a demand for preservation of function and need for bony continuity, osteomyocutaneous flap is considered. There has been an increasing incidence of oral cancers due to early detection and increasing awareness among population. The widespread availability of treatment facility and awareness among patients, and advances in treatment options, the need for reconstruction has gone up. With the increasing availability of expertise, reconstruction with free flaps for oral cavity malignancy is on a rising trend. Many types of reconstruction techniques have been employed in head and neck cancer patients. Due to the extent of the disease and proximity to vital structures and the need for restoration of function and cosmesis, there has been a need for free flap reconstruction.

The present unit in which the study was conducted is equipped to treat head and neck malignancies surgically along with the reconstruction of the defects. On an average of two free flaps every month are being done for oral cavity malignancies. The study involved monitoring the free flaps using Smartphone photography and transfers it to the operating team using 3G internet technology.

FREE FLAP MONITORING: There are many methods of monitoring microvascular free flap. The gold standard in monitoring free flaps is clinical monitoring, where assessment of the flap color, temperature, turgor, capillary refill is done. Non-invasive Doppler has been used to assess the vascularity and flow in the vessels anastomosed. There are newer methods

of monitoring free flaps, which can be broadly classified into invasive and non-invasive methods. Non invasive methods include clinical monitoring, photography and using hand held Doppler. Invasive monitoring includes implantable Doppler probe (Cook-Swartz Doppler)(8), transcutaneous Doppler probe, tissue oxygenation monitors, photoplethysmography and flow coupler device.

Recent studies have shown the importance of non invasive modalities in the monitoring of microvascular free flaps. *Engel et al* studied the diagnostic accuracy of remote real-time monitoring of free flaps via Smartphone photography and 3G wireless internet, in Taiwan. They concluded that this method of free flap monitoring using Smartphone photography and 3G wireless internet is feasible, reliable and safe. The accuracy rates of remote assessments of free flaps were comparable to in-person assessments. Hence the similar method has been utilized to study the feasibility of Smartphone technology as an adjunct to free flap monitoring(9).

LITERATURE REVIEW

Oral malignancies are one of the most common malignancies in Indian Subcontinent(1). Overall, 57.5% of global head and neck cancers occur in Asia especially in India. Head and neck cancers in India account for 30% of all cancers. In India, 60 to 80% of patients present with advanced disease as compared to 40% in developed countries. A slow decline in the incidence of most of head and neck cancers has been documented in India(10). It accounts for 6% of total deaths in India(11).

RISK FACTORS: The peculiarity of this malignancy is the use of tobacco in different forms, as a risk factor(12). Tobacco is the most common risk factor for Oral cavity malignancies(5). Among the other risk factors for head and neck malignancies is alcohol consumption. Tobacco acts synergistic to alcohol in causing oral cavity malignancy. Recent studies have shown the causative relationship between Human Papilloma Virus(HPV) in Head and Neck Cancers(13). In 25% cases of cases, HPV has been shown to have causative relationship(6).

PREMALIGNANT LESIONS: These are the lesions which presently do not show histopathological features of invasive carcinoma, but have the potential over time and in response to the risk factors, to transform into overt malignancy. Commonly seen premalignant lesions are oral leukoplakia, Erythroplakia and oral submucous fibrosis. Each of these has different likelihood of transformation into malignancy. Other lesions with doubtful likelihood of developing into malignancy are lichen planus and oral candidiasis.

Leukoplakia, as defined by the World Health Organization, is a white patch or plaque, which cannot be scraped off and cannot be characterized as any other disease. Thus, the term is not applied to other white lesions, such as those caused by candidiasis, lichen planus, or many

other disorders. On histological examination, these show hyperkeratosis, dysplasia or carcinoma in situ(14). On microscopic evaluation they vary from basal hyperkeratosis without epithelial dysplasia to mild to severe dysplasia and carcinoma in situ. Only histological evaluation distinguishes these lesions. The lesions have a strong association with tobacco use, particularly pipe smoking and smokeless tobacco (pouches, snuff, chewing). Less likely implicated causes are chronic friction due to sharp tooth, ill-fitting dentures; alcohol consumption and irritant foods. More recently, human papilloma virus antigen has been identified in some tobacco-related lesions, raising the possibility that the virus and tobacco have synergistic action in the induction of these lesions. Transformation rate for leukoplakia into overt malignancy is 0.9-17%,over 10 years(15). Variants have been described, nodular, speckled (interspersed with patches of Erythroplakia) and proliferative verrucous leukoplakia. Latter has a higher risk of progression to invasive squamous cell carcinoma(up to 70%)(16) .

Erythroplakia, by definition, is an erythematous counterpart of leukoplakia and clinically it is a velvety, red lesion which is usually discrete. It mimics certain inflammatory lesions of the oral cavity, namely aphthous ulcers, oral candidiasis. Patients can be asymptomatic or may present with burning sensation in the oral cavity. Transformation into invasive malignancy is approximately 14-50% over 10 years for erythroplakia. Erythroplakia has more number of dysplastic areas than leukoplakia(15).

Oral Submucous Fibrosis is a condition with extensive fibrosis of the oral cavity mucosa, especially the buccal mucosa. It is more commonly seen in association with areca nut use. These patients present with trismus, burning sensation and ulcers in the mouth. Submucous fibrosis with significant trismus hinders clinical examination of oral cavity. These areas show features of chronic inflammation and dysplasia. Transformation into invasive carcinoma has been seen in 17% over 10 years follow up period(17).

Oral lichen planus has been known as a precancerous lesion for oral cancer. However there are no data to prove the invasiveness and malignant transformation(18). These precancerous and potentially malignant lesions need tissue diagnosis and long term follow up with the physician. Any change in these lesions warrants excision biopsy and histopathological examination. There has been no consensus on the duration of follow up for these patients.

PATHOGENESIS: The pathogenesis of oral malignancy follows the pathway of epithelial carcinogenesis. Development of a tumor represents the loss of cellular signaling mechanisms involved in the regulation of cell growth. Following malignant transformation, mitosis, programmed cell death (apoptosis), and the interaction of a cell with its surrounding environment gets altered. Advances in molecular biology have helped in the identification of mutational analysis associated with this transformation.

Over expression of mutant p53 gene is associated with carcinogenesis at multiple cell-lines within the body. Point-mutations in p53 gene have been observed in up to 45% of head and neck carcinomas. Koch and associates noted that p53 gene mutation is the key event in the malignant transformation of over 50% of the head and neck squamous cell carcinomas in smokers (19).

Carcinogenesis has been explained by a two-hit hypothesis, involving DNA damage and the progression of mutated cells through the cell cycle. These two events are also known as *initiation* and *promotion*. Almost up to six to 10 independent genetic mutations are required for the development of a malignancy. Over-expression of mitogenic receptors, loss of tumor-suppressor proteins, expression of oncogene-related proteins which inhibit apoptosis, and over-expression of certain proteins that drive the cell cycle and allow for unregulated cell

growth. Environmental exposure leads to certain genetic mutations. Environmental exposure such as ionizing radiation or carcinogen exposure, viral infection, or spontaneous mutation (deletions, translocations, frame shift mutations). Common genetic alterations, such as loss of heterozygosity at 3p, 4q, and 11q13, and the overall number of chromosomal microsatellite losses are found more frequently in the tumors of smokers than in the tumors of nonsmokers (19).

PATHOLOGY: The most common histology in oral cavity malignancies is squamous cell carcinoma. The oral cavity malignancy in the Indian Subcontinent accounts for 30% of all cancers(20). Pathological features of early oral cavity squamous cell carcinoma have pearly white to gray, circumscribed thickenings of the mucosa closely resembling leukoplakic patches. They then may grow in an exophytic fashion to produce readily visible and palpable nodular and finally fungating lesions or they can be endophytic, with an invasive pattern having a central necrosis to create a malignant ulcer. The squamous cell carcinomas are usually moderately to well-differentiated keratinizing tumors. Depending on the depth of involvement of mucosa they can be classified as, mild, moderate and poorly differentiated tumors.

PRESENTATION: Patients with oral cavity malignancies commonly present with an ulcer or a proliferative growth in the oral cavity. They may have bleeding from the ulcer, halitosis. Carcinoma of the alveolus presents with loose tooth. Patients have difficulty in speech and swallowing. They may present with associated regional lymphadenopathy. On examination they may present with an ulcer with surrounding indurated margins, with fixity to the underlying structures. There may be difficulty on tongue protrusion, due to the involvement

of base of tongue. There may be cervical lymph node enlargement. Distant metastasis happens to the lungs, skeleton and liver.

It has been studied that a majority of people affected by this disease belong to the low socio-economic strata and has significant economic burden on them. Considering the treatment options which includes early diagnosis, evaluation of extent of the disease, surgical excision and reconstruction, and adjuvant treatment in the form of radiotherapy with or without chemotherapy, has significant economic burden on these patients. Hence it is of paramount importance to study the effectiveness of management of these patients.

Anatomically, the oral cavity extends from the skin-vermillion border of the lips to the junction of hard and soft palate above and the line of circumvallate papillae of the tongue, which demarcates between the anterior two-third and posterior one-thirds of the tongue below (posterior one-thirds forms part of the oropharynx).

Oral cavity can be divided into subdivisions for the convenience into the following sites according to AJCC 7th Edition:

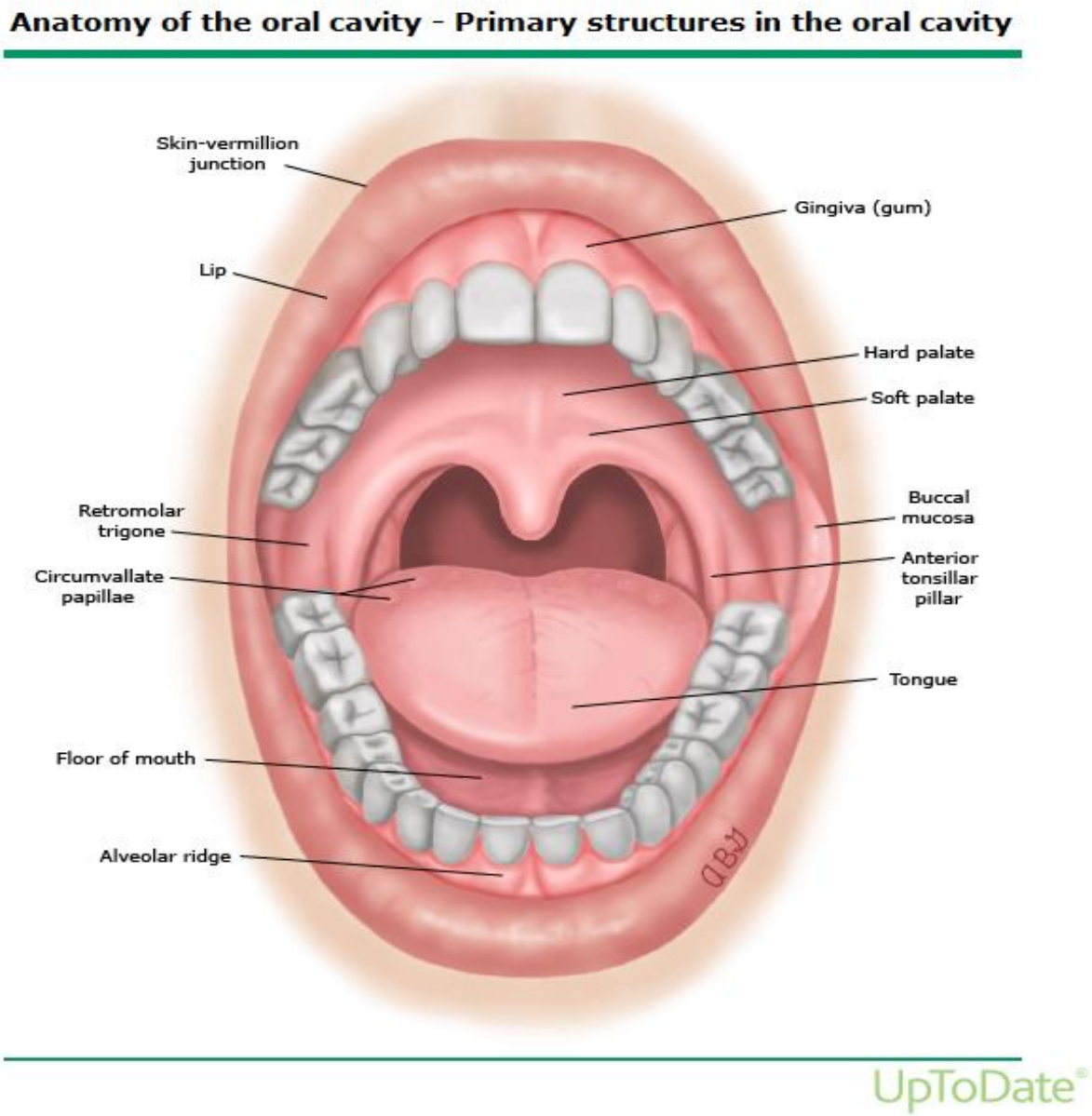

Figure 1: *Adopted from Uptodate.com®*

Lip	Buccal Mucosa
Lower Alveolar Ridge	Upper Alveolar Ridge
Retro molar Trigone (Retro molar Gingiva)	Floor of the Mouth
Anterior two thirds of the Tongue (Oral Tongue)	Hard Palate

Anatomy of the Regional Lymph nodes of the Neck:

The status of cervical lymph nodes is very important is prognostication. These can be subdivided and grouped into seven levels for the ease of description(Based on AJCC 7th edition)(21).

Level I Ia	Submental
Ib	Submandibular
Level II	Upper Jugular
Level III	Mid-jugular
Level IV	Lower jugular
Level V	Posterior triangle (spinal accessory and transverse cervical)
Level VI	Prelaryngeal (Delphian)
	Pretracheal
	Para tracheal
Level VII	Upper Mediastinal

(Adopted from AJCC 7th edition)(21).

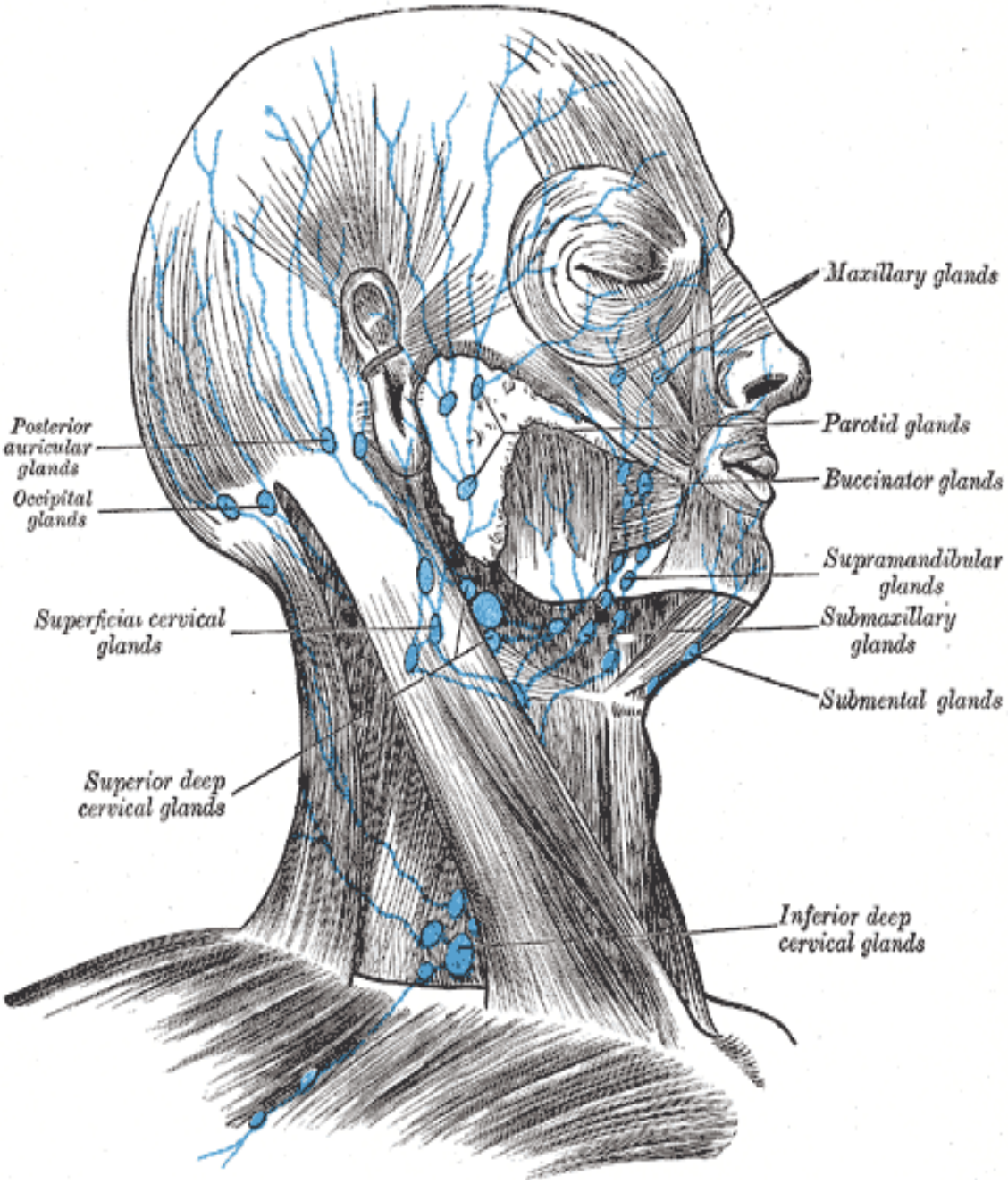

Figure 2: *Adopted from Gray's anatomy*

DIAGNOSIS: Clinical examination of the oral cavity, neck and general physical examination plays a significant role in the staging of the disease. Staging is done according to the 7th Edition of AJCC Guidelines for cancer staging (as described below). Diagnostic modalities in use for confirmation of malignancy are tissue diagnosis by biopsy of the lesion. Neck lymph nodes can be subjected to fine needle aspiration cytology or biopsy. Imaging modalities utilized in assessment of head and neck malignancies are Computed Tomography (CT) of head and neck region to look for bony erosion, intracranial extension to plan on excision and adjuvant therapy.

Magnetic Resonance Imaging (MRI) has been used to diagnose the extent of tongue involvement, soft tissue extent in oral cavity lesions and lymph nodal status in the neck. Recently Positron Emission Tomography (PET-CT) has been utilized to look for occult primary in head and neck cancers.

STAGING OF ORAL CAVITY MALIGNANCY: TNM staging system has been used for all oral cavity malignancies, based on the 7th Edition of AJCC (American Joint Committee for Cancer) Classification(21)

T stands for primary tumor, N for nodal status and M for metastasis.

According to AJCC 7th edition(21)

TX Primary tumor cannot be assessed

T0 No evidence of primary tumor

Tis Carcinoma in situ

T1 Tumor </= 2cm in its greatest dimension

T2 Tumor> 2cm but less than 4cm in greatest dimension

T3 Tumor > 4cm in greatest dimension

T4a (Lip)

Tumor invades through cortical bone, inferior alveolar nerve, floor of mouth, or skin of face.

T4a (Oral cavity)

Tumor invades through cortical bone, into deep muscles of tongue (genioglossus, hyoglossus, palatoglossus, and styloglossus), maxillary sinus, or skin of face.

T4b Tumor involves masticator space, pterygoid plates, or skull base and/or encase internal carotid artery.

Regional Lymph Nodes (N)

Nx Regional lymph nodes cannot be assessed

N0 No regional lymph node metastasis

N1 Metastasis in single ipsilateral lymph node </= 3cm in greatest dimension

N2a Metastasis in single ipsilateral lymph node, > 3cm but <6cm

N2b Metastasis in multiple ipsilateral lymph nodes, none > 6cm,

N2c Metastasis in bilateral or contralateral lymph nodes none > 6cm in greatest dimension

N3 Metastasis in a lymph node, 6cm in greatest dimension

Distant Metastasis (M)

M0 No distant metastasis

M1 Distant metastasis

Stage Grouping

Stage 0	Tis	N0	M0
Stage I	T1	N0	M0
Stage II	T2	N0	M0
Stage III	T3	N0	M0
	T1	N1	M0
	T2	N1	M0
	T3	N1	M0
Stage IVA	T4a	N0	M0
	T4a	N1	M0
	T1	N2	M0
	T2	N2	M0
	T3	N2	M0
	T4a	N2	M0
Stage IVB	Any T	N3	M0
	T4b	Any N	M0
Stage IVC	Any T	Any N	M1

MANAGEMNET OF ORAL CAVITY MALIGNANCY:

Based on NCCN Guidelines 2014, Stage I and II have been grouped as early stage disease. Radiotherapy and surgery can be offered, however surgery is the preferred mode of treatment. Radiotherapy is reserved for recurrent lesions, tumor at inaccessible sites.

Stage III and IVA have been grouped under advanced stage, multimodality treatment is offered(7). Surgical excision and reconstruction with or without selective lymph node dissection is decided based on the stage of disease. Based on the final histopathology report, plan is made on adjuvant therapy. Adjuvant radiotherapy includes 60-70 Gy in 5 fractions every week according to the conventional schedule. When the surgical resection margins are involved by carcinoma cells, adjuvant chemotherapy along with radiotherapy will be advised. Commonly administered chemotherapy agents are cisplatin, 5 fluorouracil and drugs of taxane group, based on patient selection.

RECONSTRUCTION STRATEGIES IN HEAD AND NECK:

Head and neck region reconstruction presents different challenges for a surgeon(22). Due to visibility of the region and difficulty in concealing the defect there has been a greater demand for skills and reconstructive strategies. Main aim of reconstruction is to fill the defect and to attempt to retain the physiological function of the organ. The strategy depends on the site affected, the extent of resection and the need for adjuvant therapy. In the head and neck region, the bony skeleton especially the Jaw has a very specialized function and need for special reconstructive strategies. The soft tissue of face includes external coverage with skin, internal mucosa, and muscle. The skin of face is closely related to the underlying muscle, function as a single unit. This complex unit is responsible for the unique appearance, facial wrinkles and responsible for the way we communicate. Facial muscles are unique anatomically, the fact that they are innervated by facial nerve. Facial nerve sometimes may be sacrificed for tumor clearance and this loss of facial nerve function further complicates the reconstructive strategies. Head and Neck region has many specialized structures including eyelids, ears and nose. It is difficult to reconstruct all these structures with accuracy. There are mucosa lined cavities in this region, which leads on to the aero digestive tract. Inside the oral cavity is the other most specialized organ, the tongue, which is vital for speech and swallowing and when affected by malignancy, needs to be resected. The region of Head and Neck is one of the richly vascularized areas in the body(23).

RECIPIENT SITE: The primary objective in reconstruction of any defect is to restore as closely as possible the normal, and to minimize the deformity or defect created, causing as little damage as possible at the donor site(24). The choice of recipient site is based on various strategies. Following resection of the oral cavity malignancy, surrounding area will be recognized to locate a recipient artery and vein. The most commonly used recipient artery depends on the extent of defect created after resection of the malignancy. Head and neck is

one of the richly vascularized regions of the body. The main blood supply of skin of the head comes from the external carotid artery, except for the central area which includes eyes, bridge of nose and the central portion forehead, all of which is supplied by the ophthalmic branch of Internal carotid artery. In terms of free tissue transfer, most of the branches of external carotid artery are useful. The facial artery arises from the external carotid artery and exits the neck coursing around the inferior border of mandible. Just before crossing, it gives rise to the submental artery and submental flap. This can form a soft tissue pedicled flap particularly useful in this region. This has been used in the reconstruction of lower face. The advantages of this flap being, excellent tissue characteristics with good skin texture and color match. This creates a minimal donor defect which can be closed by a cosmetic transverse submental scar (25). A problem with submental artery being the small caliber and dissection is difficult. The venae comitantes are also of small caliber, easily injured during dissection and early postoperative period edema is a not very uncommon. The facial artery gives off branches to the inferior border of the mandible. The facial artery itself is a named artery in facial artery musculomucosal flap(FAMM), described by Pribaz in 1992(26). This is an intraoral flap most commonly used for the reconstruction of intraoral defects. It incorporates both mucosa and buccinators muscle, as well as facial artery(26). The facial artery is the most commonly used recipient artery in free flaps in head and neck region. The main advantage of facial artery is the easy accessibility. However in patients who need a neck dissection or in patients where mandible reconstruction has been planned, facial artery may be difficult to access. In such cases it has to dissected well proximal towards the posterior belly of digastric muscle. At this location the recipient vein may be some distance away.

Superior thyroid artery is a branch of external carotid artery, which is commonly used for vascularized free flap. Anatomically it arises as the first branch of external carotid artery, which makes it useful for this purpose. The caliber is usually not a problem and flow through

it is excellent. The veins are in close proximity which makes anastomosis feasible. It can sustain an anastomosis from proximal or distal directions (27). Superficial temporal artery is one of the terminal branches of external carotid artery, which supplies the scalp and temporalis muscle. It supplies the temporoparietal fascia and useful in the reconstruction of scalp and midface. The transverse cervical artery arises from the thyrocervical trunk of subclavian artery. This vessel is located in the root of the neck, and it is accompanied by a named vein. It is extremely useful as a recipient vessel in free tissue transfer in this area. The transverse cervical artery provides the dominant blood supply to trapezius muscle. The trapezius flap remains a very useful flap in the reconstruction of head and neck in resurfacing the posterior aspect such as occipital region.

ARTERIAL BLOOD SUPPLY OF HEAD & NECK

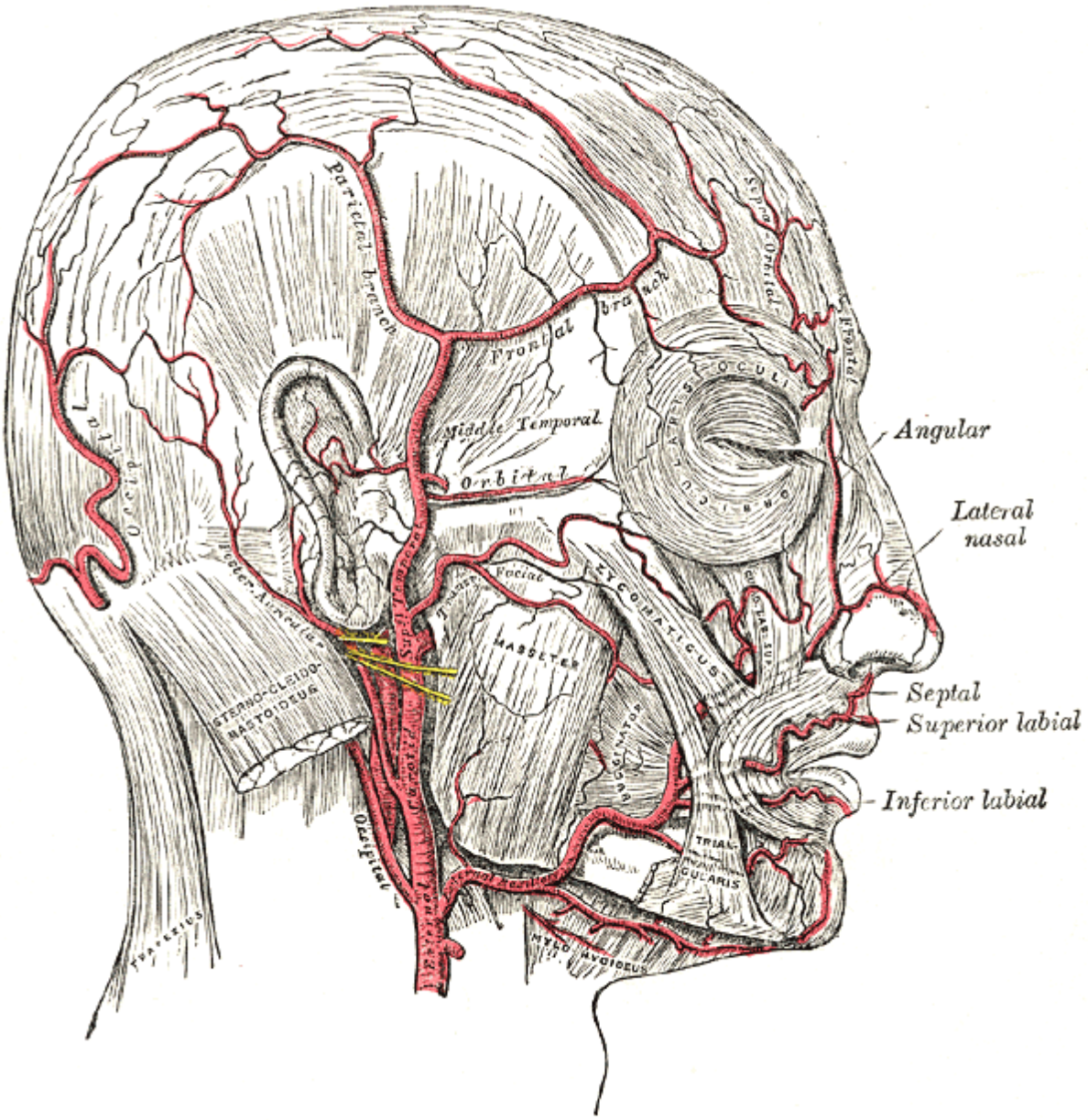

Figure 3: ***Adopted from Gray's anatomy®***

VENOUS DRAINAGE OF HEAD AND NECK REGION

Venous anatomy of head and neck region is noteworthy. The anterior facial vein is located anterior to facial artery, where it is straight, whereas the artery is tortuous. It has a good caliber and very useful in free tissue transfer. However in patients who have had neck dissection, this vein would have been ligated hence not available as a recipient vein. In such cases anterior facial vein cannot be used. In other cases, external jugular vein, transverse cervical vein can be used as a recipient vein. Otherwise, when there are no accessible veins in the neck, end to side anastomosis with internal jugular can be attempted. Due to abundance of veins in the neck and their large caliber, recipient vein usually is not a problem.

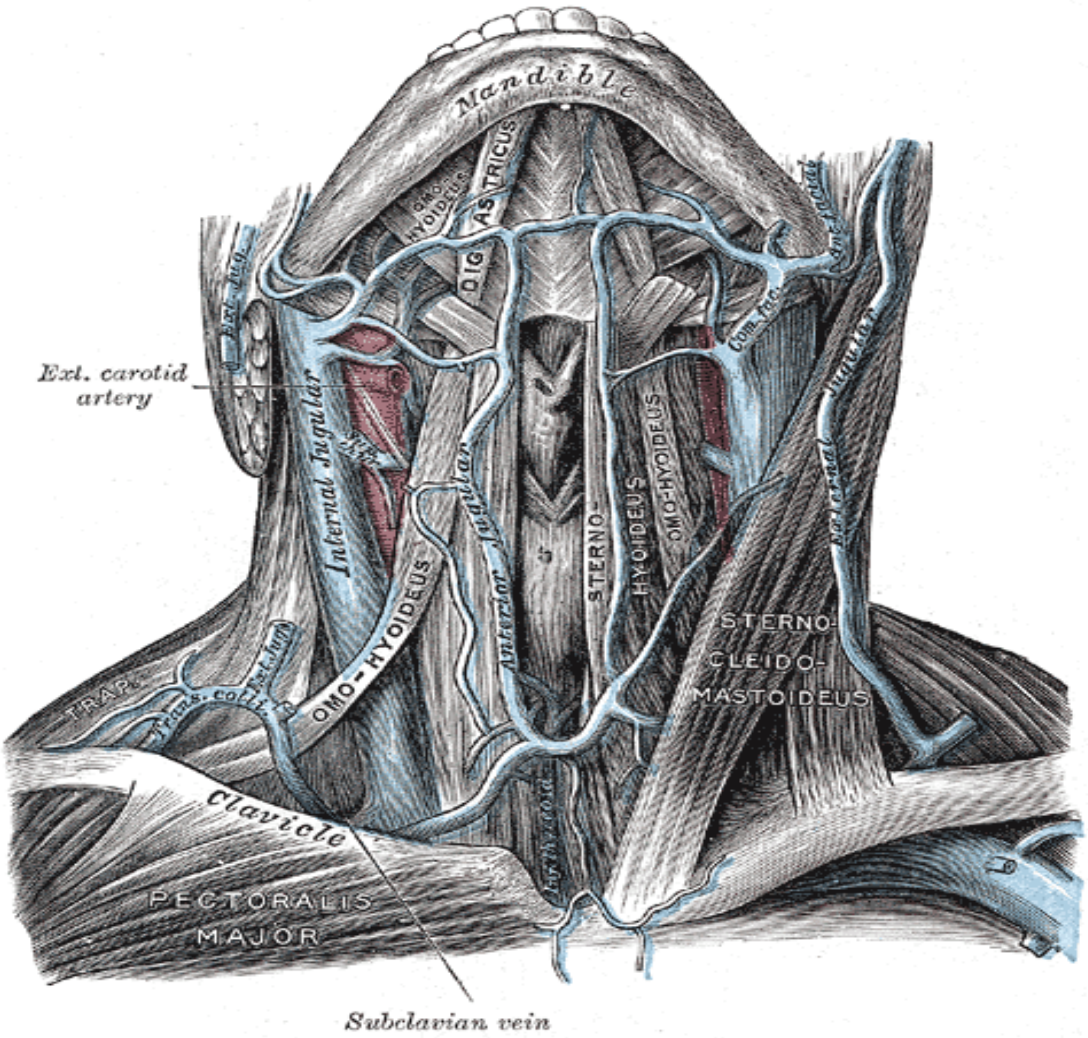

Figure 4: ***Adopted from Gray's anatomy®***

The issue of whether to innervate the free flaps or not, is still controversial. It is true that sensation can be restored and theoretically, innervated flaps are better. Whether re-innervation improves the function of the flap remains debatable. However there are very few studies which show some improvement in sensory function in patients who have had free flap reconstruction for lower lip defects(28). The nerves most commonly used in head and neck reconstruction are lingual nerve for intraoral sensory innervation. Facial and masseter nerves have been used to give motor innervation for facial reanimation. Contralateral facial nerve has been harvested to form cross-facial nerve graft, to restore facial movement (29).

DONOR SITE:

In reconstructive surgery, another equally important objective must be to reduce the morbidity at the donor site of the selected flap. It is not possible to have total absence of donor site morbidity, unless an identical twin is donating the missing part of the donor site. All the muscle flaps are known to have some loss of function at the donor site. Due to the dissection at the intermuscular plane and loss of these perforator vessels, leads to donor site morbidity. Whenever possible, direct closure of the donor site with a linear scar is always preferred. Skin grafting is another option, however the scar after that cannot be hidden. The non-cosmetic skin grafted donor site has been a major problem with all cutaneous flaps. Classical example being the radial artery forearm free flap, where none of the measures can reduce this morbidity. And additional harvest of bone exaggerates the defect(30).

HISTORY OF RECONSTRUCTIVE SURGERY : The history of Plastic Surgery originated in India where skin flaps were used centuries ago in 600 BC by Susruta for covering the defects in the face, the so-called Indian rhinoplasty. These defects were created after amputation of the nose as a punishment for adultery. The skin from the forehead was used to cover the defects in the nose. Later on after Renaissance, syphilis was very common in Europe, the Italian school, under Tagliokozzi perfected the art of replacing the skin from the arm to fill defects in the nose, which was called Italian rhinoplasty. Sooner plastic surgery was banned by the Church. Pare held that the operation was too difficult for the surgeon and too painful for patient. Hence the Faculty of Medicine in Paris prohibited operative repair of the face as late as 1798. It got revived only during the 19th century by the German and French schools. The Germans notably Dieffenbach, and French under Jobert made many contributions to plastic surgery. In 1849, Jobert published a 2-volume textbook, the second part of which has operations such as repair of cleft lip, cheiloplasty and some new procedures such as repair of vesicovaginal fistula. In the first volume of his textbook, he described the principles of plastic surgery. He described temperature changes that take place in a skin flap; he also described re-innervation of flap. He stated when a pedicle of the flap should be divided and he also described that the size of the pedicle should be proportional to the size of the flap(31). In the First World War Sir Harold Gillies founded plastic surgery specialty while repairing the terrible deformities caused by war wounds from 1914-1918. He formulated the principles of use of skin flaps and he wrote in his textbook, that in general a flap should not be longer than the width of its base(32). This statement, that the length-to-breadth ratio of a flap should be 1:1 has been followed even now(31).

The history of plastic surgery is a recapitulation of the history and the corresponding evolution of flaps. Delayed pedicled flaps were being done initially with 2:1 length to breadth ratio of flap, wherein the flap was attached at one end and dividing it 2-3 weeks later. When the flap has to move over the intervening tissue and not to return to the original bed, then it is turned into a tube with the skin on the outside and grafts the donor site underneath it. This was called a tubed pedicled flap. This technique was followed for about 40 years, till 1920 when Gillies came with the concept on viability of flaps. That 'in general the length of the flap should be no more than the base, but a longer flap could be raised if it contained a large vascular pedicle at its base'. This concept was slowly being developed, by 1960, skin flaps were divided into axial and random flaps(33) . Axial flaps are those which have a large vascular pedicle in their base and random flaps do not. The main advantage of axial flaps is that they are longer and larger than a random flap of the same size. The classical examples for axial flaps are deltopectoral flap based on the branches of internal mammary artery, forehead flap which is based on superficial temporal artery. Thus axial flaps are named after the artery which nourishes them.

Random flaps are supplied by the segmental artery which runs deep to the muscles and perforates to supply a small area of the skin. Random flaps have no specific design and no specific vascular pedicle, unlike axial flaps. The principles of their viability is not certain, hence the name. Milton in his work in1970 stated that the surviving length of a flap was independent of the width of its base. This was applicable to random flaps where he was using very large random flaps, which were later found to be axial flaps. Further experiments have shown that the surviving length of the random flap increases with the increasing width of the base up to a certain point, beyond which the surviving length cannot be increased whatever be the length of the base of the flap(32)(31).

Orticochea discovered the use of musculocutaneous flap which he accidentally found that he could raise a large cutaneous flap without the need for delay procedures, as long as the underlying muscle was intact(34). However this association of existence of a musculocutaneous artery was explained by McCraw et al, arteries crossing the muscles to reach the skin were identified and called "musculocutaneous arteries"(35) (36). The first report on musculocutaneous flap was made by Tanzini in 1906. He and many others were well versed with the use of musculocutaneous flaps(37). However it took at least 70 years when musculocutaneous flaps were frequently used in the late 1970s.

Due to the overzealous use of cutaneous flaps, the fasciocutaneous flaps did not gain much importance till 1980s when Ponten reintroduced "fasciocutaneous flaps". He noticed that few of his flaps where he had included deep fascia in his flaps, had longer survival period compared to random flaps of similar width(38). Historically in the last century, Gillies and Esser had described the advantage of including the deep fascia with the skin flap(33). The "fascial plexus" was described as essential for the survival of fasciocutaneous flaps. It represents the confluence of subfascial,intrafascial, and suprafascial vascular plexuses located within the dermal, subdermal,superficial adipofascial(above Scarpa's fascia), and deep adipofascial layers, where each has an array of interconnected blood vessels, which form an angiosome in case of a fasciocutaneous flap(39)(40)(41). A new concept of vascular supply to the skin and classification of skin flaps according to their vascularization. The success of fasciocutaneous flaps is based on the existence of epifascial vascular networks and reliable blood supply. However, there has been no thorough classification of the vascular anatomy of the fascia and skin and there is some confusion in regard to cutaneous vascular nomenclature. The vascular system involved in the cutaneous circulation can be divided into four categories.

This permits classification of skin flaps into five types cutaneous, fasciocutaneous, adipofascial, septocutaneous, and musculocutaneous flaps.

MATHES & NAHAI CLASSIFICATION: This is a classification of fasciocutaneous flaps based on type of deep fascial perforator vessel. This is very similar to Cormack & Lamberty's tripartite system of flaps (Refer the diagram).

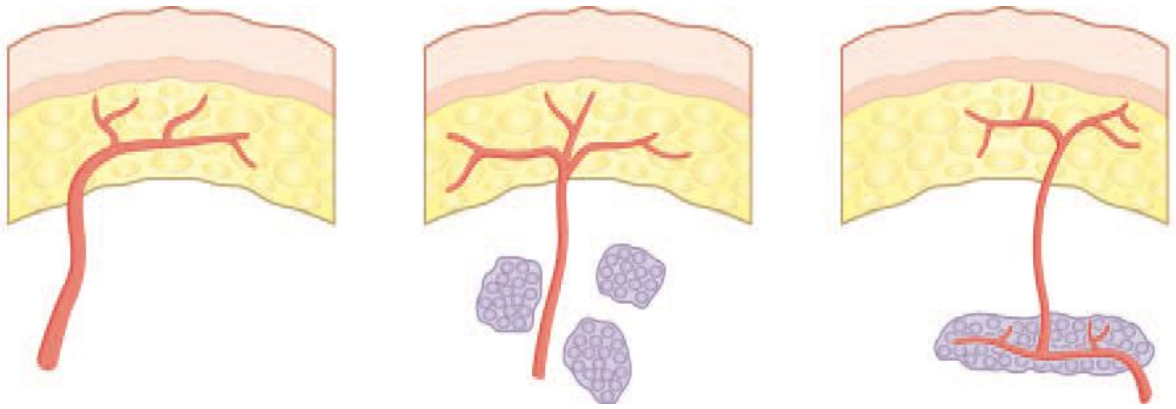

Direct cutaneous Septocutaneous Musculocutaneous

Figure 5.

Cormack & Lambert divided all skin flaps into a tripartite system including *direct cutaneous* (axial), *musculocutaneous* and *fasciocutaneous flaps*. Cormack & Lamberty described fasciocutaneous flaps, as retention of system of vascularization within a given flap and not any specific tissue constituents per se. Thus even if we exclude skin, deep fascia from a flap, the flap is dependent on the fascial plexus and it would still be called a fasciocutaneous flap. Thus a fasciocutaneous flap can be made of any or all of the tissue layers between skin and deep fascia(42).

CORMACK & LAMBERTY CLASSIFICATION(42)**:**

It has three major types as shown in the diagram

Type A: A flap has multiple fascial feeders or perforators which did not require specific identification, reminiscent of random skin flap.

Type B: A flap has large, solitary septocutaneous perforator.

Type C: A flap relied on multiple and small segmental septocutaneous branches.

CORMACK & LAMBERTY CLASSIFICATION:

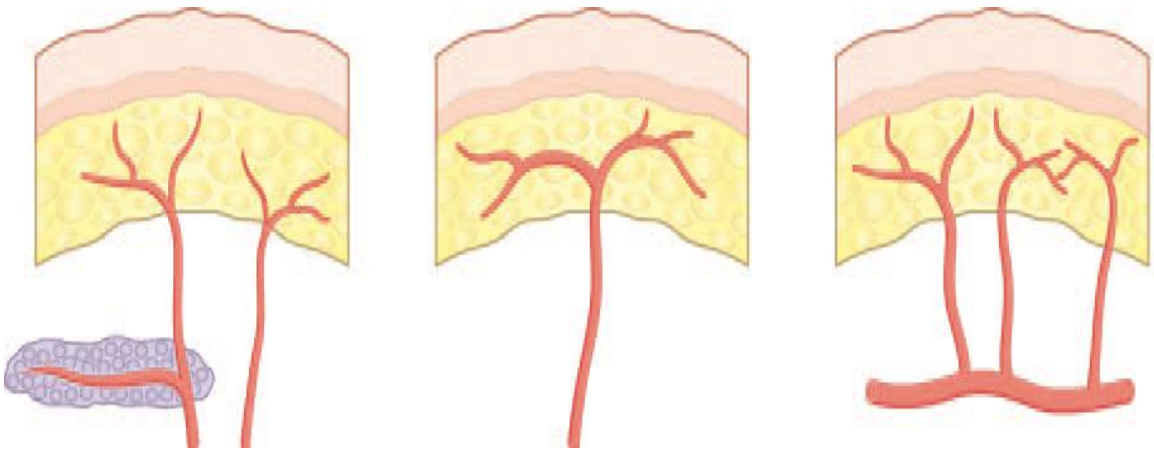

Multiple feeders (Type A) Solitary (Type B) Segmental (Type C)

Figure 6.

Nakajima et al(39) classified the fasciocutaneous flaps into six forms, each based distinctly on different perforator of the deep fascia. Type I to type VI, which have been previously described. Type I direct cutaneous flaps, similar to axial flaps identified by Morgan and Mc Gregor(31). Type II is direct septocutaneous flap, similar to Cormack &Lamberty type B and type V septocutaneous perforator flap is same as Cormack & Lamberty type C. Type VI is

musculocutaneous flap, which resembles the traditional myocutaneous flaps. The remaining two flaps were hypothesized based on direct cutaneous branch of muscular (IV) and perforating cutaneous branch of muscular vessel (III). There two latter were the most important contribution by Nakajima. In his study on three dimensional views of fascial plexus, demonstrated the axiality, vessel size and suprafascial course of these vessels. Hence he proved that function of these vessels were to provide nutrition for the skin and secondarily the muscle. The perforating cutaneous branch of a muscular vessel has become the backbone of all the muscle perforator flaps(43)(42).

ANGIOSOME CONCEPT BY TAYLOR: In 1893, Taylor proposed the concept of angiosome with reference to the perforator flap. Spalteholz demonstrated a pure (intermuscular) or impure (vessels primarily supplying deeper tissues, mostly muscle) path of cutaneous perforator vessels. All arteries to the skin were classified as either “direct” or “indirect” branches from an underlying source vessel. Taylor described that the direct vessels are the ones which primarily supply the skin, and it is immaterial whether they first traversed intermuscular or intramuscular septa, because their main destination is always to the skin. The indirect vessels arise above the deep fascia as terminal branches, which mainly supply the deeper tissues; hence they are only a secondary means of blood supply to the skin. All corresponding cutaneous flaps were named as either direct perforator or indirect perforator branches.

MUSCLE FLAPS:

Mathes and Nahai classification(44)

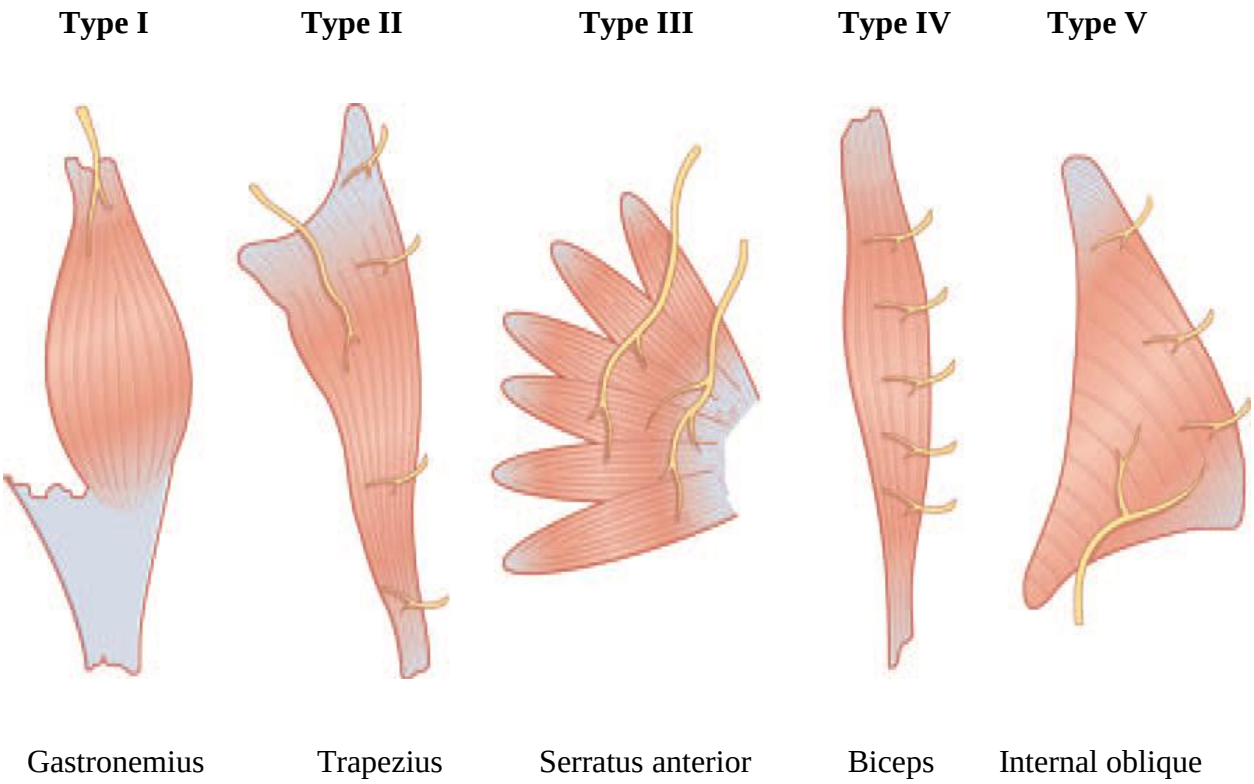

Figure 7.

MUSCLE FLAPS: The most pragmatic system was established by Mathes & Nahai(44) . Five patterns of muscle circulation, based on studies of the vascular anatomy of muscle, are described. Clinical and experimental correlation of this classification is determined by the vascular pattern of each muscle useful in reconstructive surgery with regard to the following parameters: arc of rotation, skin territory, distally based flaps, microvascular composite tissue transplantation, and design of muscle-delay experimental models. This classification is helpful in assisting the surgeon both in the choice and design of the muscle and musculocutaneous flap for its use in reconstructive surgery with all muscles categorized according to similarities of the origin of their blood supply.

On the other hand, the majority of musculocutaneous perforators arise at hilum of that muscle, where the vessels enter it. The knowledge about the most reliable muscle types, dominant pedicle, and their location, is essential to better predict the presence of musculocutaneous perforators. This is essential for the harvest of these flaps even though the muscle itself is not to be included.

TYPES OF FLAPS: Flap is by definition is a thin, flat piece of cloth, paper, metal, etc. that is hinged or attached on one side only and covers an opening or hangs down from something

(Oxford dictionary meaning). In surgery, a flap is a piece of tissue used to cover a defect. The major flap types are named according to the tissue transferred(32)(31)(45).

Skin Flap: It consists of skin and superficial fascia.

Fasciocutaneous flap: It consists of skin and investing layer of deep fascia.

Muscle flap: It consists of muscle.

Myocutaneous flap: It consists of skin, muscle.

Osteomyocutaneous flap: It consists of skin, muscle and bone. It is a composite flap.

FREE FLAPS: The technique of free flap involves the transfer of a flap whose perfusion source has been concentrated into a single arteriovenous system. This involves raising a flap and isolation of the vascular pedicle. Later the vascular pedicle is divided and the flap along with the vessels (artery and vein) is transferred to the recipient area. At the recipient area, these donor vessels are anastomosed to the recipient vessels respectively, to re-establish effective circulation to the flap, hence the name free flap. In current practice, free flaps are

used for areas where the vessels are larger in caliber and have a longer vascular pedicle, which contribute to greater technical ease and more consistent success.

Initially the technique of microvascular free flap was used in axial pattern flaps, which was later extended to myocutaneous and fasciocutaneous flaps, where the perfusion source is well concentrated, with a good caliber and length of the vessels making the anastomosis relatively easy(45).

TYPES OF FREE FLAPS:

Fasciocutaneous flaps

Myocutaneous flaps

Osteomyocutaneous flaps

Free flaps have independent blood supply and can survive without a pedicle. They are superior in cosmesis. They need close monitoring in the postoperative period. There is multitude of ways of monitoring of free flaps.

There are few drawbacks of free flaps, their higher cost and the expertise required for the reconstruction. Hence it can be performed only in specialized centers. For flap assessment, clinical evaluation has been considered the gold standard and it traditionally includes examination of flap color, temperature, capillary refill and skin turgor(46).

There are numerous sophisticated monitoring techniques that have been developed constantly with advances in technology, despite concerns about their reliability and cost efficiency.

Current technologic advances in media and the internet inspired some authors to use regular digital images to monitor color of the flap. It can help detect changes in the postoperative period more quickly. Another advantage is that images can be transmitted via the internet to the surgeon at a distance.

The basic principles of reconstruction are(47)(48)(22)(45)

- Whenever possible, the excised tissue to be replaced by the like tissue, which means a local tissue, should be used whenever possible. Local tissue gives the best match both cosmetically and functionally.

- The reconstruction should not interfere with the subsequent adjuvant treatment for the disease. The reconstructive strategies should be such that the healing does not delay adjuvant treatment such as radiotherapy, for the current disease.

- Choose a procedure that has the best likelihood of achieving success, although difficult technically.

By this definition, with the evolution of the field of plastic surgery microsurgical techniques are being used in the reconstruction of tissues(45).

General Principles of a Free flap transfer: Free tissue transfer has been in practice from 1981, when the radial forearm free flap was being used and called the Chinese flap(49). The following are the general principles of free flap transfer:

FLAP GEOMETRY: Tension anywhere along the flap should be avoided. When the flap has an anatomically recognizable arteriovenous system, that element has to be focused, regardless of pedicled or free flap nature.

VASCULAR ANATOMY: In fasciocutaneous flaps, kinking and mechanical tension on the vascular pedicle should be avoided. In myocutaneous flaps, it's the compression along the vascular pedicle causes vascular insufficiency, which has been seen in majority of cases.

Venous stasis or thrombosis is the most common cause for free flap failure in the immediate postoperative period. In the usual postoperative period of a free flap, initial edema may start after 48 hours, however should settle by 72 hours. The presence of excessive swelling, cyanosis, coolness, venous stasis on pressure are the features of venous insufficiency in a free flap.

A free flap which looks collapsed and empty , fails to blanch on pressure and feels cold, is suggestive of arterial insufficiency. Both of these are indications for re-exploration.

Postoperative monitoring methods of free flaps are discussed elsewhere.

RADIAL FOREARM FREE FLAP(CHINESE FLAP)(49)

The Chinese or radial forearm flap, first described by Yang et al(1981), has been in use both as a free or a pedicle flap(49). This flap has proved to be one of the safest and most versatile flap in various clinical situations(23). It is usually classified under the category of fasciocutaneous flap, but can also be classified as a composite flap, when a segment of radius has been used. It has been used in the reconstruction of head and neck region for both neoplastic and non neoplastic defects. It has been useful in covering the defects and few studies have shown benefit of reconstruction of oral commissure using Palmaris longus tendon(50)(51)(52).

ANATOMY OF RADIAL ARTERY FOREARM FLAP: The radial artery provides nutrient inflow to the flap via perforating vessels that pierce the antebrachial fascia as they course toward the subcutaneous fat and skin. The radial artery is readily palpable in the distal forearm and the course can be marked by following the pulse proximally. Veins accompany the radial artery and the subcutaneous cephalic vein is at the radial most edge of the forearm. This large vein can be incorporated into the flap distally, or left behind to use for radial artery reconstruction after flap harvest.

Figure 8: *Adopted from Microsurgeon.org*

STEPS OF RADIAL ARTERY FOREARM FREE FLAP HARVEST:

1) Identification of vessels, marking the flap and dissection.

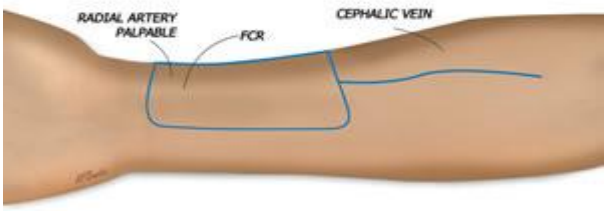

Figure 9

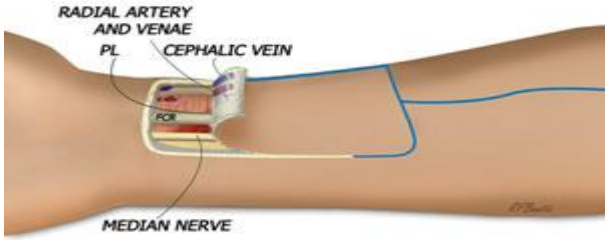

Figure 10

2) Raising the flap isolating the vessels.

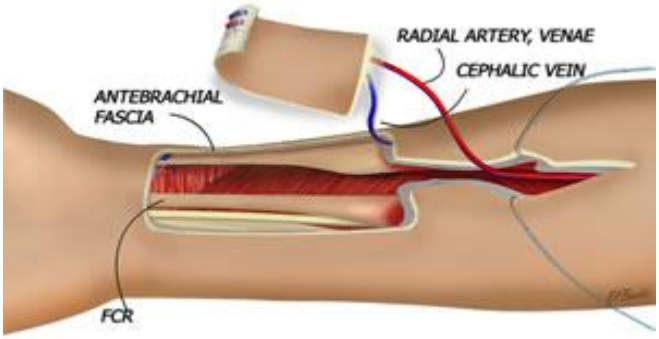

Figure 11

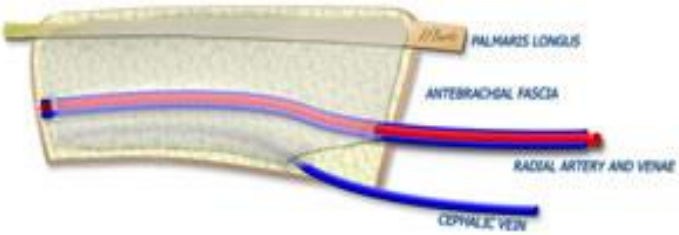

Figure 12: *Adopted from Microsurgeon.org*

Most important preoperative evaluation is to perform Allen's test for presence of a complete palmar arterial arch.

Characteristics of Radial Artery Forearm Free Flap are:

Skin and fascia: optional tendon and bone

Innervation: No

Blood supply: Radial artery and perforators from the radial artery.

Artery: Large caliber artery.

Vein(s): The venae commitantes of the radial artery can be small. The subcutaneous venous system or cephalic vein can be used for drainage, making for a larger caliber vessel.

Pedicle length: Can be dissected up to the take off from the brachial artery just distal to the antecubital fossa.

Radial artery forearm free flap is one of the versatile and reliable free flaps. However, the most common problem faced with the use of this flap is the donor-site morbidity. It has been observed to have a significant defect at the donor site, with a poor graft uptake especially over the exposed tendons. When bone has been included in the flap, this leads to a deeper defect and to a risk of fracture. Many modifications have been made to minimize the complications at the donor-site(49)(53).

ANTEROLATERAL THIGH FREE FLAP(ALT)(54)(55)(56)

Since its description by Song and colleagues in 1984 and elucidation of its vascular Anatomy by Cormack and Lamberty the anterolateral thigh free flap has become a popular flap in Asia(54)(42) (55). The large skin island, easy microsurgery, reliability, and versatility (skin, fat, muscle) have made it one of the preferred flap choices for soft-tissue defect reconstruction(57). It is a reliable flap that supplies a large area of skin, it can be harvested as either a septocutaneous or a musculocutaneous flap, and the thickness and volume can be adjusted to match the defect. Therefore, it can replace most soft-tissue free flaps in most clinical situations(58).

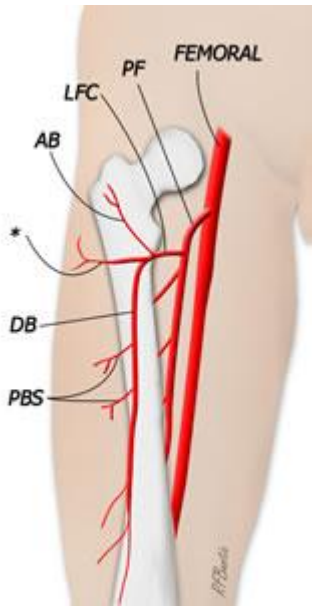

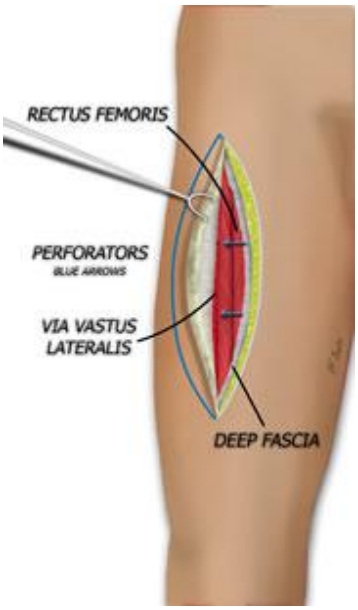

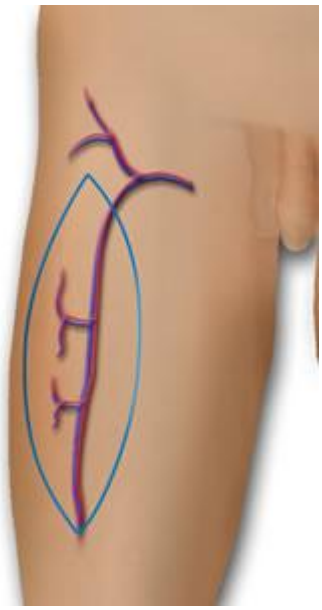

Figure 13 Figure 14 Figure 15

Adopted from Microsurgeon.org

Vascular anatomy of the lateral thigh(56). The ALT flap is nourished by the perforating branches (PBS) from the descending branch (DB) of the lateral femoral circumflex (LFC) vessels, profunda femoral (PF), ascending branch (AB) of PF and a perforator artery (*) through Tensor Fascia Lata (TFL) from muscle to skin.

Characteristics of ALT Flap:

Antero-lateral Thigh flap is a fasciocutaneous flap which can be thinned free of fascia also. Or it can be used as a thin fasciocutaneous flap. It can be made up to 8 x 25 centimeters or larger (if the donor area is grafted).

Innervation: Lateral femoral cutaneous nerve of the thigh.

Blood supply: Mainly the Descending branch of lateral femoral circumflex artery (Fig.).

Artery measures 1.5 to 2.5 millimeters in diameter and vein(s) is slightly larger than artery when taken to the origin.

Pedicle length can be upto 7 centimeters or longer, depending on the flap design and the entry of perforator(s) to the flap. The junction of the proximal and middle third is often the site of a perforator that pierces the tensor fascia lata. This point can be included in the flap to keep the TFL perforator as a sole blood supply when the distal perforators are of poor quality or injured during dissection. The junction of the middle and distal third is marked and is also incorporated into the flap. The posterior flap is elevated and the perforators to the flap are surrounded. The dominant perforator(s) is chosen. If one or two good quality perforators are visualized in the septum, then the anterior elevation can continue until the septum is isolated both medially and laterally. If the blood supply is entirely septal, the descending branch of the lateral femoral circumflex artery is found at the base of the septum between the rectus

femoris and vastus lateralis and traced proximally. The size of the perforator will determine whether an additional vessel is needed. Vessels can be temporarily clamped with microvascular clamps to determine inflow dominance. Following microvascular anastomosis, which can be hand sewn or using a venous coupler, rest of the flap is anchored to the recipient area to fill the defect. Use of coupler has made anastomosis easy and faster(59). Donor area can either be primarily closed or covered with skin graft.

VASCULARISED FIBULA FREE FLAP(60)(61)

Fibula free flap is an osteo-fascio-myocutaneous type of free flap. The fibula was investigated as a donor site for free-flap mandible reconstruction(62). It has the advantages of consistent shape, ample length, distant location to allow a two-team approach, and low donor-site morbidity(63). It has been studies in multiple centers as a choice for the reconstruction of mandibular and maxillary defects. It has been found to be of importance in cases with bony and soft tissue defect and helps stabilize the mandible(62).

ANATOMY OF VASCULARISED FIBULA FREE FLAP

The peroneal artery is closely related to the fibula. The artery arises from the tibioperoneal trunk, distal to the takeoff of the anterior tibial artery (seen in the illustration) below perforating the interosseous membrane. The peroneal artery sends perforators laterally to the skin of the leg, sometimes in a septocutaneous fashion through the lateral intermuscular septum, but sometimes with muscular perforators. The length of the pedicle is usually short, but can be increased substantially by dissecting the peroneal artery along with its venae from the fibula and use the distal bone for reconstruction.

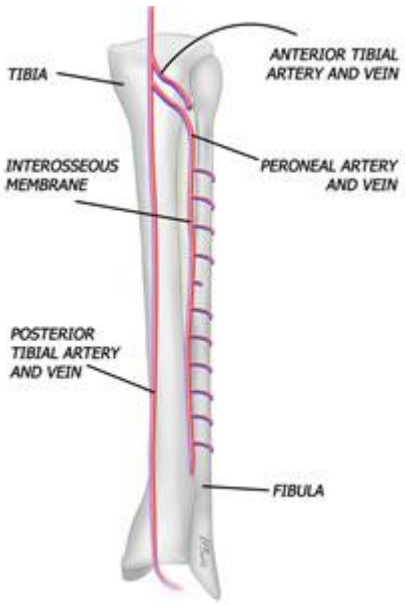

Figure 16

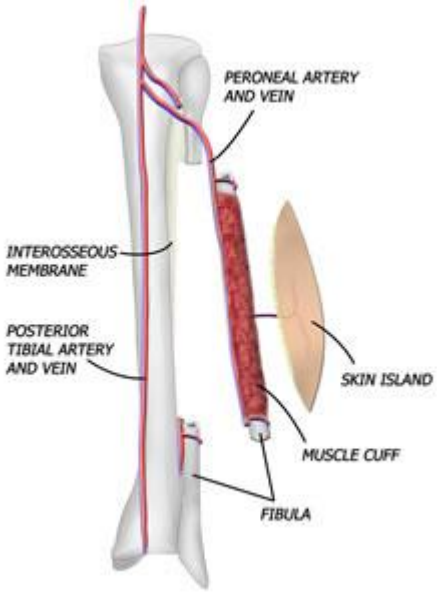

Figure 17

Adopted from Microsurgeon.org

It is important to know the anatomical relationships of the harvested fibular free flap. The bone requires a cuff of muscle at least 1 to 2 millimeters in thickness be harvested with the flap to protect the vascular inflow to the bone flap. Perforating vessels from the peroneal artery also provide circulation to the skin flap that can be taken with the flap(64).

Initially flap is marked as shown in the diagram and dissection is started to identify the fascia and the perforator vessels are identified. Dissection is continued to reach the interosseous membrane which is divided to reach the fibula. Fibula with the muscle flap, perforator vessel and skin is harvested as a free flap.

Figure 18

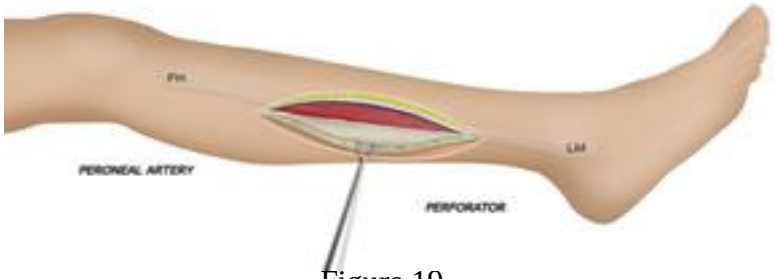

Figure 19

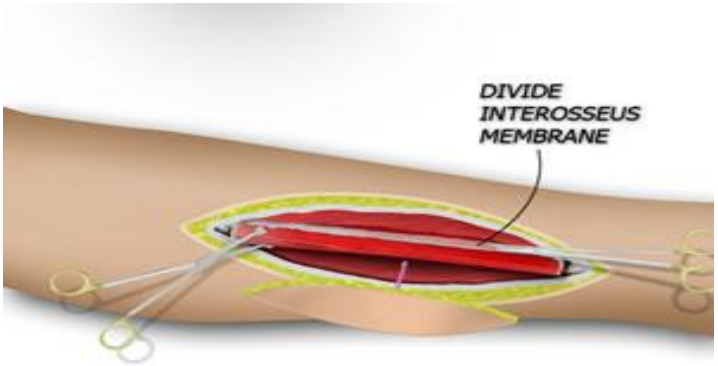

Figure 20

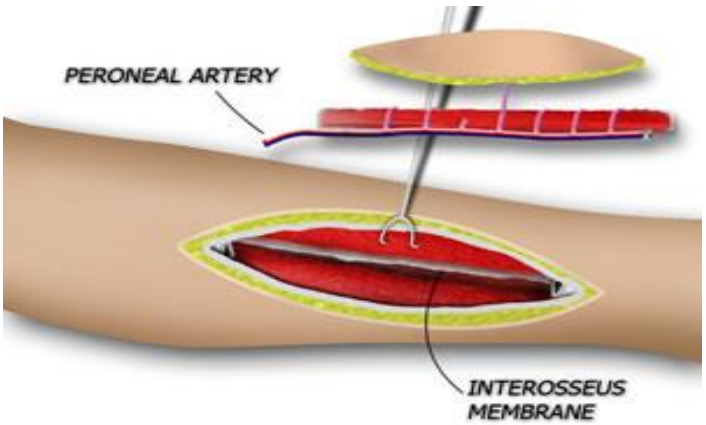

Figure 21: *Adopted from Microsurgeon.org*

Characteristics of Vascularized Fibula free flap(63)**:**

Vascularized Fibula free flap is a composite flap or osteo fascio-myocutaneous based on peroneal vessels. It consists of fibula bone with adjacent periosteum and soft tissue. It can be harvested with or without a skin paddle.

Innervation: Not sensate.

Blood supply: Peroneal artery.

Artery: Large caliber of 1.5 to 4 mm.

Vein(s): Two venae, usually similar in size to the artery. One is often very large.

Pedicle length: The short pedicle can be made longer by dissecting it free of the proximal fibula, and using the distal bone for the reconstruction.

POSTOPERATIVE MONITORING: Since its introduction in the latter part of 1950s, free flap has become the method of choice to reconstruct large defects especially the head and neck lesions. In the past ten years, the success rates of more than 95 percent have been reported for free flaps(65).

Although the success rates are high, microvascular failure remains a costly disaster. As salvage rates have been reported to be inversely proportional to the time interval between the onset of ischemia and its clinical recognition, the monitoring of free flaps remains of major importance. With increased use of protocols, education of the nursing staff and increased education and clinical experience among the trainee postgraduates, improves the quality of postoperative monitoring of the free flaps.

There are many causes for free flap failure. Most commonly postoperative thrombosis of vein or artery causes more than 80% of the flap failure in the early postoperative period(66). However the subtle changes of venous congestion can be picked up by clinical examination of the flap, and in these conditions, there is a need for immediate intervention in terms of decompression or drainage procedures. However if there has been a thrombotic occlusion of the venous anastomosis, it warrants dismantling of anastomosis and redo. In view of inadvertent consequences following flap failure and the morbidity and cost involved, flap salvage has been an area of great interest.

Postoperative monitoring of microvascular free flap monitoring has been the topic of great interest for multiple reasons. The possibility of identification of early features of flap failure both clinically and with the use of gadgets, can reduce the morbidity and cost involved. Monitoring has been divided into Invasive and Non invasive methods.

NON INVASIVE MONITORING:

Non invasive monitoring involves a thorough clinical examination of the free flap using the physical features of the free flap.

CLINICAL EXAMINATION OF THE FREE FLAP:

Clinical monitoring has been the gold standard in monitoring the free flaps for many years and its reliability has been proven through many studies(67).The criteria used for monitoring free flaps are - color, temperature, turgor and texture of the free flap. In few centers capillary refill time has been utilized and pin prick test has also been tried in various studies. Use of additional gadgets like Handheld Doppler, color Duplex Sonography, pulse oxymeter has added an advantage in the successful monitoring of microvascular free flaps(68).

Handheld Doppler Monitoring: Use of Hand held Doppler device for the assessment of vascularity of the free flap has been tried in many studies and proved to be effective. The venous and arterial pulsations are studied separately in this type of monitoring device. The phasicity of the Doppler signals has been utilized to assess the vascularity of the free flap. Absence of flow pattern is the last change to be observed in a free flap. The free flap can be unhealthy in spite of having a normal Doppler signal. Hence Doppler signal alone is not indicative of healthy free flap. Here the clinical features of the free flap need to be correlated with the Doppler signals to make an accurate assessment of the free flap(69)(70).

Color Duplex Sonography: Color Duplex Sonography is a noninvasive monitoring technique that combines the recording of blood flow velocity with the recording of blood flow direction. Combined color flow and spectral Doppler imaging within both flap and recipient vessels enable accurate assessment of anastomotic patency. However the Gold standard for free flap monitoring has been the clinical assessment of the flap. There are many studies to prove the efficacy of the same(71).

INVASIVE MONITORING:

Several invasive monitoring devices have been devised for postoperative monitoring of the microvascular free flaps. Use of Handheld Doppler apparatus to check for the vascularity has been tried foe non invasive monitoring; however implantable Doppler probes have also been under trial and found to be beneficial. The implantable Doppler system, near-infrared spectroscopy and laser Doppler flowmetry appear to be the best invasive monitoring devices currently available. As most of the publications on monitoring have focused on the reliability of the systems, future research should also address their cost efficiency(67).

Implantable Doppler System: The implantable Doppler system is an invasive technique which allows direct and continuous monitoring. This technique was introduced in 1988 by *Swartz et al* in microsurgical reconstructions(8). The system consists of an implantable 20-MHz ultrasonic probe mounted on a silicone cuff that can be wrapped around the vascular pedicle and a battery-operated portable monitor. Different methods have been described to attach the cuff around the vessel, including microclips, sutures and fibrin sealant, all with good results(68). Although earlier studies did not show any increase in detection of vascular cause of free flap compromise using this technique. *Paydar et al* showed that the implantable

Doppler probe is a useful monitoring device in buried free flaps and should be considered for monitoring free flap reconstruction for head and neck(72).

Anastomotic Coupler devices with in-built Doppler Probes: Couplers are devices used in the microvascular anastomosis where they are used in the anastomosis of vessels. It has been studied that couplers are as efficient as hand sewn anastomosis and the operative time can be reduced(73)(59). These couplers can be fitted with sensors with the capacity to detect the flow across the coupler, so that it reflects the turbulence in flow if any and it is an invasive monitoring device.

Based on the study done by *Engel et al*, a study on free flap monitoring using Smartphone photography and 3G wireless internet, the following are the features of a Healthy Flap:

1. Normal flap color is similar to that of the recipient site.
2. The flap should appear pink.
3. Temperature should be similar to temperature of the local area

Features of Flap Failure:

1. Pale relative to the recipient site- *arterial insufficiency*.
2. Shrinking skin turgidity- *arterial insufficiency*.
3. Darker color skin and oozing- *venous insufficiency*.
4. Cooler to touch- *arterial insufficiency*.

TELECOMMUNICATION IN MEDICINE: Recent usage of telecommunications and media in the area of medicine and health sciences has lead to a multitude of monitoring devices for free flap monitoring. This was observed in Taiwan, where they had been monitoring the free flaps using mobile phones and sending the images via internet facility. Due to the location of the consultants far away from the hospital and the need for immediate intervention for flap salvage, an adjunct has been tried to achieve good results so as to monitor the free flaps. With the usage of high definition camera there has been a significant improvement in the flap salvage rates and reliable close monitoring of the free flaps(9).

With the advent of digital camera, the incorporation of high definition camera in mobile phones, capturing the images and storing the data has become more convenient and the increasing usage and knowledge of 3G wireless internet technologies, a new dimension has been attained in the monitoring of free flaps. With the usage of the 3G wireless internet, through messenger system, it's possible and accurate to send the images of the free flap at frequent intervals and appropriate decision can be made regarding free flap monitoring.

Present Knowledge:

A number of research teams across the world have used the evolving technology of smart phones and the wireless internet technology for patient monitoring. A number of published literatures are available especially in the field of free flap monitoring. However, the knowledge of use of Smartphone technology is scarce in the Indian context. India has a cohort of largest mobile phone users in the world, and these resources are widely available and this study is the timely requirement.

Utilization of Smartphone and 3G technology that we propose to use in free-flap monitoring (FFM) will be the first of its kind in India. Hwang JH *et al* from South Korea have reported improved flap survival rate from 92% to 100% through use of FFM using mobile messenger application(71). They concluded that use of such technology will provide better communication and allowed early diagnosis of flap compromise. Similarly, Engel H *et al* reported that high accuracy of pictures provided by the Smartphone photography provided clear picture of the flap status and that it was a safe and reliable technology(9). A systematic review by Smit JM *et al*, that evaluated various approaches to FFM have reported that implantable Doppler, near-infrared spectroscopy, and laser Doppler flowmetry appears to be the best methods for FFM. However, they have clearly expressed their concerns over the high cost of these technologies.

In such a situation, we hope that application of 3G wireless and Smartphone photography will be an affordable alternative to expensive monitoring devices. Also, we would like to build on the hypothesis provided by *Zhang P et al* that the new versions of remote monitoring system can be a powerful supporting tool when doctors who are not in the hospital will make "telediagnosis" for patients to save lives and in our case save 'Free Flaps'. This will lead to early recognition and better utilization of valuable time in saving the free flaps.

AIMS AND OBJECTIVES

AIMS:

1. To study the role of Smartphone photography and 3G wireless technology for monitoring free flap.

OBJECTIVES:

1. To study the feasibility of Smartphone photography in free flap monitoring.
2. To study the feasibility of Smartphone photography and 3G wireless internet technology in monitoring free flaps.

MATERIAL AND METHODS

Following Institutional Review Board approval, after obtaining an informed consent from the study participants we conducted the study from January 2013 to September 2014.

Inclusion Criteria:

All adult patients (age more than 18 years) with oral cancer, undergoing micro vascular free flap reconstruction with visible skin paddle, for post excisional defects were included.

Only patients with fasciocutaneous or myocutaneous free flaps were included.

Exclusion Criteria: Patients who did not consent and free flap sites which were not readily visible and deep seated in the oral cavity were excluded from the study.

Methods: The team included three surgeons, a head and neck nurse, the principal investigator and the team of postgraduate students in the surgical unit of head and neck. In the unit, free flaps were monitored by the postgraduate registrar with clinical observation. The clinical parameters considered were the color, warmth, skin texture of the free flap and Doppler flow signals using a handheld Doppler apparatus, to look for the venous and arterial signals. The existing protocol for monitoring the free flap was adopted. Free flap was monitored every half an hourly for the first 2 hours, every hourly for the next 2 hours and every 2 hourly for the next 24 hours and then every 6th hourly for the next 96 hours, for a total monitoring period of 120 hours postoperatively. The photographic monitoring of the free flaps was done at 6 hourly intervals for 120 hours of flap survived or till the time of re-exploration. All patients who underwent a microvascular free flap reconstruction for a defect in the oral cavity were shifted to the Surgical Intensive Care Unit for postoperative

monitoring. The patients were observed for 6-8 hours in the ICU after the extubation and then shifted to the general ward. The hematocrit was maintained between 27-29%, and was monitored 8 hourly.

The Operating Surgeon (OpS) was designated as the main person making a decision on re-exploration who would receive the details of clinical monitoring of the free flap and get the images of the free flap at pre determined time intervals. The registrar would photograph the flap and send it to the Operating (OPS) and Observing Surgeon 1 (ObS1), via 3G wireless Smartphone technology. The Observing Surgeon 1 (ObS1) received only the free flap photographs and he was blinded to the clinical parameters of the free flap. The Observing Surgeon 2 (ObS2) monitored the clinical characteristics of the flap but with no photographs of the free flap. The three arms, OpS, ObS1 and ObS2, were communicated to Principal Investigator (P.I) and the differences from the three arms were compared with the tabulation of the observation. In case of early features of flap failure, the time required to make a decision on intervention and to salvage the flap was compared between the three arms. The aim was to analyze if the photographs act as an adjunct to clinical monitoring of the free flaps.

Comparison between OpS and ObS1 was done to look for the use of photographs alone can be used as a monitoring tool. Comparison between OpS and ObS2 was made to see if clinical monitoring alone is sufficient in decision making. A standardized color card was used for comparison and to maintain uniformity of the photos taken at regular intervals.

METHOD OF PHOTOGRAPHY:

The standardized color card was used in the frame of the photograph with white balancing and the in-built flash. An external light source was not used. The subject occupied two third of the frame with the color card at one side to compare the exposure quality on serial photographs.

PHOTOGRAPHIC ASSESSMENT OF FREE FLAPS USING THE FOLLOWING CRITERIA (HAVU)*

H- Healthy: Pink, full.

A- Arterial insufficiency: Pale and shrinking skin turgor.

V- Venous insufficiency: Darker color skin and oozing

U- Uninterpretable: Blurred picture, loss of focus.

In this study, we had criteria (HAVU Criteria) for the assessment of the photographs of free flaps, which we named it as HAVU, of which H stands for Healthy flap, which is pink in color and the texture is full. A stands for Arterial insufficiency, where in the flap looks pale, shrinking. V indicates venous insufficiency where in the flap was bluish, darker, surface oozing or edematous with a dull color. U stands for Uninterpretable, where the photograph was not clear to be interpreted, with blurred or had loss of focus. (If multiple photographs were uninterpretable, it was advised to take a different photo and send it). The photographs were sent using Whatsapp® messenger system, for instant delivery using 3G Internet facility. The team was expected to reply instantaneously and a decision was made using the assessment criteria, HAVU. Any deviation from the normal and clinically significant, plan was made regarding further management of the free flap. The final decision on flap re-

exploration was made by the operating surgeon and the team abided by the policy. The clinical characteristics namely the color, turgor, warmth and the Doppler signals using a handheld Doppler were assessed at pre determined intervals.

Two Smartphone were used in this study, Sony Xperia C® and Nokia Lumia 720®. Based on the availability and cost effectiveness, the study made use of these Smartphone for capturing the photographs of the free flaps and to transmit them using 3G Internet.

Sony Xperia C® has a camera with 8MP capacity with 3264x2448 pixels, autofocus and LED flash. It has a display screen of 141.5x74.2x8.9mm and weighs 153grams. The storage capacity has an internal storage capacity of 4GB, with 1GB RAM and expandable up to 32GB. The 3G compatibility has been good and the battery durability was up to 14 hours(74).

Sony Xperia C®

Nokia Lumia 720® is a type type of Smartphone which has was chosen for communication to the operating surgeon (OPS). It has the following features which fulfilled the study requirements. It has a camera of 6.7 MP capacity, with autofocus and LED flash. The storage capacity was internal storage capacity of 8GB with 512 MB RAM and expandable up to 64 GB. It has a good 3G compatibility. The battery life was 13.4 hours(75)(76).

Nokia Lumia 720®

WhatsApp® is a messenger system WhatsApp Inc. is an early stage technology startup founded in the heart of Silicon Valley. The term *WhatsApp* is based on "*What is up*". WhatsApp Messenger is a cross-platform mobile messaging application which allows exchange of messages without having to pay for SMS. WhatsApp Messenger is available for all Smartphone and those phones can all message each other. Because WhatsApp Messenger uses the same internet data plan that is used for email and web browsing, there is no cost to message and stay in communication. In addition to basic messaging, WhatsApp helps in creating groups, send each other unlimited images, video and audio media messages(77)(78). A working group was created for the purpose of the study which included: Principal Investigator (P.I), Operating Surgeon (OPS) and Observing Surgeon 1 (ObS 1).

WhatsApp® has been used in this study as a mode of communication due to the ease, user friendliness and the capability to store and transfer data with ease, in a cost effective way(79). The security and confidentiality of data transferred using this messenger system has been appreciated and considered safe(77).

Figure 22

Figure 23

STANDARDIZED COLOR CARD

A standardized color card was used for comparison of consecutive photographs and to help in grading the photographs maintaining a uniformity in the photographs(9) . The standardized color card was incorporated in all the photographs for better comparison and to avoid confusion. Although there was a debate on the complexion of the patient and the use of different form of color card with different shade, however there was no confusion as the

comparison was among the photographs of the same patient. Use of standardized lighting and flash settings in the camera, it was possible to minimize ambiguity(9).

METHOD OF PHOTOGRAPHY

A standardized color card was used in the frame of the photograph with white balancing and the in-built flash.

There was no external light source being used.

The subject occupied two-thirds of the frame with the color card at one side of the photograph to compare the exposure quality on serial photographs.

SERVICE PROVIDER:

For the transmission of the data Vodafone® 3G services was chosen as a mode of communication, based on the hospital network and the signal strength across the campus. There was an internal survey conducted by the principal investigator with regard to the ready access to network and the availability of network signals within the hospital campus and the residential area. It was compared with the cost effectiveness of availing the 3G internet facility compared with other service providers.

3G INTERNET SERVICE:

3G internet service was started worldwide in 1998. 3G is a short form of third Generation; it is the third generation of mobile telecommunications technology. This is based on a set of standards used for mobile devices and mobile telecommunications use services and networks that comply with the International Mobile Telecommunications-2000 (IMT-2000) specifications by the International Telecommunication Union. 3G finds application in

wireless voice telephony, mobile Internet access, fixed wireless Internet access, video calls and mobile TV(80).

3G telecommunication networks support services that provide an information transfer at a rate of at least 200 Kbit/s. Later 3G releases, often denoted 3.5G and 3.75G, also provide mobile broadband access of several Mbit/s to Smartphone and mobile modems in laptop computers also. This ensures it can be applied to wireless voice telephony, mobile Internet access, fixed wireless Internet access, video calls and mobile TV technologies.

A new generation of cellular standards has appeared approximately every tenth year since 1G systems were introduced in 1981 to 1982. Each generation is characterized by new frequency bands, higher data rates and non–backward-compatible transmission technology. The first 3G networks were introduced in 1998 and fourth generation "4G" networks in 2008.

3G networks offer greater security than their 2G predecessors. By allowing the UE (User Equipment) to authenticate the network it is attaching to, the user can be sure the network is the intended one and not an impersonator. 3G networks use a technology which ensures safety to the users. This has made it popular and laid to the modifications including 4G(80).

A REPRESENTATIVE CASE OF FREE FLAP MONITORING USING 3G WIRELESS INTERNET FOR 120 HOURS.

PATIENT WHO HAD A COMPROMISED FREE FLAP

A case of squamous cell carcinoma of right lateral border of tongue underwent wide local excision and reconstruction with radial artery forearm free flap. The clinical monitoring was done as per schedule and photographs were taken every sixth hourly. On the second post-operative day, there was blue discoloration at the tip of the free flap as shown in the photograph. This was noticed by the Operating Surgeon (OPS) and the Observing Surgeon 1 (ObS 1) and the Principal Investigator (P.I). Doppler signals were good and there was swelling over the flap and bulge as well. Decision was made by the OPS on re-exploration.

Intra-operatively there was thrombosis at the venous anastomosis, arterial anastomosis was intact. The venous anastomosis was taken down and re-anastomosis was done to the internal jugular vein.

At six hours (H)

At eight hours (V)

At Twelve hours (V)

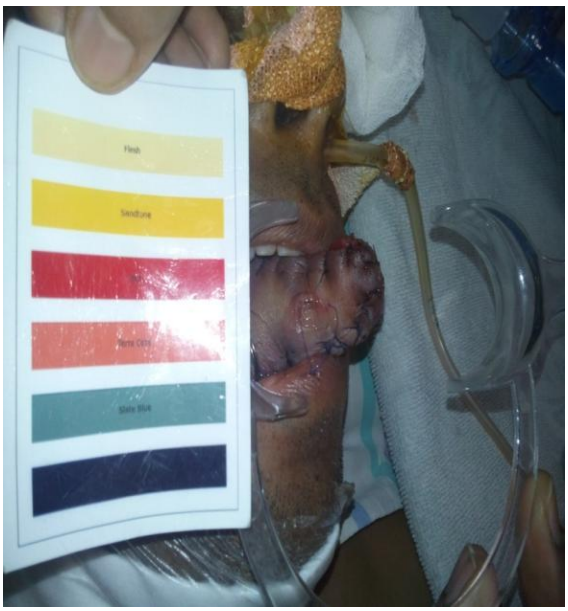

after re-exploration (H)

IDENTIFICATION OF NECK SWELLING ON PHOTOGRAPHY:

It was intended to include the side of the neck along with the photograph of the free flap but owing to the presence of large dressing over the neck, it was difficult to interpret these photographs. Hence these photographs were not included in the photographic free flap monitoring. Illustration of such a photograph has been shown in the photograph below. Identification of the neck swelling was better with thorough clinical examination, noticing induration, pitting edema and fluctuation on palpation.

PHOTOGRAPHS SHOWING HEALTHY FREE FLAP AT VARIOUS TIME INTERVALS POST OPERATIVELY:

DAY 1 (0 TO 24 HOURS)


DAY 2 (UPTO 48 HOURS)

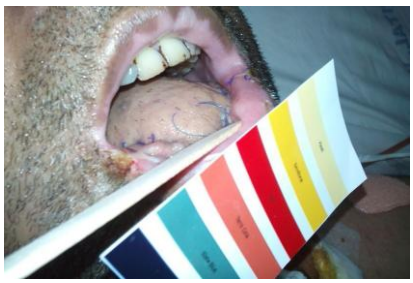


DAY 3 (UPTO 72 HOURS)


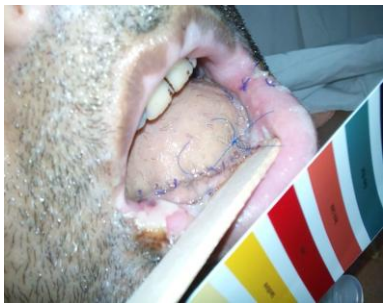

DAY 4 (UPTO 96 HOURS)

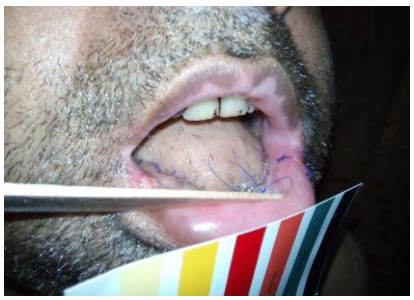
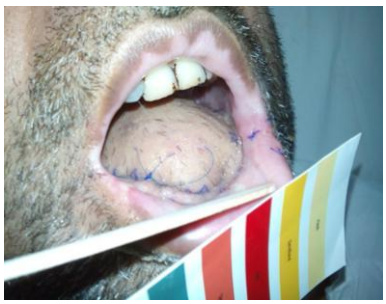

DAY 5 (UPTO 120 HOURS)


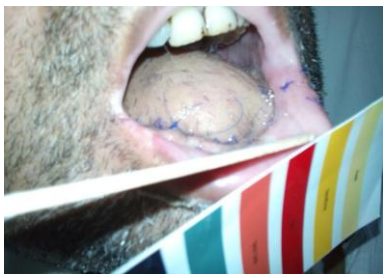

PHOTOGRAPHS OF HEALTHY FREE FLAP AT VARIOUS TIME INTERVALS POST OPERATIVELY:

DAY 1

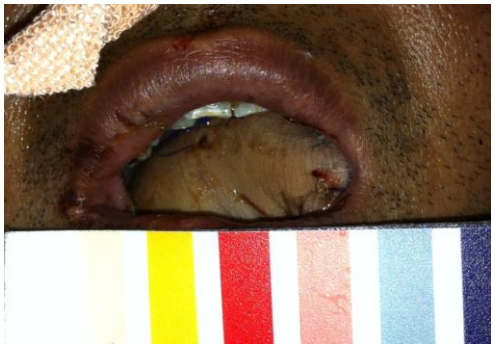

DAY 2

DAY 3

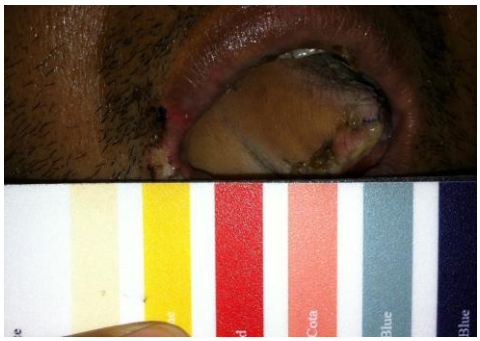

DAY 4

EXAMPLES OF PHOTOGRAPHS WITH UNINTERPRETABLE IMAGES :

RESTRICTED MOUTH OPENING WITH A HIDDEN FLAP: UNINTERPRTABLE

IMPROPER LIGHT ADJUSTMENTS: UNINTERPRETABLE

COLOR CARD NOT INCLUDED IN THE PHOTOGRAPH: UNINTERPRETABLE.

NECK COVERED BY DRESSING: UNINTERPRETABLE.

RESULTS AND ANALYSIS

There were a total of 18 cases from November 2012 to September 2014. The analysis of diagnosis of free flap failure, with the use of photographs was compared to the assessment by clinical monitoring alone. Inter-observer variability and the number of agreements in their assessments of the free flap were analyzed. Among the total of 18 cases, we had to explore 5 cases, four of which had neck hematoma which was evacuated. These 4 patients had a swelling in the neck, which was a hematoma and there were no features of free flap failure. Evacuation of the hematoma was done and vascularity of the free flap was healthy. The other patient, there were features venous congestion and the flap had turned blue, which was picked up by clinical examination and also by the interpretation of photographs. Plan was made on re-exploration of the free flap, suspecting venous thrombosis. This observation was picked up by the photograph and both the operating surgeon and observing surgeon agreed with their findings. The flap was re explored immediately and venous anastomosis had thrombosis which was dismantled and re anastomosis was done and the flap was successfully salvaged.

There were 360 total assessments made by the OPS and 360 by the ObS1. By the analysis of the study data, in 45.27% of assessments, there was agreement between the two surgeons.

The rate of re-exploration was 5/18= 27.78% and there was no free flap failure.

There were 4 cases where re-exploration was done for a neck hematoma; however they did not have loss of vascularity or any changes with respect to the free flap. These changes were not picked up by the assessments based on photographs. The early pick up rates were better with the clinical monitoring where the free flaps did not have vascular compromise. However there was one case where there was venous thrombosis and it was diagnosed by clinical and photograph assessments. Hence our success rate was 100%. Overall free flap salvage rate was 100%.

Demographic Profile		Results
Age (Mean, SD)		47.5(+/-11.5)
Sex	Male (%)	n=13(72.22%)
	Female (%)	n=5(27.78%)
Education	Illiterate (%)	n=1(5.56%)
	Primary (%)	n=3(16.67%)
	Graduates (%)	n=14(77.78%)
Occupation	Farmer	n=5(27.78%)
	Businessman	n=4(22.22%)
	Housewife	n=4(22.22%)
	Engineer	n=1(5.56%)
	Doctor	n=1(5.56%)
	Nurse	n=1(5.56%)
	Tailor	n=1(5.56%)
	Barber	n=1(5.56%)
Smoking		n=7(39%)
Tobacco use		n=9(50%)
Co-morbidities		n=7(39%)
PCV		34.1(+/-7.37)
Creatinine		0.913(+/-0.28)
RBS		109(+/-22)

TABLE NO.1

The study included all patients above the 18 years age presenting with oral cavity malignancy who have undergone microvascular free flap flap reconstruction for post-excisional defects.

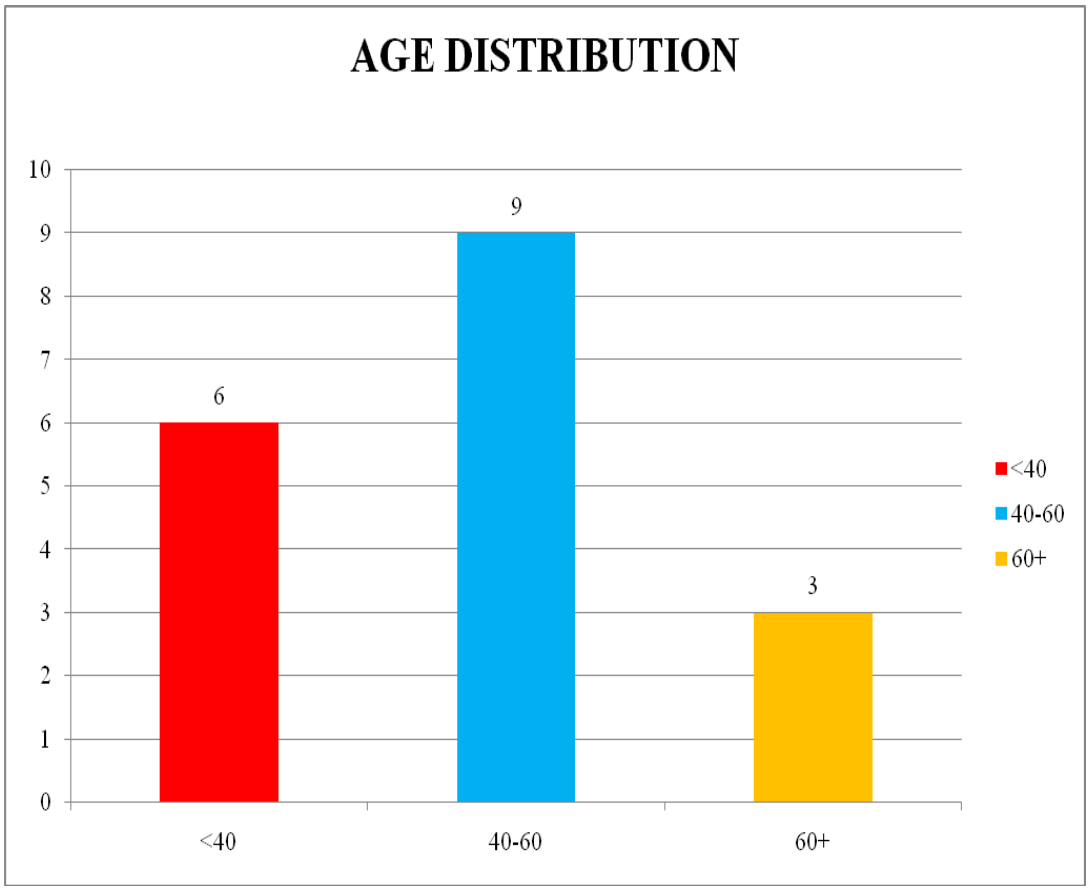

Figure No.24

Out of the 18 patients included in this study, 9 were between 40 to 60 years age, 6 were younger than 40 years and 3 were above 60 years age.

SEX DISTRIBUTION

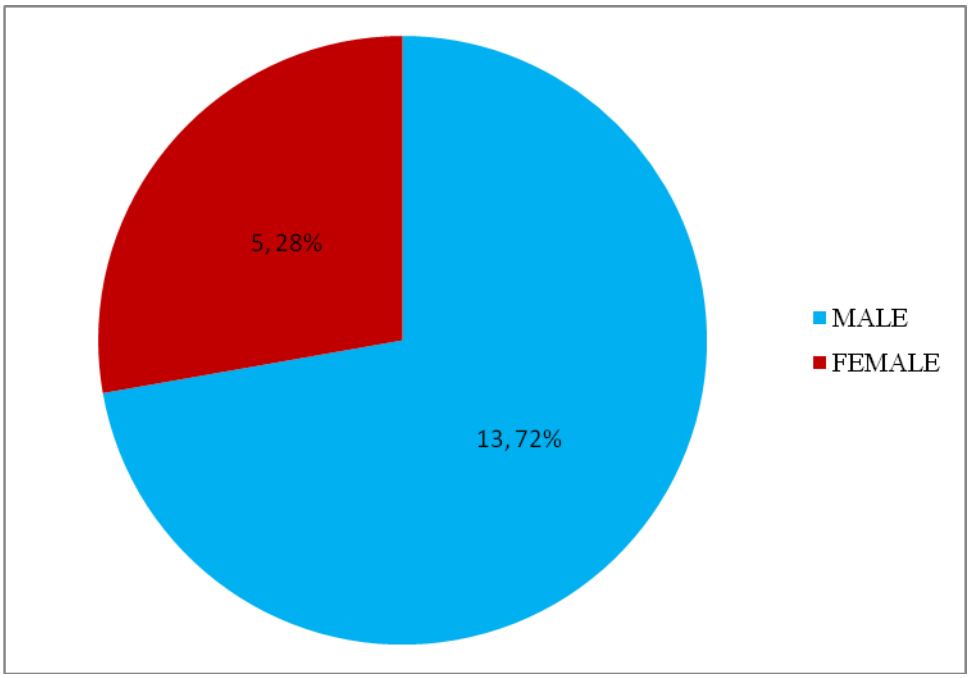

Figure No.25

Out of 18 patients studied, 13 were male and 5 were females. Hence it accounted for 72% of males and 28% females, as shown in the pie chart and table(No.).

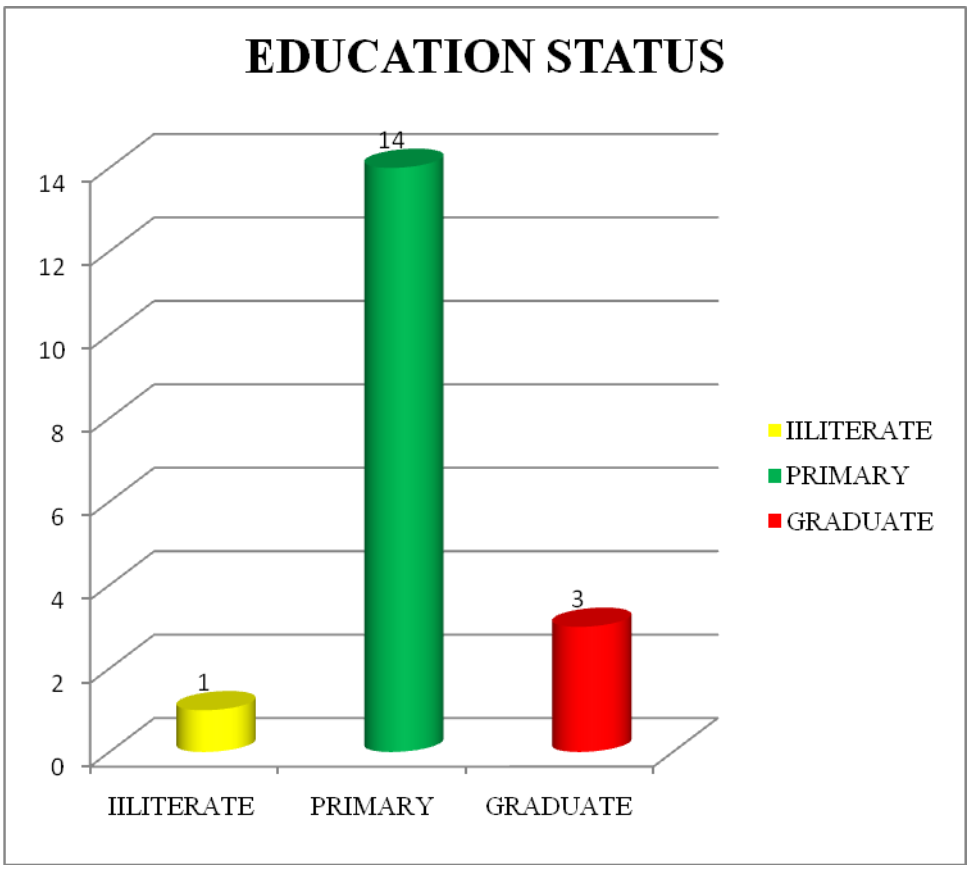

Figure No.26

In this study data, 14 out of 18 patients had studied till Primary school, 3 were graduates and 1 was an illiterate. The same has been shown with details in the table (No.)

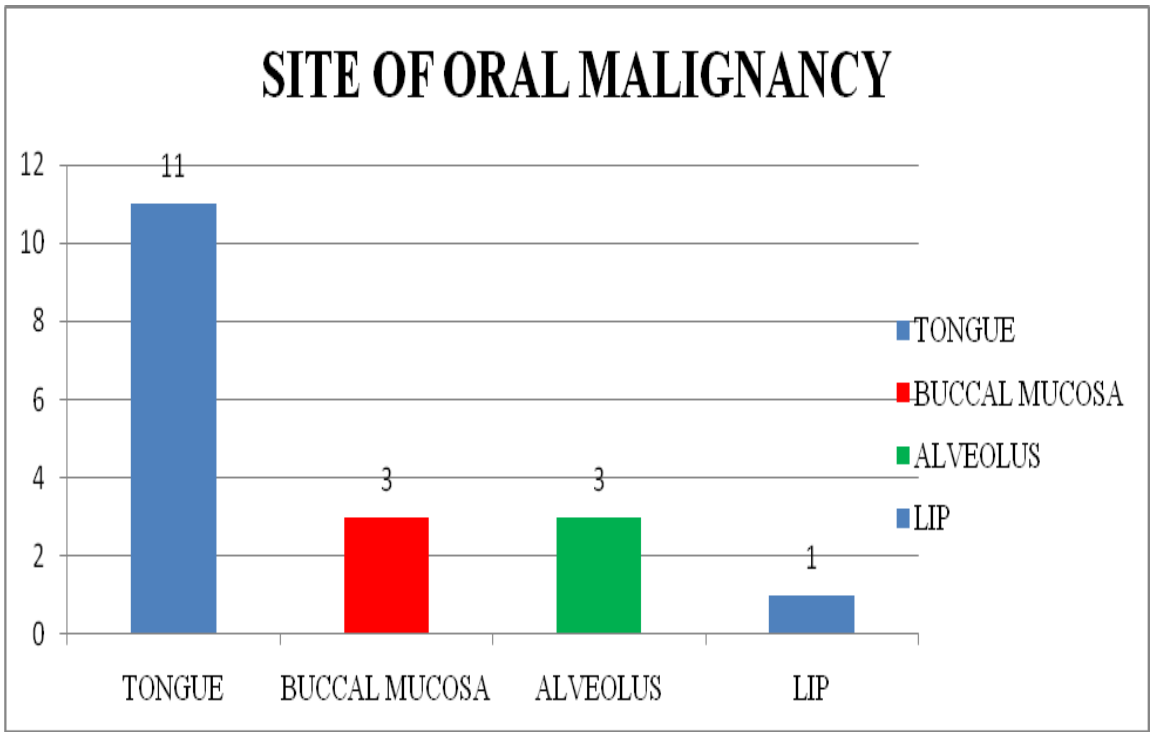

Figure No.27

In this study, the distribution of tumors has been shown in the above chart.11 cases had carcinoma tongue, who underwent wide local excision with or without neck dissection. This corresponds to the type of excision, where majority were wide local excision (15/18 cases). Carcinoma of alveolus were seen in 3 cases, who had underwent composite resection (3/18 cases).

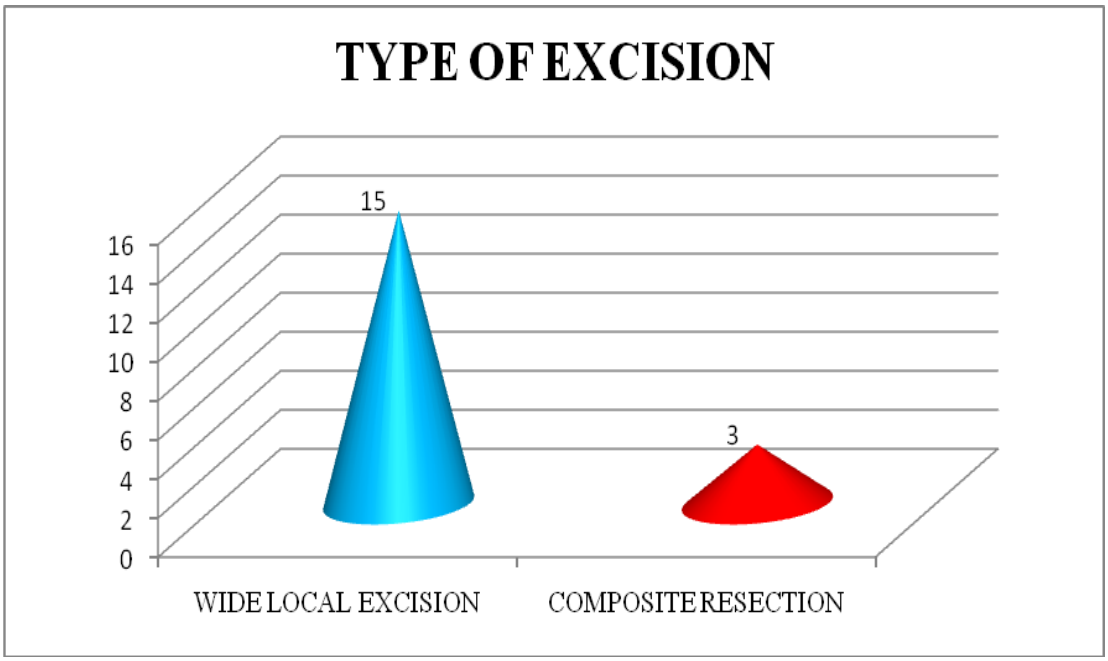

Figure No.28

Wide local excision involves the soft tissue including the tumor and 1.5 to 2cms from the induration. It usually does not include the excision of bone. This applies to the tumors involving buccal mucosa, tongue and lips.

Composite resection involves removal of the tumor with a margin of 1.5 to 2cms from the induration, involves removal of bone and the adjacent soft tissue structures for Oncological clearance. This applies to the surgeries on floor of mouth, alveolar margin of the oral cavity.

TYPE OF FREE FLAP RECONSTRCUTION

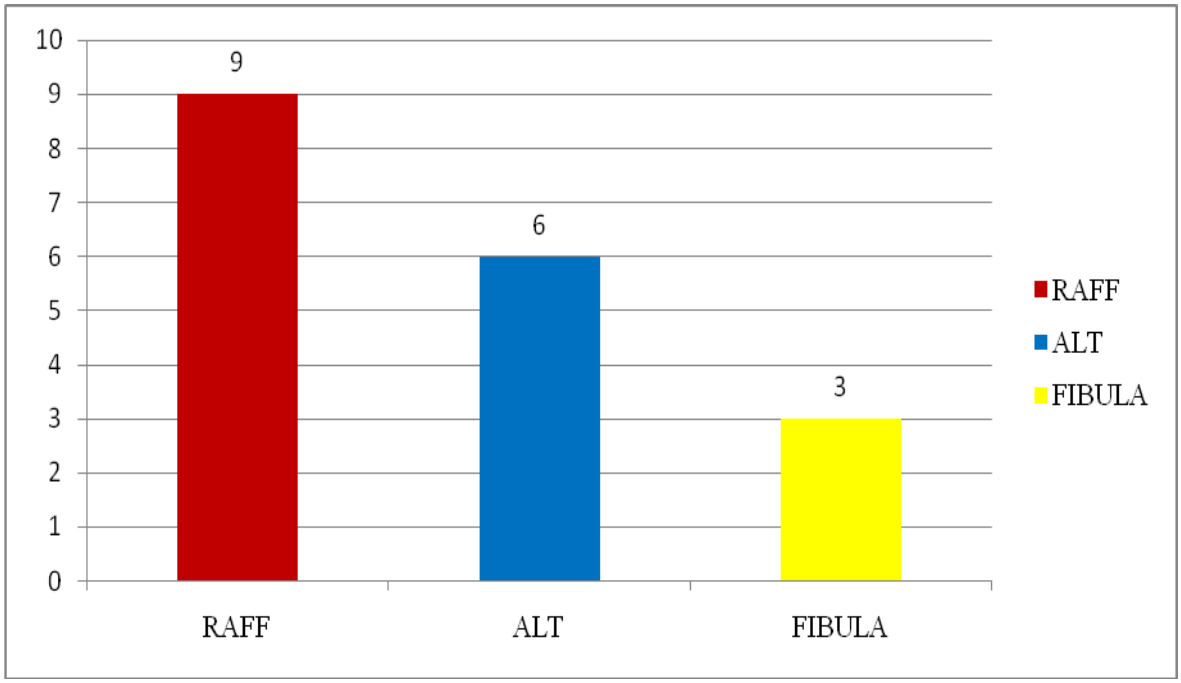

Figure No.29

Among the 18 free flap reconstructions observed during the study period,9 were radial artery forearm free flap(RAFF), six were anterolateral thigh flap(ALT) and three were fibula vascularized free flap.

Fibula free flaps are used when there has been a bony defect and needs to be stabilized by an osteomyocutaneous flap.

DISCUSSION

A prospective study was done in the department of Surgery I- head and neck oncosurgery, CMC, Vellore, between November 2012 to September 2014 to recruit 18 patients requiring microvascular free tissue transfer for the reconstruction of post-excisional defects following oral cancer extirpation. In this group of patients, the incidence of tobacco use was 50% and smoking was 39%. A majority of patients were below the age of 60 years and males. In this study, carcinoma of the tongue was the commonest subsite involved and fasciocutaneous tissue transfer was the commonest mode of reconstruction especially radial artery forearm free flap was the commonest. Patients were clinically monitored using color, turgor, temperature, capillary refill and vascularity of the free flap was assessed using a handheld Doppler device. In addition, the main focus of the study was to explore the utility of Smartphone Photography and 3G Internet as an adjunct to free flap monitoring. The photographs were transferred to the operating surgeon (OPS) and an independent surgeon, the observing surgeon 1(ObS1). There was 45.27% concurrence in the opinion of the two surgeons. But the assessment done by the OPS correlated with the independent clinical assessments by a third consultant, the observing surgeon 2(ObS2) was 78%.

In this study, there was no free flap failure. However, the re-exploration rate was 27.78%. In one patient, the impending venous thrombosis was identified on photography as well as on clinical examination, which was subsequently confirmed intra-operatively as venous thrombosis thus giving a success rate of 100% of identifying impending free flap failure.

Cannady et al analyzed patients with Head and Neck malignancies requiring reconstruction and the choice of Microvascular free tissue transfer in such patients. There was an increasing incidence of head and neck cancer in the general population and the number of patients with

such tumors who require reconstruction with microvascular free flap. The number of recent advances in the field of Head and neck reconstruction, surgical planning has been studied. Advanced computer algorithms allowed planning of these procedures, saving time and cost. Free tissue transfer is a reconstructive modality at the top of the reconstructive ladder and in many cases; it is the reconstructive method of choice giving way to the concept of reconstructive elevator. The advantage of harvesting composite tissue to match the tissue defect in composition, surface area, and bulk makes free tissue transfer superior modality, due to its versatility(81).

Bucur et al (2005) studied that, with advances in the plastic and reconstructive surgery and the use of wide variety of free and pedicled flap for the reconstruction of defect, better oncological clearance has been achieved in head and neck malignancies. Microvascular free tissue transfer has a very important impact in the field of head and neck reconstruction. These reconstructive techniques have extended the extirpative limits of resection in head and neck malignancies, facilitating complex reconstruction of defects with very high success and it is associated with minimal patient morbidity(82). Although its impact on disease cure rates and survival statistics has yet to be analyzed, it has proven invaluable in the palliative resection in patients with advanced malignancies.

Lydiatt et al studied the reconstructive options for head and neck malignancies and it was concluded that the microvascular free tissue transfers made the reconstruction of major head and neck defects possible that were considered impossible. It also improved the function and cosmesis in patients with major head and neck malignancies. It was observed that a successful reconstruction requires good co-operation between the head and neck surgeon and the plastic and reconstructive surgeon. It was observed that microvascular free tissue transfer

has an important role in the treatment of patients with head and neck malignancies, and on-going modifications in these techniques will open new avenues for the reconstructive surgeons in the future(82)(83)(84).

Mao et al analyzed a total of 545 free flaps from 1999 to 2002 done for the reconstruction of head and neck defects. In this study, free fibula flap was most commonly used, followed by free radial forearm flap, rectus abdominis flap, jejunum flap, scapular flap, iliac crest flap, latissimus dorsi flap, and anterolateral thigh flap. The overall success rate was 98.2%. The overall complication rate was 25.2%. The vessel thrombosis rate was 4.8%, and the flap salvage rate was 61.5%(85).

Another study done in 2012 done by *Bianchi et al* on reconstruction of Head and neck defects, the flap survival rate was 97.8%. Donor site morbidity consisted of two cases of partial necrosis of the skin graft used its closure with a final donor site complication rate of 2.2%. Overall results showed an 89% of patients returned to a normal or a soft diet. Speech was good or intelligible in 88% and cosmesis resulted good or acceptable in 89% of cases (86).

Methods of free flap monitoring have been classified into invasive and non-invasive methods. The non–invasive methods include clinical monitoring including monitoring of the physical features namely the color, turgor, temperature, capillary refill and the vascularity of the free flap using a handheld Doppler device. From the earlier studies worldwide, it has been established that clinical monitoring of the free flaps is the gold standard for the assessment of free flap status(46) (68)(69).

Agha et al studied the used of implantable Doppler Probes- Cook Swartz type of implantable Doppler in the free flap monitoring but the final results are yet to be confirmed(8). Similarly, *Um GT et al* in 2014 also did not find any statistically significant difference in detection of flap failures using implantable Doppler probe of venous coupler devices(87).

Guillemaud et al in 2008 had concluded that the use of Cook Swartz type of implantable Doppler probe allowed recognition of vascular compromise early, with overall flap success rate of 98.1%, with a 92.0% salvage rate of flaps in head and neck reconstruction(88).

With the advent of newer methods of free flap monitoring and incorporation of technology in free flap monitoring, it has been more effective, accurate and less time consuming. Smartphone photography and communication of data using 3G Internet, has been used and proven to be a newer, easier and efficient method of free flap monitoring by *Engel et al*. In this study 103 free flaps were studied with in-person and by photographic assessments. The accuracy rate was 98.7% and 94.2% for in-person and Smartphone photographic assessments, respectively. The reduction in flap failure rates was compared. It has been tested and proven to be comparable to in-person assessments in many large scale centers specialized in microvascular reconstruction techniques(9)(71).

With the advent and incorporation of 3G Internet technology in this study minimized the time required to transmit data. Earlier studies utilized internet to transfer the data, however there was a delay during uploading and then transmission of data. 3G Internet technology has reduced this delay and has fastened the process of data transfer(71).

Current study utilized the use of Smartphone photography and 3G Internet technology for postoperative monitoring of free flaps. It was proved that Smartphone photography and 3G Internet technology act as an adjunct to clinical monitoring of free flaps. It has been compared with clinical monitoring (gold standard for free flap monitoring), which did not show any superiority of this technique. However it has an advantage in being non-invasive, easy, quick and reliable. It has been found to be user-friendly as well as patient friendly.

Analysis of photographs has been almost uniform and there has been very minimal Inter-observer variation in the assessment of the photographs. It has been found that there was agreement between the assessments of the Operating Surgeon (OPS) and the Observing Surgeon 2(ObS2) in this study, which proved the effectiveness of the use of Smartphone photography and 3G Internet to communicate the data. Also the inter-observer variability was also minimal and the agreements between Operating Surgeon (OPS) and Observing Surgeon 1 (ObS1) were good. It has been observed and analyzed that this method can be used as an adjunct to clinical monitoring of microvascular free flaps.

LIMITATIONS OF THE STUDY

As proposed in the study methodology, it was theorized that all the abnormalities will be picked up by photographs of the free flap. However, in this review it was evident that 80% of the re-explorations were done even before flap vascularity was compromised. This was possible because of the close and careful clinical monitoring of the free flap and the neck wound of these patients. Initially at the beginning of the study, this consideration was given to include photograph of the side of the neck along with the free flap photograph, but owing to the presence of dressings in the postoperative period, it was assumed that the interpretation will be non-uniform hence it was not included as a part of routine photograph monitoring.

Induration and collection (hematoma) in the neck are clinically differentiated by pitting edema, fluctuation and with the help of diagnostic modality with an ultrasonography of the neck. These findings cannot be ascertained on visual inspection and hence clinical photography.

There was inconsistency in capturing the photographs at the predetermined time, due to the system of rotation of the registrars in different surgical units and different timing and type of working. Due to this reason, there was a modification in the design where the registrar posted in the unit of head and neck was taking the photographs, instead of the Principal Investigator (P.I) as originally conceived. Clinical photography being a skill has a learning curve and at times, certain photographs were uninterpretable due to this reason. There were a significant number of instances where there were network errors causing delay in the transmission the photographs. These were due to technical reasons.

Other instances when any one of the surgeons was on leave or out of the reach of the network, there was a delay in the responses for few of the photographs. When the surgeons were busy operating (OPS, ObS1 or ObS2), few of the responses on some photographs were missed. There were instances where there was no response from the surgeons (OPS or ObS), and inter-observer analysis could not be done, hence such assessments were excluded.

Since the sample size was small, the number of assessments and the result may be extrapolated to general population with caution. Further study with more number of case studies are warranted for better interpretation of results.

RECOMMENDATIONS

- This method of Smartphone and 3G wireless internet technology needs to be incorporated to the existing clinical monitoring protocols for free flap monitoring.

- A dedicated person may be identified to take the photographs with a short skills training course in basic clinical photography to avoid inter-personnel variation.

CONCLUSION

- Smartphone technology and 3G wireless Internet technology was able to define its role in the monitoring of free flaps performed for post-excisional defects for oral cancers.
- The quality of Smartphone cameras has improved by leaps and bounds in the recent years. Smartphone photography for clinical assessment of free flap in the early postoperative period is feasible with minimal training and short learning curve.
- When combined with Smartphone Photography, 3G wireless Internet technology greatly enhanced its reach and ability to be interpreted by an experienced clinician even without physically examining the patient in person.
- This is further aided by the cross platform applications like WhatsApp®, which utilized a narrow bandwidth for data transfer without significant drop in the image quality almost instantaneously.
- With the current data it can be concluded that the use of Smartphone photography and 3G wireless internet technology in free flap monitoring acts as an adjunct to detect early free flap compromise in cases of post-excisional defects in oral cavity malignancy and this method of free flap monitoring has been helpful for the salvage of the free flaps. It was convenient, easy, quick, patient and user friendly and non invasive.

BIBLIOGRAPHY

1. Mehrotra R, Singh M, Gupta RK, Singh M, Kapoor AK. Trends of prevalence and pathological spectrum of head and neck cancers in North India. Indian J Cancer. 2005 Jun;42(2):89–93.

2. Yeole BB, Sankaranarayanan R, Sunny M Sc L, Swaminathan R, Parkin DM. Survival from head and neck cancer in Mumbai (Bombay), India. Cancer. 2000 Jul 15;89(2):437–44.

3. Sankaranarayanan R, Masuyer E, Swaminathan R, Ferlay J, Whelan S. Head and neck cancer: a global perspective on epidemiology and prognosis. Anticancer Res. 1998 Dec;18(6B):4779–86.

4. Elango JK, Gangadharan P, Sumithra S, Kuriakose MA. Trends of head and neck cancers in urban and rural India. Asian Pac J Cancer Prev APJCP. 2006 Mar;7(1):108–12.

5. Hashibe M, Brennan P, Chuang S-C, Boccia S, Castellsague X, Chen C, et al. Interaction between tobacco and alcohol use and the risk of head and neck cancer: pooled analysis in the International Head and Neck Cancer Epidemiology Consortium. Cancer Epidemiol Biomark Prev Publ Am Assoc Cancer Res Cosponsored Am Soc Prev Oncol. 2009 Feb;18(2):541–50.

6. Fujimaki M, Fukumura Y, Mitani K, Kurisaki A, Yokoyama J, Ikeda K, et al. Histological subtypes and characteristic structures of HPV-associated oropharyngeal carcinoma: study with Japanese cases. Diagn Pathol. 2013;8:211.

7. D'cruz A, Lin T, Anand AK, Atmakusuma D, Calaguas MJ, Chitapanarux I, et al. Consensus recommendations for management of head and neck cancer in Asian countries: a review of international guidelines. Oral Oncol. 2013 Sep;49(9):872–7.

8. Agha RA, Gundogan B, Fowler AJ, Bragg TWH, Orgill DP. The efficacy of the Cook-Swartz implantable Doppler in the detection of free-flap compromise: a systematic review protocol. BMJ Open. 2014 Mar 1;4(3):e004253.

9. Engel H, Huang JJ, Tsao CK, Lin C-Y, Chou P-Y, Brey EM, et al. Remote real-time monitoring of free flaps via smartphone photography and 3G wireless Internet: a prospective study evidencing diagnostic accuracy. Microsurgery. 2011 Nov;31(8):589–95.

10. Guru K, Supe S, Manoor U. A comprehensive review of head and neck cancer rehabilitation: Physical therapy perspectives. Indian J Palliat Care. 2012;18(2):87.

11. WHO | Data and statistics [Internet]. [cited 2012 Sep 21]. Available from: http://www.who.int/research/en/

12. Sridharan G. Epidemiology, control and prevention of tobacco induced oral mucosal lesions in India. Indian J Cancer. 2014 Mar;51(1):80–5.

13. Joseph AW, D'Souza G. Epidemiology of human papillomavirus-related head and neck cancer. Otolaryngol Clin North Am. 2012 Aug;45(4):739–64.

14. Neville BW, Day TA. Oral cancer and precancerous lesions. CA Cancer J Clin. 2002 Aug;52(4):195–215.

15. Grajewski S, Groneberg D. [Leukoplakia and erythroplakia--two orale precursor lesions]. Laryngorhinootologie. 2009 Oct;88(10):666–72; quiz 673–5.

16. Grajewski S, Quarcoo D, Uibel S, Scutaru C, Groneberg D, Spallek M. [A scientometric analysis of leukoplakia and erythroplakia]. Laryngorhinootologie. 2010 Apr;89(4):210–5.

17. Melrose RJ. Premalignant oral mucosal diseases. J Calif Dent Assoc. 2001 Aug;29(8):593–600.

18. More Y, D'Cruz AK. Oral cancer: review of current management strategies. Natl Med J India. 2013 Jun;26(3):152–8.

19. Koch WM, Lango M, Sewell D, Zahurak M, Sidransky D. Head and neck cancer in nonsmokers: a distinct clinical and molecular entity. The Laryngoscope. 1999 Oct;109(10):1544–51.

20. Thiagarajan S, Nair S, Nair D, Chaturvedi P, Kane SV, Agarwal JP, et al. Predictors of prognosis for squamous cell carcinoma of oral tongue. J Surg Oncol. 2014 Jun;109(7):639–44.

21. Brandwein-Gensler M, Smith RV. Prognostic Indicators in Head and Neck Oncology Including the New 7th Edition of the AJCC Staging System. Head Neck Pathol. 2010 Feb 6;4(1):53–61.

22. Neligan PC. Head and neck reconstruction. Plast Reconstr Surg. 2013 Feb;131(2):260e – 269e.

23. Santamaria E, Granados M, Barrera-Franco JL. Radial forearm free tissue transfer for head and neck reconstruction: versatility and reliability of a single donor site. Microsurgery. 2000;20(4):195–201.

24. Millard DR. Embryonic rationale for the primary correction of classical congenital clefts of the lip and palate. Ann R Coll Surg Engl. 1994 May;76(3):150–60.

25. Curran AJ, Neligan P, Gullane PJ. Submental artery island flap. The Laryngoscope. 1997 Nov;107(11 Pt 1):1545–9.

26. Pribaz J, Stephens W, Crespo L, Gifford G. A new intraoral flap: facial artery musculomucosal (FAMM) flap. Plast Reconstr Surg. 1992 Sep;90(3):421–9.

27. Chia H-L, Wong C-H, Tan B-K, Tan K-C, Ong Y-S. An algorithm for recipient vessel selection in microsurgical head and neck reconstruction. J Reconstr Microsurg. 2011 Jan;27(1):47–56.

28. Ayhan Oral M, Zeynep Sevim K, Görgü M, Yücel Öztan H. Sensory recovery with innervated and noninnervated flaps after total lower lip reconstruction: a comparative study. Plast Surg Int. 2013;2013:643061.

29. Brenner E, Schoeller T. Masseteric nerve: a possible donor for facial nerve anastomosis? Clin Anat N Y N. 1998;11(6):396–400.

30. Hekner DD, Abbink JH, van Es RJ, Rosenberg A, Koole R, Van Cann EM. Donor-site morbidity of the radial forearm free flap versus the ulnar forearm free flap. Plast Reconstr Surg. 2013 Aug;132(2):387–93.

31. Stell PM. The viability of skin flaps. Ann R Coll Surg Engl. 1977 May;59(3):236–41.

32. Stell PM. Wound repair. Closure of surgical defects by skin flaps. Ann R Coll Surg Engl. 1978 May;60(3):226–8.

33. Ellis H. Fundamental techniques of plastic surgery. I. A. McGregor. Seventh edition. 215 × 140 mm. Pp. 336 + x. Illustrated. 1980. Edinburgh: Churchill Livingstone. £8·00. Br J Surg. 1980 Sep 1;67(9):683–4.

34. McDonald HD, Vasconez LO. Advances in Plastic Surgery. West J Med. 1982 Jan;136(1):23–8.

35. McCraw JB, Dibbell DG. Experimental definition of independent myocutaneous vascular territories. Plast Reconstr Surg. 1977 Aug;60(2):212–20.

36. Dakin RL, Minami RT. Plastic Surgery--Epitomes of Progress. West J Med. 1978 Jun;128(6):530–1.

37. Dini M, Quercioli F, Mori A, Agostini T. Expanding the Indications for Latissimus Dorsi Musculocutaneous Flap in Totally Autologous Breast Reconstruction: The Extended Variant. Ann Surg Oncol. 2011 Dec 1;18(3):266–70.

38. Pontén B. The fasciocutaneous flap: its use in soft tissue defects of the lower leg. Br J Plast Surg. 1981 Apr;34(2):215–20.

39. Nakajima H, Fujino T, Adachi S. A new concept of vascular supply to the skin and classification of skin flaps according to their vascularization. Ann Plast Surg. 1986 Jan;16(1):1–19.

40. Hallock GG. Muscle perforator flaps: the name game. Ann Plast Surg. 2003 Dec;51(6):630–2.

41. Hallock GG. The complete classification of flaps. Microsurgery. 2004;24(3):157–61.

42. Cormack GC, Lamberty BG. Fasciocutaneous vessels in the upper arm: application to the design of new fasciocutaneous flaps. Plast Reconstr Surg. 1984 Aug;74(2):244–50.

43. Nakajima H, Minabe T, Imanishi N. Three-dimensional analysis and classification of arteries in the skin and subcutaneous adipofascial tissue by computer graphics imaging. Plast Reconstr Surg. 1998 Sep;102(3):748–60.

44. Mathes SJ, Nahai F. Classification of the vascular anatomy of muscles: experimental and clinical correlation. Plast Reconstr Surg. 1981 Feb;67(2):177–87.

45. Sykes PJ. Application of microvascular surgery to plastic surgery. J R Soc Med. 1980 Jan;73(1):55–9.

46. Disa JJ, Cordeiro PG, Hidalgo DA. Efficacy of conventional monitoring techniques in free tissue transfer: an 11-year experience in 750 consecutive cases. Plast Reconstr Surg. 1999 Jul;104(1):97–101.

47. Yadav P. Recent advances in head and neck cancer reconstruction. Indian J Plast Surg Off Publ Assoc Plast Surg India. 2014 May;47(2):185–90.

48. Dancey A, Blondeel PN. Technical tips for safe perforator vessel dissection applicable to all perforator flaps. Clin Plast Surg. 2010 Oct;37(4):593–606, xi – vi.

49. Bénateau H, Laraba C, Alix T, Compère JF. [Radial forearm or Chinese flap]. Rev Stomatol Chir Maxillofac. 2002 Feb;103(1):35–40.

50. Yadav P. Recent advances in head and neck cancer reconstruction. Indian J Plast Surg Off Publ Assoc Plast Surg India. 2014 May;47(2):185–90.

51. Médard de Chardon V, Balaguer T, Chignon-Sicard B, Riah Y, Ihrai T, Dannan E, et al. The radial forearm free flap: a review of microsurgical options. J Plast Reconstr Aesthetic Surg JPRAS. 2009 Jan;62(1):5–10.

52. Avery CME. Review of the radial free flap: is it still evolving, or is it facing extinction? Part one: soft-tissue radial flap. Br J Oral Maxillofac Surg. 2010 Jun;48(4):245–52.

53. Avery CME. Review of the radial free flap: still evolving or facing extinction? Part two: osteocutaneous radial free flap. Br J Oral Maxillofac Surg. 2010 Jun;48(4):253–60.

54. Song YG, Chen GZ, Song YL. The free thigh flap: a new free flap concept based on the septocutaneous artery. Br J Plast Surg. 1984 Apr;37(2):149–59.

55. Di Candia M, Lie K, Kumiponjera D, Simcock J, Cormack GC, Malata CM. Versatility of the anterolateral thigh free flap: the four seasons flap. Eplasty. 2012;12:e21.

56. Revenaugh PC, Haffey TM, Seth R, Fritz MA. Anterolateral Thigh Adipofascial Flap in Mucosal Reconstruction. JAMA Facial Plast Surg. 2014 Aug 14;

57. Kekatpure VD, Hedne N, Chavre S, Pillai V, Trivedi N, Kuriakose MA. Versatility of adipofascial anterolateral thigh flap for reconstruction of maxillary defects with infratemporal fossa extension. Craniomaxillofacial Trauma Reconstr. 2014 Sep;7(3):213–7.

58. Kuo Y-R, Seng-Feng J, Kuo FM, Liu Y-T, Lai P-W. Versatility of the free anterolateral thigh flap for reconstruction of soft-tissue defects: review of 140 cases. Ann Plast Surg. 2002 Feb;48(2):161–6.

59. Zhang T, Lubek J, Salama A, Caccamese J, Coletti D, Dyalram D, et al. Venous anastomoses using microvascular coupler in free flap head and neck reconstruction. J Oral Maxillofac Surg Off J Am Assoc Oral Maxillofac Surg. 2012 Apr;70(4):992–6.

60. Wei F-C, Celik N, Chen H-C, Cheng M-H, Huang W-C. Combined anterolateral thigh flap and vascularized fibula osteoseptocutaneous flap in reconstruction of extensive composite mandibular defects. Plast Reconstr Surg. 2002 Jan;109(1):45–52.

61. Shpitzer T, Neligan PC, Gullane PJ, Freeman JE, Boyd BJ, Rotstein LE, et al. Oromandibular reconstruction with the fibular free flap. Analysis of 50 consecutive flaps. Arch Otolaryngol Head Neck Surg. 1997 Sep;123(9):939–44.

62. Celebioglu S, Unlü RE, Koçer U, Sensöz O, Mengi AS. Reconstruction of mandible with fibula free flap. Microsurgery. 1998;18(3):156–9.

63. Hidalgo DA. Fibula free flap: a new method of mandible reconstruction. Plast Reconstr Surg. 1989 Jul;84(1):71–9.

64. Chen HC, Demirkan F, Wei FC, Cheng SL, Cheng MH, Chen IH. Free fibula osteoseptocutaneous-pedicled pectoralis major myocutaneous flap combination in reconstruction of extensive composite mandibular defects. Plast Reconstr Surg. 1999 Mar;103(3):839–45.

65. Genden EM, Rinaldo A, Suárez C, Wei WI, Bradley PJ, Ferlito A. Complications of free flap transfers for head and neck reconstruction following cancer resection. Oral Oncol. 2004 Nov;40(10):979–84.

66. Yang Q, Ren ZH, Chickooree D, Wu HJ, Tan HY, Wang K, et al. The effect of early detection of anterolateral thigh free flap crisis on the salvage success rate, based on 10 years of experience and 1072 flaps. Int J Oral Maxillofac Surg. 2014 Sep;43(9):1059–63.

67. Chao AH, Lamp S. Current approaches to free flap monitoring. Plast Surg Nurs Off J Am Soc Plast Reconstr Surg Nurses. 2014 Jun;34(2):52–6; quiz 57–8.

68. Abdel-Galil K, Mitchell D. Postoperative monitoring of microsurgical free-tissue transfers for head and neck reconstruction: a systematic review of current techniques--part II. Invasive techniques. Br J Oral Maxillofac Surg. 2009 Sep;47(6):438–42.

69. Abdel-Galil K, Mitchell D. Postoperative monitoring of microsurgical free tissue transfers for head and neck reconstruction: a systematic review of current techniques--part I. Non-invasive techniques. Br J Oral Maxillofac Surg. 2009 Jul;47(5):351–5.

70. Yuen JC, Feng Z. Distinguishing laser Doppler flowmetric responses between arterial and venous obstructions in flaps. J Reconstr Microsurg. 2000 Nov;16(8):629–35.

71. Hwang JH, Hee Hwang J, Mun G-H. An evolution of communication in postoperative free flap monitoring: using a smartphone and mobile messenger application. Plast Reconstr Surg. 2012 Jul;130(1):125–9.

72. Paydar KZ, Hansen SL, Chang DS, Hoffman WY, Leon P. Implantable venous Doppler monitoring in head and neck free flap reconstruction increases the salvage rate. Plast Reconstr Surg. 2010 Apr;125(4):1129–34.

73. Patel SA, Pang JH, Natoli N, Gallagher S, Topham N. Reliability of venous couplers for microanastomosis of the venae comitantes in free radial forearm flaps for head and neck reconstruction. J Reconstr Microsurg. 2013 Sep;29(7):433–6.

74. सोनी का धमाका: दिवाली से पहले कम दाम में लॉन्च किया नया Xperia C [Internet]. www.bhaskar.com. [cited 2014 Sep 23]. Available from: http://www.bhaskar.com/article/GAD-LAT-new-sony-xperia-c-launched-in-india-4407318-PHO.html?

75. Nokia Lumia 720 [Internet]. Wikipedia, the free encyclopedia. 2014 [cited 2014 Sep 23]. Available from: http://en.wikipedia.org/w/index.php?title=Nokia_Lumia_720&oldid=624522109

76. Nokia Lumia 720 [Internet]. Nokia. [cited 2014 Sep 23]. Available from: http://www.nokia.com/in-en/phones/phone/lumia-720/

77. WhatsApp :: Home [Internet]. WhatsApp.com. [cited 2014 Sep 22]. Available from: http://www.whatsapp.com/

78. WhatsApp amplía hasta 50 usuarios las conversaciones en grupo [Internet]. Cadena SER. [cited 2014 Sep 22]. Available from: http://www.cadenaser.com/tecnologia/articulo/whatsapp-amplia-usuarios-conversaciones-grupo/csrcsrpor/20130415csrcsrtec_3/Tes

79. WhatsApp? Izvini, ali moram da ti kažem / plagosus / blog [Internet]. [cited 2014 Sep 22]. Available from: http://www.plagosus.net/blog/personal/whatsapp-izvini-ali-moram-da-ti-kazem/

80. 3G [Internet]. Wikipedia, the free encyclopedia. 2014 [cited 2014 Sep 23]. Available from: http://en.wikipedia.org/w/index.php?title=3G&oldid=626188431

81. Cannady SB, Rosenthal EL, Knott PD, Fritz M, Wax MK. Free Tissue Transfer for Head and Neck Reconstruction: A Contemporary Review. JAMA Facial Plast Surg. 2014 Jul 3;

82. Bucur A, Reboşapcă A, Andreescu B, Slăvescu D, Dincă O, Cioacă R, et al. [The reconstruction of the oral and maxillofacial defects with free vascularized flaps and microsurgical anastomoses]. Chir Buchar Rom 1990. 2005 Jun;100(3):259–66.

83. Kim EK, Evangelista M, Evans GRD. Use of free tissue transfers in head and neck reconstruction. J Craniofac Surg. 2008 Nov;19(6):1577–82.

84. Lydiatt WM, Johnson PJ, Hollins RR, Lydiatt DD, Yonkers AJ. Microvascular reconstruction of the head and neck cancer patient. Nebr Med J. 1993 Dec;78(12):375–9.

85. Mao C, Yu G, Peng X, Guo C, Huang M, Zhang Y. [A review of 545 consecutive free flap transfers for head and neck reconstruction in a new microsurgery unit]. Zhonghua Er Bi Yan Hou Ke Za Zhi. 2003 Feb;38(1):3–6.

86. Bianchi B, Ferri A, Ferrari S, Copelli C, Boni P, Ferri T, et al. The free anterolateral thigh musculocutaneous flap for head and neck reconstruction: one surgeon's experience in 92 cases. Microsurgery. 2012 Feb;32(2):87–95.

87. Um GT, Chang J, Louie O, Colohan SM, Said HK, Neligan PC, et al. Implantable Cook-Swartz Doppler probe versus Synovis Flow Coupler for the post-operative monitoring of free flap breast reconstruction. J Plast Reconstr Aesthetic Surg JPRAS. 2014 Jul;67(7):960–6.

88. Guillemaud JP, Seikaly H, Cote D, Allen H, Harris JR. The implantable Cook-Swartz Doppler probe for postoperative monitoring in head and neck free flap reconstruction. Arch Otolaryngol Head Neck Surg. 2008 Jul;134(7):729–34.

89. Hee Hwang J, Mun G-H. An evolution of communication in postoperative free flap monitoring: using a smartphone and mobile messenger application. Plast Reconstr Surg. 2012 Jul;130(1):125–9.

Department of Surgery
Unit 1 - General and Head & Neck Surgery
Christian Medical College, Vellore

A Prospective study on application of smartphone photography and 3G wireless internet for free flap monitoring.

Information sheet

You are invited to be part of a study to improve the current knowledge about your disease condition. This study will help other patients who later come to hospital with the same complaints. By agreeing to be a part of this study, you will contribute to recognizing early signs of flap failure and help in better monitoring of the free flaps in future .

The information collected from you will include

1. History – This includes details regarding your general health and the present illness
2. Clinical examination – Includes evaluation by the attending doctor on admission to the hospital
3. Investigations – Includes the results of relevant blood and regular handheld Doppler study.
4. Photographs of the flap will be taken at regular intervals which will be a part of the study.

Whether you accept or decline to be a part of this study will not affect your further treatment at this hospital

There is no disadvantage or complication that can happen to you by participating in this study as this study does not interfere in the treatment provided by the care taker.

All details including personal data, assessment of the doctor during and after the operation will be kept confidential.

Participation in this study is purely voluntary, and you can withdraw from the study at any time and that refusal to participate will not involve any penalty or loss of benefits to which you are otherwise entitled.

Department of Surgery

Unit 1 - General and Head & Neck Surgery

Christian Medical College, Vellore

Prospective study on free flap monitoring using smartphone & 3G wireless internet

---

Proforma For Data Collection

PATIENT INFORMATION

Patient's Sticker:

Name		Hospital no.	
Age		Study Serial no.	
Sex		Occupation	
Education	Illiterate / Primary / Graduate / Others		
Phone No.(s)			
Address			

CLINICAL INFORMATION

Final Diagnosis :

Procedure (s) undergone :

1) Type of resection:

a) Wide local excision + selective neck dissection/SOHND

b) Composite Resection +/- Mandibulectomy /MRND /RND/SND

2) Type of Free Flap:

a)Fasciocutaneous: Radial artery / ALT

b)Osteofasciocutaneous: Fibula / Iliac crest

Date of Surgery:

Habits : Smoking/Tobacco chewing/Alcohol intake/Others

Co morbidities: Hypertension/ Diabetes mellitus/ IHD/COPD/Others

Other treatment modalities: a) Radiotherapy- IMRT/EBRT

b) Chemotherapy- Cisplatin/Taxane/5FU/Others.

Biopsy Report with date:

LABORATORY INVESTIGATIONS

Haemoglobin	PCV	Creatinine	AC /PC	Others

CLINICAL MONITORING PROTOCOL:

TIME	COLOR	TEMPERATURE	TURGOR	PCV	CLINICAL RESPONSE(Healthy/Arterial insufficiency/Venous insufficiency/Uninterpretable) (H/A/V/U)

TIME	COLOR	TEMPERATURE	TURGOR	PCV	CLINICAL RESPONSE(Healthy/Arterial insufficiency/Venous insufficiency/Uninterpretable) (H/A/V/U)

H- Healthy : Pink, full.

A- Arterial insufficiency: Pale and shrinking skin turgor.

V- Venous insufficiency: Darker color skin and oozing

U- Uninterpretable: Blurred picture, loss of focus.

PHOTOGRAPHIC MONITORING OF THE FREE FLAP USING SMARTPHONE AND 3G WIRELESS INTERNET.

DAY AND TIME	OPERATING SURGEON(OpS)	OBSERVING SURGEON(ObS1)	CLINICAL RESPONSE(Healthy/Arterial insufficiency/Venous insufficiency/Uninterpretable) (H/A/V/U)	TIME INTERVAL B/W RESPONSE & RE - EXPLORATION.

PHOTOGRAPHIC MONITORING OF THE FREE FLAP

DAY AND TIME	OPERATING SURGEON(OpS)	OBSERVING SURGEON(ObS1)	CLINICAL RESPONSE(Healthy/Arterial insufficiency/Venous insufficiency/Uninterpretable) (H/A/V/U)	TIME INTERVAL B/W RESPONSE & RE - EXPLORATION.

H- Healthy : Pink, full.

A- Arterial insufficiency: Pale and shrinking skin turgor.

V- Venous insufficiency: Darker color skin and oozing

U- Uninterpretable: Blurred picture, loss of focus.

DAY AND TIME	OPERATING SURGEON (OpS)	OBSERVING SURGEON (ObS1)	CLINICAL RESPONSE(Healthy/Arterial insufficiency/Venous insufficiency/ Uninterpretable) (H/A/V/U)	TIME INTERVAL B/W RESPONSE & RE - EXPLORATION.

H- Healthy : Pink, full.

A- Arterial insufficiency: Pale and shrinking skin turgor.

V- Venous insufficiency: Darker color skin and oozing

U- Uninterpretable: Blurred picture, loss of focus.

Department of Surgery
Unit 1 - General and Head & Neck Surgery
Christian Medical College, Vellore

A Prospective study on application of smartphone photography and 3G wireless internet for free flap monitoring.

Informed Consent form to participate in a clinical trial

Study Number:

Subject's Initials: _____ Subject's Name: _____

Date of Birth / Age:_____

Please check the box below:

(i) I confirm that I have read/been read to and understood the information sheet dated _____ for the above study and have had the opportunity to ask questions. [ ]

(ii) I understand that my participation in the study is voluntary and that I am

free to withdraw at any time, without giving any reason, without my medical care or legal rights being affected. [ ]

(iii) I understand that the Sponsor of the clinical trial, others working on the Sponsor's behalf, the Ethics Committee and the regulatory authorities will not need my permission to look at my health records both in respect of the current study and any further research that may be conducted in relation to it, even if I withdraw from the trial. I agree to this access. However, I understand that my identity will not be revealed in any information released to third parties or published. [ ]

(iv) I agree not to restrict the use of any data or results that arise from this study provided such a use is only for scientific purpose(s) and I agree to observation and photography in the operating room during the procedure and following the operation [ ]

(v) I agree to take part in the above study. [ ]

Signature (or Thumb impression) of the Subject/Legally Acceptable Representative:

_____

Date: _____/_____/_____

Signatory's Name: _____

Signature of the Investigator: _____

Date: _____/_____/_____

Study Investigator's Name: _____

Signature of the Witness: _____

Date:_____/_____/_____

Name of the Witness: _____

sno	age	sex	occupa	educn	phone No.	addre	Diagno	resecn	neck	flap	date	smokin	tobacc	Co mo	RT/CT	PCV	Creat	AC/PC	OPS	OPS2	OPS3	OPS4	OPS5	OPS6	OPS7	OPS8	OPS9	OPS1	OPS1	OPS1	OPS1	OPS1	OPS
1	35	MALE	ENGIN	GRADU	1E+10	TN	Mod di	WLE	SND 1-	RAFF	19.06.2013	YES	YES	NO	NO	42.6	1.14	164	H	H	H	H	H		H	H	H		H	U	H		H
2	74	MALE	FARMB	GRADU	1E+10	KERALA	Well di	compo	MRND	FIBULA	05.11.2013	YES	NO	DM/HT	NO	28.4	1.65	96	U	H		H	U		H		U	U	U	U	H	H	H
3	41	FEMAL	HOUSE	GRADU	1E+10	JHARK	Moder	WLE	NIL	ALT	13.11.2013	NO	NO	NO	NO	27.1	0.78		H	H	H	H	H	H	H	H	H	H	H	V	H	H	H
4	60	MALE	FARMB	ILLITER	9E+09	JHARK	Moder	compo	MRND	FIBULA	20.11.2013	YES	YES	NO	NO	27.5	0.94	108	H					H			U	H		H	H	H	
5	50	MALE	BUSINI	GRADU	9E+09	SIKKIM	SCC LE	WLE	MRND	RAFF	27.11.2013	NO	NO	DM	NO	27.8	1.2	156	H	H	H	H	H	H	H	H	H	H	H	H	H	H	H
6	40	MALE	FARMB	GRADU	8E+09	BIHAR	Moder	compo	MRND	FIBULA	06.12.2013	NO	NO	NO	NO	30.5	0.72	132	H	H	H	H	H	H	H	H	H	H		H	H		
7	45	FEMAL	HOUSE	GRADU	1E+10	ASSAM	Moder	WLE	MRND	ALT	11.12.2013	NO	YES	NO	RT	23.5	0.46	112	H	H		H				H	H	H			H	H	H
8	35	MALE	TAILOR	GRADU	1E+10	BIHAR	Moder	WLE	MRND	ALT	08.01.2014	YES	YES	NO	NO	33.3	1.1	98	H	H	H	H	H		H	H	H	H	H	H	H	H	H
9	62	FEMAL	HOUSE	PRIMARY		BANGL	Moder	WLE	MRND	ALT	17.01.2014	NO	YES	DM/HT	NO	33.4	1.18	92	H		H	H	H	H	H		H	U	H	H	H	H	H
10	67	MALE	FARMB	PRIMARY		WEST	Well di	WLE	MRND	ALT	29.01.2014	YES	NO	NO	NO	36.6	0.95	91	H	U	H	H	H	H	H								
11	49	MALE	BUSINI	GRADU	1E+10	VELLO	Moder	WLE	SND 1-	RAFF	05.02.2014	YES	NO	DM	NO	42	0.62	108	H	H	H	H	H	U	H	U							
12	45	MALE	LABOU	GRADU	1E+10	KERALA	Moder	WLE	SND 1-	ALT	02.04.2014	NO	YES	NO	NO	42.2	0.8	98	H	U	V	U	H	H	H	H	H	H	H	H	H	H	H
13	48	FEMAL	HOUSE	PRIMARY		BANGL	Moder	WLE	MRND	RAFF	09.04.2014	NO	YES	DM/HT	NO	28.3	0.63	94	H	H	H	H	H	H	H	H	H	H	H	H	H	H	U
14	38	MALE	FARMB	GRADU	9E+09	CHITTO	Mod di	WLE	SND 1-	RAFF	04.06.2014	NO	YES	DM	NO	45	1.05	113	H	H	U	H	H	H	H		H	H	H	H	H		
15	42	MALE	BARBE	GRADU	9E+09	JHARK	Mod D	WLE	SND 1-	RAFF	25.06.2014	NO	YES	NO	NO	36.1	0.86	93	H	H	H	H	H	H	H	H	H	H	H	H	H	H	H
16	40	MALE	DOCTO	GRADU	9E+09	CHENN	Mod D	WLE	SND 1-	RAFF	02.07.2014	NO	NO	HTN	NO	47.3	0.87	116	H	H	U	H	H	U	U	U	H	H	H	H	H	U	H
17	50	MALE	BUSINI	GRADU	9E+09	KOLKA	Well D	WLE	MRND	RAFF	30.07.2014	YES	NO	NO	NO	37.3	0.97	92	H	H	H	H	V	V									
18	34	FEMAL	NURSE	GRADUATE		VELLO	Wll dif	WLE	SND 1-	RAFF	27.08.2014	NO	NO	NO	NO	24.9	0.52	102	H	H	H	H	H	H	H	H	H	H	H	H	H		

OPS1	OPS1	OPS1	OPS1	OPS2	OPS t1	OPS t2	OPS t3	OPS t4	OPS t5	OPS t6	OPS t7	OPS t8	OPS t9	OPS t1	OPS t1	OPS t1	OPS t1	OPS t1	OPS t1	OPS t1	OPS t1	OPS t1	OPS t1	OPS t2	ObS1	ObS2	ObS3	ObS4	ObS5	ObS6	ObS7	ObS8	ObS
H	H	H	H	H	7	0.33	7	12	19	0	7	12	19	0	6	12	18	0	6.3	12.05	19.15	0	6	19	H	H	H	H	H		H	H	H
H	U	U	U	H	22.53	6.12		0	7.14		20.08		7.01	13	19.27	9.38	13.21	19.44	1.26	7.49	7.54	19.31	8.52	13	H	U		H	U		H	U	H
	H	H			23.41	4.32	8.58	12.09	20.08	0.28	9.39	18.41	19.47		11.39	15.52	21.59	8.34	19.18		13.18	0.15			H	H	H	H	H	H	H	H	H
					16.02					4.51			7.59	15.56		6.56	8.37								H	H	H		H	H			H
H	H				7	18.41	18.41	6.4	7.05	17.06	23.32	14.18	19.18	7.33	18.02	7.41	18.39	6.41	7.02	13.37	18.28				H	H	H	H	H	H	H	H	H
					8.21	14.24	18.28	6.01	6.47	16.08	18	6.03	7.59	18.19		0.48	7.32								H	H	H	H	H	H	H	H	H
H	H	H	H		1.09	7.55		19.16				16.11	18.35	7.17			1.04	7.57	20.15	5.21	6.44	13.22	19.43	22.36	H	H	H	H	H	H	H		H
H	H	H			8.45	13.45	18.39	4	7.06		20.11	0.09	6.47	13.25	20.39	0.15	8.05	13.47	19.11	7.34	18.4	7.56			H	H	H		H	H	H	H	H
H	U	H			23.57		11.29	12.56	19.11	0.37	7.27		19.28		12.45	17.01	23.27	0.09	7.15	18.2	1	7.28				U	H	H	U			H	H
					3.46	7.32	22.48	4.32	10.1		23.09														H	U	H			H	H		
					5.14	9.43	22.13	6.36	6.36	16.32		19.01														H	H	H	H	U	H	H	
H	H	H	H		22.31	0.51	1	15.54	11.38	4.04	6.5	18.59	20.12	1.5	7	13	19.04	0.01	8.25	12.32	22.36	0.15	19.5		H				V			H	H
U					11.01	11.01	21.26	21.26	5.47	15.14	15.14	20.1	0					19.56	23.36	5.24					H	H	H	H	H		H	H	
					19.37	6.26	7.4	17.19	19.37	0.32	8.46		18.27	16.02	16.02	19	18.47										H					H	
H	H	H			0.1	5.54	14.14	20.47	5.03	7.12	15.27	19.57	0.47	12.21	21.13	0.58	7.24	14.24	19.22	7.48	14.39	21.03			H	H			H	H			
U	H	H	H	U	19.07	7.09	3.17	16.06	18.58	12.23	12.23	14.5			7.38	15.49	19.43	5.55	7.02	19.52	6.42	15	0.07	8.03									
					18.19				18.3	18.3															H				V	V			
					2.01	2.01	7.12		22.17	6.29	19.14	7	14.55	20.1	1.39	9.27	19.49								H	H	H	H		H		H	H

ObS1	ObS1	ObS1	ObS1	ObS1	ObS1	ObS1	ObS1	ObS1	ObS1	ObS2	ObSt1	ObSt2	ObSt3	ObSt4	ObSt5	ObSt6	ObSt7	ObSt8	ObSt9	ObSt10	ObSt11	ObSt12	ObSt13	ObSt14	ObSt15	ObSt16	ObSt17	ObSt18	ObSt19	ObSt	CF1	CF2	CF3
H	H	U	H	H	H	H	H	H	H	H																					H	H	H
U	U	U	H	H	H	H	U	H	U	H	22.53	6.32			7.12			3.27	8.18	13.22	19.33	8.5	16.42	18.42	6.24	7.03		19.33	6.39	13	H	H	H
H	H	H	H	H	H	H	H	H			23.42	0.45	8.14	12.37	18.2	0.25	5.48	19.14	19.3	23.53	9.41		20.54	8.43	19.41		13.19	1.46			H	H	H
H	H	H	H	H							8.26	18.41	7.28		20.1	1.44		12.53	8.5	14.18	23.51	23.51	7.39	18.55							H	H	H
H	H	H	H	H	H	H	H				14.15	14.15	22.2	0.25	9.5	12.31	20.32	14.25	20.19	9.17	0.49	7.58	18.39	6.41	7.02	13.37	18.28				H	H	H
H	H	H	H								7.29	14.26	20.19	5.3	7.43	15.31	20.59	2.33	13.09	18.24	5	5.3	13.58								H	H	H
H	H	H	H	H	H	H	H	H	H		1.09	8.41	12.59	19.05	6.56	6.56	16.21		6.05	14.3	14.3	20.51	7.33	7.33	23.54	7.01	7.01	16.55	18.41		H	H	H
H	H	H	H			H		H			13.06	13.06	19.03		11.45	13.41	21.45	0	10.11	15.36	21.34	0.16	12.13			7.59		8.55			H	H	H
	H	U	H	H	U	H	U					6.35	6.4	14.06	18.42			15.49	20.42		7.55	17.52	19.37	6.34	6.43	19.43	6.44				H	H	H
											0.13	11	3.32			12.2	18.59														H	H	H
												17.17	21.26	7.26	7.26	17.38	21.32														H	H	H
H		H	H	H	H	H	H	H	H		21.5				19.41			17.59	6.43	6.43		14.15	19	7.47	7.47	17.17	18.39	7.14	21.22		H	H	H
H	H	H	H	H							6.28			20.13	7.13		18.16	19.28		10.51	10.51	12.44	19.19	18.56							H	H	H
			H										10.55					19.03					19.43								H	H	H
		U	U	H	H	H					6.26	6.27			7.2	7.2						7.3	7.3	18.26	18.26	6.3					H	H	H
																															H	H	H
											17.02				18.2																H	H	H
H	H	H									22.04	6.53	6.53	13.43		5.41		21.38	21.38	21.38	10.17	10.17									H	H	H

F4	CF5	CF6	CF7	CF8	CF9	CF10	CF11	CF12	CF13	CF14	CF15	CF16	CF17	CF18	CF19	CF20	CFt1	CFt2	CFt3	CFt4	CFt5	CFt6	CFt7	CFt8	CFt9	CFt10	CFt11	CFt12	CFt13	CFt14	CFt15	CFt16	CFt17
H	H	H	H	H	H	H	H	H	H	H	H	H	H	H	H	H	19	0.33	7	12	19	0	7	12	19		6	12	19.15	0	6.3	12.05	19.15
H	H	H	H	H	H	H	H	H	H	H	H	H	H	H	H	H	22.14	5.57	12	23.28	6.31	18	19.23	0	5.13	12.42	18.51	6.43	12.25	18.1	0.21	7.02	13.2
H	H	H	H	H	H	H	H	H	H	H	H	H	H	H		H	22.28	0.2	7.41	11.54	18.14	0.23	9.39	13.5	19.17	23.51	9.19	14.25	20.52	8.06	18.49	6.38	13.16
H	H	H	H	H	H	H	H	H	H	H	H	S	S	S			7.17	18.4	6.43	13.2	19.06	0.23	6.27	12.53	7.54	12.03	18.51	23.49	7.38	18.51	7.29		
H	H	H	H	H	H	H	H	H	H	H	H	H	H				6.59	12.08	18.27	0.01	6.48	12.32	20.32	13.46	19.03	6.56	17.58	6.34	18.3	0.06	7.02	12.31	18.28
H	H	H	H	H	H	H	H	H	H								6.47	14.23	18.58	4.54	6.45	12.33	17.59	0.29	6.41	18.18	2.38	0.47	7.06				
H	H	H	H	H	H	H	H	H	H	H	H	H	H	H	H	H	1.07	5.49	12.24	18.16	0.01	6.57	12.54	15.59	18.32	7.14	11.39	18.35	0.16	6.25	18.5	0.03	6.2
H	H	H	H	H	H	H	H	H	H	H	H	H	H	H			6.14	12.58	18.35	3.59	6.23	13.2	19.07	23.58	6.45	12.43	19.28	0.15	8.02	12.4	18.25	6.49	18.4
H	H	H	H	H	H	H	H	H	H	H	H	H	H	S			22.02	0	6.4	12.12	18.42	0.11	7.17	13.03	19.02	0.04	7.42	16.16	18.4	0.08	6.43	12.3	0.57
H	H	H	S														0	7.03	19.33	23.34	6.12	11.55	18.45										
H	H	H	H	H													0.4	7.32	19.37	0.43	6.24	15.34	19.5	7.21									
H	H	H	H	H	H	H	H	H	H	H	H	H	H	H	H		21.29	0.47	0.56	13.14	18.56	1.45	6.48	12.24	19.16	0.16	6.59	12.5	18.5	23.55	7.29	12.25	18.35
H	H	H	H	H	H	H	H	H	H	H	H	S					0.22	6.43	14.37	18.19	23.55	6.42	15.13	18.35	23.46	0.22	9.14	12.27	18.43	18.45	23.36	5.23	
H	H	H	H	H	H	H	H	H	H								19.15	23.57	6.38	11.53	18.43	0.01	6.45	17.53	18.12	6.27	11.57	17.59	18.16				
H	H	H	H	H	H	H	H	H	H	H	H	H	H	H			0.02	5.32	13.2	18.52	0.21	6.47	12.33	18.22	0.36	12.2	18.2	0.52	6.54	13.06	18.16	6.24	13.16
H	H	H	H	H	H	H	H	H	H	H	H	H	H	H	H	H	18.55	6.27	1.58	13.27	18.45	0.06	7.35	13.42	19.1	1.44	6.2	14.28	18.4	0.02	7.01	18.37	6.27
V	V																18.18	23.01	0.01	6	18.29	19.58											
H	H	H	H	H	H	H	H	H	H								21.38	23.55	6.52	13.38	19.1	0.07	19.11	5.53	11.58	18.27	0.27	8.51	18.09				

CFt18	CFt19	CFt20	Final	Final	Final	Final	Final	Final	Final	Final	Final	Final	Final	Final	Final	Final	Final	Final	Final	Final	Final	Final
0	6	19	H	H	H	H	H	H	H	H	H	H	H	H	H	H	H	H	H	H	H	H
18.46	6.39	13	H	H	H	H	H	H	H	H	H	H	H	H	H	H	H	H	H	H	H	H
0.11			H	H	H	H	H	H	H	H	H	H	H	H	H	H	H	H	H	H		
			H	H	H	H	H	H	H	H	H	H	H	H	H	H	H	H	S,EXPLORED			
			H	H	H	H	H	H	H	H	H	H	H	H	H	H	H	H	H			
			H	H	H	H	H	H	H	H	H	H	H	H	H							
13.2	18.41	22	H	H	H	H	H	H	H	H	H	H	H	H	H	H	H	H	H	H	H	H
5.58			H	H	H	H	H	H	H	H	H	H	H	H	H	H	H	H	H	H		
6.52			H	H	H	H	H	H	H	H	H	H	H	H	H	H	H	H	H	V,EXPLORED		
			H	H	H	H	H	H	S,EXPLORED													
			H	H	H	H	H	H	H	H												
0.07	18.59		H	H	H	H	H	H	H	H	H	H	H	H	H	H	H	H	H	H	H	
			H	H	H	H	H	H	H	H	H	H	H	H	H	H	H	S,EXPLORED				
			H	H	H	H	H	H	H	H	H	H	H	H	H							
20.27			H	H	H	H	H	H	H	H	H	H	H	H	H	H	H	H	H	H		
14.14	20.45	0.1	H	H	H	H	H	H	H	H	H	H	H	H	H	H	H	H	H	H	H	H
				H	H	H	V	EXPLORED														
			H	H	H	H	H	H	H	H	H	H	H	H	H							