THE METASTATIC INVOLVEMENT

OF

THE FACIAL NODE

IN ORAL SQUAMOUS CELL

CARCINOMA

A dissertation submitted to the Dr. MGR Medical University, Tamil Nadu, in partial fulfillment of the requirement for the M.S Degree (Branch I – General Surgery) Exam to be held in February 2007.

Certificate

This is to certify that the topic, " **THE METASTATIC INVOLVEMENT OF THE FACIAL NODE IN ORAL SQUAMOUS CELL CARCINOMA,**" which is being submitted as thesis requirement for M.S Degree Branch -1 (General Surgery) examination of Dr. M.G.R Medical University of Tamil Nadu, February 2007, is a bonafide work done by Dr. Sundeep M C Kisku.

Dr. V. Sitaram
Professor and Head,
Department of General Surgery.
Christian Medical College,
Vellore. Tamil Nadu.

Certificate

This is to certify that this thesis, " **THE METASTATIC INVOLVEMENT OF THE FACIAL NODE IN ORAL SQUAMOUS CELL CARCINOMA,**" is a bonafide work of Dr. Sundeep M C Kisku, post graduate in General Surgery of Christian Medical College, Vellore. This work has been carried under my supervision and guidance in partial fulfillment of the regulations of Dr. M.G.R Medical university of Tamil Nadu, for the Masters of Surgery (General Surgery) examination to be held in February 2007.

Dr. John C. Muthusami
Professor and Head,
Department of General Surgery Unit I.
Christian Medical College,
Vellore. Tamil Nadu.

Acknowledgements:

I thank the Lord for the ability to start and complete this thesis.

I thank Dr. John Muthusami, my guide, for his guidance and contribution in this study.

I thank Dr. J.P. Raj and Dr. Pranay Gaikwad for their valuable time and effort.

I thank all the patients who form the substance of this thesis.

I thank my wife, Lillian, who has been a great source of encouragement all the way through.

Contents:

Aims and objectives:

1. To determine the prevalence of metastasis to the facial node in oral carcinoma.
2. To determine whether a palpable facial lymph node correlates with metastasis.
3. To determine whether the presence of metastasis in the facial node correlates with the outcome in terms of local recurrence and long term survival.
4. To determine whether routine facial node dissection is indicated in all patients undergoing a neck dissection for oral malignancies.

Introduction:

Oral cancer affects as many as 274,000 people worldwide annually[1]. Oral cancer is the sixth most common cancer in the world[2]. The most common type of oral cancer is squamous cell carcinoma[1].

The incidence of oral cancer is more than 30 per 100 000 population in India[3]. Oral cancer represented 14% of all cancer cases at the Regional Cancer Centre (RCC), Kerala. It constituted 17% of all cancers in males and 10.5% of all cancers in females, making it the most common cancer in males and the third most common cancer among females[4]. Approximately 20,000 new cases of cancer of the oral cavity are diagnosed each year and there are about 4000 deaths due to the same annually in the US[5].
The relatively small number of deaths is offset by the severe functional and cosmetic disabilities that many of these patients endure in coping with their disease, which is primarily preventable. Unfortunately, when first seen, most patients have an advanced tumor, partly because of self neglect and partly because of the primary physician's lack of training in the early detection of oral cancer[6].

Oral cancer detected early may be amenable to complete cure, while on the contrary, the presence of lymph nodal and distant metastasis drastically decreases survival by 50%. [30] Moreover, despite adequate local and nodal treatment, recurrences are known to occur. The key to surviving oral cancer is early detection and treatment[6].

Lymph nodal metastasis in oral cancers has been well studied. The lymph nodal status in the TNM staging (AJCC 2002) oral cancers subdivides the draining lymph nodes into seven specific sites Level I to Level VII. The neighboring lymph nodes are

clubbed in the "other groups" – Sub occipital, retropharyngeal, facial, [7]etc. Metastasis to the facial node is infrequently documented; because of this, these nodes have received little attention in the literature. Recent literature review[8] reveals that the facial node may be associated with recurrence and poor prognosis. This study is reveals our experience with oral carcinoma with facial node metastasis.

Facial node involvement in head and neck cancer is rarely documented. It has been suggested by Sheehan that the facial node may serve as a first echelon node in head and neck squamous cell carcinoma[8]. Palpable cervical lymphadenopathy is generally considered as lymph nodal metastasis. It has been our experience to note the presence of a palpable facial node often in oral malignancies. These are patients with poor oral hygiene. In a few cases it is the only node palpable. Palpation of the neck, with a sensitivity and specificity of 60% to 80%, is not a very accurate way to search for cervical metastases[9].

Does the presence of a palpable facial node contribute to the N staging of the cancer – particularly in view of ongoing oral sepsis? What is the significance of the facial node metastasis and its implication in the treatment and the prognosis of the patient? These are a few questions that have yet to be answered unequivocally.

Review of literature:

Anatomy:

The oral cavity extends from the cutaneous vermilion junction of the lips to the junction of the hard and soft palate above and to the line of the circumvallate papillae below[10]. It is divided into the lips, buccal mucosa , upper and lower alveolar ridges, retromolar trigone, floor of the mouth, hard palate and the anterior two thirds of the tongue.

Lymphatics of the oral cavity:

Several important groups of lymph nodes act as first echelon nodes in the oral cavity. Two or three submental nodes lie on the mylohyoid muscle in the submental triangle. This triangle is bounded by the anterior bellies of the digastric muscles and the hyoid bone. Six or more submandibular nodes lie on the anterior surface of the submandibular gland or between the gland and the lower jaw adjacent to the facial artery. The nodes on the surface of the gland are preglandular nodes. Those that extend upward along the course of the facial artery and are divided into prevascular and retrovascular nodes, depending on their relationship to the facial artery.

Another important first- echelon nodal group that receives afferent vessels from the oral cavity is the upper deep jugular nodes located along the upper internal jugular vein between the levels of the digastric and omohyoid muscles. The uppermost node is the jugulodigastric or tonsillar node; the lowest is the jugulo-omohyoid node. The jugulocarotid node, the principal node of the tongue, is located between these nodes just

below the level of the greater horn of the hyoid bone at the level of the bifurcation of the common carotid artery. Additionally but less common nodal groups receiving primary lymphatics from the oral cavity include the lateral retropharyngeal lymph nodes and nodes adjacent to the inferior portion of the parotid (periparotid nodes).

In general, regional metastatic squamous cell carcinoma of the oral cavity demonstrates an orderly progression from neck nodes located in the upper regions of the neck towards nodes in the lower region. Malignancies of the lips and anterior floor of the mouth as well as adjacent gingival and buccal mucosa tend to metastasize to submandibular lymph nodes first. Tumors situated more posteriorly in the oral cavity usually metastasize initially to the upper deep jugular lymph nodes. As multiple cervical nodes become involved with metastatic disease, spread to the middle and lower deep jugular nodes occur. It is unusual for a single metastatic node from an oral cavity cancer to metastasize to the lower or posterior cervical nodes initially. However, there are lymphatics channels that directly connect oral cavity sites with lower jugular nodes, which provide an anatomic basis for lower jugular lymphadenopathy.

The Facial node

Rouviere described a lymphoid "collar" of nodes, the pericervical ring that encircles the neck at the junction of the head and neck[11]. He classified the lymph nodes of the head and neck into 10 groups. The nodes in this collar group include the occipital, mastoid, parotid, facial, retropharyngeal, submaxillary, submental, and sublingual nodes (figure 1). Anterior and lateral cervical groups are descending chains that extend from this collar down along the front and sides of the neck, respectively.

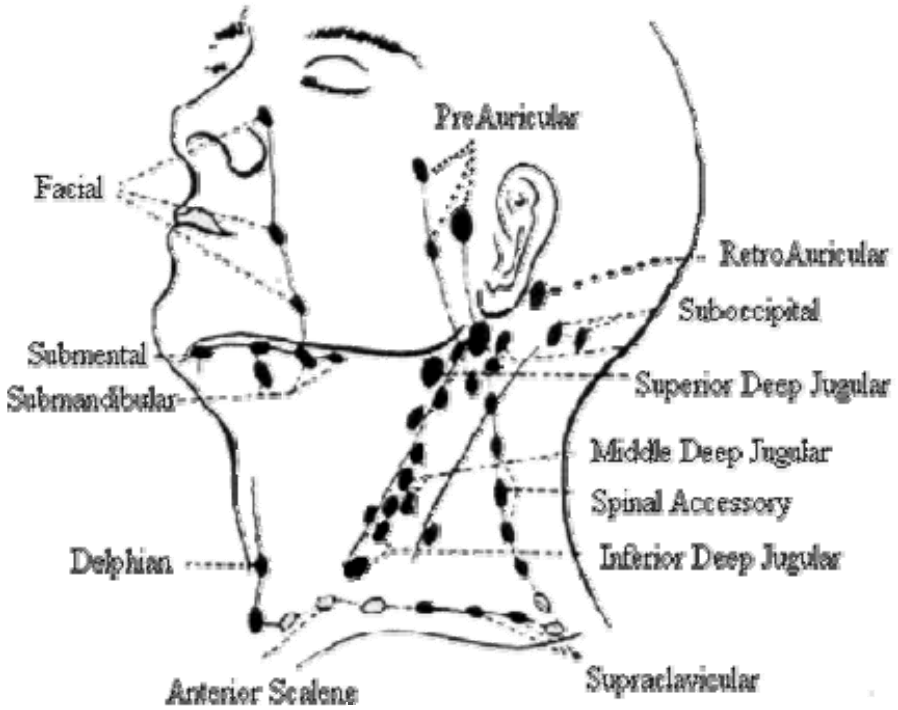

Figure 1. Lymph nodes of the neck.

The facial nodes were one of the most inconsistently present groups in the head and neck region. These are lymph nodules intercalated along the course of the lymphatic vessels that drain the face. These nodes are found along the course of the branches of the facial vessels in the subcutaneous spaces of the face. Most of the afferent drainage is from the skin and subcutaneous tissues of the face and the mucosal surface of the gums. The efferent drainage is primarily to the submandibular lymph nodes.

Rouviere divided the facial nodes into four groups. These groups are the inferior maxillary nodes (referred to as the mandibular nodes), buccinator nodes, infraorbital or nasolabial nodes, and malar nodes. To this classification, Tart [12]added an additional group of lymph nodes designated as the retrozygomatic nodes.

Mandibular Nodes

Synonyms for this group include supramaxillary nodes, supramandibular nodes, and inframandibular nodes. These nodes, when present, lie along the external surface of the mandible adjacent to the facial artery and anterior to the masseter muscle[12, 13]. Most commonly one node is present, but there may be as many as three. These nodes are deep to the superficial muscles of facial expression (figure 2). One additional node that may be a part of this group (the inferior maxillary node or inframaxillary node) does lie in the subcutaneous tissues near the inferior margin of the mandible.

The afferent drainage is from the infraorbital and buccinator lymphatics as well as from the skin and subcutaneous tissues of the cheek, lower tip, and less commonly the gingiva. The efferent drainage is to the submandibular lymphatics.

Figure 2. Diagram illustrating the locations of the facial nodes.

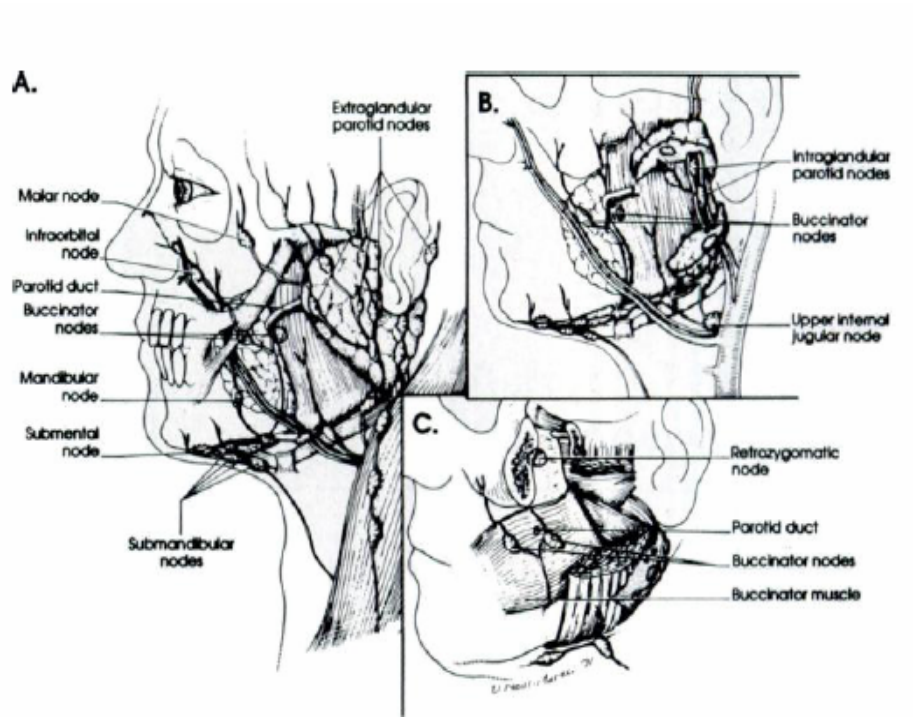

A, The skin and subcutaneous fat have been removed, revealing the more superficial facial nodes, including the mandibular, buccinator, malar, and infraorbital nodes.

B, The superficial muscles of facial expression and the sternocleidomastoid muscle have been removed, demonstrating the relationship of the facial nodes to the facial veins.

C, The masseter muscle has been removed, as has the zygomatic arch, revealing the retrozygomatic and buccinator nodes.

Buccinator Nodes

The buccinator nodes are found lying on the buccinator muscle on in the fat of the buccinator space. They are divided into two groups according to their relationship to the anterior facial vein. The anterior nodes lie anterior on superficial to the facial vein, and the posterior nodes lie posterior or deep to the facial vein. Usually one or two nodes may be found in either location. One separate node may rarely be found more anterior in the subcutaneous fat adjacent to the angle of the mouth. The afferent drainage is from the skin and subcutaneous tissues of the lower lid, nose, cheek, and rarely the temporal region. The infraorbital, malar, and possibly retrozygomatic nodes drain by this pathway. The efferent drainage is by the mandibular lymphatics to the submandibular nodes.

Infraorbital Nodes

In the canine fossa or nasolabial fold, there is usually one node lying along the course of the anterior facial vessels. This lymph node has been designated the infraorbital node. Lymphoma has a propensity for involving this region, and in most cases the lymph tissue is adherent to the infraorbital neurovascular bundle.

The afferent drainage is from the skin and subcutaneous tissues of the medial eye, nasolabial fold, and nose. The efferent drainage is to the buccinator and mandibular lymphatics.

Malar Nodes

The Malar nodes have been described as those lymph nodes found superficial to the malar eminence just lateral to the eye. These nodes are intercalated along the vertical

lymphatic channels coursing from the parotid over the zygomatic arch to the temporal region. Therefore, there is a spectrum of possible locations for these nodes, from the malar eminence to the end of the zygomatic process of the maxilla.

The afferent drainage is from the skin and subcutaneous tissues of the lids, lateral canthus region, and temporal region. The efferent drainage is to the parotid nodes, unlike the nest of the facial nodes, which drain to the submandibular group. In fact, a useful landmark is the lateral canthus of the eye; the tissues lateral and posterior to the lateral canthus usually drain via the parotid lymphatics.

Retrozygomatic Nodes

These nodes are found deep to the zygomatic arch in the infratemporal fossa just at the posterior margin of the maxillary sinus. The afferent lymphatic drainage is from the tissues of the deep temporal and infratemporal fossa. The efferent drainage is most likely via the facial lymphatics through the buccinator space.

Lips:

The lips begin at the junction of the vermilion border with the skin and form the anterior boundary of the oral vestibule. The lip includes only the vermilion surface, or that portion of the lip that comes into contact with opposing lip. The lymphatic drainage of the lips has been well described. The upper and lower lips have a cutaneous and a mucosal system of lymphatics, both arising from a fine capillary network beneath the vermilion border, the medial portion of the lip drains to submental lymph nodes, whereas the lateral portion drains into submandibular lymph nodes. Numerous anastomoses form

the lymphatic vessels of the two lip halves are present near the midline and account for bilateral metastases from tumors that are close to or cross the midline. Collecting lymphatic trunks have been shown to enter the mental foramen in 22% of lip cancer cases. The upper lip lymphatics drain to preauricular, infraparotid, submental lymph nodes. In contrast to the lower lip, only a few of the upper lip cutaneous lymph trunks drain to contralateral nodes. No crossing of the midline has been documented for the mucosal lymphatics of the upper lip. Lymphatic channels from nodes located in the submental, submandibular. And periparotid areas drain into the lymph nodes of the upper and occasionally the middle deep jugular lymphatic chain.

Buccal mucosa:

The buccal mucosa includes the entire membrane lining of the interior surface of the cheek and lips, from the opposing lip's line of contact to the pterygomandibular raphe posteriorly and to the line of attachment of the alveolar ridge mucosa above and below. The buccal mucosa forms the lateral wall of the oral vestibule. Tumours of the buccal mucosa may extend laterally through the buccinator muscle to involve the buccal fat pad posteriorly or subcutaneous tissues and skin of the cheek.

Lymphatics of the buccal mucosa arise from a submucosal network and drain to lymph nodes located in the submental and submandibular triangles.

Upper and lower alveolar ridges:

The alveolar ridges include the alveolar processes of the mandible and maxilla and their mucosal covering that, in the case of the lower alveolar ridge, extends from the line of attachment of mucosa in the buccal gutter to the line of the free mucosa in the floor of the mouth. Posteriorly, the lower alveolar ridge's mucosa extends to the

ascending ramus of the mandible. The upper alveolar ridge's mucosa extends from the line of attachment of mucosa extends from the line of attachment of mucosa in the upper buccal gutter to the junction of the hard palate. Its posterior margin is the upper end of the pterygopalatine arch.

Lymphatics of the buccal aspect of the upper and lower alveolar ridges drain into the submental and submandibular lymph nodes. Lymphatic from the lingual aspect of the upper and lower gingival pass chiefly to upper deep jugular and lateral retropharyngeal lymph nodes. Some channels may drain to lymph nodes adjacent to the tail of the parotid gland (subparotid). Lymphatics from the lingual surface of the lower alveolus also may end in submandibular nodes.

Retromolar trigone:

The retromolar trigone is the attached gingival overlying the ascending ramus of the mandible. The distal surface of the last lower molar forms the base of this triangular area, and its apex terminates at the maxillary tuberosity. The upward extension of the oblique line of the mandible to the coronoid process forms the triangle's lateral side, and a line connecting the distal lingual cusp of the last molar and the coronoid process forms the medial side. The triangle's base is continuous laterally with the gingivobuccal sulcus and medially with the gingivolingual sulcus. The triangle's lateral side is continuous with the buccal mucosa and the medial side blends into the anterior tonsillar pillars.

The lymphatic drainage of the retromolar trigone is similar to that of the tonsillar fossa, passing to the upper deep jugular chain of lymph nodes. Some lymph channels may also end in subparotid and lateral retropharyngeal lymph nodes.

Hard palate:

The hard palate is a semilunar area consisting of mucous membranes covering the horizontal laminae of the palatine bones. The upper alveolar ridge partly surrounds the hard palate, which extends from the inner surface of the superior alveolar ridge to the posterior edge of the palatine bone. Two or more foramina are located posterolaterally on either side near the junction of the hard or soft palate. The larger is the greater palatine foramen, and behind this are one to two lesser palatine foramina. The foramina represent the lower end of the pterygopalatine canal, through which nerves and vessels are conducted from the pterygopalatine fossa and regions of the skull base. Likewise, the incisive fossa and canal provide a pathway for tumor extension into the nasal cavity.

Similar to the alveolar ridge, the periosteum of the hard palate adheres more intimately to the mucosa than to the bone; thus, the two are referred to as the mucoperiosteum. The mucoperiosteum acts as a temporary barrier to the deep spread of tumor; however, cancers of the hared palate frequently extend into the underlying bone as the disease progresses

Lymphatics of the hard palate are sparse compared with other sites in the oral cavity. Drainage is similar to that of the lingual surface of the upper alveolus. Most of the lymphatics drain into upper deep jugular or lateral retropharyngeal nodes. Lymph channels draining the primary palate may terminate in the prevascular and retrovascular group or submandibular nodes.

Floor of mouth:

The floor of mouth is a crescent-shaped region of mucosa overlying the mylohyoid and hyoglossus muscles, extending from the inner aspect of the lower alveolar ridge to the underside of the anterior two thirds of the tongue. Posteriorly, the floor of the mouth is continuous with the base of the tonsillar pillar, and anteriorly the frenulum of the tongue divides it into two sides.

The lymph vessels of the floor of the mouth spring form an extensive submucosal plexus that forms two discrete systems: a superficial mucosa and a deep collecting system. The superficial system has crossing afferent lymphatic vessels in the anterior floor of the mouth, where no definite midline exists. These channels drain into the ipsilateral and contralateral preglandular lymph nodes. The deep collecting system drains into the ipsilateral preglandular lymph nodes. Only the most anterior collecting vessel of the deep system crosses the midline. Lymph channels from the posterior portion of the floor of the mouth drain directly into the jugulodigastric and jugulocarotid nodes.

Anterior two thirds of the tongue:

The anterior two thirds of the tongue, known as the oral tongue, are considered a part of the oral cavity. The oral tongue is the freely mobile portion of the tongue that extends anteriorly from the line of the circumvallate papillae to the root. The root of the tongue is the undersurface at its junction with the floor of the mouth. The oral tongue consists of four anatomic regions; the tip, the lateral borders, the dorsum, and the undersurface. The base of the tongue is that portion posterior to the circumvallate papillae and is considered a structure of the oropharynx.

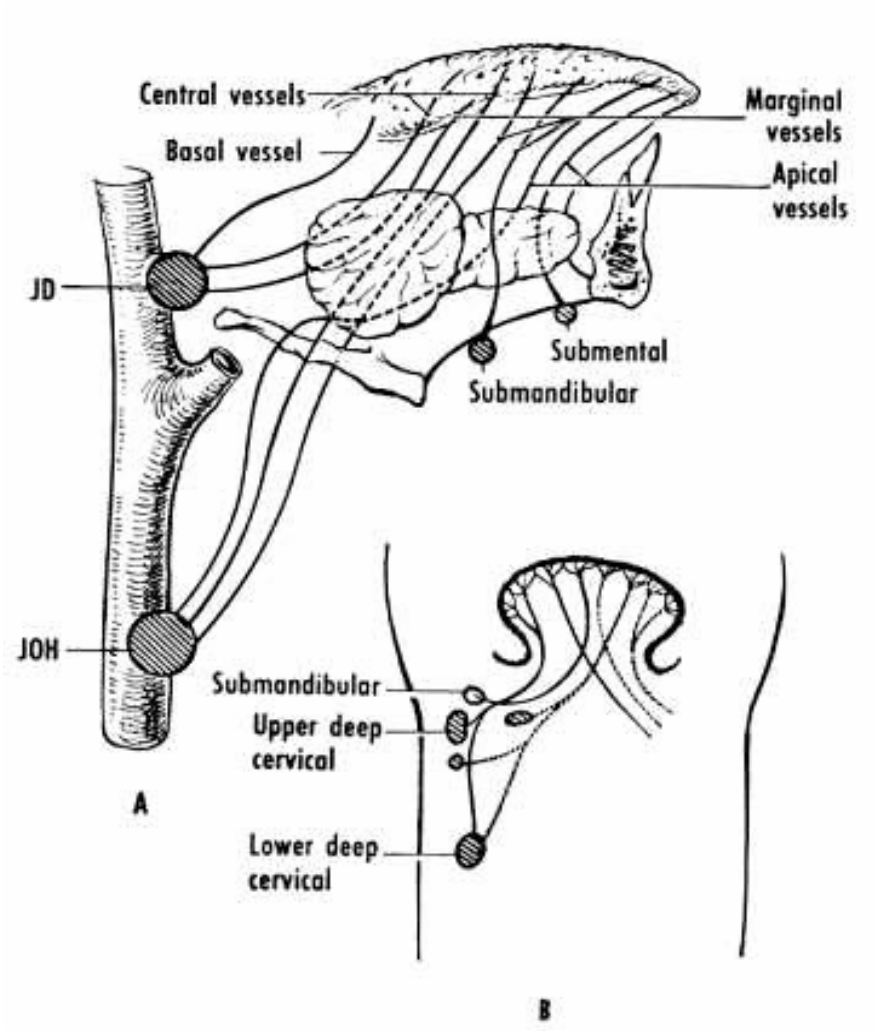

Figure 3. Lymphatic drainage of the tongue.

A, Right lateral aspect. Each cross-hatched circle represents a group of nodes. JD, jugulodigastric nodes; JOH, jugulo-omohyoid nodes.

B, Schematic coronal section. (A is based on Rouviere, B on Jamieson and Dobson.)

Lymphatics of the tongue:

Lymphatics of the tongue arise from an extensive submucosal plexus, and all vessels drain ultimately into the deep jugular lymph nodes between the levels of the digastric and omohyoid muscles. The nearer the tip of the tongue the lymphatics arise, the lower is the first echelon node; and the farther posterior, the higher the node (figure 3). Lymphatic collecting channels of the tongue are the anterior (apex), lateral (marginal), central and posterior groups. Vessels from the apex pierce the mylohyoid to end in submandibular nodes. The remaining trunks drain on either side of the hyoglossus muscle to deep jugular nodes. Lymph channels from the tongue base pass through the pharyngeal wall laterally below the tonsil to reach principally the jugulodigastric nodes.

Cancer of the tongue frequently metastasizes bilaterally, primarily because of the rich lymphatics in the submucosal plexus, which freely communicate across the midline. In addition, collecting lymphatic trunks from the apex, central, and posterior groups have many collecting channels that cross over to terminate in contralateral lymph nodes.

Gross pathology

The gross morphologic growth patterns of squamous cell carcinoma (SCC) that occur in the oral cavity are exophytic, ulcerative, and infiltrative[10]. The exophytic form is the least common, except on the lip. It tends to grow more superficially and metastasize later than the other types. This form begins as an area of thickened epithelium, which heaps up and can protrude 1 cm or more above the surrounding mucosa. Ulceration occurs early in its development. Exophytic carcinomas gradually become deeply

infiltrative in more advanced cases. On the lip this form of tumor may reach a size of 6 or 7cm, with little local destruction of tissue.

The ulcerative type is the most common form of SCC in the oral cavity. It begins as a round or oval ulcer with a gray, shaggy base that bleeds readily. Ulcerative types manifest a greater tendency for rapid infiltration and usually have a higher histologic grade than the exophytic type. The ulcer eventually may heap up and become exophytic or remain lower than surrounding mucosa.

Infiltrative malignancies are common in the tongue and initially appear as a firm mass or plaque covered by mucosa. This type of tumor extends deeply into underlying tissues, with minimal elevation above the surrounding mucosa. As the neoplasm progresses, ulceration and exophytic manifestations may be observed.

A fourth morphologic type of oral cancer is verrucous carcinoma, which is clearly defined but uncommon variant of SCC. It typically occurs in elderly patients who have poor oral hygiene or ill-fitting dentures and most commonly affects the buccal mucosa of men and women with a history of tobacco chewing or snuff dipping. The tumor has a warty, bulky, elevated, and fungating appearance. It does not invade deeply into underlying tissue. Verrucous carcinomas have an indolent behavior and do not metastasize. The characteristic histologic pattern is an undulating, densely keratinized outer layer covering large papillary fronds and a sharply circumscribed, deep margin composed of rows of bulbous, well-oriented rete ridges. The advancing margin appears to push through rather than invade and infiltrate deep tissue.

Histopathology

Broders[14] classified tumors into one of four groups depending on cellular differentiation, as based on the percentage of total cellular elements. The presence of minimal pleomorphism and few mitoses indicated a well differentiated grade I neoplasm. Poorly differentiated neoplasms show extreme pleomorphism, minimal or no keratinization, and frequent mitoses and are classified as grade IV. Most oral cavity cancers are grade I or II.

Regional metastases

Regional metastases portend a worse prognosis for patients with oral cancer. The 5-year survival rate in patients with cervical metastasis is approximately 50% lower than that in patients without clinical evidence of metastases. The prognosis is further worsened in patients with multiple cervical metastases. In addition to the correlation of clinical metastases with decreased survival, histopathologic evaluation of the metastatic lymph nodes is also significant. Patients found to have extracapsular spreads of carcinoma in cervical lymph nodes have been shown to have a statistically lower rate of survival. Despite the extracapsular spread being directly related to the size of cervical nodes, it is apparent that spread is more common in small (N1) cervical nodes than previously appreciated. Extracapsular spread may indicate depressed immunologic surveillance and failure to contain tumor spread. Several studies indicate that the survival rate of patients with cervical metastases where the tumor is limited to the node ranges from 50% to 70% for 5 years. If extracapsular spread of neoplasm occurs, however, 5-year-survival is reduced to less than 30%[10].

Regional metastases are present on initial evaluation in approximately 30% of patients with oral cavity cancer, excluding cancers of the lip and hard palate. The incidence of regional metastases is related to the size of the primary tumor, with larger tumors manifesting a higher incidence. Contralateral or bilateral metastases may develop when the primary tumor is near or crosses the midline. Approximately 25% of patients who show no evidence of regional metastases when first evaluated will eventually develop nodal disease despite control of their original primary tumor.

Clinically apparent cervical lymph node metastases occur in 10% to 15% of patients with SCC of the lip[15] and 15% to 25% of patients with cancer of the hard palate[16]. Subsequent development of regional metastases following control of lip cancer ranges from 5% to 15%. The lower incidence of metastases from hard palate tumors is related to the rather sparse lymphatic supply to this region. The lower metastatic rate of lip cancer occurs because most lip cancers are small and well differentiated when first evaluated.

Distant metastases

Distant metastasis of the tumor eventually occurs in 15% to 20% of patients dying of oral cavity cancer. In such instances regional cervical metastases have been present for prolonged periods. Disseminated neoplasm affects bone and lungs most frequently.

Multiple primary neoplasms

The occurrence of multiple primary neoplasms in patients with head and neck cancer is believed to be as high as 39%. These tumors are described as simultaneous if diagnosed with the primary tumor and synchronous, if diagnosed within 6 months after

diagnosis of the primary tumor. The frequency of second primary tumors in patients with oral cancer in the upper aeordigestive tract is approximately 18%[17] in 50% to 70% of cases and is related to the effects of alcohol and tobacco on the mucosa. Patients at the greatest risk of developing a second primary tumor are those who smoke and drink heavily for many years. The risk of developing additional malignancies in patients who discontinue smoking after control of their first malignancy is one sixth the risk for those who continue to smoke. However, this risk does not appear to decrease until 5 years after ceasing the habit, suggesting that carcinogenic factors are long-term influences. The greatest risk of developing a second primary tumor occurs within the first 3 years after therapy for the first cancer.

MANAGEMENT OF ORAL CANCERS

Symptoms:

The most common symptom of the cancer of the oral cavity is a persistent ulcer in the mouth. The diagnosis is frequently delayed, however, probably because pain associated with ulceration occurs rather late in the course of disease. Dentists may see the patients first because of loosening of the teeth or pain around the teeth or in the jaw. Occasionally, dysphagia may be present, particularly if the tumor is located in the posterior oral cavity or is extending into the oropharynx. A neck mass is seen in one third of patients.

Clinical examination:

Physical examination is the key to diagnosing and evaluating oral cavity cancer. A thorough inspection of the oral cavity along with bi-digital palpation assists the surgeon in assessing the extent of the tumor, particularly in the tongue musculature and the floor of the mouth. Pharyngoscopy and laryngoscopy is performed to evaluate the tumor's extension into regions of the oropharynx. Evaluation of the neck for possible cervical lymph node metastases is essential. Physical examination of the neck remains the most common method of staging neck disease. However, palpation has been reported to have a sensitivity of only about 75%. Sensitivity is increased with the use of imaging studies.

The division of the neck nodes into 7 regions (figure 4) as described at Memorial Sloan-Kettering is accepted universally. These are:

1. Level 1, containing the submental and submandibular nodes.
2. Level 2, containing the upper third of the jugular nodes medial to the sternocleidomastoid muscle has, as its inferior boundary, the plane of the hyoid bone (clinical) or the bifurcation of the carotid artery (surgical).
3. Level 3, containing the middle jugular nodes, is bounded inferiorly by the plane of the cricoid cartilage, (clinical) or the omohyoid (surgical).
4. Level 4, containing nodes in an area defined superiorly by the omohyoid muscle and inferiorly by the clavicle.
5. Level 5, containing the nodes in the posterior cervical triangle.
6. Level 6, containing the nodes in the paratracheal and pretracheal area.
7. Level 7, containing the nodes along the tracheoesophageal groove and superior mediastinum.

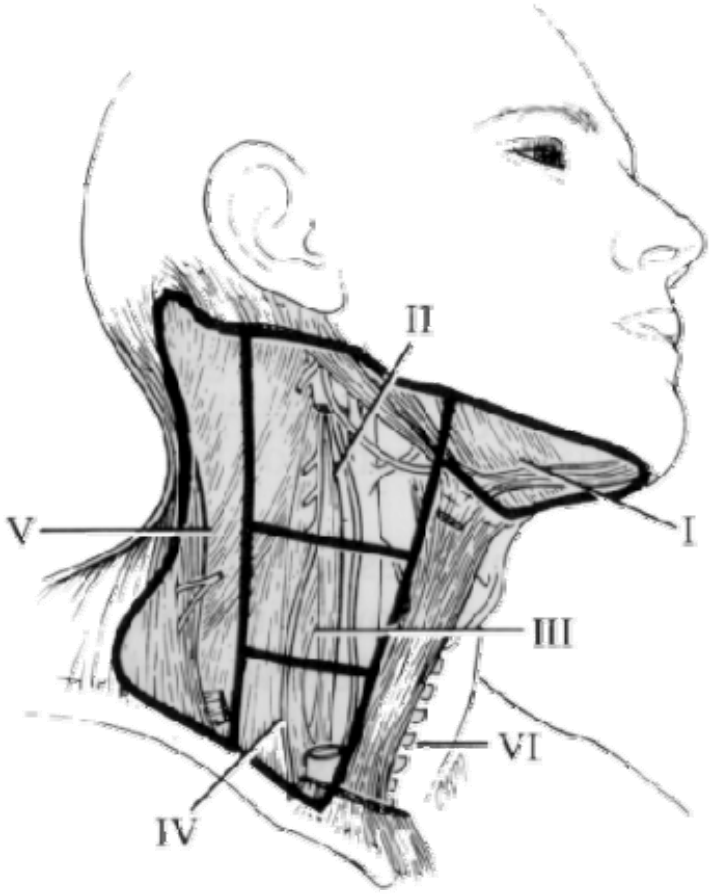

Figure 4. Division of Lymph nodes of the neck

Radiological evaluation:

Radiological imaging is an important adjunct in assessing oral cavity carcinoma that encroaches on the mandible or involves the hard palate. Conventional radiography, including an orthopantomogram, is helpful in determining invasion of bone. As many as 30% of patients with an oral cavity malignancy cancer encroaching on the mandible with normal radiographic finding have microscopic invasion of bone. Bone scanning with technetium-99mphosphate is sensitive enough to be positive in bone involved with tumor before these lesions can be detected by conventional radiographic examination. However, specificity to differentiate between tumor, infection, trauma, and inflammation is lacking.

Computed tomography (CT) is helpful in assessing soft tissue and bony extension of the tumor. CT and magnetic resonance imaging have an approximately equal sensitivity (85% to 95%) for diagnosis of nodal metastases[18]. Ultrasound evaluation can identify lymph nodes not palpable by clinical examination. The criteria used to define a pathologic node will vary the sensitivity and specificity of this technique. Criteria allowing the sensitivity of about 90% can result in specificity as low as 30%. Fine-needle aspiration cytology can be combined with ultrasound to increase its specificity to 90%.[19]Positron Emission Tomography is a recent imaging modality being used in the management of oral malignancies. Comparison between PET and standard techniques revealed that PET had an accuracy of 82%, CT 84%, and physical examination 71%[20].

Staging of Oral Carcinoma:

The American Joint Committee on Cancer Staging (AJCC 2002) recommended the following TNM Staging for head and neck malignancies.

TNM definitions

Primary tumor (T)

TX: Primary tumor cannot be assessed

T0: No evidence of primary tumor

Tis: Carcinoma in situ

T1: Tumor ≤2 cm in greatest dimension

T2: Tumor >2 cm but ≤4 cm in greatest dimension

T3: Tumor >4 cm in greatest dimension

T4: (lip) Tumor invades through cortical bone, inferior alveolar nerve, floor of mouth, or skin of face, i.e., chin or nose

T4a: (oral cavity) Tumor invades adjacent structures (e.g., through cortical bone, into deep [extrinsic] muscle of tongue [genioglossus, hyoglossus, palatoglossus, and styloglossus], maxillary sinus, and skin of face)

T4b: Tumor invades masticator space, pterygoid plates, or skull base and/or encases internal carotid artery

Regional lymph nodes (N)

NX: Regional lymph nodes cannot be assessed

N0: No regional lymph node metastasis

N1: Metastasis in a single ipsilateral lymph node, ≤3 cm in greatest dimension

N2: Metastasis in a single ipsilateral lymph node, >3 cm but ≤6 cm in greatest dimension; or in multiple ipsilateral lymph nodes, ≤6 cm in greatest dimension; or in bilateral or contralateral lymph nodes, ≤6 cm in greatest dimension

N2a: Metastasis in a single ipsilateral lymph node >3 cm but ≤6 cm in dimension

N2b: Metastasis in multiple ipsilateral lymph nodes, ≤6 cm in greatest dimension

N2c: Metastasis in bilateral or contralateral lymph nodes, ≤6 cm in greatest dimension

N3: Metastasis in a lymph node >6 cm in greatest dimension

Distant metastasis (M)

MX: Distant metastasis cannot be assessed

M0: No distant metastasis

M1: Distant metastasis

AJCC stage groupings

Stage 0

- **Tis, N0, M0**

Stage I

- **T1, N0, M0**

Stage II

- **T2, N0, M0**

Stage III

- **T3, N0, M0**
- **T1, N1, M0**
- **T2, N1, M0**
- **T3, N1, M0**

Stage IVA

- **T4a, N0, M0**
- **T4a, N1, M0**
- **T1, N2, M0**
- **T2, N2, M0**
- **T3, N2, M0**
- **T4a, N2, M0**

Stage IVB

- **Any T, N3, M0**
- **T4b, any N, M0**

Stage IVC

- **Any T, any N, M1**

Treatment

The therapeutic modalities include surgical excision, radiotherapy, chemotherapy, or a combination of these modalities. The treatment employed depends on the tumor's extent and location, the patient's physical and social status, and the physicians experience

and skill. Generally, either surgery or irradiation is successful in controlling small tumors confined to the site of origin (stage I & II). The main advantage of radiotherapy is the avoidance of surgery, anesthesia and their associated risks. Radiotherapy is particularly advantageous for ill-defined neoplasms located posteriorly that make surgical exposure and resection more difficult. The major disadvantage of radiotherapy is the often permanent xerostomia and dysgeusia. Full-mouth tooth extractions may be required before instituting therapy to avoid the risk of progressive deterioration of the teeth and the development of osteoradionecrosis.

Small, anteriorly located cancers of the oral cavity may be amenable for surgical resection. The surgical defect may be closed primarily, skin grafted, or allowed to heal by secondary intention without significant functional impairment. The advantages of surgery include the avoidance of xerostomia and the rapid rehabilitation of the patient. The major disadvantage is the functional disability, which is directly related to the extent of resection of the mandible or tongue.

Radiotherapy

There are four principles governing the use of radiotherapy in the management of oral cancer:

(1) Most squamous cell carcinomas are radio-responsive, although high doses of radiation are required for local control.

(2) Well-oxygenated neoplasms are more radio-responsive than hypoxic neoplasms.

(3) Bone or deep muscle invasion decreases radiocurability.

(4) Large cervical metastases are better managed by neck dissection, with or without adjunctive radiotherapy.

Radiotherapy is indicated when survival is equal to, and morbidity is less than surgery alone or combined therapy. Radiotherapy can be given as external-beam management, interstitial therapy (brachytherapy), or a combination of the two. The total dose of radiotherapy for oral carcinomas is usually in the range of 65 to 75 Gy. The dose may be modified according to the tolerance level of the patient. The goal is to maximize local control but minimize complications such as osteoradionecrosis.

Conventional fractionation external-beam radiotherapy is usually administered at a dose of 1.8 to 2.0Gy per fraction five times per week. The fractionation schedule may have a significant impact on locoregional control. Fraction size is known to be the major factor in determining late effects or complications. Hyperfractionation involves smaller than conventional dose fractions given twice a day to a greater total dose. .

Interstitial irradiation (brachytherapy) is frequently used in combination with external radiotherapy to treat cancers of the tongue and floor of the mouth. Much larger doses are given to the tumor than to the surrounding region with use of temporary implants of iridium-192 via hollow catheters and afterloading techniques.

Prophylactic neck irradiation

Occult metastases consist of microfoci tumors in cervical nodes that are not clinically detectable. The incidence of occult metastases varies with site and size of the primary tumor in the oral cavity and ranges from 15% to 60%. Prophylactic neck

irradiation can be used for the treatment of occult metastases. Reports indicate that radiotherapy of the clinically negative neck to a level of 50 to 55 Gy controls occult disease and prevents late occurrence of cervical metastases[21]. When the primary cancer of the oral cavity remains controlled, development of cervical nodal disease is less than 5% in patients undergoing prophylactic neck irradiation. This statistic is in contrast to an expected 25% failure rate in patients initially having N0 classified necks and receiving no neck treatment[22].

Prophylactic irradiation of the neck relieves the patient of the functional and cosmetic deformity of neck dissection. Neck fibrosis is not a serious problem when 50Gy administered over 5 weeks. However, xerostomia may occur as a result of encompassing submandibular and parotid glands in the irradiated fields. Although prophylactic neck irradiation appears to be at least as effective as elective neck dissection in the management of occult neck disease, prospective randomized studies are needed for conclusive evidence on support of one modality or the other.

Surgery

Local surgical excision may be used for malignancies of the oral cavity measuring 2 cm or less. Carcinomas of the oral cavity with invasion of the mandible are less radiocurable than are neoplasms confined to soft tissue. Thus, when a neoplasm directly invades the mandible, surgery is the preferred treatment. Surgery is also indicated in advanced tumors of the oral cavity.

The high incidence of microscopic invasion of the periosteum and cortical layer of the mandible even with normal radiographic findings has warranted guidelines for surgical management of the mandible. Tumors that encroach on the mandible and do not provide a margin of 1.5 cm of normal tissue between tumor and bone usually require resection of at least a portion of the mandible. Depending on the location of the neoplasm, a marginal resection of the upper portion of the mandible or resection of the inner or outer cortical plate of the jaw may provide and adequate margin around the tumor while still preserving mandibular continuity. Direct invasion of the mandible requires a full-thickness segmental resection of the mandible.

Surgery is also indicated in patients who have completed a full course of radiotherapy and demonstrate persistent tumor or suffer recurrence at the primary site or in the neck. Incomplete healing of the primary site immediately following full-course radiotherapy should be observed closely, allowing 8 to 12 weeks to elapse before biopsy. If tumor is persistent, en bloc resection is indicated, including the entire area of the original tumor. If clinically positive lymphadenopathy was present before irradiation, neck dissection is also performed. If radiotherapy controls the primary tumor but the patient continues to have palpable lymphadenopathy, neck dissection without resection of the primary site is indicated.

Neck dissections

Patients with clinically negative necks but extensive primary lesions (T3,or T4) have a high probability of neck metastases. Selective en block removal of the lymph

nodes most likely to harbor metastases is performed by a supraomohyoid neck dissection (zone I, II and III). Patients with no evidence of metastases have improved regional control of disease with the addition of radiotherapy.

Patients with clinically detectable neck disease (N1, N2, or N3) require a neck dissection for optimal disease control. A modified neck dissection sparing the spinal accessory nerve (MRND I) is performed if the neck disease is not in the proximity of the nerve. Patients with clinically detectable neck disease should undergo postoperative radiotherapy to optimize regional disease control.

Lesions located in the midline may cause bilateral metastases. It is therefore important to address both sides of the neck. If both are clinically N0, bilateral supraomohyoid neck dissections can be performed as staging procedures. Bilateral neck dissections should be performed if bilateral disease is noted.

Combined therapy

Most physicians have advocated the combination of radiotherapy and surgery in treating advanced stage III and IV disease of the oral cavity in hopes of reducing local recurrence and improving survival rates. Postoperative radiotherapy has also been shown to be effective in increasing loco-regional control in advanced (stage III or IV) squamous cell carcinoma of the oral cavity[23].

Chemotherapy

Chemotherapy given before other methods of treatment is called *neoadjuvant* or *induction chemotherapy*. Adjuvant chemotherapy involves the use of chemotherapy in

conjunction with other treatments. A variety of agents have been used, including cisplatin, 5-fluorouracil, methotrexate, bleomycin, paclitaxel and topotecan.

Chemotherapy agents can also be given concurrently with radiotherapy. This may result in a radiosensitizing effect and improved loco-regional control. Trials have shown improvement in local control with a trend toward survival, but with significantly increased toxicity.

Follow up: 5- year survival

Cure rates for carcinoma lip T1 and T2 lesions without cervical metastasis is > 90%. With regional metastasis the five year survival drops to 50%. The five year survival rate for stage I and II lesions of Carcinoma tongue amounts to 82% while it is 49% for stage III and IV. In a patient with Carcinoma of the floor of the mouth, the 5 year survival rate is 88% for stage I lesions while it is 32% for stage IV tumours. For carcinoma buccal mucosa and alveolus, stage I disease has a 5 year survival of 75 and 77% respectively and stage IV is 20 and 24 % respectively. Distant metastasis and recurrence have worse prognosis in any site[10].

Facial nodes are the lymph nodes found along the course of the branches of the facial vessels of the face, above the level of the margin of the mandible. The facial nodes are continuous inferiorly with the prevascular and retrovascular lymph nodes of the neck and the latter have been often incorrectly termed as facial nodes[8].

Rouviere classified them into 4 groups based on their site viz. malar, infraorbital, buccinator and mandibular[8, 24, 25]. Tart[12] added another group to these nodes – retrozygomatic.

These nodes receive afferent lymphatics draining the skin, subcutaneous tissues of the face. In addition they have been described to drain the buccal and gingival mucosa as well. The efferent drainage is to the submandibular lymph nodes.

Facial nodes may be involved in metastatic or primary head and neck cancer. There have been several reports of its involvement. These reported primary malignancies include squamous cell or adenocarcinoma of the maxillary sinus, nasopharyngeal carcinoma, tongue, lip, buccal mucosa, preauricular skin, salivary glands and the retromolar trigone. In adults, disease of these nodal groups may be the sole manifestation of a lymphoma[27]. Others include metastatic disease from ocular melanoma and distant sites such as bladder carcinoma [26, 27, 2 8].

The mandibular node has also been termed as the mandibulofacial node and has been found to be enlarged in a number of benign conditions which include infections of the oral and nasal cavities.

The facial node of most interest to the surgeon is the mandibular group, also called the supramandibular group. These nodes are located adjacent to the facial artery, at the anterior border of the masseter muscle, overlying the horizontal ramus of the mandible. The node of *STAR* described in Gray's Anatomy, 1954, as a constant node which is found just where the facial artery crosses the horizontal ramus of the mandible[29].

Lymph nodes of the head and neck

The facial nodes are of importance owing to their close proximity to the marginal mandibular nerve. Surgical techniques that are used to preserve the marginal mandibular nerve such as ligating the facial vein low in the neck and retracting it superiorly to include the nerve in the skin flap may render the removal of these nodes difficult[31].

Sheehan in his retrospective study of 32 hemi-neck dissections reported that 7 patients had metastasis in the facial node, an incidence of 24%[8]. He observed that facial node involvement was much more common with patients with palpable cervical lymphadenopathy. Further, facial node involvement was associated with metastatic cervical lymph nodal disease. The facial node was a first-echelon node in carcinoma of the retromolar trigone. The mean maximum size of a metastatic facial node was (0.7 cm), smaller than that of a non-metastatic node (1 cm). He did not find any significant difference in the T- stage of the primary tumour between patients with positive and negative facial nodes. A significant finding was that positive facial nodes were associated with an increased risk of treatment failure and a poorer survival.

Lymph node metastasis is a well-established negative prognostic indicator in the treatment of squamous cell carcinoma of the head and neck[8]. The presence of lymph node metastasis has been shown to decrease survival by 50%[30]. The determination of whether or not the disease has metastasized to the neck is therefore of critical significance.

Imaging modalities such as ultrasound, computed tomography, and magnetic resonance imaging have been used in N0 neck in an effort to identify patients with occult nodal disease. These techniques are based primarily on size criteria, with nodes smaller than 10 mm not generally considered suspicious. However, nodes as small as 2.0 mm can contain micrometastatic disease. Other factors, such as the size, site, and depth of invasion of the primary tumor, as well as the presence of perineural invasion, have also been implicated in predicting regional metastasis. These techniques, though helpful, have not proved to be completely reliable, and there is still a 20% to 30% incidence of occult nodal metastasis in N0 necks. It has been demonstrated that up to 46% of positive lymph nodes measure less than 10 mm in diameter.[9] Paradoxically, nodes in excess of 20 mm may be histologically benign and enlarged as a result of reactive hyperplasia[32].

Most neck recurrences of oral-cavity carcinomas occur within 2 years. Many studies have documented the rate of regional recurrence to be dependent on pN status: the rate is reported to be 2% to 7% in patients with pN0 neck and 15% to 22% in patients with pN neck. Patients with neck recurrences have a poor prognosis despite salvage treatment.[33] Regional recurrences developed in 4% and 35% of patients with pN0 and pN+ necks respectively. The rate of occult lymph node metastases in patients with cN0 neck has been reported between 11% and 45%. In patients with cN0 neck and a >20% probability of occult metastases, an elective treatment of the neck for diagnostic and therapeutic purposes is generally performed[33]. This 20% threshold would include most oral cavity cancers staged T2 or higher[34].

Studies of lymphatic drainage demonstrated that most regions of the oral cavity drain to neck levels I to III. Furthermore, the prevalence and distribution of lymph node metastases was analyzed on large histologic studies on radical neck-dissection specimens. These observations formed the rationale for the currently most often employed supraomohyoid neck dissection (SOHND) of oral cavity carcinomas in patients with cN0 neck[11].

The presence or absence of occult lymph nodes is one of the major prognostic factors for survival in patients with clinically negative cervical lymph nodes. Most oral cancers are stated by physical examination and/or imaging. The sensitivity of combined physical examination and computed tomography scan is 85% to 90%. However, this still leaves a significant number of clinically N0 patients with sub-clinical neck metastases. Magnano *et al* showed that 13.8% (38/274) of clinically N0 necks contained metastatic disease on histological examination of the specimen. Snyderman *et al* found that 41% of their patients without adenopathy had metastatic disease on histological examination. Khafif *et al* observed that 20% to 50% of clinically N0 patients had occult metastatic disease. These patients presented with clinically evident metastatic nodes within 1 to 2 years. Layland *et al* reported that 7.5% of patients who were staged clinically N0 and received a neck dissection as part of the treatment, were found to be pN1, and 4.5% were pN2. Leemans *et al* demonstrated that the number and size of lymph node metastases relates directly to the probability of death attributable to cancer[35].

The goal of treating the neck with radiotherapy, neck dissection, or a combination of the two is to prevent regional recurrence. Basic histopathological features of cervical metastasis such as node level, number, and size and presence of extra-capsular extension have been shown to be independently associated with increased risk of recurrence. Neck recurrence is almost four times as likely to occur in histopathologically N+ necks compared with N0 necks (9.7% vs. 2.6%)[35].

In patients with locally advanced tumors (T4), clinical nodal status and histological nodal invasion were key prognostic factors[36].

Hence we see the importance placed on the nodal status of the patient and the extent one needs to pursue a line of action that accurately stages the patient for appropriate treatment and prognosis. Given that the metastatic involvement of the facial node has been reported to have a poor prognosis special attention is to be paid to the treatment of patients who would be at such a risk.

Materials and Methods:

Type of study:

This was a prospective, observational, cohort study conducted in a single surgical unit from September 2004 to July 2006.

Ethics: -

As this was only an observational study with no interventions, approval of the Ethics committee was not required.

As this was an observational study, informed consent was not necessary.

Data collection:

Inclusion criteria:

The study was conducted between September 2004 and July 2006. All adult patients with a diagnosis of squamous cell carcinoma of the oral cavity admitted for surgery under the department of General Surgery unit I (Head and Neck Surgery) between September 2004 and July 2006 were included in the study. Patients included in the study were those scheduled to undergo excision of the primary lesion along with some form of neck dissection, either radical or selective. In addition, only those patients in whom the facial node was either palpable and /or positively identified at surgery were included in the study.

Exclusion criteria:

Children were not included in the study. Patients with a clinically palpable facial node but not detectable at surgery were not included. The patients who did not have a facial node identified in the surgery were not included in the study.

Patients undergoing surgical procedures for head and neck malignancies other than oral cavity carcinoma were not included even if the surgical procedure involved a neck dissection. Patients with oral cavity carcinoma other than squamous cell carcinoma were not included in the study. Patients who had pre-operative radiation were not included in the study. Patients who had neoadjuvant chemotherapy were, however included in the study.

Demographics:

At enrolment into the study, the patient's name, sex, age, hospital number was noted. The site of lesion with the clinical TNM staging was also noted. The presence of palpable facial node and neck nodes was noted. The histology of the lesion was recorded. If a patient was administered neoadjuvant chemotherapy, that was also noted, along with the type of chemotherapy and the number of cycles given.

Measurement of Facial Node

At surgery, the facial node was dissected separately from the rest of the specimen. The facial node was measured using a metal scale, taking the greatest dimension in centimeters as the size of the node. The facial node was then sent as a separate specimen for histopathological analysis.

The surgical procedure performed was noted. The pathological report of the entire specimen included gross and microscopic description of the tumor and the number and involvement of neck nodes. The microscopic involvement of facial node by tumor was recorded.

Follow up

All patients had post operative radiotherapy where indicated. The patients were followed up in the out patient department, for a period ranging from 6 weeks to 1 year, depending upon the time of enrollment into the study. At follow up, the patients were examined for recurrence of the disease in the lymph nodal region or the primary site. This was also recorded.

Results:

During the period September 2004 to July 2006, 110 patients underwent a surgical procedure along with a neck dissection for carcinoma of the oral cavity. Of this, the facial node could be positively identified in a total of 25 patients (22.7 %).

Demographics:

There were 19 men and 6 women. This is depicted in figure 5.

Fig 5. Distribution of patients based on gender. (N=25)

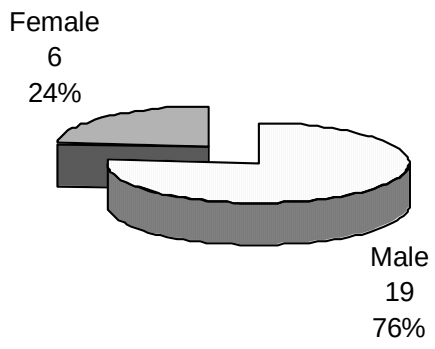

Site of lesion

Most of the patients presented with carcinoma of the tongue (44%) followed by carcinoma of the buccal mucosa (40 %). These results are summarized in figure 6.

Fig 6. Distribution of patients based on the site of Tumour. (N=25)

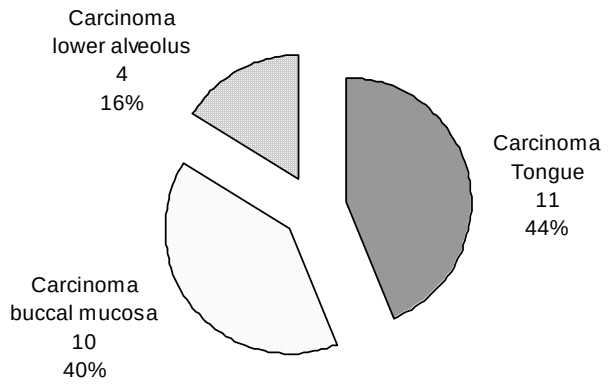

TNM Staging.

Majority (60 %) of the patients had locally advanced disease, with 11 (44%) of the patients clinically diagnosed to have T4 lesions. Only one patient had a T1 lesion. The TNM staging of patients is summarized in figure 7.

Fig 7. Distribution of patients based on the TNM Staging - T stage.

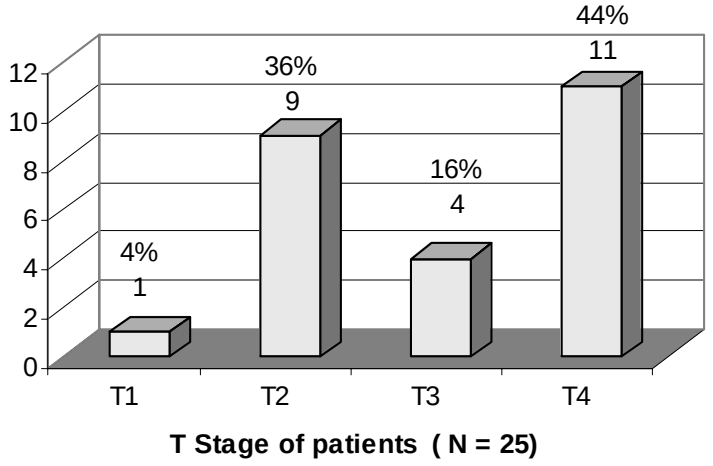

Nodal status.

Out of the 25 patients, 9 (36 %) had no palpable nodes in the neck. There were 11 patients (44%) with N1 nodes. These results are summarized in figure 8.

Fig 8. Distribution of patients based on the nodal status

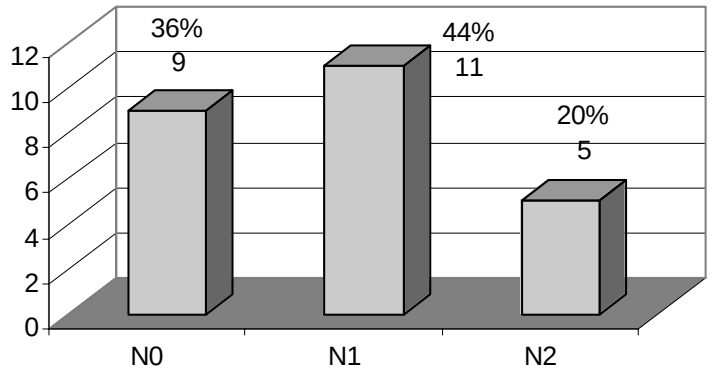

N Stage of the patients (N = 25)

TNM Staging.

Most of the patients (84 %) had advanced malignancies, either in stage III or stage IV. Only 1 patient (4%) had stage I disease. These results are summarized in figure 9.

Fig 9. Distribution of patients based on the TNM Staging. (N = 25)

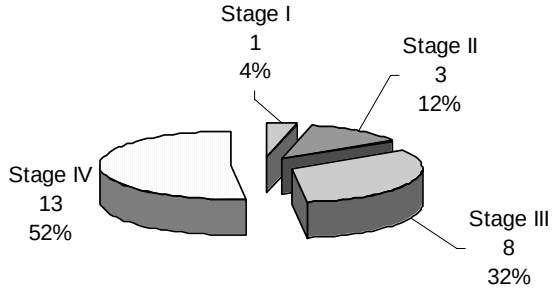

Surgery Performed:

A total of 25 neck dissections were performed. Of this, over half underwent radical neck dissection. Only 3 patients (12 %) underwent supra-omohyoid neck dissection. These results are summarized in figure 10.

Fig 10. Distribution of patients with regards to the Neck Dissection performed. (N=25)

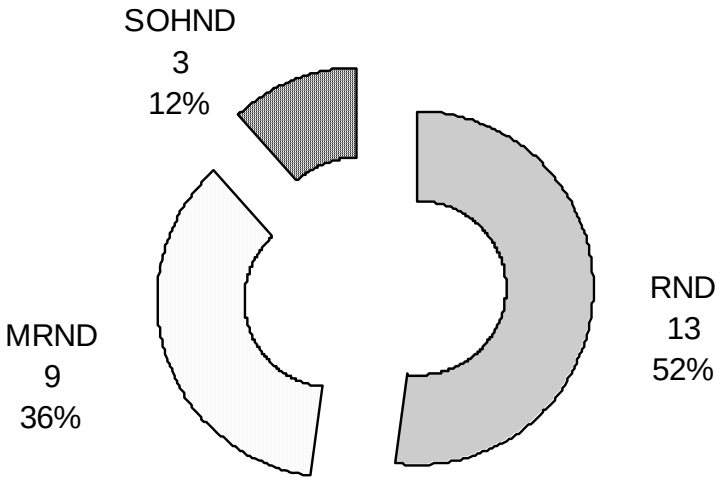

Facial Node

Histopathologically confirmed facial node involvement was present in one patient with carcinoma of the lower alveolus (25%) and 2 patients with carcinoma of the buccal mucosa (20%).

The facial node was clinically palpable in 11 patients (44%) and was positive for metastasis histologically in only three patients (12%). In contrast, of the 25 patients enrolled in the study, 13 (52%) had palpable cervical nodes. At histopathological examination, 9 (36%) had metastatic cervical lymphadenopathy (figure 12).

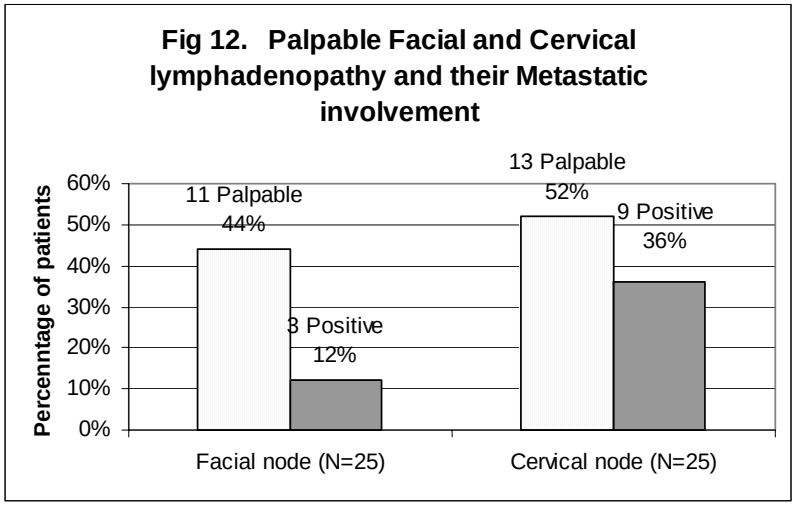

However, on closer examination of the data, only one of the 3 patients with metastatic facial lymph node involvement had a palpable facial lymph node (33%). The other two nodes that were positive for metastasis were nodes that were not clinically palpable. (Figures 13,14) while 5 of the 9 (55.5%) patients with metastatic cervical lymphadenopathy had palpable cervical lymphadenopathy.

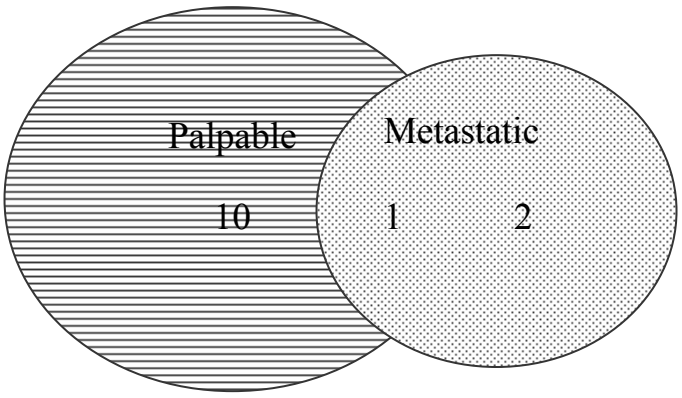

Figure 13. Proportion of palpable Facial nodes that were metastatic

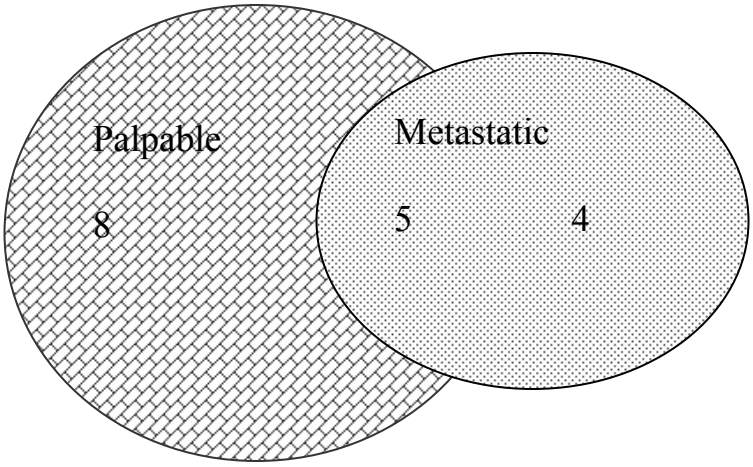

Figure 14. Proportion of palpable cervical nodes which were metastatic.

Of the 11 palpable facial nodes, only one (9%) had metastatic involvement, while of the 13 palpable cervical nodes 5 were metastatic nodes (38%) (figure 15). Palpable facial nodes did not necessarily indicate metastasis.

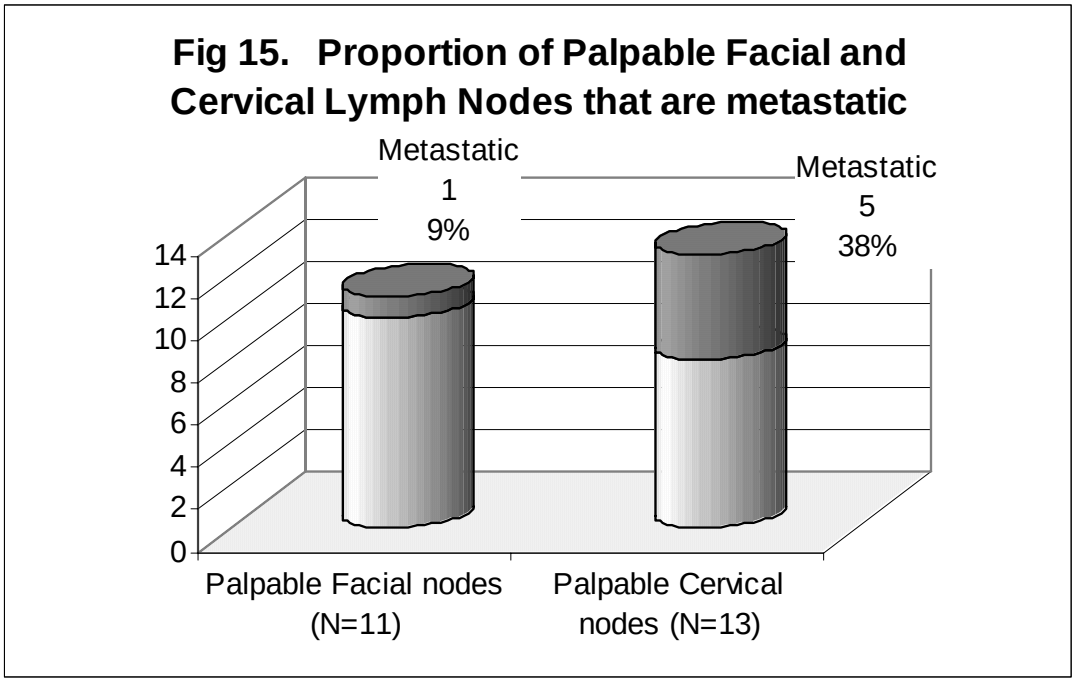

Only one of the three patients with metastatic facial node involvement had associated cervical lymph node metastasis.

Five patients in this group had no palpable cervical or facial lymph nodes. Of these, only one had metastatic deposits on histopathological examination. Clinically impalpable cervical and facial nodes may still have lymph nodal disease.

Node Size

The size of the facial node did not correspond to whether it harbored tumor or not. The median size of the positive facial node was 1.5 cm (1-2 cm) and the median size of a benign enlarged facial node was 1.05 cm (0.5-2.5). The p value was 0.353, (Mann-Whitney U test), which was not significant. The facial node was reported to have reactive hyperplasia in all of the enlarged nodes with no metastasis.

Two of the patients with metastases in the facial node had the facial node as the only node involved. The primary tumours in this case were carcinoma of the lower alveolus and buccal mucosal carcinoma.

Follow Up

All patients with nodal involvement and positive tumour margins were advised post -operative radiotherapy. Four patients developed recurrences within the study period. Of these two had no evidence of cervical and facial nodal metastasis. Of the other two, one each had facial and cervical nodal histologically proven metastasis.

Of the 3 patients with metastatic involvement of the facial node – one died in the hospital due to malignant pleural effusion and one died at home due to unknown causes (figure 16). One patient who had had microscopically involved inferior surgical margin

was advised to have radiation therapy but defaulted and developed local and nodal recurrence 4 months later. Two patients who had cervical metastasis also died. On of the them had a metastatic facial node also.

Fig 16. Mortartality among patients with Lymph node metastasis.

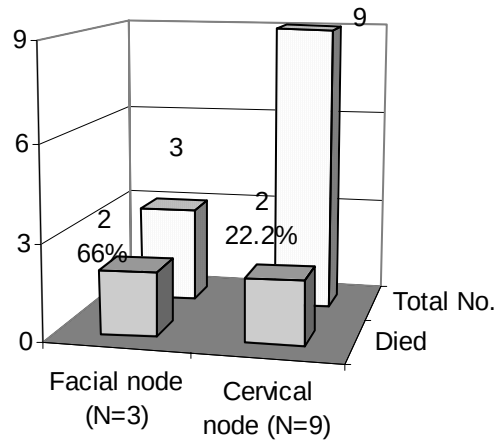

There were four patients with recurrence. All four had local recurrence. One had facial metastasis and nodal recurrence.

Fig 17. Disease recurrence in patients with lymphnode metastasis.

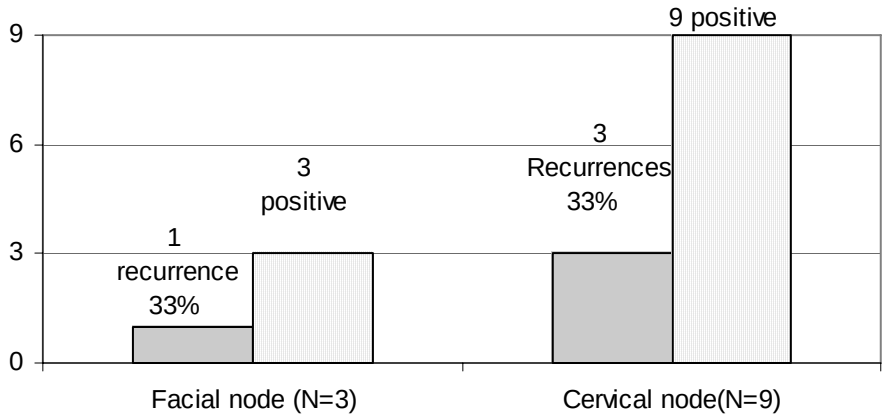

The probability of palpable cervical nodes harbouring metastasis.

	Metastasis present	Metastasis negative	Total
Palpable	5	8	13
Not palpable	4	8	12
Total	9	16	25

Table 1.
Odds ratio = 1.25 {95% CI (0.18< OR>8.76)} insignificant.
Relative risk = 1.15 {95% CI (0.4<RR> 3.31)}insignificant.
Fisher exact 1- tailed p- value = 0.5599677

The odds and relative risk appear to indicate a trend for a palpable cervical node to harbour metastasis. However, this trend was not significant statistically.

The probability of palpable facial nodes harbouring metastasis.

	Metastasis present	Metastasis neg	Total
Palpable	1	10	11
Not palpable	2	12	14
Total	3	22	25

Table 2.
Odds ratio = 0.60 {95% CI (0.20<OR> 10.79)}insignificant.
Relative risk = 0.64 {95% CI (0.70<RR> 6.14)}insignificant.
Fisher exact 1-tailed p- value = 0.5934783

The odds and relative risk of a palpable facial node was less than one suggesting an inverse relationship; i.e., that a palpable facial node is less likely to harbour metastasis than a non-palpable one. However, this was not statistically significant.

Discussion:

In this study, there were more men than women (19 Vs 6). This is in keeping with the rest of the studies that have shown similar ratios. The increased prevalence of tobacco consumption amongst men could be one of the reasons for this.

A majority of the patients presented with advanced malignancies. About 60% patients presented with T3 and T4 lesions. About 64% of patients also had nodal involvement, amounting to 84% of patients presenting with stage 3 or 4 disease.

Out of the 10 patients with carcinoma of the buccal mucosa, 2 (20%) had facial node metastasis. Out of 4 patients with carcinoma of the lower alveolus, one (25%) had facial node metastasis. If one were to assume that a probability of more than 20% occult disease in an N0 neck should be considered as grounds for an elective neck dissection, facial node metastasis in cancers of the buccal cavity and lower alveolus cannot be ignored. In our study, patients with buccal carcinoma and carcinoma of the alveolus were more likely to harbour metastasis in the facial node than in malignancies of the tongue. However, these numbers are too small to make a conclusion.

The Facial node as described in Sheehan et al. and the others drains the buccal mucosa and may be the first echelon node in the metastatic spread of the disease. Further they may be the only nodes involved in the patient as noted in this study – an observation

supported by Sheehan's study. The dissection of the facial node is not routinely performed; infact, the upper limit of a radical neck dissection is generally given as the lower border of the mandible.[31]

Given that the Facial node is an important draining and a first echelon node and its metastatic involvement in carcinomas of the oral cavity was reported to be about unexpectedly high, 24%, it is not known whether the inclusion of the facial node in a radical neck dissection specimen would alter the progression of the disease or affect recurrence and survival. Further studies are needed in this area to clarify this issue..

In this study, the metastatic involvement of the facial node was 12%. This does not support the unusually high incidence of facial node metastatic involvement as noted by Sheehan. However as the number of facial node sampled are only 25, a greater sample size would be required for a statistically significant value.

In this study, though the facial node was palpable in 11 patients, only one (9%) was positive for metastasis. On the other hand, out of the 3 facial nodes found to have tumor metastasis in them, only one (33%) was palpable. This is in contrast with cervical lymph node involvement of the population studied. About 55% of palpable cervical lymphadenopathy was found to have metastatic deposits in them. Hence we observe that the presence of a palpable facial node is more likely to indicate a reactive hyperplasia and not metastatic involvement, while a palpable cervical lymph node is more likely to be malignant.

The 3 patients with metastases in the facial node had advanced carcinoma of the oral cavity. This would suggest that the facial node may be involved generally in the

setting of advanced disease as suggested by Sheehan. Of the three, only one of the nodes was palpable.

A larger node is generally thought to be benign. In this study, I did not find any difference between the sizes of a benign and malignant facial node, though there was a trend towards the metastatic node being larger than a benign node.

Once again, though numbers are too small to make a definite conclusion, it appears that absence of palpable facial nodes does not preclude metastasis to this node. More data is required before a definite conclusion is made that in all neck dissections, the facial node must be dissected out as well.

It is also observed that the patients with facial node metastasis had a poorer outcome. Two patients died shortly after the operation and one had nodal and regional recurrence. The latter had inferior margin involved microscopically and was suggested post operative radiotherapy which he defaulted. This observation confounds the interpretation of the results. However, this observation is similar to that in Sheehan's report. As the numbers of patients studied are few, more number of patients may be required to draw a conclusion of statistical significance.

Relevance and implications of the results:

Facial node metastases may occur as a result of the facial nodes being the first echelon of lymphatic drainage from a primary site involved with carcinoma, or as a result of disturbances to the normal pattern of lymphatic drainage by established cervical metastasis. Given that lymph node metastasis decreases survival and worsens prognosis

of the patient, adequate consideration must be placed on its treatment, as it may be the reason for the nodal recurrence. This study reports an overall 12% involvement of facial node in oral cancers, a 20-25% metastatic involvement of the facial nodes in buccal and lower alveolar carcinoma and a consistently poor prognosis when the node is involved. This warrants special attention to the treatment of this entity.

A palpable facial node does not always indicate metastasis. This may be of significance in our current staging of the disease. Currently the facial node is not taken into account in the staging of oral malignancies. On the other hand, ***clinicians, not specifically looking for a facial node, are likely to club the facial node with a level I lymph node and thus staging the patient higher.*** While our sample size is small, this distinction is important. ***Subjecting all patients to neck dissections is likely to give a positive yield of a less than 10%.***

Summary and conclusions:

- The metastatic involvement of the facial node was 12% in patients with oral squamous cell carcinoma.
- Palpable facial nodes were more likely to be benign.
- The facial node may be a first echelon node in some buccal and lower alveolar squamous cell carcinomas and its involvement may be upto 20% in these sites. In the light of this, it is suggested that on these grounds, the facial node be routinely biopsied in the neck dissections for carcinoma of the buccal cavity and lower alveolus.
- Metastasis to the facial node was associated with poor outcome and nodal recurrence.

Limitations:

1. The study had a sample size of only 25 patients over 20 months; this made the numbers too small to make definite conclusions
2. Facial node could not be identified in all the neck dissections performed during the period of the study. This is perhaps due to the fact that there were several surgeons of different caliber performing these operations.
3. The short period of the study does not permit a long follow up. Recurrences could occur later.
4. The histopathological examination did not include a search for micro-metastasis. It is therefore possible that some nodes may be erroneously reported to be free of tumour.

References:

1. Proia,N.K., Paszkiewicz,G.M., Nasca, M.A. . Smoking and Smokeless Tobacco-Associated Human Buccal Cell Mutations and their association with Oral Cancer—A Review. *Cancer Epidemiol Biomarkers Prev 2006;15:*6, June 2006.

2. Parkin,D.M., Pisani,P.,& Ferlay,J. Estimates of the worldwide incidence of eighteen major cancers. *Int J Cancer 1993;*54:594-606.

3. Squamous cell carcinomas of the head and neck. BMJ 2002;325:822–7

4. Padmakumary,G.,& Varghese,C. (2000).1997 Annual Report. Hospital Cancer Registry. Thiruvananthapuram; Regional Cancer Centre, 3-7.

5. American cancer society: Cancer facts and figures, Atlanta, 1996, American cancer society.

6. Taybos,G. Oral Changes Associated with Tobacco Use. *Am J Med Sci* 2003;326(4):,179–182.

7. AJCC Cancer Staging Manual 2002. Sixth Edition page 18.

8.Sheehan, P. Facial node involvement in head and neck cancer. *Head neck* June26 2004;6;531-6.

9. Wensing, B.M, et al. . FDG-PET in the Clinically Negative Neck in Oral Squamous Cell *Carcinoma. Laryngoscope*,2006;116:809–813.

10. Sessions, R.B. Otolaryngology Head & Neck Surgery (3rd edn). St. Louis, Mosby, 1998;1737-57.

11. Som, M.P. Lymph Nodes of the Neck. Radiology, 1987;165;593-600.

12 Tart, R.P., Mukherji, S.K., Avino, A.J., & Stringer, S.P. Mancuso AA. Facial lymph nodes: normal and abnormal CT appearance. *Radiology1993;*88:695-700.

13. Rouviere, H.,. (1932). Anatomie des lymphatiques de h'homme. Paris, France: Masson et Cie.

14. Broder, A.C. Squamous cell epithelium of the lip: a study of 537 cases, *JAMA 1920;*74:656.

15. Baker, S.R., & Krause, C.J. . Carcinoma of the lip*. Laryngoscope* 1980;90:19.

16. Chung, C.K., et al. . Radiotherapy in the management of primary malignancies of the hard palate. *Laryngoscope1950;* 90:576.

17. Black, R.J., et al. Multiple primary tumors of the upper aeordigestive tract, *Clin Otolaryngol.* 1983;8:277

18 Hillsamer. P.J. Improving diagnostic accuracy of cervical metastasis with CT and MRI. *Arch Otolaryngol Head Neck Surg*, 1990;116: 1297.

19. van der Brekel MWM *et al* . Modern imaging techniques and US guided aspiration cytology for the assessment of neck node metastasis: a prospective comparative study, Eur Arch Otolaryngol, 1993;250: 11.

20. Mac Guirt et al. A comparative diagnostic study of the head and neck nodal metastasis using PET. *Laryngoscope*, 1995;105:373.

21. Fletcher, G.H. Elective irradiation of subclinical disease in cancers of the head and neck, *Cancer,1972;* 29:1450.

22. Bagshaw, M.A. Elective irradation of the neck in patients with primary carcinoma of the head and neck. *JAMA 1971;*217:456.

23. Vikram, B., et al. Elective post operative radiation therapy in stages III and IV epidermoid carcinoma of the head and neck, *American Journal of Surgery*,1980;140:580.

24. Ahuja, A.T. Imaging of Head and Neck Cancer. Page 9.

25. Rouviere, H. (1983).Anatomy of the Human Lymphatic System. Ann Arbor, Michigan: Edward Brothers.

26. Goldman,N.C. Malignant lymphoma of the canine fossa. *South Med J* 1980;73:812–813.

27. Robins, J.P., Slaughter, F.H.,& Constable, W.C. Involvement of the buccinator node in facial malignancy. *Arch Otolaryngol 1971;* 94:356–358.

28. Jinkins, J.R Computed tomography of craniocervical lymphatic system: anatomic and functional consideration*. Neuroradiology, 1987;*29:317– 326.

29. Gray, H.(1954). Anatomy of the human body (26th edn). Philadelphia, Lea and Febiger.

30. Alvi, A, & Johnson, J.T. Extracapsular spread in the clinically negative neck (N0): implications and outcome. *Otolaryngol Head Neck Surg,1996;*114:65-70.

31. .Medina, J.E Neck dissection. In: Bailey BJ (Ed): Head and Neck Surgery. Philadelphia, Lippincott – Raven, 1998, 1563-93.

32. Hart, D.R. Sentinel Lymph Node Biopsy in N0 Squamous Cell Carcinoma of the Oral Cavity and Oropharynx. *Arch Otolaryngol Head Neck Surg*. 2005;131:34-38.

33. Zbären, P. Elective neck dissection for carcinomas of the oral cavity: occult metastases, neck recurrences, and adjuvant treatment of pathologically positive necks. *The American Journal of Surgery* 2006;191:756–760.

34. Smith, G.I. Management of the neck in patients with T1 and T2 cancer in the mouth. *British Journal of Oral and Maxillofacial Surgery,* 2004;42(6): 494-500.

35. Layland, M.K. The Influence of Lymph Node Metastasis in the Treatment of Squamous Cell Carcinoma of the Oral Cavity, oropharynx, Larynx, and Hypopharynx: N0 Versus N+. *Laryngoscope* 2005;115629–639.

36. Tankéré, F. Prognostic Value of Lymph Node Involvement in Oral Cancers: A Study of 137 Cases. *Laryngoscope 2000;*110:2061–2065.

Annexure 1. Intraoperative view of the Facial node. (The white mop overlies the mandible.) The clamp points to the facial node..

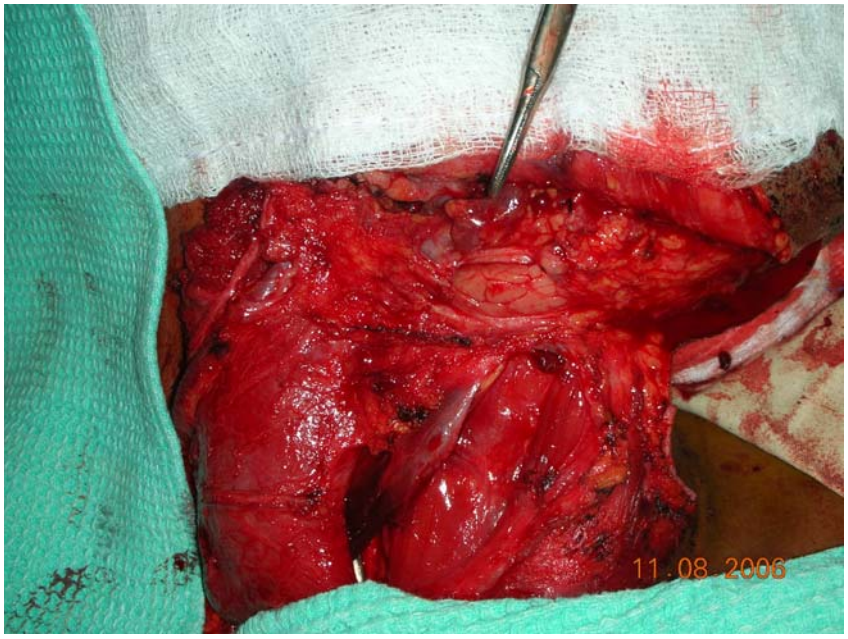

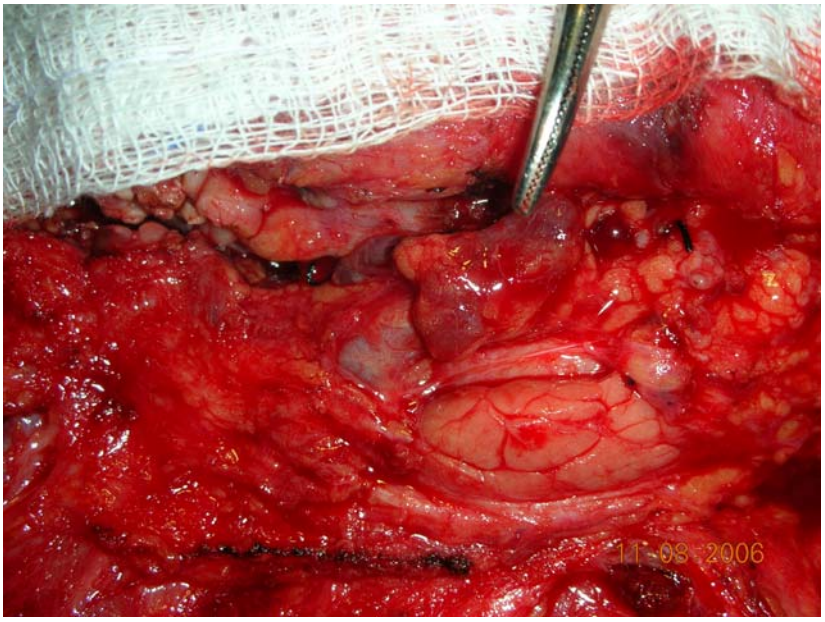

Annexure 2a

serial no	Hosp No	date	Name	Diagnosis	Facial node +/-	Palpable facial node +/-	Palpable cervical LN +/-	Cervial LN metastasis +/-	pre op chemo/rt
1	595549c	30/03/2005	Jagabandhu Acharrya	Carcinoma buccal mucosa left side T3 N1 M0	1	1	0	0	
2	725168a	28/10/2005	Chacko PV	Carcinoma tongue Right side T2N2 M0	0	0	1	1	surgery 2001
3	667096c	17/09/2005	Chandramani Tiwari	Carcinoma tongue Right side T2 N0 M0	0	0	0	0	
4	717631c	11/02/005	Anup Dutta	Carcinoma tongue Right side T2N1 Mo	0	0	1	0	
5	688651b	15/09/2004	Sathyaseelan	Carcinoma tongue right side T4 N0 M0	0	0	0	0	
6	317395b	02/022005	Ramalingam	Carcinoma right buccal mucosa T3 N1 M0	0	0	1	0	
7	578662c	2/3/2005	Badar Ali	Carcinoma right lower alveolus T2 N2 Mo	0	0	0	1	
8	559245c	23/03/2005	Chinnammal	Carcinoma right buccal mucosa T3 N2b M0	0	0	1	1	Neoadj chemo
9	588131c	30/03/2005	Upendra Prasad Srivatsav	Carcinoma right buccal mucosa T4 N1 M0	0	1	1	0	Neoadj chemo
10	634506c	17/05/2005	Kanika Das	Carcinoma tongue right side T2 N1 M0	0	0	1	1	
11	615981c	6/1/2005	Shail Mishra	Carcinoma Left lower Alveolus T4 N1 M0	0	1	0	0	Neoadj chemo
12	634896c	15/06/2005	Kanthamma	Carcinoma right buccal mucosa T2N1 M0	0	1	1	0	
13	099398c	6/10/2005	Parthasarthy	Carcinoma tongue left side T2 No Mo	0	1	0	0	
14	555545c	6/7/2005	Gopen Mech	Carcinoma right lower alveolus T4 N1 Mo	0	0	1	0	Neoadj chemo
15	680090c	24/8/2005	Prasanth Ranjan	Carcinoma tongue right side T1 M0 N0	0	0	0	0	
16	682368c	5/10/2005	Reeba Dey	Carcinoma tongue left side T4 No Mo	0	1	0	1	
17	706799c	2/11/2005	Rajamma	Carcinoma right lower alveolus T4 N2 Mo	1	0	1	0	
18	723760c	7/11/2005	Gaya Prasad	Carcinoma buccal mucosa left side T4 N0 M0	0	1	1	0	
19	731550c	11/1/2006	Jayaprakash Singh	Carcinoma buccal mucosa left side T4 N0 M0	0	0	0	0	Neoadj chemo
20	652989c	18/01/2006	Kandaswamy	Carcinoma right buccal mucosa T4 No Mo	0	1	1	0	
21	747803c	8/2/2006	Mary Verghese	Carcinoma tongue right side T4 N1 M0	0	0	1	1	Neoadj chemo
22	773481c	16/03/2006	Anrudh Shaw	Carcinoma right buccal mucosa T4 N2 Mo	1	0	1	1	
23	769016c	30/03/2006	Vinodh Kumar Singh	Carcinoma tongue left side T3 N1 Mo	0	1	0	1	Neoadj chemo
24	847134C	7/7/2006	Sandeep Kumar Das	Carcinoma tongue left side T2 N1 Mo	0	1	0	1	
25	796833c	3/6/2006	Ajith Mondal	Carcinoma buccal mucosa right side T2N0M0	0	1	0	0	

serial no	Name	Node size	recurrence	remarks	surgery done
1	Jagabandhu Acharrya	2	1	inferior mucosal margin involved. Advised immediate RT but defaulted. 4 months later had local and nodal recurrence	Left Composite resection + MRND + Flap
2	Chacko PV	1	0		Rt hemiglossectomy + MRND 3 + post op RT
3	Chandramani Tiwari	1	0		Rt WLE+MRND + RT
4	Anup Dutta	1	1	Rt submandibular region recurrence	Rt WLE+MRND3
5	Sathyaseelan	1	0		Subtotal glossectomy + MRND + post op RT
6	Ramalingam	1	0		WLE + SOHD
7	Badar Ali	1	0		Rt composite resection + RT
8	Chinnammal	1	1	local recurrence	LEFT COMPOSITE RESECTION AND PECTORALIS MAJOR FLAP
9	Upendra Prasad Srivatsav	2	0		WLE+SOHD +STSG
10	Kanika Das	2	0		WLE+ MRND1
11	Shail Mishra	1	0		Left Composite resection + RT
12	Kanthamma	1	1	ant, sup, inf margins involved, had local recurrence and then underwent RT composite resection	WLE+STSG + RT followed by RT composite resection
13	Parthasarthy	2	0		WLE + MRND
14	Gopen Mech	1	0		Hemimandibulectomy + RND +Fibular graft
15	Prasanth Ranjan	2	0		Rt composite resection
16	Reeba Dey	1	IP DEATH	IP DEATH	COMPOSITE RESECTION OF THE LEFT SIDE ,MODIFIED RADICAL NECK DISSECTION + PECTORALIS MAJOR FLAP RECONSTRUCTION
17	Rajamma	1		DIED	Right Composite resection with Pectoralis Major Flap
18	Gaya Prasad	2	0		L composite resection + MRND + forearm flap + postop RT
19	Jayaprakash Singh	1			Composite resection + RT
20	Kandaswamy	1	0		WLE +Rr RND + L radial free forearm flap
21	Mary Verghese	1	0		RIGHT COMPOSITE RESECTION + PECTORALIS MAJOR MYOCUTANEOUS FLAP
22	Anrudh Shaw	2	IP DEATH	IP DEATH	Right composite resection with partial maxillectomy with Left Radial forearm free flap reconstruction
23	Vinodh Kumar Singh	3	0		Left composite resection + RND + FLAP
24	Sandeep Kumar Das	1	0		WLE TONGUE + MRND III
25	Ajith Mondal	2	0		WLE + SOND

Annexure 3

Proforma:

Name of the patient:

Hospital Number :

Age:

Sex:

Date:

Diagnosis:

Neoadjuvant chemo or Radiation:

Previous surgery if any:

Palpable facial node +/-:

Palpable cervical nodes +/-:

Operation done:

Diameter of the facial node:

Facial node metastasis +/-:

Cervical node metastasis +/-:

Post op Radiation or Chemotherapy:

Recurrence or follow up: