

**HISTOPATHOLOGICAL SPECTRUM OF OVARIAN TUMORS:  
A DESCRIPTIVE STUDY**



Dissertation submitted in

Partial fulfillment of the regulations required for the award of

**M.D. DEGREE**

**IN**

**PATHOLOGY**



**THE TAMILNADU**

**DR.M.G.R. MEDICAL UNIVERSITY,**

**CHENNAI**

**MARCH 2011**

## **CERTIFICATE**

This is to certify that the dissertation entitled “Histopathological spectrum of ovarian tumors – A descriptive study” is a record of bonafide work done by Dr. Darshana S. Patil in the Department of Pathology, Coimbatore Medical College, Coimbatore and submitted in partial fulfillment of the requirements for the award of M.D. Degree in Pathology by the Tamilnadu Dr. MGR University, Chennai. This work has not previously formed the basis for the award of a degree or diploma.

**Dr. M. Murthy, M.D.**

Professor and Head,

Department of Pathology,

Coimbatore Medical College,

Coimbatore - 14.

**Dr. R.Vimala, M.D.**

Dean,

Coimbatore Medical College,

Coimbatore - 14.

## **ACKNOWLEDGEMENT**

I express my deep gratitude to Dr. R.Vimala M.D. Dean, Coimbatore Medical College, for granting me permission to undertake this study.

With an immense sense of gratitude, I humbly thank Dr. M.Murthy, M.D. Professor and Head, Department of Pathology, Coimbatore Medical College, for his scholarly guidance, advice and for having rendered his valuable time and encouragement, without which this study would not have been feasible.

I express my heartfelt thanks to all Additional Professors and all Assistant Professors of Department of Pathology, Coimbatore Medical College, for their constant support and encouragement throughout the work. I thank all the technical staff of Department of Pathology, Coimbatore Medical College, for their sincere and timely technical assistance.

I thank my family members for their blessings and moral support.

Above all I thank The almighty for all his blessings.

# CONTENTS

<b>SR.NO.</b>	<b>PARTICULARS</b>	<b>PAGE NO.</b>
1.	INTRODUCTION	1
2.	AIMS AND OBJECTIVES	4
3.	NEED FOR THE STUDY	5
4.	REVIEW OF LITERATURE	6
5.	MATERIAL AND METHODS	36
6.	OBSERVATION AND RESULTS	39
7.	DISCUSSION	55
8.	SUMMARY AND CONCLUSION	67
9.	BIBLIOGRAPHY	
10.	ANNEXURES	
	Annexure I - Proforma	
	Annexure II - H & E Stain procedure	
	Annexure III - PAS Stain procedure	
	Annexure IV - Reticulin Stain Procedure	
	Annexure V - Immunohistochemistry Procedure	
	Annexure VI - Master chart	

# INTRODUCTION

---

Ovarian cancer is the fifth most common malignancy among women and second most common gynecologic malignancy. It is the most common cause of death due to malignancy of female genital tract.<sup>1</sup> Ovarian malignancies constitute about 4% of the total cancers in females and 25% of malignant tumors of the female genital tract.<sup>2</sup> In India, the ovary is next in importance to cervix as the seat of cancer of female genital tract. Surface epithelial ovarian tumors constitute two thirds of all ovarian tumors and malignant forms account for 90% of ovarian cancers.<sup>3</sup> They exist in different histological patterns and exhibit varying degree of aggressiveness.<sup>4</sup>

Ovary is subjected to monthly endocrine and traumatic insults during normal ovulatory cycles and becomes susceptible to tumorigenesis. Repeated ovulatory rupture and repair theoretically creates opportunities for malignant gene mutations. This may explain the apparent protective effects of oral contraceptives, late menarche, early menopause, multiparity, and breast feeding. Each of these factors decrease the occurrence of ovulation.<sup>5</sup> Although no age group is free

from the tumors, different tumors tend to involve different age groups preferentially. The complex anatomy of the ovary and its peculiar physiology with the constant cyclical changes from puberty to menopause give rise to number of cell types, each of which is capable of giving rise to tumors. Both primary and secondary tumors of the ovaries are relatively frequent showing a variety of histopathological patterns.<sup>6</sup> Since germ cells are totipotential, it is not surprising that a very wide variety of neoplasms may develop from them. Germ cell tumors are the commonest ovarian neoplasms in young age group and constitute two thirds of ovarian tumors in this age group, out of which one third are malignant. These tumors account for 25-30% of all ovarian tumors, with great majority of them in the category of mature cystic teratoma, the most common variety of ovarian neoplasm in humans.<sup>3</sup> Ovarian tumors in children and adolescent girls constitute an important part of gynecological oncology. Detection of these tumors at such a young age creates much anxiety to parents and throws up a great challenge to doctors in charge as the question of operative safety, chance of malignancy and prospects of future child bearing associated with treatment. Practice of fertility sparing surgery, replacement of

radiotherapy by chemotherapy and arrival of newer chemotherapeutic drugs has made the prognosis much better today. The main aim lies in distinguishing ovarian neoplasms from the wide spectrum of non-neoplastic lesions. Despite the new techniques in imaging and clinical diagnosis, the diagnosis of ovarian tumors is primarily dependent upon histopathological examination.

Determination of various histologic patterns of ovarian tumors is very important in diagnosis as well as prognosis of ovarian tumors. Prognosis of the tumors can also be predicted from the degree of differentiation of the tumors. The stage and laterality of the tumors also indicates their nature for example, tumors in the sex cord stromal category are almost always confined to a single ovary. On the other hand, approximately 65% of the metastatic tumors are bilateral. In this study, it was aimed to find out the histopathological patterns which are more prevalent in our population and whether they are significantly different from other populations.<sup>7</sup> Their characteristics with regard to age, size, laterality, gross features were evaluated. Incidence of benign versus malignant tumors was also studied.

## **AIMS AND OBJECTIVES**

---

1. To evaluate the incidence of different histopathological subtypes of ovarian tumors in and around Coimbatore district.
2. To study the incidence of malignancy, both primary and secondary in ovarian tumors
3. To study the distribution of ovarian tumors with respect to various parameters like age, clinical presentation, parity, menstrual status, bilaterality, size, gross features and consistency of the tumors.
4. To study the gross morphological patterns of the various histopathological tumor types.
5. To evaluate the association between various parameters of ovarian tumors and risk of malignancy.



## **NEED FOR THE STUDY**

---

Ovarian tumors pose a major threat to public health worldwide. In global terms, ovarian cancer is the fifth most common cancer in females. Two thirds of ovarian tumors occur in reproductive age group. It has been estimated that one woman in 70 (1.4%) will develop ovarian cancer at some point during her lifetime. Its lower cure rates (less than 40%) result in 6% of total deaths in females.

Thus studying the histopathological spectrum of the ovarian tumors will help to understand the relative incidence of malignancy over benign, distribution of different tumors according to age. Studying the correlation of tumors with various parameters like age at menarche, menstrual status and parity can help to understand the risk factors and pathogenesis of ovarian tumors. This study can also contribute to understand the correlation of gross morphological features with histopathological diagnosis which can certainly help us to arrive at a close differential diagnosis even only with gross examination alone in future.

## REVIEW OF LITERATURE

---

Ovarian neoplasms have become increasingly important not only because of the large variety of neoplastic entities but more because they have gradually increased the mortality rate in female genital tract cancers.<sup>8</sup> As proposed by *Kurman et al*, efforts at early detection and new therapeutic approaches to reduce mortality have been largely unsuccessful, because the origin and pathogenesis of ovarian cancer is poorly understood.<sup>9</sup>

### **Embryological development of the ovary:**

As emphasized by *Harold N et al* in his study, in order to understand the broad range of ovarian tumors and the clinical significance of each tumor, we must review embryological origins of various histological subtypes.<sup>10</sup> The developing ovary contains three types of cell, the oocytes, the follicular cells and the supporting stromal cells.

Oocytes are derivatives of primordial germ cells that can result in germ cell tumors and represent the most common benign or malignant pediatric ovarian masses. Follicular cells are epithelial in origin and are

important in regulation of estrogen production and maturation of follicles. These cells give rise to epithelial tumors which are the commonest adult ovarian tumors. The stromal granulosa and theca cells are mesenchymal in origin. They surround follicular cells, support their development and are the origin of ovarian stromal tumors.

### **Anatomy of the ovary:**

Ovaries are situated one on each side of uterus close to lateral pelvic wall.<sup>11</sup> Each adult ovary measures 3-4 cm in length, 1.5- 3cm in width; 0.6-1.5cm in thickness .The average weight is 5-8 gms.

### **Histology:**

The surface of the ovary is covered by a single layer of cuboidal cells, which forms germinal epithelium that is continuous with the mesothelial covering. Beneath the epithelium a tough connective tissue of tunica albuginea is present under which lies the thicker outer cortex and the inner medulla. Cortex shows follicles at varying stages of maturation.

### **Classification:**

The primary purpose of classification of ovarian tumors is to implement a multidisciplinary approach in management of the patients

affected by ovarian carcinoma. As proposed by *Langley F.A et al*, the classification of ovarian tumors is primarily morphologic but is intended to reflect current concepts of embryogenesis and histogenesis of this complex organ.<sup>11,12</sup> In 1973 World health organization (WHO) gave classification based primarily on gross features. In late 1980, the International Society of Gynecological Pathologists gave a new Classification, which is adopted, as **WHO CLASSIFICATION:**

### ***I. SURFACE EPITHELIAL – STROMAL TUMOURS***

#### **A. SEROUS TUMOURS**

##### 1. Benign

- a. Cystadenoma and papillary cystadenoma
- b. Surface papilloma
- c. Adenofibroma and cystadenofibroma.

##### 2. Of borderline malignancy

- a. Cystadenoma and papillary cystadenoma
- b. Surface papilloma
- c. Adenofibroma and cystadenofibroma

##### 3. Malignant

- a. Papillary cystadenocarcinoma

- b. Surface papillary carcinoma
- c. Malignant adenofibroma and cystadenofibroma.

## **B. MUCINOUS TUMOURS**

Same as for serous tumors except that surface forms are exceptional.

## **C. ENDOMETRIOD TUMOURS**

1. Same as for serous tumors except that surface forms are rare.
2. Stromal and mixed epithelial stromal tumors
  - a. Adenosarcoma
  - b. Stromal sarcoma
    - a. Mesodermal (Mullerian) mixed tumours

## **D. CLEAR CELL TUMOURS**

Same as for serous tumors except that surface forms are not reported.

## **E. TRANSITIONAL CELL TUMORS**

1. Brenner tumor
2. Of borderline malignancy (proliferating)
3. Malignant
4. Transitional cell carcinoma (non Brenner type)

## **G. MIXED EPITHELIAL TUMOURS**

1. Benign

2. Of borderline malignancy

3. Malignant

## **H. UNDIFFERENTIATED CARCINOMA**

### **I. UNCLASSIFIED**

## ***II. SEX CORD-STROMAL TUMOURS***

### **A. GRANULOSA-STROMAL CELL TUMOURS**

1. Granulosa cell tumour

a. Adult

b. Juvenile

2. Tumors in the thecoma-fibroma group

a. Thecoma

i) Typical

ii) Luteinized

b. Fibroma

c. Fibrosarcoma

d. Stromal tumor

e. Sclerosing stromal tumor

f. Signet cell stromal tumor

g. Unclassified

**B. SERTOLI-STROMAL CELL TUMOURS:**

1. Well differentiated

a. Sertoli cell tumour; tubular androblastoma

b. Sertoli-Leydig cell tumour

c. Leydig cell tumour / hilus cell tumour

d. Stromal Leydig cell tumour

2. Of intermediate differentiation

3. Poorly differentiated [sarcomatoid]

4. Retiform

5. With heterologous elements

6. Mixed

**C. SEX CORD TUMOURS WITH ANNULAR TUBULES**

**D. GYNANDROBLASTOMA**

**E. UNCLASSIFIED**

**F. STEROID [LIPID] CELL TUMOURS**

1. Stromal luteoma

2. Leydig cell tumor

a. Hilus cell tumor

- b. Leydig cell tumor non hilar type
- 3. Adrenal cortical type
- 4. Not otherwise specified

### ***III. GERM CELL TUMOURS***

#### **A. DYSGERMINOMA**

#### **B. YOLK SAC TUMOURS**

#### **C. EMBRYONAL CARCINOMA**

#### **D. POLYEMBRYOMA**

#### **E. CHORIOCARCINOMA**

#### **F. TERATOMAS**

- 1. Immature
- 2. Mature
  - a. Solid
  - b. Cystic (Dermoid cyst)
  - c. Secondary tumors transformation of a component
  - d. Fetiform (homunculus)
- 2. Monodermal and highly specialized
  - a. Struma ovarii



- b. Carcinoid
- c. Strumal carcinoid
- d. Mucinous carcinoid
- e. Neuroectodermal tumors
- f. Others

## **G. MIXED GERM CELL TUMORS**

### ***IV. GONADOBLASTOMA***

- 1. Pure
- 2. Mixed with dysgerminoma or other form of germ cell tumor

### ***V. GERM CELL- SEX CORD- STROMAL TUMORS***

### ***VI. TUMOURS OF RETE OVARIUM***

- 1. Adenoma and cystadenoma
- 2. Carcinoma

### ***VII. MESOTHELIAL TUMORS***

### ***VIII. TUMOURS OF UNCERTAIN ORIGIN***

- 1. Small cell carcinoma hypercalcemic type
- 2. Tumor of wolffian origin
- 3. Hepatoid carcinoma
- 4. Paraganglioma

5. Wilms tumor

***IX. SOFT TISSUE TUMOURS NOT SPECIFIC TO OVARY***

***X. UNCLASSIFIED TUMOURS***

***XI. SECONDARY [ METASTATIC ] TUMOURS***

***I. SURFACE EPITHELIAL – STROMAL TUMORS:***

As seen in study by *Ramesh Dawar et al (2004)* this category constitutes almost two thirds of all ovarian tumors. 90% of all ovarian cancers are surface epithelial carcinomas.<sup>13</sup>

They are subclassified according to following patterns:

- 1) Cell type: serous / mucinous / endometrioid / clear / transitional
- 2) Exophytic / Intracystic
- 3) Pattern of growth: cystic / solid
- 4) Amount of epithelium / stroma (adenoma / adenofibroma)
- 5) Cell proliferation, nuclear atypia and stromal invasion:

Benign / borderline / malignant.

***A. SEROUS TUMORS:***

These tumors comprise 30-40 % of all ovarian tumors and are common in 4-5<sup>th</sup> decade of life. Among these, as seen in study by *Mario*

*M. Leitao et al*, 70% are benign, 5-10% are borderline and 20-25% are malignant.<sup>14</sup> Bilaterality is present in 12-20% cases.

**1) Benign serous tumors:**

Grossly these are usually endophytic cystadenomas but may be exophytic surface papillomas. Grossly, they are unilocular thin walled cysts filled with serous fluid with smooth inner surface. Multiloculation, mucinous contents and polypoid excrescence may also be seen. Microscopic examination reveals fallopian tube like epithelial lining. Stroma may be collagenous or markedly edematous. In cystadenofibromas, glands and cysts are scattered within predominantly fibrous stroma.

**2) Serous borderline ovarian tumors:**

They constitute 25-30% of malignant serous tumors with 30% bilaterality. The decision whether an ovarian serous tumor is malignant or borderline is made purely on the basis of morphologic features of primary ovarian tumor regardless of presence or absence of peritoneal, lymph node or even lung metastasis.<sup>15,16</sup> These tumors are separated from carcinoma by the absence of stromal invasion. These tumors are composed of uni/multilocular cysts lined by varying amount of polypoid

excrecences. Microscopy shows stratified cuboidal to columnar pithelial cells and ciliated cells. As revealed by *Seidman JD et al*, arborizing papillae / hierarchical branching, varying nuclear atypia and absence of frank stromal invasion characterize them.<sup>17</sup>

**Micropapillary Variant:**

Histologically it is characterized by an exuberant cellular proliferation that emanates from the surfaces of fibrous papillae without hierarchical branching.<sup>18,19</sup>

**Peritoneal implants:**

The serous borderline tumors are associated with implants in 30% of cases. These are divided into non-invasive and invasive types. Non invasive which constitute 88% of all, are further subdivided into epithelial and desmoplastic types.

**3) Malignant serous tumors:**

Serous carcinomas account for about 30 % of all ovarian cancers. These range in size from microscopically undetectable to over 20 cm in diameter and are bilateral in one third of cases as seen in study done by *CM Shahbaz Sarwar et al.*<sup>20</sup> Grossly they show predominant solid growth patterns with areas of hemorrhage and necrosis. Microscopic

examination reveals obvious stromal invasion with high grade nuclear features and irregularly branching highly cellular papillae with little or no stromal support. Psammoma bodies are commonly seen. As revealed in study by *Naseer A Shaikh et al*, the majority of patients present at advanced stage when the prognosis is poor.<sup>21</sup>

## **B) MUCINOUS TUMORS:**

These tumors account for 10-15% of all ovarian tumors.<sup>22</sup> They generally occur in older women. They may be associated with dermoid cysts, Brenner tumors or mucinous tumors of other organs.

### **1) Benign mucinous cystadenoma:**

These tend to be largest of all ovarian tumors. Most of these tumors are usually unilateral multilocular cystic masses containing viscous mucoid or watery material. Microscopically they show cysts or glands lined by mucinous columnar epithelium with minimal cellular stratification and basally located bland nuclei.

### **2) Borderline mucinous cystadenoma:**

The lining epithelium shows stratification not more than 3 layers and may form filiform intracystic papillae with absent frank stromal invasion.

Depending on the lining epithelium of cysts, these are classified as:

Intestinal type (85%) and Endocervical /mullerian type (15%) As in study by *Shappell et al*, borderline tumors are qualified as intraepithelial carcinoma based on the presence of marked cytologic atypia or a complex cribriform growth pattern involving the epithelium covering the surface of papillae or lining cystic spaces. Tumors with stromal invasion  $\leq 5$  mm are classified as microinvasive carcinoma.<sup>23</sup>

### **3) Malignant mucinous ovarian tumor (mucinous adenocarcinoma):**

These are relatively uncommon tumors accounting for 10% of ovarian cancers. They are multicystic with cut section showing both solid and papillary cystic areas with areas of hemorrhage and necrosis. As seen in study by *Stephen S Raab et al*, microscopically the lining epithelium shows stratification of more than 4 layers and atypical changes. Areas of necrosis and stromal invasion also seen.<sup>24</sup>

### **C) ENDOMETROID TUMORS:**

These tumors account for approximately 2-4% of all ovarian tumors and 10-20% of all ovarian cancers<sup>25</sup>. These occur in women in perimenopausal age. As seen in study by *Karen A.Bell et al* most endometroid tumors are carcinomas.<sup>26</sup>

**Endometrioid carcinoma:**

These tumors present as solid, friable or cystic mass with hemorrhagic content. Histopathological examination shows that these resemble the ordinary type of endometrial adenocarcinoma hence the name. Study done by *Falkenberry SS et al* shows that 15-20% of endometrioid carcinoma show synchronous endometrial adenocarcinoma.<sup>27-31</sup>

**D) CLEAR CELL TUMORS:**

Clear cell carcinomas constitute 6% of surface epithelial stromal Cancers.<sup>25,32</sup> They most commonly occur in the 5th to 6th decade of life as seen in study by *Crozeir MA et al*<sup>33,34</sup>. These are predominantly solid with cystic areas containing one or more white or yellow polypoid masses protruding in the lumen. As seen in study by *Longacre TA et al*, clear cell carcinoma shows a variety of patterns and cell types which are admixed. The common patterns are tubulocystic, papillary, reticular and solid sheets.<sup>35</sup> Cores of papillae are lined by one or two layers of hobnail cells with clear cells forming solid sheets. The stroma in ovarian clear cell carcinoma often shows alternate mucoid and hyalinized change.<sup>36</sup>

### **E) BRENNER TUMOR:**

These tumors constitute 1 to 2 % of all ovarian neoplasms<sup>25</sup>. Average age at presentation was between 30-50 years in study done by *Ehrlich CE et al*<sup>37,38</sup>. These are hormonally active accompanied by signs of hyperesternism. Most authors currently favor an origin from surface ovarian epithelium or cyst derived from them through the process of metaplasia. As seen in study *Cuatrecasas et al(2009)*, Brenner tumor is seen in association with mucinous cystadenoma and transitional cell tumor of the bladder.<sup>39</sup> Most Brenner tumors are benign. These are solid, sharply circumscribed and lobulated fibrous masses.<sup>37,38</sup> These tumors consist of nests and trabeculae of transitional cells surrounded by abundant stroma. Nuclei of tumor cells are oval with longitudinal groove (coffee bean).

### **F) TRANSITIONAL CELL CARCINOMA:**

These tumors in ovary are broadly similar to transitional cell carcinoma of urinary tract in architectural arrangement and they lack a benign or borderline Brenner component. As seen in study by *Eichhorn, John et al* mean age at presentation is around 50 to 58 years.<sup>39</sup> Grossly



these are usually cystic with few solid areas. Microscopically solid or papillary growth pattern is seen and the papillae are multilayered.

## ***II. SEX CORD STROMAL TUMORS:***

These comprise of a heterogeneous group of neoplasms accounting for 8% of all ovarian neoplasms<sup>25</sup>. They are the most common functioning ovarian tumors.

### **A.1) GRANULOSA STROMAL CELL TUMOR:**

These comprise of two groups:

- 1) The granulosa cell tumor
- 2) The thecoma - fibroma group

### **GRANULOSA CELL TUMOR:**

These are the ovarian neoplasms showing differentiation towards follicular granulosa cells. They are mainly of two types – Juvenile and adult granulosa cell tumor. Adult granulosa cell tumors account for 1-2 % of all ovarian tumors and 95% of all granulosa cell tumors. These occur in menopausal and postmenopausal age group. Three fourths are associated with hyperestrogenism which leads to endometrial hyperplasia and carcinoma in approximately 5% of cases. These are unilateral with cystic and solid areas. Cut section shows solid areas, yellow to white in

color. The most common histologic patterns include diffuse, trabecular, insular, and microfollicular. An additional morphologic variant, a pseudopapillary pattern, may also be seen in granulosa cell tumors of both adult and juvenile type, and can give rise to problems in their distinction from transitional cell neoplasms was studied by *Irving, Julie et al.*<sup>40</sup> These tumors are potentially malignant. Juvenile granulosa cell tumor usually presents in the first decade of life, almost all presenting within third decade. *Young, Robert H. M.B et al* found 82% of the prepubertal patients presenting with isosexual pseudo- precocity.<sup>41</sup> Juvenile granulosa cell tumor differs from adult granulosa cell tumor such that former shows nuclear hyperchromasia, increased mitosis, rare nuclear grooves and call exner bodies.

## **A.2) THECOMA- FIBROMA GROUP:**

### **a) Thecoma:**

These constitute 4% of all ovarian tumors and are subclassified in typical and leutinized subtypes. They affect postmenopausal females. They show estrogenic manifestations. These are unilateral, yellow, solid and have a well-defined capsule, and are firm in consistency. They are composed of fascicles of plump spindle shaped cells. The nuclei are

round to spindle and have finely dispersed chromatin with pale, vacuolated lipid rich cytoplasm.<sup>42</sup> Silver stains demonstrate reticulin fibrils investing around each tumor cells.

**b) FIBROMA:**

The most common tumor in the sex cord-stromal category, which accounts for 4% of human ovarian tumors, is the fibroma. Fibroma occurs invariably after puberty, which is often seen between 50-60 years. They may be associated with meigs syndrome or basal cell nevus syndrome. These are smooth, lobulated and firm in consistency with average 6 cm diameter. On cut section, these are white in color. These shows spindle shaped fibroblastic cells that grow in interlacing fascicles and whorls. The tumor cells have small ovoid nuclei with pointed ends. No cytologic atypia or mitotic activity is present.<sup>43</sup>

**c) FIBROSARCOMA:**

These are the most common ovarian sarcomas. They affect older women. Grossly these are large, unilateral, solid tumors with hemorrhagic and necrotic areas. These are densely cellular, with spindle cell arranged in herringbone or storiform pattern. They exhibit moderate

to severe cytological atypia and high mitotic rate (average 4 - 25 mitosis/10HPF).<sup>44</sup>

**e) Sclerosing stromal tumor of ovary:**

It is a rare ovarian neoplasm occurring predominantly in young women and is histologically characterized by cellular heterogeneity, prominent vasculature, and a pseudolobular appearance composed of cellular and hypocellular areas. As seen in study by *Kawauchi S et al*, immunohistochemistry demonstrates an expression of vascular permeability factor/vascular endothelial growth factor(VPF/VEGF) in the luteinized theca like cells.<sup>45</sup> Grossly they are solid tumors with white and yellow areas, edema and cyst formation.

**B) SERTOLI - LEYDIG CELL TUMOR:**

These tumors account for less than 0.5% of all ovarian tumors. They may occur at any age but common around 25 years. These often produce androgens. They vary in gross appearance from solid yellow lobulated masses to uni or multilocular cysts. Sertoli-Leydig cell tumors are subdivided into well-differentiated forms, tumors of intermediate differentiation, poorly differentiated tumors, and a fourth, heterologous

type. As in study by *Oliva, Esther et al* EMA, inhibin, and chromogranin represent the most helpful triad of immunomarkers serving to exclude two common mimics of Sertoli cell tumors (endometrioid carcinoma [inhibin–; EMA+; chromogranin–] and carcinoid tumor [inhibin–; EMA+; chromogranin+]).<sup>46</sup>

### **C) SEX CORD TUMOR WITH ANNULAR TUBULES:**

It is a distinctive ovarian tumor, which present with hyperestrenism. Its morphologic hallmark is the presence of simple and complex annular tubules containing eosinophilic hyaline bodies, which are often calcified. Tumors associated with Peutz –Jegher syndrome are typically multifocal, bilateral, calcified and usually benign in nature.<sup>47</sup>

### **D) GYNANDROBLASTOMA:**

It is an extremely rare tumor. It is the term used for sex cord – stromal tumor composed of a mixture in similar amounts of clearly identifiable granulosa-theca cells and sertoli leydig cell elements. The inor component should account at least 10% of the tumor.<sup>2</sup>

### **III. LIPID CELL (LIPOID, STEROID CELL) TUMOR:**

This group consists of ovarian tumors composed of cells resembling steroid hormone secreting cells. The neoplastic cells may be lipid-free or

lipid-rich.

They are subdivided into four subtypes:

1. stromal luteoma
2. leydig cell tumor – hilus / nonhilus
3. adrenal cortical type
4. not other wise specified

#### **LEYDIG CELL TUMOR:**

These are usually unilateral and grossly present as small dark reddish brown to yellow nodules. Microscopically these are composed large round to polygonal cells with abundant eosinophilic cytoplasm that shows positivity for fat stains.<sup>48</sup> Endocrine atypia is common. About 25% of tumors have tendency to develop malignancy. Malignant tumors tend to be larger with foci of necrosis and hemorrhage.

#### **IV. GERM CELL TUMORS:**

These tumors constitute approximately 30% of all ovarian neoplasms. Most of them are seen in children and young adults. Approximately 95% of tumors are benign cystic teratomas. The germ cell tumors recapitulate normal embryogenesis. The current pathogenetic

theory suggests origin from a meiotic germ cell. It could be due to failure of meiosis 1 or meiosis 2.

#### **A) DYSGERMINOMA:**

These are the most common malignant germ cell tumors of the ovary which account for 1 % of all ovarian cancers. As seen in study done by *Archana Amatya et al*, it is the most common malignant tumor occurring children and young women and in patients with gonadal dysgenesis.<sup>49</sup> Grossly they have convoluted external surface and solid gray white cut surface. Presence of calcification suggests underlying gonadoblastoma. Microscopically they show monotonous population of cells arranged in nests separated by fibrous septa with lymphocytic infiltration. The cells have abundant clear cytoplasm, prominent cytoplasmic membranes, round vesicular nucleus and central prominent nucleoli. The PAS stain helps in demonstrating the presence of intracytoplasmic glycogen. *Liang Cheng et al revealed* importance of OCT 4 marker in dysgerminoma.<sup>50</sup>

#### **B) YOLK SAC TUMOR (ENDODERMAL SINUS TUMOR):**

These neoplasm constitute 20 % of malignant germ cell tumors. External surface is smooth and glistening. Cut section shows solid and

cystic areas. Areas of hemorrhage and necrosis also seen. These tumors have a more than one growth pattern recapitulating yolk sac development, which can be reticular/microcystic, solid, papillary, polyvesicular vitelline or hepatoid. Schiller Duval bodies are the characteristic feature of this tumor. Eosinophilic PAS +ve diastase resistant hyaline globules are a frequent finding in yolk sac tumors.<sup>51</sup>

### **C) EMBRYONAL CARCINOMA:**

These tumors occur in young age group with a median age of 15 years. They present with precocious puberty, vaginal bleeding, hirsutism and amenorrhea. They are large, unilateral exhibiting solid and variegated cut surface. Foci of hemorrhage and necrosis are present. Microscopy shows large primitive cells distributed in solid sheets. Occasionally papillae and abortive glandular structures are formed. Nuclei are round and vesicular. Numerous mitotic figures are present.<sup>52</sup>

### **D) POLYEMBRYOMAS:**

These are very rare neoplasms containing large number of embryoid bodies at various stages of development embedded in primitive mesenchymal stroma.



## **E) CHORIOCARCINOMA:**

Primary ovarian choriocarcinoma are rare, highly malignant tumors usually developing before puberty. Primary ovarian choriocarcinoma are usually a component of mixed germ cell tumor. Grossly they are hemorrhagic and friable. They show the typical bilamellar pattern with admixture of syncitial and cytotrophoblastic elements in a necrotic and hemorrhagic background.

## **F) TERATOMA:**

These tumors are characterized by presence of tissues derived from two or all three embryonic layers. These are divided into three types.

- 1) Immature teratoma
- 2) Mature teratoma
- 3) Monodermal teratoma

### **1) IMMATURE TERATOMA:**

It is a malignant teratoma constituting 3% of all ovarian teratomas and 20% of all malignant germ cell neoplasms. It occurs in children and young adult with an average presentation of 20 years. Cut section shows

partly solid and cystic areas. Microscopy shows the tissues derived from all the three germ layers are present growing as disorganized mixture of mature and immature elements. Prognosis of these tumors depends mainly on relative amount of primitive neuroepithelial tissue. The most widely used grading system (Norris system) stratifies immature teratoma into three grades:

Grade 1 - Rare, primitive neuroepithelium not greater than 1 hpf/ slide

Grade 2 - Primitive neuroepithelium not greater than 3 hpf/ slide

Grade 3 - Primitive neuroepithelium greater than or equal to 4 hpf/ slide

## **2) MATURE CYSTIC TERATOMA:**

These are most common ovarian neoplasm accounting for 27–44% of all ovarian neoplasms. Two thirds of the patients are between 20 and 40 years. These are almost always cystic. Cyst content is greasy, largely composed of keratin, sebum and hairs. Teeth are often present.

Microscopically variable admixture of mature ectodermal, mesodermal and endodermal elements is seen. In almost 2% of the cases and particularly in older women, dermoid cysts undergo a secondary malignant change, usually in the form of squamous cell carcinoma, but

occasionally an adenocarcinoma, sarcoma, or other type of malignant neoplasm can occur. As observed by *Ronnett, Brigitte M et al* mature cystic teratoma can coexist with mucinous cystadenoma giving rise to pseudomyxoma peritonei or with Brenner tumor and fibrothecoma.<sup>53</sup>

### **3) MONODERMAL TERATOMA:**

These are the teratoma in which one element predominates over all others. Struma ovarii is the most common which consists of thyroid follicles with eosinophilic colloid and lined by columnar or cuboidal cells with uniform round nucleus. Carcinoid tumors are the second common monodermal teratomas. Microscopic study shows round to cuboidal tumor cells with a round nucleus with coarse salt and pepper chromatin and small nucleoli. Four types are - mucinous, insular, trabacular and strumal carcinoids.

### **G) MALIGNANT MIXED GERM CELL TUMOR:**

These comprise 5 to 10 % of all malignant germ cell tumors.<sup>54</sup> These show combination of two or more neoplastic germ cell elements. The combination of dysgerminoma and yolk sac tumor is the most

common. Proper identification of various components is necessary which requires careful gross examination and extensive sampling.

## **V. MIXED GERM CELL - SEXCORD STROMAL TUMORS:**

### **GONADOBLASTOMA:**

These are tumors composed of a combination of germ cells and sex cord stromal cells. It is a rare tumor which occurs almost exclusively in dysgenetic gonads. They vary in gross appearance from soft and fleshy to firm and completely calcified. They show admixture of primitive germ cells resembling those of dysgerminoma with sex cord stromal cells resembling that of immature sertoli and granulosa cells arranged in small islands. Hyalinization and calcification are common.

## **VI. TUMORS OF THE RETE OVARI:**

These are relatively uncommon tumors, which includes adenoma, cystadenoma and carcinoma.

## **VII. MESOTHELIAL TUMORS:**

### **A) ADENOMATOID TUMOR:**

These are benign mesothelial tumors. Histologically they resemble their more common counterparts occurring in fallopian tube.

## **B) MESOTHELIOMA:**

These are very rare.

## **VIII. TUMORS OF UNCERTAIN ORIGIN:**

### **A) SMALL CELL CARCINOMA:**

There are two types of small cell carcinoma designated as hypercalcemic and pulmonary type.

#### **Hypercalcemic type:**

Extrapulmonary small cell carcinoma is a clinicopathological entity distinct from pulmonary small cell carcinoma. As revealed by *Reckova M et al*, it is a high-grade ovarian malignant tumor, which occurs in young females.<sup>55</sup> It is usually unilateral with two thirds of patients showing hypercalcemia. The tumor is large and solid grey white resembling dysgerminoma or lymphoma. Large tumors may show hemorrhagic and necrotic areas. Two histological patterns are identified. A diffuse population of small, closely packed cells with scant cytoplasm and small nuclei constitute the common pattern. The nuclei are hyperchromatic, with fine chromatin and prominent nucleoli. Mitotic figures are numerous. Cytoplasmic hyaline globules are seen. In second type larger cells exhibiting epithelioid or rhabdoid features with abundant

eosinophilic cytoplasm and prominent nucleoli are seen.

**Pulmonary type:**

These highly malignant tumors resemble lung small cell carcinoma. Metastasis from lung primary should always be excluded.

**B) FEMALE ADENEXAL TUMOR OF WOLFFIAN ORIGIN:**

These are benign unilateral tumors. These arise from mesonephric/wolffian remnants.<sup>56</sup> The tumor cells show diffuse, trabecular and microcystic growth pattern. Small to medium sized epithelial cells are embedded in fibrous stroma as seen in study by *Karminjed MH et al.*<sup>57</sup> Almost always inhibin positivity is also recorded.

**IX. SOFT TISSUE TUMORS NOT SPECIFIC TO OVARY:**

These include various mesenchymal neoplasms arising from those tissue elements for example smooth muscle, nerves or blood vessels which are not involved in specific gonadal function. These may be leiomyomas as seen in study by *Murakami M et al* or leiomyosarcomas, rhabdomyomas, rhabdomyosarcomas, chondromas, chondrosarcomas or vascular tumors.<sup>58</sup>

## **X.METASTATIC TUMORS (SECONDARY TUMORS):**

The ovary is a common site of metastasis in female genital tract as observed by *Mazur MT et al.*<sup>59</sup> Colon , stomach, breast, uterus and lung constitute the common primary sites. As seen in study by *Zhao et al* most of the meatastatic tumors occurred in premenopausal patients and had bilateral presentation.<sup>60</sup> Metastatic tumors in the ovary vary in appearance. In some cases the ovary is completely replaced by solid white tumor or cystic tumor with solid areas. The microscopic appearance varies with the nature of primary tumor. They resemble the primary to a variable degree. Immunohistochemical stains like CK7 and CK20 are helpful in establishing the diagnosis.

### **Krukenberg tumor:**

These are adenocarcinomas with distinctive histological appearance. They show typical mucin filled signet ring cells associated with striking proliferation of ovarian stroma. Stomach is the usual primary site. Grossly, these are solid bosselated masses with grey white cut surface. Special stains for mucin and immunostains for epithelial marker are helpful in diagnosis.<sup>61</sup>

## **MATERIAL AND METHODS**

---

**STUDY DESIGN:** Descriptive study.

**PLACE OF THE STUDY AND STUDY PERIOD:**

This study was conducted in the Department of Pathology, Coimbatore Medical College, Coimbatore. The study period extended from March 2009 to June 2010.

**SAMPLE SIZE:**

This study included all the specimens of ovarian tumors sent for histopathological examination to the Department of Pathology at Coimbatore Medical College, Coimbatore between March 2007 & February 2010.

**INCLUSION CRITERIA:**

1. All the ovarian tumors, irrespective of their clinical features, stage of the disease or type of surgical procedure implemented were included.
2. Hysterectomy specimens with incidental ovarian tumors were also included.



**EXCLUSION CRITERIA:**

Non neoplastic ovarian lesions like simple ovarian cyst, tubo-ovarian mass and polycystic ovaries were excluded.

**METHODOLOGY:**

Relevant data like parity, clinical presentation, age of the patient was collected in a proforma. For specimens of ovarian tumors from May 2009 to February 2010, gross observation of the specimens received was done. For proper fixation, tumors were cut serially at 1cm thickness. The specimens were fixed in 10% formalin for 24-48 hours. After fixation, sections were given from representative areas. Sections were cut at 4-5 micrometer thickness & stained with H&E. Slides and blocks were retrieved for cases from March 2007 to April 2009. All stained histopathology slides were studied in detail. Histopathology reports for each tumor were retrieved from department of pathology, Coimbatore Medical College. Special stains of PAS, Reticulin were done whenever necessary. All details of the specimen consisting of gross features, microscopic features and final diagnosis were studied. World Health Organization classification was used for classifying the tumors. Analysis

of the data was done to find out the incidence of various types of tumors, age of presentation of various tumor types, gross features and histopathological patterns of individual tumor types. Incidence of benign versus malignant tumors was studied. This was a descriptive study and analysis of data was done using chi square test and logistic regression analysis.

## OBSERVATIONS AND RESULTS

The incidence and clinical presentation of the different ovarian tumors is extremely variable. The preoperative diagnosis of the tumors is often difficult with only clinical examination and even on exploration, though some investigations like peritoneal fluid cytology or serum LDH may help in predicting the nature of pathology. Hence one has to depend on the microscopic appearance of the tumor for further management.<sup>8</sup> The present study of ovarian tumors was undertaken for a period of three years from March 2007 to February 2010. Totally 301 cases were studied in this period.

**TABLE 1: AGE DISTRIBUTION**

Sr. No.	Age (Years)	No. Of Cases (n =301)	Percentage (%)
1.	<20	13	04.32 %
2.	21-30	79	26.24 %
3.	31-40	77	25.59 %
4.	41-50	68	22.59 %
5.	51-60	46	15.28 %
6.	>60	18	05.98 %

Table 1 shows that the majority of tumors ie. 270 out of 301 (89.7 %) were present between 3<sup>rd</sup> to 6<sup>th</sup> decade. Below 20 years and above 60

years only one tenth tumors were seen. Approximately 50 % tumors were present in reproductive age group.

**TABLE 2 : PARITY STATUS**

Sr.No.	Parity	No. Of Cases (n =301)	Percentage(%)
1.	0	29	9.63 %
2.	1	51	16.94 %
3.	2	94	31.23 %
4.	3	97	32.22 %
5.	≥4	30	9.97 %

Table 2 shows the parity status observed in the present study. There were 29(9.63%) nulliparous patients and 145(48.17%) were of parity one or two. Patients with parity three or more were 127(42.19%).

**TABLE 3: AGE AT MENARCHE**

Sr.No.	Age At Menarche (Yr)	No. Of Cases (n =301)	Percentage (%)
1.	<11	10	3.32 %
2.	11-12	46	15.28 %
3.	12-13	94	31.23 %
4.	13-14	47	15.61 %
5.	14-15	65	21.59 %
6.	>15	39	12.96 %

Table 3 shows the age at menarche recorded for the patients in the

present study. Majority of the patients, 245 (81.39%) attained menarche after the age of 12. The other 56 patients attained menarche before age of 12.

**TABLE 4 : MENSTRUAL STATUS**

Sr.No.	Category	No. Of Cases (n =301)	Percentage (%)
1.	Premenopausal	211	70.10 %
2.	Postmenopausal	90	29.90 %

Table 4 shows menstrual status among the patients of the present study. Premenopausal age group was more common than postmenopausal, contributing to 70.10% of the tumors.

**TABLE 5: MODE OF PRESENTATION**

Sr.No.	Symptom	No. Of Cases	Percentage (%)
1.	Abdominal pain	161	53.49 %
2.	Mass per abdomen	81	26.91 %
3.	Ascites	25	8.30 %
4.	Menstrual irregularities	21	6.98 %
5.	Urinary complaints	6	1.99 %
6.	Asymptomatic	7	2.32 %

Table 5 shows that abdominal pain was the commonest presentation followed by mass per abdomen. Asymptomatic ovarian tumors were least common.

**TABLE 6: LATERALITY OF THE TUMORS**

Sr. No.	Laterality	No. Of Cases (n =301)	Percentage (%)
1.	Unilateral	268	89.04 %
2.	Bilateral	33	10.96 %

Table 6 shows the incidence of unilateral and bilateral tumors. Most of the tumors were unilateral. 33 out of the 301 tumors (11%) had bilateral presentation.

**TABLE 7: INCIDENCE OF BILATERALITY IN BENIGN  
VERSUS MALIGNANT TUMORS**

Sr.No.	Type	Unilateral	Bilateral	Percentage (%)
1.	Benign	213	12	5.63%
2.	Malignant	55	21	38.18%

Table 7 shows that 12 out of 213 (5.63%) benign tumors and 21 out of 55 (38.18%) malignant tumors presented bilaterally. Among

bilateral tumors 21 (64%) were malignant as against 12(5.63%) benign tumors. Thus malignant tumors were common to present bilaterally.

**TABLE 8: INCIDENCE OF BILATERALITY IN THE MAJOR HISTOPATHOLOGICAL SUBTYPES**

Sr.No.	Microscopic Type	No.of Cases (n=301)	Bilaterality	Percentage (%)
1.	Surface Epithelial Tumors	243	24	9.88 %
2.	Germ Cell Tumors	22	5	22.73 %
3.	Sex Cord Stromal Tumors	32	0	0 %
4.	Metastatic Tumors	4	4	100 %

Table 8 shows that all the metastatic tumors had bilateral presentation whereas none of the sex cord stromal tumors were bilateral. Out of 12 cases of endometrioid carcinoma in present study 6 (50%) had bilateral presentation.

**TABLE 9: MAJOR HISTOPATHOLOGICAL SUBTYPES**

Sr.No.	Microscopic Type	No. Of Cases (n =301)	Percentage (%)
1.	Surface Epithelial Tumors	243	80.73 %
2.	Germ Cell Tumors	22	10.63 %
3.	Sex Cord Stromal Tumors	32	7.31 %
4.	Metastatic Tumors	4	1.33 %

Table 9 shows the incidence of the major histopathological subtypes of ovarian tumors. The most common histopathological pattern encountered in the present study was surface epithelial tumors followed by germ cell tumors. Metastatic tumors were the least common variety.



**TABLE 10: LATERALITY IN INDIVIDUAL  
HISTOPATHOLOGICAL SUBTYPE**

Sr.No	Diagnosis	Bilateral	Unilateral	Total (n =301)
1.	Serous Cystadenoma	4	103	107
2.	Serous Cystadenofibroma	1	3	4
3.	Mucinous Cystadenoma	2	62	64
4.	Mucinous Cystadenofibroma	-	2	2
5.	Endometrioid Adenofibroma	-	2	2
6.	Mature Cystic Teratoma	5	21	26
7.	Fibroma	-	8	8
8.	Thecoma	-	1	1
9.	Fibrothecoma	-	2	2
10.	Granulosa Cell Tumor	-	6	6
11.	Sertoli Cell Tumor	-	2	2
12.	Sex Cord Tumor With Annular Tubules	-	1	1
13.	Borderline Serous Tumor	-	2	2
14.	Serous Cystadenocarcinoma	6	14	20
15.	Borderline Mucinous Tumor	1	10	11
16.	Mucinous Cystadenocarcinoma	4	12	16
17.	Endometrioid Carcinoma	6	6	12
18.	Clear Cell Carcinoma	-	3	3
19.	Dysgerminoma	-	4	4
20.	Mixed Germ Cell Tumor	-	2	2
21.	Granulosa Cell Tumor	-	2	2
22.	Metastatic	4	-	4

Table 10 shows the laterality observed in individual histopathological subtypes. Among benign tumors, mature cystic

teratoma was common to present bilaterally. In primary ovarian carcinomas, endometrioid carcinoma and serous cystadenocarcinoma showed higher incidence of bilaterality.

**TABLE 11: SIZE OF THE TUMORS**

Sr.No.	Size Of Tumor (cm)	No. Of Cases (n =301)	Percentage (%)
1.	<10	137	45.51 %
2.	11-20	139	46.18 %
3.	21-30	24	7.97 %
4.	>30	1	0.33 %

Table 11 shows the distribution of tumors according to their size.

Majority of the tumors i.e. 276 (91.69%) were less than 20 cms in the largest dimension. Only 24 tumors had their largest dimension between 21 to 30 cms. The largest tumor was measuring 32x25x12 cms which was unilateral benign serous cystadenoma affecting a 27 year old lady. Bilateral endometrioid adenocarcinoma was the smallest tumor in this study measuring 3x2x1.5 cms present in a 55 year lady.

**TABLE 12: GROSS FEATURES**

Sr.No.	Gross Feature	No. Of Cases (n =301)	Percentage (%)
1.	Cystic	206	68.44 %
2.	Solid	57	18.94 %
3.	Cystic & Solid	38	12.62 %

Table 12 shows the details of the gross morphological features of the ovarian tumors included in the present study. The commonest gross morphology was the cystic nature of the tumors contributing to 68.44%. The tumors presenting with gross cystic morphology were benign tumors especially of surface epithelial category. Among tumors with solid or complex morphology, majority were malignant.

**TABLE 13: NATURE OF THE TUMORS**

Sr. NO	Nature Of Tumor	No. Of Cases (n =301)	Percentage (%)
1.	Benign	225	74.75 %
2.	Borderline	13	4.32 %
3.	Malignant	63	20.93 %

Table 13 shows that out of 301 cases studied, majority were benign tumors 225 (74.75%), followed by malignant 63(20.93 %) and 13 (4.32 %) cases of borderline tumors.

**TABLE 14: HISTOMORPHOLOGICAL TYPES OF THE  
OVARIAN TUMORS**

Sr.No.	Type Of Tumor	No.Of Cases (n =301)	Percentage (%)
1.	Serous Cystadenoma	107	35.54 %
2.	Serous Cystadenofibroma	4	1.33 %
3.	Borderline Serous Tumor	2	0.66 %
4.	Serous Cystadenocarcinoma	20	6.64 %
5.	Mucinous Cystadenoma	64	21.26 %
6.	Mucinous Cystadenofibroma	2	0.66 %
7.	Borderline Mucinous Tumor	11	3.65 %
8.	Mucinous Cystadenocarcinoma	16	5.32 %
9.	Endometrioid Adenofibroma	2	0.66 %
10.	Endometrioid Carcinoma	12	3.99 %
11.	Clear Cell Carcinoma	3	0.99 %
12.	Mature Cystic Teratoma	26	8.64 %
13.	Dysgerminoma	4	1.33 %
14.	Mixed Germ Cell Tumors	2	0.66 %
15.	Fibroma	8	2.66 %
16.	Thecoma	1	0.33 %
17.	Fibrothecoma	2	0.66 %
18.	Granulosa Cell Tumor	8	2.66%
19.	Sertoli Cell Tumor	2	0.66 %
20.	SCTAT	1	0.33 %
21.	Metastatic	4	1.33 %

(SCTAT- Sex Cord Tumor with Annular Tubules)

Table 14 shows the incidence of each histomorphological subtype. Benign serous cystadenoma was the commonest histopathological pattern encountered in present study contributing to 35.54% followed by benign mucinous cystadenoma. Only single case each of thecoma and sex cord

tumor with annular tubules was seen. No transitional cell tumors were seen in this study.

**TABLE 15: AGE DISTRIBUTION OF THE BENIGN / BORDERLINE / MALIGNANT OVARIAN TUMORS**

AGE(Yr)	BENIGN	BORDERLINE	MALIGNANT	TOTAL
<20	9	-	4	13
21-30	67	5	7	79
31-40	67	1	9	77
41-50	45	4	19	68
51-60	28	3	15	46
>60	9	-	9	18

Table 15 shows age distribution of benign and malignant ovarian tumors. Malignant tumors commonly affected older age group (>40 years) with only malignant germ cell tumors involving younger age group. On the contrary, benign tumors predominantly involved patients < 40 year age. The increasing incidence of malignancy with increasing age was found to be statistically significant.

**TABLE 16: AGE DISTRIBUTION OF  
THE MAJOR TUMOR CATEGORIES**

AGE (Yr)	Surface Epithelial Tumors	Germ Cell Tumors	Sex cord Stromal Tumors	Metastatic Tumors	Total
<20	6	4	3	-	13
21-30	61	13	3	2	79
31-40	60	11	6	-	77
41-50	60	2	5	1	68
51-60	41	2	3	-	46
>60	15	-	2	1	18
Total	243	32	22	4	301

Table 16 shows the distribution of major histopathological types according to age. Surface epithelial tumors were uncommon to present in adolescent age group whereas germ cell tumors had predilection for this age group. After age of 40 years, surface epithelial was the predominating category with rare germ cell tumors.

**TABLE 17: AGE DISTRIBUTION OF THE VARIOUS  
HISTOMORPHOLOGICAL TYPES OF THE TUMORS**

NO	Type Of Tumor	<20 Yr.	21- 30	31- 40	41- 50	51- 60	>60 Yr.
1.	Serous Cystadenoma	2	35	29	23	13	5
2.	Serous Cystadenofibroma	1	1	1	-	1	-
3.	Borderline Serous Tumor	-	1	1	-	-	-
4.	Serous Cystadenocarcinoma	-	1	2	9	6	2
5.	Mucinous Cystadenoma	3	17	20	15	8	1
6.	Mucinous Cystadenofibroma	-	-	-	-	1	1
7.	Borderline Mucinous Tumor	-	4	-	4	3	-
8.	Mucinous Cystadenocarcinoma	-	2	5	3	4	2
9.	Endometrioid Adenofibroma	-	-	-	-	1	1
10.	Endometrioid Carcinoma	-	-	2	6	2	2
11.	Clear Cell Carcinoma	-	-	-	-	2	1
12.	Mature Cystic Teratoma	-	11	11	2	2	-
13.	Dysgerminoma	2	2	-	-	-	-
14.	Mixed Germ Cell Tumors	2	-	-	-	-	-
15.	Fibroma	2	-	4	2	-	-
16.	Thecoma	-	-	-	-	1	-
17.	Fibrothecoma	-	1	-	-	-	1
18.	Granulosa Cell Tumor	-	1	1	3	2	1
19.	Sertoli Cell Tumor	1	1	-	-	-	-
20.	SCTAT	-	-	1	-	-	-
21.	Metastatic	-	2	-	1	-	1

Table 17 shows the age distribution of each histopathological subtype of ovarian tumors included in present study. In patients less than 20 years of age, most of the tumors were benign except malignant germ cell tumors which affected this age group most commonly.

**TABLE 18: VARIABLES RELATED TO THE RISK OF  
MALIGNANCY**

Sr. No.	VARIABLE	TOTAL	MALIGNANT	%	p VALUE
1.	AGE:				
	≤50 Years	237	49	20.67%	p < 0.01 *
	>50 Years	64	27	42.19%	
2.	GRAVIDITY:				
	≤1	80	32	40.00%	p < 0.01 *
	>1	221	44	19.91%	
3.	MENOPAUSAL STATUS				
	PRE MENOPAUSAL	211	40	13.29%	p < 0.01 *
	POST MENOPAUSAL	90	36	40.00%	
4.	TUMOR MORPHOLOGY:				
	CYSTIC	206	12	3.97%	p < 0.01 *
	SOLID	57	42	73.68%	
	COMPLEX	38	22	57.89%	
5.	TUMOR DIAMETER:				
	≤10 cm	137	29	21.17%	p > 0.05
	>10 cm	164	47	28.66%	
6.	LATERALITY				
	UNILATERAL	268	55	20.52%	p < 0.01 *
	BILATERAL	33	21	63.64%	
7.	AGE AT MENARCHE				
	≤12 YEARS	56	17	30.36%	p > 0.05
	>12 YEARS	245	59	24.08%	

\* = Significant at 1% level (p < 0.01 )



**TABLE 19: LOGISTIC REGRESSION ANALYSIS**

Variable	Log Odds(B)	S.E.	Wald	Df	Prob.	Sig.	Exp(B)
Age	1.166	0.622	4.072	1	0.01	*	1.181
Parity	-1.562	0.468	11.160	1	0.00	*	0.210
Age at Menarche	-0.077	0.486	0.025	1	0.87	Ns	0.926
Menstrual status	1.497	0.603	6.170	1	0.01	*	4.469
Laterality	1.439	0.525	7.509	1	0.01	*	4.217
Size	-0.051	0.384	0.018	1	0.89	Ns	0.950
Tumor Morphology	3.145	0.385	66.669	1	0.00	*	23.213

\* = Significant

NS = Not significant

Table 18 and 19 show the risk of malignancy associated with various variables related to ovarian tumors. Logistic regression analysis is applied to predict the probability of a particular outcome in relation to several other independent variables. Here, Logistic regression analysis was used to find out the probability (Odds) of the patients developing malignant tumor. The model was constructed based on the set of independent variables listed above. Increasing age, nulliparity or low parity, postmenopausal status, bilaterality and complex or solid tumor morphology conferred higher risk of malignancy. Early menarche and size of the tumor did not correlate with increased risk of malignancy.

**TABLE 20: PREDICTIBILITY OF THE MODEL**

	Predicted by the equation				
Observed data		Malignant	Benign	Total	Percent Correct
	Malignant	208	17	225	92.44%
	Benign	20	56	76	73.68%

Using the above seven variables together, a model was created to predict the risk of malignancy in a tumor. The following statistics was used to assess the overall effectiveness of the model.

-2 Log Likelihood      190.312

Cox & Snell - R<sup>2</sup>      0.392

Nagelkerke - R<sup>2</sup>      0.579

Chi-Square	Df	Significance
149.851	7	*

\* - Significant at 1 % level (P<0.01)

Overall 87.71% of the cases were correctly classified by the model. The – 2 Log Likelihood value is 190.312 which was used to test the effectiveness of the model using chi-square test. The chi-square value was 149.851, which was significant at 1% level indicating that the model fits the data well.

## **DISCUSSION**

---

Because of the anatomical location, ovarian tumors may remain unnoticed for a long period of time. These tumors can cause abdominal pain and abdominal distension. Based on histological patterns, these tumors are divided into benign, borderline and malignant. The common variants are epithelial cell tumors, germ cell tumors, and sex cord stromal Tumors. The ovary is one of the common sites to get metastatic deposits from other abdominal malignancies.<sup>62</sup>

### **DISTRIBUTION OF OVARIAN TUMORS ACCORDING TO AGE:**

Ovarian tumors are common in all age groups and no age is exempted. The age range in the present study was 14 to 76 years. The youngest patient in this study was a 14 year old girl with left sided dysgerminoma measuring 17x14x10 cms which is the most common germ cell tumor of adolescent age group. She presented with mass per abdomen. The oldest patient was a 76 year old lady with unilateral serous

cystadenocarcinoma with omental deposits. She presented with ascites and the tumor was measuring 5x4x3 cms. The maximum number of cases in present study were between 21 and 60 years. This age group included 89.7% of tumors. This was in concordance with following studies:

Sr.No.	Age (Yr)	Present study	<i>Pilli et al</i> <sup>63</sup>	<i>R Jha et al</i> <sup>64</sup>	<i>Kayastha et al</i> <sup>65</sup>	<i>Kar et al</i> <sup>66</sup>
1.	<20	4.32 %	7 %	6.8 %	6.3 %	7 %
2.	21-30	26.24 %	58 %	20.5 %	28.5 %	42 %
3.	31-40	25.59 %		26.7 %	27.4 %	
4.	41-50	22.59 %	30 %	21.1 %	26.3 %	46 %
5.	51-60	15.28 %		14.3 %	11.6 %	
6.	>60	5.98 %	5 %	10.6 %		5 %

The comparative analysis with above studies revealed similar results as present study. 2<sup>nd</sup> to 5<sup>th</sup> decade was the most common age group affected. Adolescent age group constituted 4.32 % in this study. This is also comparable to study done by *Deshpande et al* where the incidence of ovarian tumors in this age group was 4.2 %.<sup>67</sup>

#### **PARITY STATUS:**

Increasing parity is associated with a reduction in the risk of ovarian cancer, but it is not clear whether this association applies to all the histopathological types and to borderline tumours.<sup>68</sup> Nulliparity and low

parity were associated with increased relative risk of ovarian tumors in the present study. In this study, tumors in nullipara and women with low parity (two children) contributed to 57.80 % of all tumors which was consistent with findings of study done by *Kayastha et al.*<sup>65</sup> In their study tumors in nullipara and women with low parity contributed to 58.93 %. Similar results were obtained in study by *Adami et al.*<sup>68</sup>

#### **AGE OF MENARCHE:**

Increased risk of ovarian tumors associated with early menarche is put forward by various studies like study by *Adami et al and Hildreth et al.*<sup>68,69</sup> In the present study only 18.60 % patients attained menarche before 12 years of age. This is in contrast to the above mentioned studies. As in present study, *Kayastha et al* recorded similar finding of 91.7 % tumors in patients with menarche after age of 12 years.<sup>65</sup> This difference may be explained by the fact that both studies by Adami et al and Hildreth et al were conducted in western population where as the present study and study by Kayastha et al were conducted in Indian subcontinent. The onset of menarche is influenced by female biology, as well as genetic and environmental factors, especially nutritional factors. Females

from western countries have been shown to have younger age at menarche with possible role played by nutritional status.

### **MENSTRUAL STATUS:**

Similar to other studies, present study revealed higher incidence of ovarian tumors in reproductive age group. Higher incidence of ovarian tumors was observed in 21-40 years and premenopausal age group. In postmenopausal patients, comparatively higher incidence of malignant tumors was observed. Similar findings were recorded in study by *R Jha et al* and also in study by *Pilli et al* and by *Merino et al*.<sup>63,64,70</sup>

### **MODE OF PRESENTATION :**

Some of the ovarian tumors may be incidentally diagnosed on ultrasound whereas others may be symptomatic. Present study reveals that the presentation of the ovarian tumors is variable. If patient presented with more than one complaint then the predominant symptom was considered as the presenting symptom. In the present study the commonest presenting symptom was pain in the abdomen 209 (69.43%) followed by mass abdomen 43 (14.28 %). Ascites was present in 23 (7.64 %) patients

whereas menstrual irregularities including post menopausal bleeding in 19 (6.31 %). Asymptomatic patients were only 7 (2.32 %) with these tumors being incidentally diagnosed on ultrasound done for other cause or as a routine work up. The results comply well with a study carried out by *Rashid et al*, in which abdominal pain was the commonest presenting complaint (59%) followed by abdominal mass/distension (37%).<sup>71</sup> Study done by *Sumaria Yasmin et al* showed similar findings.<sup>7</sup> In contrast to this, in another retrospective analysis by *Jamal et al* the commonest mode of presentation was bleeding per vaginum, followed by pain abdomen, pelvic mass and gastric intestinal symptoms.<sup>72</sup>

#### **UNILATERAL / BILATERAL PRESENTATION:**

In the present study most of the tumors were unilateral. Only 33 out 301 tumors (constituting almost 11%) had bilateral presentation. Among bilateral tumors 21 (64%) were malignant. Thus among bilateral tumors, malignant tumors are more common . 21 out of 76 (27.63 %) malignant tumors presented bilaterally as against 12 out of 225 (5.33 %) benign tumors. This finding was similar to study done by *R Jha et al* who encountered only 6.7 % benign tumors and 42.3 % malignant tumors presenting bilaterally.<sup>64</sup> Compared to the present study, higher incidence

of bilaterality was present in the study by *Kar et al* which showed 26.8% bilaterality.<sup>66</sup> Out of 12 cases of endometrioid carcinoma present in this study 6 (50%) had bilateral presentation. Serous carcinoma showed 42.85 % and mucinous carcinoma 33.33 % bilaterality. The most common benign tumor to present bilaterally was mature cystic teratoma, which showed 23.8 % bilaterality. Tumours in the sex cord stromal category are almost always confined to a single ovary, similar observation is made in this study.<sup>7</sup> From 32 sex-cord stromal tumors, none had bilateral presentation. As seen in study by *Zhao et al* most of the metastatic tumors occur in premenopausal patients and have bilateral presentation.<sup>60</sup> In the present study all the metastatic tumors had bilateral presentation. Ovarian dermoids can be bilateral in 15% cases.<sup>73</sup>

### **SIZE OF THE TUMOR:**

Largest dimension of the tumor was utilized to categorize the tumors according to the size. In present study tumors ranged in size from 3cms to 32 cms. Almost all the tumors i.e. 276 (91.69%) were less than 20 cms in the largest dimension. Only 24 tumors had their largest dimension between 21 to 30 cms. The largest tumor was measuring 32x25x12 cms



which was unilateral benign serous cystadenoma affecting a 27 year old lady. Bilateral endometrioid adenocarcinoma was the smallest tumor in this study measuring 3x2x1.5 cms present in a 55 year lady. This finding correlated with study by *Pilli et al*, In their study the largest tumor measured 33x23x22 cms and smallest one measured 3x2x1 cms.<sup>63</sup>

### **GROSS FEATURES :**

In the present study, 215 out of 301 (71.43 %) tumors had purely cystic architecture. Solid tumors were 57 out of 301 and thus comprised 18.94 %. Combined solid and cystic presentation was present in 29 tumors (9.63 %). Study done by *Kar et al* had 58.21 % cystic tumors, 13.43 % solid and 28.36 % combined solid and cystic tumors.<sup>66</sup> The relatively high proportion of tumors with complex architecture and less percentage of cystic tumors in study by Kar et al can be explained by the fact that this study had more number of malignant tumors. Patients with solid or complex ovarian tumors are at high risk of ovarian malignancy was shown in study done by *McDonald JM et al*.<sup>74</sup>

## HISTOPATHOLOGICAL PATTERNS:

In this study WHO classification was implemented to classify the tumors. Surface epithelial tumors constituted the most common category in the present study contributing to 80.73 % of all tumors followed by germ cell tumors, sex cord stromal tumors and metastatic tumors in decreasing order of frequency as seen in other studies from India and neighboring countries like Pakistan and Nepal.

Histopathological type	<i>Present study</i>	<i>Shahbaz et al</i> <sup>75</sup>	<i>Naseer et al</i> <sup>21</sup>	<i>Kar et al</i> <sup>66</sup>	<i>Pilli et al</i> <sup>63</sup>	<i>Kayasth et al</i> <sup>65</sup>
Surface Epithelial Tumors	80.73 %	83.3%	81.0%	79%	70.9%	72.6%
Germ Cell Tumors	10.63 %	14.0%	10.95%	16%	21.2%	25.3%
Sex Cord Stromal Tumors	7.31 %	2.7%	5.03%	1.5%	6.7%	2.10%
Metastatic Tumors	1.33 %	-	1.58%	3.5%	0.7%	-

Benign serous cystadenoma was the commonest tumor type with 35.54% of tumors. This was followed by benign mucinous cystadenoma having incidence of 21.26%. Cases of Serous, mucinous and endometrioid cystadenofibromas were also reported. Among malignant tumors, serous

cystadenocarcinoma was the most common category followed by mucinous cystadenocarcinomas. Cases of endometrioid and clear cell carcinomas were also present. In borderline surface epithelial tumor category borderline mucinous tumor dominated the category along with only 2 cases of serous borderline tumors. No transitional cell tumors were seen in this study. Benign mature cystic teratoma was the most common germ cell tumor whereas fibroma and granulosa cell tumor were the most common sex cord stromal tumors. Metastatic Krukenberg tumors were also present. Single case of sex cord tumor with annular tubules was seen. Some differences in incidence of certain ovarian tumors in the study population were noticed when compared to other studies. The most marked one was the higher incidence of endometrioid adenocarcinoma in the present study, with 12 cases being reported. Another important feature regarding this tumor category was high incidence of bilateral presentation which was observed in 50% cases. Another important difference was in the incidence of the borderline surface epithelial tumors with higher incidence recorded in present study. Both differences in tumor morphology, the higher incidence of endometrioid carcinoma type and borderline grade are among better prognostic criteria.

Sr No.	Type Of Tumor	<i>Present Study</i>	<i>Naseer et al</i> <sup>21</sup>	<i>R Jha et al</i> <sup>64</sup>
1.	Serous Cystadenoma	35.54 %	42.07	27.33%
2.	Serous Cystadenofibroma	1.33 %		0.62%
3.	Borderline Serous Tumor	0.66 %	-	-
4.	Serous Cystadenocarcinoma	6.64 %	8.78%	7.45%
5.	Mucinous Cystadenoma	21.26 %	16.85%	13.04%
6.	Mucinous Cystadenofibroma	0.66 %		-
7.	Borderline Mucinous Tumor	3.65 %	-	-
8.	Mucinous Cystadenocarcinoma	5.32 %	12.11%	3.73%
9.	Endometrioid Adenofibroma	0.66 %	-	-
10.	Endometrioid Carcinoma	3.99 %	-	-
11.	Clear Cell Carcinoma	0.99 %	-	-
12.	Mature Cystic Teratoma	8.64 %	7.2%	40.37%
13.	Dysgerminoma	1.33 %	2.73%	-
14.	Mixed Germ Cell Tumors	0.66 %	-	-
15.	Fibroma	2.66 %	1.29%	0.62
16.	Thecoma	0.33 %	0.41%	1.86
17.	Fibrothecoma	0.66 %	-	-
18.	Granulosa Cell Tumor	2.66%	3.6%	0.62
19.	Sertoli Cell Tumor	0.66 %	-	-
20.	SCTAT	0.33 %	-	-
21.	Metastatic	1.33 %	1.58%	1.24

(SCTAT- Sex Cord Stromal Tumor with Annular Tubules)

### **BENIGN / BORDERLINE / MALIGNANT:**

Out of 301 cases studied, majority were benign tumors [225 (74.75%)], followed by malignancy [63(20.93 %)] and [13(4.32 %)] cases of borderline malignancy were found.

Sr. No.	Nature Of Tumor	Present study	Pilli et al <sup>63</sup>	Naseer et al <sup>21</sup>	R Jha et al <sup>64</sup>	Kayastha et al <sup>65</sup>	Sumaria et al <sup>7</sup>
1.	Benign	74.75 %	75%	68.25%	83.9%	90.5%	89.71%
2.	Borderline	4.32 %	3%	0.72%	-	-	-
3.	Malignant	20.93 %	22%	30.96%	16.1%	9.5%	10.29%

These findings were similar to studies done by Pilli et al and Nasser et al other studies recorded higher incidence of benign tumors.

#### **AGE WISE DISTRIBUTION OF BENIGN / BORDERLINE /**

#### **MALIGNANT TUMORS:**

Under age of 20 years, benign tumors were common than malignant tumors. All the malignant tumors in this age group belonged to germ cell tumors, dysgerminoma or malignant mixed germ cell tumor. Under age of 40 years majority of the tumors were benign with malignant tumors contributing to only 14.10%. Above the age of 40 years much higher incidence of malignancy was noted with 37.88% malignant tumors.

## **VARIABLES RELATED TO RISK OF MALIGNANCY:**

Chi square test and logistic regression analysis were applied to evaluate the risk of malignancy associated with various parameters analyzed in the present study. To find out the risk factors to predict malignancy in tumors, seven independent variables were selected. These were age, parity, age at menarche, menstrual status, laterality, size and tumor morphology. Out of these risk factors studied, increasing age nulliparity or low parity, postmenopausal status, bilaterality and complex or solid tumor morphology conferred higher risk of malignancy. Early menarche and size of the tumor did not correlate with the increased risk of malignancy. Among all the risk factors evaluated, bilaterality conferred 4 times increased risk of malignancy over unilateral tumors. Tumor morphology was the most important risk factor, predicting 23 times increased risk of malignancy in complex and solid tumors compared to cystic tumors. Using these seven risk factors together as a model to predict the risk of malignancy in a given tumor, 92.44 % of the cases could be correctly predicted as being malignant and 73.68 % of the cases as benign. Overall, the model predicted 87.71% of the cases correctly into their respective groups. (i.e. Malignant or Benign)

## SUMMARY

---

This descriptive study included all the ovarian tumors received in the Department of Pathology, Coimbatore Medical College in three years, from March 2007 to April 2010. A total 301 cases were studied and analyzed in the present study.

1. Ovarian tumors were found to be more common in reproductive age group. The premenopausal age group was more frequently affected than post menopausal age group.
2. Even though the total number of nulliparous patients and patients with low parity was low, the incidence of malignant ovarian tumors was higher in them.
3. The incidence of benign tumors was found to be much higher than that of borderline and malignant tumors.
4. Surface epithelial ovarian tumors were the most common category followed by germ cell tumors. Metastatic tumors were least common.
5. Most of the tumors were cystic in consistency with complex or solid architecture being less common, which could be explained by the

higher incidence of benign surface epithelial tumors having cystic morphology.

7. The tumors ranged in size from 3 to 31 cms. Most of the tumors were less than 20 cms in size.
8. Incidence of bilateral tumors was less than unilateral tumors. But in bilateral tumors there was a higher incidence of malignancy, whether primary or metastatic.
9. Abdominal pain was the most common symptom followed by mass per abdomen.
10. Benign serous cystadenoma was the most common ovarian tumor followed by benign mucinous cystadenoma. No case of transitional cell tumor was recorded.
11. Increased incidence of malignancy was noted with age more than 50 years, postmenopausal age group, solid and complex tumor morphology, nulliparity or low parity and bilaterality of tumors. All these risk factors were found to be statistically significant. Early menarche and tumor diameter did not correlate with increased risk of malignancy.



## CONCLUSION

---

Surface epithelial ovarian tumors was the most common category of ovarian tumors followed by germ cell tumors, sex cord stromal tumors and metastatic tumors in decreasing order of frequency. Incidence of benign tumors was much higher than malignant tumors with benign serous cystadenoma being the most common benign tumor and serous cystadenocarcinoma being the most common malignant tumor. Reproductive age group showed higher incidence of ovarian tumors whereas there was increasing incidence of malignancy with increasing age group. Exception to this was the higher incidence of malignant germ cell tumors in adolescent age group. Although nulliparity and low parity showed higher risk of malignancy, early menarche did not reveal any significant increase in malignancy. Pain in abdomen was the most common symptom whereas ascites was more commonly seen with malignant tumors. Menstrual complaints were observed more commonly with tumors with functional stroma with possible role of hormonal influence. Benign tumors showed cystic morphology and there was significant increase in incidence of malignancy in tumors with complex

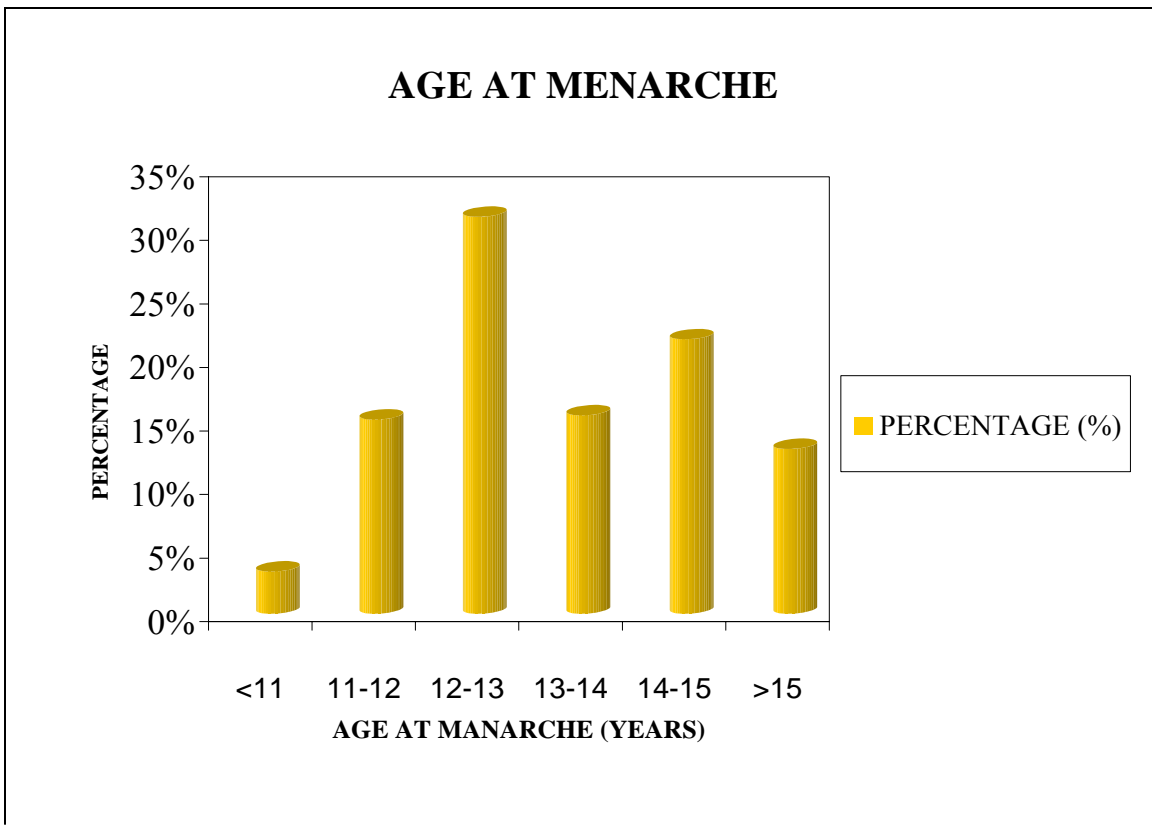
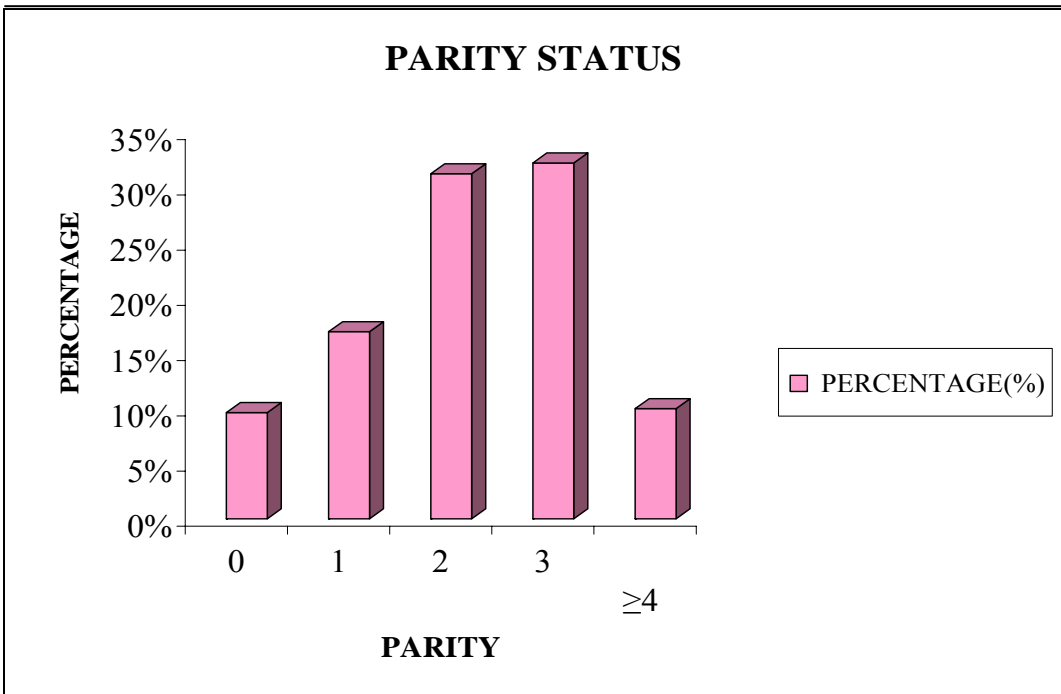
or solid morphology. Thus age more than 50 years, post menopausal age group, solid and complex tumor morphology, presence of ascites, nulliparity or low parity and bilaterality of tumors significant increased incidence of malignancy and thus these parameters can be used to predict the risk of malignancy in ovarian tumors.

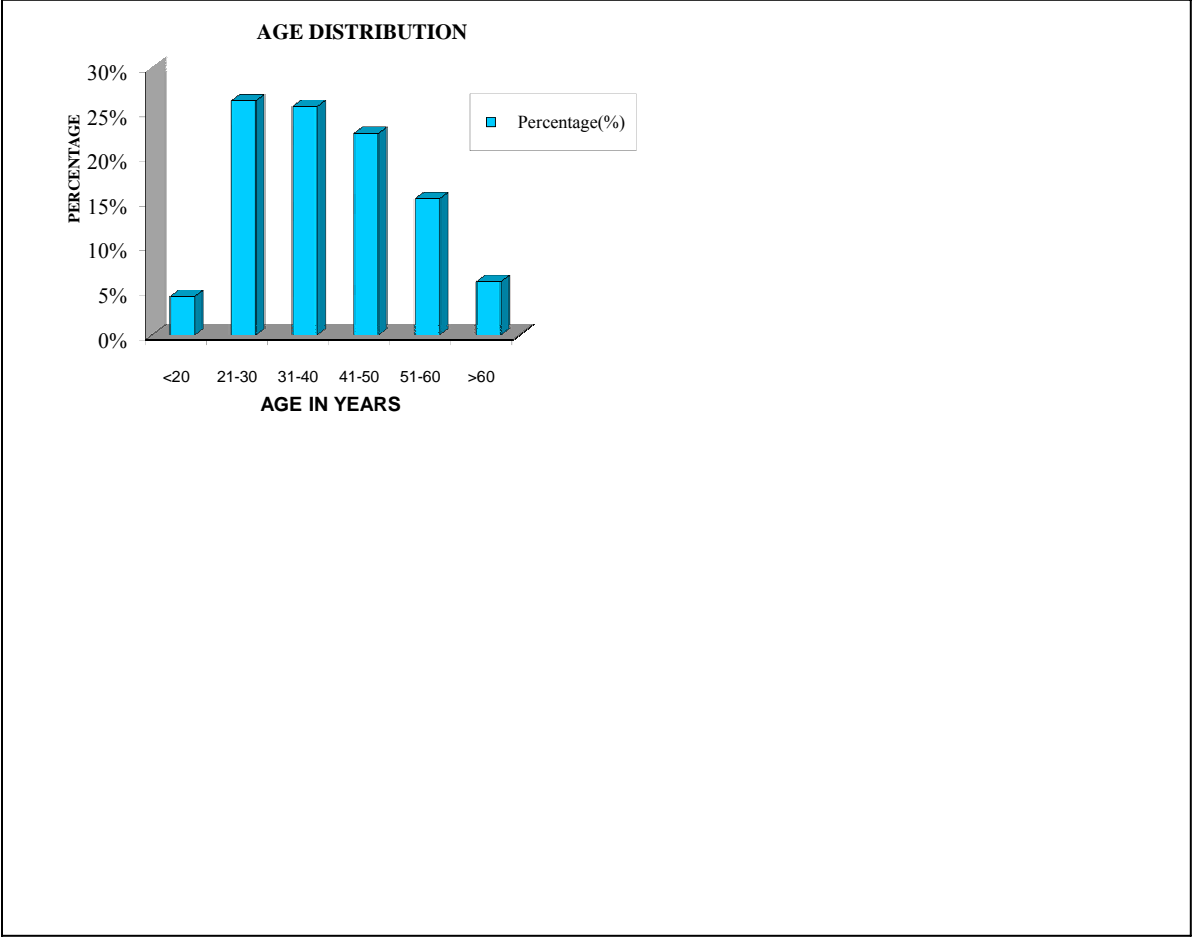
## **LIMITATIONS OF THE STUDY:**

This is a descriptive study. A longitudinal study with follow up of patients will definitely be of great value in predicting usefulness of the risk factors for malignancy evaluated in this study. In the present study, limited parameters were studied whereas a study including additional parameters such as family history of ovarian carcinoma, obesity, tumor markers, socioeconomic status, age at first childbirth, use of oral contraceptive pills or other hormonal intake will be of greater value.

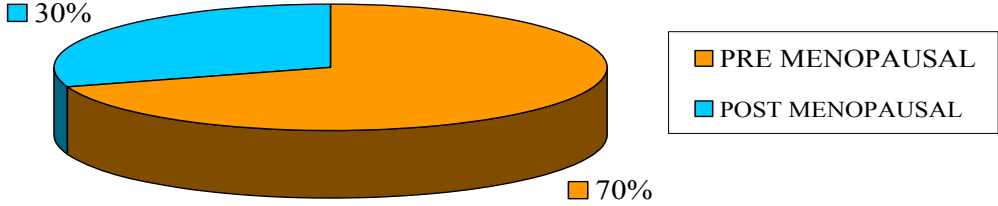
## **FUTURE SCOPE OF PRESENT STUDY:**

This study is of public health importance as it evaluates the incidence of various histopathological patterns, relative incidence of benign and malignant ovarian tumors and the risk factors associated with increased risk of malignancy in our population. This study may be helpful to clinicians as it gives them parameters to predict the relative risk of malignancy and plan the treatment protocol.

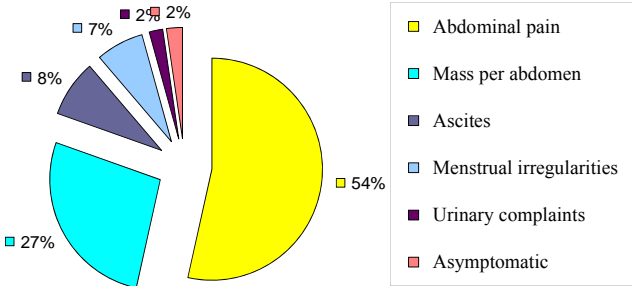




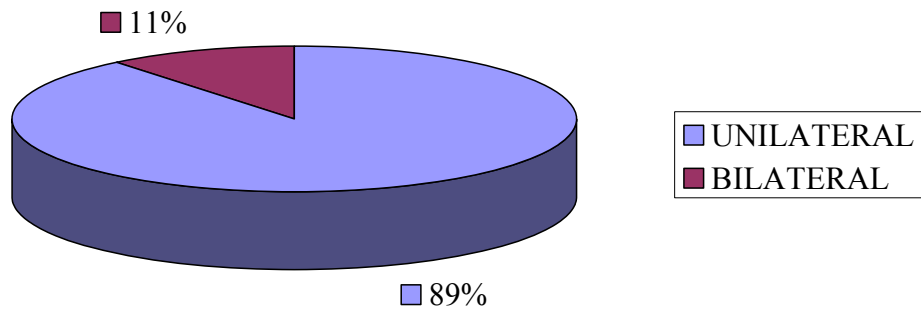
### MENSTRUAL STATUS



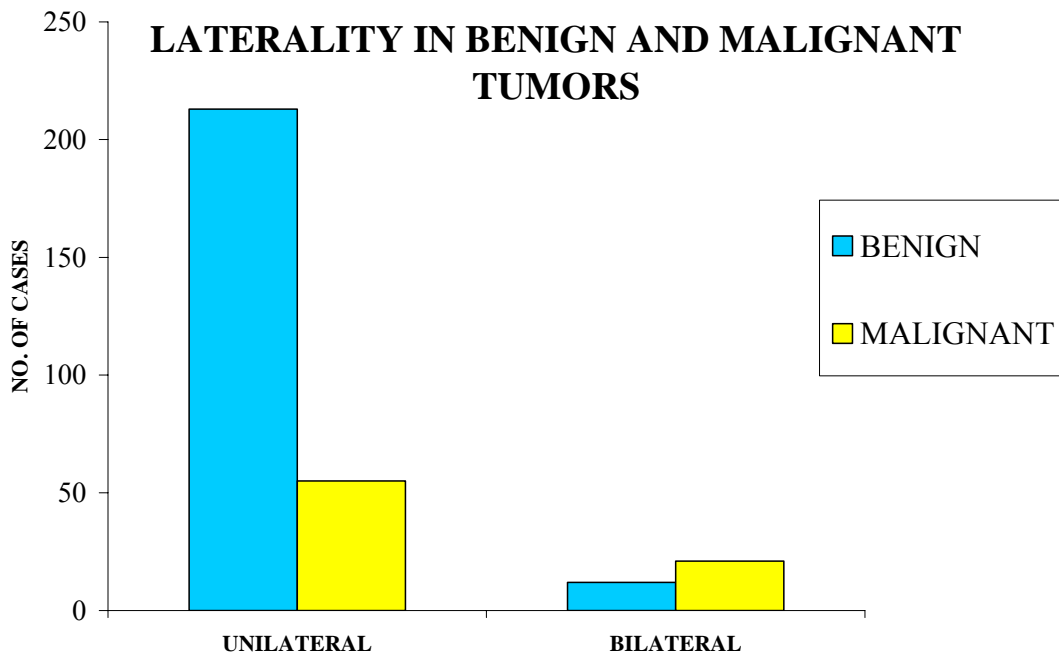
### MODE OF PRESENTATION



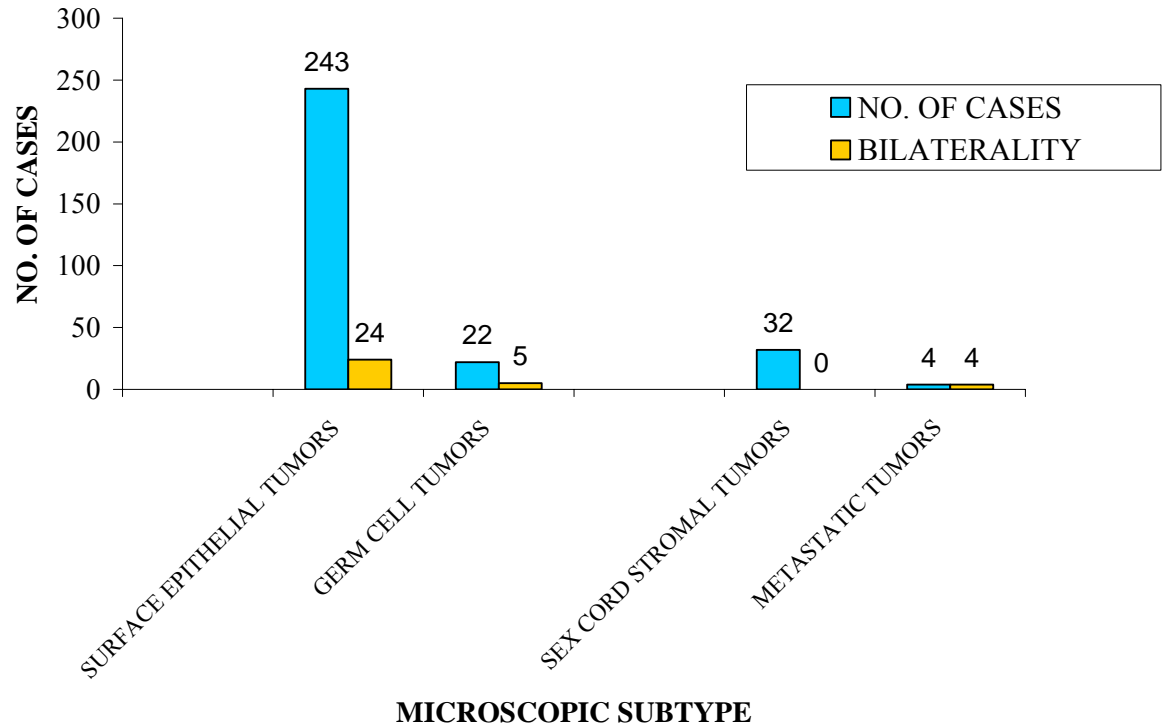
### LATERALITY OF TUMORS



### LATERALITY IN BENIGN AND MALIGNANT TUMORS

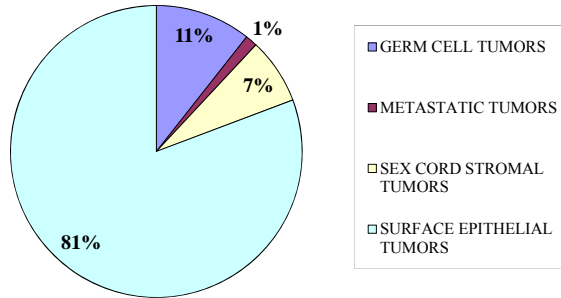


## BILATERALITY IN MAJOR SUBTYPES

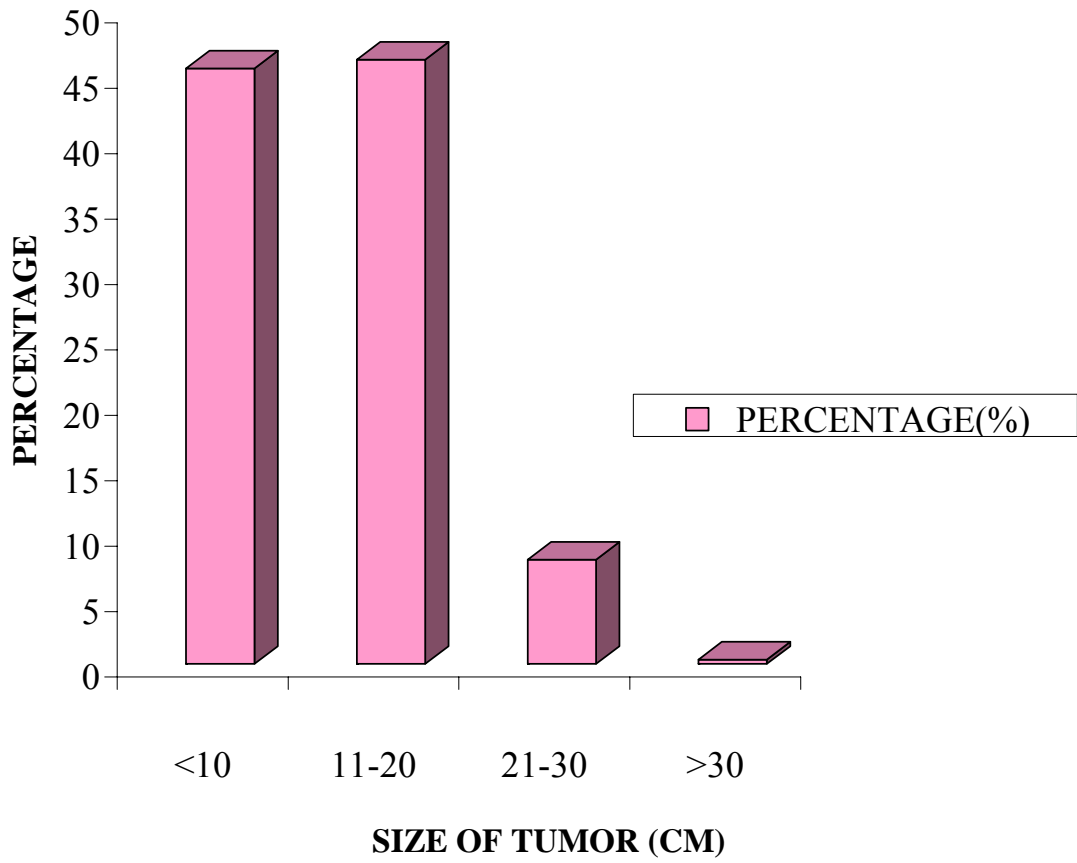




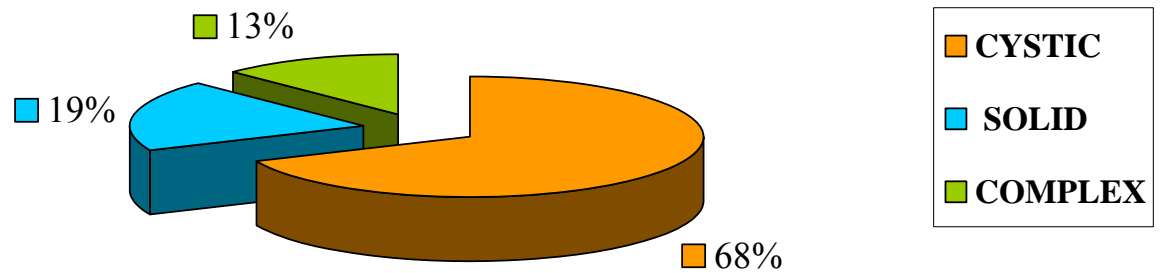
### MAJOR HISTOPATHOLOGICAL SUBTYPES



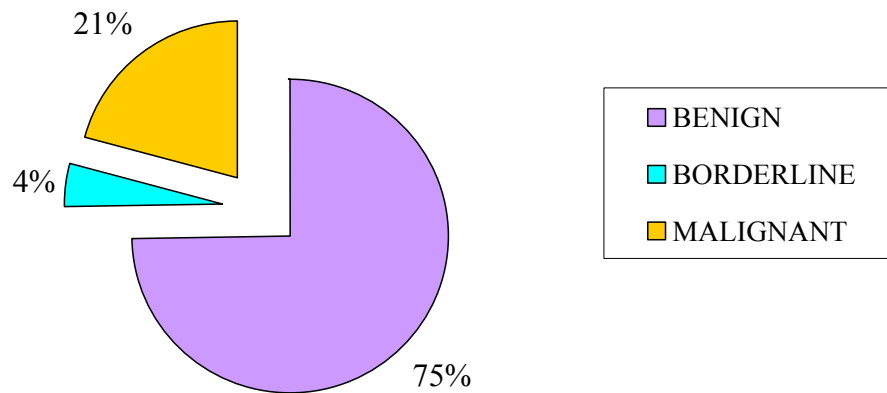
### SIZE OF THE TUMORS



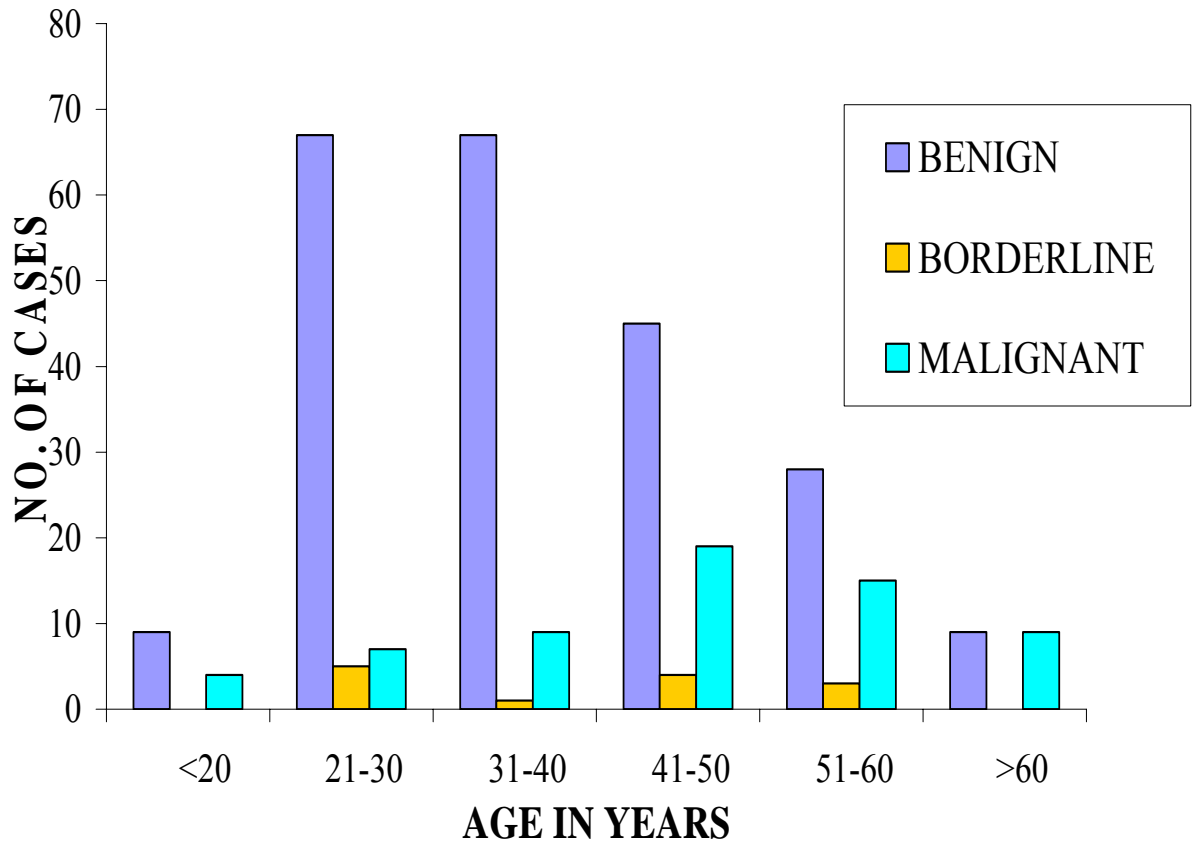
## GROSS MORPHOLOGY



## NATURE OF TUMOR



**AGE DISTRIBUTION OF  
BENIGN / BORDERLINE / MALIGNANT TUMORS**



**ANNEXURE VI - MASTER CHART**

No	HPE No	IP No	Age	Parity					Age at menarche					Menstrual status		Laterality		Complaints						Size	Gross			Diagnosis	
				0	1	2	3	≥4	<11	11to12	12to13	13to14	14to15	>15	pre	post	U/L	B/L	pain	mass	ascites	menstrua	urinary		asympto	Cystic	solid		complex
1	G136/09	208	35				+			+					+		+								7x6x5	+			12
2	G408/09	9869	20	+											+		+								6.5X6X4	+			5
3	G427/09	9138	46				+				+					+	+							5X5X2.5	+			12	
4	G632/09	10692	30			+				+					+		+							17X14X5	+			5	
5	G706/09	18166	23		+								+		+		+					+		5X3X3	+			1	
6	G737/09	12433	23		+					+					+		+							14X13X8	+			3	
7	G739/09	9319	58										+			+	+							24X20X13	+			6	
8	G760/09	14581	52												+		+							5X3X3	+			1	
9	G816/09	20626	17	+						+					+			+						10X7X6			+	2	
10	G820/09	15135	38				+				+				+		+							5X4X2.5	+			1	
11	G879/09	20382	46											+		+	+							9X7X2.5	+			1	
12	G914/09	22547	27			+									+		+							19X15X10	+			1	
13	G958/09	21200	45				+				+					+		+						20X15X7	+			1	
14	G959/09	22302	48		+					+						+		+						8.5X7X3			+	10	
15	G964/09	18007	38				+				+				+		+						+	5X3.5X2	+			1	
16	G1009/09	19583	60									+				+	+							12X10X7			+	9	
17	G1083/09	25185	42			+							+		+		+							18X13X6	+			5	
18	G1085/09	21801	42				+				+				+		+							8X7.5X5	+			5	
19	G1169/09	28992	32			+								+	+	+	+							7X5X2.5	+			5	
20	G1190/09	28400	40			+						+			+		+					+		6X4X4		+		18	
21	G1207/09	27874	40				+					+			+		+							6X5X2.5	+			12	
22	G1236/09	28283	38			+				+					+		+							20X15X6	+			5	
23	G1272/09	27255	60													+	+							7X6X2	+			1	
24	G1444/09	24632	40		+									+		+								13X11X8		+		10	
25	G1551/09	36041	34				+								+	+	+							9X8X3	+			1	
26	G1675/09	28413	60		+										+	+	+							13X12X7		+		4	
27	G1772/09	40504	45			+								+	+	+	+							12X11X6.5	+			5	
28	G1823/09	37921	60												+	+	+							25X24X15	+			7	
29	G1833/09	43422	21		+										+	+	+							7X5.5X4	+			1	
30	G1835/09	40587	27			+									+	+	+							30X25X15	+			1	
31	G1859/09	45533	24			+						+			+	+	+							5X5X4	+			1	
32	G1885/09	45085	42												+	+	+							10X8X6	+			1	
33	G1886/09	45922	35			+				+					+	+	+							10X7.5X5	+			1	
34	G1929/09	41783	63		+					+						+	+							15X13X5		+		11	
35	G1956/09	42136	60				+								+	+	+							6X5X4			+	12	
36	G2045/09	48863	68												+	+		+						21X17X7		+		21	
37	G2048/09	41809	20	+						+					+	+	+							27X18X10		+		14	
38	G2052/09	48856	50		+										+	+	+							9X5X4		+		4	
39	G2055/09	48420	58												+	+	+							8X7X5		+		11	
40	G2086/09	43242	68				+								+	+	+							5X4X3		+		4	
41	G2123/09	44907	57													+	+							25X22X7	+			2	
42	G2205/09	51388	55								+					+	+							17X15X10	+			5	
43	G2212/09	52251	70													+	+							5X4X3			+	9	
44	G2248/09	52598	50		+											+	+							14X14X13			+	10	
45	G2265/09	56505	21	+											+	+	+							8X8X7	+			1	
46	G2266/09	54748	26		+										+	+	+							7X6X3	+			12	
47	G2267/09	53408	29		+					+					+	+	+							6X5X4	+			7	
48	G2317/09	56347	46			+									+	+	+							18X15X6			+	7	
49	G2391/09	58893	26		+										+	+	+							24X18X11	+			7	

50	G2491/09	59446	28			+						+			+								+		11X9X7			+		19	
51	G2501/09	62294	60			+						+			+											6X5X4			+		4
52	G2548/09	63913	45			+																				6.5X5X2			+		18
53	G2558/09	63238	22			+																				12X9X4			+		1
54	G2664/09	66663	28																							6X4X3			+		12
55	G2676/09	58115	50																							20X15X6				+	8
56	G2738/09	69686	38			+																				9X6X4			+		1
57	G2786/09	70170	34																							15X12X10			+		5
58	G2796/09	62571	38																							10X8X4			+		1
59	G2797/09	69615	45																							10X8X3			+		7
60	G42/09	67787	43																							4X3X2			+		5
61	E40/09	4335	40																							12X11X4			+		8
62	E68/09	4823	60																							17X15X11				+	4
63	E366/09	5063	27																							13X10X7			+		12
64	E386/09	4564	32																							17X16X12			+		5
65	E471/09	5412	64																							12X12X5			+		1
66	E535/09	6984	43																							8X6X3			+		1
67	E602/09	7944	45																							15X14X6			+		5
68	E686/09	8901	40																							13X9X7			+		1
69	E723/09	9192	65																							16X11X7			+		5
70	E826/09	11338	48																							5X4X3.5			+		12
71	P7/09	3657	55																							3X2X1.5				+	10
72	P93/09	10888	28																							12X8X6			+		1
73	P117/09	13476	45																							12X9X6			+		12
74	P168/09	42071	40																							6X5X4			+		5
75	P199/09	8715	50																							27X22X14			+		5
76	P210/09	22005	30																							5X5X5			+		1
77	P215/09	20948	18																							11X9X4			+		1
78	PH139/09	20918	40																							7X5X4			+		5
79	326/09	5733	18																							21X15X11				+	14
80	PH1/09	4998	22																							7X7X6			+		5
81	PH52/09	8001	44																							15X12X7.5			+		1
82	PH61/09	10614	20																							9X8X6				+	15
83	PH75/09	12695	24																							9X7X6			+		1
84	PH78/09	12455	28																							11X11X10			+		1
85	PH80/09	13312	32																							12X9X8			+		5
86	PH105/09	37678	45																							7X4X4			+		1
87	PH106/09	16220	29																							7X6X4			+		1
88	PH123/09	16092	45																							14X11X6			+		1
89	PH130/09	16724	40																							5X4X4			+		1
90	G7/08	70835	56																							12X9X8				+	8
91	G10/08	72356	55																							9X6X3				+	4
92	G41/08	75252	40																							11X8X8			+		5
93	G58/08	443	29																							14X11X11			+		5
94	G59/08	73615	37																							9X6X4			+		12
95	G119/08	1101	55																							15X10X8				+	8
96	G153/08	922	48																							13X10X6				+	7
97	G181/08	2876	47																							15X14X7				+	4
98	G237/08	3136	35																							6X4X4			+		1
99	G265/08	5187	64																							22X15X10				+	8
100	G315/08	4957	70																							8X5X3			+		1
101	G362/08	6946	37																							17X12X10			+		5
102	G431/08	9198	45																							20X12X10			+		5
103	G446/08	7406	45																							17X15X10			+		1

104	G533/08	8201	45				+				+										7X6X4			+		4
105	G594/08	12932	60				+				+											10X10X9	+			5
106	G695/08	16718	30	+							+											17X15X8				7
107	G754/08	16702	48				+															12X11X10	+			5
108	G793/08	18699	38				+				+											17X15X11				8
109	G821/08	19841	38				+				+											7X6X3	+			12
110	G872/08	21667	45				+				+											15X9X8	+			5
111	G980/08	12673	49				+				+											12X10X9	+			5
112	G1017/08	27089	55				+				+											11X10X9	+			1
113	G1030/08	26153	47				+				+											7X4X3				4
114	G1090/08	27590	28					+			+											12X11X10				8
115	G1153/08	25630	19	+							+											25X20X17				19
116	G1253/08	31829	24				+															14X12X10	+			12
117	G1254/08	30407	76				+				+											5X4X3	+			4
118	G1294/08	31813	43				+				+											8X7X7	+			1
119	G1296/08	28054	47				+				+											9X8X8				10
120	G1321/08	31439	60				+				+											16X15X15	+			1
121	G1328/08	34992	17	+							+											20X20X18	+			5
122	G1420/08	36068	55				+				+											14X12X10	+			1
123	G1448/08	35548	62				+				+											13X12X10	+			1
124	G1250/08	35026	40				+				+											23X15X14	+			5
125	G1478/08	36398	23	+							+											17X15X14				13
126	G1497/08	36376	45				+				+											15X12X10				21
127	G1514/08	36580	45				+				+											11X10X9	+			1
128	G1515/08	36569	70				+				+											12X10X9				8
129	G1527/08	39120	32				+				+											18X17X15	+			1
130	G1585/08	39114	43				+				+											9X8X7	+			5
131	G1632/08	41329	21	+							+											12X11X10				18
132	G1690/08	36586	60				+				+											17X16X11	+			7
133	G1805/08	38092	46				+				+											22X20X19	+			5
134	G1826/08	45980	41				+				+											13X6X4				18
135	G1846/08	45242	38				+				+											11X10X7	+			12
136	G1883/08	46271	50				+				+											9X7X6	+			5
137	G1928/08	48067	35				+				+											15X14X8				20
138	G1948/08	50767	45					+			+											17X12X8				8
139	G1973/08	50858	70				+				+											22X20X17	+			1
140	G2001/08	51537	42				+				+											6X5X3				10
141	G2085/08	52396	33				+				+											17X15X14				8
142	G2153/08	56505	43				+				+											5X3X2				4
143	G2196/08	56519	40				+				+											23X17X15	+			8
144	G2204/08	54134	58				+				+											20X15X10	+			1
145	G2319/08	58922	23					+			+											8X8X6	+			12
146	G2356/08	56229	15	+							+											15X11X10	+			5
147	G2358/08	59699	30				+				+											18X12X11	+			5
148	G2394/08	55005	50				+				+											17X12X10				18
149	G2520/08	63279	55								+											20X19X15	+			12
150	G2530/08	60454	28					+			+											12X9X6				21
151	G2544/08	64358	20	+							+											13X11X10				15
152	G2589/08	64124	55				+				+											18X16X15	+			8
153	G2590/08	66177	27				+				+											3X2X2	+			5
154	G2637/08	65850	36				+				+											12X10X9				2
155	G2638/08	66019	19	+							+											15X14X9				13
156	G2679/08	67419	22	+							+											12X10X8	+			1
157	G2756/08	69854	22	+							+											14X11X9	+			5

158	E177/08	1000	29			+					+				+								13X12X9	+				5	
159	E206/08	1314	47			+						+			+									10X8X5	+				1
160	E233/08	1427	35			+									+									10X10X9			+		3
161	E237/08	1507	43				+																	9X4X3	+				1
162	E280/08	2235	24			+									+									14X11X10	+				5
163	E298/08	2413	30			+									+									6X4X4	+				1
164	E300/08	2114	59				+								+									5X5X3		+			18
165	E399/08	1376	25			+									+									6X6X4	+				1
166	E402/08	2922	44				+																	18X16X10	+				1
167	E434/08	3911	43			+																		22X19X11	+				5
168	E543/08	5173	45				+																	14X12X10	+				5
169	E800/08	3260	28			+																		12X10X9	+				7
170	E819/08	7916	49			+									+									10X8X7	+				1
171	E941/08	10303	28			+																		14X11X6			+		12
172	E943/08	9629	58				+																	14X12X10		+			16
173	E1024/08	10735	34			+																		9X6X5			+		8
174	E1111/08	11823	25			+																		5X4X3	+				12
175	PH9/08	981	58				+								+									15X12X10	+				5
176	PH23/08	1482	23				+																	6X6X6	+				1
177	PH35/08	5041	27			+																		19X16X8	+				5
178	PH46/08	7711	34				+																	8X7X6			+		1
179	PH48/08	6754	33				+																	23X18X12	+				1
180	PH53/08	7318	40				+																	10X8X8	+				1
181	PH61/08	8258	51				+																	10X9X9	+				1
182	PH63/08	9247	43				+																	6X6X6	+				1
183	PH99/08	15420	28			+																		14X13X12	+				1
184	PH120/08	23147	38				+																	14X8X6	+				1
185	PH124/08	24238	30				+																	12X12X12			+		2
186	PH137/08	24290	48				+																	5X4X3	+				1
187	P5/08	27055	29			+									+									8X7X6	+				1
188	P88/08	303582	28			+																		13X10X7		+			17
189	P151/08	15192	63				+																	20X20X20			+		10
190	G36/07	60905	24			+																		15X8X7	+				1
191	G42/07	66194	25			+																		24X15X8		+			21
192	G43/07	486	44				+																	7X6X4.5		+			4
193	G79/07	1359	23			+																		5X3X2	+				1
194	G114/07	56129	45				+																	10X8X4		+			4
195	G119/07	65696	74				+																	6X5X4	+				1
196	G157/07	1705	60				+																	10X10X7	+				1
197	G213/07	2729	60				+																	17X13X8			+		1
198	G314/07	1545	43				+																	6X3X2		+			4
199	G330/07	3315	50				+																	20X16X10	+				5
200	G332/07	5906	28			+																		12X8X6	+				1
201	G402/07	6099	45				+																	11X6X4	+				1
201	G439/07	30950	35				+																	20X16X12	+				5
203	G452/07	5006	50				+																	9X7X5		+			10
204	G465/07	9546	40				+																	7X6X5	+				12
205	G471/07	10348	70				+																	14X14X12			+		10
206	G660/07	10230	40				+																	6X4X3		+			15
207	G667/07	14142	57				+																	16X10X9			+		4
208	G673/07	12385	24			+																		16X12X8	+				5
209	G743/07	14228	50				+																	9X9X5		+			4
210	G766/07	116	53				+																	16X14X9	+				10
211	G816/07	15171	35				+																	12X8X5		+			5







## **BIBLIOGRAPHY**

1. Mario M. Leito et al. Clinopathologic analysis of early stage poradic ovarian carcinoma. Am J Surg Pathol. Volume 28, No 2, Feb 2004.
2. Pathology of the ovary, Jaime Prat ,Saunders 2004
3. Classification of human ovarian tumors , Robert E. Scully. Environmental Health Perspectives Vol. 73, pp15-24,1987.
4. Kindu Sarmila, Datta Ray Chitali, Pati Shyamapada, Majumder Anup. The incidence and management of malignant ovarian tumors in girls upto 20 years of age. J Obstet Gynecol India 2003; 53(4): 375-379.
5. Chen LM, Karlan BY. Early detection and risk reduction for familial gynecologic cancers. Clin Obstet Gynecol. 1998 ; 41 (1) : 200-214.
6. Whitney You Louis a, Dainty G, Scott Rose, Thomas Kerivac, Michael T, Ollen H et al. Gynecological malignancies in women aged more than 25 years .Am J Obstet Gynecol 2005; 105(6): 1405-1409

7. Sumaira Yasmin, Aiman Yasmin et al Clinico-histological Pattern Of Ovarian Tumors In Peshawar Region. J Ayub Med Coll Abbottabad 2008;20(4)
8. MM. Bhattacharya et al. A Clinicopathological analysis of 270 ovarian tumors. Journal of postgraduate medicine 1980;26.2; 103-7
9. Kurman, Robert J. The Origin and Pathogenesis of Epithelial Ovarian Cancer: A Proposed Unifying Theory. Am J Surg Pathol. 2010 March; 34(3): 433-443.
10. Kurman, Robert J. The Origin and Pathogenesis of Epithelial Ovarian Cancer: A Proposed Unifying Theory. Am J Surg Pathol. 2010 March; 34(3): 433-443.
11. Rosai J. Ovary. In: Ackerman's Surgical Pathology vol 2 (9th edition) St Louis : Mosby; 2004:1649-1736.
12. Langley F.A, Fox H. Ovarian tumors classification, histogenesis and etiology. In: Obstetrical and Gynecological Pathology. Fox H and Wells M (Eds) New York: Churchill Livingstone; 1995; 727-969.
13. Ramesh Dawar et al. Surface epithelial tumors of ovary. Indian Journal Of Medical And Paediatric Oncology 2004; 25(1): 5-9

14. Leita0 MM Jr, Boyd J, Hummer A, Olvera N, Arroyo CD, et al. Clinic pathologic analysis of early - stage sporadic ovarian carcinoma. *Am J Surg Pathol*. 2004 Feb;28(2):147-59.
15. Burks RT, Sherman ME, Kurman RJ. Micropapillary serous carcinoma of the ovary: a distinctive low-grade carcinoma related to serous borderline tumors. *Am J Surg Pathol* 1996;20:1319–1330.
16. Seidman JD, Kurman RJ. Subclassification of serous borderline tumors of the ovary into benign and malignant types: a clinicopathologic study of 65 advanced stage cases. *Am J Surg Pathol* 1996;20:1331–45.
17. Seidman JD, Kurman RJ et al. Ovarian serous borderline tumors: a critical review of the literature with emphasis on prognostic indicators. *Hum Pathol*. 2000 May;31(5):539-57.
18. Prat J, de Nictolis M. Serous borderline tumors of the ovary: a long-term follow-up study of 137 cases, including 18 with a micropapillary pattern and 20 with microinvasion. *Am J Surg Pathol* 2002;26:1111-28

19. Deavers MT, Gershenson DM, Tortolero-Luna G, et al. Micropapillary and cribriform patterns in ovarian serous tumors of low malignant potential: a study of 99 advanced stage cases. *Am J Surg Pathol* 2002;26:1129–1141.
20. Sarwar CM, Siddiqui N, Khokhar RA, Badar F et al. Epithelial ovarian cancer at a cancer hospital in a developing country. *Asian Pac J Cancer Prev*. 2006 Oct-Dec;7(4):595-8.
21. Naseer A Shaikh, Fazila Hashmi, Rukhsana Parveen Samoo. Pattern of ovarian tumors: report of 15 years experience at Liaquat University Jamshoro. *J Liaquat Uni Med Health Sci* Jan - Apr 2007;6(1):13-5
22. Koonings PP et al, Relative frequency of primary ovarian neoplasms : a ten year review. *Obstet Gynecol* 1989;74:921-926
23. Shappell, Heidi W, Riopel, Maureen A, Smith Sehdev, Ann E, Ronnett, Brigitte et al. Diagnostic Criteria and Behavior of Ovarian Seromucinous (Endocervical-Type Mucinous and Mixed Cell-Type) Tumors: Atypical Proliferative (Borderline) Tumors,

Intraepithelial, Microinvasive, and Invasive Carcinomas. Am Journ  
of Surg Pathol Issue: Volume 26(12), Dec 2002, 1529-1541.

24. Stephen S Raab, Robert A Robinson, Chris S Jenson, Dilik Ozkutlu, Patrik ORiley, Van H Savell. Mucinous tumors of the ovary. Interobserver diagnostic variability and utility of sectioning protocols. Arch Pathol Lab Med 1997; 121:1192-1198.
25. Scully RE , Clement et al. Endometrioid tumors in : Tumors of ovary, maldeveloped gonads, fallopian tube and broad ligament. Atlas of tumor pathology, third series, Fascicle 23, AFIP, 1998:107-140.
26. Bell, Karen A., Kurman, Robert J. et al A Clinicopathologic Analysis of Atypical Proliferative (Borderline) Tumors and Well-differentiated Endometrioid Adenocarcinomas of the ovary. American Journal of Surgical Pathology: November 2000 – Volume 24 - Issue 11 - pp 1465-1479
27. Eifel P. et al. Simultaneous presentation of carcinoma involving ovary and uterine corpus. Cancer 1982;50:163-170.
28. Zaino RJ et al. Synchronous carcinomas of the uterine corpus and ovary. Gynecol Oncol 1984; 19: 329-335.

29. Ulbright TM et al. Metastatic and independent cancers of the endometrium and ovary; a clinicopathologic study of 34 cases. *Human Pathol* 1985;16:28-34.
30. Kline RC et al. Endometrioid carcinoma of ovary: retrospective review of 145 cases. *Gynecol Oncol* 1990;39:337-346.
31. Falkenberry SS et al. Synchronous endometrioid tumors of ovary and endometrium. A Clinicopathologic study of 22 cases. *J Reprod Med* 1996;41:713-718.
32. Komiyama et al. prognosis of Japanese patients with ovarian clear cell carcinoma associated with pelvic endometriosis. *Gynecol Oncol* 1999;72:342-346.
33. Crozeir MA et al. Clear cell carcinoma of ovary a study of 59 cases. *Gynecol Oncol* 1989;35:199-203.
34. Montag AG et al. Ovarian clear cell carcinoma; A clinicopathological study of 44 cases/ *Int J Gynecol Pathol* 1989;8:85-96.
35. Longacre TA, Teng NNH, Hendrickson MR. The gynecologic frozen section. In: Ranchod M, ed. *Pathology: State of the Art views*. Philadelphia, PA: Hanley and Belfus, Inc; 1996:427-492.



36. Kleimi PJ et al. Clear cell tumors of ovary with resembling endodermal sinus tumors. *Int J Gynecol Pathol* 1982;1:95-100.
37. Ehrlich CE et al. The Brenner tumor. A clinicopathological study of 57 cases. *Cancer* 1971 ; 27:332-342.
38. Silverberg SG. Brenner tumor of ovary. A clinicopathologic study of 60 tumors in 54 cases. *Cancer* 1971;28:588-596
39. Eichhorn, John H, Young, Robert H et al. Transitional Cell Carcinoma of the Ovary: A Morphologic Study of 100 Cases With Emphasis on Differential Diagnosis. *American Journal of Surgical Pathology*: April 2004, Vol 28 (4) 453-463
40. Irving, Julie A., Young, Robert H. et al. Granulosa Cell Tumors of the Ovary With a Pseudopapillary Pattern: A Study of 14 Cases of an Unusual Morphologic Variant Emphasizing Their Distinction From Transitional Cell Neoplasms and Other Papillary Ovarian Tumors. *The American Journal of Surgical Pathology* Issue: Volume 32(4), April 2008, 581-586.
41. Young, Robert H. M.B. et al. Juvenile granulosa cell tumor of the ovary: A clinicopathological analysis of 125 cases. *Am J Surg Pathol*. 1984 Aug;8 (8):575-96.

42. Paul N. Staats, W. Glenn McCluggage, W. Philip B. Clement et al. Luteinized Thecomas (Thecomatosis) of the Type Typically Associated With Sclerosing Peritonitis. A Clinical, Histopathologic, and Immunohistochemical Analysis of 27 Cases *Am J Surg Pathol* - Volume 32, Number 9, September 2008.
43. Julie A. Irving, Abdulmohsen Alkushi, Robert H. Young et al. Cellular Fibromas of the Ovary: A Study of 75 Cases including 40 Mitotically Active Tumors Emphasizing Their Distinction From Fibrosarcoma *Am J Surg Pathol* \_ Volume 30, Number 8, August 2006.
44. Tsuji, Takahiro, Kawauchi, Shigeto, Utsunomiya et al. Fibrosarcoma Versus Cellular Fibroma of the Ovary: A Comparative Study of Their Proliferative Activity and Chromosome Aberrations Using MIB-1 Immunostaining, DNA Flow Cytometry, and Fluorescence in Situ Hybridization. *The American Journal of Surgical Pathology* Issue: Volume 21(1), January 1997, pp 52-59.
45. Kawauchi S, Tsuji T, Kaku T, Kamura T, et al. Sclerosing stromal tumor of the ovary: a clinicopathologic, immunohistochemical,

ultrastructural, and cytogenetic analysis with special reference to its vasculature. *Am J Surg Pathol* 1998 Jan;22(1):83-92.

46. Oliva, Esther, Alvarez, Teresa, Young, Robert H et al. Sertoli Cell Tumors of the Ovary: A Clinicopathologic and Immunohistochemical Study of 54 Cases. *Am Journal of Surgical Pathology*: February 2005 - Volume 29 - Issue 2 - pp 143-156.
47. Robert H Young. Sex cord-stromal tumors of the ovary and testis: their similarities and differences with consideration of selected problems. *Modern Pathology* (2005) 18, S81–S98.
48. Susanne Duun. Bilateral virilizing hilus (Leydig) cell tumors of the Ovary. *Acta Obstetricia et Gynecologica Scandinavica*. 1994, Vol. 73, No. 1 : Pages 76-77
49. Archana Amatya, Ashma Rana, Geeta Gurung et al. Ovarian tumors in childhood and adolescents -Our eight years experiences. *Nepal Journal of Obstetrics Gynaecology*, Vol 3, No 1 (2008).
50. Cheng, Liang, Thomas, Antoinette, Roth et al. OCT4: A Novel Biomarker for Dysgerminoma of the Ovary. *American Journal of Surgical Pathology*: October 2004 - Volume 28 - Issue 10 - pp 1341- 1346.

51. An Dave, FA Shah, RP Sagar, HB Raval et al. Ovarian Yolk Sac Tumor. *Ind J Radiol Imag* 2005 15:4:525-527.
52. Robek.I,JK. Lirman and Henry Krism. Embryonal carcinoma of the ovary :A Clinicopathologic Entity Distinct From Endodermal Sinus Tumor Resembling Embryonal Carcinoma of the Adult Testis. *Cancer* 38 : 24 20-24 33, 1976.
53. Ronnett, Brigitte M. M.D.; Seidman, Jeffrey D. Mucinous Tumors Arising in Ovarian Mature Cystic Teratomas: Relationship to the Clinical Syndrome of Pseudomyxoma Peritonei *American Journal of Surgical Pathology*: May 2003 - Volume 27 - Issue 5 - pp 650-657.
54. Kurman RJ et al. malignant mixed germ cell tumors of ovary. A clinical and pathological analysis of 30 cases. *Obstet Gynecol* 1976;48;579-589.
55. Reckova M, Mego M et al.Small-cell carcinoma of the ovary with breast metastases: a case report. *Klin Onkol.* 2010;23(1): 43-5.
56. Young RH et al. Ovarian tumors of probable wolffian origin: a report of 11 cases. *Am J Surg Pathol* 1983;7;125-136.

57. Karminjed MH et al. Female adnexal tumor of probable wolffian origin: a distinctive pathologic entity. *Cancer* 1973;31:671-677.
58. Murakami M, Uehara H A et al. Huge ovarian smooth muscle tumor: a case report. *J Med Invest.* 2010 Feb;57(1-2):158-62
59. Mazur MT et al Metastasis to female genital tract. Analysis of 325 cases. *Cancer* 1984;53: 1978-1984.
60. Zhao J Z et al. Clinicopathological features and prognosis of 68 patients with metastatic ovarian tumors from the gastric cancer. *Chinese journal of gastrointestinal surgery.* 2010 Mar;13(2):129-32.
61. Talia K. Ben-Jacob, Chad R. Gordon, and Frank Koniges et al. Krukenberg Tumors: A Review *Journal of Surgical Radiology Vol 1; 2010 pg no.1-60*
62. Naseer A. Shaikh, Fazila Hashmi et al. Pattern of ovarian tumors Report of 15 years experience at Liaquat University Jamshoro. *JLUMHS; January-April 2007.*
63. Ganga S Pilli, K.P.Sunitha, A.V.Dhaded, V V.Yenni. Ovarian tumors a study of 282 cases. *J Indian Med Associ* 2002; 100(7): 420-424.

64. R Jha and S Karki. Histological pattern of ovarian tumors and their age distribution. *Nepal Med Coll J* 2008; 10(2): 81-85
65. S Kayastha. Study of ovarian tumours in Nepal Medical College Teaching Hospital. *Nepal Med Coll J* 2009; 11(3): 200-202
66. Kar Tushar, Kar Asanranthi Mohapatra PC. Intraoperative cytology of ovarian tumours, *J Obstet Gynecol India* 2005; 55(4): 345-349.
67. Deshpande et al. a study of ovarian enlargement in adolescent girls. *J Obstet Gynaecol India* 1983;33:812-16.
68. Adami HO et al. Parity, age at first childbirth, and risk of ovarian cancer. *Lancet*.1994 Nov 5; 344(8932):1250-4
69. Hildreth et al. An epidemiological study of ovarian carcinoma ovary. *Amer J Epidemiol* 1981;114:389-405
70. Merino MJ, Jaffe G. Age contrast in ovarian pathology. *Cancer* 1993; 71 (2 Suppl): 537-44.
71. Rashid S, Sarwar G, Ali A. A clinicopathological Study of ovarian cancer. Departments of Radiotherapy and oncology Sir Ganga Ram Hospital and Mayo Hospital Lahore. *J Pak Med Assoc* 1998;36:117–25.

72. Jamal S, Quddusi H, Mehmood A. A Clinico Histopathological analysis of 110 ovarian tumours. Pak J Med Sci 1997;14:19–23.
73. Sinha R, Sethi S et al. Multiple and Bilateral Dermoids: A Case Report J Minim Invasive Gynecol. 2010 March - April;17(2):235-238.
74. McDonald JM et al. Predicting risk of malignancy in adnexal masses. Obstet Gynecol. 2010 Apr;115(4):687-94.
75. CM Shahbaz Sarwar, Neelam Siddiqui, Rizwan Anwar Khokhar et al. Epithelial Ovarian Cancer at a Cancer Hospital in a Developing Country. Asian Pacific J Cancer Prev, 7, 595-598

**ANNEXURE – I**  
**PROFORMA**

- **DEMOGRAPHIC DETAILS :**

Name

Age

- **IDENTIFICATION DETAILS :**

IP No.

HPE No.

- **MODE OF PRESENTATION :**

Abdominal pain

Mass per abdomen

Ascites

Menstrual complaints

Urinary complaints

Asymptomatic

- **PAST HISTORY :**

- **FAMILY HISTORY:**

- **MENSTRUAL HISTORY:**

Age at menarche



Age at menopause

- **PARITY :**

- **GROSS DETAILS :**

Laterality – Unilateral / Bilateral

Size in cms.

External surface

Cut surface – Cystic / Solid / Complex

Contents of the cyst – Serous / Mucinous / Pultaceous

Other relevant details

- **MICROSCOPIC DETAILS :**

- **HISTOPATHOLOGICAL DIAGNOSIS :**

## ANNEXURE – II

### I. HAEMATOXYLIN AND EOSIN STAINING

Fixation – 10% Formalin

Technique – Paraffin section cut at 6 microns

#### SOLUTION PREPARATION:

Haematoxylin - 10 gram.

Absolute alcohol - 100 ml     Dissolve with light heat

Aluminum Potassium sulphate 200 gram dissolved in warm 2 liters of distilled water. Both are mixed and boiled: 5 gms of mercuric oxide is added while boiling and cooled after two minutes. Prior to use, 3 ml of acetic acid for 100 ml of hematoxylin is added.

#### 1% ACID ALCOHOL

70% alcohol - 990 ml.

Concentrated HCl - 10 ml.

#### EOSIN

Eosin - 10 gram		Dissolved
D.H <sub>2</sub> O - 100 ml.		

Phloxine 'B' - 100 mg		Dissolved
D.H <sub>2</sub> O - 20 ml		

Both are mixed and 780 ml of 90% alcohol is added. 4 ml of glacial acetic acid and saturated Lithium carbonate are added.

**PROCEDURE:**

1. The slide is kept in xylene for 15 minutes.
2. It is washed in graded alcohol absolute 90% : 80% each 2 dips
3. Slide is washed in water for 5 minutes.
4. Stained in haematoxylin for 5 minutes.
5. It is washed in water for 5 minutes.
6. Differentiated in 1% acid alcohol 2 dips
7. Washed in water for 2 minutes.
8. Twice dipped in Lithium carbonate for blueing
9. Washed in water for 10 minutes
10. Dipped in 80% alcohol
11. Stained with eosin for 5 minutes.
12. Dehydrated in graded alcohol 80%, 90% then absolute alcohol
13. Cleared in xylene.
14. Mounted in D.P.X.

**RESULTS:**

Nuclei - Blue      Cytoplasm - Pink

## **ANNEXURE – III**

### **PERIODIC ACID SCHIFFS REAGENT STAIN (PAS)**

Fixation - 10% Formalin, Alcohol, Buffered Formalin.

Technique - Paraffin Section cut at 6 microns

### **SOLUTION PREPARATION**

1% Periodic Acid

Periodic Acid - 1 gram

Distilled water - 100 cc

### **SCHIFFS REAGENT**

In 100ml of warm distilled water 5 gram of Basic fuchsin is added and allowed to boil. It is then cooled and 10 gram of potassium metabisulphite and 50ml of 1 Normal HCL 50ml are added and kept in dark place over night (24 hours) Then 25 gram of charcoal powder is added, shaken and kept in dark place for 2 hours. It is filtered and stored in fridge.

#### **1. NORMAL HCL**

HCL - 8.35ml

Distilled water - 91.65 ml

**PROCEDURE:**

1. The slide is deparaffinised in 15 ml of xylene.
2. Washed in Graded alcohol ab.90%,80% each 2 dips.
3. Washed in water for 5 minutes.
4. Placed in 1% periodic acid 5 minutes.
5. Washed in water for 5 minutes.
6. Placed in Schiff's reagent 15 minutes.
7. Washed in water for 10 minutes.
8. Stained in Haematoxylin for 3 minutes.
9. Then washed in water for 2 minutes.
10. Differentiated in 1% acid alcohol 3 dips.
11. Washed in water for 2 minutes.
12. Lithium carbonate 1 dip.
13. Washed in water.
14. Dehydrated (80%, 90%, Alcohol) cleared and mounted.

**RESULT:**

Glycogen, mucin, reticulin, Basement membranes, amyloid and other elements may show a positive reaction – rose to purplish red

Nuclei – Blue

Fungi - Red

## **ANNEXURE – IV**

### **RETICULIN STAIN**

Fixation - 10% Formalin, Alcohol, Buffered Formalin.

Technique - Paraffin Section cut at 6 microns

#### **SOLUTIONS PREPARATION:**

##### **1. AMMONICAL SILVER SOLUTION:**

Take 10 ml of 10% Silver nitrate and add 2.5 ml 10% aqueous solution of KOH. Mix and then add 28% ammonia drop by drop until precipitate is completely dissolved by shaking. Add an equal volume of distilled water.

##### **2. 0.5 % KMnO<sub>4</sub>**

(0.5 gm KMnO<sub>4</sub> + distilled water 100ml)

##### **3. 2 % POTASSIUM METABISULPHITE**

( 2gm potassium metabisulphite + distilled water 100ml)

##### **4. 2 % FERRIC AMMONIUM SULPHATE**

( 2gm ferric ammonium sulphate + distilled water 100ml)

##### **5. 20% FORMALIN**

(Formaldehyde 20 ml + distilled water 80ml)

## **6. 0.2 % GOLD CHLORIDE**

( gold chloride 1% 10 ml + distilled water 40 ml)

## **7. 2% SODIUM THIOSULPHATE**

( 2gm Sodium thiosulphate + distilled water 100ml)

### **PROCEDURE:**

1. The slide is deparaffinised in 15 ml of xylene.
2. Washed in Graded alcohol ab.90%,80% each 2 dips
3. Washed in water for 5 minutes
4. Oxidize in  $\text{KMnO}_4$  for 1 minute.
5. Wash in tap water for 2 minutes.
6. Differentiate in potassium metabisulphite for 1 minute.
7. Wash in tap water for 2 minutes.
8. Sensitize in ferric ammonium sulphate for 1 minute.
9. Wash in tap water for 2 minutes.
10. 2 changes of distilled water.
11. Impregnate with silver solution for 1 minute.
12. Rinse in distilled water for 20 seconds.
13. Reduce in formalin solution for 3 minutes.
14. Wash in tap water for 2 minutes.

15. Tone in gold chloride for 10 minutes.
16. Rinse in distilled water.
17. Reduce in potassium metabisulphite for 1 minute.
18. Fix in potassium thiosulphate for 1 minute.
19. Wash in tap water for 2 minutes.
20. Dehydrated (80%, 90%, Alcohol) cleared and mounted.

**RESULT:**

Reticulin fibers: Black

Background: colorless



## **ANNEXURE – V**

### **IMMUNOHISTOCHEMISTRY PROCEDURE**

1. Sections are cut at 4 $\mu$ m, taken in coated slides and incubated at 58° c for overnight.
2. Dewax the section in xylene for about 30 minutes.
3. Immerse in absolute alcohol for 2 minutes x 2 changes.
4. Wash in tap water for about 10 minutes.
5. Rinse in distilled water for about 5 minutes.
6. Antigen retrieval was done in microwave oven with appropriate buffer solution in appropriate temperature for about 20 to 25 minutes.
7. Cool it to room temperature.
8. Rinse in distilled water for about 5 minutes.
9. Wash in wash buffer ( TBS) - 5 minutes x 2 changes.
10. Apply peroxidase block for about 10 minutes.
11. Wash in wash buffer 5 minutes x 2 changes.
12. Apply power block – 10 minutes.
13. Don't wash, drain and apply primary antibody for about 1 hr in a moisture chamber.

14. Wash in wash buffer 5 minutes x 2 changes.
15. Apply Super enhancer – 30 minutes.
16. Wash in wash buffer – 5 minutes x 2 changes.
17. Apply S.S.Label poly HRP reagent for about 30 minutes.
18. Wash in wash buffer 5 minutes x 2 changes.
19. Apply chromogen that contains DAB and substrate buffer to 5 to 8 minutes.
20. Wash in wash buffer 5 minutes x 2 changes.
21. Wash in tap water – 5 minutes.
22. Counter stain with haematoxylin..30 seconds.
23. Wash in tap water.
24. Air dry, clean in xylene and mount with DPX mountant.

## **RESULTS:**

The development of brown color is interpreted as positive and scoring done using Quick score method.