Ultrasound guided fine needle aspiration cytology for palpable thyroid tumours

A dissertation submitted in partial fulfilment of the requirement of MCh. Endocrine Surgery (Branch – IX) examination of the Tamil Nadu Dr.MGR Medical University, Chennai,

to be held in August – 2015

Certificate

This is to certify that the dissertation entitled "Ultrasound guided fine needle aspiration cytology for palpable thyroid tumours " is a bonafide work done by Dr. N. Siddhartha Chakravarthy, post graduate Resident in Department of Endocrine Surgery 2012-2015 at the Christian Medical College, Vellore, towards partial fulfilment for the MCh. Endocrine Surgery final examination to be held in August 2015.

Signature

Guide	**Head of the Department**	**Principal**
Dr Deepak Abraham	Dr. MJ. Paul	Dr. Alfred Job Daniel
Professor	Professor and Head	Professor
Dept. of Endocrine Surgery	Dept. of Endocrine Surgery	Dept. of Orthopaedics
Christian Medical College	Christian Medical College	Christian Medical
College, Vellore.	Vellore.	Vellore.

Declaration

I hereby declare that this dissertation titled **"**Ultrasound guided fine needle aspiration cytology for palpable thyroid tumours**"** was carried out by me under the direct supervision and guidance of Dr. Deepak Abraham, Professor of Endocrine Surgery, Christian Medical College, Vellore.

This dissertation is submitted to the Dr. MGR Medical University, Tamil Nadu in partial fulfilment of the requirements for the degree of MCh in Endocrine Surgery.

I also declare that this dissertation has not been submitted by me to any other university, or for the award of any other degree/ diploma.

Vellore

Dr. N. Siddhartha Chakravarthy

Christian Medical College, Vellore

Date:

Acknowledgement

- This dissertation would be incomplete without expressing my gratitude to those who were involved in its conception and completion.
- I am grateful to the patients who consented to be a part of my thesis.
- I was very privileged to have Dr. Deepak Abraham as my guide. I thank him for teaching me the process of doing a thesis. I thank him for his guidance and support. Without his persistence, gentle reminders and deadlines set for me I would not have completed this on time.
- I would like to specially thank Dr. MJ Paul for his expert opinions and suggestions.
- I thank Dr.AnuradhaChandramohan and Dr.PavithraMannam, Department of Radiology for doing the ultra sound guided fine needle aspiration cytology of thyroid tumours.
- I thank Dr. Anne Jennifer, Associate Professor of Pathology, CMC Vellore for the help extended in appropriate reporting of the FNACs.
- I thank my co-guides, Dr.Shyamkumar NK, Department of Radiology, Dr.Nihal Thomas and Dr.DukhbandhuNaik, Department of Endocrinology and Metabolism for their continuous support and guidance.
- I thank the cyto-technicians from the Department of Pathology for interpreting the onsite adequacy of fine needle aspiration cytology.
- I thank statisticians Dr.Jeyaseelan and Ms. M. Gowri for the study design and analyzing the data.
- I am also grateful for the support and valuable inputs from Dr. PoojaRamakant Dr. Anish Jacob Cherian.

- I thank my colleagues and juniors in the department for their help and support.
- I thank Mr.Santhanam and Mr.Balasubramanian from our office for all their help.
- Finally I thank my wife and family for their help, advice, guidance and support.
- Above all I thank God for His grace and guidance.

Institutional Review Board (IRB) acceptance letter

OFFICE OF RESEARCH
INSTITUTIONAL REVIEW BOARD (IRB)
CHRISTIAN MEDICAL COLLEGE, VELLORE, INDIA.

Dr. B.J. Prashantham, M.A., M.A., Dr. Min (Clinical)
Director, Christian Counseling Center,
Chairperson, Ethics Committee.

Dr. Alfred Job Daniel, D Ortho, MS Ortho, DNB Ortho
Chairperson, Research Committee & Principal

Dr. Nihal Thomas,
MD., MNAMS., DNB (Endo), FRACP (Endo), FRCP (Glas) (EDIN)
Deputy Chairperson
Secretary, Ethics Committee, IRB
Additional Vice Principal (Research)

We approve the project to be conducted as presented.

The Institutional Ethics Committee expects to be informed about the progress of the project, any **adverse events** occurring in the course of the project, any **amendments in the protocol and the patient information / informed consent**. On completion of the study you are expected to submit a copy of the **final report**. Respective forms can be downloaded from the following link: http://172.16.11.136/Research/IRB_Polices.html in the CMC Intranet and in the CMC website link address: http://www.cmch-vellore.edu/static/research/Index.html.

Fluid Grant Allocation:

A sum of 5,000 INR (Rupees Five Thousand only) will be granted for 1 year.

Yours sincerely

Dr. B. Antonisamy
Secretary (Research Committee)
Institutional Review Board

NOT TO BE MINISTERED UNTO BUT TO MINISTER
CHRISTIAN MEDICAL COLLEGE VELLORE INDIA
SECRETARY
Institutional Review Board
(Research Committee)
Christian Medical College,
Vellore - 632 002. Tamil Nadu. India

CC: Dr. Deepak Abraham, Endocrine Surgery, CMC

IRB Min. No. 8561 [OBSERVE] dated 12.11.2013 5 of 5

Ethics Committee Blue, Office of Research, 1st Floor, Carman Block, Christian Medical College, Vellore, Tamil Nadu 632 002.
Tel : 0416 - 2284294, 2284202 Fax : 0416 - 2262788, 2284481 E-mail : research@cmcvellore.ac.in

IRB

OFFICE OF RESEARCH
INSTITUTIONAL REVIEW BOARD (IRB)
CHRISTIAN MEDICAL COLLEGE, VELLORE, INDIA.

Dr. B.J. Prashantham, M.A., M.A., Dr. Min (Clinical)
Director, Christian Counseling Center,
Chairperson, Ethics Committee.

Dr. Alfred Job Daniel, D Ortho, MS Ortho, DNB Ortho
Chairperson, Research Committee & Principal

Dr. Nihal Thomas,
MD., MNAMS., DNB (Endo), FRACP (Endo), FRCP (Glas) (EDIN)
Deputy Chairperson
Secretary, Ethics Committee, IRB
Additional Vice Principal (Research)

December 10, 2013

Dr. Siddhartha Chakravarthy. N
PG Registrar
Department of Endocrine Surgery
Christian Medical College
Vellore 632 002

Sub: **Fluid Research grant project:**
Ultrasound guided fine needle aspirationcytology for thyroid tumors in the outpatient department.
Dr. Siddhartha Chakravarthy. N, Endocrine Surgery, Dr. Deepak Abraham, Endocrine Surgery, Dr. Paul MJ, Endocrine Surgery, Dr. Shyamkumar N.K, Radiology, Dr. Anucadha Chandramohan, Radiology, Dr. Pavithra Mannam, Radiology, Prof. Nihal Thomas, Endocrinology, Dr. Dukhabandhu Naik, Endocrinology, Diabetes & Metabolism, Dr. Anne Jennifer, Pathology.

Ref: IRB Min. No. 8561 [OBSERVE] dated 12.11.2013

CHRISTIAN MEDICAL COLLEGE
VELLORE
INDIA

Dear Dr. Siddhartha Chakravarthy. N,

I enclose the following documents:-

1. Institutional Review Board approval 2. Agreement

Could you please sign the agreement and send it to Dr. Nihal Thomas, Addl. Vice Principal (Research), so that the grant money can be released.

With best wishes,

Dr. B. Antonisamy
Secretary (Research Committee)
Institutional Review Board

SECRETARY,
Institutional Review Board
(Research Committee)
Christian Medical College,
Vellore - 632 002. Tamil Nadu. India

CC: Dr. Deepak Abraham, Endocrine Surgery, CMC

Ethics Committee Blue, Office of Research, 1st Floor, Carman Block, Christian Medical College, Vellore, Tamil Nadu 632 002.
Tel : 0416 - 2284294, 2284202 Fax : 0416 - 2262788, 2284481 E-mail : research@cmcvellore.ac.in

Plagiarism

turnitin

Digital Receipt

This receipt acknowledges that Turnitin received your paper. Below you will find the receipt information regarding your submission.

The first page of your submissions is displayed below.

Submission author:	181219021.(mch) Final Year Siddha...
Assignment title:	TNMGRMU EXAMINATIONS
Submission title:	Ultrasound guided fine needle asp...
File name:	Plagiarism_pdf.pdf
File size:	532.16K
Page count:	76
Word count:	9,222
Character count:	49,664
Submission date:	24-Mar-2015 08:48PM
Submission ID:	520066720

Copyright 2015 Turnitin. All rights reserved.

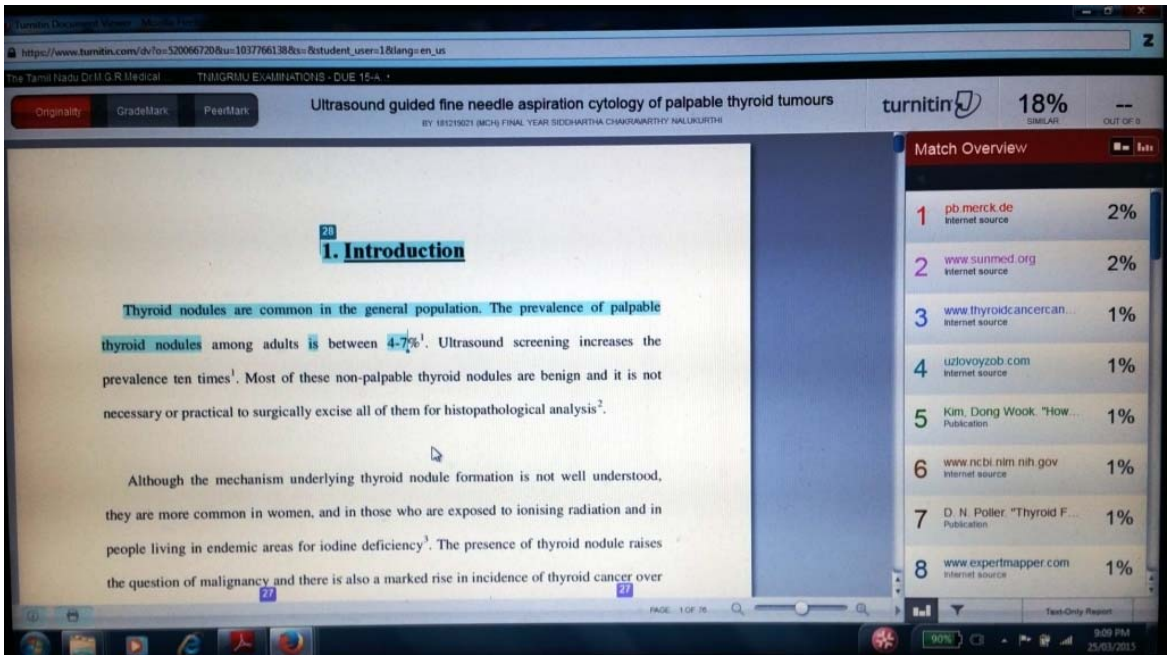

Ultrasound guided fine needle aspiration cytology of palpable thyroid tumours

BY 181219021 (MCH) FINAL YEAR SIDDHARTHA CHAKRAVARTHY NALUKURTHI

turnitin 18% SIMILAR -- OUT OF 0

Match Overview

1 pb.merck.de Internet source 2%

2 www.sunmed.org Internet source 2%

3 www.thyroidcancercan... Internet source 1%

4 uzlovoyzob.com Internet source 1%

5 Kim, Dong Wook. "How... Publication 1%

6 www.ncbi.nlm.nih.gov Internet source 1%

7 D. N. Poller. "Thyroid F... Publication 1%

8 www.expertmapper.com Internet source 1%

1. Introduction

Thyroid nodules are common in the general population. The prevalence of palpable thyroid nodules among adults is between 4-7%[1]. Ultrasound screening increases the prevalence ten times[1]. Most of these non-palpable thyroid nodules are benign and it is not necessary or practical to surgically excise all of them for histopathological analysis[2].

Although the mechanism underlying thyroid nodule formation is not well understood, they are more common in women, and in those who are exposed to ionising radiation and in people living in endemic areas for iodine deficiency[3]. The presence of thyroid nodule raises the question of malignancy and there is also a marked rise in incidence of thyroid cancer over

Index

1. Introduction

Thyroid nodules are common in the general population. The prevalence of palpable thyroid nodules among adults is between 4-7%[1]. Ultrasound screening increases the prevalence ten times[1]. Most of these non-palpable thyroid nodules are benign and it is not necessary or practical to surgically excise all of them for histopathological analysis[2].

Although the mechanism underlying thyroid nodule formation is not well understood, they are more common in women, in those who are exposed to ionising radiation and in people living in areas endemic for iodine deficiency[3]. The presence of any thyroid nodule raises the question of malignancy especially because of a marked rise in incidence of thyroid cancer over the past 10-20 years[4–6]. In the assessment of thyroid nodules, clinical evaluation plays a critical role in assessing the risk of malignancy, however clinical parameters are subjective and depend on the clinicians experience[7].

Fine needle aspiration cytology (FNAC) was first described in 1948[8] but it emerged as an important diagnostic test only after the pioneering work done by Lowhagen et al of Karolinska Institute, Sweden in the late seventies[9]. FNAC has revolutionised the management of thyroid nodules, providing an extremely safe, simple, quick and cost effective method for detecting malignancy[10]. Since only around 5-10% of thyroid nodules are malignant, excision of all nodules without a preoperative diagnostic assessment is not cost effective or practical and largely unnecessary.

Although FNAC is very simple, it requires a dedicated, multidisciplinary team to get the best results. Moreover it gives inadequate information in approximately 25% of cases

because of insufficient cellular yield and it is also difficult to differentiate between an adenoma and carcinoma on FNAC as capsular and vascular invasion cannot be assessed. FNAC is commonly done by palpatory method but this approach has various limitations including, difficulty in sampling nodules that are small, indistinct, predominately cystic, posterior in location and difficulty in selecting the suspicious nodule within a multinodular goitre.

Ultrasound helps to identify which nodule is to be biopsied, and in mixed lesions, solid areas can be sampled with ultrasound guidance. Ultrasound guided fine needle aspiration cytology **(US-FNAC**) helps in decreasing the inadequacy rate and also increases the specificity of the test.

2. Background

FNAC was introduced in this institution in the late 1980's. Initially it was done by the pathologist, but later due to logistical constraints the procedure was shifted to the surgical outpatient department after a few years and is currently being done by the General surgery residents. A study done in this institution on thyroid FNAC's in 2001, showed the inadequacy rate to be 41.2%, and recent two studies done in 2014 showed it to be 30-41%, which is much higher than the accepted international norms.

In a study done in CMC in 2011, the sensitivity and specificity of FNAC was 73 and 62% respectively. Such low sensitivity and specificity makes it difficult for the clinician to make a sound judgment, resulting in patients undergoing unnecessary thyroid operations.

Hence we propose to study the use of ultrasound to guide fine needle aspiration cytology (US-FNAC) of palpable thyroid nodules in the Outpatient Department, involving a dedicated team from multiple specialities to improve the adequacy and accuracy of FNAC. It will be done in the presence of the surgeon, radiologist and cytotechnician, and all slides would be reported by a dedicated cytopathologist.

3. Aim and Objectives

Aim: To study the effect of ultrasound guidance on the performance of Fine Needle Aspiration Cytology.

Objectives:

a) To determine the adequacy of ultrasound guided fine needle aspiration cytology (US-FNAC) samples from palpable thyroid nodules.

b) To assess the accuracy of fine needle aspiration cytology with histopathology as the gold standard for those who had subsequent thyroid surgery.

4. Literature Review

Clinical evaluation of thyroid nodules

The examination of a thyroid nodule involves assessment in the following parameters

a. **Clinical examination**
b. **Functional assessment:** TSH, Nuclear scan (if the TSH is abnormal)
c. **Radiological examination:**
    i. Ultrasound of neck
d. **Pathological examination**
    i. FNAC/ Core biopsy

History and clinical examination

Most thyroid nodules are asymptomatic, detected by the patient or during clinical examination by the physician. In symptomatic patients, history of compressive symptoms like choking, hoarseness of voice, dyspnoea, cough, dysphagia and symptoms of hyperthyroidism or hypothyroidism should be elicited. Recent onset of rapid growth, dysphagia and hoarseness are associated with thyroid cancer. Family history of thyroid disease or cancer and previous head and neck irradiation increase the risk of thyroid cancer. Syndromes which are associated with thyroid cancer are Multiple Endocrine Neoplasia (MEN 1) and MEN 2[11], Familial non-MEN medullary carcinomas, Cowden's syndrome, Gardner's syndrome and Carney's complex,

Clinical features which predict malignancy in a thyroid nodule are[12]

High degree of suspicion

- Family history of multiple endocrine neoplasia or thyroid cancer
- Recent increase in the size of the thyroid
- A hard and fixed thyroid nodule
- Recent change in voice
- Paralysis of vocal cords
- Regional lymphadenopathy
- Distant metastases

Moderate suspicion

- Age of either <20 years or >70 years
- Sex: Male
- Past history of radiation to the neck
- >4 cm nodule
- Compressive symptoms like dysphagia, cough and dyspnoea

Fine needle aspiration cytology (FNAC)

Historical aspects

Although FNAC was first described in 1948[8], it emerged as an important diagnostic test only after the pioneering work done by Lowhagen et al of Karolinska Institute, Sweden in the late seventies[9]. Routine use of FNAC has changed the management of thyroid nodules by sparing unnecessary operation for benign lesions and reducing cost of care.

Most thyroid cancers are diagnosed by FNAC, and it is the investigation of choice for evaluating a thyroid nodule. The American Thyroid Association recommends FNAC for all palpable thyroid nodules and nodules with suspicious features[13]. Management of thyroid nodules depends to a large extent on the FNAC reports[14]. Fine needle aspiration cytology FNAC should be performed in any firm, palpable, solitary nodule or nodule associated with worrisome clinical features (rapid growth, invasion to adjacent tissues, new hoarseness, or palpable lymphadenopathy)[15].

In the early days of its development, there was no consensus on reporting thyroid FNACs. Thyroid FNAC results were divided into two to five categories[16–19]. But the three major international nomenclatures followed in the world for reporting thyroid cytopathology, include, the British Thyroid Association and Royal College of Pathologists (Thy), the Italian Consensus (TIR) and the Bethesda System for Reporting Thyroid Cytopathology

The British Thyroid Association and Royal College of Physicians proposed a five tier terminology in 2002[20]. The five tier system consists of

a. Thy1 (non-diagnostic/ inadequate)
b. Thy2 (benign/non-neoplastic): Features consistent with a colloid nodule, nodular goiter, cystic goiter or thyroiditis.
c. Thy3 (follicular lesions)
d. Thy4 (suspicious of malignancy)
e. Thy5 (diagnostic of malignancy).

The Italian system of classification Italian Society of Pathology and Cytopathology–Italian Section of the Italian Academy of Pathology has the following divisions

a. Tir 1 (Non-diagnostic)
b. Tir 2 (Negative for malignant cells)
c. Tir 3 {Indeterminate (follicular proliferation)}
d. Tir 4 (Suspicious for malignancy)
e. Tir 5 (Malignancy)

After the advent of the Bethesda guidelines, the British and Italian groups divided the Thy 3 and Tir 3 into 3a and 3b, which is similar to 'atypia of undetermined significance' and 'follicular neoplasm' respectively for making it comparable to the internationally followed Bethesda system. The Bethesda System for Reporting Thyroid Cytopathology[21] was first described in 2007 in a conference held at the National Institutes of Health in Bethesda, Maryland. This system divided FNAC reports into 6 categories (table: 1).

The meeting was organised by Andrea Abati, MD, and took place on 22nd and 23rd October 2007, in Bethesda. Preparations for the conference began one-and-a-half years earlier with the designation of a steering committee, coordination with co-sponsoring

organisations, and the establishment of a dedicated, permanent web site. Literature reviews were performed dating back to 1995, using PubMed as the search engine. The conference was attended by 154 professionals from various departments like Pathology, Endocrinology, Surgery, and Radiology. The conference helped in giving an in-depth opportunity to present their conclusions and debate controversial areas[21].

The Bethesda system for reporting thyroid cytopathology (TBSRTC) was created in January 2010.The Bethesda system for reporting thyroid cytopathology have made the reports succinct, unambiguous and clinically helpful[21]. This uniform reporting system has helped us predicting the prognosis of thyroid nodules by estimating the malignant potential of individual category.

Table 1**The Bethesda System for Reporting Thyroid Cytopathology: Implied Risk of Malignancy and Recommended Clinical Management** [21]

Diagnostic category	**Category Risk of Malignancy (%)**	**Usual Management**
Non-diagnostic or Unsatisfactory	1-4	Repeat FNA with ultrasound guidance
Benign	0-3	Clinical follow-up
Atypia of Undetermined Significance or Follicular Lesion of undetermined significance	~5-15	Repeat FNA
Follicular Neoplasm or Suspicious for a Follicular Neoplasm	15-30	Surgical lobectomy
Suspicious for Malignancy	60-75	Near-total thyroidectomy or surgical lobectomy
Malignant	97-99	Near-total thyroidectomy

Non-diagnostic or Unsatisfactory

The specimens are called non-diagnostic if there is lots of obscuring blood, overly thick smears, air-drying of alcohol-fixed smears, or an inadequate number of follicular cells. For a satisfactory FNAC (and benign), a minimum of 6 groups of benign follicular cells are required, with each group composed of at least 10 cells[22].

Exceptions to this are

- If a sample has abundant colloid it is considered adequate (and benign).

- Sparsely cellular specimen (without 6 groups of cells) but with abundant colloid and macrophages is benign.

Non-diagnostic results occur in 2% to 20% of cases but should be limited to less than 10% of thyroid FNACs[14]. Few FNACs have cystic fluid alone and these should be correlated with the ultrasound findings. If the USG looks suspicious then a repeat FNAC under USG guidance is advised to rule out cystic papillary carcinoma of thyroid. In a study done by Grant et al, who analysed the cystic nodules separately the risk of malignancy was only 4%[22].

A repeat aspiration under ultrasound guidance is advised for non-diagnostic thyroid nodules and if it is persistently non- diagnostic,a diagnostic thyroidectomy is performed, as 10% of them can have an underlying malignancy[23].

Benign

The benign FNAC enables the surgeon to make a diagnosis of a benign lesion as correctly as possible thus avoiding the need of an unwanted surgery. A "benign" diagnosis is seen in about 60% or 70% of FNACs from the thyroid gland. A benign interpretation carries a low risk of being falsely negative (0% to 3%), but during follow up if the nodule shows rapid growth or any "suspicious" change on ultrasonography, then a repeat FNA is considered.

Atypia of Undetermined Significance (AUS) / Follicular Lesion of Undetermined Significance (FLUS)

Some aspirates may not be classified with ease into the categories of benign, suspicious or malignant. The common scenarios are outlined here

- Predominance of microfollicles or Hurthle cells in a sparsely cellular aspirate with scant colloid.
- Assessment of atypical cells is hindered by clotting or air drying artefacts.
- Predominance of Hurthle cells in a clinical setting of benign Hurthle cell nodule or benign multinodular goitre.
- Predominantly benign appearing nodule with few cyst lining cells which may appear atypical with nuclear groove or intranuclear cytoplasmic inclusions[21].

An AUS result is obtained in 3% to 6% of thyroid FNACs[23].The risk for malignancy for a nodule that has been labelled as AUS is very tough to establish, as only a small proportion of patients in this group have had surgery. The risk of malignancy described is low and probably between 5% to 15%, but a recent study shows a malignancy rate of 26.6-37.8%[24].

Follicular Neoplasm / Suspicious for a Follicular Neoplasm

These smears typically have high cellularity, and colloid is scant or absent. The characteristic of this category is an altered cytoarchitecture i.e. the follicular cells are arranged predominantly in microfollicular or trabecular arrangements. The majority of nodules reported ‘follicular neoplasms’ or ‘suspicious of follicular neoplasm’ cases turn out

as follicular adenomas or as adenomatoid nodules of a multi nodular goitre. Of those that are proven to be malignant, many are follicular carcinomas. However a significant proportion of these are follicular variants of papillary carcinoma **(FVPTC)**[25]. About 15% to 30% of cases turn out to be malignant.

Suspicious for Malignancy

If the FNAC smears have only 1 or 2 characteristics of papillary carcinoma (PTC) or they are only focal, or if the sample is sparsely cellular, but with definite atypical features, a diagnosis of malignancy cannot be made with certainty. These cases are classified as suspicious for malignancy. Many of these (60%-75%) prove to be papillary carcinomas and the rest are usually follicular adenomas[26].

Malignant

This category of diagnosis is usually used when the cytological and architectural features are diagnostic of malignancy. About 3% to 7% of FNACs have these confirmative features of cancer and these are mostly papillary cancers; the others being medullary thyroid carcinomas (MTC), poorly differentiated thyroid carcinomas (PDTC), anaplastic carcinomas, non-Hodgkin's lymphomas, and metastatic tumours.

Ultrasound guided fine needle aspiration cytology (US-FNAC)

FNAC is commonly done by the palpatory method. This approach has various limitations, including difficulty in sampling nodules that are small, indistinct, predominantly cystic, and posterior in location, or deep. The accuracy and adequacy of FNAC also depends on the experience of the person using this technique. All of these factors are causes for a non-diagnostic FNAC. Several ways to minimise the inadequacy rate have been described by American Association of Clinical Endocrinologists, Associazione Medici Endocrinologi, and European Thyroid Association Medical Guidelines for Clinical Practice for the Diagnosis and Management of Thyroid Nodules.

Ways to Minimise False-Negative Results[27]

- Use ultrasound-guided fine-needle aspiration (US-FNAC).
- Perform multiple punctures of the nodule so that several areas are sampled.
- Consider repeated US-FNAC for follow-up of benign nodules.
- For multiple nodules, prioritise the nodule to biopsy according to ultrasonographic findings.
- For cystic lesions, sample solid areas with US-FNAC and submit cyst fluid for examination.
- Obtain at least 6 properly prepared thin cell smears.
- Use immediate wet fixation for Papanicolaou staining technique.
- Review slides with an experienced cytopathologist.

Considering these issues, US-FNAC has emerged as a reasonable alternative to a palpatory FNAC (P-FNAC), as it reduces the sample inadequacy rate and the need for repeat biopsies.

In a study published by Rachel Redman, Hillary Zalaznick, Ernest L. Mazzaferri et al (2006) who retrospectively analysed 693 thyroid FNAC specimens obtained with and without ultrasound guidance and with or without onsite cytology assessment concluded that US-guided FNAC, with onsite evaluation of cytology specimens substantially increases the adequacy of cytology specimens and decreases the number of required needle passes, which ultimately reduces patient discomfort and diagnostic errors, thus raising the question as to whether this should eventually become the standard of care[28].

In a study published by Izquierdo R et al (2006), the authors compared the efficacy of Ultrasound guided fine-needle aspiration cytology of thyroid nodules with that of palpation guided fine needle aspiration. The accuracy rate of P-FNAC in this study was 60.9%, whereas that of US-FNAC was 80%. They concluded that US-FNAC improved the cytologic diagnostic accuracy, sensitivity, and positive predictive value and reduced the false-negative rate in comparison with P-FNAC[29].

.

In a review article by Baskin HJ, it is mentioned that real-time ultrasound guidance has technically refined the FNAC technique by decreasing the number of inadequate biopsy specimens and increasing both the specificity and the sensitivity of this procedure. In addition to being cost-effective, well tolerated, and expedient, US-FNAC has emerged as the most accurate method for evaluation of thyroid nodules[30].

Several other studies in which the surgeon has performed US-FNAC also stressed the importance of guided FNAC and the need for onsite evaluation by the cytopathologist[31–33].

Sampling techniques in ultrasound-guided fine-needle aspiration[22]

Major sampling techniques in US-FNAC are

1. **Capillary sampling**
2. **Aspiration sampling**
3. **Mixed sampling** (initial capillary sampling and progressive aspiration sampling based on the degree of the aspirate)[21]

Technique of ultrasound guided-fine needle aspiration cytology

FNAC is preferably carried out in an outpatient setting. The patient is explained about the procedure and is then invited to assume a recumbent position with a pillow under the neck muscles.

Thyroid nodules are identified by palpation and the ultrasound is done to identify the most suspicious nodule. The needle is then inserted into the nodule under the guidance of the ultrasound and moved back and forth while maintaining a slight aspiration. The aspiration is released when the aspirated material appears in the needle hub and just before withdrawing the needle, in order to avoid contaminating the sample with material coming from the needle tract.

Some operators use a “no aspiration” technique. In this a 24-guage needle is used. After inserting the needle, it is moved back and forth, and at the same time it is rotated with the

operator's fingers. Needle is also angulated in all directions during this motion. This technique reduces the incidence of bloody aspirates[36].

23-25-gauge needle is generally used for US-FNAC of thyroid nodules. Comparative studies of FNA with and without aspiration have indicated that there is no significant statistical difference between these two techniques. Capillary technique is recommended for highly vascularised thyroid nodules to minimize the bloody aspirate. Hence, a combination of capillary and aspiration techniques should be used appropriately to get adequate samples.

Local anaesthesia can be used for sensitive patients and difficult nodules which might need multiple attempts. Approximately 0.5 ml of 1% lidocaine or lidocaine 2% with 1:100,000 epinephrine can be used.

Staining techniques

Papanicolau (PAP) and May-Grunwald-Giemsa (MGG) are the two most commonly used staining techniques. With Papanicolau method details of nuclear chromatin including the ground glass nuclei and the nuclear grooves characteristics of papillary cancer are better seen. Colloid is also better evidenced with this method. On the other hand, cytoplasmic details and lymphoid cells are better recognized with May-Grunwald-Giemsa staining[37].

The Diff-Quick staining for rapid assessment of sample adequacy is used in many centres. The aspiration can be repeated if the smears are judged poor or inadequate, thus reducing to a minimum the proportion of inadequate sampling.

Onsite adequacy

It is a method of assessing the adequacy of FNAC specimen during aspiration. Some centres perform routine onsite assessment of specimen adequacy at the time of aspiration[28]. Immediate re-aspiration can be done if the specimen is inadequate. Most studies show that onsite adequacy assessment reduces the number of inadequate FNAC samples[38]. This service is provided either by a cytopathologist or a cytotechnician. A few studies show onsite adequacy assessment by cytotechnologists and cytopathologists as broadly similar. In one study, 93% of FNAC aspirates were judged correctly as adequate by a cytotechnologist as compared with 97% by a cytopathologist[28]. In a recent meta-analysis assessing whether the rapid onsite assessment by a cytopathologists or a cytotechnician will improve the adequacy of FNAC, concluded that sites with lower initial adequacy rates benefit the most from the implementation of onsite assessment[39].

Complications of US-FNAC

FNAC has no major complications and the minor complications encountered can be

1. Subcutaneous hematoma
2. Limited intranodular bleeding
3. Local pain occasionally
4. Rarely, aspiration of a cystic lesion may favour acute inflammation
5. It can cause transient paralysis of the vocal cords in very rare cases[40].

Molecular markers in FNAC of thyroid

Testing FNA samples "for a panel of mutations which includes BRAF, RAS, RET/PTC, and PAX8/ PPARγ" can help in improving the diagnostic accuracy of FNAC. These mutations are associated with malignancy in thyroid nodules and might help to refine clinical management for a significant proportion of patients with indeterminate cytology. The "Revised Management Guidelines for Patients with Thyroid Nodules and Differentiated Thyroid Cancer, recently" published by ATA recommends "the use of molecular markers, as BRAF, RAS, RET/PTC, and PAX8/PPARγ, for patients with indeterminate FNAC to help guide management". The knowledge of these molecular pathways has permitted the development of new targeted therapies for aggressive thyroid cancer[41].

Ultrasonography

Ultrasound is the investigation of choice for evaluation of thyroid nodule. Was first used in 1970 to image the thyroid gland, since than it is universally accepted for palpable thyroid abnormlities[42]. This imaging modality is portable, economical and easy to learn. The physician should not be intimidated as it is user- friendly and will eventually be a part of clinical examination. It is a sensitive tool and can detect non-palpable nodules in 13–50% of the general population[2].It is useful to differentiate between thyroid nodules and cervical masses from other origin, like thyroglossal cyst, cervical lymphadenopathy, and cystic hygroma.

Indications for ultrasound of thyroid[43]

Thyroid ultrasound is indicated in

- Patients with a palpable thyroid nodule
- Screening high risk patients for thyroid cancer: History of MEN II or irradiated neck in childhood
- Suspicious cervical lymphadenopathy
- Follow up of patients with thyroid cancer
- Guidance to FNAC for non-palpable nodules.

Thyroid ultrasound is not recommended for patients with normal thyroid gland and as a screening in general population.

Technique

Ultrasound is performed with the neck in hyperextension and both lobes of thyroid gland are imaged in longitudinal and transverse planes using a high frequency linear transducer (7-15 MHz).Colour and/or power Doppler ultrasound are useful to evaluate the vascularity of the thyroid gland and focal masses.

Normal anatomy

The normal thyroid is comprised of right and left lobes joined by the isthmus and located anterior to the trachea. It has a medium to high level echogenicity. The relationships with the surrounding structures are as follows:

- Anterior: strap muscles
- Posterior: trachea and longus colli muscles and oesophagus
- Lateral: common carotid artery and jugular vein.

Ultrasound characteristics of a suspicious nodule

Certain signs help in differentiation benign from malignant thyroid nodules on ultrasound. American Association of Clinical Endocrinologists (AACE)[44], the Italian Association of Medical Endocrinologists (AME) and Kim et al[45] proposed several criteria for suspicious nodules on ultrasound. The criteria proposed by Kim et al have the highest sensitivity and the criteria proposed by AACE have the highest specificity (table2).

Table 2Ultrasound characteristics[46]

Kim et al. criteria	AACE criteria
Microcalcification	Microcalcification
Irregular or microlobulated margins	Irregular margins
Marked hypoechogenecity	Intralesional vascular spots
Thickness greater than the length	Thickness greater than the length

Echogenicity

Echogenicity of thyroid nodules is divided into hyperechogenicity, isoechogenicity, hypoechogenicity, or marked hypoechogenicity.

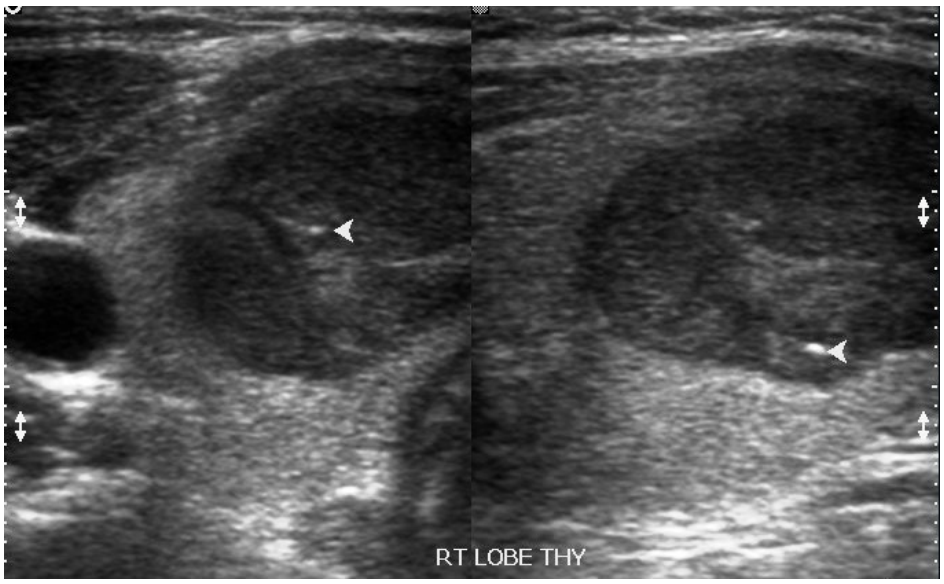

Figure 1 Well defined hypoechoic nodule with microcalcification in the right lobe of thyroid

Echogenicity of the solid nodule is compared to the normal thyroid and to the surrounding strap muscles which are hypoechoic. The majority of benign thyroid nodules will be iso-or hyper -echoic to normal thyroid. A markedly hypoechoic solid lesion should always be viewed with suspicion and has a high incidence of malignancy.

Calcification

Calcification is a hyperechoic spot with or without posterior shadowing. There are two types of calcifications in a thyroid nodule.

- Egg shell calcification: It is seen in benign nodules
- Punctuate microcalcification (1mm): these are calcifications which are $\leq$1mm in diameter and are commonly seen in malignant thyroid nodules. These calcifications correspond to the psammoma bodies in the histopathological examination.

Halo sign

It is a dark rim around the thyroid nodule. This sign is seen mostly in a benign thyroid nodule but can also be seen in a malignant nodule. Halo sign is caused by the capsule of the nodule or due to the compression of the adjacent normal thyroid parenchyma by the tumour. A thick, irregular halo is suspicious and seen in malignant thyroid nodules[47].

"Ring down or comet tail" sign of colloid

Colloid in a benign cystic nodule causes a "ring down" artefact or sign. It was first described by Ahuja et al[48]. It supposed to be due to a reverberation artefact and is seen in benign nodules (Figure 2).

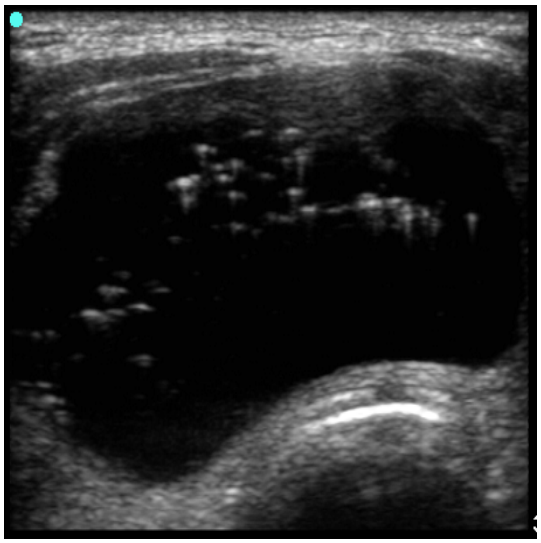

Figure 2: Comet tail artefact

Figure 3: Markedly hypoechoic lesion, with microcalcification and ill defined margins in the right lobe of thyroid

Composition

Thyroid nodules can be divided into solid, cystic and mixed lesions. Pure cystic nodules are extremely rare and are benign.

Margins

Margins are divided into well defined, microlobulated and ill defined. Some malignant nodules invade into the adjacent tissues and have irregular margins. Benign nodules have well defined borders with a thin halo around them (figure 3).

Multinodular goitre

Clinical examination cannot really distinguish between solitary and multinodular goitre. A mulitnodular goitre has the same risk of malignancy as compared to solitary nodule of thyroid[49].

Shape of the nodule

Taller-than-wide nodules have a high incidence of malignancy[50]. Malignant nodules grow across the normal tissue planes unlike benign nodules which grow parallel and are oval in shape[51].

Vascularity

Colour Doppler is used to assess the vascularity of the thyroid nodule. Intranodular vascularity is associated with malignancy, whereas peripheral vascularity and avascular lesions are more likely to be benign[52]. Some studies failed to show the association of vascularity with malignancy[53]. But the vascularity within a solid component of a cystic swelling is significant and the FNAC should be directed to this lesion.

Lymph nodes

Ultrasound of the cervical region should include assessment of the suspicious lymph nodes. Thyroid cancer commonly involves levels 6, 3, 4 and 2 of the neck. Metastatic lymph nodes appear as rounded, solid with absence of fatty hilum, with or without microcalcification and sometimes can be cystic (figure 4&5).

Figure 4 Solid and cystic lymph node

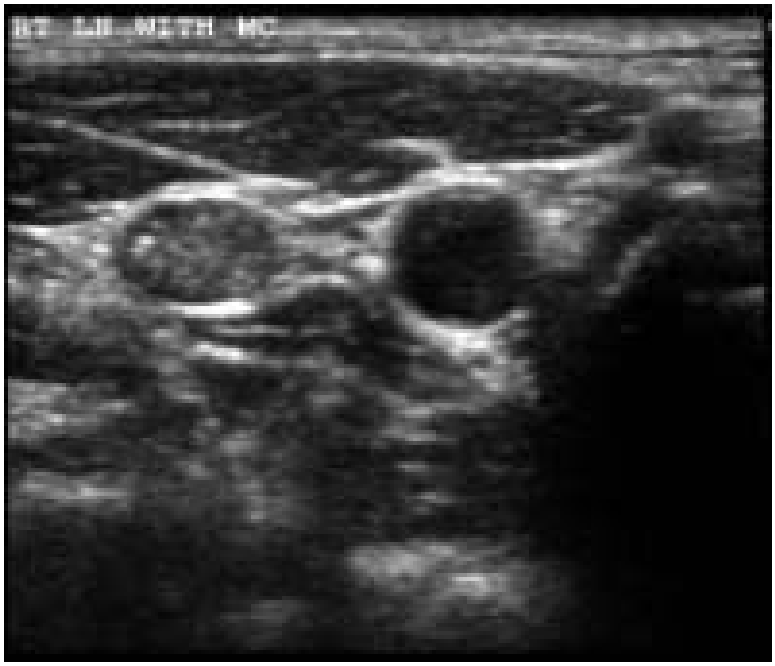

Figure 5 Metastatic cervical lymph node (solid, round with microcalcificaion)

TIRADS (Thyroid imaging reporting and data system)

It is based on the concepts of the Breast Imaging Reporting Data System (BIRADS). Thyroid imaging reporting an data system(TIRADS) was first reported by Horvath et al[54]. They described ten patterns of thyroid nodules and compared it to the malignancy rate in each pattern. Kwak et al in 2011, modified TIRADS and had five features which include solid lesion, hypoehoic, ill-defined margins, microcalcification and taller than wide lesions. They calculated the risk of cancers in each group i.e. 0% in TIRADS 1 and 2, 2%-2.8% in TIRADS 3, 3.6% to 12.7% in TIRADS 4A, 6.8% to 37.8% in TIRADS 4B, 21%-91.9% in TIRADS 4c and 88.7-97.9% in TIRADS 5 lesions.

Ultrasound elastography

It is used to measure the stiffness of the tissues or displacement in response to an applied force. A benign nodule deforms easily as it is softer, whereas a malignant nodule is harder and hence deforms less when compressed by ultrasound probe. Differences in tissue displacement are calculated and presented as colour maps, so-called elastogram. Each elasticity score is coded by different colours. The range of colours, from red to blue, corresponds to increasing stiffness of the tissue of interest. Red colour represents soft tissues, green those of intermediate stiffness and blue “hard” ones[55]. Ultrasound elastography is useful in characterizing an indeterminate nodule as malignant with its effectiveness almost comparable to FNAC[56] (figure 6).

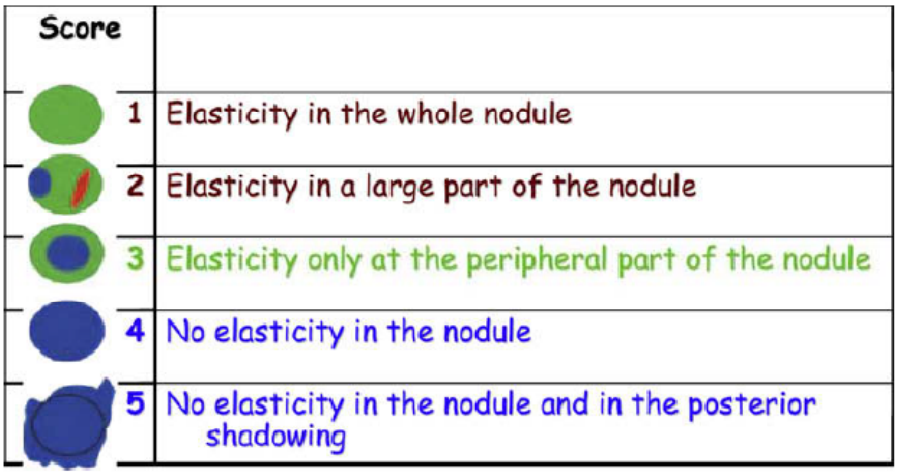

Figure 6Elasticity score[57]

Computed tomography (CT) and magnetic resonance imaging (MRI)

CT and MRI are not required for routine evaluation of a thyroid nodule. They are less sensitive than ultrasound in detecting and characterising thyroid nodules as benign or malignant. They are useful for assessing loco-regional extension of the tumour into the internal jugular vein, carotid artery, prevertebral fascia, trachea, larynx, oesophagus and to assess the retrosternal extension[58].

6. Materials and methods

All patients with palpable thyroid nodules, planned for palpatory fine needle aspiration**(P-FNAC)** during December 2013 to December 2014, underwent US-FNAC in the FNAC room of the outpatient department. The thyroid gland was screened by the portable ultrasound SonoSiteMicroMAXX 6-13 MHz (figure 7) and FNAC was done by the radiologist from the most suspicious nodule under the guidance of the surgeon. The cytotechnician assessed the onsite adequacy of FNAC sample. Cell block was prepared whenever possible. The smears were consistently reported by dedicated cytopathologists. For those who had subsequent surgery, the histopathology was correlated with FNAC to ascertain the accuracy.

\

Figure 7 Portable USG Sonosite machine (6-13MHz)

Detailed diagrammatic Algorithm of the study

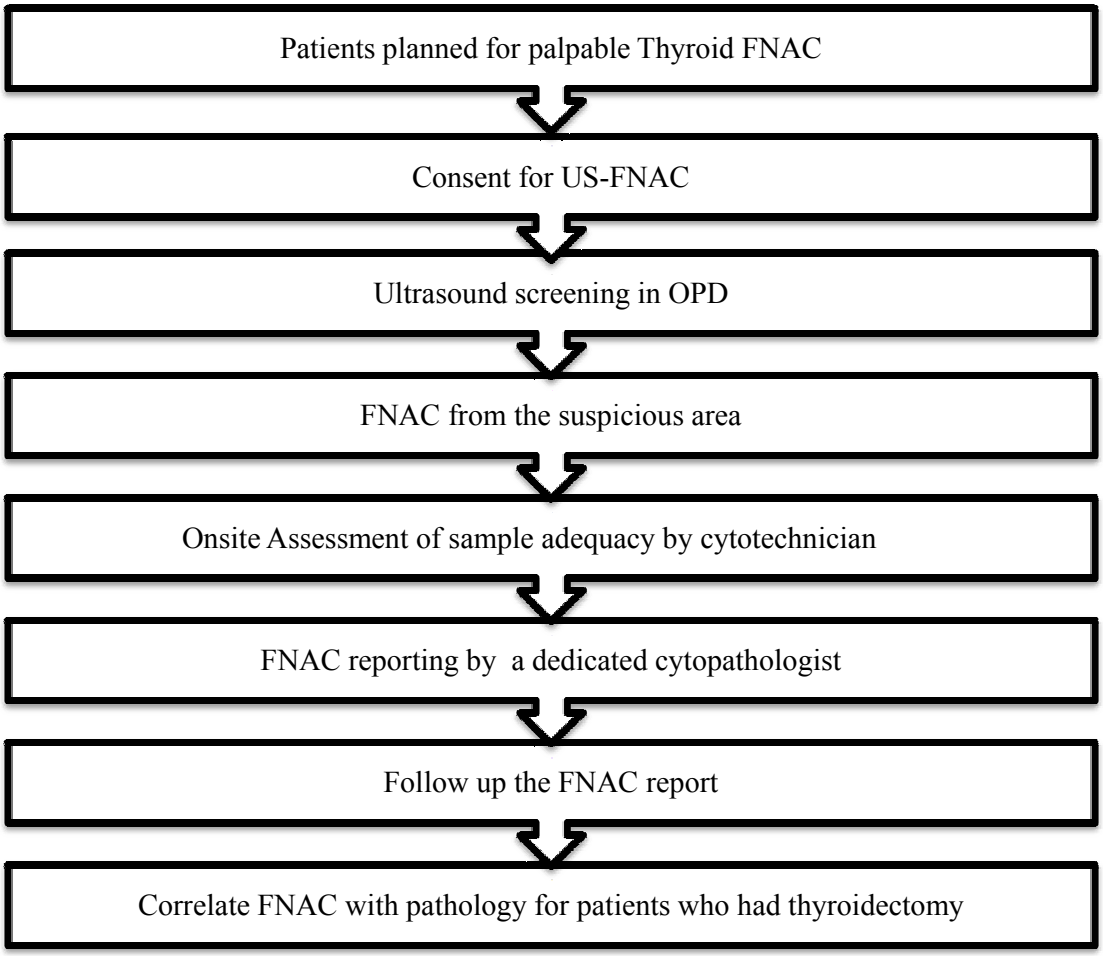

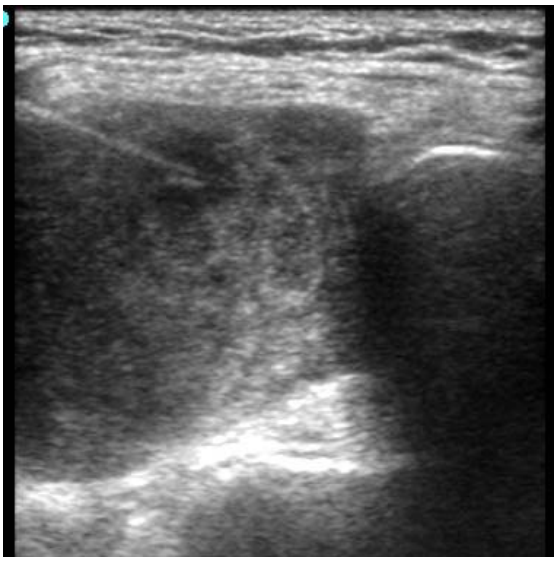

Figure 8 US-FNAC (needle targeting hypoechoic lesion)

Figure 9 Cytotechnician assessing onsite adequacy

US-FNAC Ultrasound guided fine needle aspiration cytology was done in the FNAC room in surgery Outpatient Department (OPD), 3rd floor, in the FNAC room. . It was done on Mondays and Thursdays between 11:00 to 11:45 AM from 1-12-2013 to 31-12-2014**.**

Sample size calculation

Based on our previous P-FNAC data our inadequacy rate of FNAC was 30% and the inadequacy of ultrasound guided FNAC for non-palpable thyroid nodules is 21%. Hence taking an intermediate value of 24% as the inadequacy of P-FNAC, the sample size is calculated. In order to estimate this with a precision of 5% and a 95% confidence interval the sample size needed is 290 subjects who need FNAC.

4pq/d2

4x24x76/5x5= 290

Statistical analysis

The percentage of adequate US-FNACs is calculated along with the percentage of individual categories of Bethesda system. For patients who had subsequent thyroidectomy, the US-FNAC report is correlated with the gold standard histopathology and the sensitivity, specificity and predictive values of the US-FNAC is calculated.

Inclusion criteria:

a. All adult patients (18 years and above) with thyroid nodules.

b. All clinically palpable thyroid nodules, which would have had a P-FNAC in the outpatient department.

Exclusion criteria:

a. Patients who choose not to participate in the study
b. Diffuse goitre
c. Thyroiditis with no discrete nodule.
d. Non-palpable thyroid nodule.

Proforma for collecting the data (Entire proforma with the coding is attached at the end as annexure 1)

US-FNAC DATA

1. Name
2. Hospital number
3. Age
4. Sex
5. Pre-operative voice change
6. Compressive symptoms
7. Hyper/hypothyroid symptoms
8. Retrosternal extension
9. Consistency
10. Mobility
11. Lymph nodal involvement
12. Previous neck surgery
13. Site of the FNAC
14. Onsite adequacy of FNAC

15. USG Findings:

A. Site:

B. Size of nodules

C. Number of nodules >1cm: _____

D. Composition:

E. Appearance:

F. Echogenicity:

G. Margins:

H. Halo sign:

I. Calcification:

J. Shape:

K. Lymph nodes:

L. USG size:

TIRADS Category	No. Of USG features
☐ 1 (Negative) – no thyroid nodule ----------	0
☐ 2 (Benign) – cystic lesion----------	0
☐ 3 (Probably Benign) – hyperechoic solid, complex cyst with no malignant features------	0
☐ 4a (Low Suspicion for Malignancy)----------	1
☐ 4b (Intermediate)----------	2
☐ 4c (Moderate suspicion for Malignancy)-----	3 or 4
☐ 5 (Highly Suggestive of Malignancy)---------	5

Features favouring malignancy: microcalcification, irregular or microlobulated margins, hypoechogenicity or markedly hypoechogenic and taller-than-wide shape.

In mixed lesion – solid component of mixed lesion is evaluated for above features

16. Final adequacy of FNAC
    A. FNAC adequacy
    B. Cell block adequacy
17. FNAC report of the patient
18. Final biopsy of the patients who had thyroidectomy
19. Maximum size of the tumour
    A. Side
    B. Extrathyroidal extension
    C. Lymphovascular invasion
    D. Lymph nodal involvement
20. Final histopathology report of patients who had thyroidectomy
21. Surgery performed

7. Statistical Analysis

A diagnostic test is considered to be either positive (abnormal) or negative (normal) and the disease either present or absent. There are then four possible interpretations of test results, two of which are correct and two wrong. The test has given the correct answer when it is positive in the presence of disease or negative in the absence of disease. On the other hand, the test has been misleading if it is positive when the disease is absent (false positive) or negative when the disease is present (false negative).

In case of US-FNAC's there are 6 possible results. A report of 'malignancy' or 'suspicious for malignancy' can be considered a positive test. A benign result is considered negative. Both the non-diagnostic and inadequate results do not actually reflect the test. It has more to do with the training of the performer. So these results are not considered in the calculation of the sensitivity and specificity.

The "gold standard" in the assessment of the test's accuracy rests on its relationship to some way of knowing whether the disease is truly present or not- a sound assessment of the truth. As it turns out, this gold standard is often elusive.

In case of thyroid lesions the "gold standard" is histopathological examination of the surgical specimen.

Sensitivity: is the proportion of truly diseased persons who are identified as diseased by the diagnostic test. Sensitivity is a reflection of the true positive rate.

Sensitivity = a/a+c

Specificity: is the proportion of truly non-diseased persons who are so identified by the test. Specificity is a reflection of the true negative rate.

Specificity = d/b+d

(Table: 2) The relationship between a diagnostic test result and the occurrence of disease (malignancy).

Table 3

	FNAC report	
Final HPE report	Present	Absent
Positive	True positive (a)	False positive (b)
Negative	False negative (c)	True negative (d)

Positive predictive value: The predictive value of a positive test is the probability of a test positive person truly having the disease.

The positive predictive value = a/a+b

Negative predictive value:

The predictive value of a negative test is the probability of a test negative person truly not having the disease. This is calculated by

Negative predictive value = d/c+d

In general, the sensitivity and specificity of test do not vary with the prevalence of the disease. Predictive values however are dependent on the disease prevalence. Higher the prevalence, the greater is the predictive value. In a clinical situation, the test should be highly specific to reduce the false positive thus reducing undue anxiety to the patient. At the same time, all the test positive need to be "picked up", so sensitivity of the test should be also high.

Accuracy: the closeness of a clinical observation to the true clinical state is called accuracy.

Accuracy = a+d/a+b+c+d

Analysis method

For analysis, malignant FNAC, suspicious, follicular neoplasms, atypia of undetermined significance were taken as positive i.e. indication for surgery to rule of malignancy and benign lesions were taken as negatives. The inadequate and non-diagnostic samples were excluded from the analysis because it was a function of operator training and not on the test itself.

- The analysis was performed using STATA 13.1
- The whole data set was summarised using the mean along with standard deviation for continuous variables and frequency along with percentage for categorical variables.

- **Adequacy**

    1. Percentage of adequate and inadequate US-FNACs was calculated and reported according to the Bethesda system of thyroid cytology.
    2. During calculation of adequacy of US-FNAC, cystic swellings were excluded.

3. Univariate logistic regression was performed to analyse the strength of association between inadequacy and various clinical variables like hypoechogenecity, calcification, solid lesion etc.

- **Accuracy**

1. For patients who had subsequent thyroidectomy, the US-FNAC report was correlated with the histopathology to calculate the accuracy and determine the sensitivity, specificity and predictive values of US-FNAC.
2. While calculating the accuracy of US-FNAC, cystic swellings and inadequate FNAC reports were excluded.

- **Secondary outcomes**

1. Chi square was performed to see the association between clinical variables, US-FNAC and final histopathology.
2. Univariate and multivariate logistic regression was performed to assess the strength of association between clinical variables and histopathology.
3. Univariate and multivariate logistic regression was performed to see the strength of association between histopathology results and other variables
4. A final model to predict malignancy based on clinical features was created by multivariate logistic regression and a ROC curve was constructed. An optimal cut of 0.6 was decided to calculate sensitivity and specificity. Goodness of fit was assessed using Hosmer- Lemeshow test and the chisquare was 3.2 with a p-value of 0.97.

8. Results

1 Age

The decade wise distribution of the population in this study group is depicted in the figure below. 269/290(92.5%) of our patients are between 20-60 years. (Fig10). Out of 117 patients who got operated, 67 had malignancy and 54 (80%) of them are less than 50 years of age

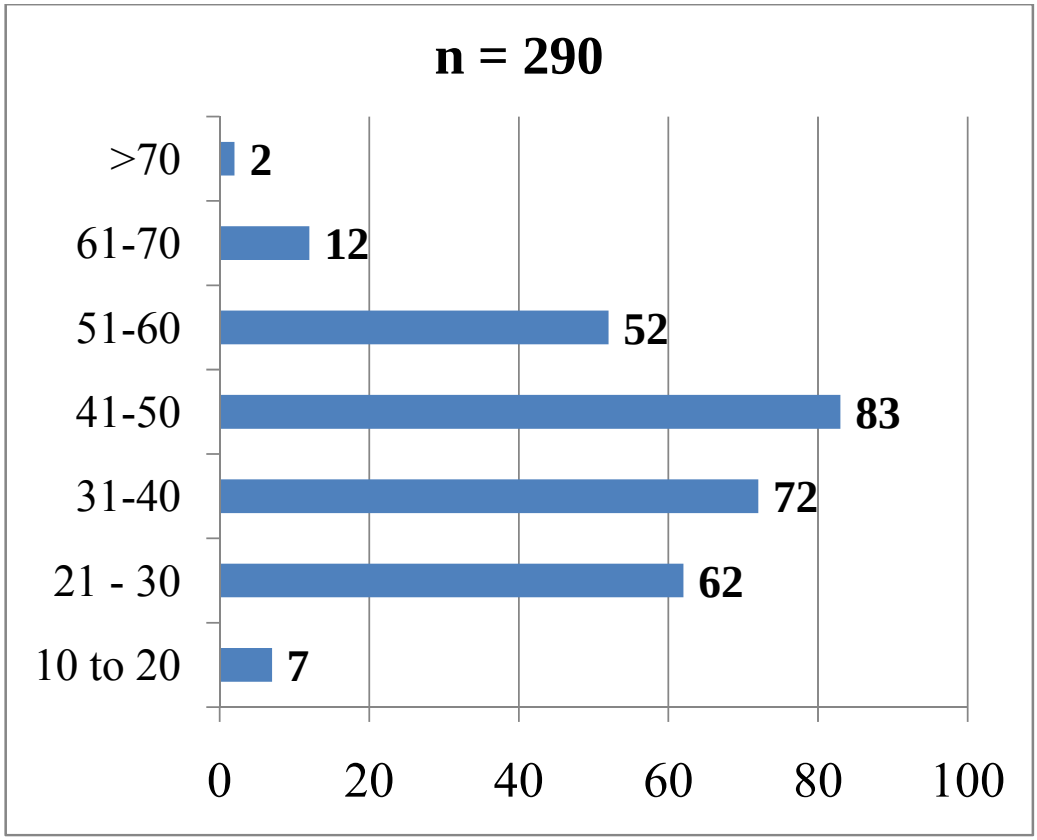

Figure 10

2 Gender

As expected there is a predominance of female 231 (79.66%) patients (Fig. 11). Thyroid cancer was diagnosed in 52/91 men (57.14%) and 15/26 women (57.69%)

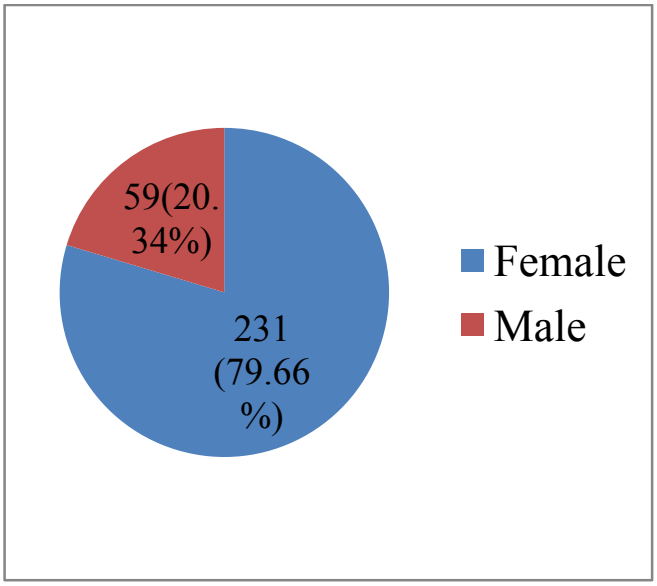

Figure 11

Table 4: Distribution of sex and malignancy in patients who had surgery

Sex	Final HPE of operated patients		Total no. of operated patients n= 117
	Benign	Malignant	
Men	11(42%)	15(58%)	26 (22%)
Women	39 (43%)	52 (57%)	91(78%)

'p' value = 0.96

3. Final FNAC Adequacy rate

Final adequacy is reported by the dedicated cytopathologist whereas preliminary or onsite adequacy is reported by the cytotechnician during the FNAC procedure.

Out of 290 patients who had FNAC, excluding the 17 cystic swellings, 219/273 (80.21%) were adequate and 54/273 (19.78%) were inadequate. (figure12)

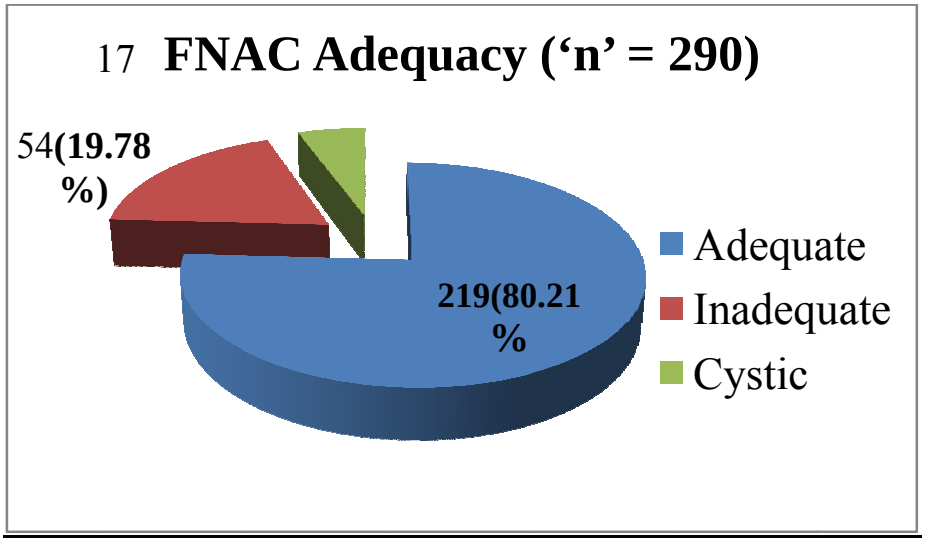

Figure 12

4. Onsite Assessment by Cytotechnician

Onsite cytotechnician identified 157 (71.36%) of the 219 adequate FNACs with a sensitivity and specificity of 78% and 53% respectively (figure13).

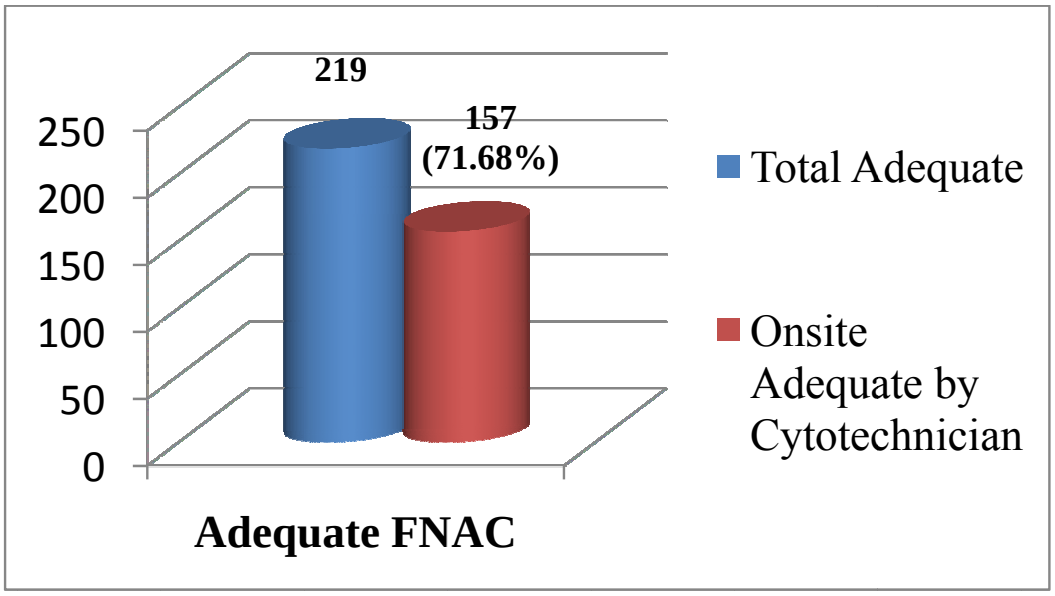

Figure 13

5. **Size of the lesion and adequacy of FNAC**

Adequacy of US-FNAC is high in lesions which are 1-2cm and lesions that are greater than 6cm as given below (table 5).

Table 5 Comparison of Ultrasound size of the nodule and final adequacy of US-FNAC

Size of the nodule	Total NO. of nodules	Adequate US-FNAC (%)
1-2cm	59	53 (89.8%)
2-4cm	147	114 (77.5%)
4-6cm	44	33 (75%)
> 6cm	19	15 (84%)

6. Ultrasound characteristics and adequacy of US-FNAC

Thyroid nodules which are hypoechoic, solid, homogenous, round (taller than wide), with or without microcalcification and with ill defined-microlobulated margins have an adequacy rate of > 80%. Mixed lesions have the least adequacy of 67%. Cystic lesion is excluded during calculation of adequacy (table 6).

Table 6 Ultrasound characteristics and adequacy of US-FNAC

S.NO	USG feature	Total NO (n=290)	Final adequacy of US-FNAC
1.	Hypoechoic/markedly hypoechoic	100	85 (85%)
2.	Hyperechoic/isoechoic	165	127 (76%)
3	Microcalcification	95	77 (81%)
4.	Macrocalcification	25	18 (72.1%)
5.	No- calcification	149	120 (80.53%)
6.	Solid lesion	171	142 (83%)
7.	Mixed lesion	94	67 (71%)
8.	Ill-defined/ microlobulated margin	64	53 (84.1%)
9.	Well defined margin	206	163 (79.1%)
10.	Taller than wide	39	34 (87.1%)

11.	Wider than tall	230	181 (78.6%)
12.	Heterogenous lesion	162	127 (78.3%)
13.	Homogenous lesion	75	61 81.3%)
14.	**Size of the nodule**	Total number	Percentage
	1-2cm	62	53(86%)
	2-4cm	158	114(72.15%)
	4-6cm	46	33(71.17%)
	>6cm	21	16(76.19%)
15	**Sex**		
	Men	59	42(71.18%)
	Women	231	177(76.62%)

7. Correlation of TIRADS and final adequacy of US-FNAC

TIRADS 4c and 5 have highest US-FNAC adequacy of 90% (table 7)

Table 7 Correlation of TIRADS and final adequacy of US-FNAC

TIRADS category	Total NO.	Final adequacy of US-FNAC
TIRADS 1&2	28	20 (71.4%)
TIRADS 3	92	75 (81.5%)
TIRADS 4a	76	56 (73.6%)
TIRADS 4b	28	22 (78.57%)
TIRADS 4c	30	28 (93.33%)
TIRADS 5	19	16 89.47%)

8. US-FNAC REPORT

Majority of our US-FNAC reports are benign 116/273 (42%), with an inadequacy rate of 19.78% (54), atypia of undetermined significance and malignancy rate of 12% each, suspicious for malignancy 7% and follicular neoplasm 6%. Cystic lesions (17) were excluded while calculating adequacy (table 8).

Table 8 US FNAC results

S.NO	Bethesda report	n=273
1	Inadequate	54(19.78%)
2	Benign	116(42%)
3	AUS/FLUS	35(12%)
4	Follicular neoplasm	16(6%)
5	Suspicious for malignancy	18(7%)
6	Malignant	34(12%)

9. **Distribution of US-FNAC and final histopathology for those who underwent surgery n=117/290**

a. **Inadequate**

Analysis showed that, 19 patents with inadequate FNAC's underwent surgery and 11/19 (58%) were malignant on final histopathological (HPE) examination.

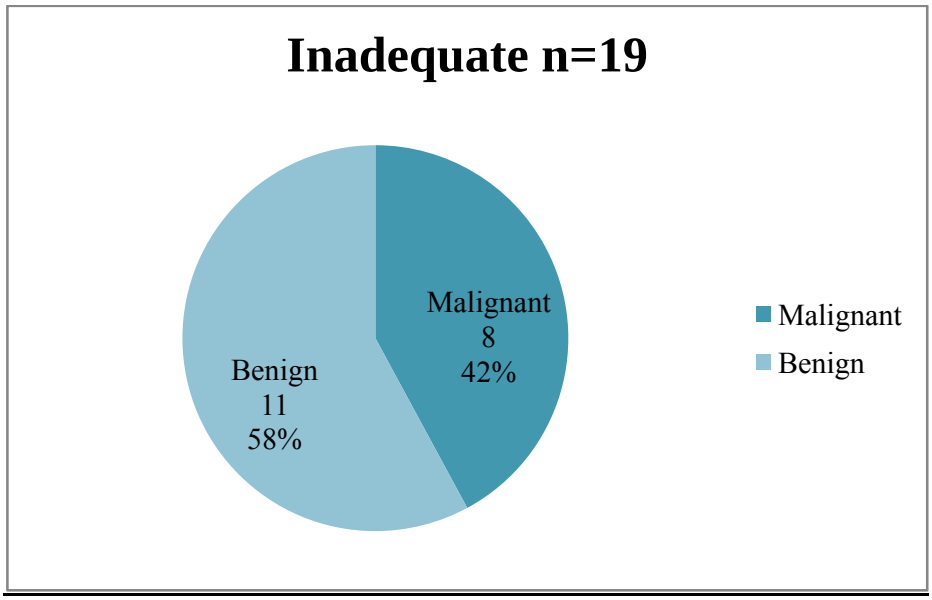

Figure 104

b. **Benign**

10/36 (28%) of benign US-FNAC were malignant on final histopathological examination. Out of the 10 benign FNAC's turning out to be malignant, 8 (80%) of

them were follicular variant of papillary carcinoma of thyroid and 2 of them were papillary carcinoma of thyroid (figure 15).

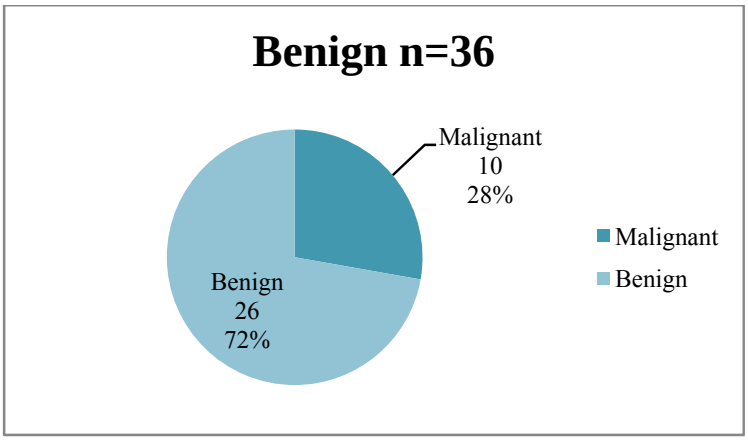

Figure 15

c. Atypia of undetermined significance (AUS) or follicular lesion of undetermined significance (FLUS)

Analysis showed that 8/11 (73%) of AUS/FLUS patients had malignancy on final histopathological examination (figure 16, 17, 18).

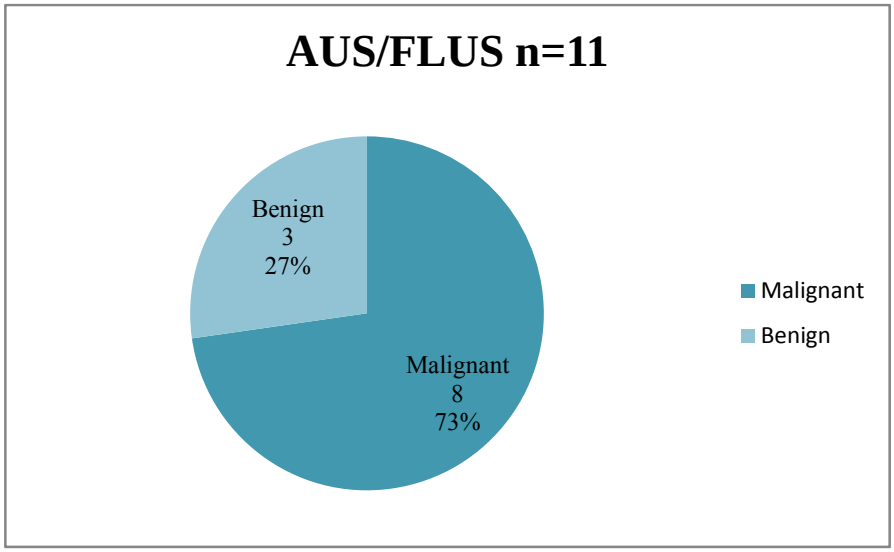

Figure 116

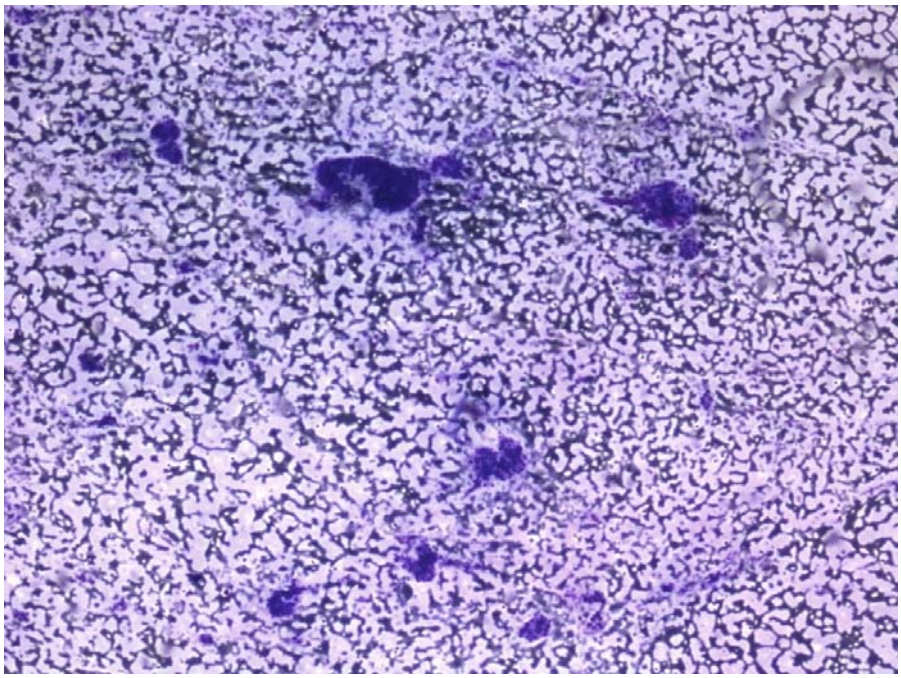

Figure 127 Cohesive and papillaroid clusters in a paucicellular sample with moderate colloid. Atypia of undetermined significance which was malignant on final histopathology (MGG 100x)

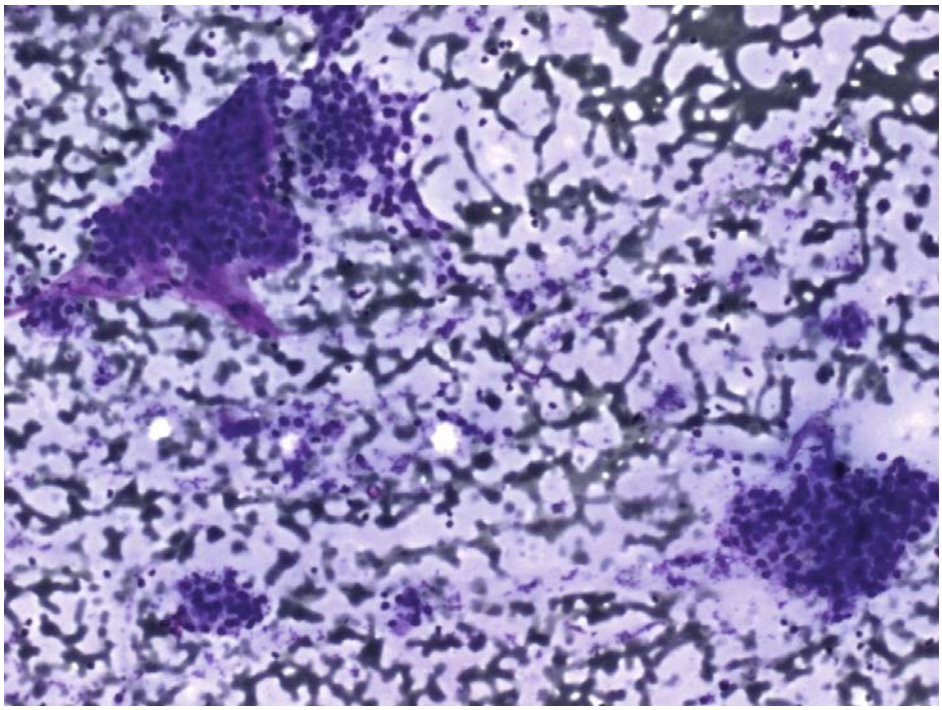

Figure 138 Cellular sample with monolayered sheets with moderate colloid, AUS which was benign on final histopathology (MGG 100x)

d. Follicular neoplasm or suspicious for follicular neoplasm

50% of follicular neoplasms are malignant on final HPE (figure 19).

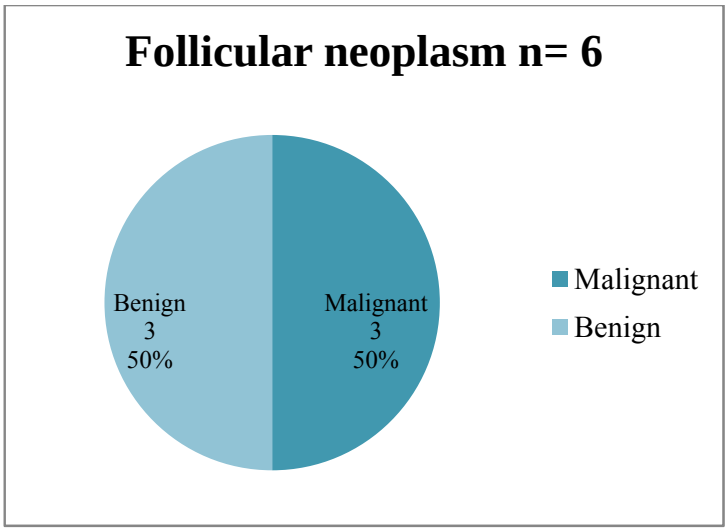

Figure 149

e. Suspicious for malignancy

92% of suspicious for malignancy is malignant on final HPE (figure 20).

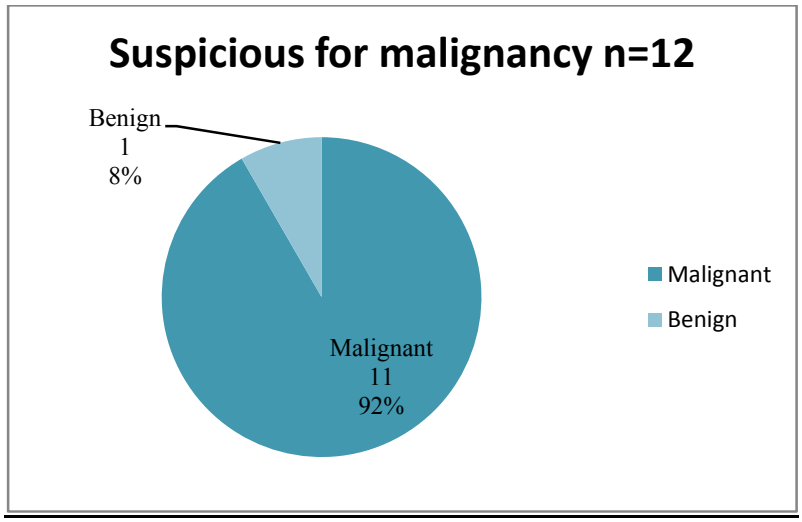

Figure 20

f. Malignant

All malignant FNACs are malignant on final HPE (figure 21, 22, 23).



Figure 21

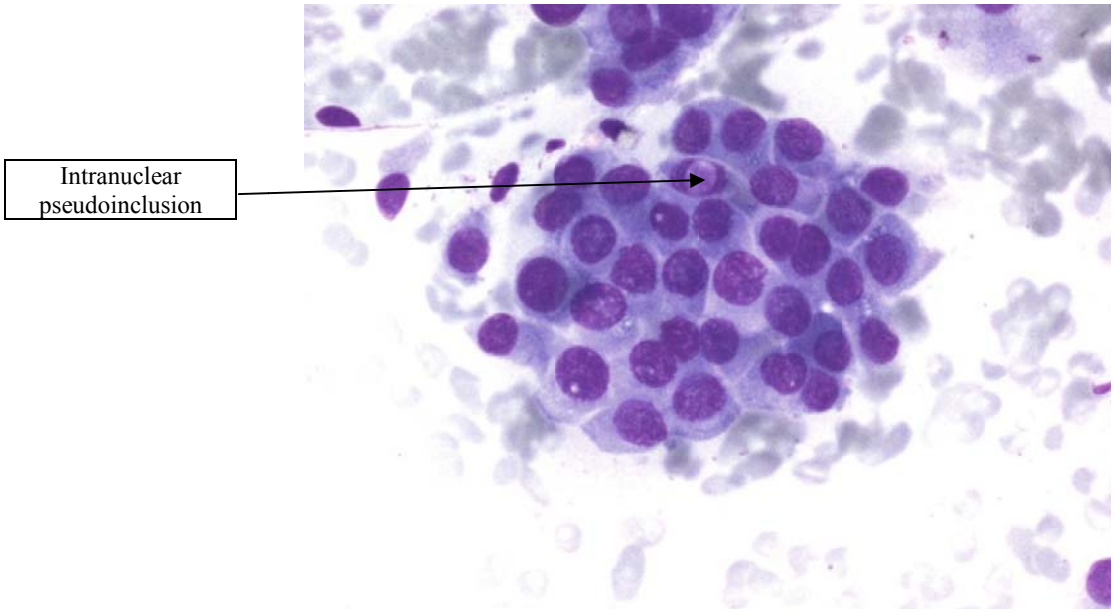

Figure 22 Nuclear enlargement with intranuclear pseudoinclusion, Papillary carcinoma of thyroid (MGG 400x)

Plasmacytoid cell

Spindle cell

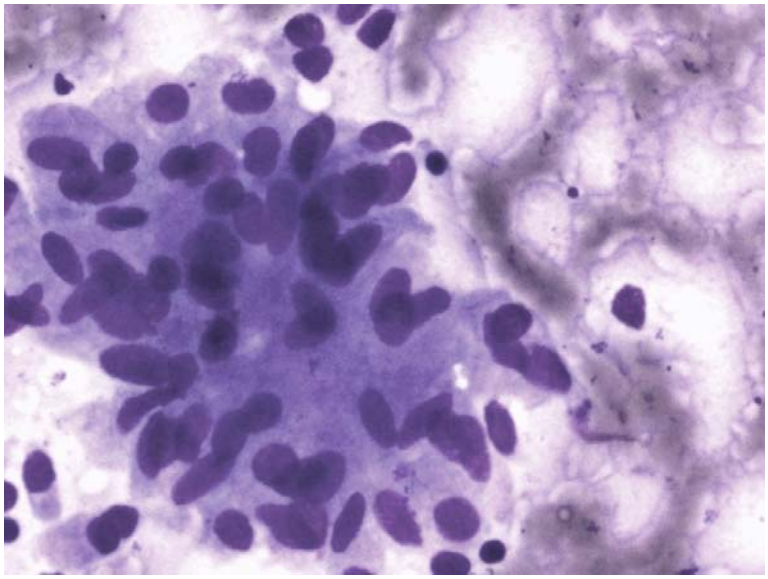

Figure 23 Plasmacytoid and spindle cells, Medullary carcinoma of thyroid MGG 400x

Table 9 Distribution of US-FNAC and final histopathology for those who underwent surgery n=117/290

FNAC Category	Total pt who had surgery (n=117)	Final histopathology correlation	
		Malignant	Benign
Inadequate	19	8 (48%)	11
Benign	36	10 (28%)	26
FLUS/AUS	11	8 (73%)	3
Follicular neoplasm	6	3 (50%)	3
Suspicious for malignancy	12	11 (92%)	1
Malignant	27	27 (100)	-

For analysis, the US-FNAC results malignant, suspicious for malignancy, follicular neoplasms, atypia of undetermined significance were taken as positive and benign lesions were taken as negatives. The inadequate and non-diagnostic samples were excluded from the analysis because it was a function of operator training and not on the test itself.US-FNAC (calculation of sensitivity and specificity).

While calculating the sensitivity and specificity of the US-FNAC test,

	US-FNAC report	
Final HPE	Positive for malignancy	Negative for malignancy
Malignant	49	10
Benign	6	26

Sensitivity of the test is 83.1% (95% CI 71%-91.6%)

Specificity of the test is 81.3% (95% CI 63.6%-92.8%)

Likelihood ratio **4.43**
Positive predictive value **89.1%**
Negative predictive value **72.2%**
Accuracy **82.4%**

3. **Final histopathology results of patients who underwent Thyroidectomy**

Based on the results of FNAC's or clinical suspicion of malignancy (which includes USG) 117 of 290 (40.34%) patients had thyroidectomy and 67 (57.26%) of them had malignancy. The rest of the patients had benign HPE and 6 had micro-papillary carcinoma of thyroid (i.e. predominantly benign with incidental micro PTC) (table 10).

Table 10 Final histopathology of those who had surgery

Final biopsy	n 117 (40.34%)
Benign	43 (37%)
Papillary carcinoma	39 (33%)
FVPTC	23 (20%)
Medullary carcinoma	3 (3%)
Anaplastic	1
Predominantly benign with micro PTC	6 (5%)
Poorly differentiated carcinoma	1
Follicular neoplasm of uncertain malignant potential	1

Secondary outcomes

4. **Compressive symptoms**

Total of 96 patients had compressive symptoms, out of which 43 got operated and 27 (62.79%) were malignant.

5. **Hyperthyroidism or hypothyroidism**

14/290 (4.8%) patients had symptoms of either hyperthyroidism or hypothyroidism.

6. **Voice change**

16/290 (4.82%) patients had voice change, out of which 10 got operated and 7 had malignancy in the final histopathology.

7. **Consistency**

26/290 (8.96%) of the nodules were hard in consistency, 18 of them got operated and 16 (88.88%) were malignant.

8. **Mobility**

23/290 (7.93%) patients had restricted/fixed mobility, 11 of them got operated and all of them were malignant.

9. **Retrosternal extension**

Clinically 24/290 (8.27%) of the patients had retrosternal extension, out of which eleven got operated and 5 of them were malignant. Only one patient needed sternotomy, as he had medullary carcinoma of thyroid with extensive mediastinal disease.

10. **Clinically palpable nodes in the neck**

12/290 (4.13%) patients had clinically palpable nodes in the neck, 11 of them got operated and all were malignant

Table11: Correlation of clinical characteristics and malignancy rate in patients who underwent surgery

Clinical characteristics	Compressive symptoms	Voice change	Consistency (Hard)	Mobility (restricted/fixed)	Significant lymph nodes
Total no. who got operated 'n' = 117	43	10	18	11	11
Malignant in final HPE	27 (62.79%)	7	16 (88.88%)	11 (100%)	11(100%)
p value	0.594	0.85	**0.002**	**0.003**	**0.002**

11. Ultrasound characteristics

Ultrasound characteristics for calculating thyroid imaging reporting and data system score (TIRADS) and the frequency of malignancy is given below. During analysis, hypoechoic, microcalcification, solid lesion, ill-defined lesions and taller than wide lesions were considered malignant and hyperechoic, isoechoic, no microcalcification, mixed lesions, cystic lesions, well defined lesions and wider than tall were considered benign lesions (table 12).

Table 12 Ultrasound characteristics and correlation with final HPE

USG characteristics	Operated n=117	Final HPE-Malignant	Sensitivity %	Specificity %	NPV %	PPV %
Hypoechoic	50	42/50 (84%)	63	82	59.7	84
Microcalcification	47	47/64 (73.4%)	70	66	62.3	73.4
Solid lesions	81	53 (65.4%)	78	42	58.3	64.2
Ill-defined/microlobulated	38	31 (81.57%)	46	86	42.8	65.7
Taller than wide	23	18 (78.26%)	26.9	90	47.9	78.3

12. TIRADS scoring and malignancy

The distribution of various TIRADS category is given below (table 13).

Table 13 Total number in each TIRADS category

TIRADS Category	Total number (n=290)
TIRADS 1	**8 (2.7%)**
TIRADS 2	**26 (8.96%)**
TIRADS 3	**100 (34.48%)**
TIRADS 4a	**76 (26.20%)**
TIRADS 4b	**30 (10.34%)**
TIRADS 4c	**30 (10.34%)**
TIRADS 5	**19 (6.55%)**

During analysis, when we take TIRADS 1, 2, 3 and 4a as benign and TIRADS 4b, 4c and 5 as malignant the sensitivity and specificity for identifying malignancy is 54% and 83% respectively. If we take TIRAD 1, 2 and 3 as benign and TIRADS 4a, 4b, 4c and 5 as malignant the sensitivity and specificity of the test is 78% and 55% respectively (table 14).

Table 14 TIRADS with final HPE (p-value = 0.078)

TIRADS	Operated n=117	Malignant
1,2	11/117(9.4%)	1/9 (9.09%)
3	29(24.78%)	10(34.48%)
4a	28(23.93%)	15(53.57%)
4b	17(14.52%)	13(76.47%)
4c	15(12.82%)	12(80%)
5	17(14.52%)	17(100%)

13. Types of surgeries during the study period.

80% of patients in the study group had total thyroidectomy and less than 5% had hemithyroidectomy (table 15).

Table 15 Types of surgeries

Type of Surgery	Number 'n'= 117
Total thyroidectomy	93 (79.48%) (2 had Tracheal resection and anastomosis)
TT+CCLND	5 (4.27%)
TT+CCLND+MRND	13 (11.11%) (1 sternotomy)
Hemithyroidectomy	5 (4.2%)
	2/5 = FVPTC
Completion for recurrent MNG	1

14. Univariate analysis has shown the following factors, FNAC (includes atypia of undetermined significance AUS/ follicular neoplasm FN/ suspicious for malignancy SM/ malignant M), hypoechoic/ markedly hypoechoic, taller than wide, ill defined margins,microcalcification and significant lymph nodal involvement, solid lesion and TIRADS to be significant in predicting malignancy.

Table 16 Univariate analysis of factors predicting malignancy

S.NO.	Category	Odds Ratio	95% confidence interval		p-value
1	FNAC (AUS, FN, SM, M)	21.23	6.93	64.96	**0.00**
2	Hypoechoic	7.77	3.12	19.31	**0.00**
3	Shape (taller than wide)	3.30	1.13	9.64	**0.029**
4	Solid lesion	2.51	1.12	5.60	**0.025**
5	Margins	5.28	2.08	13.43	**0.00**
6	Microcalcification	4.56	2.08	10.00	**0.00**
7	Lymph node involvement	8.59	1.06	69.55	**0.04**
8	TIRADS (progressive increase from 1 to 5)	2.49	1.74	3.58	**0.00**
9	Hard consistency	3.88	0.305	49.21	0.295

15. Multivariate analysis showed that FNAC (Includes AUS/ FN/SM/M), hypoechoic , markedly hypoechoic lesion and a solitary thyroid nodule were significant in predicting mali malignancy. Goodness of fit was assessed using Hosmer-Lemeshow test. Model showed a chisquare of 3.2 with a p-value of 0.92.

Table 17 Multivariate analysis for predicting malignancy

	Odds Ratio	**95% confidence interval**		**p-value**
FNAC (AUS/FN/SM/M)	**26.85**	**5.76**	**124.99**	**0.00**
Hypoechoic/ markedly hyperechoic	**5.96**	**1.39**	**25.53**	**0.016**
Solitary thyroid nodule	**6.55**	**1.51**	**28.40**	**0.012**
Hard consistency	3.88	0.305	49.21	0.295
Solid lesion	1.12	0.27	4.62	0.16
USG Size>4cm	1.65	0.65	4.14	0.285
Microcalcification	1.77	0.45	6.90	0.40

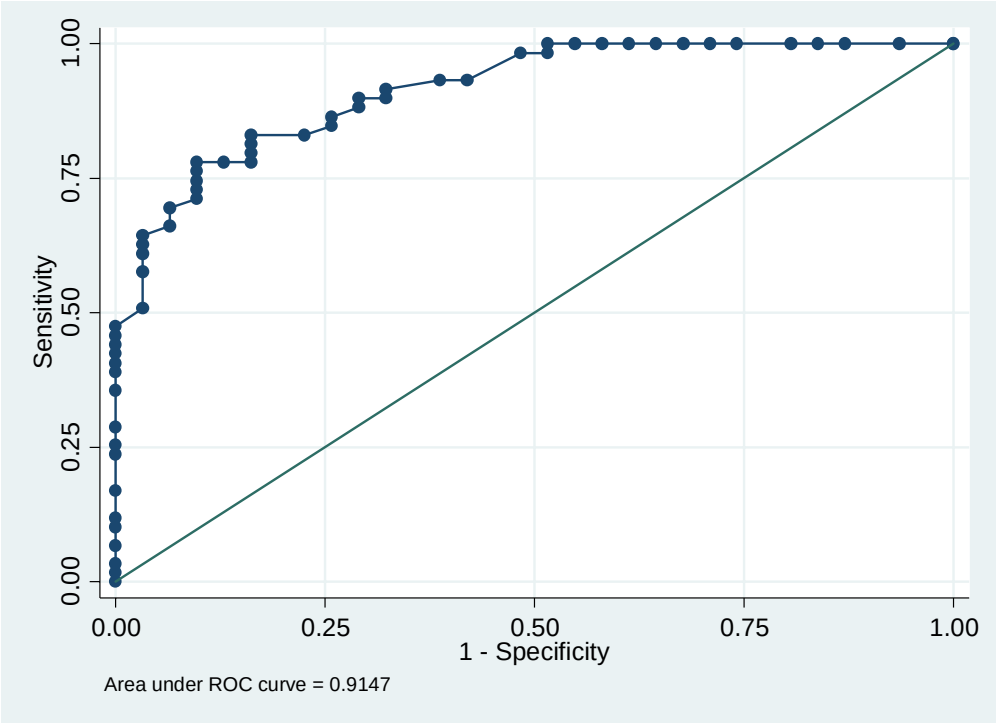

Figure 24 ROC curve for the factors in multivariate analysis

Apart from theses significant factors other important clinical variables like hard consistency, solid lesion, USG size > 4cm and presence of calcification were used to create an ROC curve (figure 24).

The area under the curve is 0.91.

Taking > 0.6 as predictive probability, a sensitivity of 84.78% and a specificity of 77.4 in predicting malignancy was calculated for these features as given in table17.

9. Discussion

Thyroidectomy is the most common operation performed by an endocrine surgeon. As we know, the important tests for diagnosing a thyroid nodule apart from clinical examination are fine needle aspiration cytology and ultrasound of neck. Fine-needle aspiration cytology is an important diagnostic test in the clinical management of thyroid nodules. FNAC has helped us in decreasing the number of diagnostic thyroidectomies for benign thyroid nodules and focus on the malignant thyroid nodules.

Demographic profile

Age

More than 90% of our patients are between 20-60 years. The highest incidence of malignancy was seen between 20-40 years (59%). This is contrary to literature where a peak incidence of malignancies is reported in the sixth to seventh decade in males and in the fifth decade in females[59,60]. This peak incidence in younger patients is probably due to health seeking patient bias and profile of patients in a non-urban tertiary centre

Gender

In literature reports, goitres are more common in females[61]. In this study as well there is a predominance of female patients presenting with goitres.

Clinical features

Compressive symptoms like dysphagia, dyspnoea and a foreign body sensation in the throat are present in both benign and malignant thyroid swellings. In literature, the majority

of patients with compressive symptoms had a benign thyroid nodule[62]. But in our study, 63% of patients with compressive symptoms had malignancy, though it is not statistically significant (p-value 0.594).

Restricted mobility and a hard swelling are considered as markers of invasive thyroid cancer[63], in our study both of them were statistically significant and have high specificity (p-value < 0.005) but with low sensitivity.

Adequacy of fine needle aspiration cytology

A non-diagnostic fine needle aspiration cytology report, even under ultrasound guidance, is reported in up to 33.6% in literature. Our study has an inadequacy rate of 19.78%. Factors which can improve the adequacy of thyroid FNACs, are use of thinner needles, non-aspiration technique, preparation of cell block and a dedicated cytopathologist. Some reports have focused on the clinical characteristics of patients and ultrasound features to predict inadequacy[64–66].

Male gender has been associated with increased risk of non-diagnostic results[67]and is probably due to technical difficulty caused by increased thickness of neck muscles. In the present study, the inadequacy rate in men and women is almost similar.

In contrast to other studies[67], the presence or absence of microcalcification, hypoechogenecity and solid nodules have a high adequacy rate of >80% and hyperechoic or isoechoic, nodules with macrocalcification and mixed lesions have high inadequacy. Hypoechogenecity and microcalcification have high specificity for malignancy; hence we must focus meticulously on these nodules to improve the adequacy.

Some authors have reported an increased frequency of inadequate FNACs in nodules >3 cm, probably due to internal degeneration[66]. Even in the present study nodules with 1-2cm size have an inadequacy rate of 14% compared to nodule 2-4cm which has a high inadequacyof 28%.

In a recent meta-analysis, assessing whether the rapid onsite assessment by a cytopathologist or a cytotechnician will improve the adequacy of FNAC, concluded that, sites with lower initial adequacy rates benefit the most from implementation of onsite assessment[39]. In the present study the cytotechnician had a sensitivity of 78% and specificity of 53% in identifying the adequate FNAC sample. This low sensitivity and specificity in this study is due to lack of an onsite cytopathologist and a dedicated cytotechnician.

Majority of our US-FNAC reports are benign 42% (116/273), with an inadequacy rate of 19.78% (54), atypia of undetermined significance and malignancy rate of 12% each, suspicious for malignancy 7% and follicular neoplasm 6%. This is comparable to the literature[68]. Cystic lesions (17) were not included while calculating adequacy.

Accuracy of ultrasound guided fine needle aspiration cytology (US-FNAC)

117 patients were operated in the study group out which 67 (57.26%) were malignant. This high rate of malignancy>50% is described[5] in the literature and is probably due to increased detection by ultrasound guided fine needle aspiration cytology or a referral bias in a tertiary hospital.

The sensitivity and specificity of US-FNAC was calculated by categorising FNAC results malignant (M), suspicious for malignancy (SM), follicular neoplasms (FN), atypia of undetermined significance (AUS) as one group and benign as other group. The inadequate and non-diagnostic samples were excluded from the analysis. The sensitivity of US-FNAC in predicting malignancy is 83.1% and specificity of 81.3%. The results are comparable to the literature[30–32,35].

There is an increased rate of malignancy (73%) in atypia of undetermined significance or follicular lesion of undetermined significance (AUS/FLUS) in the present study, and is probably due to low numbers or selection bias. In the literature, malignancy rate of 10-50% is described in AUS; The atypia of undetermined significance or follicular lesion of undetermined significance may have a higher risk of cancer than 10-15% as described in Bethesda, and the guidelines recommending repeat FNA or observation merit reconsideration[21,69,70].

The rate of 28% malignant histopathology where FNAC was reported as benign in this study is very high. Surprisingly 80% (8/10) of these patients had follicular variant of papillary thyroid cancer. In a study by Didem Ozdemir[71], 21.4% of the FVPTCs were reported as benign on FNAC, these lesions are known to be difficult to interpret and tend to have more benign features in FNAC and ultrasound. Sparse cellularity of the sample and possible sampling error could also attribute to this high rate.

Ultrasound characteristics

In our study, specificity of hypoechogenecity, microcalcification, ill-defined or lobulated margins and taller than wide is greater than 80% and is comparable to Moon et al[52] and other studies in predicting malignancy[34,45,72]. A predominantly solid criterion alone may not be useful to differentiate malignant from benign nodule. In our study solid lesion has a sensitivity of 78% and a specificity of 42%.

In our study, the TIRADS has a progressive risk of malignancy, unlike other studies, which have a risk of 2 to 31%[45,54,73] malignancy in TIRADS-3 nodules; our study has a slightly increased risk of 34%. Out of the malignant TIRADS-3 nodules, 80% were again follicular variant of papillary carcinoma of thyroid, which are difficult to diagnose both by FNAC or ultrasound[71].

In a nomogram described by Nixon et al[74], biochemical, ultrasonographic, and cytologic features were used to quantify the risk of malignancy in a thyroid nodule. In the present study clinical, ultrasonographic and FNAC categories like AUS, follicular neoplasm, suspicious for malignancy and malignancy were included to calculate a nomogram with a sensitivity of 84.78% and a specificity of 77.4% in predicting malignancy.

10. **Conclusions**

- The use of ultrasound guidance for doing fine needle aspiration cytology in palpable thyroid nodules will significantly reduce the rates of inadequate samples. The adequacy rate in this study is 80.1%.
- The accuracy rate in inadequate, benign and AUS categories need to improve in this study and most of them had FVPTC, which is known to have heterogenous features on ultrasound and patchy distribution of nuclear features for malignancy on histopathology.
- Due to the heterogeneity of the AUS category in the Bethesda system, ranging from sparse cellularity to genuine atypia, the rate of malignancy in AUS may vary. In this study, there was a high rate of malignancy in this category (73%).
- Multidisciplinary dedicated teams help in improving the adequacy of fine needle aspiration cytology in palpable thyroid nodules.
- Ultrasound and clinical features have an important role, apart from FNAC in managing thyroid nodules.
- FNAC (AUS/ FN/ SM/ M), and ultrasound features hypoechoic/ markedly hypoechoic, taller than wide, ill defined margins, microcalcification, and solid lesions are significant factors in predicting malignancy in a thyroid nodule.
- Each institute should validate Bethesda system of thyroid FNAC reporting, as the rate of malignancy may vary in individual categories.

11. Future direction

- To encourage this multidisciplinary dedicated team to perform US-FNAC for all palpable thyroid nodules and improve the services offered to the patient.

- To further refine the diagnosis of AUS with sub categorisation to provide better guidelines towards management.

- To improve the ultrasound guided sampling of the suspicious area within the nodule of interest, so as to reduce the high false negative rate of benign FNAC.

12. References

1. Rojeski MT, Gharib H. Nodular thyroid disease. Evaluation and management. N Engl J Med. 1985 Aug 15;313(7):428–36.

2. Tan GH, Gharib H. Thyroid incidentalomas: management approaches to nonpalpable nodules discovered incidentally on thyroid imaging. Ann Intern Med. 1997 Feb 1;126(3):226–31.

3. Vigneri R. Studies on the goiter endemia in Sicily. J Endocrinol Invest. 1988 Dec;11(11):831–43.

4. Reynolds RM, Weir J, Stockton DL, Brewster DH, Sandeep TC, Strachan MWJ. Changing trends in incidence and mortality of thyroid cancer in Scotland. Clin Endocrinol (Oxf). 2005 Feb;62(2):156–62.

5. Leenhardt L, Grosclaude P, Chérié-Challine L, Thyroid Cancer Committee. Increased incidence of thyroid carcinoma in france: a true epidemic or thyroid nodule management effects? Report from the French Thyroid Cancer Committee. Thyroid Off J Am Thyroid Assoc. 2004 Dec;14(12):1056–60.

6. Chen AY, Jemal A, Ward EM. Increasing incidence of differentiated thyroid cancer in the United States, 1988-2005. Cancer. 2009 Aug 15;115(16):3801–7.

7. Pacini F, Schlumberger M, Dralle H, Elisei R, Smit JWA, Wiersinga W, et al. European consensus for the management of patients with differentiated thyroid carcinoma of the follicular epithelium. Eur J Endocrinol Eur Fed Endocr Soc. 2006 Jun;154(6):787–803.

8. Piaggio-Blanco R.A., Paseyro P., Grosso O.F. El citogramma tiroideo; su interes clinico. // Arcg Urug Med – 1948 – Vol. 32. – P. 82 - 85.

9. Löwhagen T, Willems JS. Aspiration biopsy cytology of carcinoma of the thyroid. Neth J Med. 1981;24(2):58–62.

10. Chen H, Zeiger MA, Clark DP, Westra WH, Udelsman R. Papillary carcinoma of the thyroid: can operative management be based solely on fine-needle aspiration? J Am Coll Surg. 1997 Jun;184(6):605–10.

11. Musholt TJ, Musholt PB, Petrich T, Oetting G, Knapp WH, Klempnauer J. Familial papillary thyroid carcinoma: genetics, criteria for diagnosis, clinical features, and surgical treatment. World J Surg. 2000 Nov;24(11):1409–17.

12. Hegedüs L. Clinical practice. The thyroid nodule. N Engl J Med. 2004 Oct 21;351(17):1764–71.

13. American Thyroid Association (ATA) Guidelines Taskforce on Thyroid Nodules and Differentiated Thyroid Cancer, Cooper DS, Doherty GM, Haugen BR, Hauger BR, Kloos RT, et al. Revised American Thyroid Association management guidelines for patients with thyroid nodules and differentiated thyroid cancer. Thyroid Off J Am Thyroid Assoc. 2009 Nov;19(11):1167–214.

14. Ravetto C, Colombo L, Dottorini ME. Usefulness of fine-needle aspiration in the diagnosis of thyroid carcinoma: a retrospective study in 37,895 patients. Cancer. 2000 Dec 25;90(6):357–63.

15. Ogilvie JB, Piatigorsky EJ, Clark OH. Current status of fine needle aspiration for thyroid nodules. Adv Surg. 2006;40:223–38.

16. Pepper GM, Zwickler D, Rosen Y. Fine-needle aspiration biopsy of the thyroid nodule. Results of a start-up project in a general teaching hospital setting. Arch Intern Med. 1989 Mar;149(3):594–6.

17. Wang HH. Reporting thyroid fine-needle aspiration: literature review and a proposal. Diagn Cytopathol. 2006 Jan;34(1):67–76.

18. Akerman M, Tennvall J, Biörklund A, Mårtensson H, Möller T. Sensitivity and specificity of fine needle aspiration cytology in the diagnosis of tumors of the thyroid gland. Acta Cytol. 1985 Oct;29(5):850–5.

19. Cáp J, Ryska A, Rehorková P, Hovorková E, Kerekes Z, Pohnetalová D. Sensitivity and specificity of the fine needle aspiration biopsy of the thyroid: clinical point of view. Clin Endocrinol (Oxf). 1999 Oct;51(4):509–15.

20. BTA-management-_thyroid-cancer-guideline.pdf.

21. Cibas ES, Ali SZ, NCI Thyroid FNA State of the Science Conference. The Bethesda System For Reporting Thyroid Cytopathology. Am J Clin Pathol. 2009 Nov;132(5):658–65.

22. Grant CS, Hay ID, Gough IR, McCarthy PM, Goellner JR. Long-term follow-up of patients with benign thyroid fine-needle aspiration cytologic diagnoses. Surgery. 1989 Dec;106(6):980–5; discussion 985–6.

23. Yang J, Schnadig V, Logrono R, Wasserman PG. Fine-needle aspiration of thyroid nodules: a study of 4703 patients with histologic and clinical correlations. Cancer. 2007 Oct 25;111(5):306–15.

24. Ho AS, Sarti EE, Jain KS, Wang H, Nixon IJ, Shaha AR, et al. Malignancy rate in thyroid nodules classified as Bethesda category III (AUS/FLUS). Thyroid Off J Am Thyroid Assoc. 2014 May;24(5):832–9.

25. Baloch ZW, Fleisher S, LiVolsi VA, Gupta PK. Diagnosis of "follicular neoplasm": a gray zone in thyroid fine-needle aspiration cytology. Diagn Cytopathol. 2002 Jan;26(1):41–4.

26. Gharib H, Goellner JR, Johnson DA. Fine-needle aspiration cytology of the thyroid. A 12-year experience with 11,000 biopsies. Clin Lab Med. 1993 Sep;13(3):699–709.

27. Gharib H, Papini E, Paschke R, Duick DS, Valcavi R, Hegedüs L, et al. American Association of Clinical Endocrinologists, Associazione Medici Endocrinologi, and European Thyroid Association medical guidelines for clinical practice for the diagnosis and management of thyroid nodules. J Endocrinol Invest. 2010;33(5 Suppl):1–50.

28. Redman R, Zalaznick H, Mazzaferri EL, Massoll NA. The impact of assessing specimen adequacy and number of needle passes for fine-needle aspiration biopsy of thyroid nodules. Thyroid Off J Am Thyroid Assoc. 2006 Jan;16(1):55–60.

29. Izquierdo R, Arekat MR, Knudson PE, Kartun KF, Khurana K, Kort K, et al. Comparison of palpation-guided versus ultrasound-guided fine-needle aspiration biopsies of thyroid nodules in an outpatient endocrinology practice. Endocr Pract Off J Am Coll Endocrinol Am Assoc Clin Endocrinol. 2006 Dec;12(6):609–14.

30. Baskin HJ. Ultrasound-guided fine-needle aspiration biopsy of thyroid nodules and multinodular goiters. Endocr Pract Off J Am Coll Endocrinol Am Assoc Clin Endocrinol. 2004 Jun;10(3):242–5.

31. Seiberling KA, Dutra JC, Gunn J. Ultrasound-guided fine needle aspiration biopsy of thyroid nodules performed in the office. The Laryngoscope. 2008 Feb;118(2):228–31.

32. Bhatki AM, Brewer B, Robinson-Smith T, Nikiforov Y, Steward DL. Adequacy of surgeon-performed ultrasound-guided thyroid fine-needle aspiration biopsy. Otolaryngol--Head Neck Surg Off J Am Acad Otolaryngol-Head Neck Surg. 2008 Jul;139(1):27–31.

33. Al-azawi Dhafir, Mann GB, Judson RT, Miller JA. Endocrine surgeon-performed US guided thyroid FNAC is accurate and efficient. World J Surg. 2012 Aug;36(8):1947–52.

34. Kim DW. How to do it: ultrasound-guided fine-needle aspiration of thyroid nodules that commonly result in inappropriate cytology. Clin Imaging. 2013 Feb;37(1):1–7.

35. Tublin ME, Martin JA, Rollin LJ, Pealer K, Kurs-Lasky M, Ohori NP. Ultrasound-guided fine-needle aspiration versus fine-needle capillary sampling biopsy of thyroid nodules: does technique matter? J Ultrasound Med Off J Am Inst Ultrasound Med. 2007 Dec;26(12):1697–701.

36. Santos JE, Leiman G. Nonaspiration fine needle cytology. Application of a new technique to nodular thyroid disease. Acta Cytol. 1988 Jun;32(3):353–6.

37. Nguyen G-K, Lee MW, Ginsberg J, Wragg T, Bilodeau D. Fine-needle aspiration of the thyroid: an overview. CytoJournal. 2005 Jun 29;2(1):12.

38. Eedes CR, Wang HH. Cost-effectiveness of immediate specimen adequacy assessment of thyroid fine-needle aspirations. Am J Clin Pathol. 2004 Jan;121(1):64–9.

39. Witt BL, Schmidt RL. Rapid onsite evaluation improves the adequacy of fine-needle aspiration for thyroid lesions: a systematic review and meta-analysis. Thyroid Off J Am Thyroid Assoc. 2013 Apr;23(4):428–35.

40. Burguera B, Gharib H. Thyroid incidentalomas. Prevalence, diagnosis, significance, and management. Endocrinol Metab Clin North Am. 2000 Mar;29(1):187–203.

41. Fallahi P, Giannini R, Miccoli P, Antonelli A, Basolo F. Molecular diagnostics of fine needle aspiration for the presurgical screening of thyroid nodules. Curr Genomics. 2014 Jun;15(3):171–7.

42. Scheible W, Leopold GR, Woo VL, Gosink BB. High-resolution real-time ultrasonography of thyroid nodules. Radiology. 1979 Nov;133(2):413–7.

43. Solbiati L, Osti V, Cova L, Tonolini M. Ultrasound of thyroid, parathyroid glands and neck lymph nodes. Eur Radiol. 2001;11(12):2411–24.

44. Gharib H, Papini E, Paschke R, Duick DS, Valcavi R, Hegedüs L, et al. American Association of Clinical Endocrinologists, Associazione Medici Endocrinologi, and European Thyroid Association medical guidelines for clinical practice for the diagnosis and management of thyroid nodules. J Endocrinol Invest. 2010;33(5 Suppl):1–50.

45. Kim E-K, Park CS, Chung WY, Oh KK, Kim DI, Lee JT, et al. New sonographic criteria for recommending fine-needle aspiration biopsy of nonpalpable solid nodules of the thyroid. AJR Am J Roentgenol. 2002 Mar;178(3):687–91.

46. Peli M, Capalbo E, Lovisatti M, Cosentino M, Berti E, Mattai Dal Moro R, et al. Ultrasound guided fine-needle aspiration biopsy of thyroid nodules: Guidelines and recommendations vs clinical practice; a 12-month study of 89 patients. J Ultrasound. 2012 Jun;15(2):102–7.

47. Frates MC, Benson CB, Charboneau JW, Cibas ES, Clark OH, Coleman BG, et al. Management of thyroid nodules detected at US: Society of Radiologists in Ultrasound consensus conference statement. Radiology. 2005 Dec;237(3):794–800.

48. Ahuja A, Chick W, King W, Metreweli C. Clinical significance of the comet-tail artifact in thyroid ultrasound. J Clin Ultrasound JCU. 1996 Apr;24(3):129–33.

49. Papini E, Guglielmi R, Bianchini A, Crescenzi A, Taccogna S, Nardi F, et al. Risk of malignancy in nonpalpable thyroid nodules: predictive value of ultrasound and color-Doppler features. J Clin Endocrinol Metab. 2002 May;87(5):1941–6.

50. Alexander EK, Marqusee E, Orcutt J, Benson CB, Frates MC, Doubilet PM, et al. Thyroid nodule shape and prediction of malignancy. Thyroid Off J Am Thyroid Assoc. 2004 Nov;14(11):953–8.

51. Stavros AT, Thickman D, Rapp CL, Dennis MA, Parker SH, Sisney GA. Solid breast nodules: use of sonography to distinguish between benign and malignant lesions. Radiology. 1995 Jul;196(1):123–34.

52. Moon W-J, Jung SL, Lee JH, Na DG, Baek J-H, Lee YH, et al. Benign and malignant thyroid nodules: US differentiation--multicenter retrospective study. Radiology. 2008 Jun;247(3):762–70.

53. Unlütürk U, Erdoğan MF, Demir O, Güllü S, Başkal N. Ultrasound elastography is not superior to grayscale ultrasound in predicting malignancy in thyroid nodules. Thyroid Off J Am Thyroid Assoc. 2012 Oct;22(10):1031–8.

54. Horvath E, Majlis S, Rossi R, Franco C, Niedmann JP, Castro A, et al. An ultrasonogram reporting system for thyroid nodules stratifying cancer risk for clinical management. J Clin Endocrinol Metab. 2009 May;94(5):1748–51.

55. Zaleska-Dorobisz U, Kaczorowski K, Pawluś A, Puchalska A, Inglot M. Ultrasound elastography - review of techniques and its clinical applications. Adv Clin Exp Med Off Organ Wroclaw Med Univ. 2014 Aug;23(4):645–55.

56. Rago T, Vitti P. Role of thyroid ultrasound in the diagnostic evaluation of thyroid nodules. Best Pract Res Clin Endocrinol Metab. 2008 Dec;22(6):913–28.

57. Itoh A, Ueno E, Tohno E, Kamma H, Takahashi H, Shiina T, et al. Breast Disease: Clinical Application of US Elastography for Diagnosis. Radiology. 2006 May 1;239(2):341–50.

58. Jennings A. Evaluation of substernal goiters using computed tomography and MR imaging. Endocrinol Metab Clin North Am. 2001 Jun;30(2):401–14, ix.

59. Enewold L, Zhu K, Ron E, Marrogi AJ, Stojadinovic A, Peoples GE, et al. Rising thyroid cancer incidence in the United States by demographic and tumor characteristics, 1980-2005. Cancer Epidemiol Biomark Prev Publ Am Assoc Cancer Res Cosponsored Am Soc Prev Oncol. 2009 Mar;18(3):784–91.

60. Hodgson NC, Button J, Solorzano CC. Thyroid cancer: is the incidence still increasing? Ann Surg Oncol. 2004 Dec;11(12):1093–7.

61. Siegel R, Ma J, Zou Z, Jemal A. Cancer statistics, 2014. CA Cancer J Clin. 2014 Feb;64(1):9–29.

62. McHenry CR, Piotrowski JJ. Thyroidectomy in patients with marked thyroid enlargement: airway management, morbidity, and outcome. Am Surg. 1994 Aug;60(8):586–91.

63. Randolph GW, Kamani D. The importance of preoperative laryngoscopy in patients undergoing thyroidectomy: voice, vocal cord function, and the preoperative detection of invasive thyroid malignancy. Surgery. 2006 Mar;139(3):357–62.

64. Romitelli F, Di Stasio E, Santoro C, Iozzino M, Orsini A, Cesareo R. A comparative study of fine needle aspiration and fine needle non-aspiration biopsy on suspected thyroid nodules. Endocr Pathol. 2009;20(2):108–13.

65. G Fadda FB. Cytological classification of thyroid nodules. Proposal of the SIAPEC-IAP Italian Consensus Working Group. Pathologica. 2010;102(5):405–8.

66. Richards ML, Bohnenblust E, Sirinek K, Bingener J. Nondiagnostic thyroid fine-needle aspiration biopsies are no longer a dilemma. Am J Surg. 2008 Sep;196(3):398–402.

67. Grani G, Calvanese A, Carbotta G, D'Alessandri M, Nesca A, Bianchini M, et al. Intrinsic factors affecting adequacy of thyroid nodule fine-needle aspiration cytology. Clin Endocrinol (Oxf). 2013 Jan;78(1):141–4.

68. Cibas ES. Fine-Needle Aspiration in the Work-Up of Thyroid Nodules. Otolaryngol Clin North Am. 2010 Apr;43(2):257–71.

69. Ho AS, Sarti EE, Jain KS, Wang H, Nixon IJ, Shaha AR, et al. Malignancy rate in thyroid nodules classified as Bethesda category III (AUS/FLUS). Thyroid Off J Am Thyroid Assoc. 2014 May;24(5):832–9.

70. Salillas AL, Sun FCS, Almocera EG. Review of the Bethesda System for Reporting Thyroid Cytopathology: A Local Study in Bohol Island, Philippines. Acta Cytol. 2015 Feb 19;

71. Ozdemir D, Ersoy R, Cuhaci N, Arpaci D, Ersoy EP, Korukluoglu B, et al. Classical and follicular variant papillary thyroid carcinoma: comparison of clinical, ultrasonographical, cytological, and histopathological features in 444 patients. Endocr Pathol. 2011 Jun;22(2):58–65.

72. Kwak JY, Han KH, Yoon JH, Moon HJ, Son EJ, Park SH, et al. Thyroid imaging reporting and data system for US features of nodules: a step in establishing better stratification of cancer risk. Radiology. 2011 Sep;260(3):892–9.

73. Park J-Y, Lee HJ, Jang HW, Kim HK, Yi JH, Lee W, et al. A proposal for a thyroid imaging reporting and data system for ultrasound features of thyroid carcinoma. Thyroid Off J Am Thyroid Assoc. 2009 Nov;19(11):1257–64.

74. Nixon IJ, Ganly I, Hann LE, Lin O, Yu C, Brandt S, et al. Nomogram for predicting malignancy in thyroid nodules using clinical, biochemical, ultrasonographic, and cytologic features. Surgery. 2010 Dec;148(6):1120–7; discussion 1127–8.

13. Annexure 1

- **Patient information sheet and consent form**

CHRISTIAN MEDICAL COLLEGE, VELLORE

Department of Endocrine Surgery

Participant Information sheet

Date:_____

We are inviting you to participate in a study called Ultrasound Guided Fine Needle Aspiration Cytology in the Outpatient Department. Your participation in this study is entirely voluntary. Your decision whether or not to participate will have no effect on the quality of medical care you will receive in this hospital

An investigator in this study will explain the purpose of this study including how this study will be carried out and your role in the study. The paragraphs below explain the study. Please ask questions about anything you do not understand, before you decide to participate in this study.

Title of the study

Ultrasound guided fine needle aspiration cytology for thyroid tumors in the outpatient department

What is the purpose of the study?

This study is to improve the adequacy rate of fine needle aspiration cytology and to determine the accuracy of FNAC when compared to final biopsy report.

What does this study involve?

You will undergo a needle test of the thyroid nodule (FNAC) as part of your routine investigation. This FNA sample that is collected is used for studying the structure of the cells

(cytology). In this study ultrasound machine will be used to perform the FNAC from the most suspicious lesion

Are there any benefits from participating in this study?

Ultrasound guidance may help us in improving the adequacy and accuracy of the FNAC. This will help the clinician for further management of thyroid nodule.

What are the risks involved with being enrolled in this study?

The study does not increase your risk in any way and you will receive the same standard of care with/without participating in the study. Ultrasound scan does not involve injections or radiation and it is completely non invasive. Further, you will not have to bear any penalty if you wish to withdraw from this study.

What will you have to do as part of the study?

You will be asked to provide information regarding your age, sex, and presenting complaints. A screening ultrasound scan of your neck will be done followed by an FNAC under the guidance of ultrasound.

Will your personal details be kept confidential?

All the information collected for this study will be kept confidential and patient identity will not be revealed. However, for the sake of improving science, the results may have to be published in national/international journals. If at any point you want to withdraw from the study, you are free to do so. If the above information does not provide answers to your questions, request the investigator to answer them for you. Also this sheet is for your information and you can retain this copy with you.

If you have any further questions, please ask Dr. Siddhartha Chakravarthy N, Endocrine Surgery Registrar (tel: 0416 2282609, 9791439133) or email: sidhu80@gmail.

CHRISTIAN MEDICAL COLLEGE, VELLORE

INFORMED CONSENT FORM

Title of the study:

Ultrasound guided fine needle aspiration cytology for thyroid tumors in the outpatient department

Principal Investigator of the study: Dr.SiddharthaChakravarthy N

Study No.: _____

Participants name:

Date of birth / Age: _____

(Subject)

i. I have read through the details of the study mentioned in the participant information form clearly and/or all my questions regarding my participation have been answered satisfactorily by the investigator.

Yes / No

ii. I understand that my participation in the study is voluntary and that I am free to withdraw at any time, without giving any reason, without my medical care or legal rights being affected.

Yes / No

iii. I understand that the investigators and the Ethics Committee will not need my permission to look at my health records both in respect of the current study and any further research that may be conducted in relation to it, even if I withdraw from the trial. I agree to this access. However, I understand that my identity will not be revealed in any information released to third parties or published.

Yes / No

iv. I agree not to restrict the use of any data or results that arise from this study provided such a use is only for scientific purpose(s) . **Yes / No**

v. I agree to participate in this ultrasound guided fine needle aspiration cytology study. **Yes / No**

Signature (or Thumb impression) of the Subject/Legally Acceptable

Date: _____/_____/_____

Signatory's Name: _____ Signature:

Or

Representative: _____

Date: _____/_____/_____

Signatory's Name: _____

Signature of the Investigator: _____

Date: _____/_____/_____

Study Investigator's Name: _____

Signature of the Witness: _____

Date: _____/_____/_____

Name & Address of the Witness: _____

Annexure 2

- **Data entry form**

US-FNAC DATA

- **Name**
- **Hospital number**

- **Age**

10-20	21-30	31-40	41-50	51-60	>60
1	2	3	4	5	6

- **Sex**

Male	Female
1	2

- **Pre operative Voice change**

Yes	No
1	2

- **Compressive symptoms**

Yes	No
1	2

- **Hyper/hypothyroid symptoms**

Yes	No
1	2

- **Retrosternal extension**

Yes	No
1	2

- **Consistency**

Soft/firm	Hard
1	2

- **Mobility**

Mobile	Restricted/ fixed
1	2

- **Lymph nodal involvement**

Yes	No
1	2

- **Previous neck surgery**

Yes	No
1	2

- **Site of the FNAC**

Right lobe	Left lobe	Isthmus	Lymph node

1	2	3	4

- **Onsite adequacy of FNAC**

- **USG Findings:**
- **Site:**

Right lobe	Left lobe	Isthmus	Lymph node
1	2	3	4

- **Size of nodules**

Site	≤1cm	>1cm	Normal
Right	1	2	3
Left			
Isthmus			

Side	Well circumscribed	Microlobulated	Ill-defined/ irregular
Right	1	2	3
Left			
Isthmus			

- **Number of nodules >1cm**: _____
- **Composition:**

Side	Cystic	Solid	Mixed
Right	1	2	3
Left			
Isthmus			

Yes	No	Cystic
1	2	3

- **Appearance**

Side	Homogenous	Heterogenous
Right	1	2
Left		
Isthmus		

- **Echogenicity:**

Side	Hyperechoic to thyroid	Isoechoic to thyroid	Hypo to thyroid and iso to strap muscles	Markedly hypo compared to straps
Right	1	2	3	4
Left				
Isthmus				

- **Margins:**
- **Halo sign**

Side	**Yes**	No
Right	1	2
Left		
Isthmus		

- **Calcification:**

Side	Micro <1mm	Macro	Micro & macro	Comet tail	No calcification/no comet tail
Right	1	2	3	4	5
Left					
Isthmus					

Side	Taller than wide	Wider than tall
Right	1	2
Left		
Isthmus		

- Lymph nodes:

Side	Present	Absent
Right	1	2
Left		
Isthmus		

- **Usg size**

1-upto 2cm	2-4	4-6	6-8	>8cm
1	2	3	4	5

- Shape:

TIRADS Category	**No. Of USG features**
☐ 1 (Negative) – no thyroid nodule ----------	0
☐ 2 (Benign) – cystic lesion----------	0
☐ 3 (Probably Benign) – hyperechoic solid, complex cyst with no malignant features----------	0
☐ 4a (Low Suspicion for Malignancy)----------	1
☐ 4b (Intermediate)----------	2
☐ 4c (Moderate suspicion for Malignancy)----------	3 or 4
☐ 5 (Highly Suggestive of Malignancy)----------	5

- Features favouring malignancy: microcalcification, irregular or microlobulated margins, hypoechogenicity or markedly hypoechogenic and taller-than-wide shape.
- In mixed lesion – solid component of mixed lesion is evaluated for above features
- **Final adequacy of FNAC**

Yes	No	cystic
1	2	3

- **Fnac adequacy**

Yes	No
1	2

- **Cell block adequacy**

Yes	No
1	2

- **FNAC report of the patient**

Diagnostic category	Patients result (circle the numerical)
Non-diagnostic or Unsatisfactory	1
Benign	2
Atypia of Undetermined Significance or Follicular Lesion	3
Follicular Neoplasm or Suspicious for a Follicular Neoplasm	4
Suspicious for Malignancy	5
Malignant	6
Fluid for cytology	7a : Malignant cells/atypical cells 7b: no malignant or atypical cells

- **Final biopsy of the patients who had thyroidectomy**
- **Maximum size of the tumor**

Side	≤ 1	1-4cm	>4cm
Right	1	2	3
Left	4	5	6
Isthmus	7	8	9

-
- **Side**

Right lobe	Left lobe	Isthmus
1	2	3

- **extrathyroidal extension**

Yes	No
1	2

- **lymphovascular invasion**

Yes	No

1	2

- **lymph nodal involvement**

Yes	No	Not done
1	2	3

- **Final histopathology report of patients who had thyroidectomy**

(Kindly circle the option)

Benign non-neoplastic	Nodular hyperplasia, thyroiditis, colloid goiter, adenomatous hyperplasia, ,	1
Benign neoplastic	follicular adenoma, hurthle cell adenoma	2
Malignant	Papillary carcinoma (PTC)	3
	Follicular carcinoma	4
	Follicular variant of papillary carcinoma of thyroid (FVPTC)	5
	Medullary carcinoma	6
	Anaplastic carcinoma	7
	Poorly differentiated carcinoma	8
	Hurthle cell carcinoma	9
	Lymphoma	10
	Others	11
Predominantly benign with subcentemetric foci of malignancy		12
Follicular lesion of uncertain malignant potential		13

- **<u>Surgery performed</u>**

Total thyroidectomy	1
Hemithyroidectomy	2
Total thyroidectomy+lateral Neck dissection	3
Total thyroidectomy + CCLND	4
Completion thyroidectomy(hemi done in cmc) Completion thyroidectomy(hemi-done outside benign)	5a 5b
Completion thyroidectomy (recurrent mng)	6

Excel sheet

No.	dor	?	FVP	Hosp. No	Age	Sex	Pre	compr	hype	retro	consist	mob	LN	in-	previc	site	F	onsit	usg	l size	ı no	of	compı	appea	echog	marg	halo	calcifi	shap	LN's	SIZE	TIRACAE2	FNAI	CELL	FNAC	fin	SIDE	EXT	LYI	LA	FINAI	sid	fi	surj	soli
1	3			547349X	2	2	2	2	2	2	1	1	2	2	1	2	1	2	2	2	1	2	1	2	1	1	5	2	2	1	3	1	1	1	2b											
2	3			391246F	4	2	2	2	2	2	1	1	2	2	1	2	1	2	2	2	1	2	1	1	4	2	2	2	3	1	1	2	3													
3	3			852576F	4	1	2	2	2	2	1	1	2	2	1	2	1	2	2	3	2	2	1	1	1,4	2	2	2	4a	1	1	1	5	2	1	2	2	2	3		1	2				
4	1			825921	3	2	2	2	2	2	1	1	2	2	1	1	1	2	4	2	2	4	1	1	5	2	2	1	4a	1	1	1	4													
5	1			850241F	2	1	2	2	2	2	1	1	2	2	1	2	1	2	1	2	2	2	1	2	1	2	2	3	4b	1			6	2	1	2	2	1	3		4	1				
6	1			102172F	5	2	2	2	2	2	1	1	2	2	2	1	2	2	1	2	2	2	1	1	1,4	2	2	3	4a	2	2	2	1	2	2			1a			1	2				
7	1			847337F	5	1	1	1	2	1	2	2	2	2	1	1	1	2	2	2	na		3	3	2	1	1	1	4	5	1		6c													
8	1			759803F	6	2	2	1	2	2	1	1	1	2	1	2		2	3	2	2	2	1	1	2	2	2	4A	1			2	1	1	2	2	2	12a		1	2				
9	1			833569F	3	2	2	2	2	2	1	1	2	2	1	2	1	2	1	2	2	3	1	1	1	1	2	4c	1			3													
10	1			850929F	2	2	2	2	2	2	1	1	2	2	1	1	1	2	1	1	na	na		1	1	4	2	2	2	2	1		3													
11	1			855492F	4	1	2	1	2	2	1	1	2	2	1	1	1	2	1	2	2	2	1	1	5	2	2	3	3	1	1	1	2	2	1	2	2	2	5		1	1				
12	1			854318F	2	2	2	2	2	2	1	1	2	1	1	2	2	2	1	2	2	2	1	2	5	2	2	3	3	1			2	3	2			1a			6	2				
13	1			850250F	6	1	2	2	2	2	1	1	2	2	1	3	1	2	2	1				1	1	4	2	2	1	2	3		7b	2	1			1a			1	2				
14	1		1	849979F	4	2	2	2	2	2	1	1	2	2	2	1	2	2	1	2	2	2	1	1	4	2	2	4	4a	1			2	2	2	2	2	3	5		1	1				
15	1			856769f	3	2	2	2	2	2	1	1	2	2	1	1	1	2	1	2	1	4	1	1	4	2	2	2	4b	1		6a	2	1	2	2	2	3		1	1				
16	1			553866A	2	1	2	2	1h		2	1	1	2	2	2	2	2	2	2	2	2	2	2	2	2	2	2	3	1		2a													
17	1			855378F	1	2	2	2	2	2	1	1	2	2	1	1	1	2	2	2	1	4	1	1	5	2	2	2	4a	1			3													
18	1			743824D	3	2	2	2	2	2	1	1	2	2	1	2	1	2	2	1				1	1	2,4	2	2	2	4a	2			1												
19	1			851419F	2	1	2	2	2	2	1	1	2	2	2	2	2	2	1	2	2	2	1	1	5	2	2	4	3	1		2a													
20	1			859003F	5	1	2	1	2	2	2	2	2	2	2	2	2	2	2	2		2	1	2	1	1	2	2	4A	1			3													
21	1			858509F	5	2	2	1	2	2	1	1	2	2	1	1	1	2	4	2	2	4	3	2	1	2	2	1	5	2			1	2	2	2	2	3	5		1	2				
22	1			007715c	5	2	2	2	2	2	1	1	2	2	1	1	1	2	2	2	2	4	2	2	1	2	2	2	4b	1			6	2	1	2	2	3	3		1					
23	1			202585F	3	2	2	1	2	2	1	1	2	2	1	1	1	2	2	2	2	4	1	2	3	2	2	2	4b	2			1	2	1	2	2	3	5		1					
24	1			860391F	5	1	2	2	2	2	1	1	2	2	2	3	2	2	2	1				1	1	4	2	2	3	2	3		7b	2	1			1a			1					
25	1			054436F	3	1	2	1	2	1	1	1	2	2	2	1	2	2	2	2	2a		2	1	1	5	2	2	5	3	1			2	3	1			1a			1				
26	1			510868F	3	2	2	2	2	2	1	1	2	2	2	1	2	2	2	2			1	1	1	5	2	2	3	3	1		2b													
27	3		1	867241F	4	1	2	1	2	2	4	1	2	2	2	2	2	2	1	2	2	2	1	2	1	2	2	3	4a	1			2	2	2	2	2	3	5a		1					
28	3			859074F	3	2	2	2	2	2	1	1	2	2	1	2	1	2	2	2	1	4	2	2	1	2	2	1	4c	1	1	1	5	2	1	2	1	1	3a		4					
29	3		1	873745F	2	1	2	2	1	2	1	1	2	2	1	1	1	2	1	2	2	2	1	2	3	2	2	2	4a	1	1	1	6	2	1	2	2	3	3	1	1					
30	3		1	867607F	2	1	2	1	2	2	1	1	2	2	1	1	1	2	1	2	2	2	1	1	5	2	2	3	3	1			2	3	1	2	2	3	3		1					
31	3			866982F	4	2	2	2	2	2	1	1	2	2	1	1	1	2	1	2	2	2	1	1	5	2	2	2	3	1	2		2													
32	3			872571F	4	2	2	2	2	2	1	1	2	2	1	2	1	2	3	2	2	3	1	2	3	2	2	5	4b	1			3	3	1	2	2	3	5a		1					
33	3			187212D	4	2	2	2	2	2	1	1	2	2	1	1	1	2	1	3	2	2	1	1	5	2	2	1	3	1		2a													
34	3			805360F	4	2	2	2	2	2	1	1	2	2	2	2	2	2	2	3	2	4	1	1	5	2	2	3	4a	1		2a													
35	3			183943C	3	2	2	1	2	2	1	1	1	2	1	2	1	2	2	2	1	4	3	2	1	1	2	1	4c	1			2													
36	3			846179F	3	2	2	2	2	1	1	1	2	2	2	2	2	2	3	3	2	2	1	2	2,4	2	2	2	4a	2			1	2	2	2	2	3	5a		1					
37	1			910088f	4	2	2	1	2	2	1	1	1	2	2	2	2	2	2	2	2	3	3	2	3	2	1	2	5	1			6	2	2	2	2	1	3		4					
38	1			872623F	4	2	2	2	2	2	1	1	2	2	2	1	2	3	2	2	2	2	1	1	4	2	2	2	3	1			5									1				
39	1			882229F	4	2	2	1	2	2	1	1	2	2	3	2	3	2	1	2	2	2	1	1	4	2	2	1	3	1			5									1				
40	1			883833F	2	2	2	1	2	2	1	1	1	2	1	2	1	2	1	3	2	2	1	1	1,4	2	2	2	4a	2			1	2	1	2	2	1	3		4					
41	1		1	391220F	2	1	2	2	2	2	1	1	2	2	2	2	2	2	1	2	2	2	1	1	5	2	2	3	3	2	2	2	1												
42	1			812837F	3	1	2	2	2	2	2	2	2	2	1	1	1	2	1	2	2	3	1	1	3	1	2	1	4c	1			6													
43	1			880672F	3	2	1	2	2	2	1	1	2	2	2	2	2	2	1	2	2	3	1	2	5	2	2	3	4a	2	2	2	1												
44	1			860001F	2	2	2	2	2	2	2	1	2	2	2	1	2	2	2	2	1	3	3	2	1	1	2	2	4c	1	1	1	6	2	2	2	2	1	3a		3					
45	1			511168f	1	2	2	2	2	2	1	1	2	2	1	2	1	2	1	3	2	1	2	2	5	2	2	2	4a	1	2	1	2												
46	1			886911F	6	1	1	1	2	2	2	2	1	2	1	1	1	2	1	2	1	4	3	2	3	1	1	3	5	1		6d	2	1	2	2	1	7		3b					

1

No.	dor	?	FVP	Hosp. No	Age	Sex	Pre	compr	hypo	retro	consist	mob	LN in	previc	site F	onsit	usg	l size	no of	compo	appea	echog	marg	halo	calcifi	shag	LN's	SIZE	TIRA	CAE2	FNA	CELL	FNA(	fin	SIDE	EXT	LYI	LN	FINAI	sid	fr	sur	soli
47	1			102172F	4	2	2	2	2	2	1	1	2	2	2	2	2	2	1	2	2	1	3	2	1,4	2	2	3	4a	2	2	2	1	3	2			1a			1
48	1			877542F	2	2	2	2	2	2	1	1	2	2	1	2	1	2	2	3		2	1	1	4	2	2	2	3	1	1	1	2	2	1			2b			1
49	1			873816F	5	2	2	2	2	2	1	2	2	2	1	1	2	2	2	3	2	3	1	2	3	2	2	1	4a	1	1	1	5	3	2	2	2	1	5			3
50	1			867293F	6	2	2	1	2	2	1	1	2	2	3	1	3	2	2	2	2	2	1	2	1,4	2	2	2	4a	1			3									
51	1			884424F	4	1	2	2	2	2	1	1	2	2	1	2	1	2	1	3	1	2	1	1	1	2	2	2	4a	2	2	2	1									
52	1			880930F	4	2	2	2	2	2	1	1	2	2	2	2	1	2	1	2	2	3	1	1	1,4	2	2	2	4b	2	2	2	1	1	2	2	2	2	3			1
53	1			883347F	5	2	2	1	2	2	1	1	2	2	2	2	2	2	2	3	2	2	3	2	1	1	2	3	4c	1	1	1	2	2	3	1		1a			1
54	1			023949G	4	2	2	2	2	2	1	1	2	2	1	1	1	2	2	3	2	2	1	1	4	2	2	2	2	1	1		2	2								
55	1			025552G	2	2	2	2	2	2	2	1	2	2	1	1	1	2	1	2	2	4	3	2	1	1	2	1	5	1		6A	2	1	2	1	3	3			1
56	1			024476G	2	2	2	2	2	2	1	1	2	2	1	1	1	2	1	3	1	2	1	1	4	2	2	3	3	1			2									
57	1			018910G	5	2	2	2	2	2	1	1	2	2	1	1	1	2	1	2	1	3	1	1	5	2	2	1	4a	1			2									
58	1			026256G	3	1	0	1	2	1	2	2	1	2	1	1	1	2	3	2	1	4	3	2	1	1	1	4	5	1	1	1	6b	3	1	1	1	1	6		3	stern
59	1		1	232666d	5	2	2	2	2	2	1	1	2	2	1	-2	1	2	1	2	2	2	1	1	5	2	2	2	3	1	1	1	2									
60	1			018866G	4	2	2	2	2	2	1	1	2	2	1	1	1	2	1	2	2	3	3	2	3	2	2	1	4c	1			2									
61	1		1	006955g	2	1	2	2	2	2	1	1	2	2	2	1	2	2	1	2	2	2	1	1	5	2	2	2	3	1			2									
62	1		1	014420G	3	1	2	2	2	2	1	1	2	2	1	1	1	2	2	2	2	2	1	1	5	2	2	2	3	1	1	1	5	2	1			2b			1
63	1			005656g	2	2	2	2		2	1	1	2	2	1	1	1	2	2	2	1	2	1	1	4	2	2	4	4a	1	1	1	3							1		
64	1			028746G	4	2	2	1	2	2	1	1	2	2	1	2	1	2	1	3	1	2	1	1	4	2	2	2	3	2	2	2	1									
65	1			071446A	5	2	2	2	2	2	1	1	2	2	2	1	2	2	3	2		2	1	1	4	2	2	1	3	1			2									
66	1			098343D	3	2	2	2	2	2	1	1	2	2	1	1	1	2	3	2		2	1	1	2,4	2	2	2	4a	1	1	1	2	2	1			1a			1
67	1			028818G	6	2	2	1	2	2	1	1	2	2	2	2	2	2	3	2	2	2	3	1	2	2	2	2	4a	2	2	2	1									
68	1			023919G	3	2	2	2	2	2	1	1	2	2	1	2	1	2	1	3	2	2	1	2	5	2	2	2	3	2	2	2	1									
69	1			451555C	5	2	2	2	2	2	1	1	2	2	1	1	1	2	3	3	1	2	1	1	5	2	2	1	3	1	1	2	5	1	1	2	2	3	5			1
70	1			617104F	5	2	2	1	2	2	1	1	2	2	2	1	2	2	1	2	2	2	1	2	4	2	2	2	3	1			2									
71	1			373018D	5	1	2	2	2	2	1	1	2	2	1	2	1	2	1	3	2	2	1	2	2	2	2	3	4a	1	1	2	5									
72	1			014116G	4	2	2	2	2	2	1	1	2	2	2	2	2	2	2	2	1	4	1	1	5	2	2	2	4a	2	2	2	1									
73	1			007444G	5	2	2	1	2	2	1	1	2	2	1	1	1	2	4	2	1	2	1	2	3	2	2	3	4a	1	1	1	2									
74	1			011206G	5	2	2	1	2	2	1	1	2	2	1	2	1	2	1	3	1	2	1	2	4	2	2	2	3	1			2									
75	1			723434D	3	2	2	2	2	2	1	1	2	2	1	2	1	2	2	2		2	1	1	4	2	2	2	3	2	2	2	1									
76	1			297797F	2	1	2	1	2	2	1	1	2	2	2	2	2	2	2	3	2	3	1	2	3	2	2	2	4a	1	1	1	3	2	2	1	2	3	5a			2,5a
77	1			031358G	3	2	2	2	2	2	1	1	2	2	2	2	2	2	2	2	2	4	3	2	1	2	1	3	4c	1	1	1	4	2	2	2	2	3	5a			1
78	1			016470G	3	2	1	1	2	1	1	1	2	2	1	1	1	2	4	2	2	2	1	2	2	2	2	5	4a	1			2	3	1			1a		2	1
79	1			840887F	4	2	2	1	2	2	1	1	2	2	1	1	1	2	2	2	2	2	1	1	5	2	2	2	3	1		2b										
80	1			845354F	3	2	2	1	2	2	2	1	2	2	1	1	1	2	5	2	1	2	1	1	5	2	2	2	3	1			2	2	1			1b			1
81	1			584418C	4	1	2	1	2	2	1	1	2	2	2	2	2	2	2	2	2	2	1	1	2	2	2	1	3	2	2	2	1							2		
82	1			881257F	2	1	2	2	2	2	1	1	2	2	1	1	1	2	1	2	2	2	1	1	5	2	2	2	3	1	1	1	2									
83	1			842153F	3	2	2	1	2	2	1	1	2	2	1	1	1	2	1	2	2	2	1	2	5	2	2	3	3	1			2	2	1	2	2	3	5			1
84	3			027142G	3	2	2	2	1h	2	2	2	2	2	1	1	1	2	4	2	2	4	3	2	1	2	2	1	4c	1		6a										
85	3			057503G	2	2	2	2	2	2	1	1	2	2	1	1	1	2	1	3	2	2	1	2	1	1	2	2	4a	1			5	2	1	2	2	3	3a			1
86	3			976237B	2	1	2	2	1h	2	1	1	2	2	1	1	1	2	2	2	1	4	1	2	5	2	2	2	4a	1			4									
87	1			290676C	3	2	2	2	2	2	1	1	1	2	1	1	1	2	3	2	2	4	3	2	1	1	1	1	5	1			5	2	1	2	1	1	3a			3
88	1			846817F	3	2	2	2	2	2	1	1	2	2	1	1	1	2	2	2	2	2	1	1	5	2	2	2	4a	1			2									
89	1			846903F	2	1	2	1	2	2	1	1	2	2	1	1	1	2	1	3	2	2	1	1	5	2	2	2	4a	2			1	2	1	2	2	3	5			1
90	2	Diffus		c	3	2	2	2	2	2	1	1	2	2	2	1	2	2	d								2	3	2b	1		2b										
91	2			995942C	7	2	2	2	2	2	1	1	2	2	2	2	2	2	2	2	2	1	1	1	3	1	2	2	4a	2	2	2	1									
92	2			440480F	5	2	2	1	2	2	1	1	2	2	3	1	3	2	1	3	2	2	1	2	2	2	2	2	3	2	2	2	1									

2

No.	dor ?	FVP'	Hosp. No	Age	Sex	Pre	compl	hypo	retro	consist	mob	LN in	previc	site F	onsit	usg l	size ı	no of	compı	appea	echog	marg	halo	calcifi	shap	LN's	SIZE	TIRADAE2	FNAI	CELL	FNA(	fin	SIDE	EXT	LYI	LN	FINAI	sid	fı	surg	soli
93	3		916402B	4	1	2	2	2	2	1	1	2	2	2	1	2	2	2	3	2	3	1	1	5	2	2	2	3	1			2									
94	2		808597F	3	1	2	1	2	2	1	1	2	2	1	2	1	2	2	3	2	1	1	2	3	1	2	3	4a	2			1									
95	1		808250F	3	1	2	2	2	2	1	1	2	2	1	1	1	2	2	2	2	2	1	1	2	2	2	1	4a	1			3	3	1	2	2	1	3a			1
96	1		813837F	2	2	2	1	2	2	1	1	2	2	2	1	2	2	2	2	1	1	1	1	4	2	2	2	1	1			2	2	2				1a			1
97	1		843981F	3	2	2	1	2	1	1	1	2	2	2	1	2	2	3	3		2	2	2	4	2	2	1	2	2			1									
98	1		831378F	2	2	2	2	2	2	1	1	2	2	1	1	1	2	1	2	2	2	1	1	5	2	2	1	3	1			2									
99	1		840844F	3	2	2	1	2	2	1	1	2	2	1	1	1	2	2	2	2	3	1	1	5	2	2	2	4b	2	2	2	1									
##	1		836783F	3	2	2	2	2	2	1	1	2	2	2	1	2	2	2	2	1	2	1	1	5	2	2	1	3	1			2									
##	1		828639F	5	2	2	1	2	2	1	1	2	2	1	1	1	2	2	2	2	3	1	2	1	1	2	2	4b	1			2	2	1				1a			1
##	1		796596F	5	1	2	2	2	2	1	1	2	2	2	1	2	2	1	2	1	4	3	2	1	1	2	1	5	1			2	1	2	2	2	3	3a			1
##	3		827952F	7	2	2	2	2h	2	1	1	2	2	2	2	2	2	1	1	1		1	2	4	2	2	2	2	1			2									
##	1		807255F	2	2	2	2	2	2	1	1	2	2	2	2	2	2	1	3		2	1	1	4	2	2	1	2	2			1									
##	1		328332D	3	2	2	2	2	2	1	1	2	2	2	-1	2	2	3	3		2	1	1	2,4		2	2	2	3	2			1									
##	1		831526F	3	1	2	1	2	2	1	1	2	2	1	1	1	2	4	2	2	3	3	2	2	1	2	1	4c	1		6a										
##	1		039720D	3	2	2	2	2	2	1	1	2	2	3	1	3	2	3	2	2	2	1	1	4	2	2	1	4a	1			4									
##	1		834505F	4	2	2	2	2	2	1	1	2	2	3	1	3	2	3	2	1	2	3	2	5	2	2	1	3	1		2b										
##	2		801785F	3	2	2	2	2	2	1	1	2	2	1	2	1	2	2	3	2	3	1	1	1	2	2	2	4a	1	1	1	2									
##	3		603073F	4	2	2	2	2	2	1	1	2	2	2	1	2	2	1	3	2	2	1	2	5	2	2	2	3	1			2									
##	3		813453F	5	2	2	1	2	2	1	1	2	2	2	1	2	2	3	3	2	1	1	1	5	2	2	2	3	1			2									
##	3		833284F	2	2	2	2	2	2	1	1	2	2	1	2	1	2	2	2	2	2	1	2	1	2	2	1	4a	1	1	1	4									
##	3		405759F	4	2	2	1	1	2	2	1	2	2	2	1	1	2	2	2	1	3	1	1	1	2	2	1	4b	1	1	2	4									
##	2		804736F	5	2	1	1	2	2	2	1	2	2	2	1	2	2	1	2	1	4	3	2	1	2	2	2	5	1	1	1	6A	3	2	1	2	1	3a			1
##	2		509862F	4	1	2	1	2	2	1	1	2	2	2	2	2	2	2	3	2	2	1	1	5	2	2	3	3	2	2	2	1									
##	2		809473F	5	2	2	2	2	2	1	1	2	2	2	2	2	2	2	3	2	2	1	1	1	2	2	2	4a	1	1	1	2									
##	2		817148F	4	2	1	2	2	2	1	1	2	2	2	1	2	2	2	3	2	3	1	1	3	2	2	2	4a	1	1	1	2									
##	3		829987F	2	2	2	2	2	2	1	1	2	2	1	1	1	2	1	2	1	4	1	2	5	1	2	1	4c	1	1	1	5	1	1	2	2	3	3			1
##	1		817211f	6	2	2	2	2	2	1	1	2	2	2	2	2	2	2	3	2	2	1	2	3	2	2	2	4a	1		2	2						1a			1
##	1		751543F	5	2	2	2	2	2	1	1	2	2	2	2	2	2	1	3	2	3	3	2	3	2	2	3	4a	2			1									
##	1	1	817214F	4	2	1	2	2	2	1	1	2	2	1	1	1	2	1	2	2	2	1	1	5	2	2	2	3	1			3	2	1	2	2	3	5			1
##	1		828784F	5	2	2	2	2	2	1	1	2	2	2	1	2	2	1	3		3	3	2	3	1	2	1	4c	1			2									
##	1		165260D	4	2	2	2	2	2	1	1	2	2	1	2	1	2	2	3		1	1	1	5	2	2	2	3	1			4	1	1				1b			1
##	1		832669F	5	2	2	1	2	2	1	1	2	2	2	1	2	2	3	2	2	2	3	2	2,4		2	2	2	4b	1			4	2	2				1			1
##	1		820721F	4	2	2	1	2	2	1	1	2	2	2	2	2	2	3	2	2	1	1	2	4	2	2	1	3	1			2									
##	1		259365A	3	1	2	1	2	2	1	1	2	2	2	1	2	2	3	2	2	2	1	1	5	2	2	2	3	2			1	2	2				1e (dyshor			1
##	1		807594F	2	2	2	2	2	2	1	1	2	2	1	1	1	2	1	2	2	1	1	1	5	2	2	2	2	1	1		2	2								
##	3		774603F	4	2	2	2	2	2	1	1	2	2	1	1	1	2	1	3	2	1	1	1	4	2	2	2	4a	2			1									
##	3	1	785490F	6	2	2	1	2	2	2	2	2	2	1	1	1	2	2	2	2	4	3	2	1	1	2	4	5	1	1	1	6a	3	1	2	1	3	3			1
##	3	1	659572F	6	2	2	1	2	2	1	2	2	2	2	2	2	2	1	3	2	2	1	1	5	2	2	2	3	1			2									
##	3		791596F	4	1	2	1	2	2	1	1	2	2	1	1	1	2	1	3	2	2	1	2	5	2	2	2	3	1	1	1	2									
##	3		788477F	4	2	2	2	2	2	1	1	2	2	1	1	1	2	1	3	2	3	1	1	1	2	2	2	4b	1	1	2	2									
##	2		791630F	4	2	2	1	2	2	1	1	2	2	2	1	2	2	2	3	2	2	2	2	3	2	2	2	4b	1			3									
##	3		431666F	2	2	2	1	2	2	1	1	2	2	1	1	1	2	1	2	1	3	2	2	5	2	2	2	4b	1			5	2	1	2	2	1	3a			4
##	2		708166F	4	2	2	2	2	2	1	1	2	2	1	1	1	2	2	3	2	2	1	2	2	2	2	2	3	1	1	1	3									
##	2		792869F	4	2	1	1	2	2	2	2	2	2	1	2	2	2	3	2	2	3	1	2	3	2	1	4	4c	1			6b	3	2	1	1	3	6			1trache
##	2		778979F	4	2	2	2	2	2	1	1	2	2	2	1	2	2	2	2	2	2	1	2	3	1	2	3	4a	1			2									
##	3		689982F	5	1	2	2	2	2	1	1	2	2	3	1	1	2	3	3	2	2	1	2	1	2	2	2	4a	1			2	2	1				1a			1

3

No.	dor	?	FVP'	Hosp. No	Age	Sex	Pre	compr	hype	retro	consist	mob	LN in	previc	site F	onsit	usg f	size (	no of	compc	appea	echog	marg	halo	calcifi	shap	LN's	SIZE	TIRA	CAE2	FNA(	CELL	FNA(	fin	SIDE	EXT	LYI	LN	FINA	sid	fi	surg	soli
##	2			913729D	5	2	2	2	2	2	1	1	2	2	2	1	2	2	3	3	2	1	1	1	5	2	2	2	3	1			2	2	2			1a			1		
##	2			781879F	2	2	2	2	2	1	1	2	2	2	2	1	2	2	1	3	2	3	1	2	2,4	2	2	2	3	2			1											
##	2			745850F	4	1	2	1	2	2	1	1	2	2	1	1	1	2	2	3	2	3	1	1	5	2	2	1	4a	2			1											
##	3		1	780209F	5	2	2	1	2	1	2	2	2	2	1	1	3	2	2	2	1	4	3	2	3	2	2	2	4c	1			6c		2	1	1	2	2	8		1trache		
##	3			780125F	3	2	2	2	2	1	1	1	2	2	1	1	1	2	2	2	2	1	1	1	5	2	2	2	4a	1	1	1	3	2	2			1a			1		
##	1			045020G	4	2	2	2	2	2	1	1	2	2	1	2	1	2	2	3		2	1	1	4	2	2	4	2	2			1	3	1			1a			1		
##	1			9736148	6	2	2	2	2	2	2	1	2	2	1	1	1	2	1	2	1	1	2	2	5	2	2	1	4b	1			6	2	1	2	1	3	3a			1		
##	1		1	878644f	5	2	2	2	2	2	1	1	2	2	1	1	1	2	2	2	2	1	1	1	5	2	2	1	3	1			3											
##	1			803371B	3	2	2	2	2	2	1	1	2	2	1	2	1	2	2	3		2	1	1	4	2	2	1	3	1			2	2	1			1a			1		
##	1			337307	6	2	2	1	2	1	1	1	2	2	2	1	2	2	1	2	2	2	1	1	5	2	2	5	3	1			2											
##	1			042736G	4	1	2	1	2	2	1	1	2	2	2	1	2	2	4	3		1	1	1	5	2	2	2	3	2			1									2		
##	1			043307G	2	2	2	1	2	2	2	1	2	2	2	1	2	2	2	2	1	4	3	2	1	1	2	2	5	1			6a		2	2	2	2	1	3a			3	
##	1			740866B	5	2	2	1	2	2	1	1	2	2	1	·2	1	2		2		2	1	1	5	2	2	2	3	1			2	2	1			1b			1		
##	3			047511G	4	2	2	2	1	2	1	1	2	2	3	2	3	2	4	2	2	1	1	2	5	2	2	1	3	1			2b											
##	1			045433G	3	2	2	1	2	2	1	1	1	2	1	1	1	2	2	3		2	1	2	4	2	2	3	3	1			6	2	1	2	1	1	3	1	3		
##	2			792726F	2	2	2	2	2	2	1	1	2	2	1	2	1	2	1	3	2	3	1	1	1	2	2	3	4a	1			3											
##	1			788659F	5	1	2	1	1	2	1	1	2	2	1	1	1	2	4	3	2	3	1	2	1	2	2	4	3	2			1											
##	2			796730F	3	2	2	2	2	2	1	1	2	2	1	1	1	2	2	3	2	2	1	2	4	2	2	3	3	1	1	1	2											
##	2			057205C	5	2	2	2	2	2	1	1	2	2	2	1	3	2		3	2	2	3	2	3	2	2	1	4b	1			2											
##	2			799781F	2	1	2	2	2	2	1	1	2	2	2	2	2	2	1	3	2	2	1	2	4	2	2	2	3	1	1	2	2	2	2			1a			1		
##	2			772993F	5	2	2	2	2	2	1	1	2	2	2	1	2	2	1	3	2	2	1	2	5	2	2	3	3	1	1	1	2											
##	2			800179F	4	2	2	2	2	2	1	1	2	2	1	1	1	2	1	3	2	2	3	2	2	2	2	2	4b	1	1	2	3	2	1	2	2	3	5		1		
##	1			804215F	5	2	2	2	2	2	1	1	2	2	1	1	1	2		2	2	2	2	2	5	2	2	1	4b	1			3											
##	1			801415F	1	2	2	1	2	2	1	1	2	2	1	1	2	2		1	1	1	1	1	4	2	2	2	4a	1			2											
##	1			788642F	4	2	2	1	2	2	1	1	2	2	1	2	1	2		2	2	2	1	1	5	2	2	4	3	1			2											
##	1			775456F	3	2	2	2	2	2	1	1	2	2	2	1	1	2		3		2	1	1	4	2	2	2	2	1			2											
##	1			793097F	4	2	2	2	2	1	1	2	2	2	2	2	2	2		2	2	2	1	2	4	2	2	1	4a	1	1	2	3											
##	1			017118G	4	2	2	1	2	2	1	1	2	2	2	1	2	2	1	2	1	2	1	1	5	2	2	1	1	1			2b											
##	3			030277G	4	2	2	2	2	2	1	1	2	1	1	1	1	2	2	3	1	2	1	1	5	2	2	3	3	1	1	1	2	3	1			1a			1		
##	1			041750G	3	1	2	1	2	2	1	2	2	2	3	1	3	2	1	2	2	4	1	1	1	2	2	2	4b	1	1	2	2											
##	1			030569G	4	2	2	2	2	2	1	1	2	2	2	1	2	2	2	2		2	1	1	5	2	2	3	2	1			2	3	2			1a			1		
##	1			040363G	3	2	2	2	2	2	1	1	2	2	2	1	2	2	3	2	2	3	3	2	4	1	2	1	4c	1			6a	1	2	2	2	3	3		1		
##	3			064311G	4	2	2	2	2	1	1	1	2	2	2	1	2	2	1	3	2	1	1	1	3	2	2	4	4a	1				4										
##	3			985908D	4	2	2	2	2	2	1	1	2	2	2	1	2	2	1	3		2	1	2	1	2	2	2	4a	1	1	2	2											
##	3			054363G	3	2	2	2	2	2	1	1	2	2	1	3	1	2	1	3	1	2	1	2	5	2	2	2	3	3			2											
##	3			055000G	2	1	2	2	1	2	1	1	2	2	1	1	1	2	1	2	1	4	1	2	5	2	2	2	4a	1	1	1	3											
##	3			810129F	4	1	2	2	2	2	1	1	2	2	1	2	1	2	2	2	1		2	1	2	2	2	2	4a	1	2	1	3											
##	3			374453F	3	2	2	1	2	2	1	1	2	2	1	1	1	2	3	2	2	3	1	2	1	2	1	1	4b	1			5											
##	1			012069G	2	2	2	2	2	2	1	1	2	2	2	2	2	2	2	2	1	3	1	2	5	2	2	2	4a	2	2	2	1											
##	1			049561G	5	2	2	2	2	2	1	1	2	2	1	1	1	2	2	3	1	2	1	1	4	2	2	1	3	1	1	1	3											
##	1			032550G	2	1	1	2	2	2	1	1	1	2	2	1	2	2	1	2	1	4	3	2	1	1	1	1	5	1	1	1	6a	2	2	2	2	1	3		3		
##	1			033184G	5	2	2	1	2	2	1	1	2	2	2	1	2	2		3	2	3	1	2	5	2	2	2	4a	1	1	1	5											
##	1			012457G	5	2	2	2	2	2	1	1	2	2	1	2	1	2	3	2	2	2	1	1	5	2	2	3	3	1	1	1	2	3	1								
##	1			046739g	3	1	2	2	2	2	1	1	2	1	1	1	1	2	1	2	1	3	3	2	5	2	2	2	4a	1			5											
##	1			048832G	2	2	2	1	2	2	2	2	1	2	2	1	2	2	1	2	1	3	3	2	1	1	1	1	5	1	1	1	6a	3	2	1	2	1	3a		3		
##	1			050420G	3	2	2	1	2	2	1	1	2	2	1	1	1	2	1	3	2	2	1	2	5	2	2	2	3	1	1	2	2b											

4

No.	dor	? FVF	Hosp. No	Age	Sex	Pre	compr	hypo	retro	consist	mob	LN in	previc	site F	onsit	usg f	size r	no of	compa	appea	echog	marg	halo	calcifi	shap	LN's	SIZE	TIRACAE2	FNAI	CELL	FNAC	fin	SIDE	EXT	LYI	LN	FINAI	sid	fi	surg	soli
##	1		045313g	4	2	2	2	2	2	1	1	2	2	2	2	1	2	1	2	1	4	3	2	1	2	2	2	5	1	1	1	6									
##	1		264914C	4	2	2	2	2	2	1	1	2	2	2	1	2	2	2	1	1	1	1	1	4	2	2	2	3	3	1	2	7b									
##	1		055224g	2	2	1	2	2	1	1	2	2	1	2	1	2	2	1	3		2	1	2	4	2	2	2	2	1	1	2	2									
##	1		054828G	4	2	2	2	2	2	1	1	2	2	2	1	1	2	1	3	a hom	3	1	1	4	2	2	2	2	1			2	1	2	2	2	3	5a			1
##	1		111587C	2	1	2	2	2	2	1	1	2	2	2	1	2	2		1	1	1	1	2	2	2	2	2	4a	1	1	2	2									
##	1		051142G	2	2	2	2	1b	2	1	1	2	2	2	1	2	2	1	1	1		1	2	5	2	2	2	2	1			2b									
##	1		047116G	4	2	2	1	2	2	1	1	2	2	1	2	1	2	1	3		2	1	1	4	2	2	2	3	1	2		2b									
##	1		049406G	1	2	2	2	2	2	1	1	2	2	2	2	2	2	2	2	1	4	3	2	3	1	2	2	4c	2	2	2	1	2	2			2b		2	1
##	1		052600g	4	2	2	1	2	2	1	1	2	2	2	1	2	2	2	2	2	2	1	2	5	2	2	d	3	1			2b									
##	1		950222a	5	2	2	2	2	2	1	1	2	2	2	2	2	2	2	3		3	1	1	4	2	2	1	2	1	1	2	2									
##	1	1	055405g	2	2	2	2	2	2	1	1	2	2	2	1	2	2	1	2	2	2	1	2	1	2	2	2	4a	1			2	2	2	2	2	3	5			1
##	1		054258g	2	2	2	1	2	2	1	1	2	2	2	1	2	2	2	1	1	1	1	1	4	2	2	2	1	2	2	2	1	2	2			1d				1
##	1		702521A	3	2	2	1	1	2	1	1	2	2	1	1	1	2	1	2	1	4	3	2	5	1	2	1	4c	1			3									
##	1	1	622526f	2	2	1	1	2	2	1	1	2	2	1	2	1	2	1	2	2	3	1	1	5	2	2	2	4a	1	1	1	2	2	1			2a				2
##	3		837119f	2	2	1	1	2	2	1	1	2	2	1	2	1	2	1	2		2	1	1	5	2	2	3	3	2	2	2	1	3	1			1d				1
##	3		026796G	4	2	2	1	2	2	1	1	2	2	1	1	1	2	3	2	2	2	1	1	5	2	2	2	3	1	1	1	2									
##	3		025191D	5	2	2	2	2	2	1	1	2	2	1	2	2	2	2	2	2	3	1	1	5	2	2	2	4a	1	1	1	4									
##	3		030740g	1	2	2	2	2	2	1	1	2	2	2	2	2	2	1	3	2	3	1	1	5	2	2	2	3	1	1	1	2	2	2			1d				1
##	3		4711500	4	2	2	2	2	2	1	1	2	2	2	2	2	2	1	2	2	2	1	1	2	2	2	1	4a	1	1	1	2	2								
##	3		028371G	2	2	2	2	2	2	2	1	2	2	2	1	2	2	2	2	2	3	1	2	1	2	2	2	4b	1	1	1	6a	2	2	2	1	3	3			1
##	3		006907c	6	2	2	2	2	2	1	1	2	2	1	1	1	2	1	3	2	1	1	1	5	2	2	2	3	1	1	2	2	2								
##	3		022322g	3	2	2	2	2	2	1	1	2	2	2	2	2	2	2	2	2	3	1	2		1	2	2	4b	1	1	1	3									
##	3		431422F	3	2	2	2	2	2	1	1	2	2	2	2	2	2	3	3		3	1	1	5	2	2	2	3	1			2	3	2			1a				1
##	3		898279F	3	2	2	1	2	2	1	1	2	2	1	1	1	2	1	2	1	4	3	2	1	1	1	2	5	1			6a	2	1	1	1	1	3			3
##	1	1	056830G	4	2	2	1	2	2	1	1	2	2	1	1	1	2	2	2	1	3	1	2	5	2	2	2	4a	1	1	1	3									
##	3		475156C	3	1	2	1	2	2	1	1	2	2	2	1	2	2		3		3	1	1	5	2	2	2	3	1	1	1	2									
##	3		688913D	3	2	2	2	2	2	1	1	2	2	1	3	1	2	1	3	1	2	3	1	1	1	2	2	4b	3			7b									
##	1		034107G	2	2	2	2	2	2	1	1	2	2	2	3	2	2	1	3	2	3	1	1	4	2	2	1	3	3			7b								1	
##	1	cystic	015262G	4	2	2	2	2	2	1	1	2	2	1	3	1	2	4	1			1	1	2	2	2	2	3	3			7b									
##	3	cystic	474384d	3	2	2	2	2	2	1	1	2	2	2	3	2	2	2	1			2		2	2	2	2	3	3			7b									
##	1		015361G	2	2	2	2	2	2	1	1	2	2	1	3	1	2	2	3	1	2	1	1	4	2	2	3	3	3			7b	3	1			1a				1
##	3		048200G	3	1	2	2	2	2	1	1	2	2	3	1	3	2	1	2	2	2	1	2	1	2	2	2	4a	1			6a	2	3	1	2	2	3			1
##	1		023809g	2	1	2	2	2	2	1	1	2	2	2	3	2	2	1	1	1	1	1	1	4	2	2	5	1	3			7b									
##	3		047621G	5	1	2	2	2	2	2	1	2	2	1	1	1	2	3	3		2	1	2	5	2	2	1	3	1			2									
##	1		036504G	4	1	1	2	2	2	1	1	2	2	2	1	2	2	1	2	2	2	1	1	1	2	2	2	4a	1			3									
##	1		791419F	4	2	2	2	2	2	1	1	2	2	1	2	1	2	2	1		1	1	1	2	2	2	2	2	1			2									
##	1		840512F	4	2	2	1	2	2	1	1	2	2	1	1	1	2	1	2	2	3	3	2	4	2	2	3	4b	2			1									
##	3		023122g	3	2	2	2	2	2	1	1	2	2	1	1	1	2	3	2	1	4	1	2	1	2	2	2	4b	1		2	5	2	2	2		3a				1
##	1		224329F	3	2	2	2	2	2	1	1	2	2	1	1	1	2	2	2	1	2	1	1	5	2	2	2	3	1			3	2	1	2	2	3	5			1
##	1		892236F	4	2	2	2	2	2	1	1	2	2	2	1	2	2	2	2	2	2	1	2	5	2	2	3	3	1			2									
##	1		039279G	4	2	2	1	1	2	1	1	2	1	1	1	1	2	2	3	1	1	1	1	5	2	2	4	2	1			3									
##	1		041214G	2	2	2	1	2	2	1	1	2	2	2	2	2	2	2	2	1	2	1	1	5	2	2	2	1	2	2	2	1									
##	3		021271G	3	2	1	2	2	2	1	1	2	2	2	1	2	2	1	2	2	2	1	2	2	2	2	2	4a	1			2	2	2	2	2	3	12			1
##	1		035619G	2	2	2	2	2	2	1	1	2	2	1	1	1	2	2	2	1	4	1	1	5	2	2	2	4a	1	1	1	4									
##	1		847415F	4	2	2	1	2	2	1	1	2	2	1	2	1	2	2	3		2	1	1	4	2	2	2	3	1			2									
##	1		881472F	6	1	2	2	2	1	1	2	2	2	2	1	2	2	1	2	1	4	3	2	3	1	1	1	4c	1			6c									

5

No.	dor ?	FVP'	Hosp. No	Age	Sex	Pre	compr	hype	retro	consist	mob	LN in	previc	site F	onsit	usg	l size	no of	compa	appea	echog	marg	halo	calcifi	shag	LN's	SIZE	TIRADA	E2	FNAI	CELL	FNAI	fin	SIDE	EXT	LYI	LN	FINAI	sid	fi	surg	soli
##	3		892064F	5	2	1	1	2	1	2	2	2	2	1	1	1	2	1	2	2	4	3	2	3	2	2	4	5	1			6a	3	1	1	1	3	3a			1
##	1		895000F	3	2	2	1	2	2	1	1	2	2	1	2	1	2	2	2	2	2	1	2	1	2	2	2	4a	2	2	2	1	3	1				1d			1
##	1		216495D	3	2	2	2	2	1	1	2	2	2	2	2	2	2	1	3	2	3	1	1	5	2	2	4	4a	1	1	1	2	3	2	2	2	3	5			1
##	1	1	605981B	4	2	2	1	2	1	1	1	2	2	2	1	2	2	2	2	2	2	1	2	5	2	2	3	3	1			4	3	2				13			1
##	1		881046F	4	2	2	1	2	2	1	1	2	2	2	2	2	2	1	2	1	2	1	2	5	2	2	2	1	2			1										
##	1		881274F	4	2	2	2	2	2	1	1	2	2	1	2	1	2	3	2	1	1	1	1	4	2	2	2	3	1			4										
##	1	1	886368F	2	2	2	1	2	2	1	1	2	2	2	3	2	2	1	3		1	1	1	5	2	2	2	3	3			7b										
##	1		880071F	4	2	2	1	2	2	1	1	2	2	2	2	2	2 d		2	2						2 d		2	1			2b										
##	1		883197F	2	2	2	2	2	2	1	1	2	2	2	1	2	2	3	3		3	2	1	4	2	2	1	3	1				2										
##	1		510889F	5	2	2	2	2	2	1	1	2	2	1	3	1	2	1	1			1	1	5	2	2	2	2	3			7b										
##	1		881333F	4	2	2	2	2	2	1	1	2	2	1	3	1	2	1	1			1	1	4	2	2	2	2	3			7b						12			1	
##	3		829560F	5	2	2	2	2	2	1	1	2	2	1	2	1	2	2	3		2	1	1	4	2	2	1	3	2	2	2	1										
	3		881202F	2	2	2	2	2	2	1	1	2	2	1	3	1	2	1	1			1	1	4	2	2	2	2	3			7b	2	1			1a				2	
##	3		078184F	3	2	2	2	2	2	1	1	2	2	2	1	2	2	1	1		2	1	1	4	2	2	2	2	1			2a										
##	3		877876F	4	2	2	2	2	2	1	1	2	2	3	1	3	2	1	2	1	2	1	1	4	2	2	1	3	1	1	1	2										
##	3		886588F	1	2	2	2	2	2	1	1	2	2	1	1	1	2	1	2	2	3	1	2	1	1	2	2	4c	1	1	1	2	2										
##	3		886805F	5	2	2	2	2	2	1	1	2	2	1	2	1	2	1	3	2	2	1	2	5	2	2	3	3	1	1	2	2a										
##	3		844176F	5	2	2	1	2	2	1	1	2	2	1	3	1	2	3	1		2	1	1	4	2	2	2	2	3			7b										
##	3		894585f	3	1	2	2	2	1	1	1	2	2	2	2	2	2	1	2	2	2	3	2	1	2	2	5	4b	2			1	2	1			1d				1	
##	3		894560F	2	2	2	1	2	2	1	1	2	2	1	1	1	2	1	2	2	4	3	2	1	2	1	2	4c	1			6a	3	1	2	2	3	3			1	
##	3		864737F	3	2	2	2	2	2	1	1	2	2	1	2	1	2	1	2	2	2	1	1	5	2	2	2	3	2	2	2	1										
##	1		373812F	4	2	2	2	2	2	2	1	2	2	1	1	1	2	2	2	2	4	3	2	3	2	2	2	5	2			1	2	1	2	2	3	3a			1	
##	3		892232F	5	2	2	2	2	2	1	1	2	2	2	2	2	2	1	2	2	2	3	2	5	2	2	2	4a	2			1	2		2	2	3	5			2, 5a	
##	1		895434F	3	2	2	1	1	2	1	1	2	2	1	1	1	2 d									2	d	1	1			2										
##	3		873706F	2	2	2	2	1	2	1	1	2	2	2	3	2	2	1	1			1	1	4	2	2	2	2	3			7b	1	2	2	2	3	12			1	
##	1		705287F	2	2	2	2	2	2	1	1	2	2	1	1	1	2	1	2	1	2	1	1	5	2	2	2	3	1				2	2	1	2	2	3	5a			1
##	3		835009F	2	1	2	2	2	2	1	1	2	2	1	1	1	2	1	2	2	2	1	1	4	2	2	2	3	1	1	2	2										
##	1		960880A	4	2	2	1	2	2	1	1	2	1	1	1	1	2	2	3		3	1	2	4	2	2	1	4a	1			2	1	1	2	2	3	12a			1	
##	1		887977F	2	2	2	2	2	2	1	1	2	2	1	1	1	2	1	3	1	2	1	1	4	2	2	3	3	1			3	3	1	2	2	3	5			1	
##	1		578875D	4	2	2	2	2	1	1	2	2	2	2	2	2	2	6	3	2	2	1	2	3	1	2	4	2	2		1	1										
##	1		888418F	4	1	2	2	2	2	1	1	2	2	1	1	1	2	1	2	1	2	1	1	1	2	2	3	4a	1			3										
##	3		002942G	3	2	2	2	2	2	1	1	2	2	3	1	3	2	2	2	2	3	3	2	1	1	2	2	5	1			6	2	3	2	2	3	3			1	
##	3		837868F	5	1	2	2	2	1	1	1	2	2	1	2	1	2	2	2	2	2	1	2	5	2	2	2	3	2	2	2	1	2	1			1a				1	
##	3		004382G	2	2	2	1	2	2	1	1	2	2	1	1	1	2	1	2	2	4	3	2	1	1	2	1	4c	1			4	1	1	2	2	3	3			1	
##	3		890603F	4	2	2	1	2	2	2	1	2	2	1	1	1	2	2	2	2	3	2	1	1		2	2	4c	1			6										
##	1		892928F	2	2	2	1	2	2	1	1	2	2	1	3	1	2	1	3	1	2	1	1	1	1	2	2	4b	3			7b										
##	1	1	004812G	3	1	2	2	2	2	1	1	2	2	1	2	1	2	1	2	2	2	1	1	5	2	2	3	3	2	2	2	1	3	1			2b				1	
##	1		891746F	4	2	2	2	2	2	2	2	2	2	1	2	1	2	2	2	2	3	2	2	3	2	2	1	4c	1	1	1	3										
##	1		897559F	1	2	2	2	2	2	1	1	2	2	2	1	2	2	1	2	1	3	1	1	5	2	2	2	4a	1	1	1	2	1	1	2	2	1	12			1	
##	1		002267G	4	1	2	2	2	2	2	1	2	2	1	1	1	2	3	2	2	2	3	2	3	1	2	3	4c	1	1	2	2	3	1			1a				1	
##	1	cystic	513280C	3	2	2	2	2	2	1	1	2	2	1	3	1	2	3				1					2	1	3	3			7b										
##	3		509628F	2	2	1	2	2	1	1	1	2	2	2	2	1	2	1	2	2	4	2	1	2	2	2	3	4c	1	1	1	2b										
##	3		899049F	5	2	2	1	2	2	2	2	1	2	1	1	1	2	1	2	2	4	3	2	1	1	1	2	5	1			6	3	1	2	2	1	6			3	
##	1		014622G	3	2	2	2	2	2	1	1	2	2	1	1	1	2	1	3	1	2	1	1	5	2	2	2	3	1			3	2	1	2	2	1	5a			1	
##	1		855772D	5	2	2	2	2	2	1	1	2	2	2	1	2	2	1	1	1	1	1	1	4	2	2	1	1	1			2	2	2			1c				2	
##	1		013143G	3	2	2	2	2	1	1	1	2	2	2	2	2	2	2	2	2	2	1	2	2	2	2	2	4a	1			3								2		

6

No.	dor	?	FVP'	Hosp. No	Age	Sex	Pre	compr	hypo	retro	consist	mob	LN in	previc	site F	onsit	usg l	size	no of	compr	appea	echog	marg	halo	calcifi	shap	LN's	SIZE	TIRA	CAE2	FNA	CELL	FNA	fin	SIDE	EXT	LYI	LN	FINAI	sid	fi	surg	soli
##	1			014171G	3	1	2	1	2	2	1	1	2	2	1	1	1	2	1	2	2	4	1	2	1	1	2	3	4c	1	1	2	6a	2	1	2	2	3	3			1
##	1			122563D	4	2	2	1	2	2	1	1	2	2	1	1	1	2	2	2	2	2	1	1	1	1	2	2	4B	1			3	2	1			2B				1
##	1			520274b	5	2	2	1	2	1	1	1	2	2	2	1	2	2	2	2	2	2	2	2	3	1	2	3	4C	2	2	2	1								2		
##	1			505221F	4	2	2	2	2	2	1	1	2	2	3	1	3	2	3	2	1	3	1	2	3	2	2	1	4c	1	1	2	4								2		
##	3			682874d	2	2	2	2	2	2	1	1	2	2	2	1	2	2	1	2	1	3	2	2	2	2	2	3	4b	1			3	3	3			2a				1
##	3			717265f	3	2	2	2	2	2	1	1	2	2	2	1	2	2	1	2	3	4	1	2	1	2	2	2	4b	1			4	2	2	1	2	3	3			1
##	3			306755f	3	2	2	2	2	2	1	1	2	2	1	2	1	2	1	3	2	1	1	1	5	2	2	2	3	1	2	1	2										
##	3			749777f	2	2	2	2	1	2	1	1	2	2	1	1	1	2	1	2	1	4	3	2	3	2	2	2	4c	1			5	1	1	2	2	1	3a			3
##	3			745799f	4	2	2	2	2	2	2	2	1	2	2	1	2	2	2	3	3	3	2	1	1	2	1	3	4c	1	1	1	5	3	2	2	2	2	3a			3
##	3			798589c	4	2	2	2	2	2	1	1	2	2	2	1	2	2	2	3	2	3	1	2	5	2	2	1	4a	1	1	2	2										
##	3			768333f	3	2	2	2	2	2	1	1	2	2	2	2	1	2	2	1	3	3	1	2	5	2	2	2	4a	2	2	2	1										
##	3			725307f	5	1	2	2	2	2	1	1	2	2	1	1	1	2	1	2	3	2	1	2	1	2	2	2	4b	2			1										
##	3			853747f	5	2	2	2	2	2	1	1	2	2	1	·1	1	2	1	3	2	2	1	2	5	2	2	2	3	1	1	1	2										
##	3			893218f	4	2	2	2	2	1	1	1	2	2	1	2	1	2	2	3	1	1	1	1	5	2	2	2	2	2	2	2	1										

7