CLINICAL EVALUATION OF LATERAL PEDICLE GRAFT STABILIZED WITH CYANOACRYLATE AND RESORBABLE SUTURES – A RANDOMIZED CONTROLLED TRIAL

A Dissertation submitted in

partial fulfillment of the requirements

for the degree of

MASTER OF DENTAL SURGERY

BRANCH – II

PERIODONTOLOGY

THE TAMILNADU DR. M.G.R. MEDICAL UNIVERSITY

CHENNAI – 600 032

2014 – 2017

DECLARATION BY THE CANDIDATE

I hereby declare that this dissertation titled **"CLINICAL EVALUATION OF LATERAL PEDICLE GRAFT STABILIZED WITH CYANOACRYLATE AND RESORBABLE SUTURES – A RANDOMIZED CONTROLLED TRIAL"** is a bonafide and genuine research work carried out by me under the guidance of **Dr.C.S.PRABHAHAR., M.D.S., Professor, Head of the Department,** Department of Periodontology, Best Dental Science College, Madurai – 625104.

Dr.M.JEEVITHA

CERTIFICATE BY THE GUIDE

This is to certify that **Dr.M.Jeevitha** Post Graduate student (2014 – 2017) in the Department of Periodontology, Best Dental Science College, Madurai has done this dissertation titled **"CLINICAL EVALUATION OF LATERAL PEDICLE GRAFT STABILIZED WITH CYANOACRYLATE AND RESORBABLE SUTURES – A RANDOMIZED CONTROLLED TRIAL"** under my direct guidance and supervision in partial fulfillment of the regulations laid down by The Tamil Nadu Dr.M.G.R Medical University Chennai – 600032, in Periodontology (Branch II) for M.D.S Degree Examination.

Dr.C.S.Prabhahar., M.D.S.,

Professor and Guide

Head of the Department

Department of Periodontology

Best Dental Science College,

Madurai-625104.

PROFESSOR & H.O.D.,
DEPT. OF PERIODONTICS
BEST DENTAL SCIENCE COLLEGE
MADURAI-625 104

ENDORSEMENT BY HEAD OF THE DEPARTMENT AND HEAD OF THE INSTITUTION

This is to certify that the dissertation titled **"CLINICAL EVALUATION OF LATERAL PEDICLE GRAFT STABILIZED WITH CYANOACRYLATE AND RESORBABLE SUTURES – A RANDOMIZED CONTROLLED TRIAL"** is a bonafide research work done by **Dr.M.JEEVITHA** Post Graduate student (2014 - 2017) in the Department of Periodontology under the guidance of **Dr.C.S.PRABHAHAR., M.D.S., Professor and Guide,** Department of Periodontology, Best Dental Science College, Madurai – 625104.

Dr.C.S.PRABHAHAR., M.D.S.,
Professor and Head of the Department
Department of Periodontology
Best Dental Science, Madurai.

PROFESSOR & H.O.D.,
DEPT. OF PERIODONTICS
BEST DENTAL SCIENCE COLLEGE
MADURAI-625 104

Dr. K.VIJAYALAKSHMI., M.D.S.,
Principal,
Best Dental Science College,
Madurai.

BEST DENTAL SCIENCE COLLEGE
RUN BY ULTRA TRUST
MADURAI.

PRINCIPAL
BEST DENTAL SCIENCE COLLEGE
MADURAI-625104

ACKNOWLEDGEMENT

"Like fire in a piece of flint, Knowledge exists in the mind.

Suggestion is the friction which brings it out"

- *Swami Vivekananda*

Firstly, I thank **the Almighty** for blessing strength and amazing grace to finish up this work.

It is with utmost pleasure I thank all those who lended me a helping hand throughout my study course and preparing this dissertation.

I am very much thankful to the honorable Chairman, Prof.**Dr.K.R.Arumugam., M.Pharm.,** and honorable Vice Chairman, Prof.**Dr.A.Babu Thandapani., M.Pharm.,Ph.D.,** for providing facilities and encouragement to do this work

I owe a deep debt of gratitude to my Principal **Dr.K.Vijayalakshmi., M.D.S.,** and Vice Principal **Dr.V.Premkumar., M.D.S.,** Best dental science college, Madurai for their constant strategic support and encouragement.

I express my profound sense of gratitude and respect to my teacher and research guide, **Dr.C.S.Prabhahar., M.D.S.,** Professor and Head, Department of Periodontics, for his valuable support and guidance to accomplish this work. His immense knowledge and perseverance has always been the guiding force in realizing my goals in time.

I express my deepest gratitude to ever inspiring teacher Prof.**Dr.M.Narendra Reddy., M.D.S.,** for the vision and foresight which inspired me to conceive this project. I sincerely thank him for his concern, motivation and support throughout the project.

I express my heartfelt gratitude to my esteemed teacher **Dr.V.K.Vijay., M.D.S., M.B.A., (HM)** for the dynamic motivation and suggestions that helped me to complete this task. I must especially record the selfless spirit with which he bore a heavy load of responsibilities and risks on my behalf.

I am very much grateful to my senior lecturers, **Dr.M.Umayal., M.D.S.,** and **Dr.M.Navarasu., M.D.S.,** for the continuous support and helping me throughout the period of study. Without them this work would have not been possible.

This is the time to remember my esteemed professors **Dr.V.Shivakumar., M.D.S.,** and **Dr.Flemingson Lazarus., M.D.S.,** for their scholarly supervision, critical evaluation and encouragement in the initial part of the study.

I extend my deep felt gratitude to **Dr.Sudharson., M.D.S.,** and **Dr.Vel Latha., M.D.S.,** for their guidance and encouragement in the initial part of the academic training.

I am thankful to my biostatistician, **Mrs.V.Divyadharshini Elavarasan, M.Sc.,** for helping me to prepare the statistical data for this study.

This is an opportunity to remember my colleague **Dr.S.P.Brindha Devi** and my beloved juniors, **Dr.R.Nivetha, Dr.K.B.R.Ramyakumari, Dr.T.Suganya Harshni** and **Dr.V.Benedict** for their selfless and untiring help from time to time.

I would like to thank the **non-teaching staffs** of the department, who have helped me directly or indirectly in the making of this dissertation.

Words are nothing but just a medium to express love to my parents, **D. Manicka Vasagam** and **M.Dhanalakshmi** and my sister, **M.Karthika Mukesh** for being my pillars of strength, and for their constant support, prayers and inspiration throughout my project.

I am indebted to my beloved friend **Dr.D.Ahila** for her contribution and efforts which have played an important role in different aspects of my academic training.

I thank all the participants of the study who wilfully offered their cooperation in the successful completion of this study.

A full scale acknowledgment note would fill many pages, and thus my sincere apologies for obvious omissions.

DECLARATION

TITLE OF DISSERTATION	CLINICAL EVALUATION OF LATERAL PEDICLE GRAFT STABILIZED WITH CYANOACRYLATE AND RESORBABLE SUTURES – A RANDOMIZED CONTROLLED TRIAL
PLACE OF STUDY	BEST DENTAL SCIENCE COLLEGE, MADURAI – 625104.
DURATION OF THE COURSE	3 YEARS
NAME OF THE GUIDE	DR.C.S.PRABHAHAR., M.D.S.,
HEAD OF THE DEPARTMENT	DR.C.S.PRABHAHAR., M.D.S.,

I hereby declare that no part of the dissertation will be utilized for gaining financial assistance/any promotion without obtaining prior permission of the Principal, Best Dental Science College, Madurai – 625104. In addition, I declare that no part of this work will be published either in print or in electronic media without the guide who has been actively involved in dissertation. The author has the right to reserve for publish of work solely with the prior permission of the Principal, Best Dental Science College, Madurai – 625104.

HOD

PROFESSOR & H.O.D.,
DEPT. OF PERIODONTICS
BEST DENTAL SCIENCE COLLEGE
MADURAI-625 104

GUIDE

PROFESSOR & H.O.D.,
DEPT. OF PERIODONTICS
BEST DENTAL SCIENCE COLLEGE
MADURAI-625 104

Signature of the Candidate

This agreement herein after the "Agreement" is entered into on this day of 30/12/2016 between the Best Dental Science College represented by its Principal having address at Best Dental Science College, Madurai-625104.(Hereafter referred to as "the college")

And

Dr.C.S.PRABHAHAR M.D.S., aged 44 years working as Professor and Head of the Department at the college, having residence address at 9/3, Vallalar street, Alagappapuram, Karaikudi-630002, Sivagangai district, Tamil Nadu. Herein after referred to as the Principal Investigator.

And

Dr.M.JEEVITHA aged 25 years studying as postgraduate student in the Department of Periodontics in Best dental science college. Herein after referred to as the PG/Research student and co-investigator.

Whereas PG/Research student as part of her curriculum undertakes to research **"Clinical evaluation of lateral pedicle graft stabilized with cyanoacrylate and resorbable sutures – a randomized controlled trial"** for which purpose PG/Principal Investigator shall act as Principal Investigator and the college shall provide requisite infrastructure based on availability and also provide facility to the PG/Research student as to the extent possible as a co-investigator.

Whereas the parties, by this agreement have mutually agreed to the various issues including in particular the copyright and confidentiality issues that arise in this regard.

Now this agreement witnesseth as follows:

1.The parties agree that all the Research material and ownership therein shall become the vested right of the college, including in particular all the copyright in the literature including the study, Research and all other related papers.

2. To the extent that the college has legal right to do go, shall grant to license or assign the copyright do vested with it for medical and or commercial usage of interested persons/entities subject to a reasonable terms/conditions including royalty as deemed by the college.

3. The royalty so received by the college shall be shared equally by all the parties.

4. The PG Student and Principal Investigator shall under no circumstances deal with the copyright, Confidential information and know – how generated during the course of research / study in any manner whatsoever, while shall sole vest with the college.

5. All expenses pertaining to the research shall be decided upon by the principal investigator/co-investigator or borne sole by the PG/Research student (co-investigator)

6. The college shall provide all infrastructure and access facilities within and in other institutes to the extent possible. This includes patient interactions, introductory letters, recommendation letters and such other acts required in this regard.

7. The Principal Investigator shall suitably guide the student Research right from selection of the Research Topic and Area till its completion. However the selection and conduct of research, topic and area research by the student researcher under guidance from the principal investigator shall be subject to the prior approval, recommendations and comments of the Ethical Committee of the college constituted for this purpose.

8. It is agreed that as regards other aspects not covered under this agreement, but which pertain to the research undertaken by the student Researcher, under guidance from the Principal Investigator, the decision of the college shall be binding and final.

9. If any dispute arises as to the matters related or connected to this agreement herein it shall be referred to arbitration in accordance with the provisions of the arbitration and conciliation Act, 1996.In witness whereof the parties herein above mentioned have on this the day month and year herein above mentioned set their hands to this agreement in the presence of the following two witness.

Principal

PRINCIPAL
BEST DENTAL SCIENCE COLLEGE
MADURAI-625104

PG Student

Student guide

PROFESSOR & H.O.D.,
DEPT. OF PERIODONTICS
BEST DENTAL SCIENCE COLLEGE
MADURAI-625 104

Witnesses

1. (Dr. UMAYAL. M)

2. M. Navaraju (M. NAVARASU)

COPYRIGHT

DECLARATION BY THE CANDIDATE

I hereby declare that The Tamil Nadu Dr. M.G.R Medical University, Tamil Nadu shall have the rights to preserve, use and disseminate this research in print or electronic format for academic / research purpose.

Signature of the Candidate

(Dr.JEEVITHA.M)

Date: 30/12/2016

Place: MADURAI

ABBREVIATIONS

HCl	Hydrochloric acid
pH	Potential of hydrogen
SCRF	Semilunar coronally repositioned flap
NBC	N-butyl-cyanoacrylate
EDTA	Ethylenediaminetetraacetic acid
SEM	Scanning electron microscope
FGG	Free gingival graft
UNC	University of North Carolina
PI	Plaque index
GI	Gingival index
PPD	Probing pocket depth
CAL	Clinical attachment level

RD	Recession depth
RW	Recession width
TKG	Thickness of keratinized gingiva
HKG	Height of keratinized gingiva
CEJ	Cementoenamel junction
MGJ	Mucogingival junction
NSAID	Nonsteroidal anti-inflammatory drug
SPSS	Statistical package for the social sciences

TABLE OF CONTENTSLIST OF FIGURES

LIST OF TABLES

LIST OF GRAPHS

TABLE OF CONTENTS

Introduction

INTRODUCTION

In the world of periodontics, root coverage procedures, materials, and surgical researches have advanced tremendously. These advances have produced an abundance of studies in the process. A denuded root is more susceptible to caries and tooth hypersensitivity and has compromised esthetics. Several factors are associated with marginal gingival tissue recession and its etiology is complex.

Wennstrom (1996) have been postulated that the following risk factors play a role in the etiology of gingival recession: Tooth malposition, path of eruption, profile and position in the arch, tooth shape, muscle attachment and frenal pull, alveolar bone dehiscence, iatrogenic restorative or operative treatment, periodontal disease and treatment, improper oral hygiene methods, other self-inflicted injuries (e.g. oral piercing).[1]

In the past, indications for treatment of gingival recession consisted in halting progressive recession, enhancing plaque control, decreasing frenum pull, preserving a band of keratinized gingiva and preventing post-orthodontic and post-prosthetic marginal tissue recession. The objectives were then modified not only to prevent a disease process but also attempts have been occasionally made to cover denuded roots and to regenerate a lost tissue.

Since the middle of 20th century, different techniques have been developed to cover the denuded roots.[2] Different surgical procedures have been proposed to improve clinical parameters such as recession depth, width of keratinized gingiva and clinical attachment level without any residual periodontal pocket. These procedures can be

divided into three main groups: pedicle soft tissue grafts, free soft tissue grafts and regenerative techniques.[3]

In patients with esthetic request where there is adequate keratinized tissue lateral to the recession defect, pedicle flap technique, namely lateral sliding flap is recommended.[4-7] **Grupe and Warren** first described the sliding flap as a method to repair isolated gingival defects (1956). They reported elevating a full-thickness flap one tooth away from the defect and rotating it to cover the recession. The advantage of the pedicle graft is the presence of its own blood supply from the wide base of the flap that will nourish the graft and also facilitate reestablishment of vascular anastomoses at the recipient site during the healing phase.[8] The laterally positioned flap will be healing with an attachment to the exposed root which may be a connective tissue attachment, a long junctional epithelium, or a combination of the two.[9] Coverage of the exposed root surfaces with this technique has varied from 60% to 72%.[10,11]

Proper stabilization of flap margin in its desired position is a very much important factor that influence the success of the surgical outcome.[12] Close postoperative adaptation of the flap onto the denuded root surface and the maintenance of this adaptation for a period of time determines the reestablishment of a healthy dentogingival unit.[13] Wound healing depends primarily on early formation and organization of the blood clot that is resistant to mechanical forces acting on the flap.[12] Impaired clot adhesion may weaken the tensile strength of the wound and leave the root surface–gingival flap interface susceptible to tearing compared with tensile forces arising physiologically on wound margins.[14] Such rupture between the flap and participating wound surfaces may be the

result of naturally occurring tensile forces or a developing tissue edema if postoperative flap stability cannot be guaranteed.[12]

Materials like silk, nylon, catgut and polyglycolic-polylactic acid derivatives are being used for the post-operative closure of the flaps.[13] Silk sutures are prone to colonization by biofilms, so called the phenomenon of 'wicking' and may act as a reservoir of secondary infection. Hence, silk should not be applied for prolonged periods of time.[12,13] In current periodontal surgical practice, synthetic threads are predominantly employed. The advantages of synthetic sutures are their stable physical properties and, once placed in situ, their biocompatibility.[12]

The use of tissue adhesives as an alternative to sutures in wound closure and stability of the flap for an adequate period of time has long been an area of clinical interest. The adhesive properties of alkyl-2-cyanoacrylates were discovered in 1959.[15] More recent studies have focused on non-toxic higher homologues such as the butyl form of cyanoacrylates. N-butyl-2-cyanoacrylate has a wide range of applications in health-related settings which fulfills most of the properties required for its use as tissue adhesive material.[16] It has been reported to offer advantages, such as effective and immediate hemostasis, bacteriostatic properties, ease of application and rapid adhesion to hard and soft tissues.[17]

Stability of the laterally positioned flap is critical for accomplishing successful root coverage. The present study was undertaken to evaluate the clinical outcomes of lateral pedicle graft stabilized by using either of the two different stabilization methods, cyanoacrylate tissue adhesive or resorbable sutures.

Aim & Objectives

AIM AND OBJECTIVES

AIM

The aim of the present study is to evaluate the clinical outcomes of lateral pedicle graft stabilized with cyanoacrylate and resorbable sutures.

OBJECTIVES

- To compare the parameters like plaque index, gingival index, recession width, recession depth, thickness and height of keratinized gingiva when lateral pedicle graft stabilized with cyanoacrylate tissue adhesive and resorbable sutures.
- To evaluate and compare percentage of root coverage at the end of 3 months when lateral pedicle graft stabilized with cyanoacrylate tissue adhesive and resorbable sutures.

Review of Literature

REVIEW OF LITERATURE

GINGIVAL RECESSION

Gingival recession can be defined as the location of the gingival margin apical to the cementoenamel junction.[18] By clinical definition, recession is exposure of the root surface by an apical shift in the position of the gingiva.[19]

The etiology of gingival recession is multifactorial. The most significant factors which cause gingival recession are improper oral hygiene measures, plaque induced inflammation, high frenal attachment, tooth malpositions, restorative iatrogenic factors, traumatic occlusion and uncontrolled orthodontic movements.[20]

Classification of gingival recession

a) **Sullivan and Atkins (1968)**[21] classified gingival recession into four categories

- Deep-wide
- Shallow-wide
- Deep-narrow
- Shallow-narrow

b) **Miller (1985)**[22] expanded this classification for gingival recession taking into account the nature and quality of gingival recession and its relationship to the adjacent interproximal tissue height.

- Class I- Marginal tissue recession does not extend to the mucogingival junction. There is no loss of bone or soft tissue in the interdental area. This type of recession can be narrow or wide.
- Class II- Marginal tissue recession extends to or beyond the mucogingival junction. There is no loss of bone or soft tissue in the interdental area. This type of recession can be subclassified into wide and narrow.

- Class III- Marginal tissue recession extends to or beyond the mucogingival junction. There is bone and soft tissue loss interdentally or malpositioning of the tooth.
- Class IV- Marginal tissue recession extends to or beyond the mucogingival junction. There is severe bone and soft tissue loss interdentally or severe tooth malposition.

Lateral pedicle graft

The term 'periodontal plastic surgery', first suggested by **Miller (1988),** is defined as 'surgical procedures performed to correct or eliminate anatomic, developmental or traumatic deformities of gingiva or alveolar mucosa'.

The pedicle graft was the first periodontal plastic surgery procedure proposed by **Grupe and Warren (1956)** for root coverage. They developed an original and unique procedure called the lateral sliding operation for covering an isolated exposed root. It was first described as the 'lateral sliding flap'. It involved moving a full-thickness flap to the mucogingival junction, after which a partial-thickness flap was raised.[23] The procedure was then modified and named as the 'laterally positioned flap'.

Advantages:

- One surgical site.
- Good vascularity of the pedicle flap.
- Ability to cover a denuded root surface.

Disadvantages:

- Limited by the amount of adjacent keratinized attached gingiva.
- Possibility of recession at the donor site.
- Dehiscence or fenestrations at the donor site.

- Limited to one or two teeth with recession.

Contraindications:

- Presence of deep interproximal pockets.
- Excessive root prominences.
- Deep or extensive root abrasion or erosion.
- Significant loss of interproximal bone height.

CYANOACRYLATE TISSUE ADHESIVE

Tissue adhesives are the substances that hold the tissues together. Cyanoacrylates were first synthesized in the year 1949 and were first used in surgery 10 years later when Harry Coover discovered their inherent adhesive properties in the research laboratories of Tennessee Eastman Company.[24]

Synthetic cyanoacrylate adhesives (alkyl-2-cyanoacrylates or alkyl-α-cyanoacrylates) are a family of liquid monomers consisting of the alkyl esters of 2-cyanoacrylic acid. They polymerize at room temperature in an exothermic reaction releasing heat on contact with a small amount of water or basic fluid to form polymers, poly (alkyl-2-cyanoacrylates). They form strong adhesive bonds with a variety of different substrates such as wood, metal, hard tissue (i.e., bone and tooth), and soft tissue (i.e., skin, vascular tissue) [25]

Synthetic cyanoacrylate tissue adhesives have been used widely as an alternative to current conventional treatments in clinical applications and studies. They include the use of cyanoacrylates for embolization in neurologic, urologic and cardiovascular procedures and for cartilage and bone grafting procedures.[24] They have widespread indications and applications such as fixation of implants, tissue adhesion, closure of cerebrospinal fluid leaks and embolisation of blood vessels.[26] These compounds have their greatest use in facial plastic and reconstructive surgery as an

alternative to traditional suture closure. In contrast to fibrin tissue adhesives, the cyanoacrylate tissue adhesives are synthetic compounds that do not naturally occur in the human body.[24]

Different synthetic cyanoacrylate adhesives (alkyl-2-cyanoacrylates) are manufactured by altering the alkoxycarbonyl group (-COOR) of the molecule. The alkyl side chain (-R) determines the rate of degradation, rate of polymerization with release of heat in the process, flexibility, toxicity, and the properties of adhesive formed when a monomer polymerizes into a polymer.[25] Table 2 shows various cyanoacrylate adhesive products.

Table 1: Various Cyanoacrylate Adhesive Products

R	NAME
$-CH_3$	methyl-2-cyanoacrylate
$-C_2H_5$	ethyl-2-cyanoacrylate
$-C_4H_9$	n-butyl-2-cyanoacrylate
$-C_8H_{17}$	2-octyl cyanoacrylate

Studies have shown that when the side chain (-R) of the cyanoacrylate monomers were short, such as in methyl-2-cyanoacrylate, it polymerized to give a rigid polymer matrix, poly(methyl-2-cyanoacrylate), and it rapidly degraded into corresponding alkyl cyanoacetate and formaldehyde which can lead to significant histotoxicity. The degradation of polymer also depends upon the molecular weight of the polymer formed. Poly (methyl-2-cyanoacrylate), a lower molecular weight polymer degrades more rapidly into corresponding alkyl cyanoacrylate, formaldehyde and other breakdown products. Also when cyanoacrylate monomers with longer side chains (higher homologues), such as n-butyl-2-cyanoacrylate and 2-octyl-

cyanoacrylate, polymerize slowly. These longer side-chain derivatives form flexible polymers and undergo a slower process of biodegradation which result in fewer toxic byproducts released into the tissues per unit of time allowing for more efficient tissue clearance of these toxic byproducts with less ensuing tissue toxicity. Thus longer chain cyanoacrylate monomers are considered to be less toxic due to their slower degradation when compared to shorter chain counterparts.[25]

Isobutyl cyanoacrylate and butyl-2 cyanoacrylate are known for reasonable binding strength and lesser degrees of histotoxicity when compared with their short-chain counterparts. The use of isobutyl-2-cyanoacrylate was reduced when more convincing studies reported moderate histotoxic reactions when applied subcutaneously or within mucosal lined cavities. After then butyl-2-cyanoacrylate began to gain acceptance and is used in a variety of facial plastic procedures as its use has shown clinical success with less frequent and severe histotoxic reactions.[24]

RESORBABLE SUTURE

A surgical suture is one that approximates the adjacent cut surfaces or compresses blood vessels to stop bleeding. Surgical sutures have been used to close wounds since prehistoric times (50000-30000 B.C). The first written description of their use dates back to as early as 4000 B.C. Various materials like gold, silver. hemp, fascia, hair, linen and bark have been used. Yet none have provided all of the desired characteristics.[23] There are two different kinds of sutures. One is absorbable sutures that will dissolve on their own. Another one is non-absorbable sutures that will be removed after certain period of time.[27]

Qualities of the ideal suture material[28] compiled from **Postlewait (1971), Varma et al (1974)** and **Ethicon (1985)**

1. Pliability, for ease of handling
2. Knot security
3. Sterilizability
4. Appropriate elasticity
5. Nonreactivity
6. Adequate tensile strength for wound healing
7. Chemical biodegradability as opposed to foreign body breakdown

With the possible exception of coated Vicryl (Ethicon, Somerville, new Jersey), none of the sutures available today meet this criteria

Absorbable sutures may be used to hold wound edges in approximation, until they have healed sufficiently to withstand normal stress. These sutures are prepared either from the collagen of healthy mammals or from synthetic polymers. Some are treated or chemically structured to lengthen absorption time while others are absorbed rapidly. They may also be impregnated or coated.[29] Table 3 shows different types of absorbable suture materials.

Polyglactin 910 is a synthetic heteropolymer consisting of 90% of glycolide and 10% of lactide. These are braided, multifilament, coated, absorbable synthetic sutures. This suture is degraded by hydrolysis. [30]

The residual tensile strength of a polyglactin 910 suture is consistently greater than that of polyglycolic acid suture. Polyglactin 910 sutures are absorbed more rapidly than polyglycolic acid suture. In a study comparing the absorption of polyglactin 910 and polyglycolic acid, all remnants of polyglactin 910 were absorbed by 90 days, while considerable quantities of polyglycolic acid persisted at120 days.[31]

Table 2: Absorbable sutures[30]

Type	Material	Duration at maximum strength (days)	Complete absorption time (days)	Colors available
Catgut	Sheeps Intestine Submucosa	3-4	Variable	Undyed
Chromic catgut	As above but tanned with chromic salts to delay absorption	10-14	>120	Undyed
Dexon	Polyglyccolic	10-14	90-120	Undyed or green
Vicryl	Polyglactin 910	14-21	90	Undyed or purple
Polyglyconate	Glycolic acid and trimethylene carbonate	10-14	180	Undyed
Glycomer 631	Polyster of glycolide, diaxanone and	12-20	90-110	Undyed

	trimethylene carbonate			
Polyglytone 6211	Polyester of glycolide, Caprolactone, trimethylene carbonate and lactide	7-10	Variable	Undyed

Wilderman et al. (1960)[32] conducted a study based on histological examination of the maxillary and mandibular premolars of ten young dogs following mucogingival surgery. Histologic study between two days and one hundred eighty five days showed three phases in the healing process. These phases are: I. Osteoclastic phase (2-10 days) II. Osteoblastic phase (10 -28 days) III. Phase of functional repair of dentoperiodontal unit and dentogingival junction (28-185 days). The entire reaction following mucogingival surgery was a connective tissue response. Osteoclasis began within two days and became most active between fifth and tenth day. Finally, at the two to fourteen day postoperative period there was complete loss of the exposed vestibular bone. The most significant finding was the source and rate of the proliferating young connective tissue. Two days postoperative, the fixed connective tissue of the cut dento-gingival junction and the periodontal ligament, the incised gingival papillae and the lateral wound edges were the sources of the initial granulation tissue. At six days, after the resorption of the vestibular plate, the granulation tissue from the marrow spaces and periodontal ligament fused with the

initial granulations from the fixed wound edges to cover the defect. Finally, there was a junction of these rapidly growing tissues with the alveolar mucosa. New bone formation was greatest between the twenty-first and twenty-eighth day period.

Wilderman and Wentz (1965)[9] histologically studied the repair of a surgically created dentogingival defect utilizing a pedicle flap in dogs, three to four years of age. The repair of the dentogingival defect was accomplished by a gingival and mucosal mucoperiosteal flap from an area adjoining and distolateral to the defect. The healing process was divided into four stages. I. Adaptation stage (0-4 days) where the laterally repositioned flap is separated from the exposed root surface by a thin fibrin layer. The epithelium covering the transplanted tissue flap proliferates and reaches contact with the tooth surface at the coronal edge of the flap after a few days. II. Proliferation stage (4-21 days) where the fibrin layer between the root surface and the flap is invaded byconnective tissue proliferating from the subsurface of the flap. After 6-10 days a layer of fibroblasts is seen in apposition to the root surface. These cells are believed to differentiate into cementoblastsat a later stage of healing. The epithelium proliferated apically along the root surface and stop within the coronal half of the defect although further downgrowth of the epithelium was also frequently observed. III. Attachment stage (27-28 days) where thin collagen fibers become inserted in a layer of new cementum inserted at the root surface in the apical portion of the recession. IV. Maturation stage characterizaed by continuous formation of collagen fibers. After 2-3 months bundles of collagen fibers insert into the cementum layer on the curetted root surface in the apical portion of the recession.

Grupe H E (1966)[4] conducted a case study about treating gingival defects by a sliding flap operation in which 3 cases were treated with the application of a modified technique where, the marginal gingiva was retained with its attachment to the tooth

and bone by making a horizontal incision apical to the gingival sulcus. It was concluded that this technique may be limited to cases which have an adequate amount of fibrous gingiva in the area of the donor site. Consideration of the influence of the frenum in mucogingival problems is re-emphasized.

Bhaskar S N et al. (1966)[33] conducted a clinical study with the use of butyl cyanoacrylate (a chemical adhesive) as a periodontal and surgical dressing. A total of 105 patients in whom 276 applications were made. The results revealed that butyl cyanoacrylate is a better periodontal dressing than any other because of its properties of easy use, hemostatic agent and also reduces postoperative pain, does not induce overabundant granulation, and accelerates the healing process.

Frisch J et al. (1968)[34] treated 17 cases of mean age from 20 to 63 years with free mucosal graft procedure who showed periodontal problems such as shallow vestibule, reduced width of the attached gingiva and/or exposure of the root surface of the anterior teeth which included the mandibular incisor area for 14 patients and mandibular cuspid area for 3 cases. Following the graft placement, the entire area was sprayed with butyl cyanoacrylate and care was taken that the adhesive did not get between the graft and the recipient connective tissue. The donor site was then sprayed with the adhesive and the patient dismissed. The dressing was finally removed 22 days after surgery. The follow-up from 6 months to 26 months showed that all the free tissue graft procedures were successful with the use of a chemical adhesive (a normal butyl cyanoacrylate) is far superior to the use of sutures.

Binnie W H et al. (1974)[35] conducted a comparative study to assess histological changes following healing with the use of butyl cyanoacrylates and silk sutures in contiguous areas of two 6 months male beagle dogs. Periodontal flap procedures were carried out on both the sides with the use of sutures on one side where

butylcyanoacrylate on contralateral side. One week review shown that the appearance of the cyanoacrylate flaps was better than those which had been sutured. Histologically, there was less disturbance of the periodontal tissues with little inflammation at one week where cyanoacrylate had been used. Thus it was concluded that cyanoacrylates are acceptable agents in flap retention.

Forest J O (1974)[36] used cyanoacrylate over a period of three years and the material has been applied in comparative studies of periodontal wounds in Beagle dogs and in more than three hundred humans. The study resulted that the patients show less apprehension with the use of tissue adhesive during operation compared with suturing. Also the effort and time taken to suture all around the mouth at the end of a long session was reduced to a five minute task. A further advantage with the unconscious patient was the rapid control of haemorrhage. Thus it was concluded that butyl cyanoacrylate used in the closing of wounds in more than 300 patients demonstrated a number of advantages of which most important were the ready acceptance of the technique by all patients and rapid control of bleeding.

Smukler H et al. (1976)[10] evaluated the mucoperiosteal laterally positioned flap, in the treatment of isolated gingival recession, with special regard to the criteria included, Stability of the grafted tissue, "Bridging" of the denuded root surfaces, Width of attached gingiva and Depth of the gingival crevice in 21 areas of isolated on 15 patients with age range from 20 to 56 years with a mean of 38. Results of the study showed that the mean width of the gingiva had increased to 4.29 mm ± 0.22 mm 9 months postoperatively. However the percentage coverage obtained on this basis was calculated to be 86.77%. Correlation of Root Coverage Attempted and Root Coverage Obtained was significant with loss of approximately 20% of the grafted tissue occurred during the study. These results indicate that the grafts endure very well over

a 9-month period of observation, thus supporting the beneficial clinical outcomes of using mucoperiosteal laterally positioned flap, in treating isolated gingival recession.

Guinard E A et al. (1978)[11] evaluated the changes that occur on the recipient site as well as on its neighbouring tooth with regard to gingival recession, sulcus depth and width of keratinized gingiva after performing a lateral sliding flap with to the original technique or a coronally repositioned flap. 28 teeth in 23 patients aged from 19 to 68 years, mean 35 years showing localized gingival recessions. The results obtained in the study showed that areas of gingival recession were significantly reduced by the lateral sliding flap with a significant increase ($P < 0.001$) in the width of keratinized gingiva and showed a slight decrease in sulcus depth on the recipient tooth after performing the lateral sliding flap.

Caton J G et al. (1986)[37] evaluated the effects of a commercially available tissue adhesive upon healing of the coronal periodontium. 24 teeth were extracted from four squirrel monkeys and the coronal third of the roots were planed free of fibers and cementum. Eight teeth were replanted without further alteration and eight teeth were coated with tissue adhesive prior to replantation. In the remaining eight teeth, the planed surface was decalcified, coated with tissue adhesive and replanted. Histological observations were made at 1st and 7th day after replantation. In the teeth replanted after root planing alone and root planing plus tissue adhesive, epithelium got migrated apically and was within the ligament space lining the denuded root at 7 days. In contrast, those teeth which were decalcified prior to application of tissue adhesive showed fiber attachment to the planed root surface and little or no epithelial down growth.

Lafferty T A et al. (1993)[38] compared the surface characteristics of periodontally diseased single- rooted human teeth extracted after treatment with either tetracycline

HCl or citric acid solutions .The teeth were sectioned and then the solutions of tetracycline HCl or citric acid (pH 1) were applied to the surfaces with cotton pellets for 5 minutes. Extracted teeth were processed and root surface samples were examined by scanning electron microscope. Acid-treated specimens exhibited dentinal tubules exposed by the removal of the smear layer. The surfaces devoid of the debris were normally present in root planed-only specimens. Although differences were seen in surface depressions and fiber-like structures among some specimens, the tetracycline HCl and citric acid solutions produced comparable morphologic characteristics

Madison J G et al. (1997)[39] compared the surface effects of various topical applications of tetracycline on the instrumented dentin root surface of 82 human teeth dentin samples by scanning electron microscope (SEM) examination which were prepared from periodontally-compromised teeth planned for extraction. Solutions of tetracycline HCl, doxycycline, minocycline, sumycin, and a saline control were prepared and applied to the dentin samples for 0.5, 1, 3, 5, and 10 minutes. After then, each solution pH was measured: tetracycline HCl (pH 1.6), doxycycline (pH 2.2), minocycline (pH 3.8), sumycin (pH 4.4), and saline (pH 5.1). Tetracycline periodontal fiber also was evaluated at 1,4, 7, and 10 days of exposure for dentin surface effects. Tetracycline HCl removed the smear layer in dentin leaving clean and open tubules which was significantly better than other solutions tested in as little as 30 seconds. Doxycycline and minocycline produced similar results to each other, which were shown to be significantly better than sumycin and saline, but not as effective as tetracycline Hcl. Results of this study suggested that tetracycline HCl is the best current tetracycline form for root surface conditioning because of its ability to affect both dentin smear layer removal and dentin tubule exposure effectively.

Giray C B et al. (1997)[17] compared the clinical outcomes using tissue adhesives as an alternative or replacement for sutures in wound closure in 15 patients, who underwent root resections of the upper incisors on both sides, the incision lines were closed with silk sutures on one side and n-butyl-2-cyanoacrylate on the other side of the frenum. Clinical comparison was made on the 1st, 2nd, 3rd, 7th, 14th and 21st postoperative days. On the 7th postoperative day following the removal of sutures and the coating, small punch biopsies were obtained from n-butyl-2-cyanoacrylate treated and sutured sides and were examined under transmission electron microscope. On the 3rd and 7th postoperative days, epithelialization was better on the sides treated with n-butyl-2-cyanoacrylate and on the 21st postoperative day it was observed that the scar formation was significantly more marked and there was more local inflammation during the healing period on the sutured side recommends the use of tissue adhesives as an alternative to or replacement for sutures.

Grisdale J (1998)[40] presented 2 cases demonstrating the use of Cyanoacrylate in periodontal therapy, where in case one shows its use in free gingival graft surgery, following preparation of the recipient site, the donor tissue is obtained from the palate where cyanoacrylate is then applied as a dressing over the donor site and in case two following the soft-tissue biopsy, applied a thin layer of cyanoacrylate to the biopsy site. The material is effective as a surgical dressing during the early healing phase. Thus the author concluded that cyanoacrylate to be useful in several other periodontal surgery applications which includes post-gingivectomy, gingivoplasty, securing apically positioned flaps and following ridge preservation using osseous graft materials.

Bouchard et al. (2001)[41] reviewed on decision making in aesthetics in root coverage procedures. Based on the personal experience, it is suggested that careful decision-

making prior to root coverage procedures will enhance the success rate and overall esthetic outcome. The longer the roots have been exposed, the more the surface changes. Thus the removal of the biofilm on the exposed portion of the root appears to be of importance for healing. Gentle root planing must render the root surface free from microbial plaque. Root reduction before root coverage therapies is only indicated for anatomical reasons, such as root prominence, or caries removal. For vascularization postsurgically, blood supply following flap operations will have to come from the areas bordering the recession defect and from the pedicle. The healing of nonsubmerged graft primarily depends on the restoration of collateral circulation from the periosteal connective tissue bed that is bordering the defect. The thinner the soft tissues, the more difficult the procedure and higher the risk of postoperative necrosis. A thin clot promotes tensile strength and stability of the wound. Thus the surgical technique and the early postoperative period are the keystones to achieve successful root coverage. Also added that the undesirable postoperative recession can be avoided by suturing the flap 1 to 2 mm coronal to the cementoenamel junction. They listed certain professional evaluation factors for aesthetic outcome of root coverage procedures. These are degree of root coverage, color match of the tissues (alveolar mucosa, pre-existing keratinized tissues and gingival graft), soft tissue appearance (lack of hypertrophic scars or fibrosis and, matching volume and texture) and location of the mucogingival line.

Jahangirnezhad M (2006)[42] compared the outcomes of gingival recession therapy using the semilunar coronally repositioned flap (SCRF) alone and in conjunction with a tissue adhesive (EPIGLU). 32 anterior and premolar teeth with class I and II Miller gingival recessions were selected and randomly divided into two groups. The test group received SCRF followed by EPIGLU application and the control group was

managed with SCRF alone. The recession depths decreased significantly in both groups (P<0.05). Three months after surgery, the mean root coverage in the test and control groups was 1.86mm (77.96%) and 1.57mm (69.1%) respectively. Except for probing depth, the width of keratinized tissue along with all the other tested parameters, increased significantly in both groups, during the study period (p<0.05). Thus it was concluded that the SCRF alone or with EPIGLU is an effective procedure for root coverage in anterior and premolar teeth. The addition of EPIGLU has shown to improve the amount of root coverage, especially in relatively shallow defects.

Kulkarni S et al. (2007)[43] compared the healing of periodontal flaps when closed with silk sutures and tissue adhesive n-butyl cyanoacrylate (NBC) on 24 patients who needed flap surgical procedure for pocket therapy. It was found that healing with the cyanoacrylate reduced the amount of inflammation during the first week when compared with silk. However, over a period of 21 days to 6 weeks, the sites treated with both the materials showed similar healing patterns. Thus it was concluded that flaps healed by primary union when closed with sutures and with NBC with the added effect that NBC aids in early initial healing.

Chen W L et al. (2007)[44] compared the bacteriostatic effects, corneal cytotoxicity, and ability to seal corneal incisions among fibrin glue and 2 commercially available cyanoacrylate derivatives: *N*-butyl cyanoacrylate and methoxypropyl cyanoacrylate. By measuring the zones of bacterial growth inhibition surrounding the adhesive droplets on agar plates, the bacteriostatic activities of these tissue glues were verified. Corneal cytotoxicity was tested by a direct contact method by using cultured bovine corneal epithelial cells, keratocytes, and corneal endothelial cells challenged with droplets of adhesives. By calculating the maximum intraocular pressure resistant to leakage of rabbit corneal stab wounds sealed with tissue adhesives, the ability to seal

corneal incisions was verified. Methoxypropyl cyanoacrylate and *N*-butyl cyanoacrylate showed bacteriostatic effects against *S. aureus*, *S. pneumoniae*, and *M. chelonae* but not *E. coli* and *P. aeruginosa*. But fibrin glue had no such effects against either Gram-positive or negative bacteria ($P < 0.01$). Methoxypropyl cyanoacrylate showed the highest levels of corneal cytotoxicity, followed by *N*-butyl cyanoacrylate. Fibrin glue, however, showed minimal cytotoxicity ($P < 0.01$). Methoxypropyl cyanoacrylate and *N*-butyl cyanoacrylate also displayed a greater ability to seal corneal incisions than that of fibrin glue concluded showing the beneficial effects of cyanoacrylate derivatives as tissue adhesives.

Jathal B et al. (2008)[45] conducted a study to check the consequence of fibrin sealant as an alternative to sutures. Two patients were treated. Flaps were closed using fibrin in the first patient and sutures in the second patient. Ethicon Mersilk 3–0 sutures were used as a control since it is the usual means of fixing tissues in periodontal surgery. The use of fibrin glue saves remarkable amount of time and makes it easier to fix the tissues in difficult inaccessible areas and esthetically critical areas. The time saved range from 3–19.5 minutes per procedure, 1–8.5 minutes per tooth. They concluded that the fibrin glue was easier and quicker to use than sutures, provides better early hemostasis and complete adhesion of the whole surface of the tissues to the underlying layer. Fibrin sealing system is effective as a means of fixing tissues after periodontal surgery.

Shetty B et al. (2008)[46] compared the dentin surface changes following applications of tetracycline and citric acid to the instrumented root surface of periodontally involved human teeth under scanning electron microscope. 80 dentin samples were prepared from periodontally-compromised teeth and planned for extraction. Diseased surfaces were root planed and sectioned and then solutions of tetracycline HCl,

doxycycline, minocycline, and citric acid were applied to the surfaces with cotton pellets for 5 minutes. On evaluation with scanning electron microscope resulted in removal of smear layer in all the four groups. The proportion of patent dentinal tubules was (74%) in tetracycline HCl group compared to minocycline (48.3%), doxycycline 42%), citric acid (52%), showing the differences statistically significant. Thus suggested that tetracycline was the best current tetracycline form for root surface conditioning as measured by its ability to affect both dentin smear layer removal and tubule exposure.

Ghoreishian M et al. (2009)[47] evaluated and compared the efficacy of cyanoacrylate in postoperative pain and bleeding with suturing. 16 patients with similar bone impaction and inclination of mandibular third molars on the right and left sides were included for the study. The right flap was closed with 3-0 silk sutures and the left flap was closed with cyanoacrylate. A visual analogical scale was used to evaluate the severity of pain and bleeding on postoperative days. The results showed that postoperative bleeding with cyanoacrylate was less significant than with suturing on the first and second days after surgery, and thus suggested that the efficacies of cyanoacrylate and suturing were similar in the severity of pain but use of cyanoacrylate resulted in better hemostasis.

Barbosa F L et al. (2009)[48] evaluated the dimensional changes in free gingival grafts fixed with ethyl cyanoacrylate or sutures. 24 subjects with gingival recession and absence of keratinized mucosa were divided into two groups as (Group 1) free gingival grafts fixed with ethyl-cyanoacrylate and (Group 2) fixed with sutures. Results demonstrated that dimensional changes related to the area of gingival graft were similar for both groups. It was also added that the dimensional changes in the

height of the grafts in the recipient bed was influenced by the thickness of the gingival graft tissue ($p < 0.047$). Gingival grafts thinner than 1 mm showed a greater average height at the end of the study and showed no significant changes regarding the total area of the graft. Hence it was concluded that the modality of gingival graft fixation did not present any significant influence over the clinical parameters evaluated and the use of ethyl cyanoacrylate did not alter the graft healing process, suggesting a possible alternative for free gingival graft fixation.

Ashok K P et al. (2010)[49] evaluated the effectiveness of saturated citric acid, saturated tetracycline hydrochloride, 8% ethylenediaminetetraacetic acid (EDTA) and saline is on periodontally involved root surfaces of 60 root dentin samples using Scanning Electron Microscopy which were prepared from extracted teeth. The teeth were root planed and sectioned and then the saturated solutions of citric acid, tetracycline hydrochloride, EDTA and saline were prepared and applied. SEM examination revealed that Citric acid treated specimens showed greatest degree of morphological alteration than tetracycline or EDTA. Citric acid group and tetracycline group showed higher diameter and surface area of tubules compared to EDTA and were statistically significant. It was concluded that to achieve maximum exposure of fibrils and dentinal openings, it may be desirable to use citric acid as root conditioner than tetracycline or EDTA.

Guncu G N et al. (2012)[50] evaluated the shrinkage of FGGs, either sutureless or suturing technique, in both horizontal and vertical dimensions and also calculated the changes in the surface area of the graft at early and delayed time points. A total of 26 patients requiring FGG due to lack of keratinized gingiva in the buccal aspect of mandibular incisors. Patients were randomly treated by FGG using either tissue adhesive or suture. The graft dimensions were measured and the shrinkage of the

graft was calculated at baseline, 10th, 21st and 180th day. Significant reductions were observed in horizontal and vertical dimensions at all time-points. The percentage of vertical shrinkage was significantly lower in the test group at day 10 and 180 when compared to baseline. With this study, the authors concluded that tissue adhesives can reduce the amount of vertical graft shrinkage that occurs following FGG procedures.

Ruchi S et al. (2013)[51] presented a case series in which treatment of Millers class II gingival recession involving the teeth no 31 and 41 with partial thickness lateral pedicle grafting along with root surface conditioning using tetracycline HCl in 2 patients of age 22 and 28 years respectively. The outcome of this procedure resulted in clinically significant amount of root coverage and the re-evaluation at 3 months follow-up resulted in an esthetically healthy periodontium along with good patient's acceptance.

Chahal G S et al. (2013)[52] conducted an in vitro study about the effects of citric acid, doxycycline and tetracycline on the instrumented periodontally involved root surfaces using a scanning electron microscope. 45 dentin samples obtained from 15 extracted teeth which were scaled, and root planed, and then were divided into three groups. The root conditioning agents were applied with cotton pellets using the “Passive burnishing technique” for 5 minutes. The samples then examined by the scanning electron microscope. Results shown that the root conditioning agents used in this study were found to be effective in removing the smear layer, widening and uncovering the dentin tubules, and unmasking the dentin collagen matrix. Among the three, tetracycline HCl was found to be the best root conditioner which plays significant role in periodontal wound healing.

Rajkarnikar J (2014)[53] studied the efficacy of lateral pedicle grafts in various grades of gingival recession defects. A total of 18 systemically healthy patients with the age

of ≥30 years were included. Baseline gingival recession height was measured using Williams probe and assigned as group 1 (3-4mm), group 2 (5-7mm) and group 3 (>=8mm). Following the surgery, re-evaluation was done at 7 days and 3 months which showed that 100% in group 1 had complete coverage or minimal loss of attachment whereas 71.5% in group 2 had complete coverage. Thus they concluded that this technique has been demonstrated as a reliable and predictable treatment modality for obtaining root coverage in recession defects for complete or partial root coverage.

Gumus P et al. (2014)[54] compared and evaluated 3 different stabilization methods with regards to the amount of shrinkage in free gingival graft. 45 patients were included in three study groups. Stabilization was achieved with conventional technique, cyanoacrylate or microsurgery. Standardized 5-0 sutures were used in the conventional group. In the micro- surgery group, grafts were stabilized with 7-0 sutures and loupe. Graft was stabilized with cyanoacrylate in the third group. At baseline, 1, 3, 6 month follow-ups, keratinized tissue width, graft area and gingival recession were calculated by a specific software on standard photographs. Duration of surgery was also recorded. Pain in recipient and donor sites was assessed using visual analogue scale. The results showed that the change in keratinized tissue width was similar in all the groups throughout the study. Graft shrinkage was significantly less ($p < 0.05$) in the cyanoacrylate group than the other groups. Also significantly less pain in the recipient site was reported by the patients in the cyanoacrylate group ($p < 0.05$) compared to the other two groups. Duration of surgery was significantly less in the cyanoacrylate group than the other groups. Thus it was concluded that cyanoacrylate may be considered as an alternative for stabilization of free gingival grafts.

Kumar A et al. (2016)[55] conducted a pilot study using auto transplant of periosteum in combination with laterally positioned flap. A total of 20 teeth with Miller's class I and II gingival recession with ≥ 3 mm defect, which were treated by laterally positioned flap with periosteal graft. The result revealed that significant reduction in recession defect with a root coverage of 95.6% and 80% predictability for recession coverage in 12 months. Hence they concluded that laterally positioned flap with periosteal graft technique can be successfully used for the treatment of gingival recession defects with good esthetic results.

Materials and Methods

MATERIALS AND METHODS

The study was approved by the Scientific and Ethical Committee review board of Best Dental Science College and Hospital, Madurai. The study was carried out from January 2015 to September 2016

STUDY POPULATION

The study population were recruited from patients attending outpatient clinics of Department of Periodontics, Best Dental Science College and Hospital, Madurai.

A total of 22 subjects (16 males and 6 females) for complaints associated with gingival recession like receded gums and unaesthetic looks were included in this study. The study sample size was determined to ensure an alpha error of 0.05 % and 80% power.

All the participants in the study were verbally informed about the nature, risks and benefits of the study and a written informed consent was obtained.

RANDOMIZATION

Subjects were randomly allocated into two groups by generating the random number using SPSS software version 20.

Test - Lateral pedicle graft stabilized with cyanoacrylate tissue adhesive.

Control - Lateral pedicle graft stabilized with resorbable sutures.

CRITERIA FOR SELECTION OF SUBJECTS

Inclusion Criteria:

- Patients with age between 20 and 45 years
- Miller's class I and II gingival recession with deep narrow defect (≥3 mm) in relation to anterior tooth that have adequate donor tissue laterally and adequate vestibulate depth.
- Vital teeth with no history of active periodontal treatment (surgical and non-surgical) for the past 6 months.

Exclusion Criteria:

a) Medically compromised patients.
b) Presence of cervical abrasion, erosion or root caries that would require restoration.
c) Pregnant or lactating women.
d) Taking any medications known to affect the outcomes of periodontal therapy.
e) Using any form of tobacco.

All the patients were subjected to phase I therapy. Trauma from occlusion if detected was eliminated. At the end, only those patients demonstrating the acceptable oral hygiene standards and gingival health were considered for the present study. Each patient was explained about treatment design. An informed consent was taken from each of the participating subject.

ARMAMENTARIUM

Armamentarium for clinical evaluation

1. Mouth mirror
2. Explorer
3. UNC-15 probe
4. Digital vernier caliper
5. #15 endodontic reamer with a stopper

Surgical armamentarium

1. Mouth mirror
2. UNC-15 probe
3. Explorer
4. Cotton pliers
5. Tissue holding forceps
6. Sterilized cotton pellets and gauze
7. Povidone iodine
8. Bard Parker handle no. 3
9. Surgical blade no. 15
10. Straight and curved scissors
11. Castroviejo scissors
12. Gracey curettes for anterior teeth
13. Needle holder
14. Normal saline
15. Suture cutting scissor
16. Resorbable 5-0 polyglactin 910 sutures (Vicryl)
17. N-butyl-2-cyanoacrylate tissue adhesive (Enbond)

18. 2% lignocaine local anesthetic agent containing adrenaline in the ratio of 1:80,000
19. Tetracycline capsule (250 mg)
20. Dapendish
21. Applicator tip
22. Disposable syringes- 2 ml and 10 ml
23. Periodontal dressing (COE- PAK)
24. Glass slab
25. Cement spatula

CLINICAL PARAMETERS

1. Plaque index (PI)[56]
2. Gingival index (GI)[57]
3. Probing pocket depth (PPD)[58]
4. Clinical attachment level (CAL)[58]
5. Recession depth (RD)[58]
6. Recession width (RW)[58]
7. Thickness of keratinized gingiva (TKG)[59]
8. Height of keratinized gingiva (HKG)[58]
9. Root coverage percentage (%)[60]

The probing pocket depth, clinical attachment level, recession depth, recession width and height of keratinized gingiva were measured using UNC-15 probe.[58]

Plaque Index (Silness and Loe 1964)

Table 3: Plaque Index Scores

Score	Criteria
0	No plaque

1	A film of plaque adhering to the free gingival margin and adjacent area of the tooth. The plaque may be seen only by running a probe across the tooth surface.
2	Moderate accumulation of soft deposits within the gingival pocket, on the gingival margin and/or adjacent tooth surface, which can be seen by the naked eye.
3	Abundance of soft matter within the gingival pocket and/or on the gingival margin and adjacent tooth surface

Calculation of plaque index:

PI for the area: Each area (disto-facial, mesio-facial, facial and lingual) is assigned a score from 0-3

PI for a tooth: The scores from the four areas are calculated and divided by four

PI score for the individual: The scores for each tooth were added and then divided by the total number of teeth examined.

Table 4: Plaque Index Interpretation

Excellent	0
Good	0.1-0.9
Fair	1.0-1.9
Poor	2.0-3.0

Gingival Index (Loe and Silness 1963)

Table 5: Gingival Index Scores

Score	Criteria
0	Absence of inflammation/normal gingival

1	Mild inflammation, slight change in colour, slight edema and no bleeding on probing
2	Moderate inflammation, moderate glazing, redness, edema, hypertrophy and bleeding on probing.
3	Severe inflammation, marked redness, hypertrophy, ulceration and tendency for spontaneous bleeding.

CALCULATION

GI Score for the area: Each area (disto-facial, facial, mesio-facial, lingual) is assigned a score from 0 to 3

GI Score for a tooth: The scores from the four areas of the tooth are added and then divided by four.

GI score for the individual: The indices for each of the teeth are added and then divided by the total number of teeth examined. The scores range from 0 to 3.

Table 6: Gingival Index Interpretation

Gingival scores	Condition
0.1-1.0	Mild Gingivitis
1.1-2.0	Moderate Gingivitis
2.1-3.0	Severe Gingivitis

Probing pocket depth: It was measured at the mid-buccal aspect of the study tooth from the gingival margin to the bottom of the sulcus

Clinical attachment level: It was measured at the mid-buccal aspect of the study tooth from the cementoenamel junction (CEJ) to the bottom of the sulcus.

Recession depth: It was measured at the mid-buccal aspect of the study tooth from the CEJ to the most apical extension of gingival margin.

Recession width: It was measured at the CEJ level

Thickness of keratinized gingiva: It was measured 3 mm below the gingival margin at the attached gingiva or the alveolar mucosa. The mucosal surface was pierced at a 90 degree angle with slight pressure until hard tissue was reached using a #15 endodontic reamer with a silicone disk stop. The silicone stop on the reamer was slid until it was in close contact with the gingiva. After removal of the reamer, the distance between the tip of the reamer and the inner border of the silicone stop was measured to the nearest 0.1 mm with caliper.

Height of keratinized gingiva: It was measured from the most apical point of gingival margin to the mucogingival junction (MGJ)

Root coverage percentage (%): Percentage of root coverage was calculated according to the following formula

$$\text{Root coverage} = \frac{\text{Recession depth (preoperative - postoperative)}}{\text{Recession depth preoperative}} \times 100$$

All the above clinical parameters were recorded at the baseline, 1 month and 3 months post-operatively. Percentage of root coverage was calculated at 3 month post-operatively.

PREPARATION OF THE PATIENT

The extraoral skin preparation was done with 5% povidone-iodine solution. The patient was asked to rinse his/her mouth with 10 ml of 0.2% chlorhexidine digluconate solution for 1 minute.

SURGICAL TECHNIQUE

The surgical area was prepared and adequately anaesthesized using 2% Lignocaine HCl containing 1:80,000 epinephrine by giving infiltration anesthesia.

Preparation of the recipient site

With a no.15 scalpel blade V-shaped incision was made about the denuded root to remove the adjacent epithelium and connective tissue. In the case of deep labial pockets and associated frenula, the apex of the V-shaped incision was extended far and wide apically enough to remove them. Also the V-shaped incision was beveled out on the opposite side to permit overlap and to increase vascularity for the donor site in this area. All these remnants were removed from the area and the roots were planed.[23]

Root conditioning with tetracycline solution: (250 mg/ml)

A fresh tetracycline solution (250 mg/ml) applied to the root surface for each surgery. It was prepared by mixing tetracycline HCl 250 mg in 1 ml of sterile water. Cotton pellets soaked in tetracycline solution (250 mg/ml) were burnished to the root surface with a light pressure every 30 seconds for 5 minutes. The root surface was then extensively rinsed with saline solution.[52]

Preparation of the pedicle flap

The pedicle flap should be twice as wide as the defect. A full thickness flap was reflected to the mucogingival junction after which a partial thickness flap was raised.[6,8,61] The flap should be free on its underlying side to permit movement to the recipient site without tension. It is sometimes necessary to make a short oblique incision (cutback incision) at the base of the flap to avoid tension that may impair the vascular circulation. The flap was then moved laterally to cover the exposed root,

leaving the donor site exposed. Finger pressure was applied with wet gauze to minimize blood clot and to encourage fibrinous adhesion.[8]

The pedicle flap was then carefully secured with either 5-0 resorbable sutures (control) or n-buty-2-cyanoacrylate tissue adhesive (test) without tension. Good adaptation of the flap to the underlying tissues is essential for adequate diffusion.

Periodontal dressing (Coe Pack Standard, GC America Inc., Alsip, IL, USA) was given thereafter and left in place for 1 week.[8]

The patient was discharged with postoperative instructions and NSAIDs as medications for 3 days to avoid postoperative pain and to reduce inflammation.[53] The patient was instructed to avoid tooth brushing in the surgical area.

The patient was recalled after 7 days. The periodontal dressing was removed and thoroughly irrigated with normal saline. The surgical site was examined for uneventful healing. The defect created at the donor site healed by secondary intention. The patient was instructed to use soft toothbrush for mechanical plaque control in surgical area. Oral hygiene instructions were re-instructed. The patient was monitored regularly postoperatively, to ensure good oral hygiene in the surgical area.[53]

Plaque index (Silness P and Loe H 1964), gingival Index (Loe H and Silness J 1963), probing pocket depth, clinical attachment loss, recession width and depth, thickness and height of keratinized gingival were recorded at baseline and at 1st month and 3rd month postoperatively. The percentage of root coverage was evaluated at the end of 3 months postoperatively.

1. ARMAMENTARIUM FOR CLINICAL EVALUATION

2. ARMAMENTARIUM FOR SURGICAL PROCEDURE

CYANOACRYLATE TISSUE ADHESIVE (N-BUTYL-2-CYANOACRYLATE)

VICRYL RESORBABLE SUTURE MATERIAL (POLYGLACTIN 910)

PERIODONTAL DRESSING (COE-PAK)

3. SURGICAL PROCEDURE – CONTROL SITE

Pre-op recession depth

Pre-op recession width

Measurement of thickness of keratinized gingiva using digital vernier caliper and #15endodontic reamer

Local anesthesia (2% lidocaine with adrenaline1:80000 concentration

Incision done with no.15 bard-parker blade

V-shaped tissue removed along the gingival margin of the recipient site

Sulcular and vertical incisions given

Flap elevation

‘

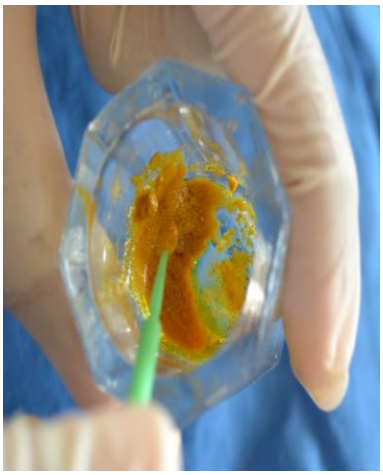

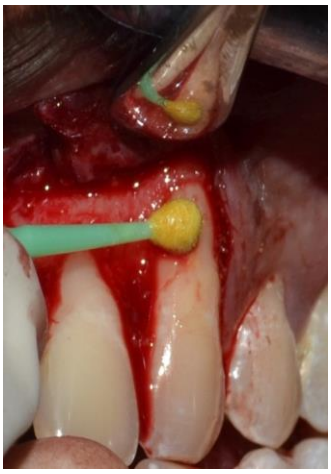

Root conditioning with tetracycline (250mg/dl)

Flap displaced laterally along the recipient site

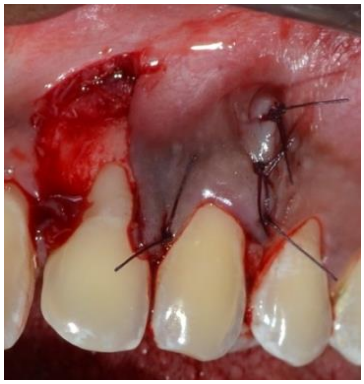

Laterally positioned graft secured with 5-0 resorbable suture

Periodontal dressing placed

Pre-op recession depth

1st month post-op recession depth

3rd month post-op recession depth

4. SURGICAL PROCEDURE - TEST SITE

Pre-op recession depth

Pre-op recession width

Local anesthesia (2% lidocaine with adrenaline1:80000 concentration)

Incision done with no.15 bard-parker blade

V-shaped tissue removed along the gingival margin of the recipient site

Sulcular and vertical incisions given

Flap elevatIon

Root conditioning with tetracycline (250 mg/ml)

Flap laterally displaced along the recipient site

Laterally positioned graft stabilized with cyanoacrylate tissue adhesive

Periodontal dressing placed

Pre-op recession depth

1st month post-op recession depth

3rd month post-op recession depth

Pre-op recession

1st month post-op recession width

3rd month post-op recession width

Statistical Analysis

STATISTICAL ANALYSIS

Data were analyzed using Statistical Package for Social Sciences (SPSS) Software version 20. Both descriptive and analytical statistics were performed.

1. **Mann-whitney test** has been performed to analyse the difference between test and control groups at various time periods for the following variables.
    - Plaque index
    - Gingival index
2. **Mann-Whiney test** has been performed to analyse between test and control groups by taking the difference of two time points for the following variables.
    - Clinical attachment level (CAL)
    - Recession depth (RD)
    - Recession width (RW)
    - Thickness of keratinized gingiva (TKG)
    - Height of keratinized gingiva (HKG)
3. **Kruskal wallis test** has been performed for within group analysis for both the groups and **Mann-whitney test** has been performed to see the difference between baseline vs first month, baseline vs third month and first month vs third month within the group for the following variables.
    - Plaque index (PI)
    - Gingival index (GI)
    - Clinical attachment level (CAL)
    - Recession depth (RD)
    - Recession width (RW)

- Thickness of keratinized gingiva (TKG)
- Height of keratinized gingiva (HKG)

p-value:

The p-value or calculated probability is the estimated probability of rejecting the null hypothesis of a study question when that hypothesis is true. Differences between the two populations were considered significant when $p < 0.05$.

Results

RESULTS

The purpose of the present study is to evaluate the clinical outcomes of lateral pedicle graft stabilized with cyanoacrylate tissue adhesive or resorbable sutures.

Twenty two patients (16 males and 6 females) fulfilling the selection criteria were selected for the study and were randomly divided into **test group** and **control group.**

TEST GROUP: Lateral pedicle graft stabilized with cyanoacrylate tissue adhesive (Enbond)

CONTROL GROUP: Lateral pedicle graft stabilized with resorbable sutures (Vicryl)

The following clinical parameters were recorded at the selected sites.

1) Plaque index (PI)[56]
2) Gingival index (GI)[57]
3) Probing pocket depth (PPD)[58]
4) Clinical attachment loss (CAL)[58]
5) Recession depth (RD)[58]
6) Recession width (RW)[58]
7) Thickness of keratinized gingiva (TKG)[59]
8) Height of keratinized gingiva (HKG)[58]
9) Root coverage percentage (%)[59]

All clinical parameters were recorded at baseline, 1st month and 3rd month postoperatively. All the clinical parameters recorded were subjected to the statistical analysis except probing pocket depth which remained unchanged.

CLINICAL PARAMETERS:

PLAQUE INDEX: (Table7a, 7b; Graph 1)

Table 7a: Comparison of mean plaque index score between test group (Cyanoacrylate tissue adhesive) and control group (Resorbable sutures) at various time periods.

Parameter	Time Period	Group	Mean	Standard Deviation	p-value*
PLAQUE INDEX	**Baseline**	**Test**	0.269	0.252	0.123
		Control	0.552	0.441	
	First Month	**Test**	0.375	0.219	0.002*
		Control	0.761	0.234	
	Third Month	**Test**	0.463	0.347	0.009*
		Control	0.916	0.255	

***** $p<0.05$ → statistically significant

Test group (Cyanoacrylate tissue adhesive): The mean plaque index at baseline was 0.269. At the first month, the mean plaque index was increased to 0.375 and at the third month further increased to 0.463.

Control group (Resorbable sutures): The mean plaque index at baseline was 0.552. At the first month, the mean plaque index was increased to 0.761 and at the third month further increased to 0.916.

Between group comparison: (Table 7a)

Mann- Whitney test was used to compare the difference at baseline, first month and third month. At baseline, the p-value was 0.123, which was statistically non-significant. At first month and third month, the p-values were 0.002 and 0.009 respectively, which were statistically significant ($p<0.05$).

Within group comparison: (Table 7b)

Table 7b: Comparison of mean plaque index score within the groups

		Baseline vs First month	**First month vs Third month**	**Baseline vs Third month**
p- value*	**Test Group** (Cyanoacrylate Tissue Adhesive)	0.309	0.693	0.178
	Control Group (Resorbable Sutures)	0.278	0.107	0.039*

***** $p<0.05 \rightarrow$ statistically significant

Mann whitney test was used to calculate the p-values for within group comparison.

Test group: The p-values were 0.309, 0.693 and 0.178 for baseline vs first month, first month vs third month and baseline vs third month respectively. All the three comparisons were not statistically significant.

Control group: The p-values were 0.278, 0.0.107 and 0.039 for baseline vs first month, first month vs third month and baseline vs third month respectively. The comparison for baseline vs third month was statistically significant but the other two comparisons were not statistically significant.

GINGIVAL INDEX: (Table 8a, 8b; Graph 2)

Table 8a: Comparison of mean gingival index score between test group (Cyanoacrylate tissue adhesive) and control group (Resorbable sutures) at various time periods

Parameter	Time Period	Group	Mean	Standard Deviation	p-value*
GINGIVAL INDEX	**Baseline**	**Test**	0.276	0.351	0.158
		Control	0.604	0.402	
	First Month	**Test**	0.339	0.139	0.002*
		Control	0.697	0.251	
	Third Month	**Test**	0.372	0.214	0.002*
		Control	0.772	0.276	

***** $p<0.05 \rightarrow$ statistically significant

Test group (Cyanoacrylate tissue adhesive): The mean gingival index at baseline was 0.276. At the first month, the mean plaque index was increased to 0.339 and at the third month further increased to 0.372.

Control group (Resorbable sutures): The mean gingival index at baseline was 0.604. At the first month, the mean plaque index was increased to 0.697 and at the third month further increased to 0.772.

Between group comparison: (Table 8b)

Mann- Whitney test was used to calculate the difference at baseline, first month and third month. At baseline, the p-value was 0.123 which was not statistically significant. At first month and third month, the p-values were 0.002 and 0.002 respectively, which were statistically significant ($p<0.05$)

Within group comparison: (Table 8b)

Table 8b: Comparison of mean gingival index score within the groups

		Baseline vs First month	**First month vs Third month**	**Baseline vs Third month**
p- value*	**Test Group** (Cyanoacrylate Tissue Adhesive)	0.066	0.921	0.071
	Control Group (Resorbable Sutures)	0.533	0.490	0.490

***** $p<0.05 \rightarrow$ statistically significant

Mann whitney test was used to calculate the p-values for within group comparison.

Test group: The p-values were 0.066, 0.921 and 0.071 for baseline vs first month, first month vs third month and baseline vs third month respectively. All the three comparisons were not statistically significant.

Control group: The p-values were 0.533, 0.490 and 0.490 for baseline vs first month, first month vs third month and baseline vs third month respectively. All the three comparisons were not statistically significant.

CLINICAL ATTACHMENT LEVEL: (Table 9a, 9b, 9c; Graph 3)

Table 9a: Mean and standard deviation of clinical attachment level at baseline, first month and third month (in mm) for both test group (cyanoacrylate tissue adhesive) and control group (Resorbable sutures)

Group	**Baseline**		**First Month**		**Third Month**	
	Mean	**SD**	**Mean**	**SD**	**Mean**	**SD**
Test Group (Cyanoacrylate Tissue Adhesive)	3.91	1.044	2.18	0.751	1.91	0.701
Control Group (Resorbable Sutures)	5.27	1.794	2.64	1.502	2.55	1.128

Test group (Cyanoacrylate tissue adhesive): The mean clinical attachment level at baseline was 3.91 mm which was reduced to 2.18 mm at the first month showing the mean reduction of 1.73 mm. At the third month, the clinical attachment level was 1.91mm showing the mean reduction of 2.00mm.

Control group (Resorbable sutures): The mean clinical attachment level at baseline was 5.27 mm which was reduced to 2.64 mm at the first month showing the mean reduction of 2.64 mm. At the third month, the mean clinical attachment level was 2.55 mm showing the mean reduction of 2.73 mm.

Between group comparison: (Table 9b)

Mann- Whitney test was used to compare the difference between baseline and first month, first month and third month, baseline and third month and their p-values were 0.077, 0.516 and 0.278 respectively, which was statistically not significant ($p>0.05$).

Table 9b: Comparison of clinical attachment level between test group (Cyanoacrylate tissue adhesive) and control group (Resorbable sutures) at various time periods (in mm)

Parameter	Time Period	Group	Mean	Standard Deviation	p-value*
CLINICAL ATTACHMENT LEVEL	**Baseline - First month**	**Test**	1.73	0.905	0.077
		Control	2.64	1.362	
	First month -Third month	**Test**	0.27	0.786	0.516
		Control	0.09	0.831	
	Baseline - Third month	**Test**	2.00	0.894	0.278
		Control	2.73	1.737	

***** $p<0.05 \rightarrow$ statistically significant

Within group comparison: (Table 9c)

Mann whitney test was used to calculate the p-values for within group comparison.

Test group: The p –values were 0.001, 0.372 and 0.001 for baseline vs first month, first month vs third month and baseline vs third month respectively. Except the comparison between first month and third month, the other two comparisons were statistically significant.

Control group: The p-values were 0.001, 0.918 and 0.000 for baseline vs first month, first month vs third month and baseline vs third month respectively. Except the comparison between first month and third month, the other two comparisons were statistically significant

Table 9c: Comparison of clinical attachment level at various time periods within the groups (in mm)

		Baseline vs First month	**First month vs Third month**	**Baseline vs Third month**
p- value*	**Test Group** (Cyanoacrylate Tissue Adhesive)	0.001*	0.372	0.001*
	Control Group (Resorbable Sutures)	0.001*	0.918	0.000*

***** $p<0.05 \rightarrow$ statistically significant

RECESSION DEPTH: (Table 10a, 10b, 10c; Graph 4)

Table 10a: Mean and standard deviation of recession depth at baseline, first month and third month (in mm) for both test group (cyanoacrylate tissue adhesive) and control group (Resorbable sutures)

Group	**Baseline**		**First Month**		**Third Month**	
	Mean	**SD**	**Mean**	**SD**	**Mean**	**SD**
Test Group (Cyanoacrylate Tissue Adhesive)	3.18	0.405	0.82	0.874	0.91	0.701
Control Group (Resorbable Sutures)	4.18	1.834	1.27	1.489	1.55	1.128

Test group (Cyanoacrylate tissue adhesive): The mean recession depth at baseline was 3.18mm which was reduced to 0.82 mm at the first month showing the mean reduction of

2.36mm. At the third month, the mean recession depth was 0.91mm showing the mean reduction of 2.27mm.

Control group (Resorbable sutures): The mean recession depth at baseline was 4.18mm which was reduced to 1.27 mm at the first month showing the mean reduction of 2.91mm. At the third month, the mean recession depth was 1.55mm showing the mean reduction of 2.64mm.

Between group comparison: (Table 10b)

Mann- Whitney test was used to compare the difference between baseline and first month, first month and third month, baseline and third month, and their p-values were 0.238, 0.534 and 0.560 respectively, which was statistically non-significant ($p>0.05$).

Table 10b: Comparison of recession depth between test group (Cyanoacrylate tissue adhesive) and control group (Resorbable sutures) at various time periods (in mm)

Parameter	Time Period	Group	Mean	Standard Deviation	p-value*
RECESSION DEPTH	**Baseline - First month**	**Test**	2.36	0.924	0.238
		Control	2.91	1.514	
	First month -Third month	**Test**	-0.09	0.701	0.534
		Control	-0.27	0.647	
	Baseline - Third month	**Test**	2.27	0.647	0.560
		Control	2.64	1.690	

***** $p<0.05 \rightarrow$ statistically significant

Within group comparison:

Table 10c: Comparison of recession depth at various time periods within the groups (in mm)

		Baseline vs First month	**First month vs Third month**	**Baseline vs Third month**
p- value*	**Test Group** (Cyanoacrylate Tissue Adhesive)	0.000*	0.725	0.000*
	Control Group (Resorbable Sutures)	0.001*	0.476	0.000*

***** $p<0.05$ → statistically significant

Mann whitney test was used to calculate the p-values for within group comparison.

Test group: The p-values were 0.000, 0.725 and 0.000 for baseline vs first month, first month vs third month and baseline vs third month respectively. Except the comparison between first month and third month, the other two comparisons were statistically significant.

Control group: The p-values were 0.001, 0.476 and 0.000 for baseline vs first month, first month vs third month and baseline vs third month respectively. Except the comparison between first month and third month, the other two comparisons were statistically significant

RECESSION WIDTH: (Table 11a, 11b, 11c; Graph 5)

Table 11a: Mean and standard deviation of recession width at baseline, first month and third month (in mm) for both test group (cyanoacrylate tissue adhesive) and control group (Resorbable sutures)

Group	**Baseline**		**First Month**		**Third Month**	
	Mean	**SD**	**Mean**	**SD**	**Mean**	**SD**
Test Group (Cyanoacrylate Tissue Adhesive)	2.73	0.647	1.45	1.293	1.64	1.120
Control Group (Resorbable Sutures)	3.09	0.539	1.55	1.508	2.27	1.191

Test group (Cyanoacrylate tissue adhesive): The mean recession width at baseline was 2.73 mm which was reduced to 1.45 mm at the first month showing the mean reduction of 1.27 mm. At the third month the mean recession width was slightly increased to1.64 mm

Control group (Resorbable suture): The mean recession depth at baseline was 3.09 mm which was reduced to 1.55 mm at the first month showing the mean reduction of 1.55 mm. At the third month, the recession depth was slightly increased to 2.27 mm

Between group comparison: (Table 11b)

Mann- Whitney test was used to compare the difference between baseline and first month, first month and third month, baseline and third month and their p-values were 0.684, 0.139 and 0.553 respectively, which were statistically non-significant ($p>0.05$)

Table 11b: Comparison of recession width between test group (Cyanoacrylate tissue adhesive) and control group (Resorbable sutures) at various time periods (in mm)

Parameter	Time Period	Group	Mean	Standard Deviation	p-value*
RECESSION WIDTH	**Baseline - First month**	**Test**	1.27	1.489	0.684
		Control	1.55	1.572	
	First month - Third month	**Test**	-0.18	1.250	0.139
		Control	-0.73	1.104	
	Baseline - Third month	**Test**	1.09	1.375	0.553
		Control	0.82	1.471	

***** $p<0.05$ → statistically significant

Within group comparison: (Table 11c)

Table 11c: Comparison of recession width at various time periods within the groups (in mm)

		Baseline vs First month	**First month vs Third month**	**Baseline vs Third month**
p- value*	**TEST GROUP** (Cyanoacrylate tissue adhesive)	0.020*	0.807	0.014*
	CONTROL GROUP (Resorbable suture)	0.009*	0.272	0.051

***** $p<0.05$ → statistically significant

Mann whitney test was used to calculate the p-values for within group comparison.

Test group: The p-values were 0.020, 0.807 and 0.014 for baseline vs first month, first month vs third month and baseline vs third month respectively. Except the comparison

between first month and third month, the other two comparisons were statistically significant.

Control group: The p-values were 0.009, 0.272 and 0.051 for baseline vs first month, first month vs third month and baseline vs third month respectively. Except the comparison between first month and third month, the other two comparisons were statistically significant.

THICKNESS OF KERATINIZED GINGIVA: (Table 12a, 12b, 12c; Graph 6)

Table 12a: Mean and standard deviation of thickness of keratinized gingiva at baseline, first month and third month (in mm) for both test group (cyanoacrylate tissue adhesive) and control group (Resorbable sutures)

Group	**Base Line**		**First Month**		**Third Month**	
	Mean	**SD**	**Mean**	**SD**	**Mean**	**SD**
Test Group (Cyanoacrylate Tissue Adhesive)	0.332	0.22	0.662	0.378	0.607	0.34
Control Group (Resorbable Sutures)	0.514	0.477	1.063	0.559	0.936	0.522

Test group (Cyanoacrylate tissue adhesive): The mean thickness of keratinized gingiva at baseline was 0.375 mm which was increased to 0.662 mm at the first month showing the mean difference of 0.33 mm. At the third month, the mean thickness of keratinized gingiva was slighltly decreased to 0.607 mm showing the mean difference of 0.276 mm.

Control group (Resorbable suture): The mean recession depth at baseline was 0.514 mm which was increased to 1.063 mm at the first month showing the mean difference of 0.55 mm. At the third month, the thickness of keratinized gingiva was slightly reduced to 0.936 mm showing the mean difference of 0.422 mm.

Between group comparison: (Table 12b)

Table 12b: Comparison of thickness of keratinized gingiva between test group (Cyanoacrylate tissue adhesive) and control group (Resorbable sutures) at various time periods (in mm)

Parameter	Time Period	Group	Mean	Standard Deviation	p-value*
THICKNESS OF KERATINIZED GINGIVA	Baseline - First month	Test	-0.33	0.234	0.324
		Control	-0.55	0.453	
	First month -Third month	Test	0.055	0.063	0.070
		Control	0.127	0.100	
	Baseline - Third month	Test	-0.276	0.195	0.742
		Control	-0.422	0.435	

***** $p<0.05$ → statistically significant

Mann- Whitney test was used to compare the difference between baseline and first month, First month and third month, Baseline and third month and their p-values are 0.324, 0.070 and 0.742 respectively, which were statistically non-significant ($p>0.05$)

Within group comparison: (Table 12c)

Mann whitney test was used to calculate the p-values for within group comparison.

Test group: The p-values were 0.007, 0.511 and 0.010 for baseline vs first month, first month vs third month and baseline vs third month respectively. Except the comparison between first month and third month, the other two comparisons were statistically significant.

Control group: The p-values were 0.018, 0.340 and 0.049 for baseline vs first month, first month vs third month and baseline vs third month respectively. Except the comparison between first month and third month, the other two comparisons were statistically significant

Table 12c: Comparison of thickness of keratinized gingiva at various time periods within the groups (in mm)

		Baseline vs First month	**First month vs Third month**	**Baseline vs Third month**
p- value*	**TEST GROUP** (Cyanoacrylate tissue adhesive)	0.007*	0.511	0.010*
	CONTROL GROUP (Resorbable sutures)	0.018*	0.340	0.049*

***** $p<0.05 \rightarrow$ statistically significant

HEIGHT OF KERATINIZED GINGIVA: (Table 13a, 13b, 13c; Graph 7)

Table 13a: Mean and standard deviation of height of keratinized gingiva at baseline, first month and third month (in mm) for both test group (cyanoacrylate tissue adhesive) and control group (Resorbable sutures)

Group	**Baseline**		**First Month**		**Third Month**	
	Mean	**SD**	**Mean**	**SD**	**Mean**	**SD**
Test Group (Cyanoacrylate Tissue Adhesive)	2.00	0.894	4.09	0.539	4.00	0.632
Control Group (Resorbable Sutures)	1.64	0.924	4.55	1.440	4.18	1.537

Test group (Cyanoacrylate tissue adhesive): The mean height of keratinized gingiva at baseline was 2.0 mm which was increased to 4.09 mm at the first month showing the mean difference of 2.09 mm. At the third month, the mean height of keratinized gingiva was 4.00 mm showing the mean difference of 2.00 mm.

Control group (Resorbable suture): The mean height of keratinized gingiva at baseline was 1.64 mm which was increased to 4.55 mm at the first month showing the mean difference of 2.91mm. At the third month, the mean height of keratinized gingiva was 4.18mm showing the mean difference of 2.55 mm.

Between group comparison: (Table 13b)

Mann- Whitney test was used to compare the difference between baseline and first month, first month and third month, baseline and third month and their p-values were 0.061, 0.136 and 0.196 respectively, which were statistically non-significant ($p>0.05$)

Table 13b: Comparison of height of keratinized gingiva between test group (Cyanoacrylate tissue adhesive) and control group (Resorbable sutures) at various time periods (in mm)

Parameter	Time Period	Group	Mean	Standard Deviation	p-value*
RECESSION DEPTH	**Baseline - First month**	**Test**	-2.09	0.701	0.061
		Control	-2.91	1.446	
	First month -Third month	**Test**	0.09	0.302	0.136
		Control	0.36	0.505	
	Baseline - Third month	**Test**	-2.00	0.632	0.196
		Control	-2.55	1.635	

***** $p<0.05 \rightarrow$ statistically significant

Within group comparison: (Table 13c)

Mann whitney test was used to calculate the p-values for within group comparison.

Test group: The p-values were 0.000, 0.719 and 0.000 for baseline vs first month, first month vs third month and baseline vs third month respectively. Except the comparison between first month and third month, the other two comparisons were statistically significant.

Control group: The p-values were 0.001, 0.450 and 0.001 for baseline vs first month, first month vs third month and baseline vs third month respectively. Except the comparison between first month and third month, the other two comparisons were statistically significant.

Table 13c: Comparison of height of keratinized gingiva (mm) at various time periods within the groups

		Baseline vs First month	**First month vs Third month**	**Baseline vs Third month**
p- value*	**Test Group** (Cyanoacrylate Tissue Adhesive)	0.000*	0.719	0.000*
	Control Group (Resorbable Suture)	0.001*	0.450	0.001*

* $p<0.05$ → statistically significant

PERCENTAGE OF ROOT COVERAGE: (Table 14; Graph 8)

Table 14: Percentage of root coverage (%) for both the groups

PERCENTAGE OF ROOT COVERAGE	**Groups**	**% of root coverage (%)**
	Test Group	71.97
	Control Group	61.36

Test group: The percentage of root coverage achieved at 3 months was 71.97%

Control group: The percentage of root coverage achieved at 3 months was 61.36%

Graph 1

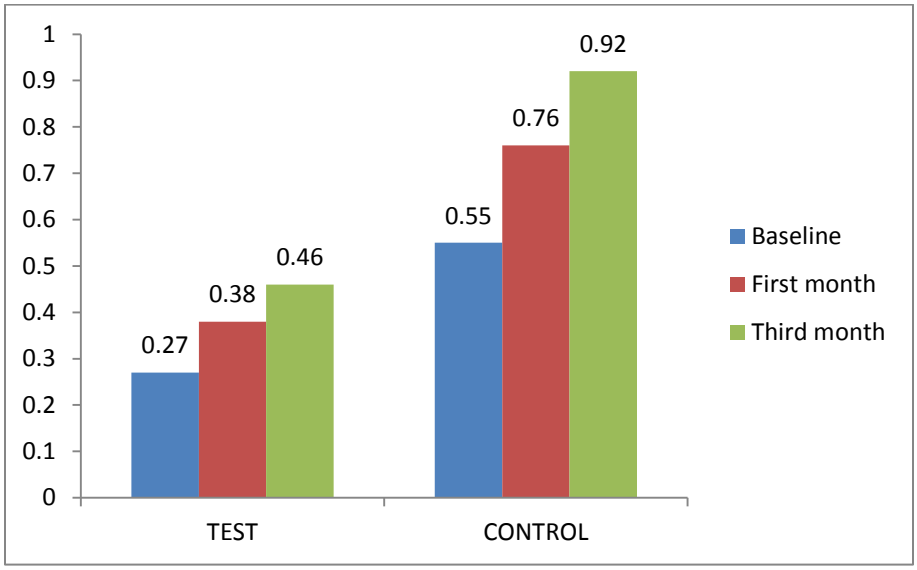

Graph 1 depicts mean plaque index scores at baseline, first month and third month for both test and control groups.

Graph 2

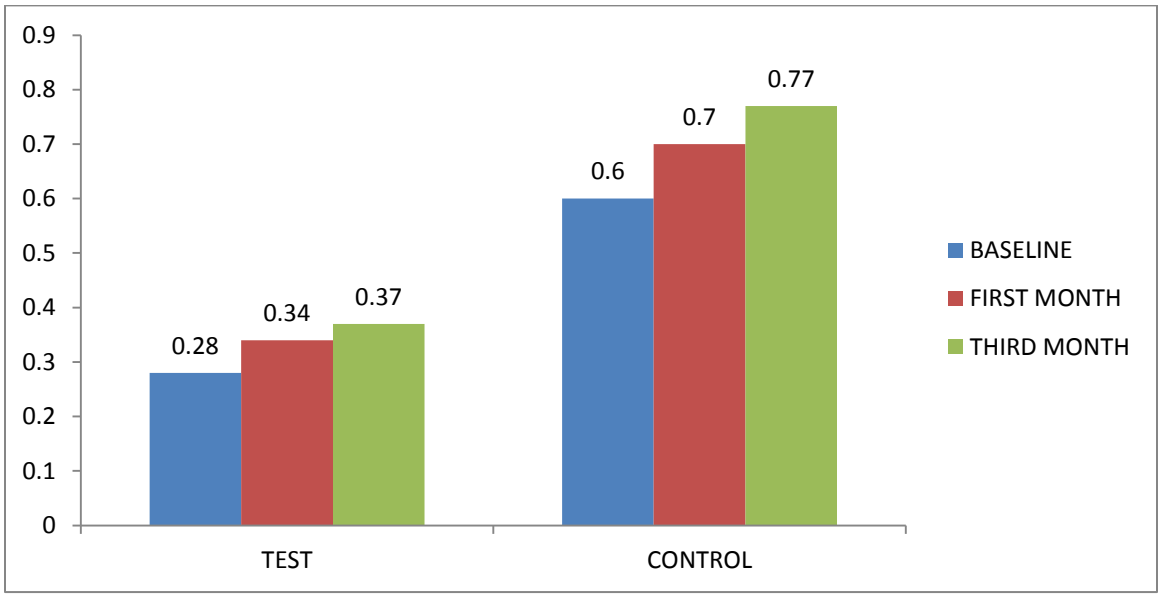

Graph 2 depicts the mean gingival index scores at baseline, first month and third month for both test and control groups.

Graph 3

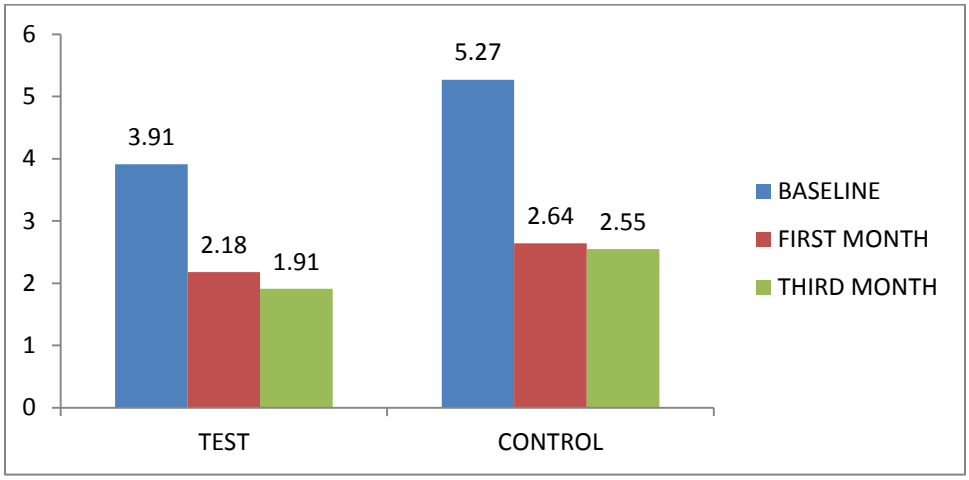

Graph 3 depicts the mean clinical attachment level at baseline, first month and third month for both test and control groups.

Graph 4

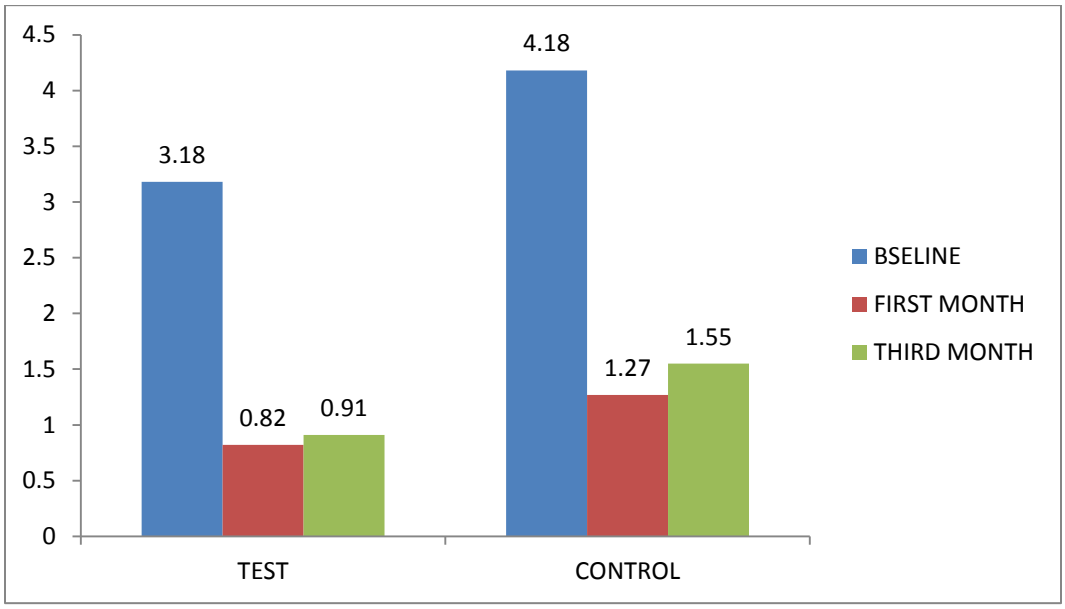

Graph 4 depicts the mean recession depth at baseline, first month and third month (in mm) for both test and control groups.

Graph 5

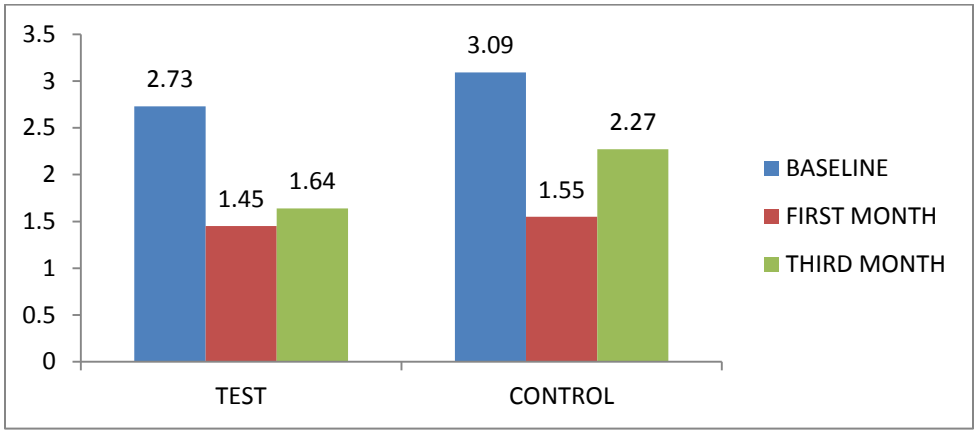

Graph 5 depicts the mean recession width at baseline, first month and third month for both test and control groups (in mm).

Graph 6

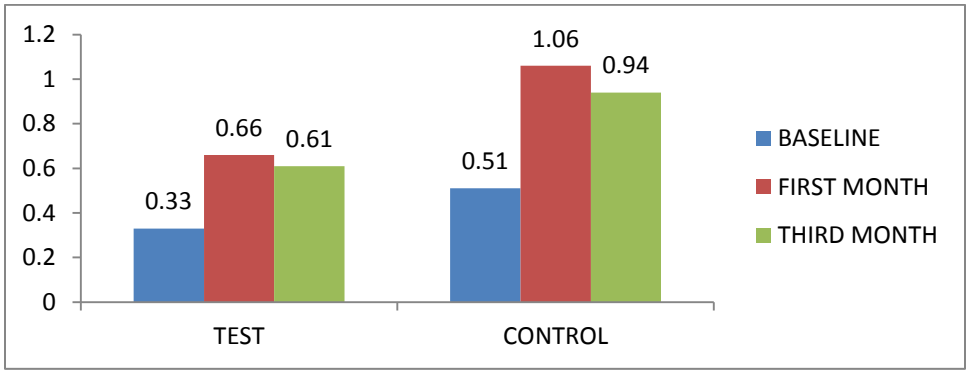

Graph 6 depicts mean thickness of keratinized gingiva at baseline, first month and third month for both test and control groups (in mm).

Graph 7

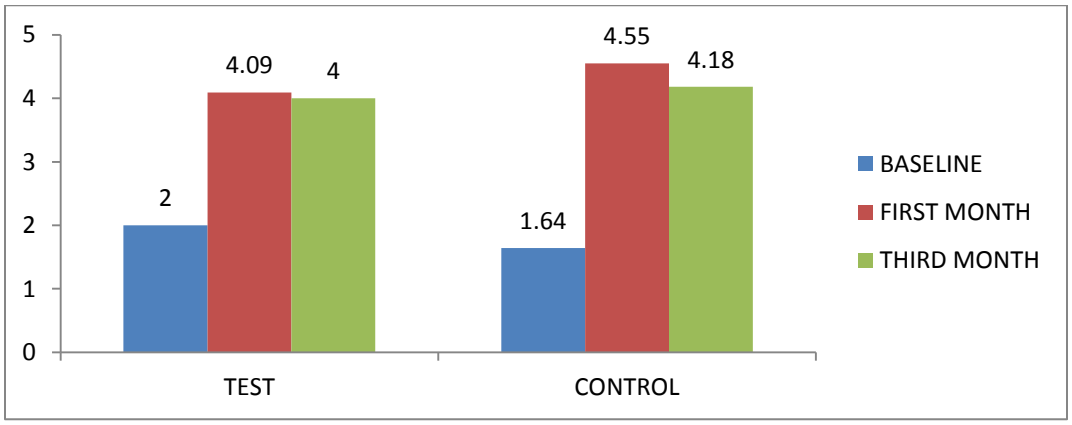

Graph 7 depicts mean height of keratinized gingiva at baseline, first month and third month for both the test and control groups (in mm).

Graph 8: Percentage of root coverage (%) for both the groups at the end of three months

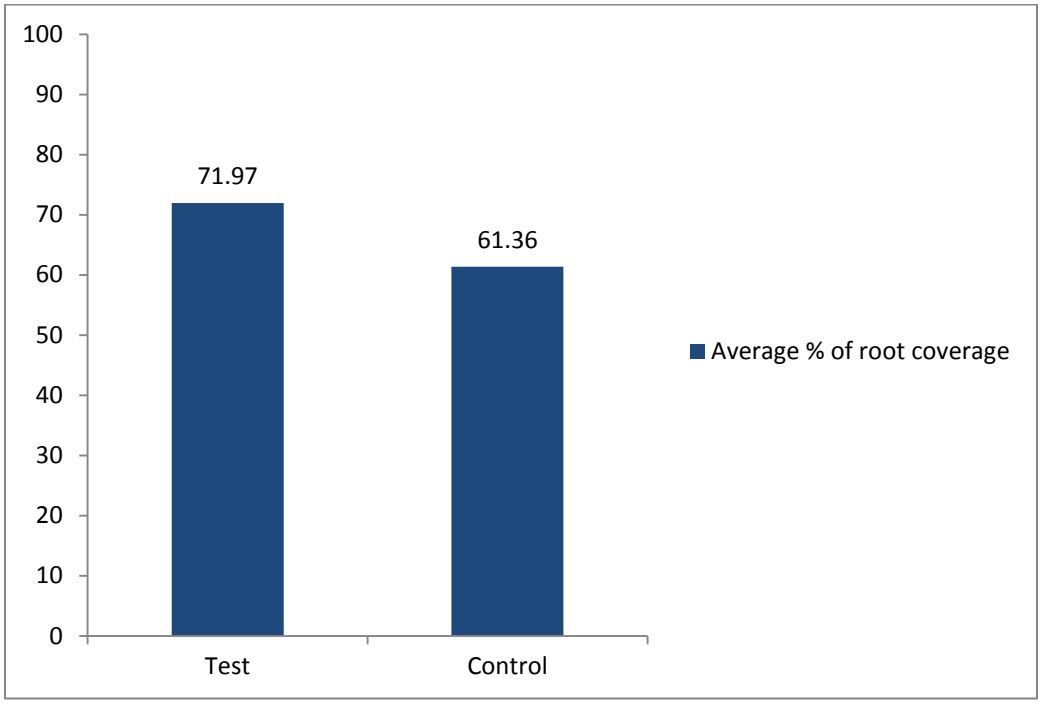

Discussion

DISCUSSION

The aim of the present study is to evaluate the clinical outcomes of lateral pedicle graft stabilized with cyanoacrylate tissue adhesive and resorbable sutures. Clinical parameters including plaque index, gingival index, probing pocket depth, clinical attachment level, and mucogingival parameters such as width and depth of gingival recession, height and thickness of the keratinized gingiva were assessed at baseline, first and third month, and percentage of root coverage at the end of three months subsequently through surgical correction.

In the present study, clinical periodontal parameters taken for assessment were found to be similar for both the test group (cyanoacrylate tissue adhesive) and control group (resorbable sutures) as evidenced by non-significant p-value except for plaque and gingival index.

Patients enrolled in the study maintained fairly good oral hygiene as observed by mean plaque index score at various time periods of observation in both control and test groups. The gingival status also are found to be healthy in control and test groups as revealed by mean gingival index at various time periods of observation.

The baseline mean values of plaque index and gingival index were statistically similar between the two groups whereas at the first month and third month, the difference between the groups were found to be statistically significant. Thus in the present study, the increased plaque index scores in control group (Resorbable sutures) may be related to difficulty in oral hygiene maintenance post-surgery. The suture threads may act as sites of plaque accumulation, which is in accordance with **Binnie and Forest (1974)**[35].

When comparing 3-0 silk suture and n-butyl-2-cyanoacrylate tissue adhesive in closure of intraoral surgical incisions, n-butyl-2-cyanoacrylate showed a better intimate healing with no gaps compared to use of silk suture and thus it was concluded that the use of n-butyl-2-cyanoacrylate reduces patient discomfort and irritation, and it is an easy and effective way in managing intraoral wounds.[63]

N-butyl-2-cyanoacrylate tissue adhesive results in faster initial wound healing as compared to silk sutures.[64] The gingival index is an indicator of inflammation and response of the tissues to both the materials. There was significant difference in the control group (resorbable sutures) at first month and third month when compared to test group (cyanoacrylate tissue adhesive) which can be attributed to the fact that suture material present within the tissue might have provoked inflammatory response, according to **Macht and krizek (1978)**[65] whereas **Levin (1980)**[66] related to suture material being a foreign protein is treated as such by the body and thus there may be increased inflammatory response.

Saska et al (2009)[62] analyzed and compared the compatibility of the adhesives ethylcyanoacrylate (Super Bonder) and butyl-cyanoacrylate (Histoacryl) and the healing of incisions in the dorsum of rats with suture and concluded that ethylcyanoacrylate and butyl-cyanoacrylate enable healing of incised tissues, without promoting inflammatory reaction. Moreover, adhesives facilitate the approximation of incised margins reducing the surgical time compared to the use of suture. These adhesives promoted lower inflammatory reaction in the subcutaneous layer of rats and caused no tissue necrosis. Therefore, cyanoacrylate adhesives may be used for wound synthesis, lacerations or cutaneous incisions.

Among all the variables, probing pocket depth remained unchanged at all periods of observations.

In the present study, the changes in depth and width of the gingival recession and clinical attachment level were found to show no difference on comparing the two groups between baseline and first month, first month and third month, baseline and third month, as evident by non-significant p-values. These findings reveal that cyanoacrylate tissue adhesive is a simple and reliable alternative material to resorbable sutures.

The height of keratinized tissue between various time periods revealed differences with non-significant p-values on comparing the two groups which can be related with the studies done by **Barbosa et al (2009)**[48] and **Gumus et al (2014)**[54].

A positive association exists between flap thickness and mean and complete root coverage. Thick tissue exhibits less clinical inflammation, resists trauma and subsequent recession and show predictable surgical procedure which can be correlated to the present study.[67] In the control group, the mean baseline value of thickness of keratinized gingiva which is of 0.51 mm has increased to 1.06 mm at first month and slightly reduced to 0.94 mm at third month. In the test group, the mean baseline value of 0.33 mm has increased to 0.66 mm and slightly reduced to 0.61 mm at third month.

The percentage of root coverage was 71.97% for the test group and 61.36% for the control group which is in accordance to various other studies. (**Smukler**[10], **Guinard et al**[68], **Espinel et al**[69] **and Wennstrom**[1])

When the keratinized tissue apical or lateral to the gingival defect is not adequate, free graft procedures have to be performed.[70,71] The use of free gingival grafts to treat

recession defects in patients with esthetic requests is not recommended because of the poor esthetic outcome and the low root coverage predictability but the pedicle flap provides root coverage predictability.[72]

When comparing the efficacy of single-stage lateral pedicle graft and coronally advanced flap techniques in the treatment of localized maxillary gingival recession defects, both flap designs were effective in treating recession defects resulting in similar improvements for percentage of root coverage, frequency of complete root coverage, and gain in clinical attachment level. The lateral pedicle flap resulted in significantly more gain in width of keratinized gingiva than the coronally advanced flap

Chemical root-surface conditioning using a variety of agents has been introduced in order to detoxify, decontaminate and demineralize the root surface, thereby removing the smear layer and exposing the collagenous matrix of dentin and cementum.

Tetracycline conditioning of root surface will not only selectively remove the smear layer, but may also act favourably by inhibiting collagenase activity and bone resorption and by its local antimicrobial effect.[74] The regenerative effects of root conditioning with tetracycline was also proved in other studies (**Chahal et al[52], Labahn et al[75]**). Thus in the present study, tetracycline HCl was used for conditioning the root surface in both the study groups for better periodontal wound healing.

Bhasker and Frisch[15] stated that there would be giant cell reaction if the cyanoacrylate material were to be implanted deep into the tissue, which was not the case in the study, as the material was placed superficially.

The drawback of the present study is that the cyanoacrylate tissue adhesive material is used only in the labial aspect in the anterior region where the material is easy to apply.

Due to lack of available published studies on the use of cyanoacrylate tissue adhesive in lateral pedicle graft procedure, the study could not be compared and analyzed.

Summary and Conclusion

SUMMARY AND CONCLUSION

The present study was conducted to evaluate clinical outcomes of lateral pedicle graft stabilized with either cyanoacrylate tissue adhesive or resorbable sutures.

A total of twenty- two patients satisfying the inclusion criteria were selected and randomly assigned to two groups.

Test - Lateral pedicle graft stabilized with cyanoacrylate tissue adhesive.

Control - Lateral pedicle graft stabilized with resorbable sutures.

Various clinical parameters like plaque index, gingival index, probing pocket depth, clinical attachment level, recession depth, recession width, thickness of keratinized gingiva and height of keratinized gingiva were recorded at baseline, 1st month and 3rd month. The percentage of root coverage was evaluated at the end of 3rd month.

From the results of the present study, we arrive at the following conclusion,

- Cyanoacrylate tissue adhesive is clinically effective in stabilization of lateral pedicle graft and can be used as an excellent alternative to resorbable sutures.
- Plaque index and gingival index were found to be statistically significant between test and control groups.
- Clinical attachment level, recession depth and width, height and thickness of keratinized gingiva were statistically similar between both the test and the control groups.
- The average percentage of root coverage achieved was 71.97% for the test group and 61.36 % for the control group.
- N-butyl-2-cyanoacrylate tissue adhesive was safe to use, without causing any immunologic or antigenic reactions in any of the patients

However further clinical trials including,

- with long term period of assessment
- with more number of clinical cases
- with the use of microsurgical techniques

might also be considered to improve the outcome of the study.

Bibliography

BIBLIOGRAPHY

1. Wennstrom. J. (1996). Mucogingival therapy. Ann Periodontol 1996;1:671-701.
2. Kanakamedala et al. Platelet-rich-fibrin, a novel root coverage approach. J Indian Soc Periodontol 2016;13(1):50-54.
3. Del Pizzo M, Modica F, Bethaz N, Priotto P, Romagnoli R. The connective tissue graft: a comparative clinical evaluation of wound healing at the palatal donor site. A preliminary study. J Clin Periodontol 2002;29(9):848-854.
4. Grupe HE. Modified technique for the sliding flap operation. J Periodontol 1966;37(6):491-495.
5. Valletta G, Matarasso S, Gagliardi G. Lateral sliding flaps in mucogingival surgery. Minerva Stomatol. 1978;27(4):231-244.
6. Caffesse RG, Guinard EA. Treatment of localized gingival recessions. Part IV. Results after three years. J Periodontol. 1980;51(3):167-170.
7. Caffesse RG, Kon S, Castelli WA, Nasjleti CE. Revascularization following the lateral sliding flap procedure. J Periodontol. 1984;55(6):352-358.
8. Sergediebert, Mamdouh M.Karima. Periodontal plastic surgery. Blackwell publishing company 1st ed. 2006. Chapter 7. Pedicle grafts: Rotational flaps and double-papilla procedure: 35-40.
9. Wilderman M.N, Wentz F.M. Repair of a dentogingival defect with a pedicle flap. J Periodontol 1965;35:218–231.
10. Smukler H. Laterally positioned mucoperiosteal pedicle grafts in the treatment of denuded roots. J Periodontol 1976;47:590-595.
11. Guinard EA, Caffese RG. Treatment of localized gingival recession part-I lateral sliding flap. J Periodontol 1978;49:351-356.

12. Rino Burkhardt & Niklaus P. Lang. Influence of suturing on wound healing. Periodontol 2000 2015;68:270–281.

13. Kulkarni S. Healing of periodontal flaps when closed with silk sutures and N-butyl cyanoacrylate: a clinical and histological study. Ind J Den Res 2007;18:72-7.

14. Wikesjo UME, Nilveus R. Periodontal repair in dogs: effect of wound stabilization on healing. J Periodontol 1990: 61:719–724.

15. Bhaskar S.N. and Frisch J. Use of cyanoacrylate adhesives in dentistry. J Am Dent Assoc 1968;77:831-837.

16. MS Kumar et al. Comparison between silk sutures and cyanoacrylate adhesive in human mucosa- a clinical and histological study. J Int Oral Health 2013;5(5):95-100.

17. Giray CB, Atasever A, Durgun B, Araz K. Clinical electron microscope comparison of silk sutures and n- butyl-2-cyanoacrylate in human mucosa. Aust Dent J 1997;42:225-228.

18. American Academy of Periodontology. Glossary terms in periodontology. Chicago: The American Academy Periodontology, 2001.

19. Fiorellini et al. Carranza's clinical periodontology. W. B. Saunders company. 10th edition. Chapter 22.Clinical features of gingivitis: 362-372.

20. Tugnait A, Clerehugh V. Gingival recession - its significance and management. J Dent 2001; 29(6):381-394.

21. Sullivan HC, Atkins JC: Free autogenous gingival grafts. III. Utilization of grafts in the treatment of gingival recession. Periodontics 1968;6(4)152-160.

22. Miller P. A classification of marginal tissue recession. Int J Periodontics Restorative Dent 1985;5:9.

23. Edward S Cohen. Atlas of cosmetic and reconstructive surgery. BC Decker Inc.3rd ed. 2007. Chapter 6.Mucogingival surgery: 45-85.

24. Mobley et al. Surgical tissue adhesives. Facial Plast Surg Clin N Am 2002;10:147-154.

25. G.J.Mattamal. U.S. FDA Perspective on the Regulation of Cyanoacrylate Polymer Tissue Adhesives in Clinical Applications. Materials Science Forum 2007;539-543:692-697.

26. Toriumi DM et al. Use of octyl-2-cyanoacrylate for skin closure in facial plastic surgery. Plast Reconstr Surg. 1998;102:2209–19.

27. Chellamani et al. Surgical Sutures: An overview J. Acad. Indus. Res.2013;1(12):778-782.

28. Edward S Cohen. Atlas of cosmetic and reconstructive surgery. BC Decker Inc.3rd ed. 2007. Chapter 3.Sutures and suturing: 15-28.

29. Sudha Salham. Textbook of gynecology. JP Medical Ltd. 1st ed. 2001. Chapter 64. Sutures and needles:506-511.

30. Kudur et al. Sutures and suturing techniques in skin closure. Indian J Dermatol Venereol Leprol 2009;75(4):425-434.

31. Craig et al. A biologic comparison of polyglactin 910 and polyglycolic acid synthetic absorbable sutures. Surg Gynecol Obstet 1975;141(1):1-10.

32. Wilderman et al. Histogenesis of repair after mucogingival surgery. J Periodontol 1960;31(4):283-299.

33. Bhaskar, S.N., Frisch, J., Margetis, P.M. and Leonard, F. Application of a new chemical adhesive in periodontic and oral surgery. Oral Surg 1966;22:526–535.

34. Frisch J. and Bhaskar SN. Free mucosal graft with tissue adhesives: Report of 17 cases. J Periodontol 1968; 39:190-195.

35. Binnie WH, Forrest JO. A study of tissue response to cyanoacrylate adhesive in periodontal surgery. J Periodontol 1974;45:619-25.

36. Forest JO. The use of cyanoacrylates in periodontal surgery. J Periodontol 1974;45:225-9.

37. Caton JG, Polson AM, Pini Prato GP, Bartolucci EG, Clauser C; Healing after application of tissue- adhesive material to denude and citric acid treated root surfaces. J Periodontol 1986; 57(6): 385-90.

38. Lafferty TA, Gher ME, Gray JL. Comparative SEM study on the effect of acid etching with tetracycline HCl or citric acid on instrumented periodontally involved human root surfaces. J Periodontol 1993;64:689-93.

39. Madison JG, Hokett SD. The effects of different tetracyclines on the root surface of instrumented, periodontally involved human teeth: A comparative scanning electron microscope study. J Periodontol 1997;68:739-45.

40. Grisdale J. The use of cyanoacrylates in periodontal therapy. J Can Dent Assoc 1998; 64: 632-633.

41. Bouchard et al. Decision-making in aesthetics: root coverage revisited. Periodontol 2000 2001;27:97-120.

42. Jahagirnezhad. Semilunar coronally repositioned flap for the treatment of gingival recession with and without tissue adhesives: a pilot study. Journal of Dentistry of Tehran University of Medical Sciences 2006; 3(1):36-39.

43. Kulkarni S. Healing of periodontal flaps when closed with silk sutures and N-butyl cyanoacrylate: a clinical and histological study. Ind J Den Res 2007;18:72-7.

44. Chen WL, Lin CT, Hsieh CY, Tu IH, Chen WY, Hu FR. Comparison of the bacteriostatic effects, corneal cytotoxicity, and the ability to seal corneal incisions among three different tissue adhesives. Cornea 2007;26:1228-34.

45. Jathal et al. Use of fi brin glue in periodontal flap surgery. J Indian Soc Periodontol 2008;12(1):21-25.

46. Shetty B, Dinesh A, Seshan H. The comparative effects of tetracyclines and citric acid on dentin root surface of periodontally involved human teeth: A scanning electron microscope study. J Indian Soc Periodontol 2008;12:8-15.

47. Ghoreishian M, Gheisari R, Fayazi M. Tissue adhesive and suturing for closure of the surgical wound after removal of impacted mandibular third molars: a comparative study. Oral Surg Oral Med Oral Pathol Oral Radiol Endod 2009;108:e14-6.

48. Barbosa et al. Dimensional changes between free gingival grafts fixed with ethyl cyanoacrylate and silk sutures J Int Acad Periodontol 2009;11(2): 170-176.

49. Ashok KP, Shobha PM. A comparative scanning electron microscope study on the effect of acid etching with citric acid, tetracycline hydrochloride and EDTA on instrumented, periodontally involved root surfaces. Indian J Stomatol 2010;1:61-6.

50. Guncu et al. Vertical and horizontal dimensional evaluation of sutureless free gingival grafts. Clin Dent Res 2012; 36(2):29-35.

51. Ruchi et al. Root coverage with laterally sliding flap Case Series. Indian J Dent Adv 2013; 5(2): 1226-1229.

52. Chahal et al. Effect of citric acid, tetracycline, and doxycycline on instrumented periodontally involved root surfaces: A SEM study. J Indian Soc Periodontol 2014;18:32-37.

53. Rajkarnikar J. Efficacy of lateral pedicle graft in the treatment of isolated gingival recession defects**.** Inter J of Pharm Sci Inven 2014;3(1):46-50.

54. Gumus et al. Graft stabilization with cyanoacrylate decreases shrinkage of free gingival grafts. Aus Dent J 2014; 59: 1–8.

55. Kumar A, Jan SM, Behl R, Nazir R, Khairat RU, Ganaie TA. Laterally positioned flap with periosteal graft for the treatment of gingival recession, novel technique - A pilot study. IAIM 2016; 3(6): 192-198.

56. Silness J, Loe H. Periodontal disease in pregnancy II. Correlation between oral hygiene and periodontal conditions. Acta Odont Scand 1964;24:747-759.

57. Loe H, Silness J. Periodontal disease in pregnancy. I. prevalence and severity. Acta Odont Scand 1963;21:533-551.

58. Skurska et al. The assessment of the influence of vertical incisions on the aesthetic outcome of the Miller class I and II recession treatment: a split-mouth study; J Clin Periodontol 2015; 42:756–763.

59. Aroca et al. Clinical evaluation of a modified coronally advanced flap alone or in combination with a platelet-rich fibrin membrane for the treatment of adjacent multiple gingival recessions: a 6-month study. J Periodontol 2009.80(2);244-252.

60. Shieh AT et al. Development and clinical evaluation of a root coverage procedure using a collagen barrier membrane. J Periodontol 1997;68:770-8.

61. Periodontal Literature Reviews. 1st ed. J Periodontol 1996; current volume:145-203.

62. Sybele Saska, Ana Maria Minarelli Gaspar, Eduardo Hochuli-Vieira. Cyanoacrylate adhesives for the synthesis of soft tissue. An Bras Dermatol 2009;84(6):585-592.

63. Hesham. S. Khalil et al. Healing of oral surgical wounds using 3/0 silk suture and n-butyl cyanoacrylate tissue adhesive. EDJ 2009 Oct;55(4.2):2607.

64. Kulkarni S, Chava V. Comparison of Cyanoacrylates and sutures on healing of oral wounds: An animal model study. Indian J Dent Res 2003;14(4):254-8.

65. Macht SD, Krizek TJ. Sutures and suturing: Current concepts. J Oral Surg 1978:36:710-3.

66. Levin MP. Periodontal suture materials and surgical dressings. Dent Clin North Am 1980;24:767-81.

67. Hwang et al. Flap thickness as a predictor of root coverage: a systematic review. J Periodontol 2006;77(10):1625-1634.

68. Guinard EA, Caffese RG. Treatment of localized gingival recession part-I lateral sliding flap. J Periodontol 1978; 49 :351-356.

69. Espinel M, Caffesse R. Comparison of the results obtained with the laterally positioned pedicle sliding flap-revised technique and the lateral sliding flap with a free gingival graft technique in the treatment of localized gingival recessions. Int J Periodontics Restorative Dent 1981: 1:30–37.

70. Allen EP, Miller PD Jr. Coronal positioning of existing gingiva: short term results in the treatment of shallow marginal tissue recession. J Periodontol 1989: 60: 316–319.

71. Caffesse R, Kon S, Castelli W, Nasjleti C. Revascularization following the lateral sliding flap procedure. J Periodontol 1984: 55: 352–358.

72. Zuchelli et al. Periodontal plastic surgery. Periodontol 2000 2015;68:333–368.

73. Santana et al. Clinical evaluation of single-stage advanced versus rotated flaps in the treatment of gingival recessions. J Periodontol 2010;81(4):485- 492.

74. Hanes P, Polson A, Ladenheim S. Cell and fiber attachment to demineralized dentin from normal root surfaces. J Periodontol 1985: 56: 752–765.

75. Labahn R, Fahrenbach W, Clark S, Lie T, Adams D. Root dentin morphology after different modes of citric acid and tetracycline hydrochloride conditioning. J Periodontol 1992;63:303–309.

Annexure

BEST DENTAL SCIENCE COLLEGE
ULTRA TRUST

69/1A, Ultra Nagar, Madurai - Chennai Highway,
Madurai - 625 104. Ph : 0452 2423290 / 91

Trust Regd.office : 4/235, College Road, Thasildhar Nagar, Madurai - 625020. Ph : 2534593, 2534701 Fax : 91-452-2539828

ANNEXURE-I

Ref:UT:BDSC:IRB-EC/2014 Date:18.11.2014

From

Institutional Review Board-Ethical committee,
Best dental science college,
Madurai.

To

The Controller of Examinations,
The Tamil Nadu DR.MGR Medical University,
No.69, Anna salai,
Guindy,
Chennai-600032

Sir/Madam

The Dissertation topic titled "CLINICAL EVALUATION OF LATERAL PEDICLE GRAFT STABILIZED WITH CYANOACRYLATE AND RESORBABLE SUTURES – A RANDOMIZED CONTROLLED TRIAL" submitted by DR.M.JEEVITHA postgraduate student has been approved by Institutional Review Board of Best Dental Science College on 18.11.2014.

DR.K.S PREM KUMAR.M.D.S.,
VICE PRINCIPAL
MEMBER SECRETARY
INSTITUITONAL REVIEW BOARD-ETHICAL COMMITTEE
BEST DENTAL SCIENCE COLLEGE
MADURAI

DR.PURUSHOTHAM MANVI.M.D.S.,
PRINCIPAL
BEST DENTAL SCIENCE COLLEGE
MADURAI

ANNEXURE 2

INFORMATION SHEET

We are conducting a study on CLINICAL EVALUATION OF LATERAL PEDICLE GRAFT STABILIZED WITH CYANOACRYLATE AND RESORBABLE SUTURES – A RANDOMIZED CONTROLLED TRIAL.

The identity of the patients participating in the research will be kept confidential throughout the study. In the event of any publication or presentation resulting from the research, no personally identifiable information will be shared.

Taking part in the study is voluntary. You are free to decide whether to participate in the study or to withdraw at any time; your decision will not result in any loss of benefits to which you are otherwise entitled.

The results of the special study may be intimated to you at the end of the study period or during the study if anything is found abnormal which may aid in the management or treatment.

Name of the patient Signature / Thumb impression

ANNEXURE 3

DIVISION OF PERIODONTICS

BEST DENTAL SCIENCE COLLEGE & HOSPITAL

DR.M.G.R MEDICAL UNIVERSITY

CLINICAL EVALUATION OF LATERAL PEDICLE GRAFT STABILIZED WITH CYANOACRYLATE AND RESORBABLE SUTURES – A RANDOMIZED CONTROLLED TRIAL

Name: Age/Sex Op.No: Date:

Address:

I, _____ aged _____ have been informed about my role in the study.

1. I agree to give my personal details like name, age, sex, address, previous dental history & the details required for the study to the best of my knowledge.

2. I will co-operate with the dentist for my intra oral examination & extra oral examination.

3. I will follow the instructions given to me by the doctor during study.

4. I permit the dentist to take photos, intraoral radiographs & I accept to undergo surgical procedures as required for the study.

5. If unable to participate into study for reasons unknown, I can withdraw from the study.

In my full consciousness & presence of mind, after understanding all the procedures in my own language, I am willing & give my consent to participate in this study.

Name of the patient: Name of the investigator:

Signature/Thumb impression Signature

ஒப்புதல் படிவம்

திரு/திருமதி/செல்வி_____ வயது_____

த/க/பெ_____ என்ற முகவரியில் வசித்து வரும் நான் முழு சுயநினைவுடனும், மனப்பூர்வமாகவும், யாருடைய தூண்டுதலின் பெயரில் அல்லாமலும் உறுதி கூறுவது என்னவென்றால்,

மருத்துவர் கூறிய ஈறுஅறுவை சிகிச்சையை செய்து கொள்ள சம்மதிக்கிறேன். எனக்கு செயல் முறையினை பற்றி நன்கு விளக்கப்பட்டிருக்கிறது. மேலும் இதில் வரும் நன்மை தீமையை என் சுயநினைவோடு புரிந்து கொண்டேன். இதன் மூலம் என்னுடைய மனப்பூர்வமான சம்மதத்தினை உறுதிபடுத்துகிறேன். .

இடம்: கையொப்பம்

தேதி:

ANNEXURE 4

DIVISION OF PERIODONTICS

BEST DENTAL SCIENCE COLLEGE AND HOSPITAL

DR.MGR MEDICAL UNIVERSITY

CLINICAL EVALUATION OF LATERAL PEDICLE GRAFT STABILIZED WITH CYANOACRYLATE AND RESORBABLE SUTURES

PROFORMA

Op No: **SL No:**

Date:

Name: **Age/ Sex:**

Address: **Occupation:**

Chief Complaint:

Personal History:

Type of Recession (Miller's):

PLAQUE INDEX (SILNESS & LOE 1964) - BASELINE

B														
L														

B														
L														

Score = [ ] **EXCELLENT/GOOD/ FAIR / POOR**

GINGIVAL INDEX (LOE AND SILNESS 1963) - BASELINE

B														
L														

B														
L														

Score = [ ] **MILD GINGIVITIS/MODERATE GINGIVITIS/SEVERE GINGIVITIS**

PLAQUE INDEX (SILNESS & LOE 1964) – 1st MONTH

B														
L														

B														
L														

Score = [ ] **EXCELLENT/GOOD/ FAIR / POOR**

GINGIVAL INDEX (LOE AND SILNESS 1963) – 1st MONTH

B														
L														

B														
L														

Score = [ ] **MILD GINGIVITIS/MODERATE GINGIVITIS/SEVERE GINGIVITIS**

PLAQUE INDEX (SILNESS & LOE 1964) – 3rd MONTH

B														
L														

B														
L														

Score = [ ] **EXCELLENT/GOOD/ FAIR / POOR**

GINGIVAL INDEX (LOE AND SILNESS 1963) – 3rd MONTH

B														
L														

B														
L														

Score = [ ] **MILD GINGIVITIS/MODERATE GINGIVITIS/SEVERE GINGIVITIS**

PARAMETERS

PARAMETERS	BASELINE	1st MONTH	3rd MONTH
PLAQUE INDEX			
GINGIVAL INDEX			
PROBING POCKET DEPTH			
CLINICAL ATTACHMENT LOSS			
GINGIVAL RECESSION WIDTH			
GINGIVAL RECESSION DEPTH			
THICKNESS OF KERATINIZED GINGIVA			
HEIGHT OF KERATINIZED GINGIVA			

DATE	TREATMENT DONE	STAFF INCHARGE

ANNEXURE 5

MASTER CHART

TEST GROUP

BASELINE

S.NO	PI	GI	PPD	CAL	RW	RD	TKG	HKG
1	0.79	1	1	4	2	3	0.58	4
2	0.55	0.95	1	4	3	3	0.18	2
3	0.205	0.161	1	5	3	4	0.21	2
4	0.214	0.116	1	4	3	3	0.32	2
5	0.151	0.071	1	4	3	3	0.24	2
6	0.152	0.063	1	5	2	3	0.18	1
7	0.366	0.152	1	4	2	3	0.17	1
8	0.482	0.027	1	4	3	3	0.87	2
9	0.045	0.107	1	4	4	3	0.45	3
10	0	0.143	1	1	2	3	0.22	1
11	0	0.25	1	4	3	4	0.23	2

FIRST MONTH

S.NO	PI	GI	PPD	CAL	RW	RD	TKG	HKG
1	0.41	0.44	1	3	2	2	0.72	5
2	0.35	0.32	1	3	3	2	0.28	4
3	0.643	0.322	1	3	3	2	0.36	4
4	0.116	0.527	1	1	0	0	0.45	4
5	0.348	0.027	1	2	2	1	0.47	4
6	0.429	0.42	2	2	2	0	0.49	4
7	0.143	0.223	2	2	0	0	0.57	4
8	0.536	0.402	2	3	1	1	1.67	4
9	0.795	0.438	2	2	0	0	0.65	5
10	0.188	0.223	1	1	0	0	0.86	4
11	0.17	0.384	1	2	3	1	0.76	3

THIRD MONTH

S.NO	PI	GI	PPD	CAL	RW	RD	TKG	HKG
1	0.77	0.8	1	3	2	2	0.71	5
2	0.35	0.54	1	2	2	1	0.36	4
3	0.259	0.321	1	3	3	2	0.33	4
4	0.473	0.446	1	2	3	1	0.42	4
5	0.134	0.018	1	2	2	1	0.42	4
6	0.491	0.348	1	2	2	1	0.45	3
7	0.179	0.269	1	2	2	1	0.53	4
8	1.223	0.348	1	1	0	0	1.54	4
9	0.83	0.589	1	1	0	0	0.53	5
10	0.134	0.196	1	1	0	0	0.76	4
11	0.25	0.214	1	2	2	1	0.63	3

CONTROL GROUP

BASELINE

S.NO	PI	GI	PPD	CAL	RW	RD	TKG	HKG
1	0.713	0.806	1	5	3	4	1.66	3
2	0.063	0.018	1	4	4	3	0.66	3
3	0.036	0.053	2	5	4	3	0.48	2
4	1.018	0.777	1	4	3	3	0.45	2
5	0.113	0.352	1	5	3	4	1.12	2
6	0.223	0.705	1	4	3	3	0.35	1
7	0.185	0.139	1	5	3	4	0.24	1
8	1.148	1.055	1	10	3	9	0.16	0
9	0.902	1.196	1	7	3	6	0.18	1
10	1.08	0.777	1	4	3	3	0.2	2
11	0.596	0.764	1	5	2	4	0.15	1

FIRST MONTH

S.NO	PI	GI	PPD	CAL	RW	RD	TKG	HKG
1	1.028	0.926	2	2	0	0	1.94	6
2	0.973	0.482	1	2	2	1	1.72	5
3	0.42	0.509	1	1	0	0	1.18	6
4	0.634	0.188	1	4	3	3	0.53	3
5	0.602	0.761	2	2	0	0	1.26	5
6	0.723	0.83	2	2	0	0	1.23	5
7	0.435	0.462	1	4	3	3	0.16	1
8	0.935	0.926	2	6	3	4	0.46	5
9	0.634	0.75	1	3	3	2	0.57	5
10	1.071	0.852	1	2	3	1	1.28	5
11	0.913	0.98	1	1	0	0	1.36	4

THIRD MONTH

S.NO	PI	GI	PPD	CAL	RW	RD	TKG	HKG
1	1.046	1.093	1	1	0	0	1.72	6
2	0.83	0.589	1	3	3	2	1.56	4
3	1.214	0.928	1	1	0	0	0.86	6
4	0.339	0.277	1	4	3	3	0.36	2
5	0.92	0.568	1	2	2	1	1.22	4
6	0.75	0.678	1	2	2	1	1.17	4
7	0.759	0.685	1	4	3	3	0.16	1
8	1.204	1.018	1	4	3	3	0.34	5
9	1.089	0.839	1	3	3	2	0.53	5
10	0.83	0.598	1	2	3	1	1.23	5
11	1.096	1.221	1	2	3	1	1.14	4

ANNEXURE 6

RANDOMIZATION OF SAMPLES

SUBJECT NO.	RANDOM SUBJECTS FOR TWO GROUPS
1	1
2	0
3	0
4	0
5	0
6	0
7	0
8	0
9	1
10	1
11	0
12	0
13	1
14	0
15	0
16	1
17	1
18	1
19	1
20	1
21	1
22	1