ROLE OF OPTICAL COHERENCE TOMOGRAPHY IN MANAGEMENT OF POST OPERATIVE CYSTOID MACULAR EDEMA

Dissertation submitted to

THE TAMIL NADU M.G.R. MEDICAL UNIVERSITY
CHENNAI, INDIA.

M.S. DEGREE EXAMINATION
BRANCH – III, OPHTHALMOLOGY

MARCH 2007

ACKNOWLEDGEMENT

I would like to express my profound gratitude to Professor and Director **Dr. C.A. Nelson Jesudasan**, M.S., D.O.M.S., FRCS (Edin. & Glas.), for having assigned me this very interesting topic, for providing me all the necessary facilities and guidance to enable me to complete my study.

I am really indebted to **Prof. Dr. M. Rajamohan**, M.S., D.O., C.C.E.H. (London) for being my guide in this study. His corrections and criticisms moulded every step in this study.

I would like to thank **Prof. Dr. Amjad Salman**, M.S. (Oph.), Registrar, who was the co-guide for this study. I express my gratitude to his customary patience and guidance taken in clarifying my various doubts and rendering his valuable advice.

The wisdom and guidance of **Prof. Dr. V.M.L. Loganathan**, M.S., D.O., had a definite impact on the study.

I am also grateful to **Dr. Prathiba**, M.S., D.O., Reader, **Dr. Vanila**, M.S., DNB, Reader and all Retina Department Staff for their guidance and inspiration throughout this study.

I would like to thank **Mr. S.A. Shafi**, ASP Computers, Trichy who helped in preparing the manuscript and printing.

I would like to thank my **Parents,** brother **Dr. A. Karthik Kumar**, my wife **Mrs. Sneha**, for their prayers and moral support.

I also thank all teachers, my colleagues, **Mr. R. Venkat Raman**, Asst. Registrar, **Mr. Rajkumar**, Librarian, and all who have helped and supported during this study.

Finally I am indebted to all my patients for their sincere co-operation for completion of the study.

CONTENTS

INTRODUCTION

High resolution cross sectional imaging of the retina is useful for identifying, monitoring and quantitatively assessing macular diseases. Optical Coherence Tomography (OCT) is a new medical diagnostic imaging technology which can perform micron resolution, cross sectional or tomographic imaging in biological tissues. Cross sectional images of the retina are obtained at the resolution of 10 microns. OCT uses low coherence or white light interferometry to perform high resolution measurements and imaging. The infra red light beam has a wavelength of 820 nm.

Post Operative Cystoid Macular Edema (CME) frequently occurs following cataract surgery. It can also occur following YAG capsulotomy, Cryo, Laser photocoagulation, scleral buckling and Penetrating Keratoplasty (PKP). Cystoid macular edema is the result of accumulation of fluid in the outer plexiform and inner nuclear layers of the retina centrered about the foveala and formation of fluid filled cyst like changes. OCT offers an objective test for quantitative evaluation of patients with CME. OCT can quantitatively assess retinal thickness and demonstrate any associated RPE structural anomalies beneath edematous retina which can be obscured by leakage on angiography.

Measurement of retinal thickness by OCT correlate more strongly with visual acuity than presence of leakage on angiography.

The aim of the present dissertation is to study optical coherence tomographic features in post operative CME and monitor it with OCT.

AIM OF THE STUDY

1. To study the optical coherence tomography features of post operative CME.
2. To assess the role of optical coherence tomography in monitoring, diagnosis and followup of cystoid macular edema.

REVIEW OF LITERATURE

Anatomy of the Macula

Macula refers to that part of central retina having a diameter of 5.5 mm and limited by the outer boundary of the perifovea where ganglion cells are reduced to single layer.

Parts of the Macula

- Umbo
- Foveola
- FAZ
- Fovea
- Parafoveal area
- Perifoveal area

Umbo

It is a tiny depression in the very centre of the foveola which corresponds to ophthalmoscopically visible foveolar reflex.

Foveola (350 µ)

It is the small central region in which thickness of retina is reduced so as to contain only photoreceptors, glial cells and Muller's cells.

Fig. 1. Topography of Macula

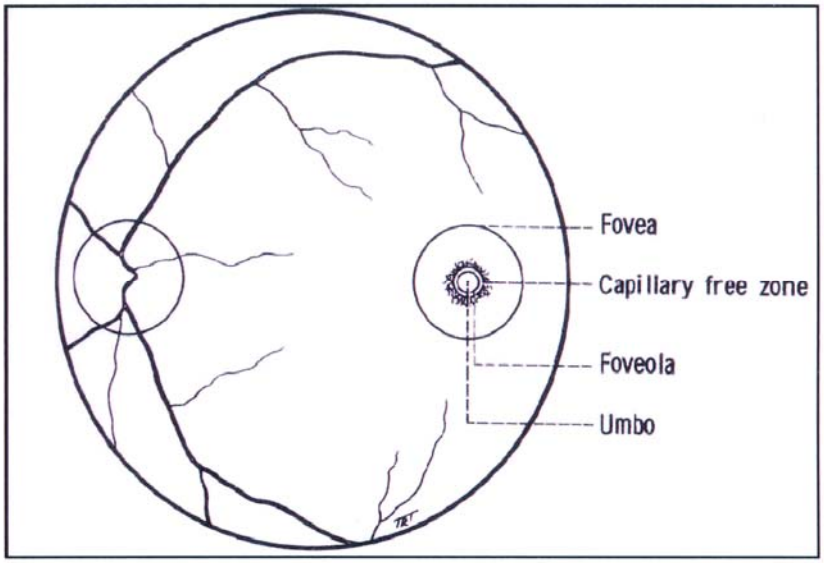

Fig. 2. Histology of Macula

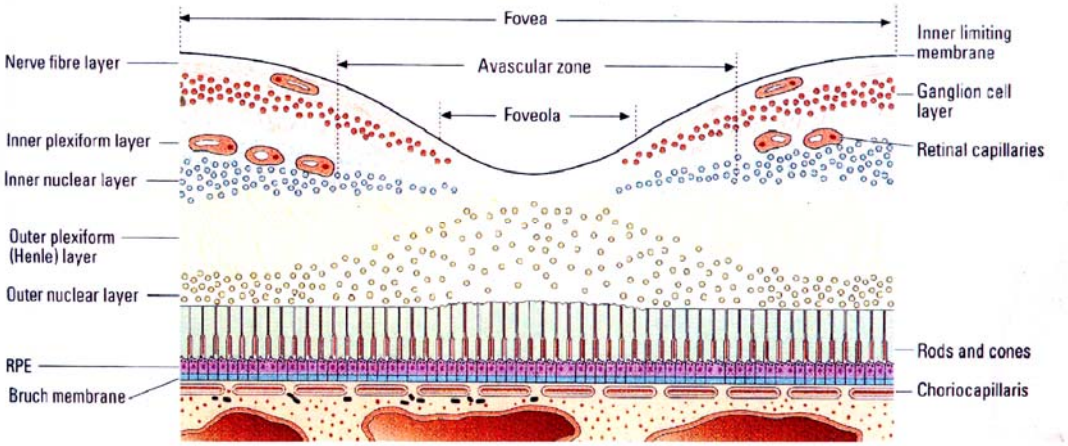

Foveal Avascular Zone (FAZ – 800 μ)

It is located inside the fovea but outside the foveola.

Fovea (1500 μ)

It is a small depression in which retina is reduced to about half its normal thickness. Moving towards the centre of retina, the inner nuclear layer is reduced to double row of cells at the edge of fovea.

Parafoveal Area (500 μ)

It is characterized by densest accumulation of nerve cells in entire retina; especially ganglion cells and inner nuclear layer. The outer boundary is the part where ganglion cell layer has four rows of nuclei.

Perifoveal Area (1500 μ)

It ends where the ganglion cells are reduced to a single layer.

Histology of the Macula

The centre of the macula is the fovea containing following layers.

- Internal limiting membrane
- Outer plexiform layer
- Outer nuclear layer
- Layer of cones
- Retinal Pigment Epithelium (RPE)

Histological Review

Cystoid macular edema[1,2,31,56] is still the most frequent cause of decreased vision, 1 to 3 months following cataract surgery. However, its incidence has declined with advances in surgical techniques (most notable, the change from ICCE to ECCE).

Clinical CME has histologically been defined as a reduction in vision to 20/40 or less that is attributable to ophthalmoscopically or angiographically visible CME.[37,63] The condition occurs in as many as 1% - 6% of patients after uncomplicated phaco surgery.[3,4,7]

In 1953, Irvine[5,34,59] described a syndrome that now bears his name. By definition, this condition included improvement of vision after cataract surgery followed by dimunition of vision associated with post operative rupture of anterior hyaloid membrane with or without adherence of vitreous to surgical wound.

Approximatley 1% of patients may develop CME after Nd-YAG capsulotomy.[49] This complication occurs after 1 – 5 months later and is believed to be related to opening of the posterior capsule rather than to the energy of Nd : YAG laser.

It is also common after other surgeries such as glaucoma procedures, vitrectomy, penetrating kerotoplasty (KP) and retinal detachment (RD) surgery.[33]

Mechanism[1,42,43,47]

Uveal stimulation or release of lens epithelial cells
during intraocular surgery

↓

Prostaglandins synthesis in Anterior chamber

↓

Disturbance of blood aqueous barrier

↓

Release of Cytokines and other inflammatory mediator in AC

↓

Diffuses to vitreous

↓

Breakdown in inner Blood – retinal barrier that leads to CME[50-52]

(higher in older patients and those with various ocular conditions)

Risk Factors[8,34,61]

In cataract surgery, risk of post operative CME appears to be lower with Phacosurgery (0.2 – 1.4%) than ECCE (20%) or ICCE (60%).

A PC rent with vitreous loss is associated with 11.5% - 20% incidence of clinical CME in patients undergoing phacoemulsification and 30.8% in ECCE.[46,55,58]

In retained lens fragments, the risk of CME is 29% after phacoemulsification.[41]

In AC IOLs, it is seen more in rigid type and lower with well positioned open loop types.[40]

In Nd : YAG capsulotomy, 1% develop complications which is 1 – 4 months later and usually due to opening of posterior capsule.[57]

Jaffe Chamblers[12,32] reported a low incidence of CME and RD in blacks a fact difficult to explain.

Definite risk factors are :[15]

- Diabetes
- Older Age
- Uveitis

Clinical Features

Following surgery first improvement, then drop in visual acuity.

***Slit Lamp Biomicroscopy of Fundus*[12,44]**

- Loss of foveal depression, thickening of retina and multiple cystoid spaces in sensory retina.

- In many early cases cystoid changes may be difficult to discern and the main finding is yellowish spot at fovea.

Indirect Ophthalmoscopy[14,48,54]

- Good overall view of retina is seen and this is of value in detecting areas of eccentric retinal thickening, if present.

FFA[20]

- The arteriovenous phase shows mild parafoveal hyper fluorescence due to early leakage.
- The late venous phase shows increasing hyper fluorescence and coalescence of foveal leaks.
- The late phase shows a flower petal pattern of hyper fluorescence caused by accumulation of dye within microcystic spaces in outer plexiform layer of retina with radical arrangement of fibres about centre of foveola.

Vitreous Fluorophotometry

- Developed by Cunha Vaz et al.[6] particularly very useful in aphakic CME.
- Normally only small amount of fluorescein will gain entry to the vitreous because of presence of blood retinal barrier. Increased fluorescence leakage in vitreous can be detected in post operative CME.

OCT[15]

It shows intraretinal cystic spaces and occasionally a small amount of Sub Retinal Fluid (SRF).

OCT may be sufficient for diagnosis in patients whose presentation is classic.[17] In diabetics or patients with an atypical presentation, however FFA assists the diagnosis by ruling out other causes of macular edema such as Diabetic Retinopathy (DR), venous occlusive disease, Choroidal Neovascular Membrane (CNVM), idiopathic juxtafoveal retinal telengietasia.

Hyper fluorescence of the optic disc is typically present in post operative CME, but this clinical sign is often absent in other etiologies, including Clinically Significant Macular Edema (CSME), epiretinal membrane or Age Related Macular Degeneration (ARMD).

OCT helps in ruling out macular edema due to Retinal Detachment (RD), Central Retinal Vein Occlusion (CRVO), Diabetic Retinopathy (DR), epiretinal membrane or Vitreo Macular Traction.

FFA rules out CNVM / Juxtra foveal telengiectasia.

Optical Coherence Tomography[22]

Optical Coherence Tomography is a new diagnostic tool that can perform tomography / cross -sectional imaging of biological tissues with ≤ 10 microns axial resolution using light waves.

Principle

It uses infra red light. The speed of light-is almost a million times faster than sound and this difference - allows the measurement of structures with resolution of ≤ 10 microns compared to 100 micron scale of ultrasound. Ultrasound needs contact with the tissue under study, whereas OCT does not, require any contact.

It is a non- contact, non- invasive device where a broad band-width of near infra-red light beam (820nm) is projected on to the retina. The light gets reflected from the boundaries between the microstructure and also gets scattered differently from tissues with different optical properties. It then compares the echo time delay of the same wavelength that is reflected from a reference mirror at a known distance.

Optical coherence tomography uses, low coherence or white light interferometry to perform high resolution measurements and imaging.

An optical beam from a laser or light source which emits short optical pulses or short coherence length light, is directed onto a partially reflecting mirror (optical beam splitter). The partially reflecting mirror splits the light into two beams, one beam is reflected and the other is transmitted. One light beam is directed on to the patients eye and is reflected from intraocular structures at different distances.

The reflected light beam from the patient's eye consists of multiple echoes which give information about the range or distance and thickness of different intra-ocular structures. The second beam is reflected from a reference mirror at a known spatial position. This retro-reflected reference optical beam travels, back to the partial mirror (beam splitter) where it combines into the optical beam reflected from the patient's eye.

When the two light pulses coincide they produce a phenomenon known as interference which is measured by a light sensitive detector (photodetector). Thus the interferometer can precisely measure the echo structure of reflected light and perform high resolution measurements of the distance and thickness of different tissue structures.

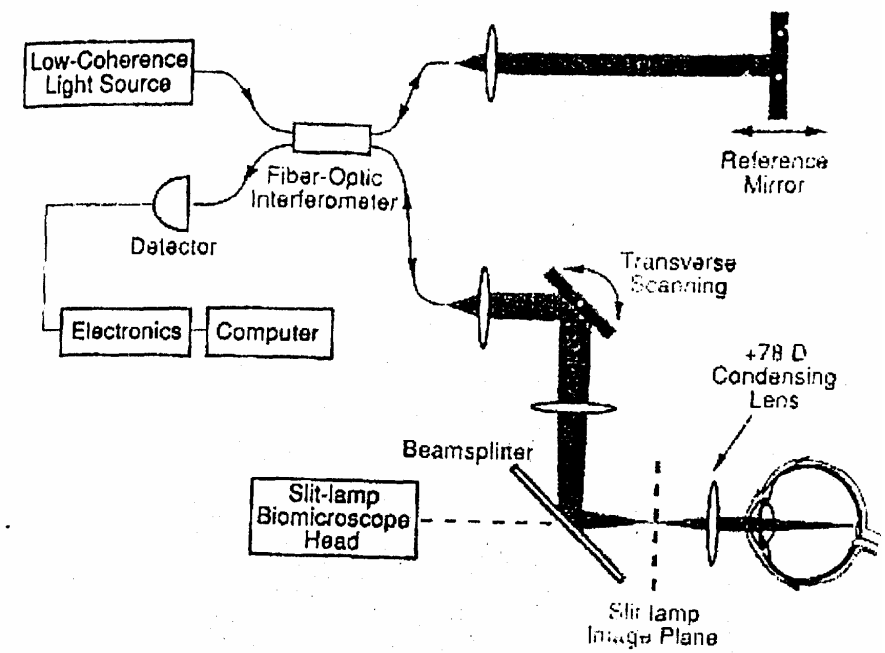

Fig. 3. Schematic diagram of the optical coherence tomography system. Axial profiles of backscattering (A-scans) within the eye are measured by translating the reference mirror and recording the interferometric signal. Cross-sectional tomographs of optical reflectivity are constructed analogous to ultrasound B-scan by scanning the probe beam across the fundus.

The key feature of interferometer is that it can measure the time delay of optical echoes by comparing the reflected light beam with a reference beam. While the explanation presented here assumes that the light is composed of short optical pulses, the measurement may also be performed using non-pulsed or continuous light with a short coherence length. For this reason, the measurement techniques has been termed 'low coherence interferometry'.

The light source for the interferometer is a compact super luminescent diode, which is coupled directly into an optical fibre. This light source is similar to laser diode used in optical compact

disc players, except in OCT, the diode source is designed to emit short coherence length light. The interferometer is constructed using a fibre optic coupler which functions, analogous to a beam splitter. The arm of the interferometer which consists of reference mirror is located within the instrument, while the optical fibre in the second arm of the interferometer is connected to the OCT ophthalmic instrument resembling a slit lamp biomicroscope or fundus camera.

Image Resolution[23]

The image resolution of OCT in the axial (or longitudinal) verses transverse directions is determined by different mechanisms. The resolution of the image in the axial (longitudinal) direction is determined by the resolution of the optical ranging measurement. This is determined by the physical properties of light source which is used for the measurement. If a short pulse laser source is used, the axial resolution is determined by the pulse duration. Conversely, if a continuous, low-coherence light source is used, the axial resolution is determined by the 'coherence length' of the light source. It is important to note that the measurement of distance or tissue thickness can, in practice, be performed with significantly higher resolution than this limit.

The transverse resolution of the image is determined by the size of the focused optical beam. This is a function of the optics used to project the beam onto the eye and this is determined by

factors such as whether imaging is performed over a large depth, such as in the anterior eye, or whether the focusing angle is restricted, as in imaging the retina. The image resolution is also a function of the size of the tomogram that is desired.

OCT Scan Protocols in Macula[21,26,29,30]

The protocols that are helpful in macular diseases are the following :

(i) Line Scan

The line scan gives an option of acquiring multiple line scan without returning to main window. The length of the line scan and the angle can be altered, though one has to keep in mind that as the scan length increases the resolution decreases.

(ij) Radial lines

The scan protocol consists of 6 - 24 equally spaced line scans that can be varied in size and parameters. All the lines pass through a central common axis. The radial lines are useful for acquiring macular scan and retinal thickness / volume analysis.

(iii) Macular thickness map

This is the same as radial lines except that the aiming circle has a fixed, diameter of 6 mm. This helps in measuring the retinal thickness.

(iv) Fast macular thickness map

it is designed for use with retinal thickness analysis. When done in both the eyes, it can be used for comparative retinal thickness / volume analysis. It is a quick protocol that takes only 1.92 sec to acquire six scans of 6 mm length each.

(v) Raster line

This provides an option of acquiring series of line scans that are parallel, equally spaced and are 6 - 24 in number. These multiple line scans are placed over rectangular regions, the area of which can be adjusted so as to cover the entire area of pathology. This is especially useful in conditions like choroidal neovascular membrane where one wishes to obtain scans at multiple levels.

(vi) Repeat

Repeat protocol enables one to repeat any of the previously saved protocols using same set of parameters, that includes scan size, angle, placement of fixation, light emitting diode (LED) and landmark.

Normal macular scan

On a 10 mm horizontal line scan passing through the foveal centre, one can clearly demarcate two major landmarks namely optic disc and fovea.

The optic disc is seen towards the right of the tomogram and is easily identifiable by its contour. The central depression represents the optic head cup and the stalk continuing behind is the anterior part of the optic nerve. The fovea is seen to the left and is easily identifiable by the characteristic thinning of retinal layers. The vitreous anterior to the retina is non-reflective and is seen as a dark space. The interface between the non-reflective vitreous and back scattering retinal layers is the vitreoretinal interface. The retinal nerve fibre layer (NFL) is highly reflective and increases in thickness towards the optic nerve. The posterior boundary of the retina is marked by a hyper-reflective layer that represents retinal pigment epithelium (RPE) and choriocapillaries.

Just anterior to RPE - choriocapillaries complex, is a minimally reflective layer that represents photoreceptors. Above this layer of photoreceptors, are alternating layers of moderate and low reflectivity that represents different layers of neurosensory retina. The retinal blood vessels within the neurosensory retina shows back scatter and also cast a shadow behind.

Image Interpretation[28]

a) Objective

b) Subjective

1) Objective

Hyper-reflective lesions are:

Hard exudates : are seen as hyper-reflective shadows in the neurosensory retina that completely blocks the reflections from the underlying retina.

Blood: Blood causes increasing scattering. Small to thin haemorrhages are seen as hyper-reflective lesions. Thick haemorrhages blocks the reflections from the underlying structure.

Scars : All fibrotic lesions including disciform scars, choroidal rupture scars, healed choroiditis etc are hyper- reflective.

Hypo-reflective lesions are:

Serous fluid : Retinal edema is the commonest cause of reduced back scattering and one can actually point out the site of fluid accumulation. The serous fluid that is devoid of any particular matter, produces an optically empty space with no back scattering.

Hypo-pigmented lesions of RPE.

Subjective analysis

Qualitative.,

Protocols are

a) Normalize
b) Align
c) Median Smoothing
d) Guassian Smoothing

Quantitative

a) Retinal thickness / volume
b) Retinal thickness or volume tabular
c) Retinal thickness / volume change

Advantages of OCT over FFA[27-29]

- Non contact, non invasive
- Time saving technique
- Totally avoids mild complications like nausea to life threatening hypersensitivity reactions seen in FFA.
- Measurement of retinal thickness by OCT correlate more strongly with visual acuity than the presence of leakage on angiography.
- OCT is effective and superior to FFA in demonstrating axial distribution of fluid.
- Can be repeated as many times needed
- Can quantitatively assess retinal thickness and demonstrate any associated RPE structural anomalies

beneath the retina which is observed by leakage on angiography.

- Can be done in cases where FFA is contraindicated.

Treatment

Tina A Scheufele[11,17] and Jeffrey et al. advise topical therapy consisting of prednisolone acetate and a Nonsteroidal Anti Inflammatory Drug (NSAID) qid for at least 6 weeks in all patients with pseudophakic CME. If we observe a response, the patients continues therapy until edema resolves.

Later it is tapered one drop / week.

A recent small study found no statistic significant difference in response of pseudophakic CME to ketorolac alone versus ketorolac and prednisolone.[10,11]

FDA

A new twice daily topical NSAID (bromfenac 0.09% (Xibrom ista pharmaceutical)) for controlling inflammation after cataract surgery. It's effectiveness for the patients has been studied. If effective, it may increase patients compliance.

If Topical Therapy Fails

Topical therapy alone is usually effective in treating routine pseudophakic CME, but it may fail in patients who have other risk factors.[65]

- If no improvement occurs after 6 weeks, then the patient is treated with periocular or intravitreal steroids.
- For refractory pseudophakic CME, intravitreal triamcinolone acetonide may reduce and improve vision but this effect may last only 2 – 4 months.[18]
- Pars plana vitrectomy may be indicated when macular edema is associated with epiretinal membranes, suspected retained lens fragments unresponsive to maximum medical therapy.[45,60]
- Yannuzzi and Co workers[13] (1977) treated established CME lasting 4 months or longer orally with indomethacin 25 mg tid for 3 weeks and noticed no beneficial effect.
- Burnett and Co-workers[23,30] (1983) used topical % fenoprofen for treatment of established CME and several patients showed improvement while receiving therapy, with recurrence after discontinuation of therapy.
- Gass and Norton (1969)[7,53] also noticed improvements in vision in many of their patients who were treated locally and systemically with corticosteroids in varying dosages.

- Gehring (1968)[24] treated CME patients with 20 – 40 mg oral prednisolone and noted a beneficial response but recurrence of the same following withdrawl.

Prophylactic Treatment

- Very important in persons undergoing cataract surgery who had developed CME after uncomplicated surgery in the other eye.[64]
- Sholizon[34] and co-workers (1979) reported no beneficial effect of 25 mg of indomethacin 3 times / day on incidence of CME after ICCE.
- Miyake and Co-workers (1968)[35] also demonstrated that analysis of aqueous humour from cataract patients during post operative period showed elevated level of proteins. These levels could be decreased by prior topical indomethacin therapy.
- Fluch AJ et al. (1976) studied prophylaxis of post operative CME using NSAIDS 0.5% ketorolac sodium without use of concurrent cortiocosteroids and ketorolac sodium given before and after the surgery and was found to markedly reduce the breakdown of blood aqueous barrier compared with placebo solution.

PATIENTS AND METHODS

Patients with Clinical diagnosis of CME who presented to the Retina Clinic of Institute of Ophthalmology, Joseph Eye Hospital, Trichy between May 1st 2005 to April 30, 2006, were included in this study.

Inclusion Criteria

Inclusion criteria were all patients with clinical diagnosis of CME > 4 weeks following ocular surgery.

Exlusion Criteria

- CME due to other causes including Diabetic retinopathy, Branch Retinal Vein Occlusion, Central Retinal Vein Occlusion, Uveitis
- Patients who did not complete minimum followup period of 3 months.

A standard protocol was used to collect and document all the details regarding the cases included in this study.

A detailed information about history and complaints of the patients were taken. This included

- Type / date of surgery
- Complications of surgery
- Chief complaints
- Duration of symptoms

A complete ocular examination was done for all patients which included the following : Best corrected visual acuity, Near Vision, Slit Lamp Examination of the anterior segment.

Slit Lamp biomicroscopy of the fundus was done with + 90D lens and following were noticed. Presence of cystoid spaces, macular thickening, associated hemorrhages, disc edema, vitreous hemorrhage were looked for.

Digital fundus fluorescein angiography was done using Carl Zeiss FF 450 Plus IR digital Camera. 3 ml of 20% sodium fluorescein is injected into anterior cubital vein. A series of photographs were taken. Presence and Extent of leak were noted.

OCT was done for all the cases, fast macular scan and line scans through the fovea were used. Retinal thickness analysis and retinal map analysis were done.

Typical findings in OCT looked for were, cystoid spaces in the outer plexiform and inner nuclear layers.

Management

All patients were treated with ketorolac and prednisolone eye drops qid. If macular thickness failed to reduce by 1 month, patients were given posterior subtenon injection of steroid – Triamcinolone acetonide 0.1 ml (4 mg).

Follow up

All patients were asked to come after 1, 2, months respectively for follow up. At each visit the following were noted. Visual acuity, near vision, Amsler's grid, slit lamp microscopy using + 90 D lens to assess the course of CME. OCT was done using a line scan at each visit.

Statistical Analysis

Statistical analysis was done by student 't' test and regression analysis. The value of $p < 0.05$ was considered significant.

RESULTS

The demographical data includes age, sex of the patients, laterality, type of surgery, duration of problem, pretreatment and post treatment BCVA, macular thickness.

The minimum follow up period was 6 months. Patients included in this study were subjected to FFA, OCT at the time of presentation and also at first and second review after 1 and 2 months respectively.

Twenty patients were included in this study. Of these 16 were male patients and 4 were female patients (Fig. 1).

Fig. 2 shows age distribution. Of these 20 patients, 7 patients were in 51 – 60 years age group 5 in 71 – 80 years age group, 4 in 61 – 70 years age group, 3 in 41 – 50 years, 1 in < 40 years age group.

Fig 3 shows laterality. RE was involved in 55% (n = 11) of cases and LE in 45% (n = 9) of cases.

Fig. 4 shows type of surgeries done. 95% (n = 19) were cataract surgeries. Of these 65% (n = 13) were small incision cataract surgeries, 25% (n = 5) were phacoemulsifications, 5%

(n = 1) were extracapsular cataract surgeries . 5% (n = 1) were filtering surgeries.

Fig. 5 shows the duration of problem. 50% (n = 10) of the patients presented between 4 to 6 weeks, 35% (n = 7) of the patients presented between 6 to 8 weeks, 10% (n = 2) less than 4 weeks and 5% (n = 1) more than 8 weeks.

Fig. 6 shows comparison between pretreatment and post treatment BCVA.

Before treatment, 50% (n = 10) of patients had vision range between 6/18 – 6/12, 30% (n = 6) of patients had vision range between 6/36 – 6/18, 20% (n = 4) of patients had vision range between 6/30 – 6/36.

Average 0.2886 and standard deviation – 0.132091.

After 2 months of treatment, 95% of patients (n = 19) had vision range between 6/18 – 6/6 and 5% (n = 1) had between 6/36 – 6/18.

Fig. 7 shows OCT macular thickness at the time of presentation. At the time of presentation 35% (n = 7) had macular thickness between 400 – 500 μ, 15% (n = 3) had macular thickness

between 300 – 400 μ, 20% (n = 4) had macular thickness between 200 – 300 μ and 15% (n = 3) had macular thickness < 200 μ and > 500 respectively. Average was 395 μ and standard deviation was 158.26893.

At first time review visit, 60% (n = 12) had macular thickness < 200 μ, 20% (n = 4) between 300 – 400 μ, 15% (n = 3) > 500 μ and 5% (n = 1) between 200 – 300 μ. Average 275 μ and Standard deviation 163.32145.

At second time review visit, 75% (n = 15) had macular thickness < 200 μ, 20% (n = 4) between 300 – 400 μ, 5% (n = 1) remained between 400 – 500 μ. Average 275, standard deviation – 71.031201.

Sex of the Patients

Sex	No. of Patients	Percentage
Male	16	80
Female	4	20

Age of the Patients

Age	No. of Patients	Percentage
< 40	1	5
41 – 50	3	15
51 – 60	7	35
61 – 70	4	20
70 – 80	5	25

Laterality

Laterality	No. of Patients	Percentage
Right Eye	11	55
Left Eye	9	45

Type of Surgeries

Type of Surgeries	No. of Patients	Percentage
Cataract Surgeries		
ECCE with IOL	1	5
SICS with IOL	13	65
Phaco with IOL	5	25
Filtering Surgeries	1	5

Duration of Problem

Duration	No. of Patients	Percentage
< 4 weeks	2	10
4 – 6 weeks	10	50
6 – 8 weeks	7	35
> 8 weeks	1	5

Pretreatment BCVA

Pretreatment BCVA	No. of Patients	Percentage
6/18 – 6/12	10	50
6/36 – 6/18	6	30
6/60 – 6/36	4	20
< 6/60	-	--

Final Visual Acuity

Final Visual Acuity	No. of Patients	Percentage
6/18 – 6/6	19	95
6/36 – 6/18	1	5
6/60 – 6/36	-	-
< 6/60	-	-

OCT Findings Macular Thickness

Macular thickness (μ)	At presentation	First Visit	Second Visit
< 200	3	12	15
200 – 300	4	1	4
300 – 400	3	4	0
400 – 500	7	-	1
> 500	3	3	-

DISCUSSION

Optical coherence tomography is a noninvasive, non contact imaging system that uses superluminescent diode light source to create high resolution, real time, cross sectional tomographic images of retina.

In our study it was used in 20 patients with post operative CME. Clinical findings in CME may be subtle without matching with visual acuity. OCT can play an important role in these eyes. OCT can also prove useful for objective followup in these cases.

In our study, the maximum number of patients were between 51 – 60 years age group (Mean 61.85 years) which was similar to the study done by Jalementel[65] and associates (Avg. 69.883). In our study males were more compared with females (4 : 1). Williamson et al.[25] in their study have mentioned the sex ratio to be 1.2 : 1.

The main risk factors for development of CME in our study were PC rent, vitreous loss, AC IOL, ECCE. Tina A et al.[17] in their study have mentioned ruptured PC, ECCE, retained lens fragments, vitreous loss, iris trauma, AC IOL, Post uveitis as major risk factors.

Duration of problem in our study was between 4 – 6 weeks which is similar to observations made by Gass and Norton et al.[53]

In our study, slit lamp biomicroscopy showed yellow spot at the foveola, loss of foveal depression, thickening of the retina and multiple cystoid spaces in the sensory retina. This is similar to the biomicroscopic appearance of CME mentioned by Gass JDM et al.[7] in their study.

Fundus fluorescein angiogram in our study showed flower petal pattern hyperfluorescence in almost all cases Cogan D.G., Guzak et al. have described mild parafoveal hyperfluorescence due to early leakage in arterio-venous phase. It was followed by increasing hyperfluorescence, coalescence of the focal leaks and flower petal pattern of hyper fluorescence.

In our study, average macular thickness at time of presentation was 395 μ. Karocorlu, Murat et al.[18] in their study have mentioned it as 504 μ.

Drexlen W, Sattman et al.[21] studied patients with cystoid macular edema using optical coherence tomography. They have concluded that optical coherence tomography was potentially useful as a non-invasive diagnostic technique for quantitative examination and objectively monitoring the clinical course of the post operative

cystoid macular edema. They also reported topographic features in cystoid macular edema with associated RPE structural anomalies beneath the edematous retina, which can be obscured by leakage on angiography. We did not detect any RPE structural anomalies in any patients in our study.

Vanden Moere et al.,[19] felt that presence of subretinal fluid, gross CME, sponge like retinal thickening and retinal thickness > 350 μ on OCT correlated well with leakage on FFA (p value 0.01). The presence of solitary foveal cyst correlated well will OCT than with leaks on FFA. In our study also, presence of CME on OCT correlated well with leakage on FFA. All 20 patients with CME on OCT showed typical flower petal leak on FFA.

Elesh Kumar Jain, Pankaj Chowdhary et al.[22] found intra retinal cystic spaces and occasionally a small amount of SRF in post operative CME. OCT may be sufficient for diagnosis in patients whose presentation is classic. However in atypical presentation FFA helps the diagnosis by ruling out other causes of macular edema such as DR, Venous occlusive diseases, CNVM, Idiopathic Juxtafoveal retinal telengicetasia.

In our study, all the patients were prescribed steroid and NSAIDS eye drops. Posterior subtenon triamcinolone acetonide was given if it was not resolved by 1 month. Burnett and

coworkers[23] used topical 1% fenoprofen for the treatment of established CME in randomized trial. Gehring[24] treated 17 patients with CME orally with 20 to 40mg of prednisolone daily and noted a beneficial response in 13 cases after average of 5.5 weeks. After medication was discontinued, 3 of the 13 patient showed recurrences. In our study no patients had any recurrence.

Karakorlu et al.[18] observed baseline CME to be 504 μ which reduced to 264, 240, 232 microns at 1, 3, 6 months respectively. In our study there was a significant decrease in macular thickness from presentation to first ($p = 0.002$) and second visits ($p < 0.0001$) done by OCT. Measurement of retinal thickness by OCT correlated more strongly with visual acuity than presence of leakage on angiography.

SUMMARY

In this prospective, non comparative study, 20 eyes of 20 patients with post operative cystoid macular edema were included. FFA was done for all the patients. Optical coherence was done to all patients at presentation and during follow up. OCT was used to quantitatively assess retinal thickness and demonstrate any associated RPE structural anomalies beneath the oedematous retina, which can be obscured by leakage on angiography. Line scan was done through the leak site.

Steroids and NSAID eye drops were prescribed to all the patients at the time of presentation. Posterior subtenon triamcinolone acetonide was given, if it was not resolved by 1 month. Measurements of retinal thickness by OCT correlate more strongly with visual acuity than the presence of leakage on angiography. The correlation between the macular thickness at presentation and at first and second visits was statistically significant.

Optical coherence tomography with its high resolution imaging of the retina has a role in the diagnosis and follow up of post operative cystoid macular edema. It is also useful to detect subtle cystoid spaces missed by slit lamp biomicroscopy. It may aid in redefining the pathological process in leak site.

CONCLUSION

- Optical coherence tomography with its high resolution imaging of retina helps in the diagnosis and followup of post operative cystoid macular edema.
- Optical coherence tomography is a noninvasive technique (unlike FFA) to detect subtle cystoid spaces which may be difficult to detect clinically.
- Optical coherence tomography objectively monitors the course of post operative cystoid macular edema till its resolution.

BIBLIOGRAPHY

1. A. Brigman, A. Recihenberg, P. Wiedemann et al., Pathomechanism of CME, Ophthalmic Research, Sep. 2004.

2. Heslin, KS, Guerrirro, PN. Wound Complications following cataract surgery, CLAOJ, 1987, 13 : 67 – 70.

3. Henman et al. Incidence of CME after uncomplicated cataract surgery. Trans American Ophthalmological Society, 1998 : 96557 – 634.

4. Arango and Margo. Wound complications following cataract surgery. A case control study. Arch. Ophthalmol., 1998 : 116 : 1021 – 1024.

5. Irvine, SR. A newly defined vitreous syndrome following cataract surgery, interpreted according to recent concepts of the structure of vitreous. Francis : Proctor Lecture, Am. J. Oph., 1953, 36 : 599 – 619.

6. Miyake, K. et al. Vitreous fluorophotometry in aphakin and pseudophakic eyes with persistent cystoid macular edema. Jpn. J. Oph., 1985; 29(2) : 146 – 52.

7. Gass, JDM, Norton, EWD. Cystoid macular edema and papilledema following cataract extraction. A fluorescein fundoscopicand angioscopic study. Arch. Ophthalmo, 1966 : 116 : 648 – 656.

8. Vincent Victor D, Ocampo MD, Stephen Foster. Serile Catarct Emedicine specialities. Ophthalmology Lens Web MD, Sep. 18, 2006.

9. Weitzman MB et al. Ketrolac versus prednisolone versus combination therapy in treatment of acute pseudophakic cystoid macular edema. Ophthalmology, Vol. 107, Issue 11, 2034 – 2038.

10. Juan Orellana, MD, MS, et al. Using NSAIDS to treat Macular edema. Ophthalmology Management, 2006.

11. Tina A, Scheufele et al. Pseudophakic CME. Understanding the mechanism and risk factors for this condition may help guide. Prophylaxis and treatment and refractive cataract therapy. July 2004.

12. Chamblers WB. Personal Communication, April 19, 1984.

13. Yanuzzi LA, Rohen KT et al. FFA Complications. Survey Ophthalmology 93, 1986. 611 – 7.

14. Nusssenblatt RB, Kaufmann SC, Palestini AG, et al. Macular thickening and visual acuity. Measurement in cystoid macular edema. Ophthalmology, 1987 : 94 : 1134 – 9.

15. Anteliff, RJ et al. Comparison between OCT and FFA for detection of CME in patients in uveitis. Oph. March 2000, 107(3) : 593 – 9.

16. Puliafito CA, Wong C, Duker JS et al. Quantitative assessment of macular edema with OCT. Arc. Ophthalmol, 1995, 113 : 1019 – 29.

17. Tina et al. Pseudophakic CME. Cataract and refractive surgery today. 1995, 113 : 1000 – 10.

18. Karakoalu, Murat, Odzemia. Intravitreal triamcinolone acetonide for the treatment for chronic psuedophakic cystoid macular edema. Acta. Ophthalmological Scandinavia, 81 (6) : 648 – 652, Dec. 2003.

19. Vander Moere et al. Correlation of optical coherence tomography and fundus fluorescein angiography following photodynamic therapy for choroidal Neovascular membranes. BJO, 2005, 90 : 304 – 6.

20. Cogan DG, Guzak, SV, Fluoroangiographic pattern of macular edema and retinal swelling in Postmortem eyes. Am. J. Ophthalmol, 1971, 171 (29) : 297.

21. Drexlerw, Sattman H, Hermann S, et al. Enhanced visualization of macular pathology with the use of ultrahigh-resolution optical coherence tomograph. Arch. Ophthalmol., 2003, 121 : 698 – 708.

22. Flesh Kumar Jain, Pankaj Kohudhany et al. Optical coherence tomography – conceptand clinical application. Dos Times, Vol. 11, No. 1, Jly 2005.

23. Burnett J and Others. Double masked trial of fenoprofen sodium : treatment of chronic aphakin cystoid macular edema. Ophthalmol. Surg. 14 : 1983, 150 – 152.

24. Gehring, JR. Macular edema following cataract extraction. Arch. Ophthalmol., 80 : 626 – 631, 1968.

25. Williamson MD et al. Cataract surgery in Senegal. Communite Eye Health Journal, vol. 10, No. 21, 10 – 13, 1997.

26. Irene Voo, Clinical Applications of OCT, ophthalmology clinics of North America, Imaging, Joel S. Schuman. Vol. 17, March 2004, Elsevier Saunders, 21 – 31.

27. Pascale Massin, OCT for evaluating DME, AMJ Ophthalmol., 2003, 135 : 169 – 177.

28. Tewari HK, Wagh VB, Sony P, Venkatesh P, Singh R. Macular thickness evaluation using the optical coherence tomography in normal Indian eyes. Indian J. Ophthalmol., 2004, 42 : 199 – 204.

29. Puliafito CA, Hee MR, Lin CP, et al. Imaging of macular diseases with optical coherence tomography. Ophthalmology, 1995, 102 (2) : 217 – 29.

30. Jones AL, Sheer NJ, North RV, Morgan JE. The humphrcy Optical coherence tomography scanner : Quantitative analyis

and reproducibility study of the normal human retinal nerve fibre layer. Br. Jr. Ophthalmol, 2001, 85 (6) : 673 – 7,

31. Jaffe NS, Claymann HM. Cystoid macular edema after intracapusular and extracapsular cataract extension with our without an intra ocular lens. Ophthalmology, 1982, 89 : 25 – 29.

32. Chamblers WS. Phacoemulsification and the retina : cystoid macular edema. Ophthalmology, 1979, 86 : 2019 – 2022.

33. Stern AL and others. Psuedophakic cystoid Maculopathy – a study of 50 cases. Ophthalmology, 1981, 88 : 942 – 946.

34. Irvine AR. Cystoid Maculopathy. SMV Ophthalmol, 1976, 21 : 1 – 17.

35. Burnett J. and others. Double masked trial of fenoprofen sodium : treatment of chronic aphakic cystoid macular edema. Ophthalmic Surg. 1983, 14 : 150 – 152.

36. Miyake K. Prevention of cystoid macular edema after lens extraction by topical indomethacin II. A control study of bilateral extractions. Jpn. J. Ophthalmol, 1978, 22 : 80 – 94.

37. Jacobson Dr, Dellapoata A. Natural history of cystoid macular edema after cataract extraction. Amj. Ophthalmol. 1974, 77 : 445 – 447.

38. Kraff MC and Others. Prophylation of pseudophakic cystoid macular edema with topical indomethacin. Ophthalmology, 1982, 89 : 889 – 890.

39. Freedman J, Jordan AJ, Kokoris N. Cystoid macular edema in aphakic block patients. Ann. Ophthalmol, 11 : 1699 – 1701, 1979.

40. Winslow RL, Taylor BC, Harris WS. A one year follow up of cystoid macular edema after intra ocular lens implementation. Ophthalmology, 85 : 190 – 196, 1978.

41. Binkhort CD. Extracapsular cataract extrachon and lens implementation. J. Ocul. Ther. Surg., 1 : 20 – 25, 1981.

42. Oliver M. Posterior pole changes after cataract extraction in elderly subjects. Am. J. Ophthalmol, 62 : 1145 – 1148, 1966.

43. Binkhorst, Corneal and retinal complications after cataract extraction : the mechanical aspects endophthalmodonesis.

44. Wolter JR. The histopathology of cystoid macular edema. Grafer Arch. Clin. Exp. Ophthalmol, 216 : 85 – 101, 1981.

45. Federman, JL and others. Vitrectomy and cystoid macular edema. Ophthalmology, 87 : 622 – 628, 1980.

46. Mc Donel PJ and others. Vitreous incurration complicating cataract surgery : a light and electron microscopic study. Ophthalmology, 93 : 247 – 283, 1986.

47. TSO Mom : Pathology of cystoid macular edema, Ophthalmology, 89 : 902 – 914, 1982.

48. Frisen L, Frisen M. A simple relationship between the probability distribution of visual acuity and the density of retinal output channels.

49. Duke – Elder System of Ophthalmology, Vol. 10, Diseases of retina, St. Louis, 1967, CV Mosby.

50. Frisen L, Frisen M. Mocropsia and visual acuity in macular edema : A study of neuro retinal basis of visual acuity.

51. Tolentino FL, Sephepens CL. Edema of posterior pole after cataract extraction : a biomicroscopic study. Arch. Ophthalmol, 74 : 781 – 786, 1965.

52. Jaffe MS. Vitreous traction at the posterior pole of the fundus due to alterations in the vitreous posterior. Trans. Am. Acad. Ophthalmol. Otoluryngol. 71 : 642 – 652, 1967.

53. Gass JDM, Norton EWD. Followup study of cystoid macular edema following cataract extraction. Trans. Am. Acad. Ophthalmol. Otoluryngol. 73 : 665 - 682, 1969.

54. Maumenee AE. Further advances in the study of Macular. Arc. Ophthalmol, 78 : 151 – 167, 1967.

55. Rheese AB, Jones IS, Cooper WC. Macular changes secondary to vitreous traction. Trans Am. Ophthalmol. Soc., 64 : 123 – 234, 1966.

56. Fine BS, Brucker AJ. Macualr edema and cystoid macular edema. Am. J. Ophthalmol, 92 : 466 – 481, 1981.

57. Foos RY. Vitrero retinal juncture, topographical variations. Vest Ophthalmol, 11, 801 – 808, 1972.

58. Osterlin S. Vitreous changes after cataract extraction. In Freeman HM, Hirose T, Schepens CL, Editors : Viterous surgery and advances in fundus diagnosis and treatment. New York, 1977, Appleton – Century – Crofts.

59. Irvine AR and others. Macular edema after cataract extraction. An. Ophthalmol, 1 : 1234 – 1240, 1971.

60. Fung WE. Anterior vitrectomy for chronic aphakic cystoid macular edema. Ophthalmology, 57 : 622 – 628, 1980.

61. Kratz RP. Results of phaco emulsification by Kelman and Crirard techniques. In symphosrum on cataract. Transactions of new Orbeans academy of Ophthalmology, St. Louis, 1979, Mosby.

62. Wolff, E. Anatomy of the eye and orbit, ed. 6, Philadelphia, 1968. WB Saunders, pp. 122, 130, 139 (revised by RJ Last).

63. Tennnat JL : is cystoid macular edema reversible by oral indocin, yes on No? In Emerg. Jan. Pot D, Editors : current concepts in cataract surgery : Selected proceedings of the fourth biennial cataract surgical congress, St. Louis, 1976, CV Mosby.

64. Klein RM, Katzin Hm, Yanuuzzi LA. The effect of indomethacin pretreatment of aphakic cystoid macular edema. Am. J. Ophthalmol, 87 : 487 – 489, 1979.

65. Jale Mentes, Tansu Erakgun, Filiz Afreshi et al. Indicence of cystoid macular edema after uncomplicated phacoemulsification. Ophthalmologica, 2003, 217 : 408 – 412.

INSTITUTE OF OPHTHAMOLOGY
Joseph Eye Hospital
Tiruchirappalli.

ROLE OF OPTICAL COHERENCE TOMOGRAPHY IN MANAGEMENT OF POST OPERATIVE CYSTOID MACULAR EDEMA

Name : Age : Sex :

Address S. No. M.R. No.

Phone :

Complications

History of Ocular Surgery			
Type of Surgery			
Intra Operative complications			
Type of IOL			
Current Treatment			
Personal History			
Hypertension			
Diabetes			
Others			
Family History Associated Ocular Conditions			
General Examination			
B.P.		Pulse Rate	
Cardiac Status		Others	
Ocular Examination		RE	LE
Visual Acuity	Without correction		
	Best Corrected		
	Near Vision		

IOP			
Anterior Segment			
	Lids and Adnexa		
	Conjuntiva		
	Corena		
	AC		
	Iris		
	Pupils		
	Lens		
Posterior Segment	**Fundus**		
Media			
Disc	Colour		
	Margins		
	CD Ratio		
	Neuroretinal Rim		
Macula			
Provisional Diagnosis			

OCT

FFA

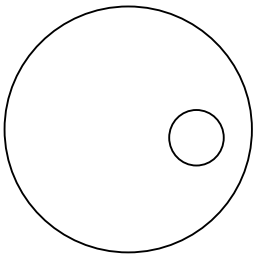

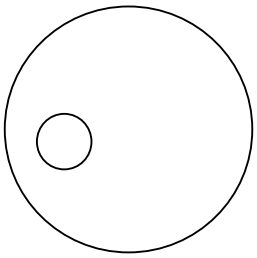

Management

Fig. 4.

Carl Zeiss Digital Camera with Fundus Fluorescein Angiogram

Fig. 5.

Carl Zeiss Stratus Optical Coherence Tomogram Model 3000

PLATE 1

Fundus Fluorescein Angiogram of a post operative cystoid macular edema patient showing flower petal pattern of hyperfluorescence in late phase

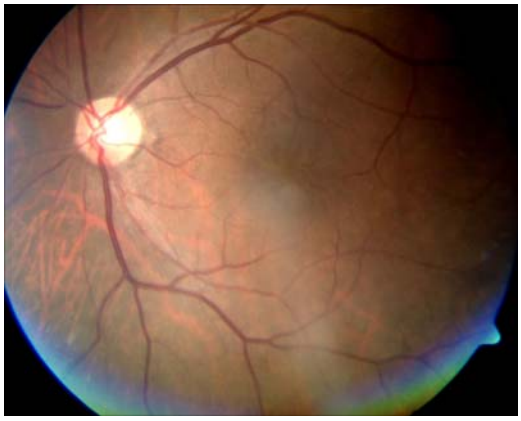

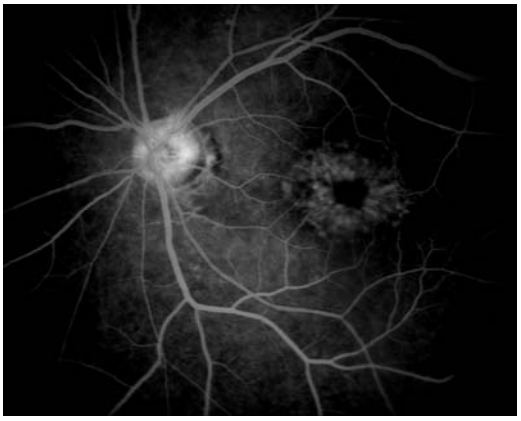

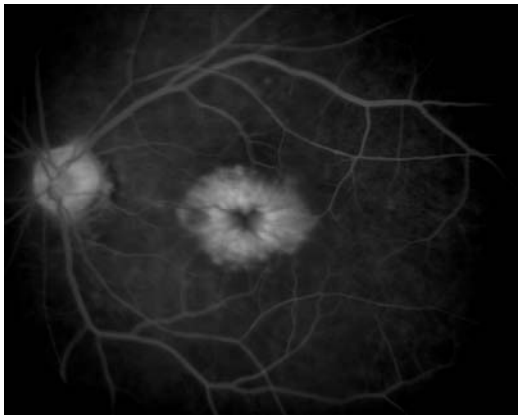

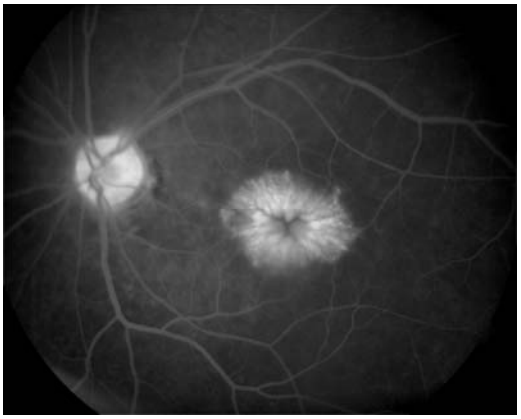

PLATE 2

DIGITAL FUNDUS PHOTOGRAPHS AND OCT (LINE SCAN) OF A PATIENT HAVING POST OPERATIVE CYSTOID MACULAR EDEMA

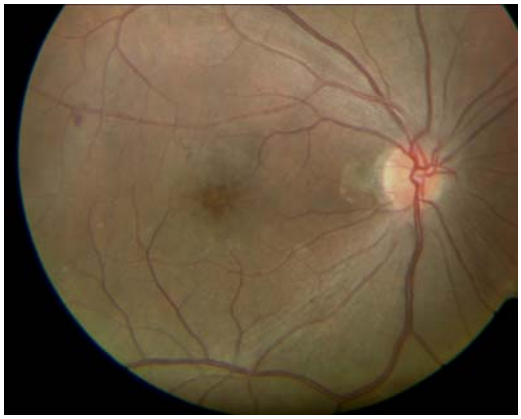

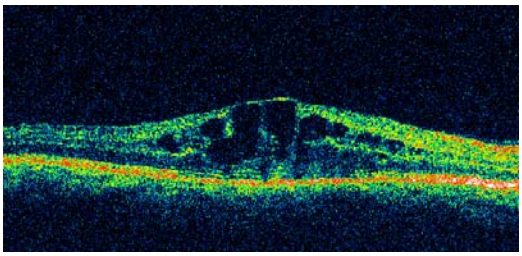

At Presentation

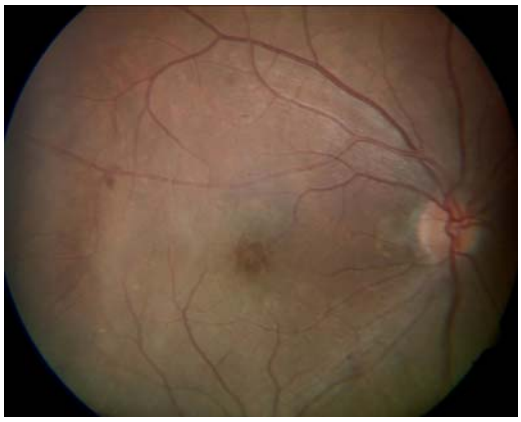

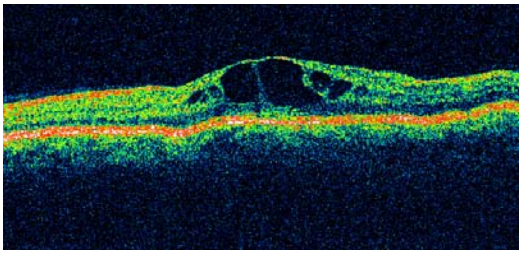

First Review Visit

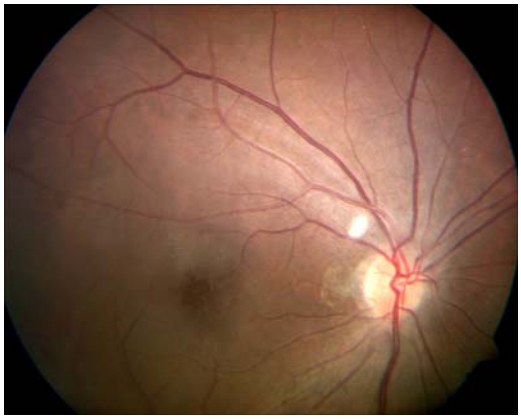

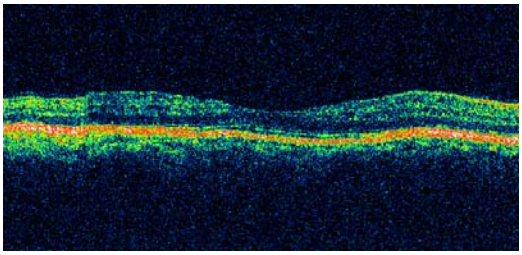

Second Review Visit

OCT, at second review visit shows resolution of cystoid spaces and decrease in thickening of macula whereas digital fundus photo show loss of foveal depression, thickening of retina and few cystoid areas

PLATE 3

ROLE OF OPTICAL COHERENCE TOMOGRAPHY IN MANAGEMENT OF POST OPERATIVE CYSTOID MACULAR EDEMA

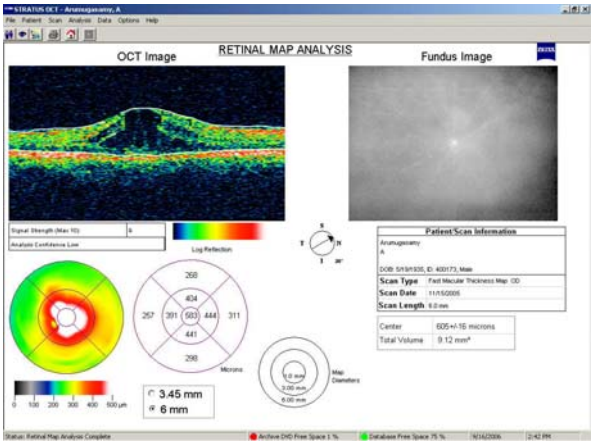

At presentation

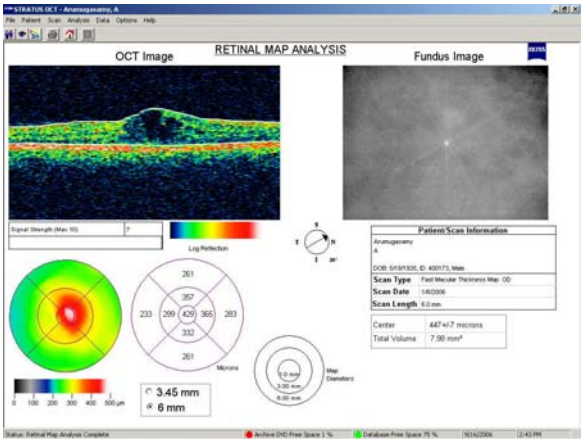

First Review Visit

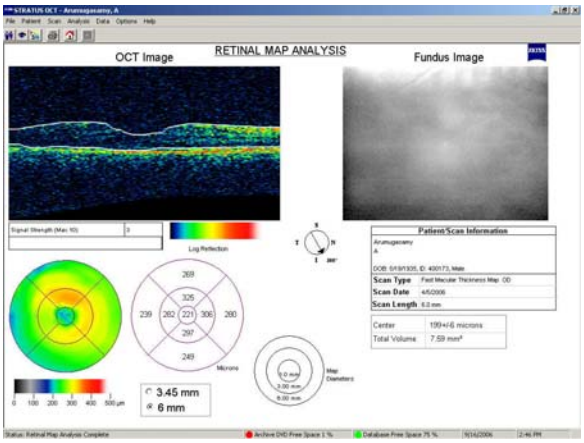

Second Review Visit

Male	16
Female	4

< 40	1
41 - 50	3
51 - 60	7
61 - 70	4
70 - 80	5

RE	11
LE	9

ECCE with	1
SICS with I	13
Phaco with	5
Filtering Su	1

< 4 weeks	2
4 - 6 weeks	10
6 - 8 weeks	7
> 8 weeks	1

	Pre Treatm	Post Treatment
6/18 - 6/12	11	19
6/36 - 6/18	6	1
6/60 - 6/36	4	0
< 6/60	0	0

< 6/60	0
6/60 - 6/36	0
6/36 - 6/18	1
6/18 - 6/6	19

	At presenta	First Visit	Second Visit
< 200 µ	3	12	15
200 - 300 µ	4	1	4
300 - 400 µ	3	4	0
400 - 500 µ	7	0	0
> 500 µ	3	3	1

Fig. 1. Sex of the Patients

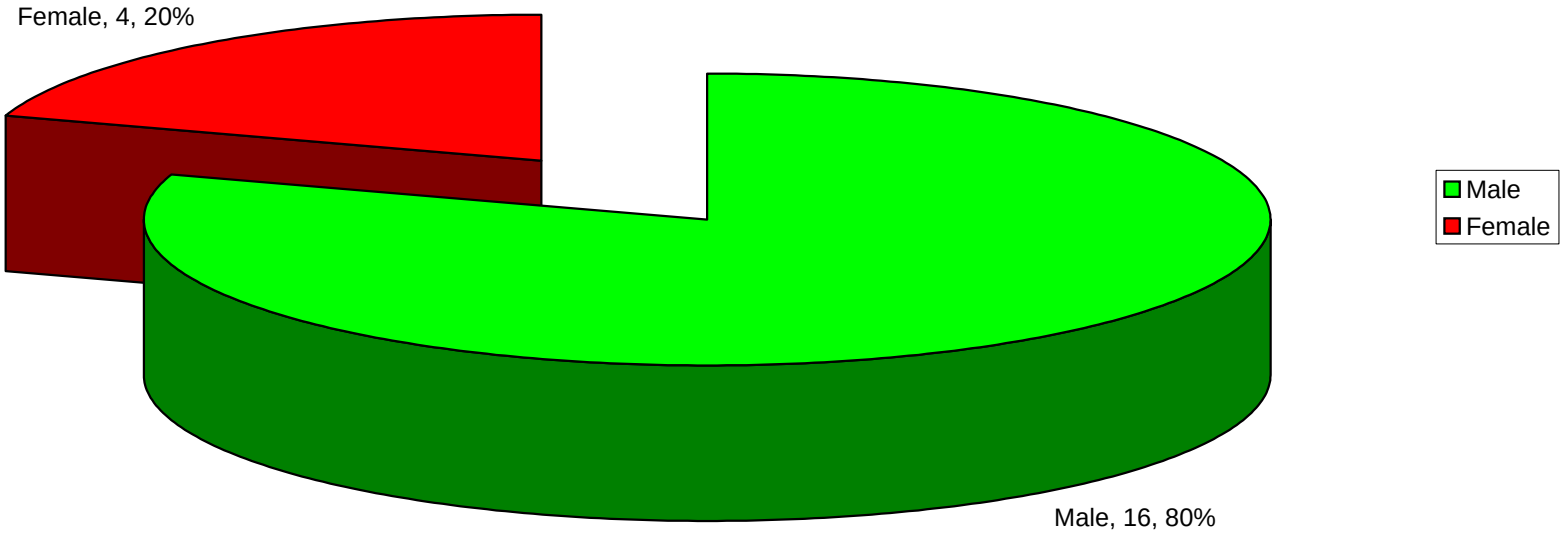

Fig. 2. Age of the Patients

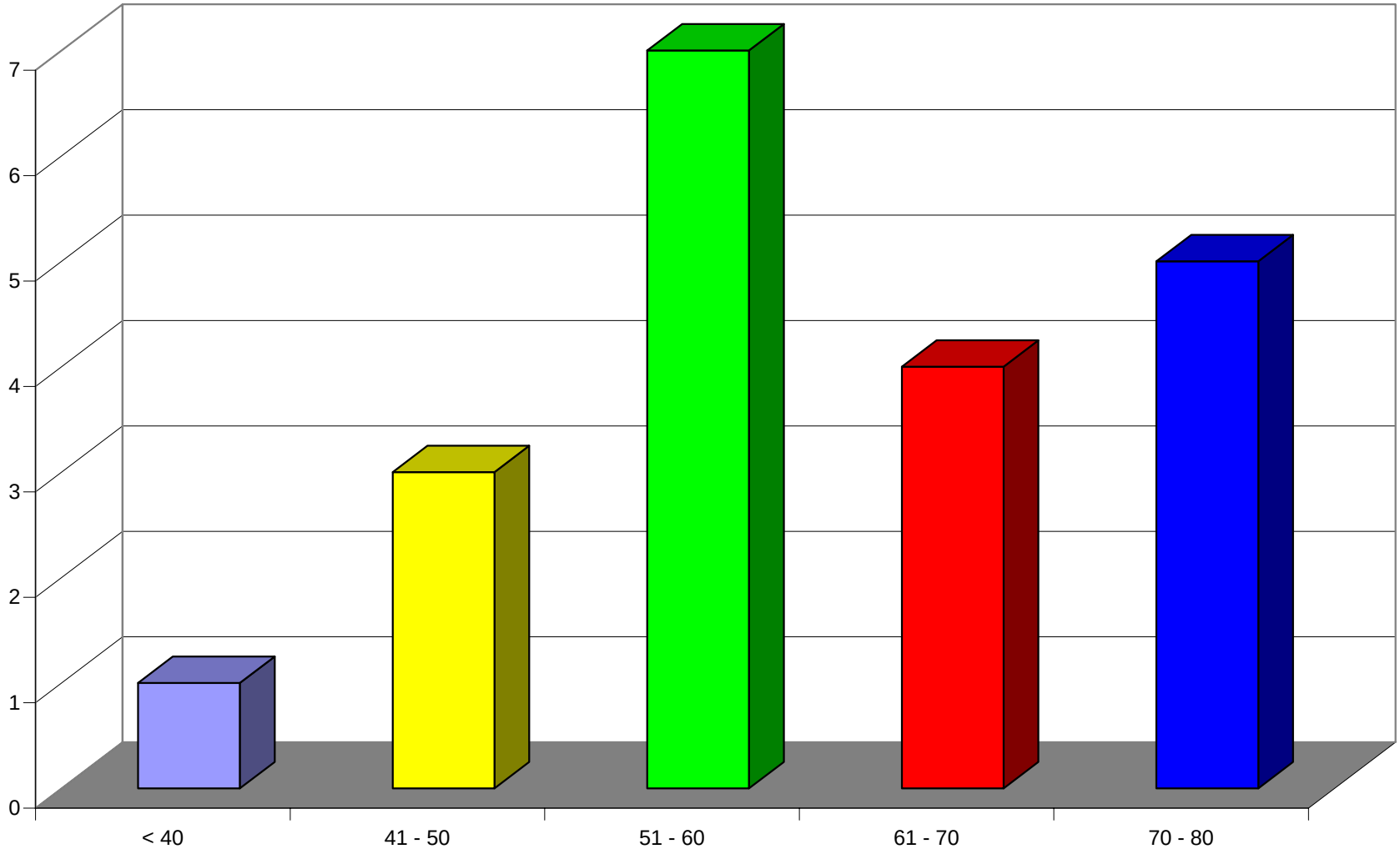

Fig. 3. Lateraility

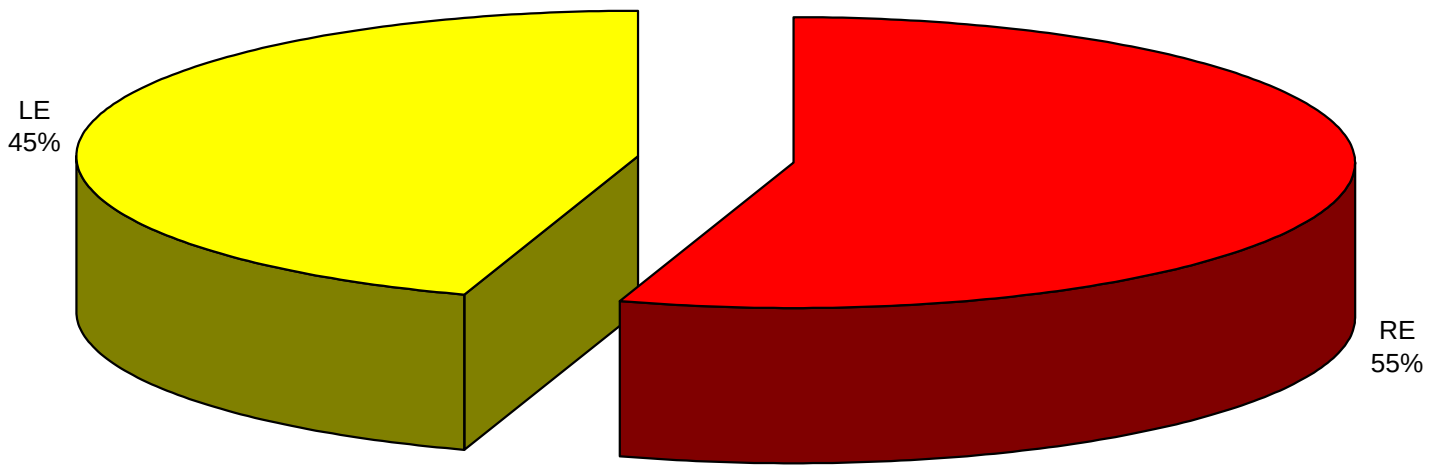

Fig. 4. Type of Surgeries

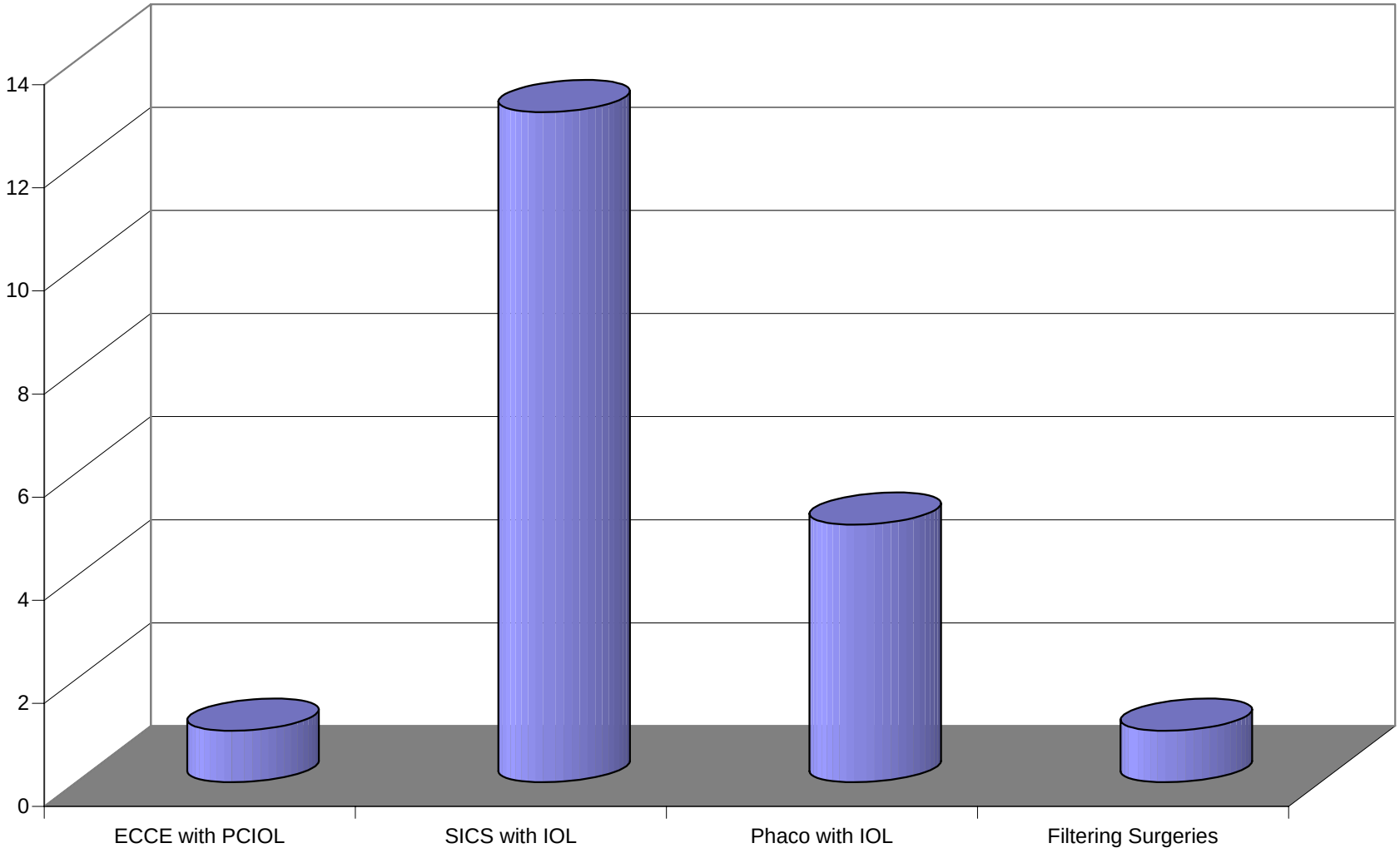

Fig. 5. Duration of Problem

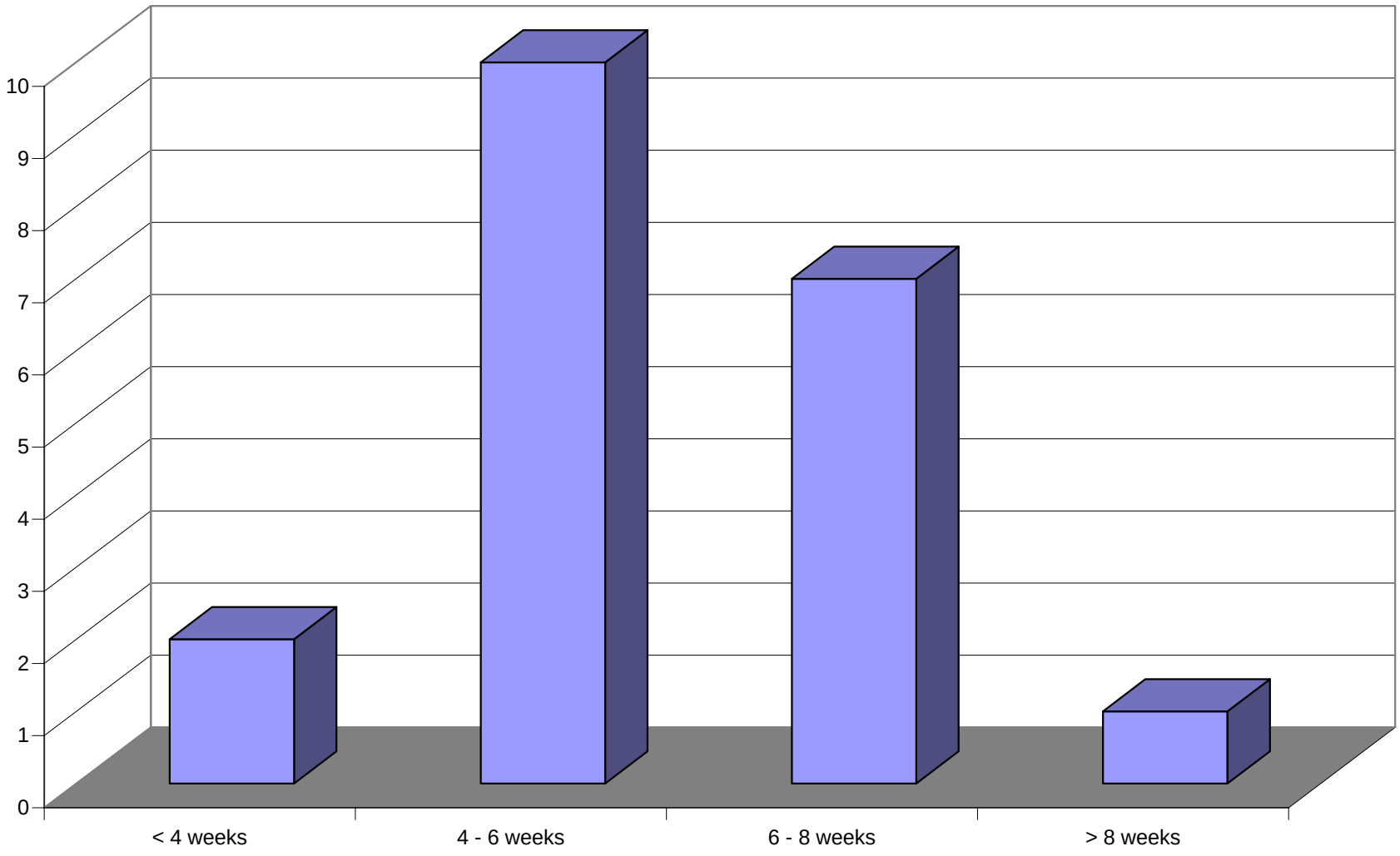

Fig. 6. Pretreatment and Post Treatment BCVA

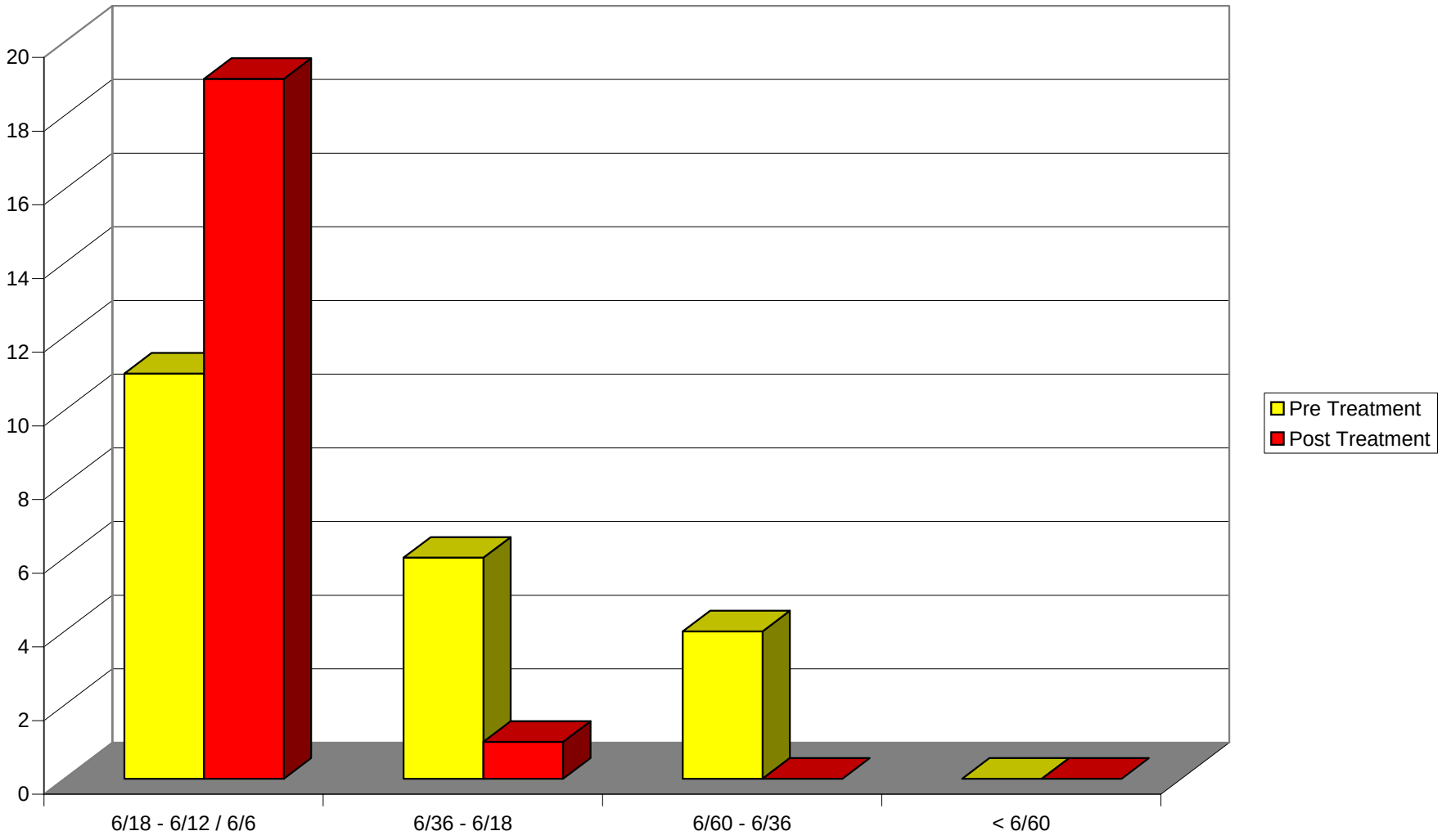

Fig. 7. OCT findings Macular Thickness

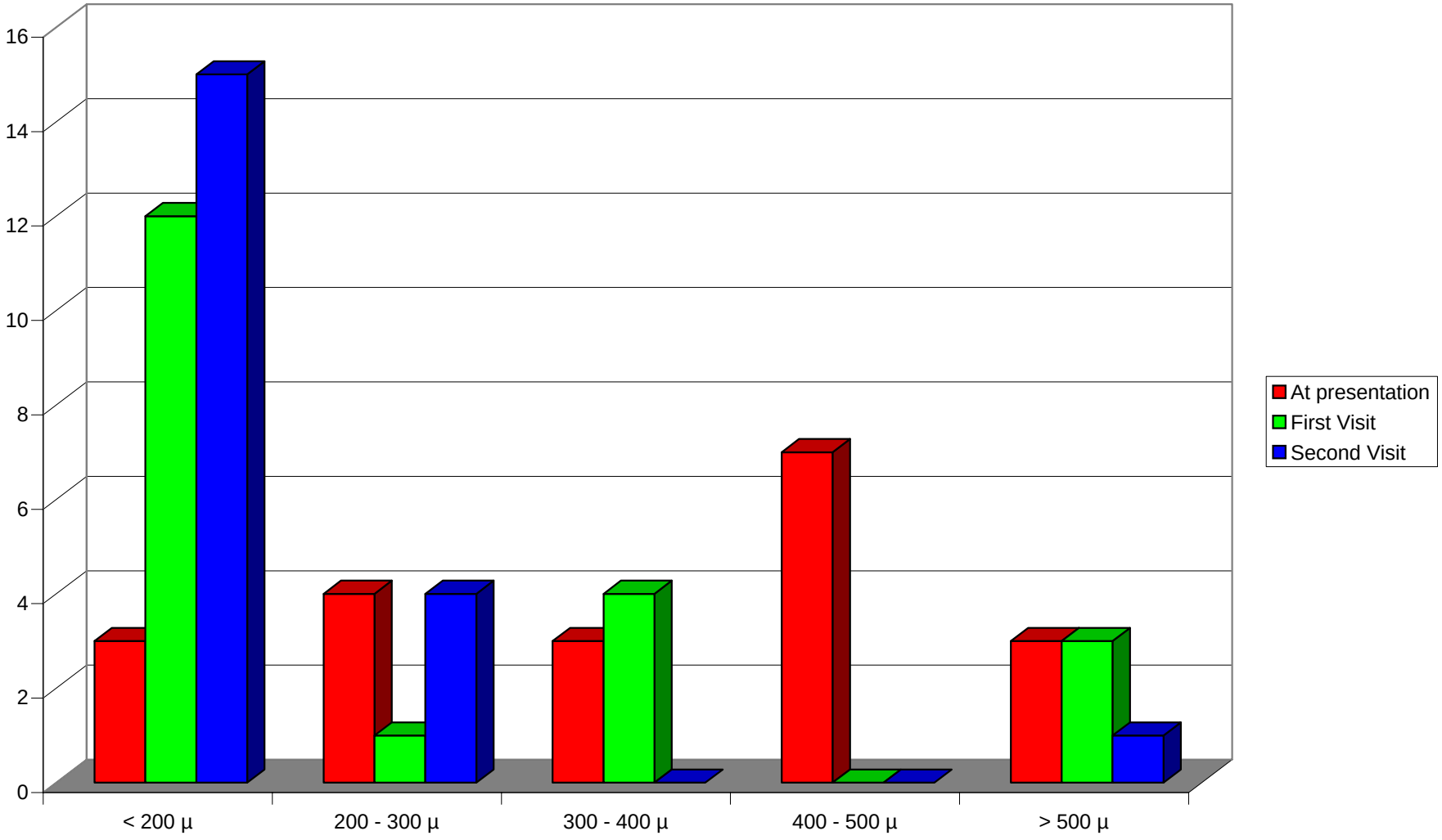

S. No.	Name	MRD No.	Age	Sex	Eye	Surgery Done	Visual Problem	Duration	BCVA	NV	Retinal Findings	FFA findings	OCT Findings	Management	I			II			Final Visual Acuity	Any recurrence
													Macular thickness in microns		VA	OCT in microns	FFA	VA	OCT in microns	FFA		
1	Thomas	400758	75	M	LE	Phaco with allergan foldable IOL	Improvement after cataract surgery then decrease in vision	6 Weeks	6/12	N8	Loss of foveal depression, thickening of retina, multiple cystoid	Flower petal - hyperfluorescence during late phase	492	Predmet e/d qid, Ketlur e/d qid	6/12	380.00	Leak present	6/12	130	No leak	6/9	--
2	Pappu	401036	70	M	LE	SICS with AC IOL / PC Rent	Improvement after cataract surgery then decrease in vision	4 Weeks	6/18	N12	Loss of foveal depression, thickening of retina, multiple cystoid	Flower petal - hyperfluorescence during late phase	180	Predmet e/d qid, Ketlur e/d qid	6/24	176.00	No leak	6/18	150	No leak	6/12	--
3	Kaliyamoorthy	382362	50	M	RE	SICS with PC IOL	Improvement after cataract surgery then decrease in vision	6 Weeks	6/9	N8	Retinal thicking, multiple cystoid spaces	Flower petal - hyperfluorescence during late phase	420	Predmet e/d qid, Ketlur e/d qid	6/12	200.00	Leak present	6/9	150	No leak	6/6	--
4	Gopalakrishnan	401996	65	M	RE	SICS with PC IOL	Improvement after cataract surgery then decrease in vision	6 Weeks	6/36	N8	Loss of foveal depression, multiple cystoid spaces	Flower petal - hyperfluorescence during late phase	605	Predmet e/d qid, Ketlur e/d qid	6/18	360.00	Leak present	6/19	210	No leak	6/12	--
5	Ramiah	354113	65	M	RE	Phaco with IOL	Improvement after cataract surgery then decrease in vision	8 weeks	6/24p	N8	Loss of foveal depression, multiple cystoid spaces	Flower petal - hyperfluorescence during late phase	703	Predmet e/d qid, Ketlur e/d qid	6/18	560.00	Leak present	6/18	250	Leak persists	6/12	--
6	Rajamanickam	401199	55	M	LE	SICS with PC IOL	Improvement after cataract surgery then decrease in vision	6 Weeks	6/60	N6	Loss of foveal depression, multiple cystoid spaces	Flower petal - hyperfluorescence during late phase	600	Predmet e/d qid, Ketlur e/d qid	6/12	600.00	Leak present	6/12	400	Leak persists	6/9	--
7	Narasimhan	362679	74	M	RE	Phaco with PC IOL	Improvement after cataract surgery then decrease in vision	8 weeks	6/18	N12	Loss of foveal depression, multiple cystoid spaces	Flower petal - hyperfluorescence during late phase	476	Predmet e/d qid, Ketlur e/d qid	6/12	650.00	Leak present	6/12	160	No leak	6/9	--
8	Kasiammal	314377	72	F	RE	SICS with PC IOL	Improvement after cataract surgery then decrease in vision	6 Weeks	6/24	N12	FR dull no obvious cystoid spaces	Flower petal - hyperfluorescence during late phase	480	Predmet e/d qid, Ketlur e/d qid	6/18	180.00	No leak	6/18	160	No leak	6/12	--
9	Samboornam Jambulinga	408549	56	M	RE	Trabeculectomy	Defective vision following surgery	6 Weeks	6/18	N8	0.8 cupping tinning of NRR, loss of foveal depression	Flower petal - hyperfluorescence during late phase	460	Predmet e/d qid, Ketlur e/d qid	6/18	360.00	Leak present	6/12	90	No leak	6/9	--
10	Susai	366367	40	M	LE	SICS with PC IOL	Following cataract surgery increase vision followed by decreased vision	8 weeks	6/60	N8	Loss of foveal depression, thinning of retina, multiple cystoid spaces	Flower petal - hyperfluorescence during late phase	300	Predmet e/d qid, Ketlur e/d qid	6/18	180.00	No leak	6/12	140	No leak	6/12	--
11	Manickam	494054	60	M	RE	SICS with PC IOL	Improvement after cataract surgery then decrease in vision	6 Weeks	6/60	N12	Loss of foveal depression, thinning of retina, multiple cystoid spaces	Flower petal - hyperfluorescence during late phase	380	Predmet e/d qid, Ketlur e/d qid followed by post subtenon	6/18	154.00	No leak	6/12	110	No leak	6/12	--
12	Booshana Bai	513273	57	F	RE	SICS with PC IOL	Improvement after cataract surgery then decrease in vision	7 weeks	6/18	N12	Loss of foveal depression, thinning of retina, multiple cystoid spaces	Flower petal - hyperfluorescence during late phase	203	Predmet e/d qid, Ketlur e/d qid	6/18	154.00	No leak	6/12	106	No leak	6/12	--
13	Arockia Samy	457510	69	M	LE	Phaco with IOL	Improvement after cataract surgery then decrease in vision	8 weeks	6/24	N12	FR dull, no cystoid spaces	Flower petal - hyperfluorescence during late phase	150	Nil Yag capsulatomy advised	6/18	120.00	No leak	6/9	120	No leak	6/12	--
14	Samuel	459470	80	M	LE	SICS with IOL	Improvement after cataract surgery then decrease in vision	6 Weeks	6/18	N12	No foveal depression, multiple cystoid spaces	Flower petal - hyperfluorescence during late phase	180	Predmet e/d qid, Acular e/d qid	6/18	120.00	No leak	6/12	120	No leak	6/9	--
15	Chellamuthu	467731	50	M	LE	ECC with PC IOL	Improvement after cataract surgery then decrease in vision	8 weeks	6/18	N12	Retinal thickening, absence of foveal depression	Flower petal - hyperfluorescence during late phase	207	Predmet e/d qid, Acular e/d qid	6/18	186.00	Leak present	6/12	160	No leak	6/12	--
16	Rajasekaran	483692	59	M	LE	SICS with PC IOL + Corneal Edema	Improvement after cataract surgery then decrease in vision	10 weeks	6/24	N12	Cystoid spaces + absence of foveal reflex	Flower petal - hyperfluorescence during late phase	506	Acular e/d qid + predmet e/d qid	6/24	310.00	Leak present	6/18	180	No leak	6/12	--
17	Annapattu	354113	60	F	RE	SICS with PC IOL	Improvement after cataract surgery then decrease in vision	4 weeks	6/18	N12	Cystoid spaces + absence of foveal reflex	Flower petal - hyperfluorescence during late phase	408	Acular e/d qid + predmet e/d qid	6/36	300.00	Leak present	6/18	120	No leak	6/12	--
18	Annapattu	480680	50	F	RE	Phaco with IOL	Improvement after cataract surgery then decrease in vision	6 Weeks	6/8	N12	Cystoid spaces + absence of foveal reflex	Flower petal - hyperfluorescence during late phase	390	Acular e/d qid + predmet e/d qid	6/36	160.00	No leak	6/12	110	No leak	6/9	--
19	Monohar	278281	70	M	LE	SICS with PC IOL	Improvement after cataract surgery then decrease in vision	6 Weeks	6/12	N12	Cystoid spaces + absence of foveal reflex	Flower petal - hyperfluorescence during late phase	280	Acular e/d qid + predmet e/d qid	6/36	180.00	Leak present	6/12	70	No leak	6/18	--
20	Kumar	268843	60	M	RE	SICS with PC IOL	Improvement after cataract surgery then decrease in vision	8 weeks	6/24	N12	Cystoid spaces + absence of foveal reflex	Flower petal - hyperfluorescence during late phase	480	Acular e/d qid + predmet e/d qid	6/24	170.00	No leak	6/18	180	No leak	6/9	--

Male	16
Female	4

< 40	1
41 - 50	3
51 - 60	7
61 - 70	4
70 - 80	5

RE	11
LE	9

ECCE with	1
SICS with I	13
Phaco with	5
Filtering Su	1

< 4 weeks	2
4 - 6 weeks	10
6 - 8 weeks	7
> 8 weeks	1

	Pre Treatm	Post Treatment
6/18 - 6/12	11	19
6/36 - 6/18	6	1
6/60 - 6/36	4	0
< 6/60	0	0

< 6/60	0
6/60 - 6/36	0
6/36 - 6/18	1
6/18 - 6/6	19

	At presenta	First Visit	Second Visit
< 200 µ	3	12	15
200 - 300 µ	4	1	4
300 - 400 µ	3	4	0
400 - 500 µ	7	0	0
> 500 µ	3	3	1