

# **Effectiveness of Prenatal Ultrasonography in Detecting Fetal Anomalies and Perinatal Outcome of Anomalous Fetuses**

*Dissertation submitted to*

THE TAMIL NADU DR.M.G.R.MEDICAL UNIVERSITY

*In partial fulfillment of the regulations*

*for the award of degree of*

**M.D. OBSTETRICS AND GYNAECOLOGY**

**BRANCH-II**



**GOVT.STANLEY MEDICAL COLLEGE**

**CHENNAI**

**APRIL 2012**

## **BONAFIDE CERTIFICATE**

Certified that this dissertation is the bonafide work of **Dr.S.SARANYA** on **EFFECTIVENESS OF PRENATAL ULTRASONOGRAPHY IN DETECTING FETAL ANOMALIES AND PERINATAL OUTCOME OF ANOMALOUS FETUSES** during her M.D., (Obstetrics & Gynaecology) course from April 2009 to April 2012 at Govt Raja Sir Ramasamy Mudaliar Lying-in Hospital, attached to Stanley Medical College, Chennai.

**Prof. Dr. N. Hephzibah Kirubamani**

**M.D., D.G.O., MICOG., Ph.D.,**

*Professor and Head of Department,*

*Department of Obstetrics and Gynaecology,*

*Govt RSRM Lying in Hospital,*

*Govt Stanley Medical College,*

*Chennai*

**Prof. Dr. R. Selvi M.D.,**

**DEAN i/c,**

*Govt Stanley Medical College,*

*Chennai – 600 001.*

## ACKNOWLEDGEMENT

At the outset, I would like to place on record my deep sense of gratitude to the **Prof. Dr. R. Selvi M.D.**, Dean i/c, Stanley Medical College for allowing me to use the hospital facilities for this study.

The present study, bears at every stage, the impression of the meticulous attention of our beloved chief **Prof. Dr. N. Hephzibah Kirubamani**, Professor & H.O.D of Obstetrics and Gynaecology. She was instrumental in starting first ever Fetal Care Clinic in government setup which actually made this endeavour a successful one. I fear to imagine what shape this work would have taken without her valuable guidance. I take this opportunity to express my heartfelt gratitude for her inspiration and support not just for this research, but throughout my career.

A special note of thanks to **all my professors and assistant professors** for placing, guiding and goading me on the right track from the very beginning of my career in Obstetrics and Gynaecology and till this day.

An endeavour of this nature involves help and coordination, encouragement and advice of my departmental colleagues. My heartfelt thanks to all of them.

I can't find appropriate words to express my gratitude towards my parents who sculpted in me a humane nature.

Last but not the least, I express my thanks to all my patients who endured with me in a patient manner. I pray the Almighty to bless them with healthy babies.

# CONTENTS

	PAGE NO.
❖ INTRODUCTION	01
❖ REVIEW OF LITERATURE	04
❖ AIMS AND OBJECTIVES	30
❖ MATERIALS AND METHODS	32
❖ RESULTS AND OBSERVATION	38
❖ DISCUSSION	56
❖ SUMMARY	66
❖ CONCLUSION	68
❖ REFERENCES	
❖ ANNEXURE	
➤ PROFORMA	
➤ MASTER CHART	

# INTRODUCTION

## **INTRODUCTION**

Fetal anomaly is one of the most emotionally charged issues that parents, obstetricians and diagnosticians may have to face. During the past two decades, Ultrasound had undergone a transformation that has allowed us to answer not only the basic question as to whether the patient is pregnant but also whether fetal anomaly is present. The key to an accurate antenatal diagnosis is careful scanning of the fetus and first-hand knowledge about fetal anatomy and the knowledge of abnormalities that may be associated with a particular anomaly.

Screening and Diagnosis are the two faces of fetal imaging. The number of, and gestational age at which these examinations are performed are not driven only by technical and developmental factors, but also by economic and social considerations, as well as legal aspects surrounding termination of pregnancy. As a result, screening has moved towards earlier gestations while diagnostic accuracy is increasing at later gestations, when Termination of Pregnancy is either not an option or has stopped being relevant to the management of the pregnancy. However there is a continuum between them, so much so that it is often difficult to draw a clear separation line. One aspect can benefit from the other when this continuum transforms into a progressive, pragmatic and didactic approach of diagnosis.

When addressing Screening one should distinguish between universal screening and targeted screening. Targeted screening refers to the examination of women at known increased risk of having off-spring with congenital anomalies. Two risk situations can be distinguished for such an indication-based only ultrasound scan. Firstly, there is the situation that risk factors are known prior to the pregnancy, i.e. a previously affected infant, a parent with a congenital anomaly, maternal type 1 Diabetes Mellitus, maternal use of antiepileptic drugs. In this subset of

women, 18-22 weeks is the ideal time for a thorough fetal anomaly scan. In another group the ultrasound scan for suspected fetal anomalies is based on abnormal obstetric findings that appear during the current pregnancy. Whereas in early pregnancy it is fetal nuchal translucency which is closely associated with chromosomal abnormalities, notably trisomy 21 and cardiac anomalies, obstetric markers for fetal congenital anomalies later in pregnancy include poly- and oligohydramnios, severe fetal growth restriction and fetal cardiac arrhythmias.

Ultrasound is the main diagnostic tool in the prenatal detection of congenital anomalies. It allows the examination of external and internal anatomy of the fetus and the detection of not only major defects but subtle markers of the chromosomal abnormalities and genetic syndromes. Although some women are at high risk of fetal abnormalities, either because of family history or due to exposure to teratogens, such as infection and various drugs, the vast majority of fetal abnormalities occur in the low-risk group. Consequently, Ultrasound examination should be offered to all pregnant women. The scan which is usually performed at 18-23 weeks, should be carried out to a high standard, and should include systematic examination of the fetus to detect both major and minor defects.

Since many fetal anomalies are associated with an increased risk of chromosomal anomalies, karyotype analysis is offered as an investigation for the anomaly or anomalies. An anomaly or anomalies with a documented normal karyotype require classification as isolated or as part of a defined syndrome, sequence, or association. Over the past years the role of the fetal imaging specialist has evolved from just listing the anomalies detected in a fetus to recognizing the specific syndrome or sequence or association of which these anomalies are components of. This facilitates proper counseling of the parents as well as management planning.


**REVIEW OF  
LITERATURE**



## Ultrasound in Obstetrics – A brief look into the Past

*“Those who cannot learn from History are doomed to repeat its Mistakes” – George Santayana*

The Obstetric Ultrasound story begins in 1961 when an Obstetrician in Scotland, Ian Donald, invented Biparietal Diameter (BPD). And soon, fetal cephalometry became the standard method for the study of fetal growth for many years. Within the next few years it became possible to study pregnancy from beginning to end and diagnosis of complications like multiple pregnancies, fetal abnormality and placenta praevia became possible.



The Gestational sac diameter in the assessment of fetal maturity was described by Lou M Hellman and M Kobayashi in 1969. The ability to recognize and confirm the presence of fetal cardiac action in early pregnancy was considered to be one of the most indispensable uses of ultrasonography (and still is).

Gray scale equipments had soon become widely available commercially by 1976. The addition of gray scale had been instrumental at that point in time to the evolution of the measurement of the fetal abdominal circumference, first described by the Campbell.

The invention of the real-time scanner had enabled much more effective diagnosis of many fetal malformations and in particular cardiac anomalies which hitherto was impossible to diagnose accurately. Fetal sonography and prenatal diagnosis (a term which was only coined in the 1970s) had emerged as the 'new' science in Obstetrics and fetal medicine.

The diagnosis of fetal malformations obviously received enormous attention that was deserved and findings of many abnormalities diagnosable by ultrasound have been described. Ian Donald included a case of hydrocephaly in one of his early "introduction" ultrasound papers in 1961. In Bertil Sunden's thesis in 1964 there was description of the diagnosis of anencephaly in the third trimester. In 1968 D Hofmann and Hans Hollander in Germany reported on 9 cases of 'hydrops fetus universalis'. The diagnosis and management of a 17 weeks anencephaly was reported as early as 1972 by Stuart Campbell using static B-mode equipment. This was followed by the diagnosis of spina bifida in 1975. They were the first cases of such conditions in which a correct diagnosis by ultrasound had effectively led to a termination of pregnancy.

The ability to recognize and follow up in utero of all these malformations by ultrasound has opened up further the entire avenue of "Prenatal Diagnosis" and has markedly enhanced and pushed forward the study of congenital abnormalities among obstetricians, pediatricians, geneticists, pathologists and other allied specialties.

With improvements in ultrasonic and computer technology, work on three-dimensional visualization began to appear in the early 1980's. Kazunori Baba at the Institute of Medical Electronics, University of Tokyo, Japan, first reported on a 3-D ultrasound system in 1984 and succeeded in obtaining 3-D fetal images by processing the raw 2-D images on a mini-computer in 1986. In 1996, Nelson's group and the Medical Imaging group at the university College Hospital in London published independent researches on 4-D (motion 3-D) fetal echocardiography, using sonographic cardiac gating methods to remove motion artefacts, which are present with conventional (static) 3-D methods.

## **REVIEW OF LITERATURE**

Aside from confirming viability and establishing gestational age, ultrasound may also indicate the possibility of an abnormality. An obvious structural problem, such as anencephaly, will have predictable consequences that can be discussed with the patient with some confidence. Less straightforward is the case in which a scan identifies a so called "soft marker"—a minor, usually transient, structural change which may indicate a risk of serious fetal anomaly but which in it is probably inconsequential.

### **Imaging Parameters for a Standard Fetal Examination**

The American College of Radiology and American Institute of Ultrasound in Medicine practice guidelines and technical standards recognize that

- ❖ Fetal cardiac activity, fetal number, and presentation should be reported.
- ❖ A qualitative or semi quantitative estimate of amniotic fluid volume should be reported.
- ❖ The placental location, appearance, and relationship to the internal cervical os should be recorded. The umbilical cord should be imaged, and the number of vessels in the cord should be evaluated when possible.
- ❖ Gestational age assessment & Fetal weight estimation.
- ❖ Maternal anatomy - Evaluation of the uterus, adnexal structures, and cervix should be performed when appropriate.
- ❖ Fetal anatomic survey.

Fetal anatomy, as described in this document, may be adequately assessed by ultrasound after approximately 18 weeks' gestational (menstrual) age.

The following areas of assessment represent the minimal elements of a standard examination of fetal anatomy. A more detailed fetal anatomic examination may be necessary if an abnormality or suspected abnormality is found on the standard examination.

i. Head, face, and neck

Cerebellum

Choroid plexus

Cisterna magna

Lateral cerebral ventricles

Midline falx

Cavum septi pellucidi

Upper lip

ii. Chest

The basic cardiac examination includes a 4-chamber view of the fetal heart.

If technically feasible, views of the outflow tracts should be attempted as part of the cardiac screening examination.

iii. Abdomen

Stomach (presence, size, and situs)

Kidneys

Bladder

Umbilical cord insertion site into the fetal abdomen

Umbilical cord vessel number

iv. Spine

Cervical, thoracic, lumbar, and sacral spine

v. Extremities Legs and arms: presence or absence

The minimum standard for a "20 week" anomaly scan - Recommendations given by Royal College of Obstetricians & Gynaecologists (RCOG) and Royal College of Radiologists

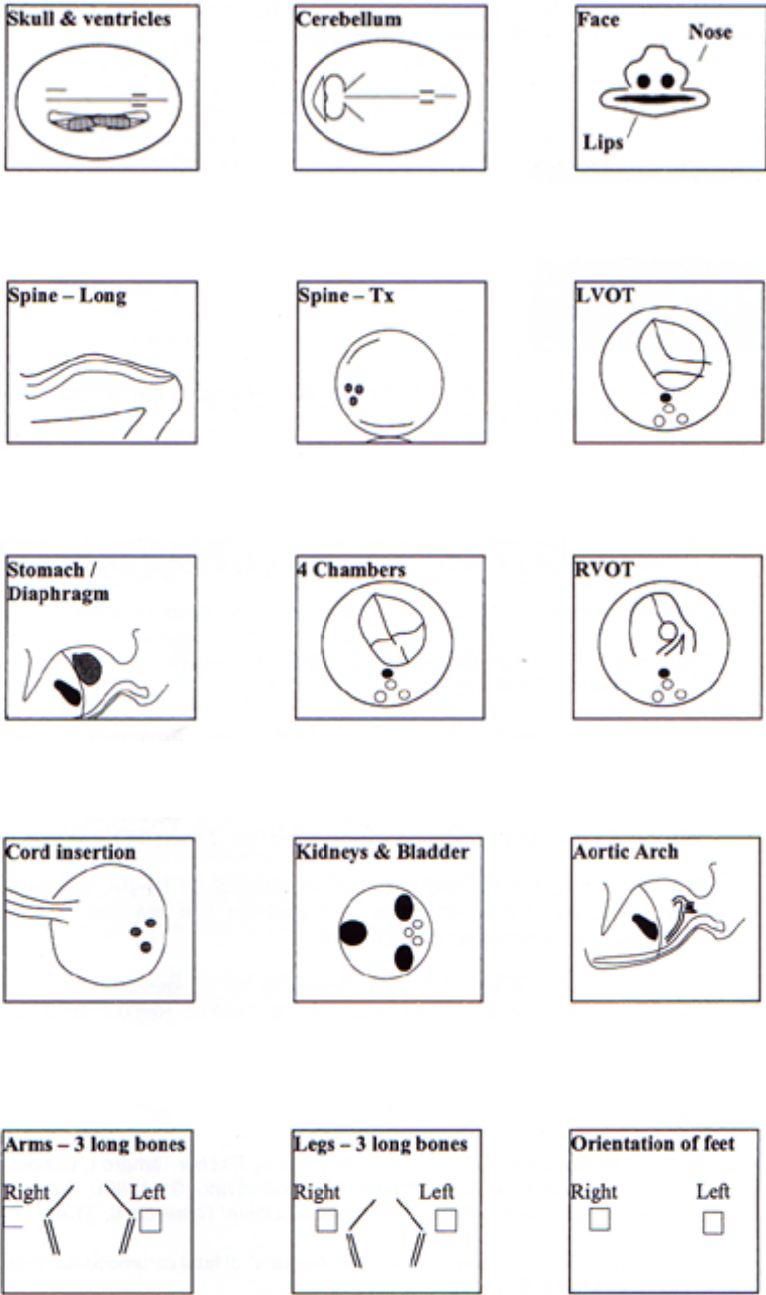
*Fetal Normality*

- Head shape + internal structures cavum pellucidum cerebellum ventricular size at atrium (<10 mm)
- Spine: longitudinal and transverse
- Abdominal shape and content at level of stomach
- Abdominal shape and content at level of kidneys and umbilicus
- Renal pelvis (<5 mm AP measurement)
- Longitudinal axis - abdominal-thoracic appearance (diaphragm/bladder)
- Thorax at level of 4 chamber cardiac view
- Arms - three bones and hand (not counting fingers)
- Legs - three bones and foot (not counting toes)

If resources allow, the following could be added to the features mentioned above

- Cardiac outflow tracts
- Face and lips

Baseline fetal anomaly scan



**Roberts AB et al (1993)** conducted an audit of ultrasound screening for fetal abnormalities in central Auckland 1988-89. There were 12,909 births. 218 babies had a congenital abnormality of which 88% were scanned antenatally. 48% of abnormalities were detected (27% before 24 weeks). In fetuses that were scanned the detection rate was 52% (44% before 24 weeks). The range of detection of specific abnormalities included neural tube defects 95% and congenital heart defects 16%. The conclusions offered were 1. Major abnormalities of the central nervous system, renal tract and abdominal wall have a high detection rate. 2. Cardiovascular, facial and gastrointestinal abnormalities are either not detectable or difficult to detect. 3. Detection rates could be improved by routine scanning, better ultrasound equipment and training, and by the introduction of maternal biochemical screening tests.

**Saari-Kemppainen A et al (1994)** compared whether systematic strictly timed screening of all pregnancies would improve the detection of major fetal anomalies. All pregnant women were randomly allocated for one ultrasound screening examination between the 16th and 20th weeks of gestation. Otherwise the screening (N = 4691) and control groups (N = 4619) received the same antenatal care. In the screening group, 40% of major fetal anomalies were detected in the screening, and 11 abortions were induced because the malformation was either lethal or severely handicapping. In the control group, 77.0% of participants had ultrasound examination any time during pregnancy. By ultrasound 13 (27%) major fetal anomalies were detected, only two of these before the 21st week of gestation. The perinatal mortality rate was 4.2 per 1000 in the screening group and 8.4 per 1000 in the control group ( $p = 0.013$ ). The detection of major fetal anomalies in ultrasound screening can reduce perinatal mortality. They concluded that a

systematic search for fetal anomalies should be included in the ultrasound screening of all pregnancies.

**Lee K et al (1998)** performed a retrospective study over a 5 year period (1990-1994) to evaluate the effectiveness of prenatal ultrasonography in terms of sensitivity, specificity, and predictive values in detecting fetal anomalies by comparing prenatal ultrasonic results with anomalies found in neonates and the perinatal outcome of anomalous fetuses. From a total of 5544 singletons, 4819 had at least one ultrasound scan (87%). A total of 136 fetuses were structurally abnormal (2.82%) and 200 major anomalies were recorded. The overall sensitivity of the ultrasound test was 78.7% for abnormal fetuses and 58.0% for anomalies. The overall specificity was 99.9% and the positive and negative predictive values were 97.3% and 99.4%, respectively. The sensitivity of ultrasound for the detection of abnormal fetuses before 24 weeks was 22.8% which was associated with a 61% (25/41) termination rate and a 24.4% (10/41) postnatal survival rate.

**Behrens O et al (1999)** studied the congenital malformations in the study population of 11,172 deliveries and compared it with corresponding antenatal findings. 341 defects were found in 297 children from mothers who had had prenatal care. 8.8% of all defects were lethal, 37% severe. 237 (69.5%) were classified as "diagnosable by ultrasound prenatally". 125 of them (53%) were identified prenatally, with high rates of 71% in central nervous system, 65.5% in intestinal and 54% in urogenital tract, while the detection rate was only 13.6% in chromosomal and 3.3% in cardiac defects. Only 14.3% were found before 24 weeks of gestation.



**Papp C et al (2007)** evaluate the contribution of second trimester ultrasound examination to the prenatal diagnosis of trisomy 21 in 207 fetuses with this aneuploidy. The type and frequency of abnormal sonographic findings were determined. Singleton fetuses that had prenatal sonography during the second trimester, and then underwent cytogenetic evaluation in their institution were included in the Study. An abnormal karyotype was diagnosed in 514 cases (2.3%); among them 207 fetuses with trisomy 21 were detected (40.3%). Abnormal sonography was seen in 63.8% of the cases. Structural anomalies were detected in 28.5% of the trisomy 21 fetuses, among them cardiac defects (15.9%), central nervous system anomalies (14.5%), and cystic hygromas (6.8%) were the most common.

**Papp C et al (2007)** assessed the value of perinatal autopsy following mid-trimester termination of pregnancy due to major fetal trisomies. Singleton fetuses (n=305) that underwent prenatal sonography and karyotyping during the second trimester of pregnancy and that had trisomy 21, trisomy 18, or trisomy 13 constituted the study population. The findings of second trimester sonography and fetal autopsy were compared. Altogether, 611 separate major structural malformations were diagnosed during autopsy. Full agreement was achieved between sonography and autopsy in 35.8% of the malformations. The additional findings at autopsy (64.2%) involved mainly two organ systems: face, including ears and eyes, and extremities, including hands and feet. Some ultrasound findings were not confirmed at autopsy (n=49). They concluded prenatal sonography and perinatal autopsy should be considered as complementary ways of increasing our knowledge about the possible features of fetal aneuploidies.

**Aagaard-Tillery et al (2009)** studied 7,842 pregnancies including 59 with Down's syndrome. The detection rate for the genetic sonogram alone was 69%; the detection rate increased from 81% to 90% with the combined test, from 81% to 90% with the quadruple test, from 93% to 98% with the integrated test, from 97% to 98% with the stepwise test, and from 95% to 97% with the contingent test. The stepwise and contingent use of the genetic sonogram after first-trimester screening both yielded a 90% detection rate. They concluded that Genetic sonography can increase detection rates substantially for combined and quadruple tests and more modestly for sequential protocols.

**Fadda GM et al (2009)** established the effectiveness of a program of ultrasound screening in detecting fetal malformations in prenatal period. The examined pregnant women were 42,256 and the period of reference ranged from January 1981 to December 2004. In the considered period were reported 1050/42,256 (2.48%) cases of fetal malformations, of which 974 single and 76 multiple malformations. The cases of malformations diagnosed in prenatal period were 578/1050 (55.05%), of which 65/578 (11.24%) multiple anomalies. The overall sensitivity was 55.05% (95% confidence interval: 52-58%), with a variability from the 32.95% (cardiovascular system) to 81.05% (central nervous system) in relationship to the typology of the examined apparatus. The overall specificity was 99.88% (95% confidence interval: 98-99.9%), the predictive positive value 91.89% (95% confidence interval: 89-93%) and the negative predictive value 98.87% (95% confidence interval: 95-99%).

**Pitukkiyornakorn S et al (2009)** evaluated the detection rate of major fetal anomalies by mid-trimester routine ultrasound screening in a single center with low-risk population. The

ultrasonographic results were compared with the pregnancy outcome in aspects of prediction of major fetal anomalies. 316 out of 29,839 (1.06%) had major anomaly. 144 fetuses (45.57%) were diagnosed as having major anomaly by routine ultrasound screening. 172 fetuses (54.43%) were undiagnosed. The sensitivity, specificity, positive predictive value, and negative predictive value were 45.57%, 99.97%, 94.74% and 99.42% respectively. Although the rate of the detection of major congenital fetal anomaly was low, almost all lethal and life threatening anomalies could be diagnosed antenatally thus allowing the option of counseling, pregnancy termination, or selective referral.

**Borell et al (2010)** conducted a literature search to determine the clinical value of the 11- to 13 (+6)-week ultrasound evaluation for diagnosis of congenital abnormalities. The reported data were integrated and a pooled analysis was performed to provide meaningful clinical interpretations. They analyzed data from 36,237 pregnancies generated by eight centers and the overall detection rate of major congenital anomalies during the 11- to 13(+6)-week ultrasound evaluation is only 29% (95% confidence interval 25 to 33). They concluded that prenatal diagnosis at these stages of development could only improve if evaluations are implemented in accordance to very well delineated protocols. Hence, Target scan at 18-20 weeks is still the backbone of the Prenatal Diagnosis of Congenital Malformations.

**Santos XM et al (2010)** performed a retrospective review of patients referred to the Texas Children's Fetal Center (TCFC) between September 2001 and July 2007 with a fetal structural malformation. Data were abstracted to compare the referral diagnosis to TCFC imaging diagnoses and both were compared to postnatal diagnosis. 224 patients were referred who had a

fetal US and MRI at TCFC. The most frequent indications were for abnormalities of the central nervous system (38%) and lung/thoracic cavity (34%), with congenital diaphragmatic hernia (CDH) the single most common referral diagnosis (n = 39; 17%). In 99 cases (42.7%) the referral diagnosis was concordant with the post-referral diagnosis, however, in 68 cases (29.3%) the post-referral diagnosis changed completely, and in 65 cases (28%) additional findings were discovered. Prenatal diagnoses following imaging at TCFC were concordant with postnatal diagnoses in 94.9% of cases.

**Phadke SR and Gupta A (2010)** conducted a retrospective study over a 7-year period from 2001 to 2007. Pregnancies terminated after prenatal identification of fetal malformation were evaluated by post mortem examination of 91 fetuses. Fetal autopsy provided a definite diagnosis in 72/91 (79.1%) of the cases. Fetal autopsy confirmed the sonographic findings in 89 of 91 cases (97.8%). In 66 (72.5%) cases there was complete concordance between prenatal and autopsy findings, while in 23 cases there was major concordance. There were 49 cases with isolated malformations, 41 cases with multiple (89) malformations, and, in one case, no malformation was found at autopsy. This study emphasized the importance of autopsy in providing accurate etiologic diagnosis necessary for genetic counseling.

## Fetal Anomalies – A glance

### Central Nervous System Anomalies

#### a) Neural tube defects

These include Anencephaly, spina bifida and encephalocele mainly. Anencephaly and Spina bifida, with an approximately equal prevalence, account for 95% of the cases and encephalocele for the remaining 5%. As reported in several epidemiological survey, the prevalence of NTDs was fairly high and varied in different parts of India (ranging from as low as 1.1/1000 live births in Kolkata to as high as 18/1000 live births in the state of Rajasthan). Another study, indicated that the prevalence of NTDs was 11.4/1000 births in southern areas of India. Chromosomal abnormalities, single mutant genes, and maternal diabetes mellitus or ingestion of teratogens, such as antiepileptic drugs, are implicated in about 10% of the cases. When a parent or previous sibling has had a neural tube defect, the risk of recurrence is 5-10%. Periconceptual supplementation of the maternal diet with folate reduces by about half the risk of developing these defects.

**Anencephaly** – In Anencephaly, there is absence of the cranial vault (acrania) with secondary degeneration of the brain. The diagnosis of anencephaly during the second trimester of pregnancy is based on the demonstration of absent cranial vault and cerebral hemispheres. Associated spinal anomalies are found in up to 50% of cases. In the first trimester, the diagnosis can be made after 11 weeks, when ossification of the skull normally occurs. Ultrasound reports have demonstrated that there is progression from acrania to exencephaly and finally anencephaly. In the first trimester, the pathognomic feature is acrania, the brain being either entirely normal or at varying degrees of distortion and disruption. In study conducted among 8640 antenatal cases by Dhapate et al in Maharashtra in 2007, the incidence of Anencephaly is

0.19%. But the incidence of Anencephaly among Craniospinal anomalies is as high as 50 % ( 17 out of 35 cases).

**Spina bifida** – The neural arch, usually in the lumbosacral region, is incomplete with secondary damage to the exposed nerves. Diagnosis of spina bifida requires the systematic examination of each neural arch from the cervical to the sacral region both transversely and longitudinally. In the transverse scan the normal arch appears as a closed circle with an intact skin covering, whereas in spina bifida the arch is ‘U’-shaped and there is an associated bulging meningocele or meningomyelocele. The extent of the defect and any associated kyphoscoliosis are best assessed in the longitudinal scan. The diagnosis of spina bifida has been greatly enhanced by recognition of associated abnormalities in the skull and brain. These abnormalities are secondary to the Arnold-Chiari malformation and include frontal bone scalloping (lemon sign), and obliteration of the cistern magna with either an “absent” cerebellum or abnormal anterior curvature of the cerebellar hemispheres (banana sign). Dhapate et al have reported an incidence of Spina bifida as 35% among all other Craniospinal anomalies.

**Encephalocele** – They are cranial defects, usually occipital, with herniated fluid-filled or brain-filled cysts. Alternative sites include the frontoethmoidal and parietal regions.

#### b) **Hydrocephalus and Ventriculomegaly**

In hydrocephalus, there is pathological increase in the size of the cerebral ventricles.

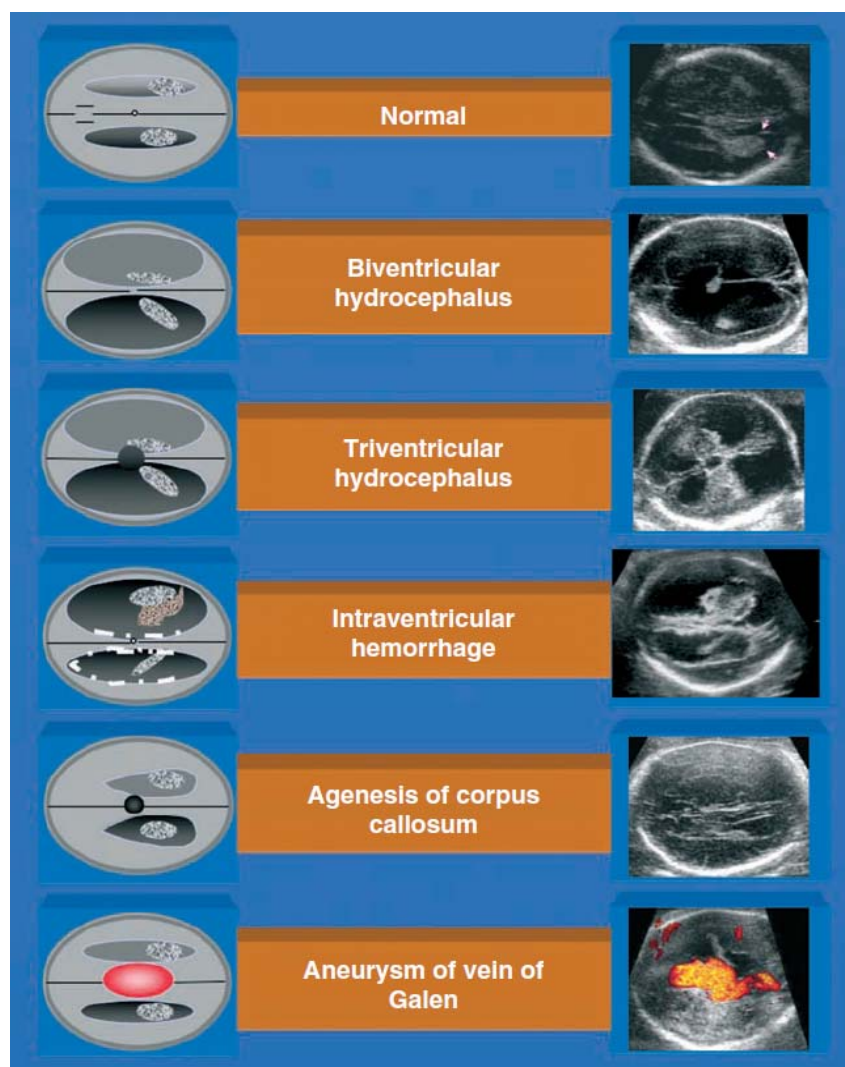
Incidence: High. 0.3–1.5 per 1000 births (global); probably higher *in utero*. In an Indian study, out of 124 malformed fetuses 41(27.33%) fetuses had ventriculomegaly.

Ultrasound diagnosis: *Axial transventricular view*. Uni- or biventricular dilatation  $\geq 10\text{mm}$ . It can be isolated or associated with other congenital (Dandy Walker Malformation, corpus callosum agenesis) or acquired (hemorrhage, infections) CNS anomalies.

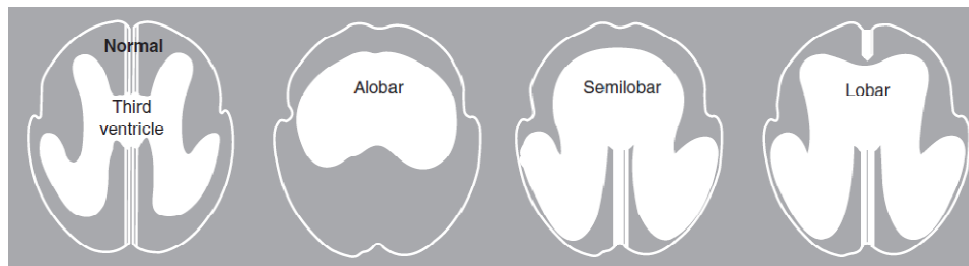Risk of chromosomal anomalies: Moderate to high. 1.5–12% for isolated ventriculomegaly; 9–36% if ventriculomegaly is associated with other malformations; almost absent if ventriculomegaly is associated with acquired lesions.

Risk of non-chromosomal syndromes: High.

Outcome: Variable, and depending on the etiology and associated lesions.



**c) Holoprosencephaly** – This is a spectrum of cerebral abnormalities resulting from incomplete cleavage of the forebrain. There are 3 types according to the degree of forebrain cleavage. The alobar type, which is the most severe, is characterized by a monoventricular cavity and fusion of thalami. In the semi lobar type, there is partial segmentation of the ventricles and cerebral hemispheres posteriorly with incomplete fusion of the thalami. In lobar type, there is normal separation of the ventricles and thalami but absence of the septum pellucidum.



Incidence: 1 in 6000–16 000 births, but much higher in aborted fetuses (1 in 250).

Ultrasound diagnosis: *Midsagittal, axial, and coronal views*. Alobar and semi lobar HPE: completely or partially fused thalami, single or partially fused ventricles, absence of the cavum septi pellucidi, corpus callosum dysgenesis, midline facial abnormalities. Lobar HPE: fusion of the frontal horns, absence of the cavum septi pellucidi, corpus callosum dysgenesis.

Risk of chromosomal anomalies: High. Trisomy 13 is associated in up to 40% of cases, especially if other anomalies are associated.

Outcome: Very poor in alobar and semi lobar forms, better in lobar form.

#### **d) Agenesis of the Corpus Callosum**

Developmental abnormalities of the corpus callosum include hypoplasia, agenesis, and dysgenesis. Agenesis of the corpus callosum can be complete or partial.

Incidence: From 0.3–0.7% in the general population to 2–3% in the developmentally disabled population.



Ultrasound diagnosis: *Midsagittal view*. Complete or partial absence of the corpus callosum.

*Axial views*: colpocephaly, absence of the cavum septi pellucidi (in complete agenesis).

*Coronal views*: lateral convexity and increased distance between the frontal horns.

Hilpert et al used transvaginal ultrasound and reported that the technique may be useful in identifying the intracranial structures and anomalies, especially in the late second and third trimester when the fetal head is presenting.

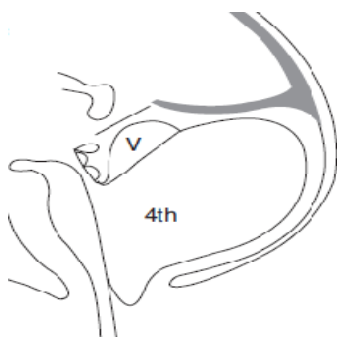Risk of chromosomal anomalies: High. 20%.

Outcome: From good to poor. However, 15–28% rate of significant neurodevelopmental delay also in isolated forms.

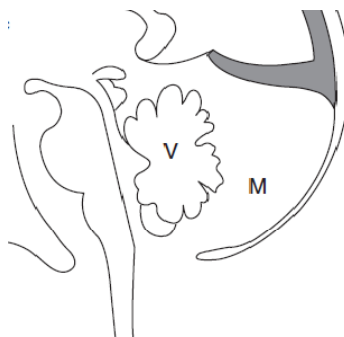
#### e) Dandy-Walker Complex

It refers to a spectrum of abnormalities of the cerebellar vermis, cystic dilatation of the fourth ventricle and enlargement of the cistern magna. The condition is classified into

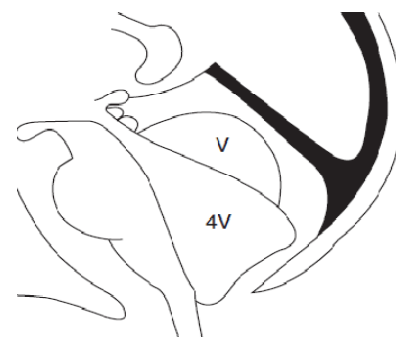
- a. Dandy-Walker malformation – complete or partial agenesis of the vermis and enlarged posterior fossa,
- b. Dandy-Walker variant – partial agenesis of the vermis without enlargement of posterior fossa,
- c. Mega cisterna magna – normal vermis and fourth ventricle.



Dandy Walker Malformation



Mega cisterna magna



Dandy-Walker variant

Incidence: 1 in 25 000–30 000 live births.

Ultrasound diagnosis: On the *midsagittal view of the fetal brain*, it is characterized by expansion of the posterior fossa, CSF collection (cystic dilatation of the 4th ventricle) determining an upward displacement of the tentorium, anticlockwise rotation of the vermis; partial or complete agenesis of the vermis.

Risk of chromosomal anomalies: High, up to 35% of cases.

Outcome: Poor when associated with other malformations and syndromes; less severe if isolated.

#### **f) Hydranencephaly**

Hydranencephaly is characterized by a complete or almost complete absence of the cerebral cortex, with the normal brain tissue being replaced by a large fluid collection covered by leptomeninges and dura. The presence of the falx and of the cranial nerves demonstrates that the hemispheres have developed but have subsequently been destroyed.

Incidence: 1–2.5 in 10 000 newborns.

Ultrasound diagnosis: A huge fluid collection filling the whole cranial cavity, with no recognizable cerebral cortex.

Risk of chromosomal anomalies: Low.

Outcome: Very poor.

#### **g) Arachnoid cyst**

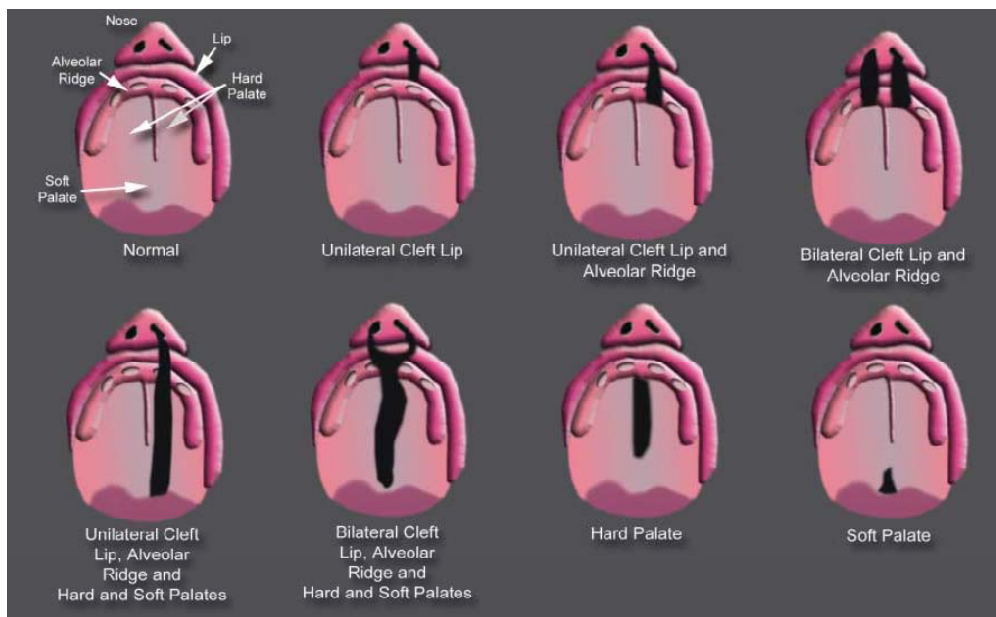
These are represented by extra-axial sonolucent cysts of variable dimensions, with regular walls, with or without septa, and which do not communicate with the ventricular system.

## h) Choroid Plexus cyst

Presence of single or multiple cysts in choroid plexuses of both lateral ventricles. They are usually of no pathological significance, but they are associated with an increased risk for trisomy 18 and possible 21.

## Facial Anomalies

Orbital defects, Hypertelorism, Hypotelorism, Microphthalmia/Anophthalmia, Facial cleft, Cleft lip, Cleft palate, Cleft lip/palate

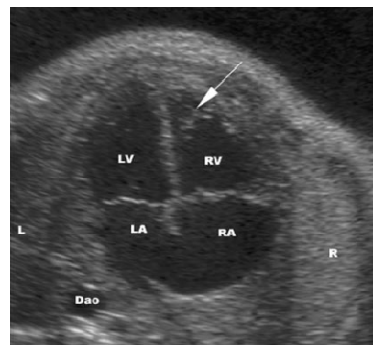


\*In the selected studies there was diversity in the gestational age at which the ultrasound examination was performed and there was considerable variety in the diagnostic accuracy of 2D ultrasound in the low-risk women, with prenatal detection rates ranging from 9% to 100% for cleft lip with or without cleft palate, 0% to 22% for cleft palate only and 0% to 73% for all types of cleft. 3D ultrasound in high-risk women resulted in a detection rate of 100% for cleft lip, 86% to 90% for cleft lip with palate and 0% to 89% for cleft palate only.

## **Cardiovascular anomalies**

Structural cardiac anomalies are estimated to occur in 8 of 1,000 live births. Cardiovascular anomalies are frequently associated with other congenital anomalies because the heart begins to develop the 3rd week after conception and continues to develop until the end of the 8th week. The ultrasonographic (US) view that is most commonly used is the four-chamber view, which allows assessment of abnormalities involving the atria and the ventricles. However, anomalies involving the outflow tracts of the aorta and pulmonary artery are not visualized on this view. By adding the base view of the heart, the outflow tracts can be visualized, thus increasing not only the sensitivity of detection of cardiac anomalies but also the accuracy of diagnosis.

Yagel et al showed that 80% of cardiac anomalies would be detected at 22 weeks' gestation with universal fetal echocardiography in a low-risk population.



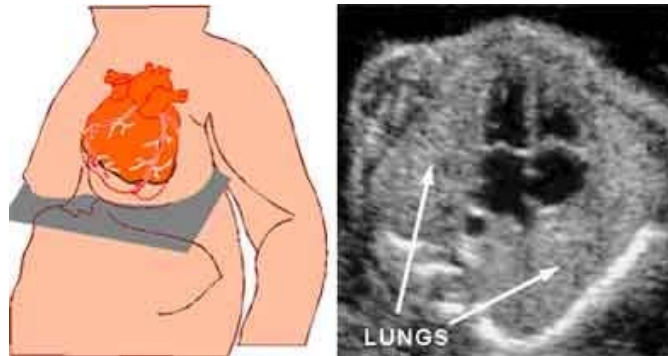
**Four – Chamber view**

### **Congenital Cardiac Defects that can be made out in Fetal 2-D Ultrasound**

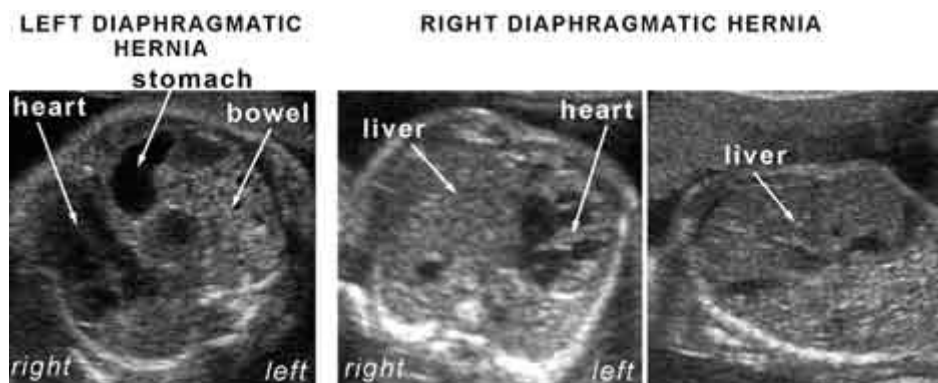
Atrioventricular septal defect, Univentricular heart, Aortic stenosis, Coarctation and Tubular hypoplasia of the Aorta, Interrupted Aortic arch, Hypoplastic left heart syndrome, Pulmonary stenosis and atresia, Ebstein's Anomaly and Tricuspid valve dysplasia, Conotruncal malformations, Transposition of the Great Arteries, Tetralogy of Fallot, Double outlet Right ventricle, Truncus Arteriosus communis, Cardiosplenic syndromes, Echogenic foci, Cardiac dysrhythmias.

## Pulmonary anomalies

At 18-23 weeks, the central third of the thoracic area at the level of the four chamber view is occupied by the heart and the remaining two-thirds by the lungs that are normally uniformly echogenic. A sagittal view of the fetal trunk usually allows one to identify the diaphragm as a thin sonolucent line separating the abdominal from the thoracic cavity.



**\*Diaphragmatic hernia** - In the presence of a defective diaphragm, there is herniation of the abdominal viscera into the thorax at about 10–12 weeks, when the intestines return to the abdominal cavity from the umbilical cord. Diaphragmatic hernia is found in about 1 per 4000 births. Diaphragmatic hernia can be diagnosed by the ultrasonographic demonstration of stomach and intestines (90% of the cases) or liver (50%) in the thorax and the associated mediastinal shift to the opposite side.



**\*Cystic adenomatoid malformation** - Cystic adenomatoid malformation of the lung is a developmental abnormality arising from an overgrowth of the terminal respiratory bronchioles. Prenatal diagnosis is based on the ultrasonographic demonstration of a hyperechogenic pulmonary tumor which is cystic (CAM type 1), mixed (CAM type 2), or solid – microcystic (CAM type 3).

In a study conducted by Cavoretta et al, 170 cases of CAM were analyzed and Microcystic type was the most common among the three types.

**\*Pleural effusion** - Fetal pleural effusions, which may be unilateral or bilateral, may be an isolated finding or they occur in association with generalized edema and ascites

**\*Lung sequestration** - In lung sequestration, a portion of the lung develops without connection to the airways. The blood supply to the abnormal lung tissue is through arteries that arise from the descending aorta rather than from the pulmonary artery. This condition is classically divided into intralobar (about 75%) and extralobar (about 25%).

### **Anterior Abdominal Wall Defects**

Developmental defects in the fetal anterior abdominal wall with resultant omphalocele or gastroschisis are rare anomalies having a frequency of approximately 1 in 2500 births.

\***Exomphalos** - An Exomphalos is the persistent herniation of the abdominal viscera into the umbilical cord. On ultrasound amnioperitoneal membrane is seen to cover an echogenic mass (herniated viscera) protruding through the umbilical ring. Omphalocele is seen in about 1 in 4,000 live births. Additional anomalies occur in up to 70% of cases.

\***Gastroschisis** - Gastroschisis is a defect in the abdominal wall, usually to the right of the umbilicus that allows bowel to protrude into the amniotic cavity. On ultrasound, multiple, round, freely floating structures along the abdominal wall suggests the diagnosis. Gastroschisis occurs with an incidence of 1:10,000 births.

\* Bladder Exstrophy and Cloacal Exstrophy

\* Body stalk anomaly

### **Gastrointestinal Tract anomalies:**

**Esophageal atresia** – It is found in about 1 in 3000 births. Prenatally, the diagnosis of esophageal atresia is suspected

When, in the presence of polyhydramnios, repeated ultrasonographic examinations failed to demonstrate the fetal stomach.

**Duodenal atresia** – Duodenal atresia is found in about 1 per 5000 births. Prenatal diagnosis is based on the demonstration of the characteristic “double-bubble” appearance of dilated stomach and proximal duodenum, commonly associated with polyhydramnios.

\*Hirschsprung’s disease, Choledochal cyst, Mesenteric and Omental cyst, Hepatic cyst, Intestinal duplication cyst.

## **Kidneys and Urinary Tract**

**Renal Agenesis** – Bilateral Renal agenesis is found in about 1 per 5000 births; while unilateral agenesis is found in about 1 per 2000 births. Antenatally, the condition is suspected by the combination of anhydramnios and empty fetal bladder. Failure to visualize the renal arteries is another important clue to the diagnosis in dubious cases.

**Infantile Polycystic Kidney Disease (Potter type I)** – It is found in about 1 per 30,000 births. This is an autosomal recessive condition. Prenatal diagnosis is based on the demonstration of bilaterally enlarged and homogeneously hyperechogenic kidneys.

**Multicystic Dysplastic Kidney Disease (Potter type II)** – It is found in about 1 per 1000 births. Ultrasonographically, the kidneys are replaced by multiple irregular cysts of variable size with intervening hyperechogenic stroma.

**Adult Polycystic Kidney Disease (Potter type III Renal dysplasia)** – It is found in about 1 per 1000 births. Prenatal diagnosis by ultrasonography is based on the demonstration of enlarged and hyperechogenic with or without multiple cysts. Unlike infantile polycystic kidneys, where there is a loss of the corticomedullary junction, in ADPKD there is accentuation of this junction.

**Obstructive Uropathies** –When the obstruction is complete and occurs early in fetal life, renal hypoplasia and dysplasia ensue. On the other hand, when it occurs in the second half of pregnancy, hydronephrosis will result and the severity of the renal damage will depend on the degree and duration of the obstruction.

### **Spectrum of Obstructive Uropathies:**

Hydronephrosis, Ureteropelvic Junction obstruction, Ureterovesical junction obstruction, Vesicoureteric reflux, Megacystic Microcolon, Intestinal Hypoperistalsis Syndrome, and Urethral obstruction.



## **Musculoskeletal Anomalies**

**Achondroplasia** - This condition is inherited as an autosomal dominant trait with 100% penetrance, 90% of cases are sporadic with an increased risk correlated with paternal age (more than 36 years) at the time of conception. Achondroplasia occurs in 1 in 25,000 live births.

**Osteogenesis imperfecta** – It is a heterogeneous group of conditions characterized by severe osseous fragility, defective ossification and multiple fractures. There are six types and type II is the most severe. The incidence for osteogenesis is 0.4:10,000 live births, about half of which represent Type II.

**Achondrogenesis** – It is a lethal skeletal dysplasia characterized by extreme hypoplasia of the bones, resulting in marked micromelia, disproportionately large calvaria and decreased bone ossification. Achondrogenesis occurs in approximately 6.4 in 1, 00,000 births and leads to death in utero or during the neonatal period.

**Thanatophoric Dysplasia** – Thanatophoric dysplasia is a uniformly lethal osteochondrodysplasia characterized by rhizomelia, micromelia, bowing of the femurs, thoracic hypoplasia, and macrocrania with a frequency of about 1.7 to 3.8 per 1,00,000 live births. The cause of death is cardio respiratory failure due to hypoplastic lungs.

\*Hypophosphatasia, Campomelic dysplasia, Jarcho-Levin syndrome, asphyxiating thoracic dysplasia (Jeune syndrome), Chondroectodermal dysplasia (Ellis van creveld syndrome), Diastrophic dysplasia, Limb deficiency or congenital amputations, Split hand and foot syndrome, Club hands, Polydactyly, Fetal Akinesia Deformation Sequence.

**AIMS**

**AND**

**OBJECTIVES**

## **AIMS AND OBJECTIVES**

The aims and objectives of this study are:

- ✓ To detect and characterize fetal malformations by ultrasonography
- ✓ To evaluate associated anomalies, if any, so that they can be brought under a single syndrome
- ✓ To study the influence of various fetal anomalies in obstetric decision making
- ✓ To compare and correlate prenatal ultrasound findings with postnatal examination
- ✓ To do radiography, autopsy and karyotyping whenever possible

**MATERIALS**

**AND**

**METHODS**

## **Materials and Methods**

This Study was carried out in Government RSRM Lying in Hospital, Chennai from January 2010 to September 2011. The cases were selected from those who attended the Outpatient Department and from those who are admitted to the Antenatal wards of Government RSRM Lying in Hospital, Chennai. Most of the patients were residents of North Chennai

### **Patient Selection:**

The antenatal Mothers who came for routine antenatal visits were screened for anomalies. Only singleton pregnancies were included. A thorough history was obtained in order to classify a pregnancy as “low risk” and “high risk”. “High risk” pregnancies were evaluated with extra caution. Those Mothers with anomalous babies detected by Level I ultrasound were chosen for our Study. They underwent Level II Ultrasound and the anomalies were characterized. 60 antenatal mothers with anomalous fetuses were detected from a total of 2960 patients.

### **Inclusion Criteria:**

- Antenatal mothers with fetal anomalies detected by antenatal ultrasound screening irrespective of gestational age
- Antenatal mothers with history of congenital anomalies in previous pregnancies
- Antenatal mothers with unexplained recurrent pregnancy loss
- Antenatal mothers with h/o medical disorders like diabetes, epilepsy, heart disease, psychiatric illness

- Antenatal mothers on chronic medications

**Exclusion Criteria:**

- Antenatal Mothers who have normal Ultrasound findings in Level I ultrasound
- Vesicular mole and Intrauterine demise on first Ultrasound study itself

**Clinical Evaluation:**

Detailed history regarding the consanguinity of marriage, past obstetric history, history of medical disorders, any history of anomalies in family members, history of any teratogenic drug intake, exposure to radiation were obtained. Health of the previous babies was enquired. A meticulous record of the investigations underwent by the participants were maintained. It includes Blood Grouping and Typing, Hemoglobin, Urinalysis, HIV, VDRL.

Per Abdomen and Per Vaginum Examination when necessary were done. The nature of the ultrasound study was explained to them and a written consent was obtained from each of them. The anomaly scan findings were then recorded as per the proforma enclosed in the annexure.

**Ultrasound evaluation:**

The patients were examined on TOSHIBHA ultrasound machine using 3.5 MHz curvilinear transducer transabdominally in all cases. Additionally, transvaginal ultrasound study was done with 5.0MHz transducer whenever appropriate. A complete study of fetal anatomy as per the guidelines laid out by the American College of Radiology (ACR), the American Institute

of Ultrasound in Medicine (AIUM) and the American College of Obstetricians and Gynaecologists (ACOG) was attempted in every case.

### **Scanning Technique:**

With the patients in supine position, coupling gel was applied over the abdomen and the ultrasound examination was carried out in the longitudinal, transverse and oblique positions, depending upon the variable lie of the fetuses. Magnification mode was sometimes used for better characterization of anomalies. Doppler study was done when appropriate. The findings were recorded in the same format as in the proforma (in Annexure). All the cases were followed up till the final outcome of pregnancy. Correlation of antenatal findings was attempted after birth by direct evidence, radiographs, ultrasonography, and computed tomography and by autopsy in few others.

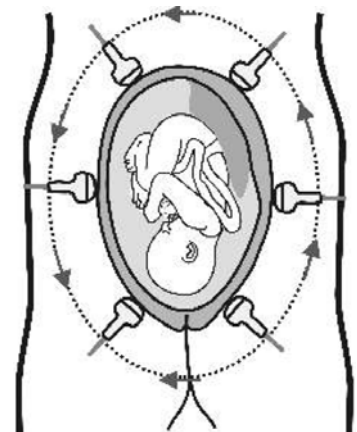
### Systematic Examination:

#### **Fetal Survey:**

The Survey scan is meant to have a global picture of the gravid uterus.

The information that can be gathered from the survey scan is:

- Number of fetuses and their viability
- Lie and position of the spine
- Placental location



- Available space around the baby – amniotic fluid

### **Fetal Biometry**

Fetal Biometry was done to assess the “fetal age” and “size of the fetus for the age”. Among large number of available biometric parameters, BPD, HC, AC and FL were measured. Transcerebellar diameter and other long bone measurements were added to the biometric arsenal when considered appropriate.

### **Targeted Imaging for Fetal Anomalies (TIFFA)**

.The three goals of this most crucial step in the systematic examination are:

1. To predict with confidence, structural normalcy of the fetus with reasonable limits of expectation
2. To identify severe and lethal abnormalities
3. To raise the suspicion of an abnormality, which would warrant further tests/serial scans

### **Fetal Activity**

Fetal Activity was assessed simultaneously during the course of TIFFA. The fetus was observed for flexion, extension movements of the trunk and limbs. Opening and closing of fingers were also observed. An actively moving fetus was considered to be a reassuring factor for normalcy.

### **Fetal Environment**



Placenta – Location of the placenta with particular attention to the relation of its lower edge with internal os and assessment of placental substance and retroplacental clear space.

Amniotic Fluid – Liquor volume was assessed by Amniotic Fluid Index

Umbilical Cord – Number of vessels and the Cord insertion site were assessed.

**After the Ultrasound Examination:**

\*The nature of anomalies was explained to the parents and the various therapeutic options were discussed with them.

\*Further, they were counseled by the Neonatologist and the Genetic Clinic about the outcome. Pedigree Analysis and Karyotyping for parents when necessary were done in the genetic clinic. They were counseled about the nature of the anomaly and risk of recurrence.

\*After risk assessment, a decision whether to continue with pregnancy or to terminate was taken by the patient and based on that appropriate obstetric management was initiated.

\*The abortus/baby was examined clinically and by appropriate imaging studies and the findings were recorded and correlated with the Antenatal Ultrasound findings.

\*Dead fetuses (with informed consent from parents) were subjected to autopsy when possible.

\*Live anomalous babies were registered in Newborn Clinic and they were referred to specialty centers like pediatric surgery when necessary and utmost newborn care was provided to them.

-----

**RESULTS**

**AND**

**OBSERVATION**

## RESULTS AND OBSERVATION

The present study was carried out in the Department of Obstetrics and Gynaecology, Govt RSRM Lying in Hospital, Chennai, during the period of January 2010 to September 2011. A total of 2960 Antenatal mothers underwent ultrasound examination. 60 Antenatal mothers with anomalous babies were detected and studied during the period.

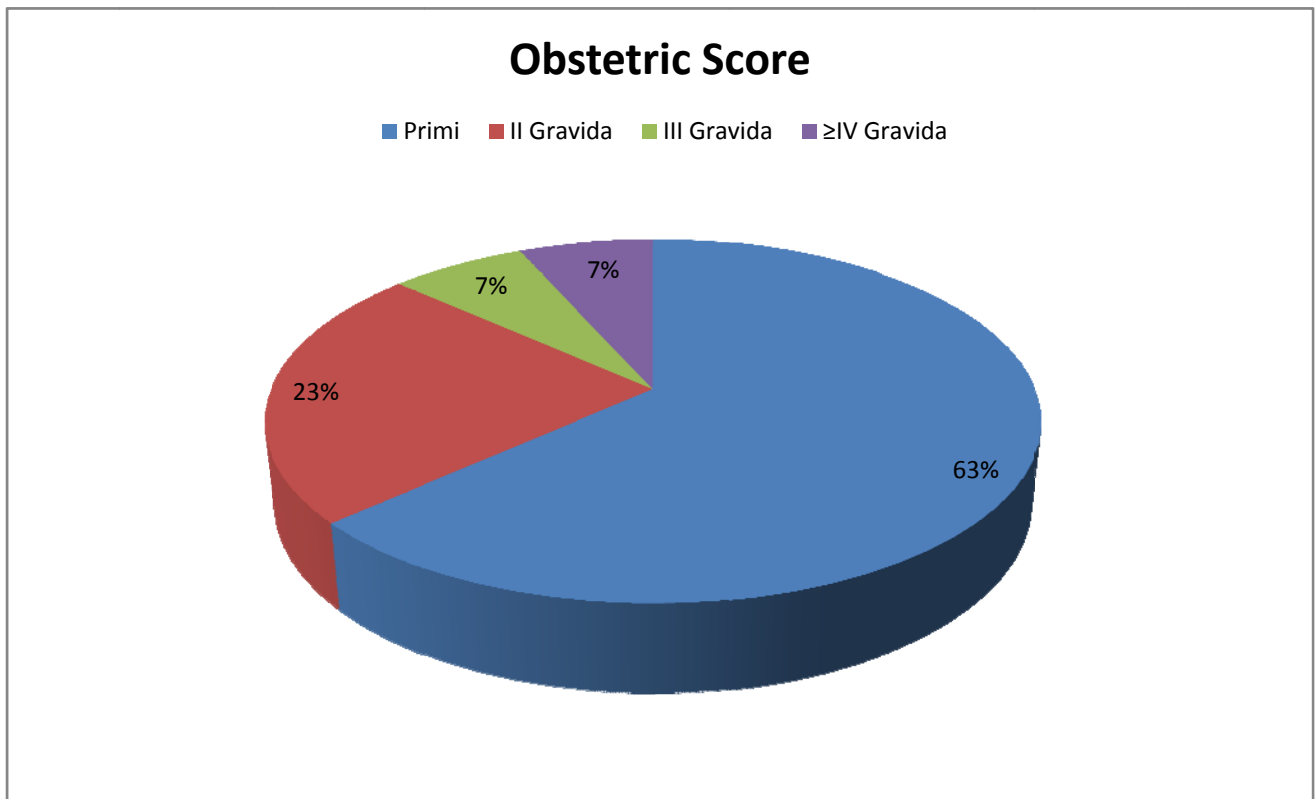
**Table 1: Age-wise distribution of Antenatal Mothers:**

SR. NO.	AGE GROUPS	NO. OF CASES	PERCENTAGE
1	≤ 20 yrs	10	17%
2	21-25 yrs	33	55%
3	26-30 yrs	12	20%
4	31-35 yrs	4	6%
5	> 35 yrs	1	2%

Majority of the Antenatal Mothers in the study belong to age group between 21–25 years. They constituted 55% of the study population. Around 17% of the study population was very young (≤20 years). And 2% of the total study population had advanced maternal age (>35 years).

**Table 2: Analysis of the Obstetric Score of the Antenatal Mothers:**

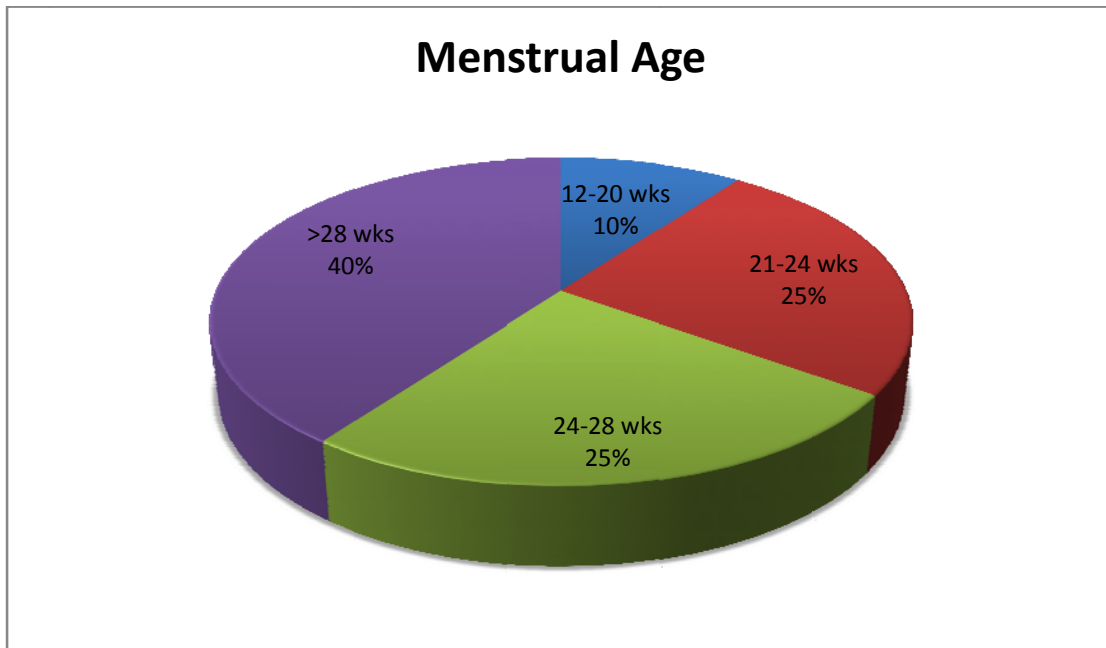
S. No.	Obstetric Status	No. of Cases	Percentage of Cases
1	Primi	38	63%
2	2 <sup>nd</sup> Gravida	14	23%
3	3 <sup>rd</sup> Gravida	4	7%
4	≥4 <sup>th</sup> Gravida	4	7%



Most of the Antenatal Mothers in the study population were primi (63%). Around 23% of the study population was 2nd Gravida. Only 7% of the population was Grand Multi-gravida.

**Table 3: Analysis of Menstrual Age during which the Anomaly was first detected**

S. No.	Menstrual Age	No. of Cases	Percentage of Cases
1	12-20 wks	6	10%
2	21-24 wks	15	25%
3	24-28 wks	15	25%
4.	>28 wks	24	40%



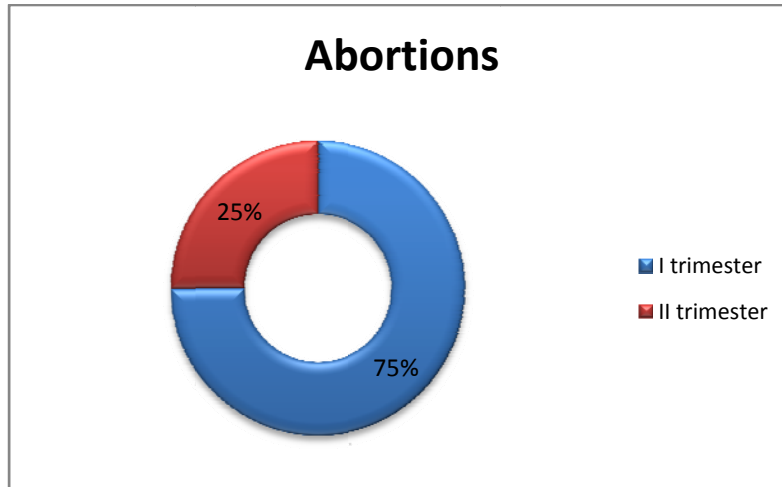
Majority of the Anomalies were first detected between 21-28 weeks. As much as 50% of the study population belonged to this group. Only 10% of the antenatal mothers were detected to have anomalies before 20 weeks.

**Analysis of previous Obstetric history of the Multi-Gravida:**

A) Pregnant women with previous history of Abortions: n = 8

I Trimester – 6

II Trimester – 2

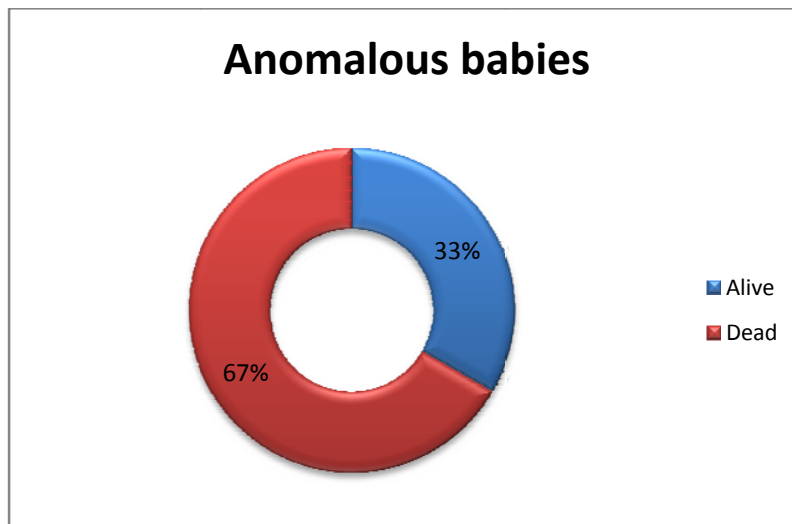


Among the study population, 13% of the pregnant women had history of abortion(s). More abortions have taken place during the I trimester (75%) than during II trimester (25%).

B) Congenital Anomalies: n = 6

Alive – 2

Dead – 4



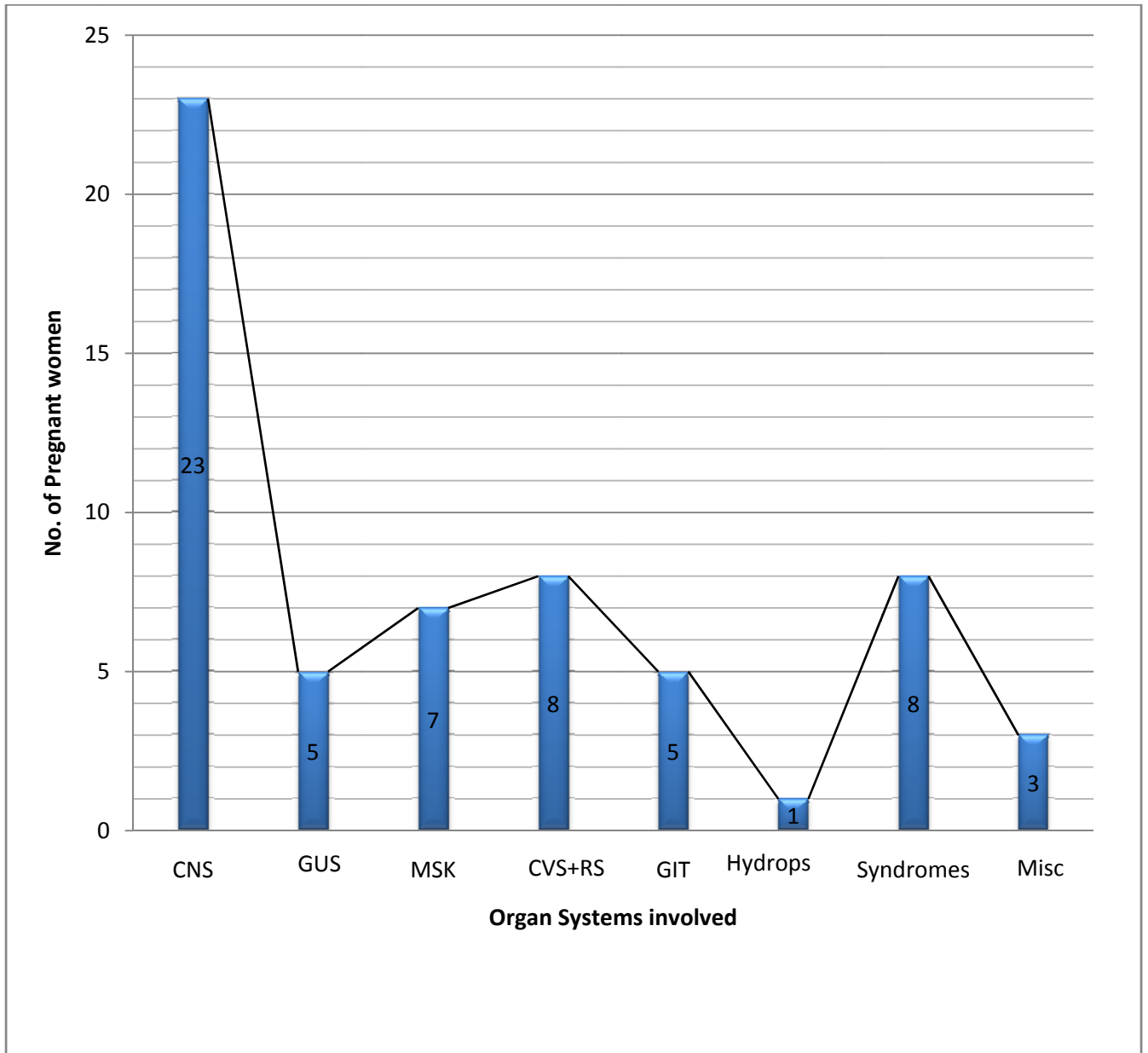
Majority of the congenital anomalous babies (67%) have died spontaneously while few of them (33%) managed to survive.

**Table 4: Analysis of involvement of Organ Systems among anomalous fetuses**

S.No.	Organ System	No. of Fetuses
1	Central Nervous System	23
2	Genitourinary System	5
3	Musculoskeletal System	7
4	Cardiovascular System and Respiratory System	8
5	Gastrointestinal System	5
6	Hydrops fetalis	1
7	Syndromes	8
8	Miscellaneous	3

Majority of the anomalies detected by Ultrasound examination were involving Central Nervous System. In the study population, around 23 antenatal mothers had anomalous babies (38%) with CNS involvement. Next most commonly involved organ system is Cardio respiratory system (13%). Around 8% had genitourinary anomalies. Musculoskeletal anomalies were found in 12% of fetuses. Gastrointestinal System was involved only in 8% of the fetuses. 1 baby had Hydrops fetalis. Syndromes like Downs, Edwards, etc were found in 13% of babies.

## Pictorial Depiction of Organ System involvement





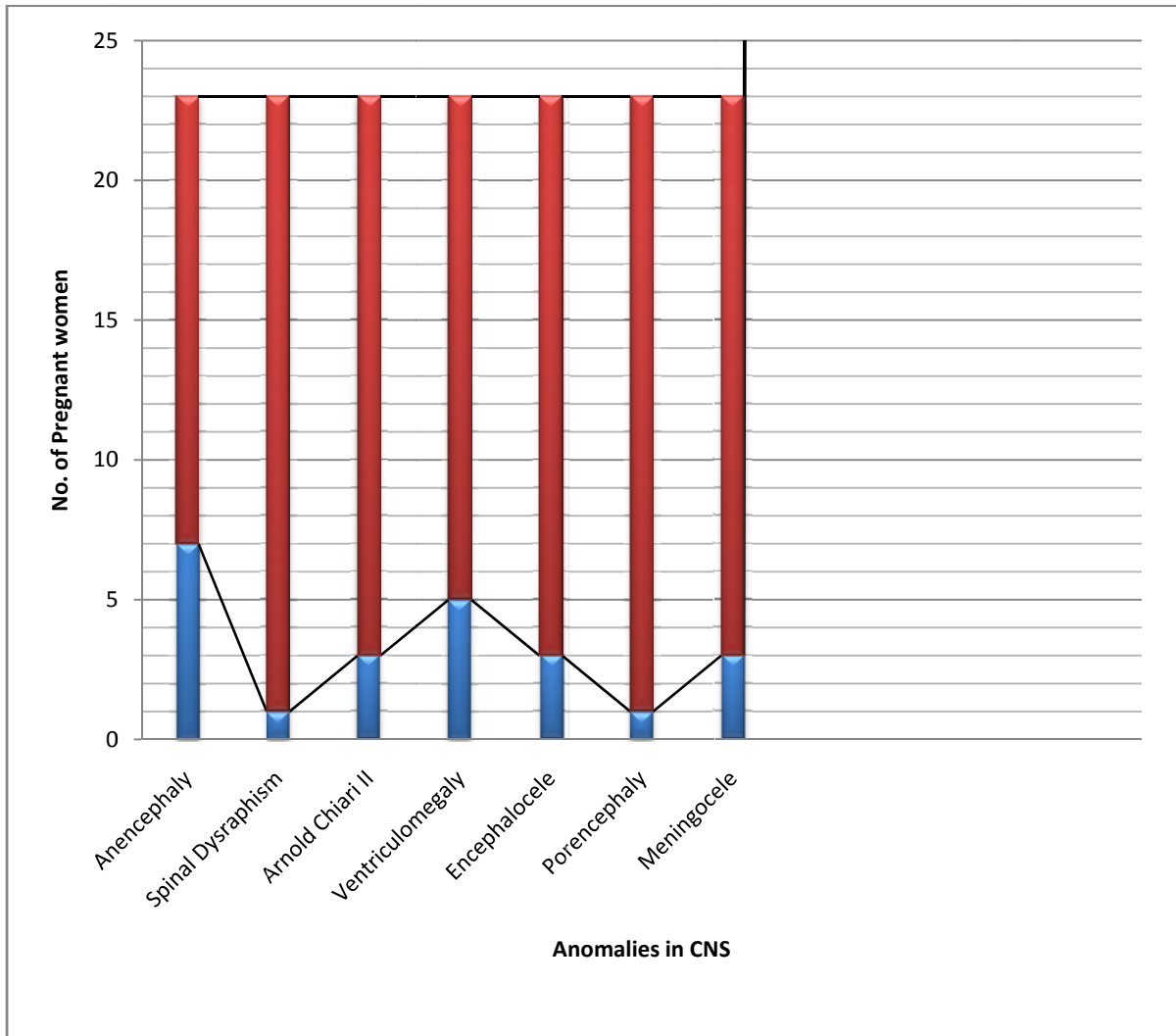
**Table 5: Analysis of Fetuses with CNS anomalies**

*n* = 23

<b>S. No.</b>	<b>Anomaly</b>	<b>No. of Cases</b>
1	Anencephaly	7
2	Spinal Dysraphism	1
3	Arnold Chiari Malformation II	3
4	Ventriculomegaly	5
5	Encephalocele	3
6	Porencephaly	1
7	Meningocele	3

Most Common CNS anomaly encountered was Anencephaly/Acrania complex (7). 3 fetuses with had Spinal dysraphism with ventriculomegaly (Arnold Chiari II malformation). Encephalocele is observed in 3 fetuses, all involving the occipital region. Porencephaly was diagnosed in 1 case. Meningocele was present in 5 cases. Of the 5, 2 had associated gastroschisis.

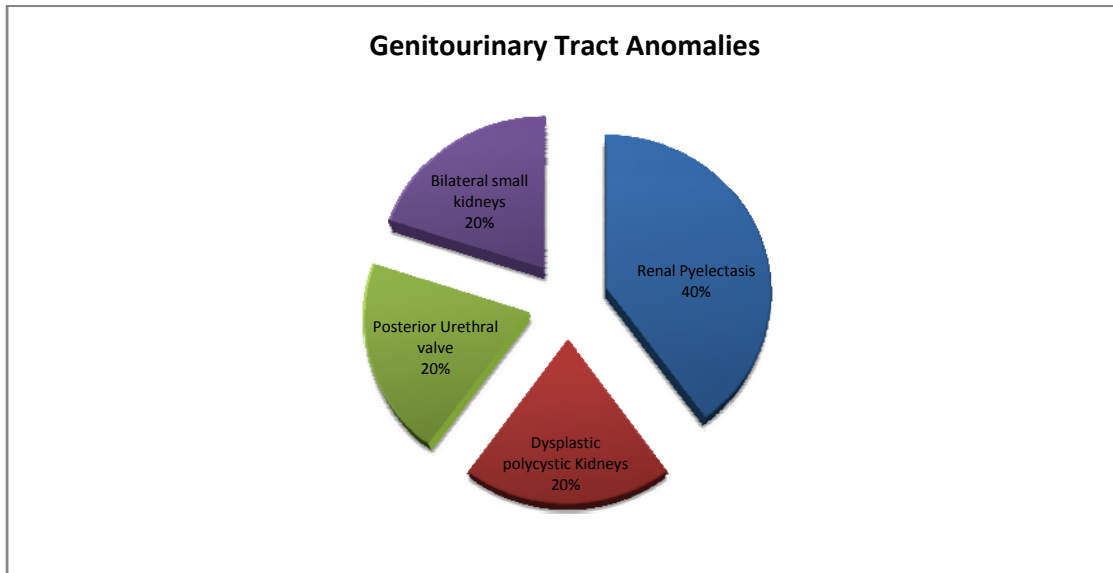
## Graphical Representation of incidence of various CNS anomalies



**Table 6: Analysis of Fetuses with Genitourinary Tract Anomalies:**

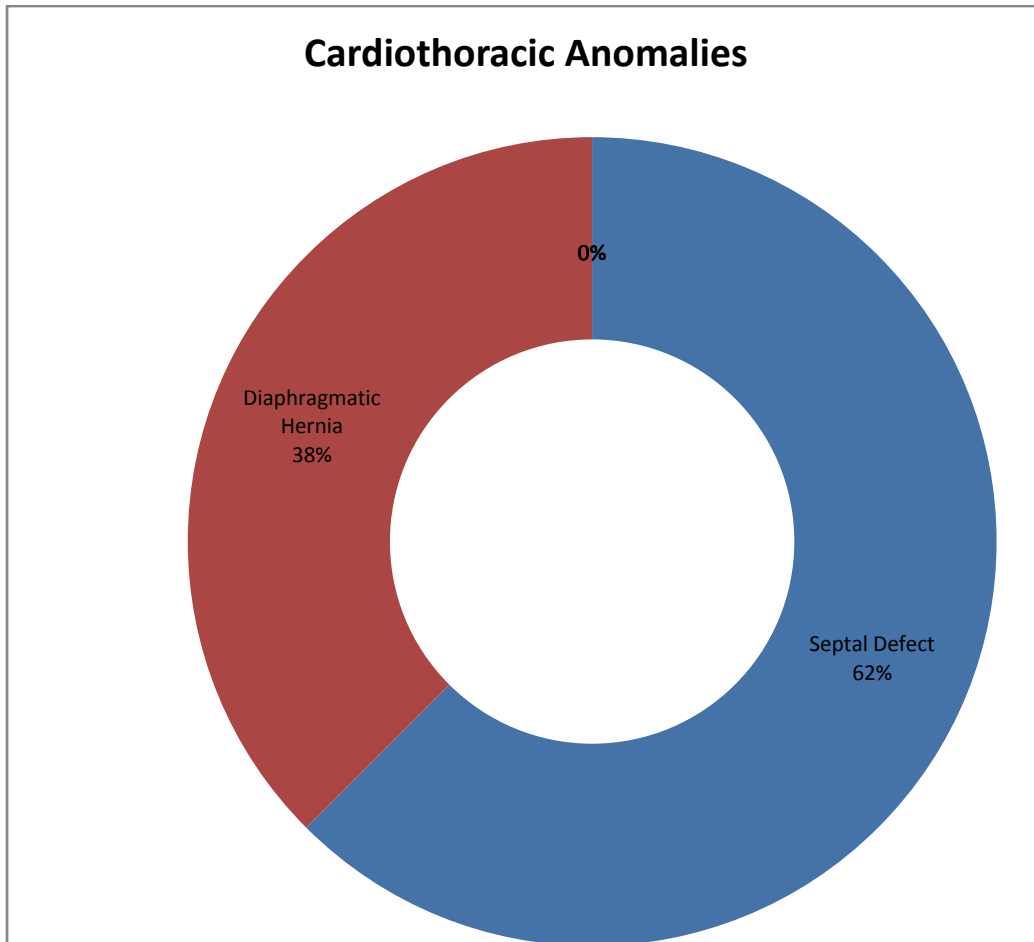
*n = 5*

Sl.No	Anomaly	No. of Cases
1	Bilateral Renal Pyelectasis	2
2	Posterior Urethral Valve with HUN	1
3	Polycystic Dysplastic Kidneys	1
4	Bilateral Small kidneys	1



Out of 5 fetuses with genitourinary anomalies, 2 had Renal pyelectasis. They were followed up to 6 months, which revealed non progressive renal pelvis dilatation. 1 baby had bilateral Hydroureteronephrosis due to Posterior Urethral Valve. 1 baby had bilateral Multicystic Dysplastic Kidney Disease.

## Pictorial Analysis of Cardiothoracic Anomalies



Ventricular Septal Defect is the most common cardiac defect. 1 baby with Diaphragmatic Hernia and VSD had Edwards Syndrome on karyotyping. 1 baby with absent radius was found to have Holt Oram syndrome whose grand mother and aunt had the same condition.

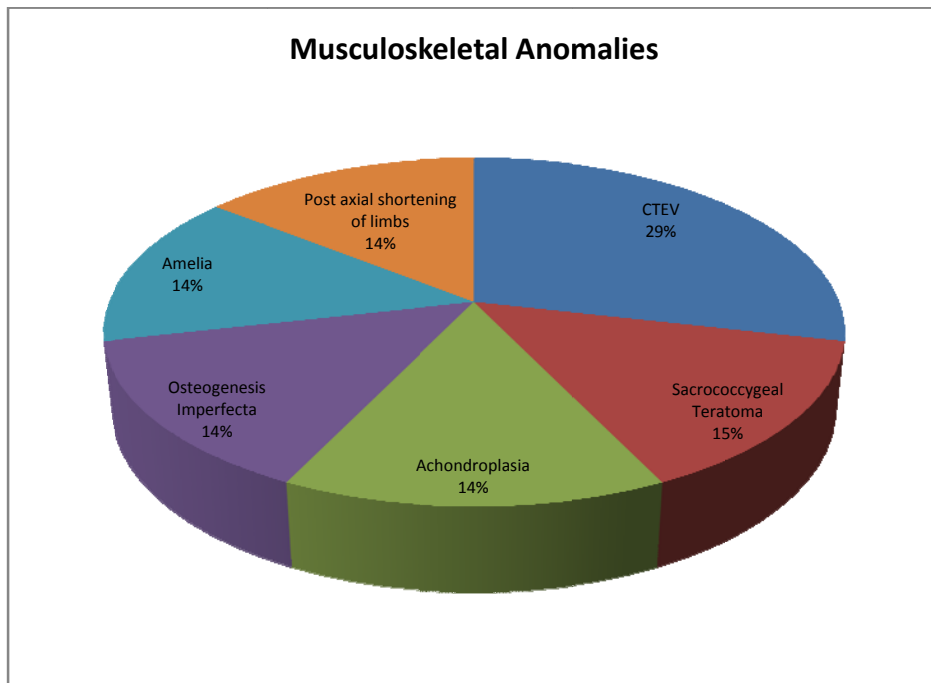
Diaphragmatic Hernia is the most common pulmonary anomaly.

**Table 7: Analysis of Musculoskeletal Anomalies**

*n* = 7

S.No.	Anomaly	No. of cases
1	Achondroplasia	1
2	Osteogenesis Imperfecta	1
3	Sacrococcygeal Teratoma	1
4	Congenital Talipes Equino Varus	2
5	Amelia	1
6	Post axial shortening of limbs	1

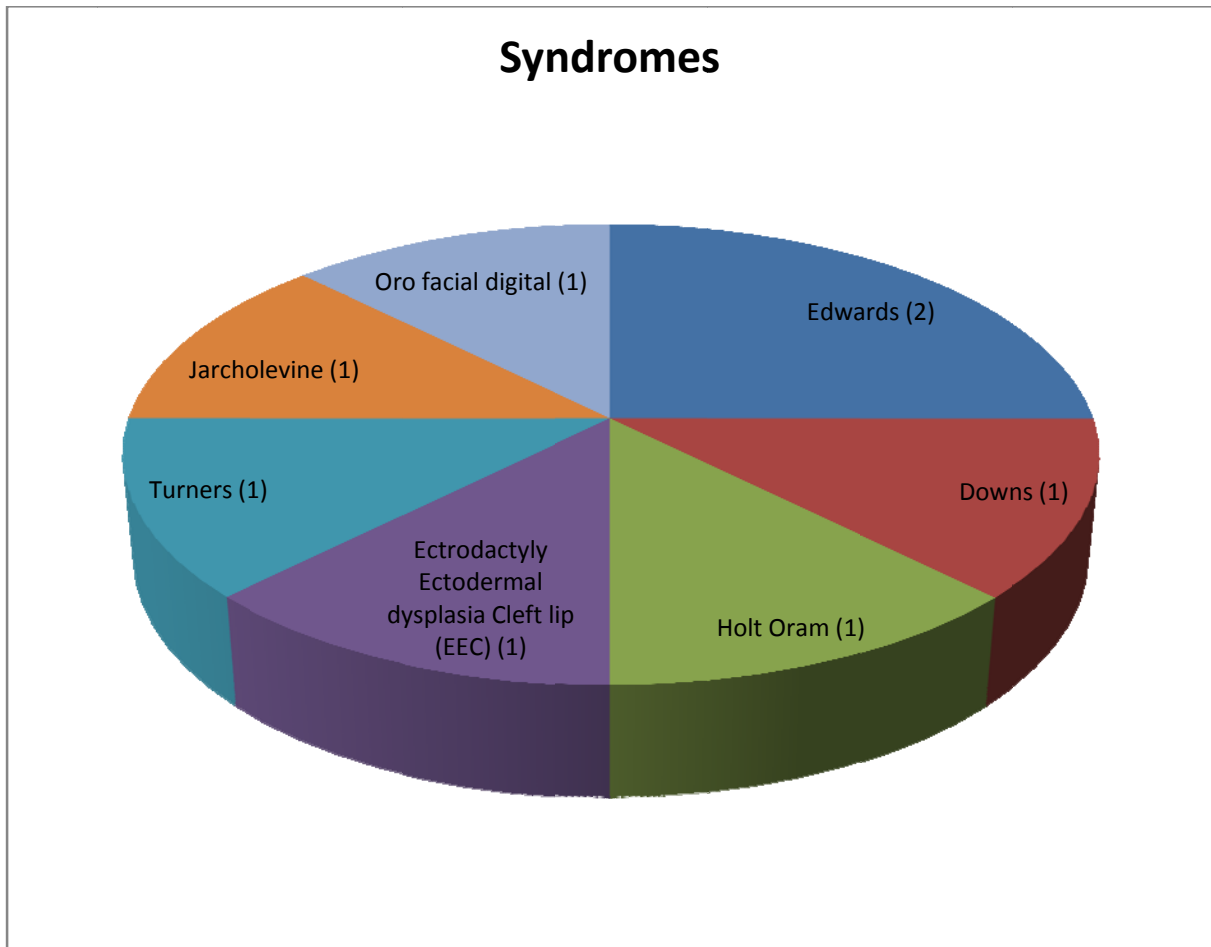
**Pictorial analysis of Musculoskeletal Anomalies**



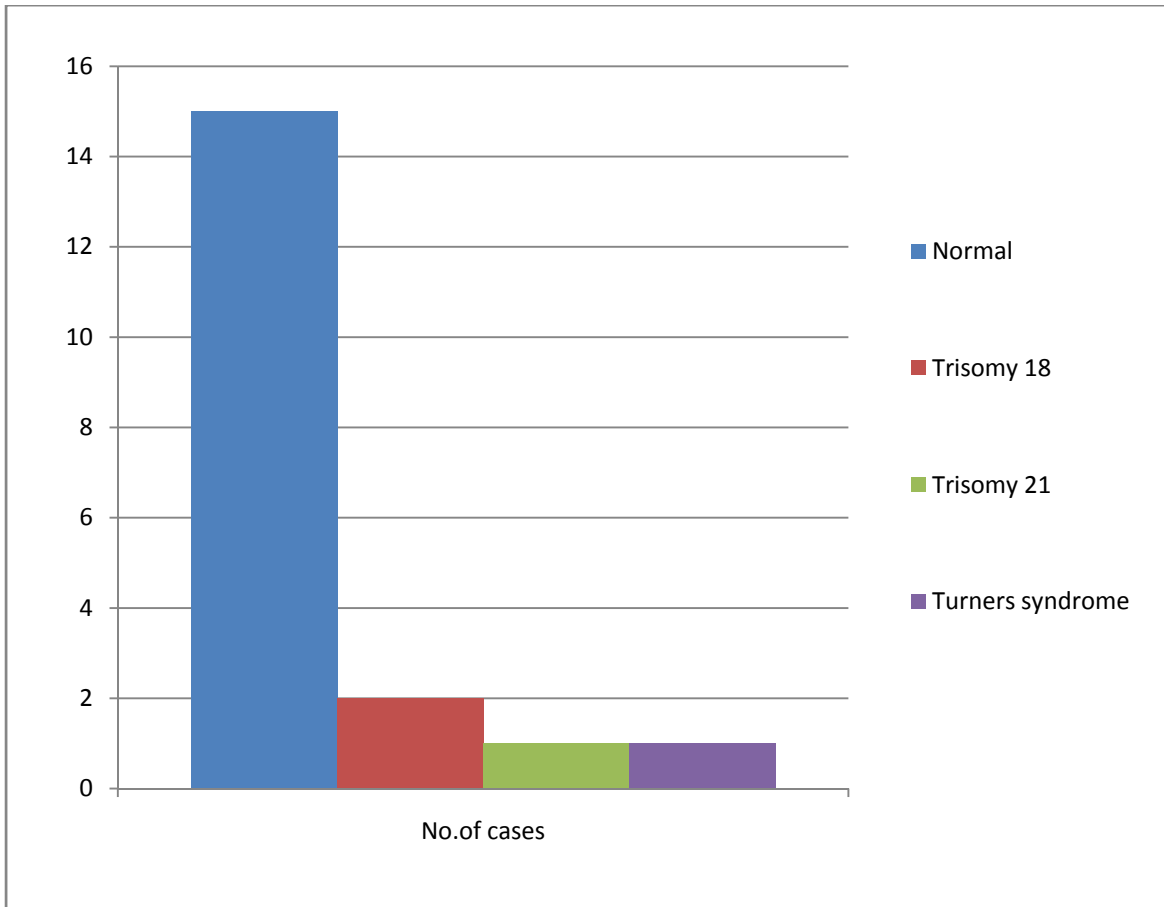
Congenital Talipes Equino Varus is the single most common musculoskeletal anomaly. One baby had spinal dysraphism associated with CTEV.

**Analysis of the Syndromes among Congenital Anomalies**

N=8



## **Analysis of Karyotyping among Anomalies**



Karyotyping was done for 15 babies from cord blood, 2 babies had pure trisomy, 1 baby had trisomy 21 and 1 baby with cystic hygroma had Turners Syndrome.

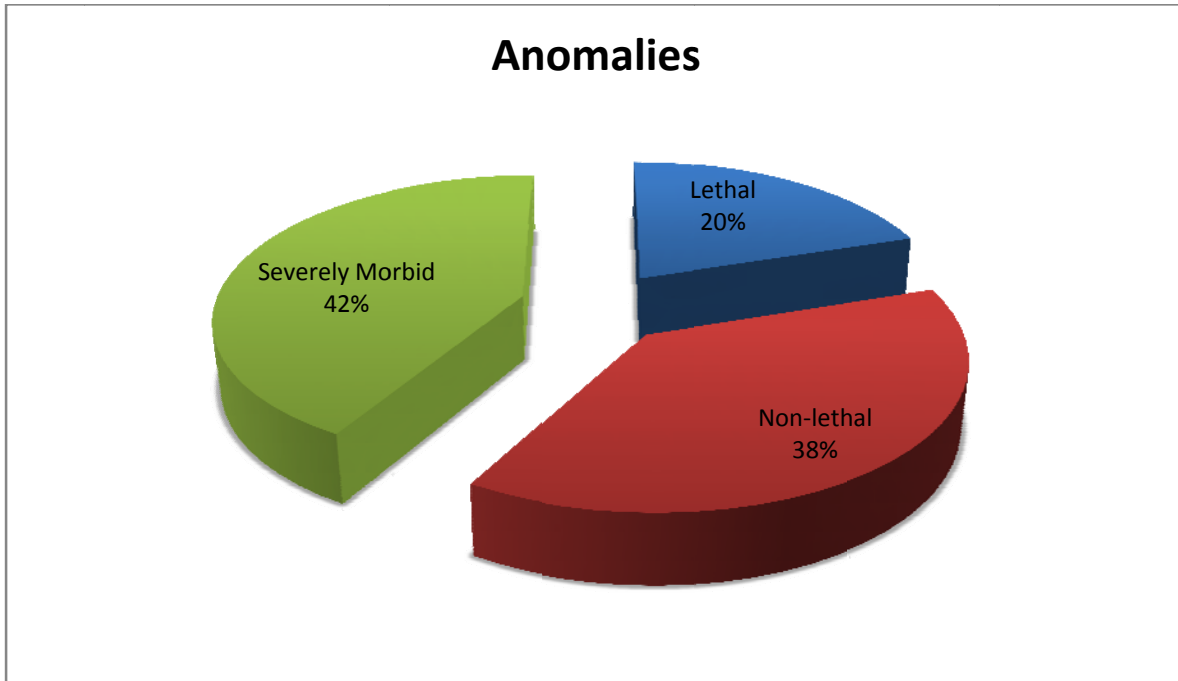
## **Analysis of autopsy among anomalies**

Autopsy was done for 15 cases, additional findings were present in 3 cases, 1 case of Edward syndrome had blind ending small bowel, 1 anencephaly had pulmonary hypoplasia, and 1 hydrocephalus baby had ectopia vesicae.

**Table 8: Analysis of Lethality of anomalous fetuses by Ultrasound**

*n = 60*

S.No.	Nature of the Anomaly	Number of Cases	Percentage
1	Lethal	12	20%
2	Severely Morbid	25	42%
3	Non-Lethal	23	38%



20% of the fetuses had lethal anomalies and were advised termination. Most of them had multiple anomalies. The single most lethal anomaly in our Study is Anencephaly (12%). The next most common Lethal anomaly is examphalos and gastroschisis (8%). 42% of the fetuses had anomalies which are severely morbid and the option of termination were left to the parents. 38% of the fetuses had Non-lethal anomalies and the parents were counseled about the outcome and the possible investigations to be done after birth.

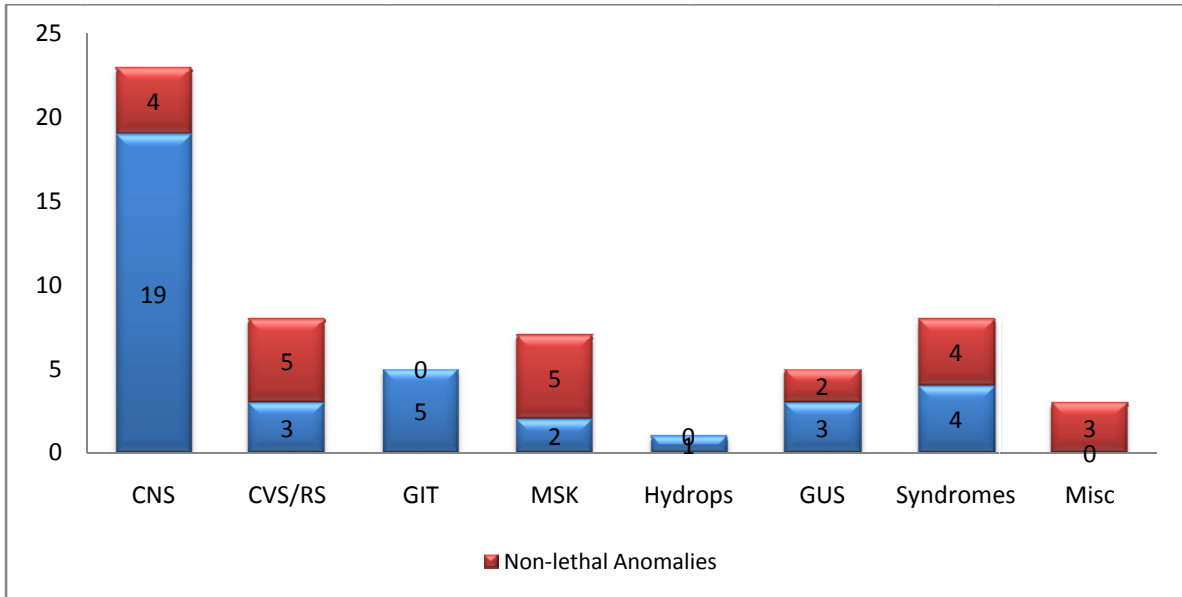


**Table 9: Analysis of organ system-wise distribution of Lethality of Anomalies**

<b>S.No.</b>	<b>Organ System</b>	<b>Total No. of Anomalies</b>	<b>No. of Lethal and Severely morbid anomalies</b>	<b>No. of Non-lethal anomalies</b>
1	CNS	23	19	4
2	CVS/RS	8	3	5
3	GIT	5	5	0
4	MSK	7	2	5
5	Hydrops	1	1	0
6	GUS	5	3	2
7	Syndromes	8	4	4
8	Miscellaneous	3	0	3

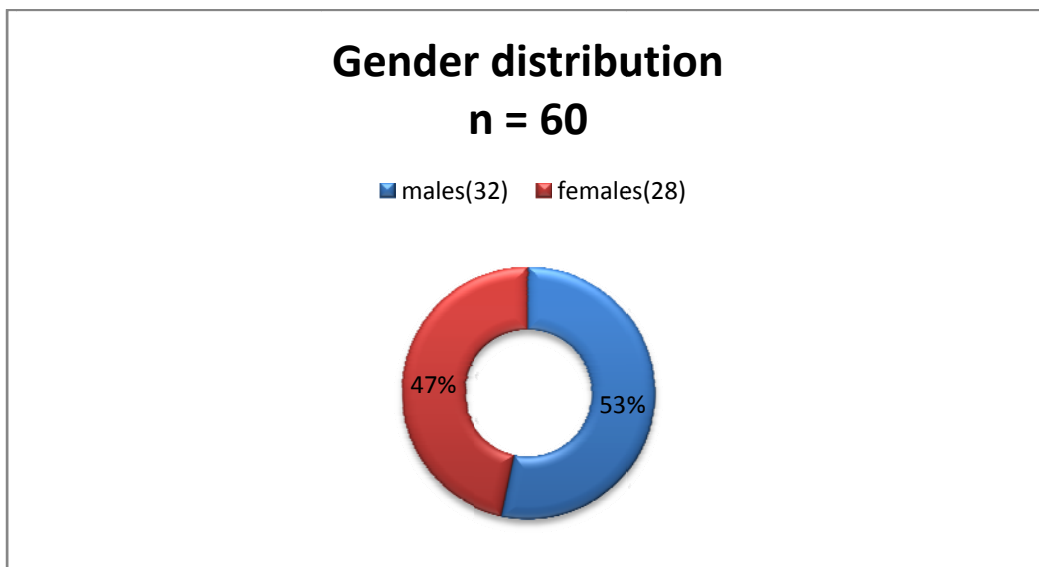
Out of 23 fetuses with CNS anomalies, Lethal outcome was predicted by Antenatal Ultrasound in 7 fetuses (31%). 38% of Cardiothoracic anomalies were lethal. 14% of the Musculoskeletal anomalies proved to be lethal. All the fetuses with genitourinary tract anomalies were non-lethal. All the fetuses with Hydrops fetalis were proved to be lethal.

### Graphical Representation of the organ system-wise distribution of Lethal Anomalies



### Gender distribution among the Anomalous babies

Anomalies are almost uniformly distributed among both the genders. While the incidence of male anomalous babies was 53%, it was 47% for their counterparts.

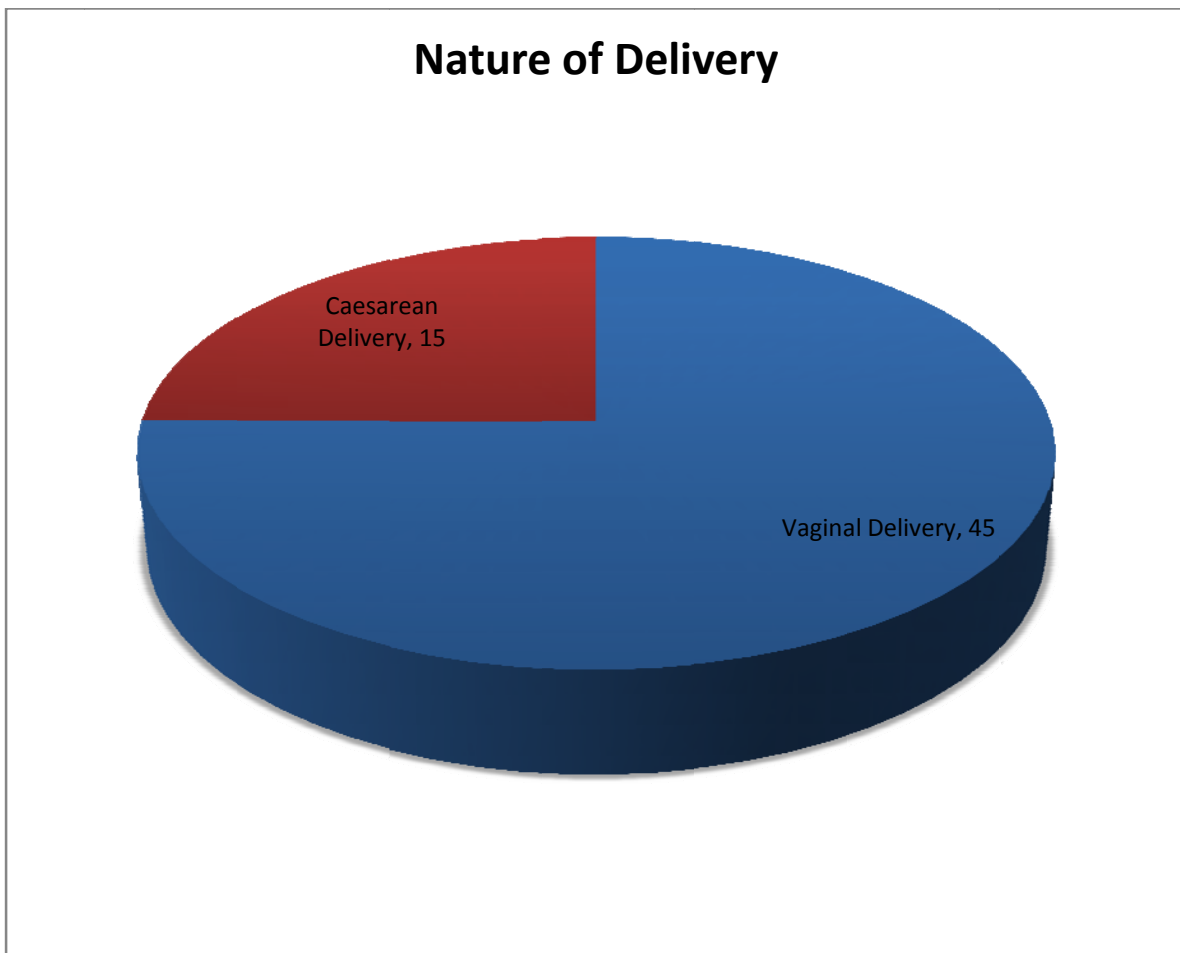


### **Analysis of Nature of Delivery**

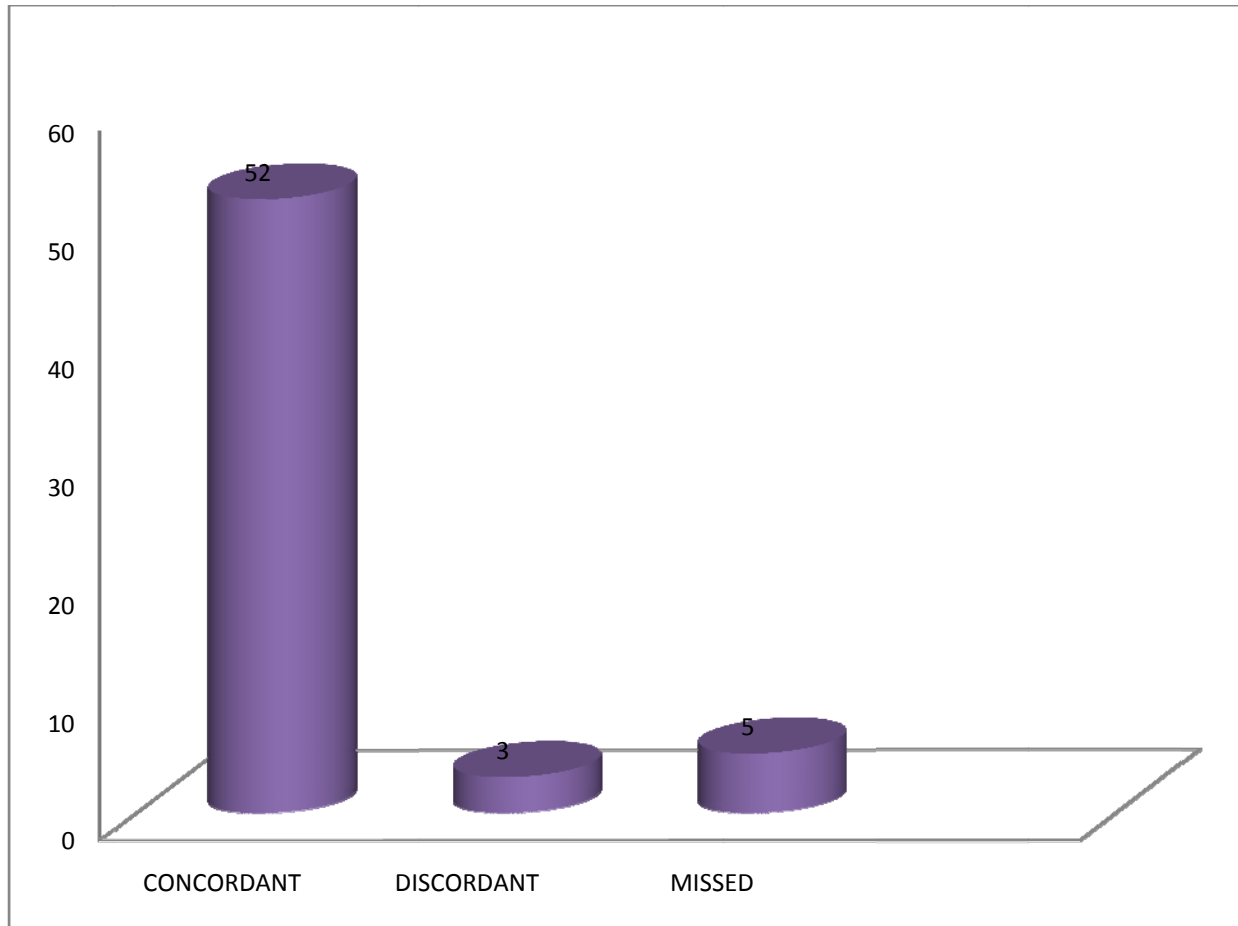
Vaginal Delivery – 45

Caesarean Delivery – 15

**Pie Diagram depicting Nature of Delivery in Pregnancies with Anomalous Fetuses**



## EFFECTIVENESS OF ULTRASOUND IN DETECTING ANOMALIES



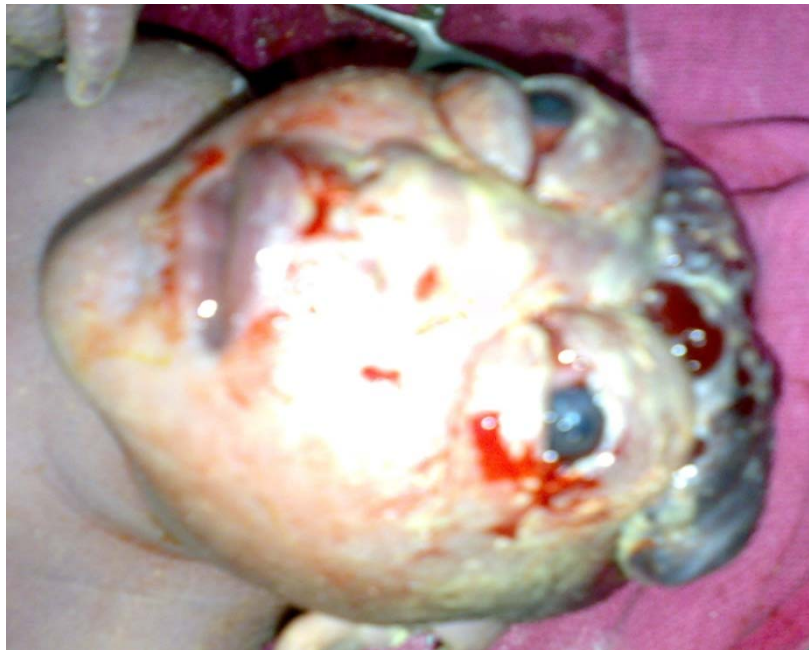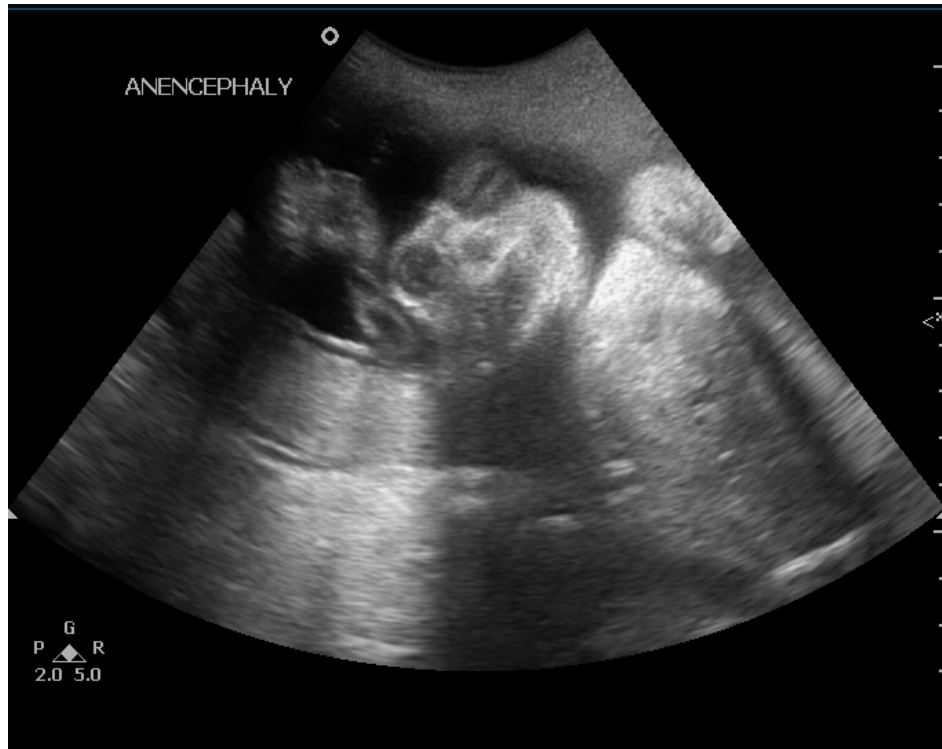- **Findings concordant with Antenatal ultrasound → 52**

- **Findings discordant with Antenatal ultrasound → 3**

*(Exomphalos – 1, Posterior Urethral Valve – 1, infratentorial arachnoid cyst- 1,)*

- **Findings missed in Antenatal ultrasound → 5**

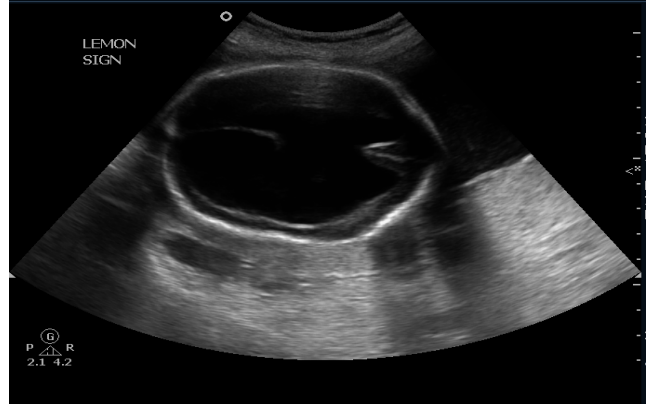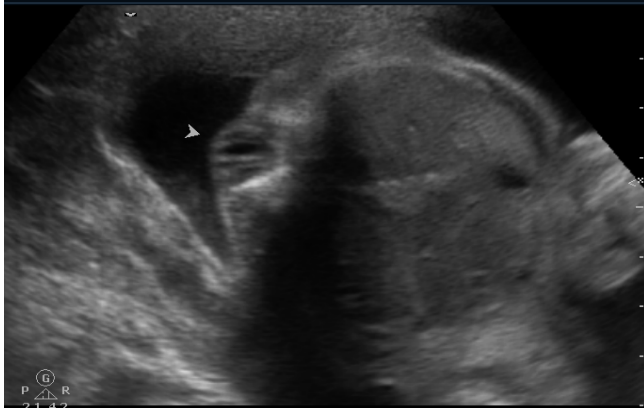
*(cleft palate ( with cleft lip) – 1, ASD (with increased NT) – 1, Lung sequestration (in a case of anencephaly) – 1, CTEV (in spinal dysraphism) – 1, Ectopia vesicae (with hydrocephalus) - 1)*



### **Anencephaly**

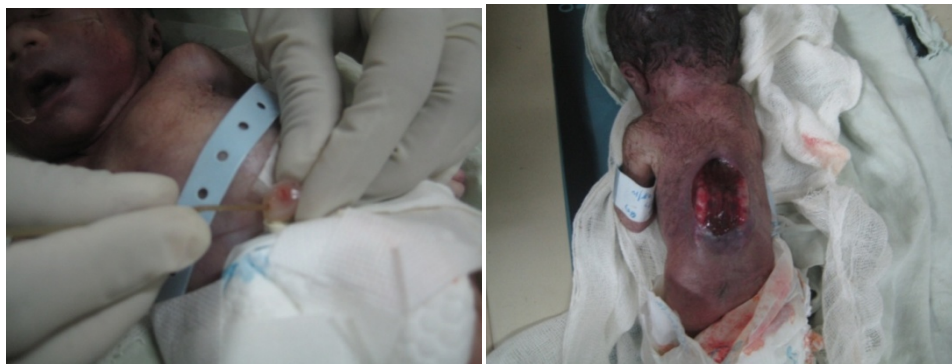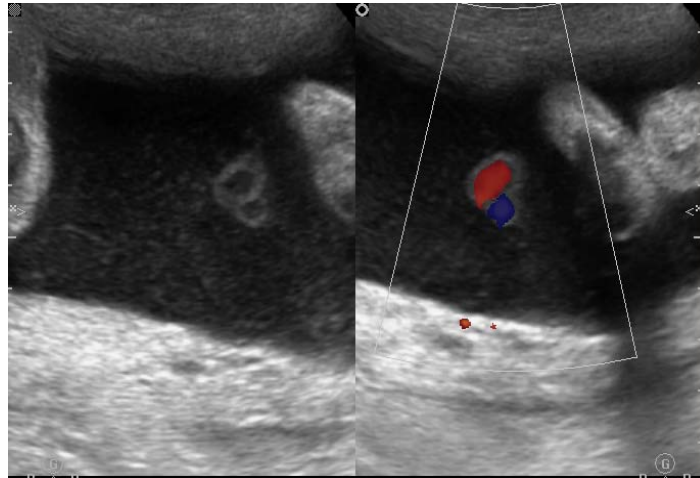
(Top) Coronal section of face showing anencephaly with frog eye appearance.

(Bottom) Fetus confirming ultrasound findings.



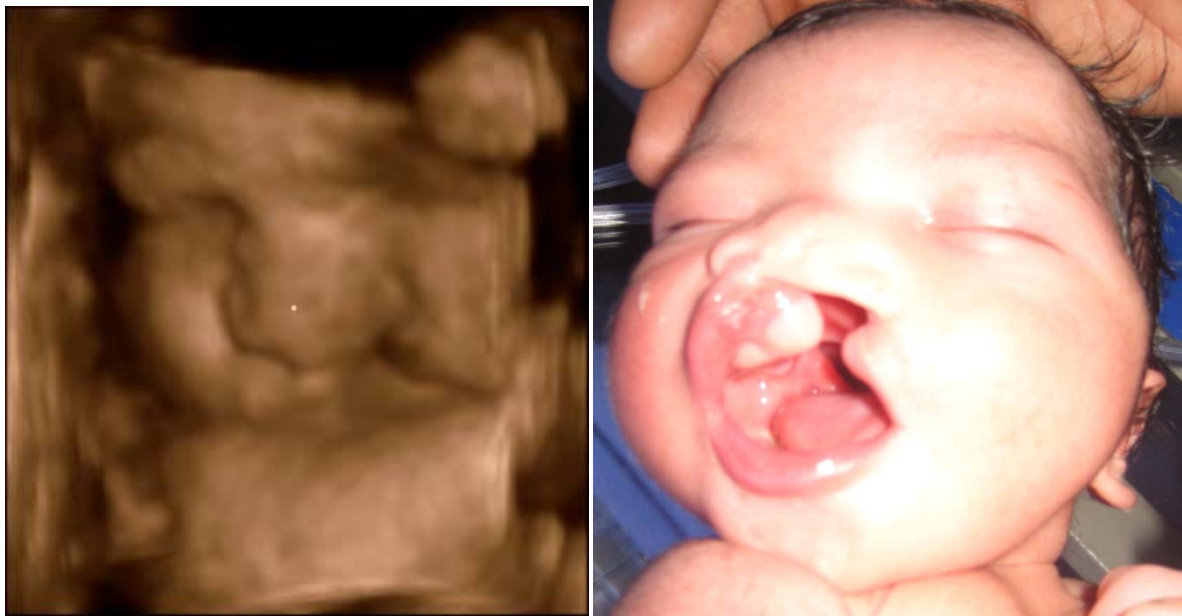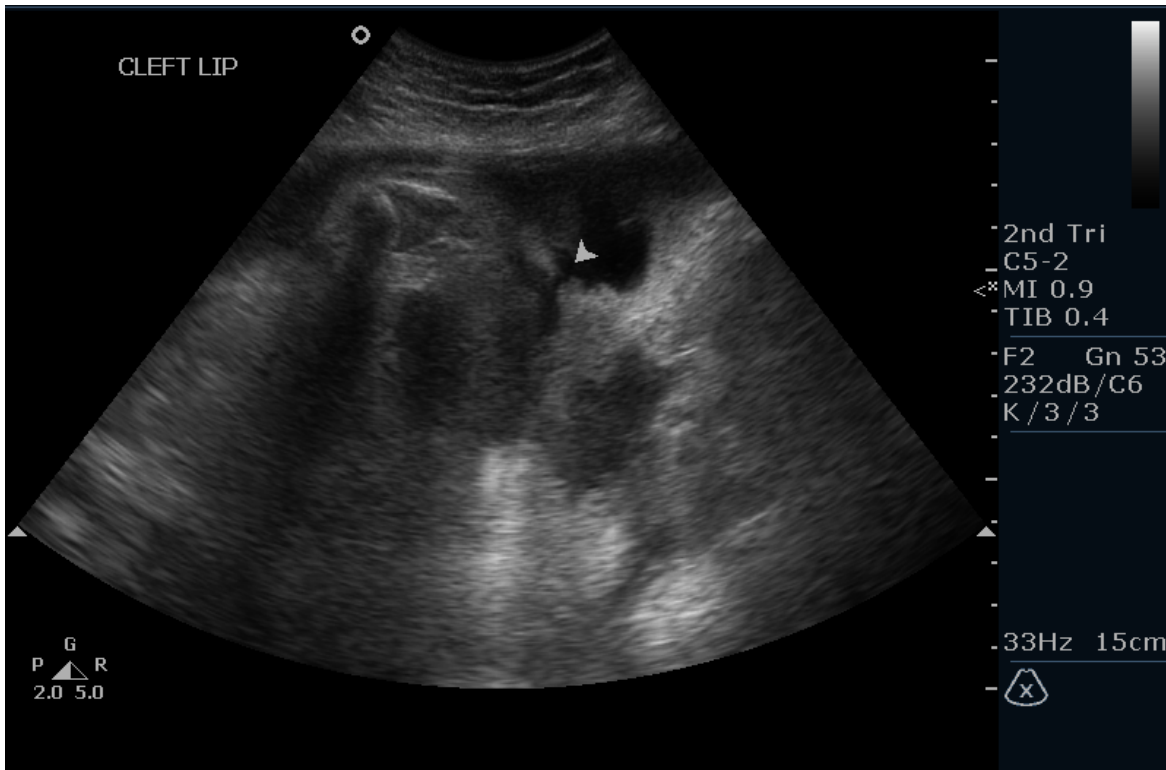**Arnold Chiari Malformation with Single Umbilical Artery**

(Left) Transverse section showing Lumbar Meningocele (Right) Lemon sign with gross ventriculomegaly



**Arnold Chiari Malformation with Single Umbilical Artery**

(Top) Gray scale and Doppler images of the umbilical cord reveals single umbilical artery.  
 Postnatal images of single umbilical artery (Bottom left) & Lumbar meningocele (Bottom right)

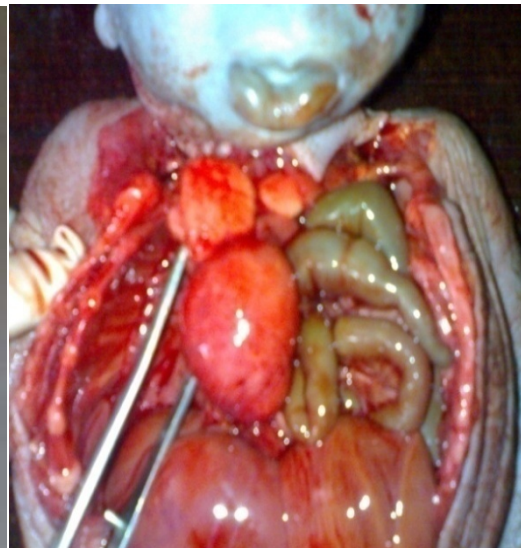
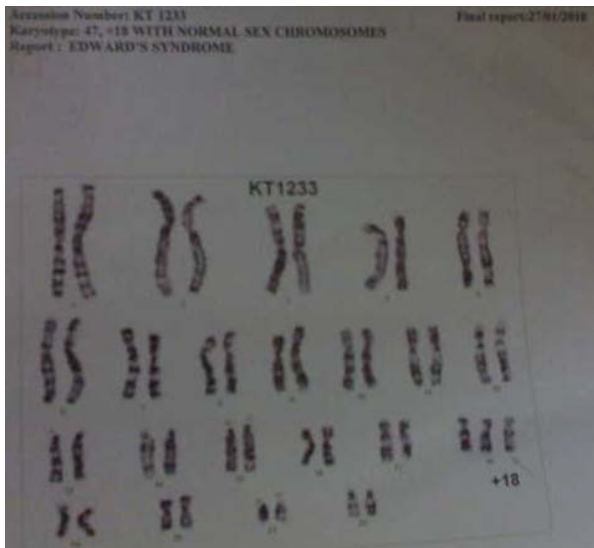
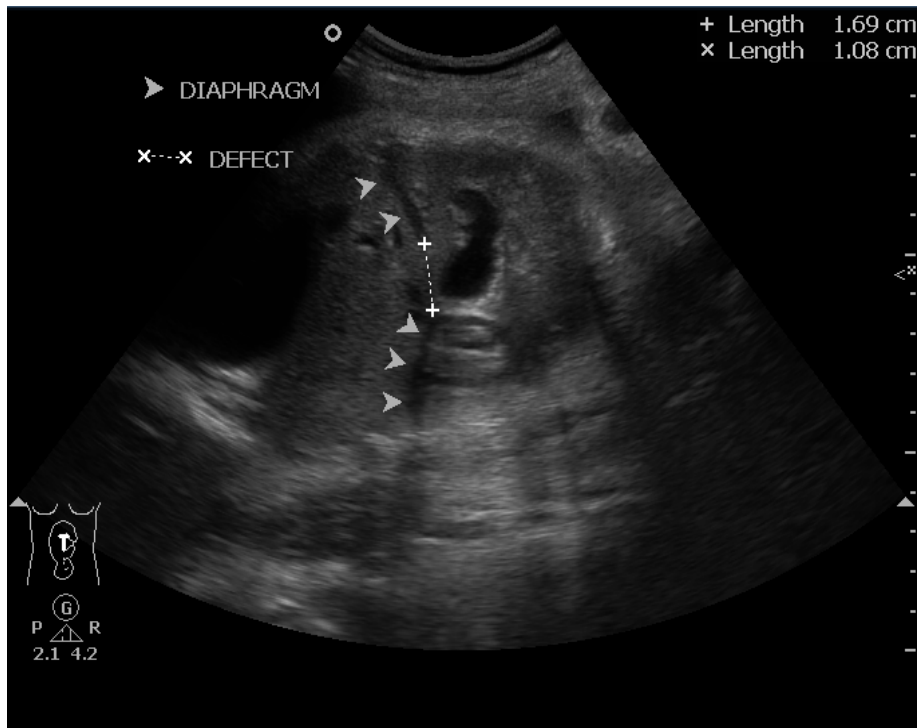


### Cleft Lip and Cleft Palate

(Top) Coronal section of the face showing cleft lip.

3D surface rendering (Bottom left) shows cleft lip and palate and its neonatal correlation.





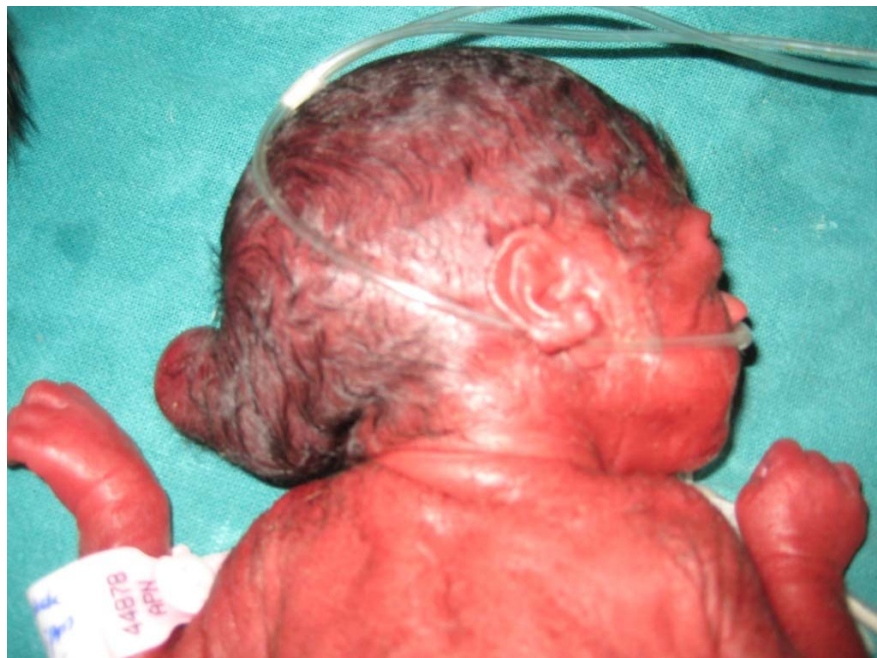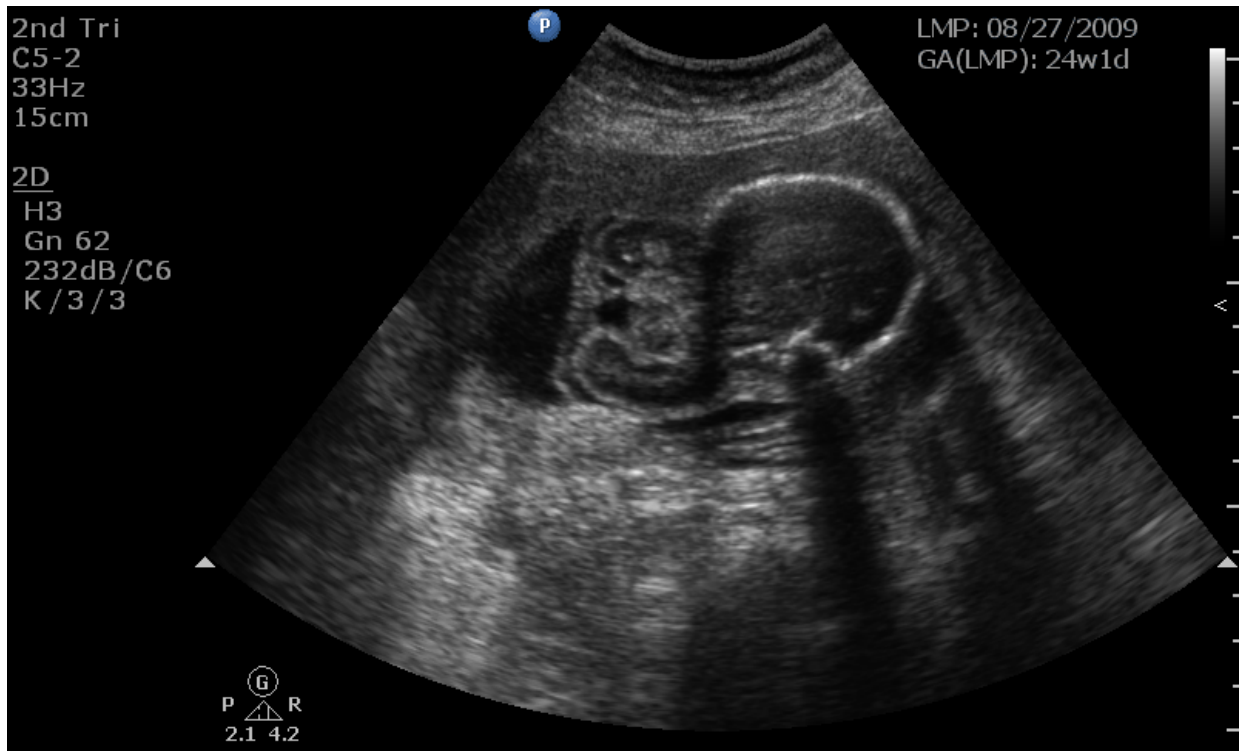### Diaphragmatic Hernia

(Top) Coronal section showing the defect (calipers) in the diaphragm (arrow heads) through which the stomach has herniated into the thorax and lying in the same plane as the heart

(Bottom left) Cord blood sent for Karyotyping confirmed Edward's syndrome.

(Bottom right) Fetal autopsy showing the herniation of bowel loops into the thorax.

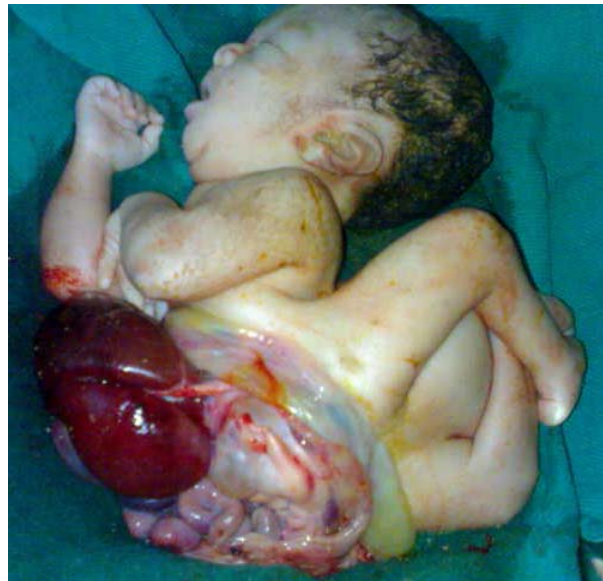
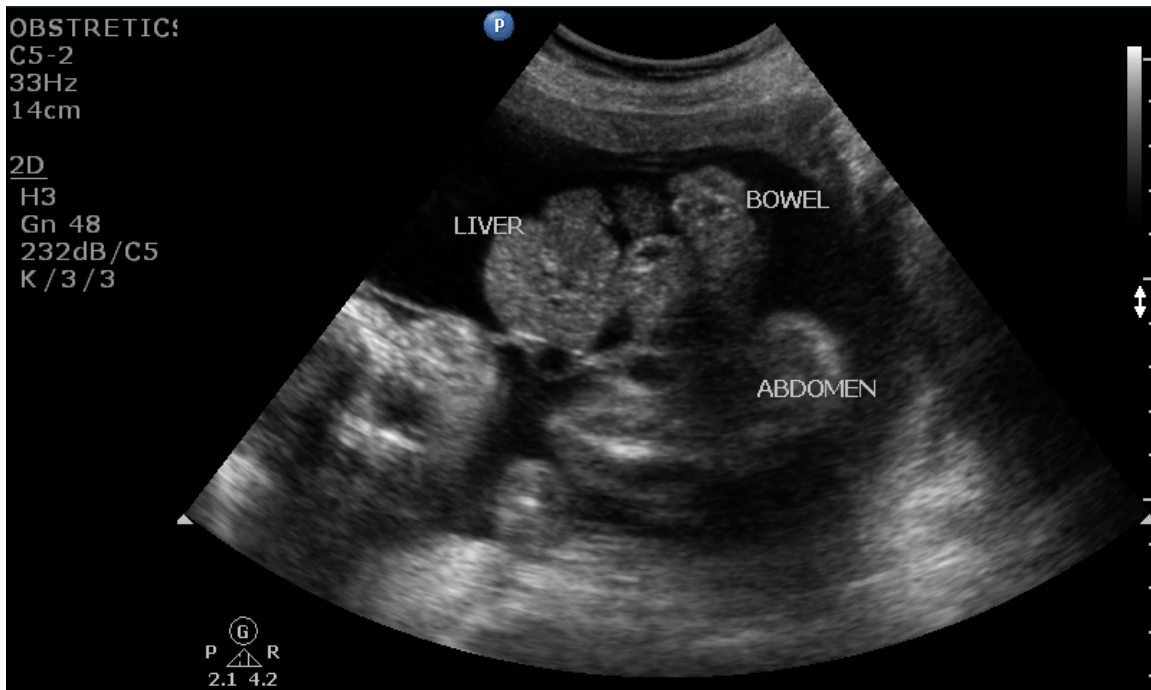


### **Encephalocele**

(Top) Ultrasound showing herniation of brain parenchyma through the occipital bone defect.

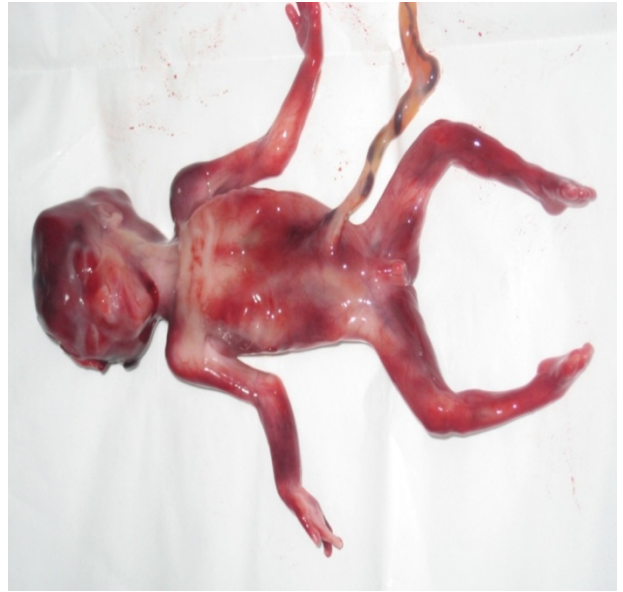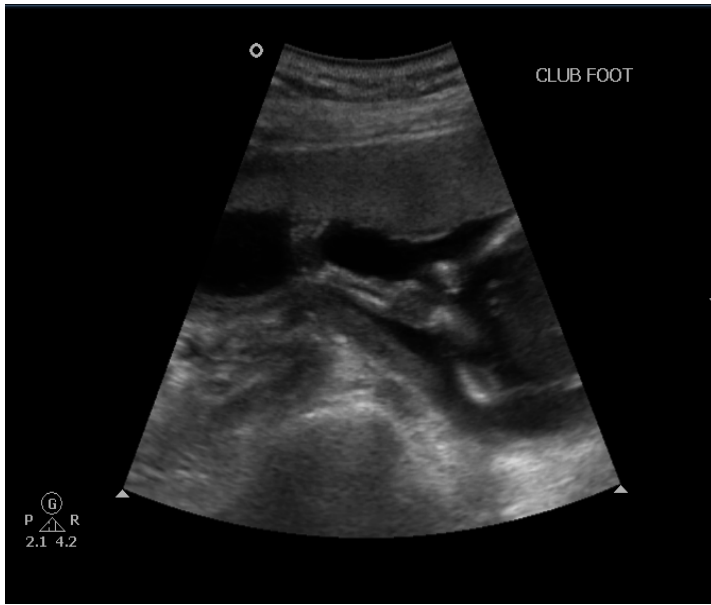
(Bottom) Occipital Encephalocele as seen after birth



### **Gastroschisis**

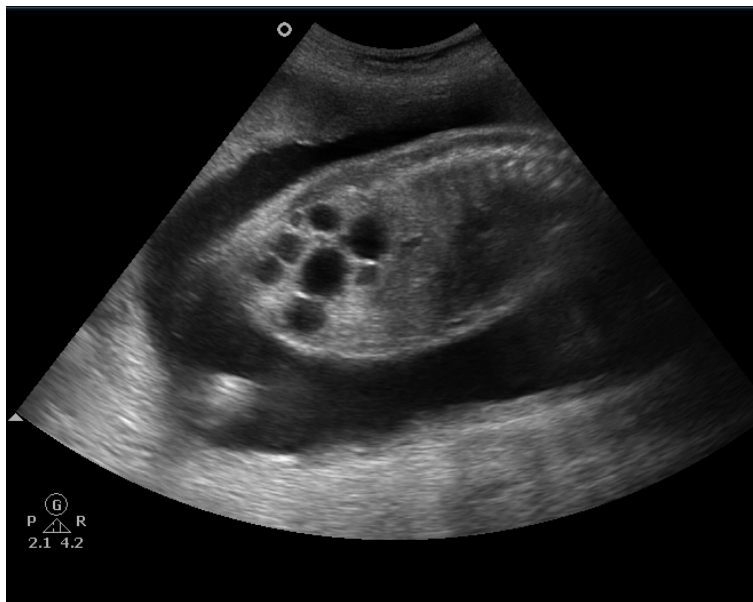(Top) Oblique axial section at the level of abdomen showing Liver and Bowel loops freely floating in the amniotic fluid.

(Bottom) Post natal examination confirming Gastroschisis.



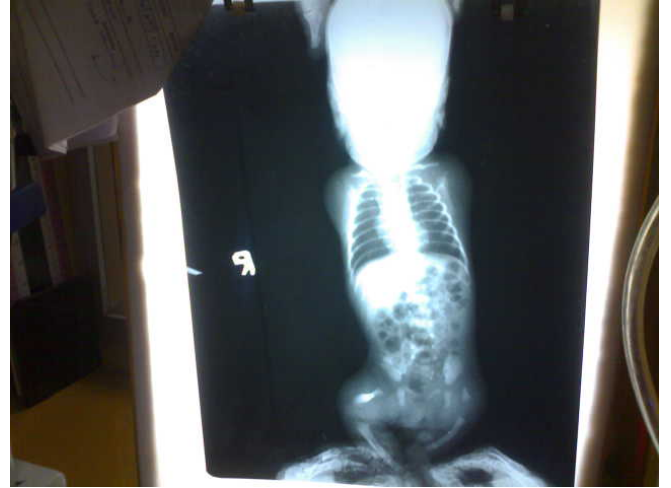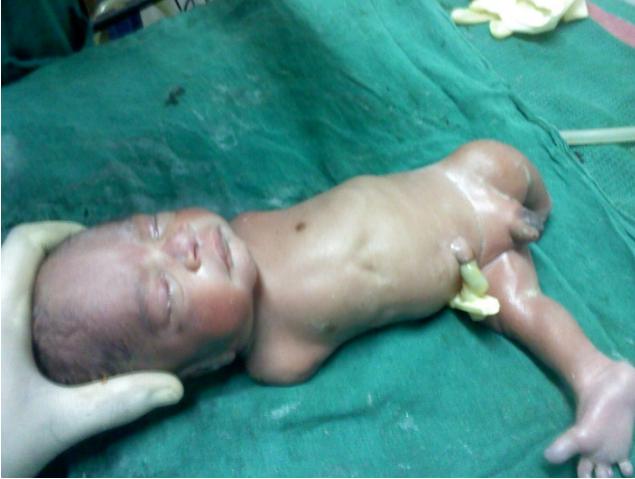### **Congenital Talipes Equino Varus**

Ultrasound appearance (top) of the club foot and its post-natal correlate (bottom)



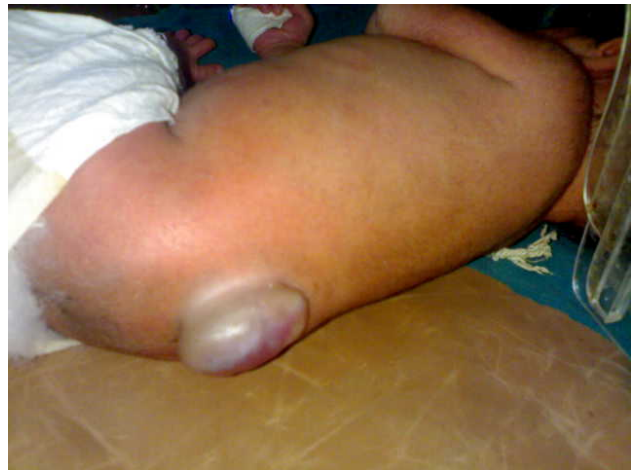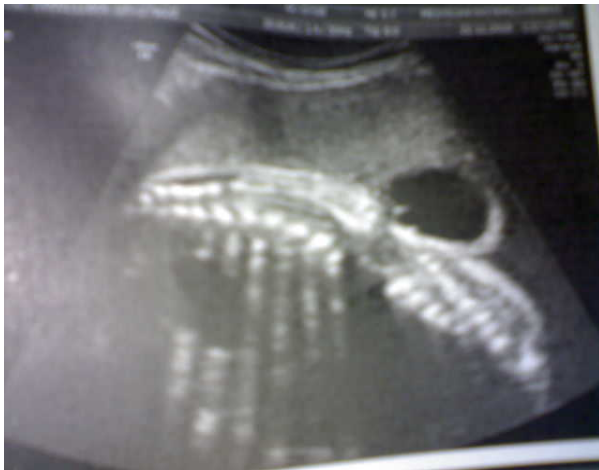### **Multicystic Dysplastic Kidney Disease**

Sagittal section of the left kidney shows multiple non-communicating cysts.



### Amelia

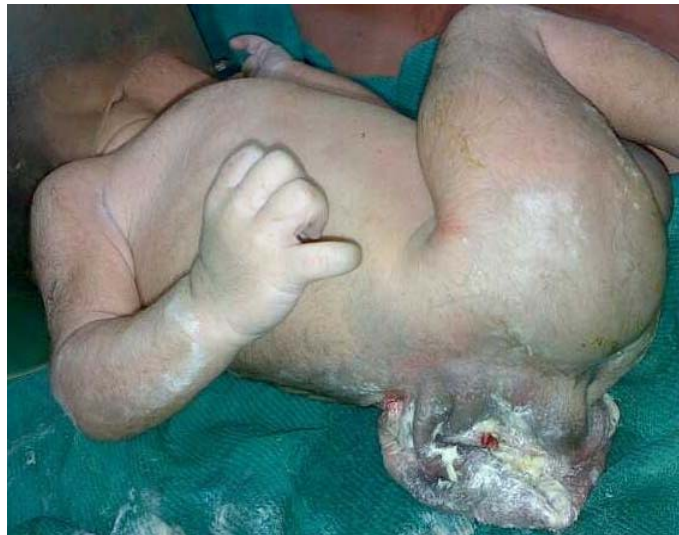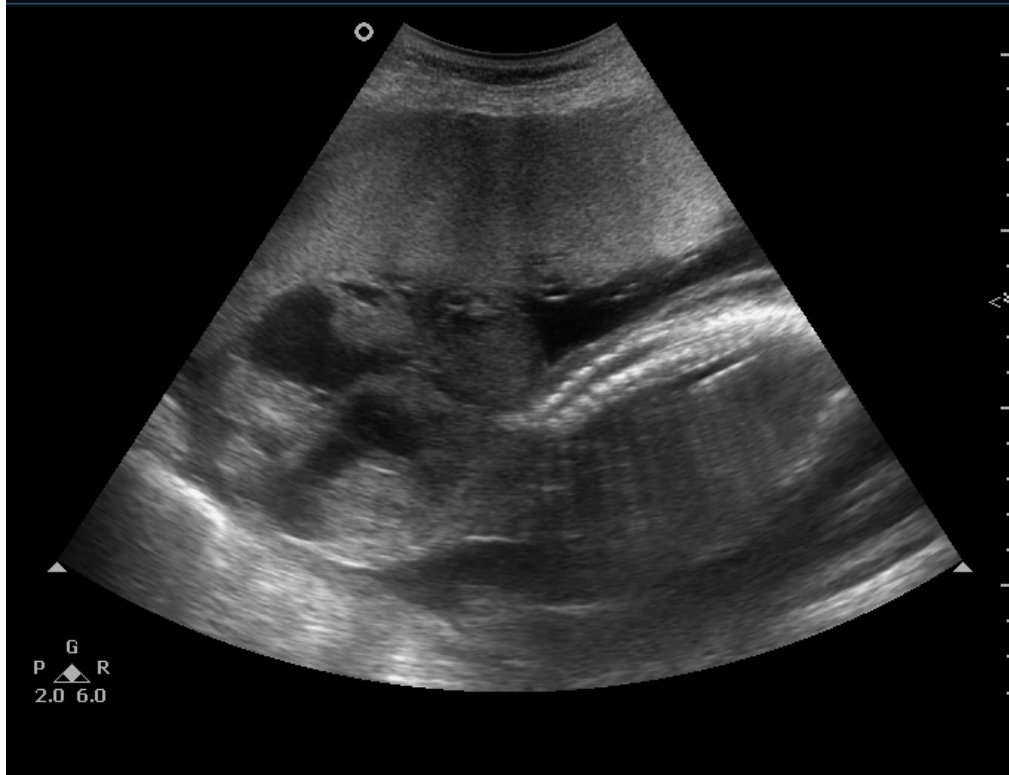**(Left) post natal image of absent upper limb (Right) X-Ray image of the baby**



### Meningocele

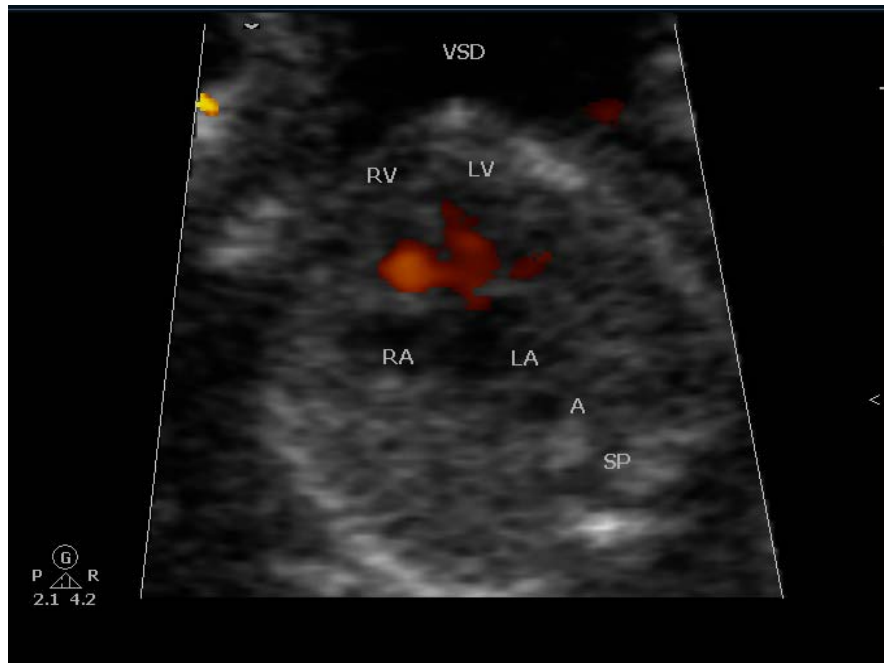
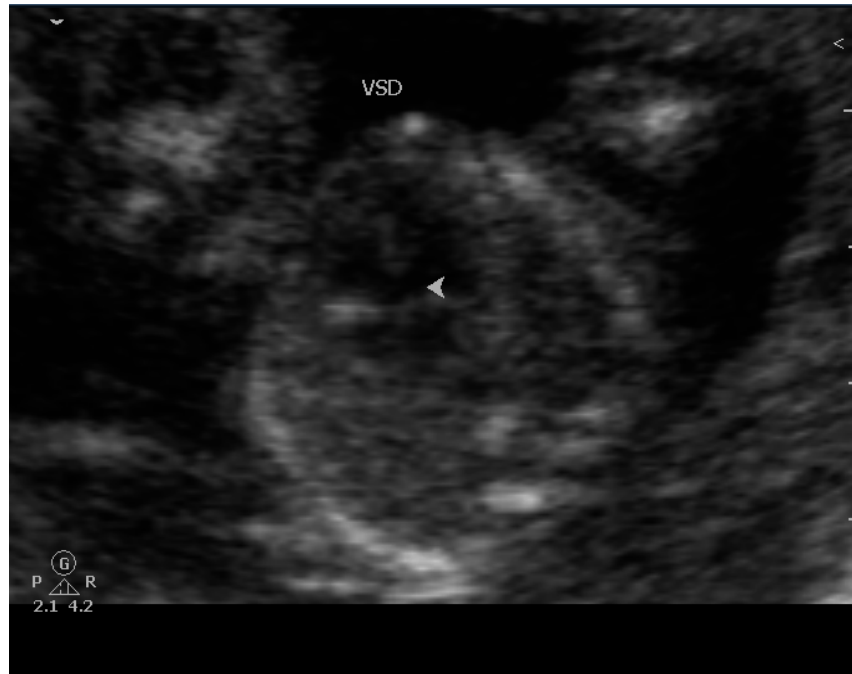
**(Left) Ultrasound showing herniation of meninges (Right) Meningocele as seen after birth**





### **Sacroccygeal Teratoma**

(Top)Sagittal section at the lumbosacral level shows a large well-defined solid-cystic lesion.  
(Bottom right) Postnatal Photograph of the baby



### Ventriculo Septal Defect

Gray-scale (top) and Doppler (bottom) images at the level of thorax showing VSD with colour flow across the Interventricular septum.

# DISCUSSION

## **DISCUSSION**

Ultrasonography is the primary modality and the real workhorse of obstetric imaging. Ultrasonography is a dynamic real time imaging technique without any hazards of ionization as with that of X-rays. It is cost effective investigation and doesn't consume much time.

The single most important scan during the pregnancy is the II trimester Targeted Anomaly Scan, which is done between 18 to 20 weeks. Since this scan is primarily meant for exclusion or diagnosis of anomalies, it is important that a thorough examination is done during this scan.

Ultrasound performance is based on technical and organizational variables including the number of exams performed, operator experience, organization, type of equipment used in the different centers, and health policy, but also on variables that are related to the structural abnormalities such as the gestational period in which the exam should be performed, severity of malformation, and type of malformation.

The present study comprises of 60 selected antenatal mothers out of the total 2960 patients who came for antenatal visit. The incidence of congenital anomalies is 2.02%. It is comparable to the Incidence percentage observed in other Standard National and International Studies. Different authors have reported an incidence ranging from 1.26 to 2.7% in larger series.



**Table 10: Comparison of Incidence of Fetal Malformations with other Studies**

Author/Year	Country	No. of Cases	Incidence
Levi S et al, 1991	Belgium	16,370	2.3%
Radius study, 1993	USA	7,812	2.4%
Reynier et al, 1994	France	1,64,509	1.26%
Euro fetus group, 1999	Europe	1,70,800	2.7%
S Singh et al, 2006	India	10,890	1.14%
Balakumar K, 2007	India	30,030	2.59%
<b>Present Study, 2011</b>	<b>India</b>	<b>2,960</b>	<b>2.02%</b>

The most common organ system involved was central nervous system (38%). The percentage of involvement of other organ systems (in the descending order) were cardiothoracic system (13%), musculoskeletal system (11%), genitourinary system (8%) & and gastrointestinal system (8%) comparable to study by Santos et al (2010) 38% CNS anomalies and 34% cardiothoracic anomalies.

## **Central Nervous System**

Anencephaly was the single most common anomaly in this study. Incidence of Anencephaly in our study was 0.2%. This incidence is in line with the study conducted by Dhapate et al (0.19%) and by Md. Jafer Golalipour et al (0.12%). S. Singh et al (2006) reported a higher incidence of 0.35%. Anencephaly contributed 30.43% of CNS anomalies. This observation is well within the range observed with larger studies, for instance, studies conducted in India by Dhapate et al showed the incidence to be 48.57%, while Balakumar reported 32.14%. Out of the 7 cases, 2 had acrania with some recognizable brain parenchyma. About 29% (2 of 7 cases) of anencephaly cases had polyhydramnios as evidenced in the literature (30-50%).

The diagnosis of Ventriculomegaly remained controversial till Cardoza et al (1988) reported that the normal atrial diameter remained relatively constant throughout the gestation. Ventriculomegaly is considered mild, if the atrial diameter is 10 to 15mm, moderate if it is 15 to 20mm, and severe if it is greater than 20mm. The main causes of fetal ventriculomegaly are aqueductal stenosis, Chiari II malformation, Dandy-Walker complex, and agenesis of the corpus callosum. Although the diagnosis of ventriculomegaly is easy, the prenatal identification of the cause of ventricular dilatation is a more difficult task. For this purpose the evaluation of the posterior fossa in association with the visualization of the corpus callosum is useful. In our Study, Ventriculomegaly has accounted for 21.73% of CNS anomalies, as against that observed in the study conducted by Muhammed Nafees et al (36.16%).

## Genitourinary system

Incidence of Genitourinary anomalies in our study was 8%. It is well within the range of 6.4 to 20.7% observed in various national and international articles. A comparison of the same is tabulated below:

**Table 11: Comparison of incidence of genitourinary anomalies with other studies**

S. No.	Author	Year	Incidence Percentage
1	Md. Nafees et al	2006	13.4%
2	Balakumar K	2007	18.1%
3	S. Singh et al	2006	6.4%
4	Euro fetus study group	1999	20.7%
5	Present study	2011	8%

Renal Pelvis dilation was the most common fetal renal abnormality. The incidence of Renal Pelvis Dilation in our study was 40% among other renal anomalies as against the incidence percentage reported by Dicke et al (66.4%).

In our study the baby with multicystic dysplastic kidney died soon after birth due to pulmonary hypoplasia (due to severe oligohydramnios).

## Cardiac and Respiratory Anomalies

Fetal cardiac scanning is well recognized as one of the most tedious scanning of all fetal organ systems.

**Table 12: Comparison of Incidence of CVS anomalies with other studies**

Sl.no	Author	Incidence among pregnancies
1.	Todros et al (1997)	4.8/1000
2.	Our study (2010)	1/1000

The incidence of cardiac malformations detected in our Study was just 1/1000 pregnancies which is quite low when compared to the incidence given in the literature, for instance, Todros et al (1997) reported an incidence of 4.8/1000 pregnancies in his study on 8299 pregnancies.

**Table 13: Comparison of incidence of CVS anomalies among anomalous babies**

**With other studies**

Sl.no	Author	No. of anomalous babies	Incidence among anomalous babies
1.	Gallegos Rivas et al (2007)	98	15.3%
2.	Muhammed Nafees et al (2006)	134	0.7%
3.	Our study (2010)	60	6.7%

Gallegos Rivas et al (2007) reported 15.3% incidence of heart defects out of 98 newborn babies born with various anomalies. Muhammed Nafees et al (2006) reported an incidence as low as 0.7% out of 134 babies with different anomalies. The incidence of cardiothoracic anomalies is higher in newborn; however, the detection rate of cardiac and pulmonary anomalies by antenatal ultrasound is much lower. Behrens et al (1999) reported 67(19.6%) defects in the heart out of the total 341 defects observed. However, only 3.3% of the defects were identified prenatally by ultrasound.

Ventricular Septal Defect (VSD) was the single most common cardiac defect observed in this Study. All the 3 cases had VSD of membranous type. One of them also had multiple small muscular VSDs. Colour Doppler is highly beneficial in the diagnosis of VSD. The incidence of VSD in our study was 40% and is comparable to the incidence reported by the Euro fetus Study Group (38.3%).

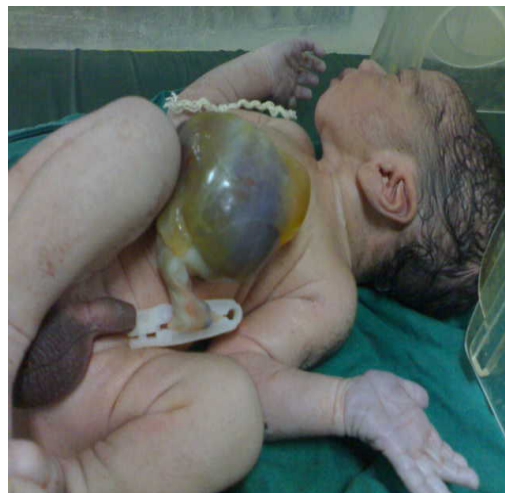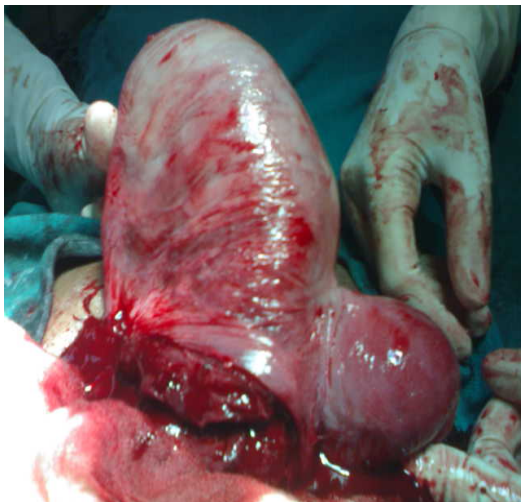Congenital diaphragmatic hernia (CDH) affects one in 2500 to 5000 births and can be detected in utero by means of ultrasound screening. Colvin et al conducted a retrospective study in which almost 47% of the CDH were diagnosed only postnatally. CDH was seen in 5 cases in our Study. All were left sided. Vogel et al reported 111 cases of Left sided diaphragmatic hernia out of the total 125 cases. Only stomach and bowel loops were seen within the thoracic cavity. In our study, one fetus had diaphragmatic hernia, VSD, strawberry head, clenched fist with overriding fingers. Cordocentesis was done and Karyotyping showed pure Trisomy 18. Hence termination was offered. Fetal autopsy revealed blind ending small bowel. Bollmann et al (1995)

reported 18.1% incidence of chromosomal abnormalities among 33 fetuses with CDH, the most common trisomy being Trisomy 18.

### **Gastrointestinal System**

There were 3 cases of gastroschisis in our study. 2 cases had associated sacral meningocele. 1 was isolated gastroschisis. Parents opted for termination. Fratelli et al (2007) retrospectively analyzed 42 cases of gastroschisis and reported that 95% of them were isolated. The majority (90%) of fetuses with antenatally diagnosed gastroschisis survived to delivery, but the mortality in affected newborns was 11%. Murphy et al (2007) reported a detection rate of 53% for gastroschisis.

2 cases had examphalos. Of this 1 mother was operated for anorectal malformation during her childhood details of which is not known. Patient was taken up for emergency LSCS for flexed breech with fetopelvic disproportion (baby had examphalos); mother was found to have bicornuate uterus intra operatively.



Left: bicornuate uterus – intra operative picture, Right – baby with examphalos (post natal picture)

## Musculoskeletal System

In our Study, 3 newborns were found to have Congenital Talipes Equino Varus (CTEV). 2 fetuses with CTEV were diagnosed prenatally. In one fetus, only lumbar meningocele was diagnosed by antenatal ultrasound but the unilateral CTEV was completely missed.

**Table 14: Comparison of Incidence of Musculoskeletal Anomalies with other studies**

Sl.no.	Author	No. of pregnant women studied	Incidence among pregnancies
1.	Swamy et al (2009)	75,933	0.06%
2.	Our study	2960	0.01%

The incidence of CTEV was 0.01%. Swamy et al (2009) reported an incidence of 0.06% out of 75,933 pregnancies.

While Offerdal et al (2007) reported an incidence of associated anomalies in 50%, Cohen-Overbeek et al (2006) reported incidence of 66%. In our study incidence of associated anomalies was 33%.

Lauson et al (2010) studied the outcome of prenatally diagnosed isolated clubfoot. They concluded that approximately 10% of neonates with clubfoot will have a normal foot or positional foot deformity requiring minimal treatment. Conversely, 10-13% of prenatally diagnosed cases of isolated clubfoot will have complex clubfoot postnatally.

## **Facial Anomalies**

Ultrasound is a useful tool in screening for cleft lip with or without cleft palate, but not for cleft palate alone. In our study, 3 cases of facial clefts were seen. Two of them had cleft lip with cleft palate and was diagnosed prenatally by ultrasound. The other baby with Cleft palate was missed antenatally. Hence, the detection rate of facial cleft was 66%. Maarse et al (2010) reported detection rate of 100% for cleft lip, 86-90% for cleft lip with palate and 0-89% for cleft palate by 3D ultrasound. They concluded that 2D ultrasound screening for cleft lip and palate in a low-risk population has a relatively low detection rate but is associated with few false-positive results. 3D ultrasound can achieve a reliable diagnosis, but not of cleft palate only. Euro fetus study group reported a sensitivity of 25% for cleft lip, 22% cleft lip with cleft palate and 1.4% for cleft palate only.

## **Incidence of Caesarean Delivery in Fetal Anomalies**

In our Study, 15 antenatal mothers underwent Caesarean Delivery as against 45 who underwent Vaginal Delivery. The incidence of Caesarean Delivery in our Study is 25%. Dempsey et al (2010) studied the impact of fetal anomalies on the mode of delivery. They reported significantly lower caesarean deliveries when anomalies were detected (17.5%) versus undetected (31%). They also concluded that the indication for caesarean delivery is more often maternal in the antenatal mothers diagnosed to have anomalous fetuses (42% versus 19%). In our study, 73 % of cesarean deliveries were due to maternal indication (placenta previa, breech with fetopelvic disproportion, previous cesarean with failed induction etc) as against 17% for fetal indication (fetal distress).



# SUMMARY

## SUMMARY

This is a prospective study conducted in Department of Obstetrics and Gynaecology, Govt RSRM Lying in Hospital, Chennai during the period January 2010 to September 2011 in 2960 cases who attended the outpatient department.

All antenatal mothers were subjected for ultrasonography after relevant history taking about their last menstrual period, obstetric score and the outcome of previous pregnancies. 60 antenatal mothers with anomalous fetuses were selected among them and were subjected for Level II Ultrasound study (Target anomaly scan). The anomalies were classified under 3 groups: Lethal, Severely Morbid and Non-Lethal. The prognosis of the baby was explained to the parents. Follow-up Ultrasound studies were done when appropriate. The final outcome of the pregnancy was assessed.

Among the 60 antenatal mothers with anomalous fetuses, 12 fetuses were classified as lethal. The single most common anomaly is Anencephaly. The most common organ system involved is Central Nervous System. Most of the lethal anomalies are seen in Central Nervous System. All cases of Hydrops Fetalis were considered lethal and suggested termination. Awareness about Fetal Karyotyping and Fetal Autopsy is very less among the patients and a positive step towards this is highly desirable. II trimester anomaly scan should be offered to all the antenatal mothers between 18-20 weeks and should be made an essential part of the standard antenatal care.

# CONCLUSION

## CONCLUSION

Ultrasonography is the real workhorse in Obstetric Imaging. The primary goal of routine obstetric sonography at 18-20 weeks gestation is to ensure structural normalcy of the fetus and to detect fetal anomaly at a time when legal termination of pregnancy is an option. The approach should be 'from ultrasound sign to final diagnosis' and not the other way round. The increasing technical advancements make the sonologists to improve their operator skill. An echo anatomic correlation is desirable. Identifying fetal anomalies at the earliest helps in taking decision by the patient without much emotional involvement. Those couples who choose to continue the pregnancy have the opportunity to prepare themselves through counseling with neonatologist, paediatric surgeon, obstetrician, genetics specialist to ensure appropriate care during pregnancy and following delivery. Those who takes decision for termination of pregnancy, it is easier for obstetrician and patient to offer termination. With fetal medicine and multidisciplinary approach, it is possible to provide the unfortunate couple with a reliable estimate of the diagnosis, the cause of the anomaly, the possible treatments if available, the chances of survival and the recurrence risk in subsequent pregnancies.



# REFERENCES

## REFERENCES

1. Winter, R.M., Baraitser, M.: Multiple Congenital Anomaly Syndromes: A Catalogue of Human Malformation Syndromes, Chapman and Hall, London (1991). The Winter-Baraitser Dysmorphology Database. <http://www.lmdatabases.com>.
2. Rama Murthy. Fetal Syndromes. Indian J Radiol Imaging/November 2008/Vol 18/Issue 4.
3. American Institute of Ultrasound in Medicine. AIUM practice guideline for the performance of obstetric ultrasound examinations. J Ultrasound Med 2010; 29:157–166.
4. The “20 week” anomaly scan: Royal College of Obstetricians and Gynaecologists. Report of the RCOG Working Party. London: RCOG Press, 2000.
5. Roberts AB, Hampton E, Wilson N. Ultrasound detection of fetal structural abnormalities in Auckland 1988-9. N Z Med J. 1993 Oct 27;106(966):441-3.
6. Saari-Kemppainen A, Karjalainen O, Ylöstalo P, Heinonen OP. Fetal anomalies in a controlled one-stage ultrasound screening trial. A report from the Helsinki Ultrasound Trial. J Perinat Med. 1994;22(4):279-89.
7. Lee K, Kim SY, Choi SM, Kim JS, Lee BS, Seo K, Lee YH, Kim DK. Effectiveness of prenatal ultrasonography in detecting fetal anomalies and perinatal outcome of anomalous fetuses. Yonsei Med J. 1998 Aug;39(4):372-82.

8. Behrens O, Steiner C, Böhmer S, Mühlhaus K. Efficacy of ultrasound screening in pregnancy. *Zentralbl Gynakol.* 1999;121(5):228-32.
9. Papp C, Bán Z, Szigeti Z, Csaba A, Lázár L, Nagy GR, Papp Z. Prenatal sonographic findings in 207 fetuses with trisomy 21. *Eur J Obstet Gynecol Reprod Biol.* 2007 Aug;133(2):186-90.
10. Papp C, Szigeti Z, Joó JG, Tóth-Pál E, Hajdú J, Papp Z. The role of perinatal autopsy in the management of pregnancies with major fetal trisomies. *Pathol Res Pract.* 2007;203(7):525-31.
13. Aagaard-Tillery KM, Malone FD, Nyberg DA, Porter TF, Cuckle HS, Fuchs K, Sullivan L, C1mstock CH, Saade GR, Eddleman K, Gross S, Dugoff L, Craigo SD, Timor-Tritsch IE, Carr SR, Wolfe HM, Bianchi DW, D'Alton ME; First and Second Trimester Evaluation of Risk Research Consortium. Role of second-trimester genetic sonography after Down syndrome screening. *Obstet Gynecol.* 2009 Dec;114(6):1189-96.
12. Fadda GM, Capobianco G, Balata A, Litta P, Ambrosini G, D'Antona D, Cosmi E, Dessole S. Routine second trimester ultrasound screening for prenatal detection of fetal malformations in Sassari University Hospital, Italy: 23 years of experience in 42,256 pregnancies. *Eur J Obstet Gynecol Reprod Biol.* 2009 Jun;144(2):110-4.
13. Pitukkijronnakorn S, Chittacharoen A, Jetsawangsi T, Panburana P, Jaovisidha A, Roungsipragarn R, Saropala N, Herabutya Y. The value of mid-trimester routine ultrasonographic screening in antenatal detection of congenital malformations. *J Med Assoc Thai.* 2009 Jun;92(6):748-53.

14. Borrell A, Robinson JN, Santolaya-Forgas J. Clinical Value of the 11- to 13+6-Week Sonogram for Detection of Congenital Malformations: A Review. *Am J Perinatol*. 2010 Aug 10.
15. Santos XM, Papanna R, Johnson A, Cass DL, Olutoye OO, Moise KJ Jr, Belleza-Bascon B, Cassidy CI. The use of combined ultrasound and magnetic resonance imaging in the detection of fetal anomalies. *Prenat Diagn*. 2010 May;30(5):402-7.
16. Phadke SR, Gupta A. Comparison of prenatal ultrasound findings and autopsy findings in fetuses terminated after prenatal diagnosis of malformations: an experience of a clinical genetics center. *J Clin Ultrasound*. 2010 Jun;38(5):244-9.
17. Kulkarni ML, Mathew MA, Reddy V. The range of neural tube defects in southern India. *Archives of diseases in childhood* 1989;64:201-204.
18. Singh S, Shergill GS, Singh A, Chander R. Role of ultrasound in detection of antenatal foetal malformations. *Indian J Radiol Imaging* 2006;16:831-4
19. Dhapate SS, Shingare AK, Sanjay Desai. Early Diagnosis of Anencephaly – Value of ultrasound in Rural area. *J. Anat. Soc. India* 56 (2) 4-7 (2007)
20. Diagnostic accuracy of transabdominal ultrasound in detecting prenatal cleft lip and palate: a systematic review. Maarse W, Bergé SJ, Pistorius L, van Barneveld T, Kon M, Breugem C, Mink van der Molen AB; *Ultrasound Obstet Gynecol*. 2010 Mar 16
21. Ott WJ. The accuracy of antenatal fetal echocardiography screening in high and low risk patients. *Am J Obstet Gynecol* 1995; 172:1741–1749



22. Sermer M, et al.;Prenatal diagnosis and managment of congenital defects of the anterior abdominal wall. Am J Obstet Gynecol 156:308,1987
23. Balakumar K, Major anatomical fetal anomalies in Northern Kerala. J Obstet Gynecol India Vol. 57, No. 4 : July/August 2007 Pg 311-315
24. J D Cardoza, R B Goldstein and R A FillyExclusion of fetal ventriculomegaly with a single measurement: the width of the lateral ventricular atrium. Radiology December 1988 169:711-714
25. Muhammad Nafees, Muhammad Hamid Akram, Makki Muhammad Afridi, Aqsa Javed. Congenital Fetal Anomalies Antenatal Ultrasound. Pakistan Armed Forces Medical Journal:2006:3:September.
26. Dicke JM, Blanco VM, Yan Y, Coplen DE. The type and frequency of fetal renal disorders and management of renal pelvis dilatation. J Ultrasound Med. 2006 Aug;25(8):973-7.
27. Todros T, Faggiano F, Chiappa E, Gaglioti P, Mitola B, Sciarrone A. Accuracy of routine ultrasonography in screening heart disease prenatally. Prenat Diagn. 1997 Oct;17(10):901-6.
28. Gallegos Rivas MC, Romero Gutiérrez G, Pérez López NM, Salazar Torres M. Ginecol Obstet Mex. Major and multiple birth defects in newborns of women attended in a tertiary care hospital, Ginecol Obstet Mex. 2007 May;75(5):247-52.
29. Grandjean H, Larroque D, Levi S. The performance of routine ultrasonographic screening of pregnancies in the Eurofetus Study. Am J Obstet Gynecol. 1999 Aug;181(2):446-54..

30. Bollmann R, Kalache K, Mau H, Chaoui R, Tennstedt C. Associated malformations and chromosomal defects in congenital diaphragmatic hernia. *Fetal Diagn Ther.* 1995 Jan-Feb;10(1):52-9.
31. Maarse W, Bergé SJ, Pistorius L, van Barneveld T, Kon M, Breugem C, Mink van der Molen AB. Diagnostic accuracy of transabdominal ultrasound in detecting prenatal cleft lip and palate: a systematic review. *Ultrasound Obstet Gynecol.* 2010 Apr;35(4):495-502.
32. Fratelli N, Papageorghiou AT, Bhide A, Sharma A, Okoye B, Thilaganathan B. Outcome of antenatally diagnosed abdominal wall defects. *Ultrasound Obstetrics and Gynecology.* 2007 Sep; 30(3):266-70.
33. Offerdal K, Jebens N, Blaas HG, Eik-Nes SH. Prenatal ultrasound detection of talipes equinovarus in a non-selected population of 49 314 deliveries in Norway. *Ultrasound Obstet Gynecol.* 2007 Nov;30(6):838-44.
34. Neubert S, Trautmann K, Tanner B, Steiner E, Linke F, Bahlmann F. Sonographic prognostic factors in prenatal diagnosis of Sacrococcygeal teratoma. *Fetal Diagn Ther.* 2004 Jul-Aug;19(4):319-26.
35. Dempsey MA, Breathnach FM, Geary M, Fitzpatrick C, Robson M, Malone FD. Congenital anomalies: Impact of prenatal diagnosis on mode of delivery. *Ir Med J.* 2010 Mar;103(3):88-9.

# **ANNEXURE**

## PROFORMA

Name:

Age:

Residence/Location:

Socioeconomic status:

LMP:

EDD:

Period of Gestation:

Obstetric Code:

Any Specific Complaints

H/o any radiation exposure/ viral illness/ drug intake in first trimester

Previous Obstetric History:

→H/o Abortions:

→H/o Intra Uterine Demise:

→H/o Congenital Anomalies:

Previous Ultrasound Reports:

1)

2)

Past Medical History:

→Diabetes Mellitus

→Hypertension

→Epilepsy

Personal History:

→H/o Smoking:

→H/o Alcoholism:

Drug History:

→Anti-epileptics

→Anti-depressants and Lithium

→Broad-spectrum Antibiotics

Significant Family History:

→H/o Consanguinity

→H/o anomalies in the families

Significant Obstetric Examination Findings:

→Fundal height

→Presentation

→Per Vaginum findings

Significant Laboratory Findings:

→Hb%

→Blood grouping and typing

→HIV

→VDRL

Ultrasound Examination Report:

Examination Date:

A) Number of fetus(es)

B) Presentation

C) Fetal Biometry

BPD (in mm):

HC (in mm):

AC (in mm):

FL (in mm):

HC/AC:

Avg. Gestational age:

Estimated Fetal Weight (in grams):

## D) Fetal Anatomy and Survey

- Cranium
- Cerebral ventricles, cavum septi pellucid, midline falx, choroid plexus
- Posterior fossa: cistern magna, cerebellum
- Face: orbits, lips
- Spine
- Chest
- Cardiac Four-chamber view
- Cardiac outflow tracts
- Cardiac three-vessel view
- Situs
- Stomach
- Bowel
- Kidneys
- Bladder
- Abdominal cord insertion
- Number of cord vessels
- Upper extremities
- Lower extremities

## E) Amniotic Fluid

Normal/Increased/Decreased/Absent

AFI (if applicable):

F) Placenta

Position:

Relationship to the cervical os:

G) Maternal Anatomy

Uterus

Cervix

Ovaries

Bladder

Postnatal findings in baby/abortus:

→ Delivery Details

→ External examination

→ Radiological examination

→ Karyotyping

→ Autopsy



