ANALYTICAL STUDY OF ADVANTAGES OF HARMONIC SCALPEL IN THYROID SURGERY.

Dissertation submitted to

THE TAMILNADU
DR. M.G.R. MEDICAL UNIVERSITY
CHENNAI – 600032

With fulfillment of the Regulations
For the Award of the Degree of

M.S. GENERAL SURGERY (BRANCH - I)
APRIL – 2015

DEPARTMENT OF GENERAL SURGERY
MADURAI MEDICAL COLLEGE AND GOVERNMENT RAJAJI HOSPITAL
MADURAI – 625020

CERTIFICATE

This is to certify that this Dissertation titled *" **ANALYTICAL STUDY OF ADVANTAGES OF HARMONIC SCALPEL IN THYROID SURGERY**"* **at Government Rajaji Hospital, Madurai** submitted by **DR. K.VASANTHAN**, to the faculty of General Surgery, **The Tamilnadu Dr. M.G.R. Medical University, Chennai** in partial fulfillment of the requirement for the award of MS degree (Branch I) General Surgery, is a bonafide research work carried out by him under my direct supervision and guidance from September 2013 to September 2014.

Prof. Dr. A. SANKARAMAHALINGAM, M.S.,
Professor and Head of the Department,
Department of General Surgery,
Madurai Medical College,
Madurai.

CERTIFICATE

This is to certify that this Dissertation titled ***"ANALYTICAL STUDY OF ADVANTAGES OF HARMONIC SCALPEL IN THYROID SURGERY"*** **at Government Rajaji Hospital, Madurai** submitted by **DR. K. VASANTHAN**, to the faculty of General Surgery, **The Tamilnadu Dr. M.G.R. Medical University, Chennai** in partial fulfillment of the requirement for the award of MS degree (Branch I) General Surgery, is a bonafide research work carried out by him under my direct supervision and guidance from September 2013 to September 2014.

I have great pleasure in forwarding it to The Tamilnadu Dr. M.G.R. Medical University, Chennai.

Captain. Prof. Dr. B. SANTHAKUMAR M.Sc., M.D.,
Dean
Madurai Medical College,
Madurai.

DECLARATION BY THE CANDIDATE

I hereby declare that this dissertation entitled *" **ANALYTICAL STUDY OF ADVANTAGES OF HARMONIC SCALPEL IN THYROID SURGERY"*** is a bonafide and genuine research work carried out by me in the Department of General Surgery, Madurai Medical College, during the period of September 2013 to September 2014 , under the guidance and supervision of **Prof.Dr.A.SANKARAMAHALINGAM, M.S.,** Professor and Head, Department of Surgery, Madurai Medical College, Madurai. This is submitted to **The Tamilnadu Dr. M.G.R. Medical University, Chennai**, in partial fulfillment of the regulations for the award of MS degree (Branch I) General Surgery course on April 2015.

Dr. K. VASANTHAN

Post Graduate Student

Department of General Surgery

Madurai Medical College,

Madurai.

ACKNOWLEDGEMENT

First I would like to give thanks to the God almighty whose blessing made this study possible.

I have absolutely no words to express my deep sense of gratitude and sincere thanks to my guide **Prof. Dr. A. SANKARAMAHALINGAM M.S.,** Professor and Head of the Department, **Prof. Dr. DHAMOTHARAN M.S.,** for his constant encouragement, help, invaluable guidance, moral support and blessings throughout my Post Graduation course, I thank both of them for helping me in selecting and preparing this dissertation.

I thank the **DEAN** of Madurai Medical College and Govt Rajaji Hospital, **Captain. Prof. Dr. B. SANTHAKUMAR M.Sc., M.D.,** for permitting me to conduct this study in the Department of General Surgery of the Govt Rajaji Medical college and Hospital, Madurai.

I am greatly indebted and thankful to my unit Assistant Professors **Dr. P. Ganesh, M.S., Dr. Ashok Chakravarthy M.S., Dr. Ganga Lakshmi M.S., and Dr. Ganga M.S.,** who have put in countless hours in guiding me in many aspects of this study and also in tuning my surgical skills.

My heartfelt gratitude to the professors and Assistant Professors of all other units.

My deep sense of gratitude and indebtedness to my loving parents Mr. R. Kathirasen, Mrs. K. Seethalakshmi and my wife for their abundant love, endurance, support , innumerable sacrifices and unceasing encouragement that has moulded me into the person I am today.

I extend my sincere thanks to my friend post graduate colleagues Dr. P. Mukesh Kumar M.S.,

Last but not the least I am thankful to all my **Patients** without whom this study could not have been completed.

LIST OF ABBREVIATIONS

CT	Computed Tomography
DIT	Di Iodo Thyronine
DVT	Deep Vein Thrombosis
EBSNL	External Branch of Superior Laryngeal Nerve
EMG	Electro Myography
ESU	Electro Surgical Unit
FDG	Fluorodeoxyglucose
FNAC	Fine Needle Aspiration Cytology
HS	Harmonic Scalpel
IBSNL	Internal Branch of Superior Laryngeal Nerve
IDL	Indirect Laryngoscopy
IRMA	Immuno Radiometric Assay
ITA	Inferior Thyroid Artery
KTP	Potasium Titanium Phosphate
MIT	Mono Iodo Thyronine
MNG	Multi Nodular Goitre
MRI	Magnetic Resonance Imaging
NIS	Sodium Iodide Symport
PET	Positron Emission Tomography
PTH	Parathormone
RAI	Radio Active Iodine
RLN	Recurrent Laryngeal Nerve
RLND	Recurrent Laryngeal Nerve Dysfunction
SLN	Superior Laryngeal Nerve
SNG	Solitary Nodular Goitre
SSKI	Saturated Solution of Potassium Iodide
T3	Triiodothyronine
T4	Tetraiodothyronine
TBG	Thyroid Binding Globulin
TE	Tracheoesophageal
Tg	Thyroglobulin
TPO	Thyroid Peroxidase
TR	Thyroid Receptors
TSH	Thyroid Stimulating Hormone
TSHR	Thyroid Stimulating Hormone Receptor
USG	Ultrasonogram

TABLE OF CONTENTS

LIST OF TABLES

INTRODUCTION

Thyroid surgery is one of the most commonly performed surgery for benign and malignant conditions of the thyroid gland worldwide.

The thyroid gland is closely related to many vital structures and hence poses a unique challenge to the surgeon.

Kocher and Billroth developed the approach to the thyroid gland, both revolutionized the understanding of treatment of thyroid disease.

In rapid succession, the understanding of altered physiology, advances in imaging, minimally invasive diagnostic and surgical techniques have taken place.

Harmonic scalpel is one such advance which is now extensively used in all surgeries including thyroidectomies.

There is well documented usefulness of harmonic scalpel by means of reduced blood loss in modern surgical practice

The gold standard technique for feeding vessel is being hemostasis by means of non absorbable suture tie

But even though this technique was followed for quite a long time, nowadays the ultrasonic Harmonic scalpel has been emerging as the safe tool since it is proved in reducing post operative pain, drainage and transient hypocalcemia

ABSTRACT

Background and Objectives

Thyroid surgery is known to its complications post operatively. In recent times this complications are reduced due to expertise in techniques and technologies. One of this is harmonic scalpel in hemostasis proven to reduce blood loss and operative time in various gastrointestinal surgery. Meticulous hemostasis has and will always be an essential prerequisite for a successful outcome in thyroid surgery.

In last twenty years, many reports have evaluated the effectiveness of the Harmonic Scalpel for thyroid surgery and the greater part of these studies have been carried out at European Hospitals.

The purpose of this study was to determine the advantages of harmonic scalpel in thyroid surgery in our setup. Now harmonic scalpel is very useful tool in thyroid surgery to minimize operative time, blood loss and post operative complications.

Methods

From Sep 2013 to Sep 2014 our study has been conducted which includes 33 successive patients undergoing (Hemi/Total) Thyroidectomy procedures and meeting the inclusion criteria in our surgical ward at GRH Madurai.

Results

In our study, mean duration for Hemi thyroidectomy was 63.5 min and for Total thyroidectomy 101.1 min. Mean post operative pain score 1.45±1.43 in which 14 patients had No pain and 14 patients had Mild pain, 5 patients had score 4 or more. Post operative drainage fluid volume in 1st 24 hrs was 25.4ml and 2nd 24 hrs was 14.4 ml, and 12% patients had transient post operative Hypocalcemia.

Conclusion

Harmonic Scalpel is a reliable and safe tool in thyroidectomy. The total drainage fluid volume and surgical operative time is reduced. In addition, the postoperative pain is less and the rate of Post operative transient hypocalcemia is lower.

Key words: Harmonic Scalpel, Thyroidectomy, Complications

AIMS AND OBJECTIVES

The advantages of harmonic scalpel over conventional hemostasis is by means of

1. Duration of surgery
2. Postoperative
    a. drainage fluid volume
    b. Pain
    c. Transient hypocalcemia
    d. RLN Injuries

STUDY CRITERIA

INCLUSION CRITERIA:

All patients admitted in General surgical wards of Govt Rajaji Hospital with SNG, MNG thyroid in Euthyroid status and thyroid lobe size less than 5cm (greatest dimension) included in the study.

EXCLUSION CRITERIA :

1. Carcinoma Thyroid
2. Toxic nodules
3. Recurrent thyroid swelling

REVIEW OF LITERTURE

SURGICAL ANATOMY OF THYROID GLAND: [1,2]

"The extirpation of the thyroid gland for goiter typifies perhaps, better than any operation the supreme triumph of the surgeon's arm"-William Halsted.

The anatomic relations of the thyroid gland and surrounding structures are as follows. The adult thyroid gland is chocolate in colour and is located anterior to the trachea between cricoid cartilage and the suprasternal notch.

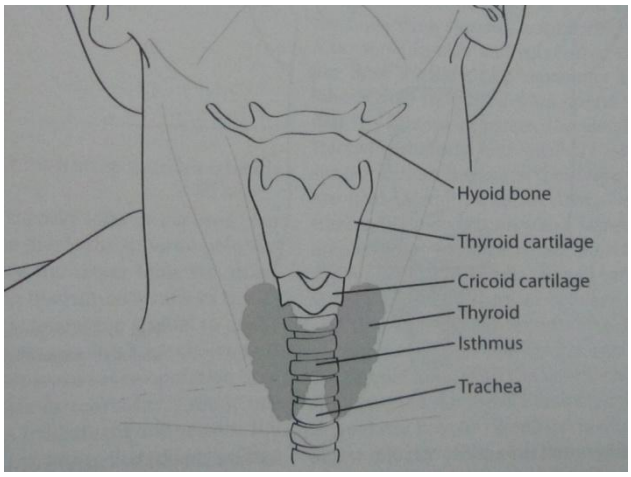

The weight of the normal thyroid gland is around 20 g, about 50% of patients pyramidal lobe is present and represents the most distal portion of the thyroglossal duct.

The true capsule is the peripheral condensation of the connective tissue of the gland. The false capsule is derived from the pretracheal layer of the deep cervical fascia. It is thin along the posterior border of the

lobes, but thick on the inner surface of the gland where it forms a suspensory ligament, which connects the lobe to the cricoid cartilage.

A dense capillary plexus is present deep to the true capsule. To avoid haemorrhage during operations the thyroid is removed along with the true capsule.

Relations

The lobes are conical in shape having a) an apex b) a base c) three surfaces, lateral, medial and posterolateral, and d) two borders, anterior and posterior. The lateral (superficial) surface is convex, and is covered by; a. the sternothyroid, b. the sternohyoid, c. the superior belly of the omohyiod; and d. the anterior border of the sternomastoid.

Transverse section at thyroid gland level

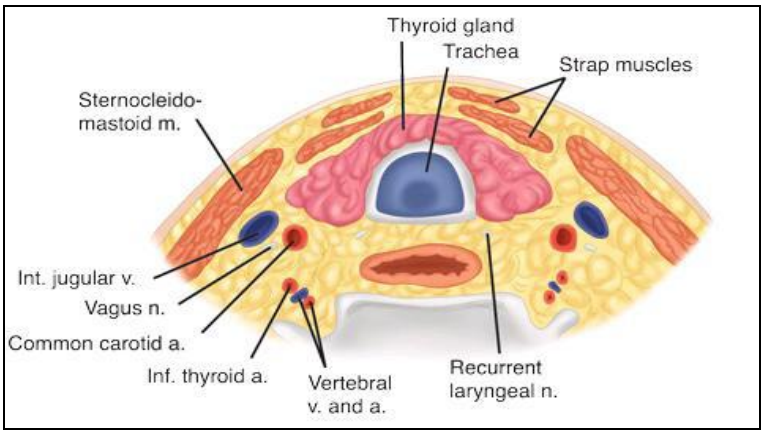

The medial surface is related to a. two tubes, trachea and oesophagus b. two muscles, inferior constrictor and cricothyroid and c. two nerves external laryngeal and recurrent laryngeal.

The posterolateral (posterior) surface is related to the carotid sheath and overlaps the common carotid artery.

The anterior border is thin and is related to the anterior branch of the superior thyroid artery.

The posterior border is thick and rounded and separates the medial and posterior surfaces. It is related to a. the inferior thyroid artery, b. the anastomosis between the superior and inferior thyroid arteries, c. the parathyroid glands, and d, the thoracic duct(on the left side).

The apex is directed upwards a slightly laterally it is limited superiorly by the attachment of the sternothyroid to the oblique line of the thyroid cartilage.

The base is on level with the 4th or 5th tracheal ring.

The isthmus connects the lower parts of the two lobes. It has (a) two surfaces, anterior and posterior; and (b) two border, superior and inferior. Occasionally the isthmus is absent.

The anterior surface is covered by: a. the right & left sternothyroid and sternohyoid muscles; b. the anterior jugular veins; c. fascia and skin.

The posterior surface is related to the 2nd and 3rd tracheal rings. It may be placed at a higher, or lower level. The upper border is related to the anastomosis between the right and left superior thyroid arteries. Lower border – inferior thyroid veins leave the gland at this border.

Anatomy of thyroid gland anterior view

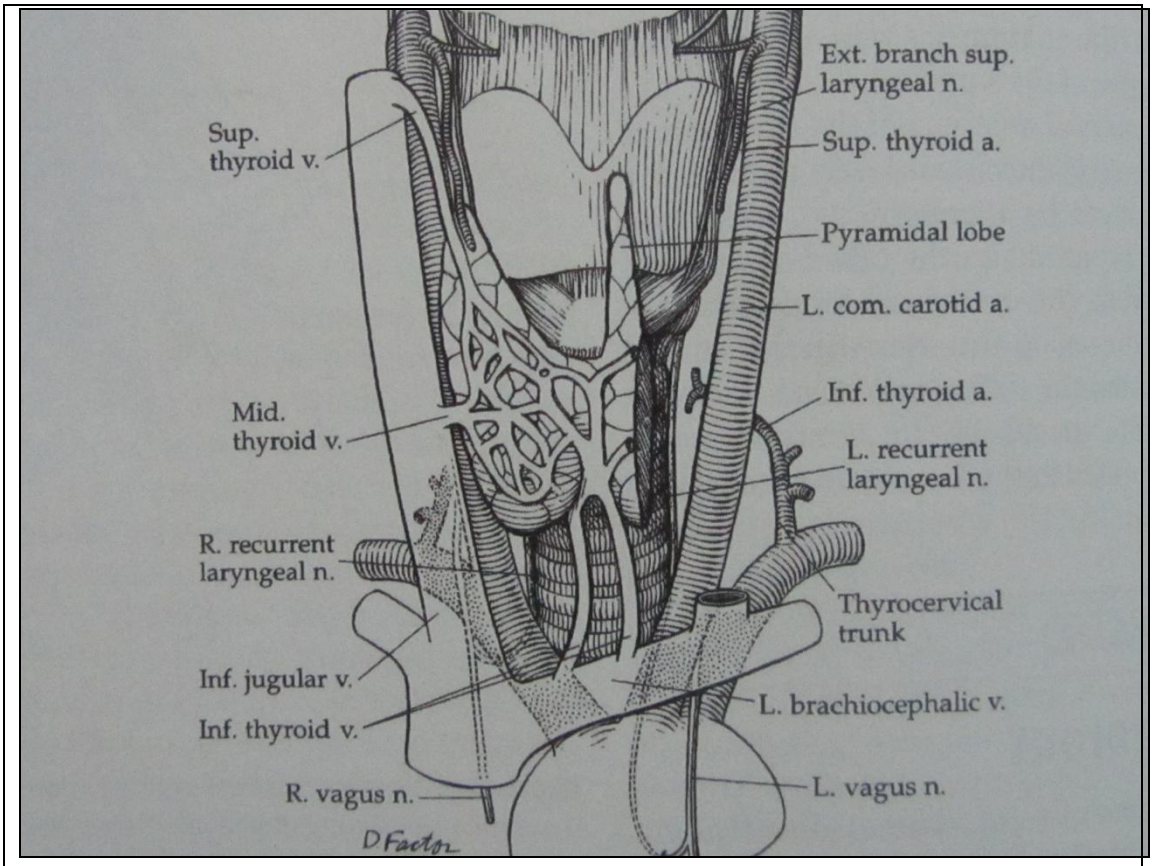

Arterial Supply

The thyroid gland is supplied by the superior and inferior thyroid arteries.

The superior thyroid artery is the first anterior branch of the external carotid artery. It runs downwards and forwards in intimate relation to the external laryngeal nerve. After giving branches to adjacent structures it pierces the pretracheal fascia to reach the upper pole of the lobe. Here it divides into anterior and posterior branches. The anterior branch descends

on the anterior border of the lobe and continues along the upper border of the isthmus to anastomose with its fellow of the opposite side. The posterior branch descends on the posterior border of the lobe and anastomoses with the ascending branch of the inferior thyroid artery.

The inferior thyroid artery is a branch of the thyrocervical trunk which arises from the subclavian artery. It runs first upwards, then medially, and finally downwards to reach the lower pole of the gland. During its course, it passes behind the carotid sheath and the middle cervical sympathetic ganglion; and in front of the vertebral vessels; and gives off branches to adjacent structures. Its terminal part is intimately related to the recurrent laryngeal nerve. The artery divides into 4 or 5 glandular branches which pierce the fascia separately to reach the lower part of the gland. One ascending branch anastomoses with the posterior branch of the superior thyroid artery, and supplies the parathyroid gland.

It is often said that the superior thyroid artery supplies the upper one third of the lobe and the upper half of the isthmus; and that the inferior thyroid artery supplies the lower two thirds of the lobe and the lower half of the isthmus. However, the superior and inferior thyroid arteries anastomose freely both on the surface of the gland as well as in its substance; and the territories supplied by the two arteries overlap considerably.

Sometimes (in 3% of individuals) the thyroid is also supplied by the lowest artery (thyroidea ima artery) which arises from the branchiocephalic trunk or directly from the arch of the aorta. It enters the lower part of the isthmus. Accessory thyroid arteries arising from tracheal and oesophageal arteries also supply the thyroid.

VASCULAR ANATOMY OF THYROID GLAND: [2]

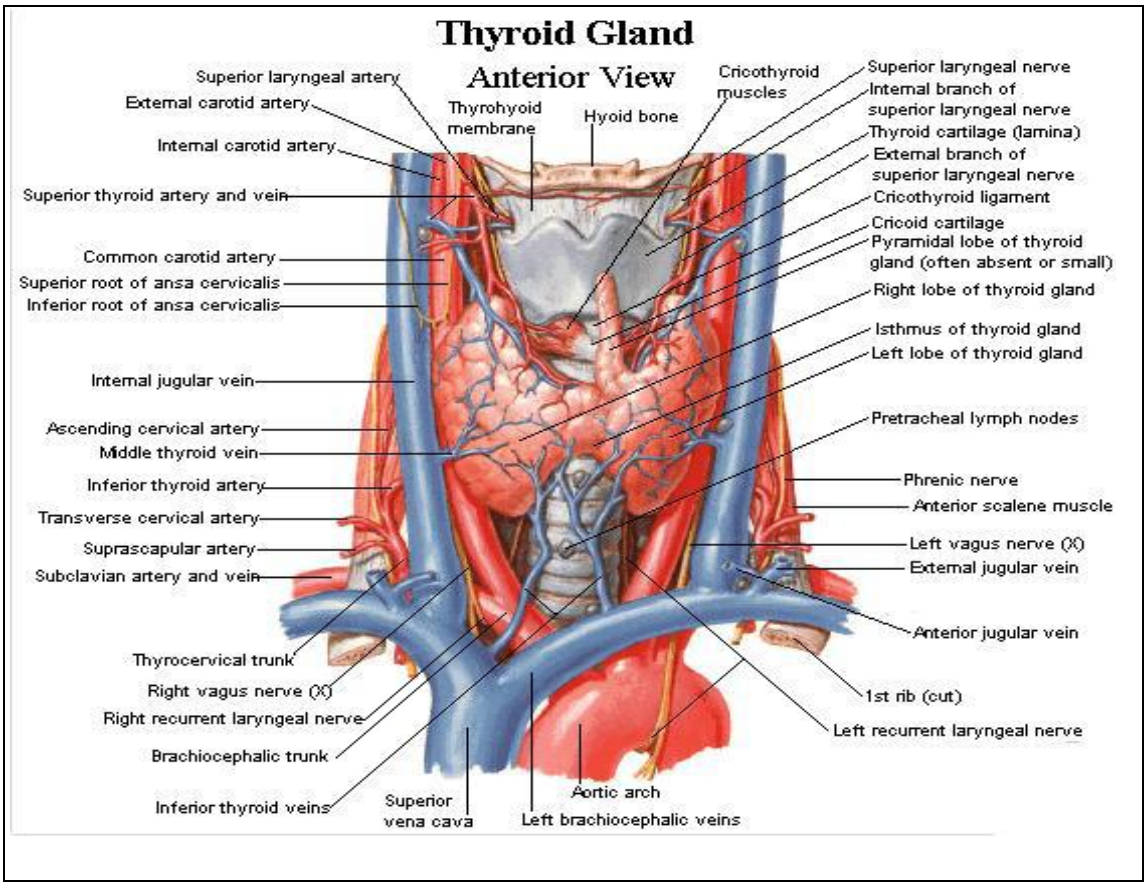

Venous Drainage

The thyroid is drained by the superior, middle and inferior thyroid veins. The superior thyroid vein emerges at the upper pole and accompanies the superior thyroid artery it ends either in the internal jugular vein or in the common facial vein. The middle thyroid vein is a short, wide channel which emerges at the middle of the lobe and soon enters the internal jugular vein. The inferior thyroid vein emerges at the lower border of the isthmus. They form a plexus in front if the trachea, and drain into the left brachiocephalic vein. A fourth thyroid vein (of Kocher) may emerge between the middle and inferior veins, and drain into the internal jugular vein.

LYMPHATIC DRAINAGE: [3]

The relationship of the thyroid gland to its lymphatic drainage is most important when considering surgical treatment of thyroid carcinoma. The thyroid gland and its neighboring structures have rich lymphatics that drain the thyroid in almost every direction. Within the gland, lymphatic channels are present immediately beneath the capsule and communicate between lobes through the isthmus. This drainage connects to structures directly adjacent to the thyroid, with numerous lymphatic channels into the regional lymph nodes.

Clinically, it is useful to divide the lymph nodes between the central and lateral neck; the boundary between them is marked by the carotid sheath. The lateral neck zones are further subdivided. Most thyroid cancers drain directly to central nodal basins (level VI), expect those in the superior third of the gland, which may drain directly to the lateral compartment.

The superior laryngeal nerve

The superior laryngeal nerve arises from the inferior ganglion of the vagus, runs downwards and forwards on the superior constrictor deep to the internal carotid artery, and reaches the middle constrictor where it divides into the external and internal laryngeal nerves. The external laryngeal nerve is thin. It accompanies the superior thyroid artery, pierces the inferior constrictor, and ends by supplying the cricothyroid muscle. It also gives branches to the inferior constrictor and to the pharyngeal plexus. The internal laryngeal nerve is thick. It passes downwards and forward, pierces the thyrohyoid membrane (above the superior laryngeal vessels) and enters the larynx. The supplies the mucous membrane of the larynx above the level of the vocal folds.

Course of RLN in Relation with Inferior Thyroid Artery

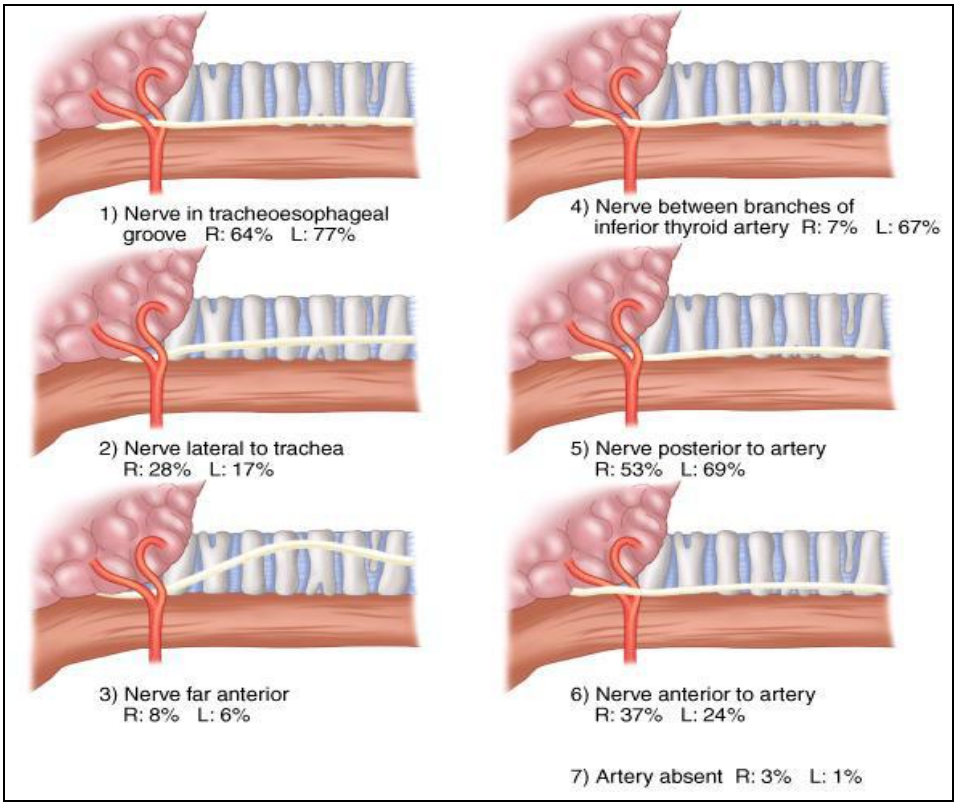

The right recurrent laryngeal nerve.

The right recurrent laryngeal nerve arises from the vagus in the front of the right subclavian artery, winds backwards below the artery, and they runs upwards and medially behind the subclavian and common carotid arteries to reach the trachea oesophageal groove. In the upper part of the groove it is related to the inferior thyroid artery. It may be superficial or deep to the artery. Occasionally, some branches are in front of the nerve, and some are behind it. The nerve then passes deep to the lower border of the inferior constrictor, and enters the larynx behind the cricothyroid joint. It supplies: a) all intrinsic muscles of the larynx, except

the cricothyroid, b) sensory nerves of the larynx below the level of the vocal cords c) cardiac branches to the deep cardiac plexua, d) branches to the trachea and oesophagus, and e) to the inferior constrictor.

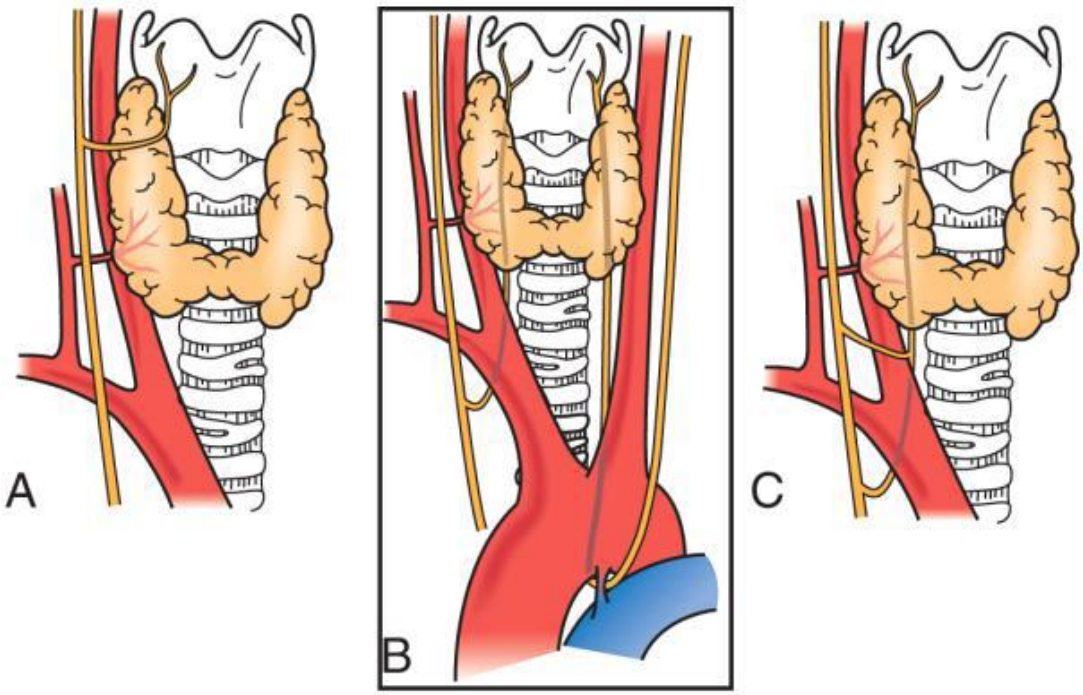

A. Non Recurrent **B. Recurrent** **C. Both**

The left recurrent laryngeal nerve

The left recurrent laryngeal nerve arises from the vagus in the thorax, as the latter crosses the left side of the arch of the aorta. It loops around the ligamentum arteriosum and reaches the trachea oesophageal groove. Its distribution is similar to that of the right nerve. It does not have to pass behind the subclavian and carotid arteries, and usually it is posterior to the inferior thyroid artery.

The cardiac branches are superior and inferior. Out of the four cardiac branches of the vagi (two on each side) the left inferior branch goes to the superficial cardiac plexus. The other three cardiac nerves go to the deep cardiac plexus.

The most commonly encountered congenital cervical anomalies are Thyroglossal duct cysts, the thyroglossal duct lumen starts to obliterate from fifth week of gestation, and at the end of eighth week of gestation, duct disappears fully.

PARATHYROID GLAND

The parathyroid glands develop from Branchial Pouches III and IV. The superior parathyroid glands develop from Pouch IV, travel a shorter distance than the inferior glands, and are typically located along the posterior border of the thyroid gland at approximately 1 cm superior to the entrance of the inferior thyroid artery. Because of this location, when the superior glands descend further, they almost always remain posterior, in the tracheoesophageal groove or retroesophageal space. The location of the inferior gland can range from being high, anterior to the carotid artery to being in the anterior mediastinum within the thymus.

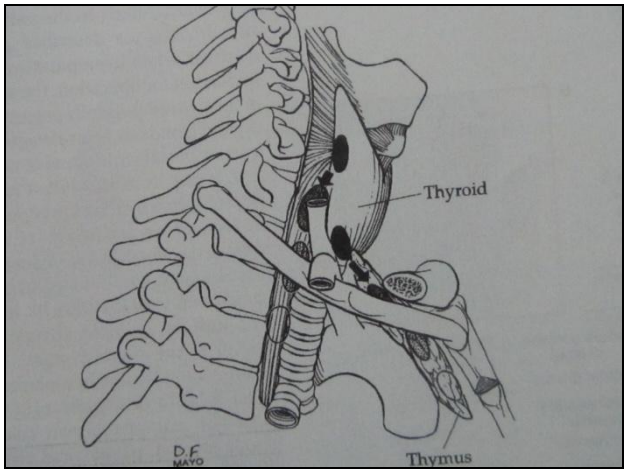

Inferior glands associated with the thyroid gland usually remain ventral to the recurrent laryngeal nerve, whereas the superior glands are found dorsal to the nerve.

Parathyroid glands and its relationship to RLN

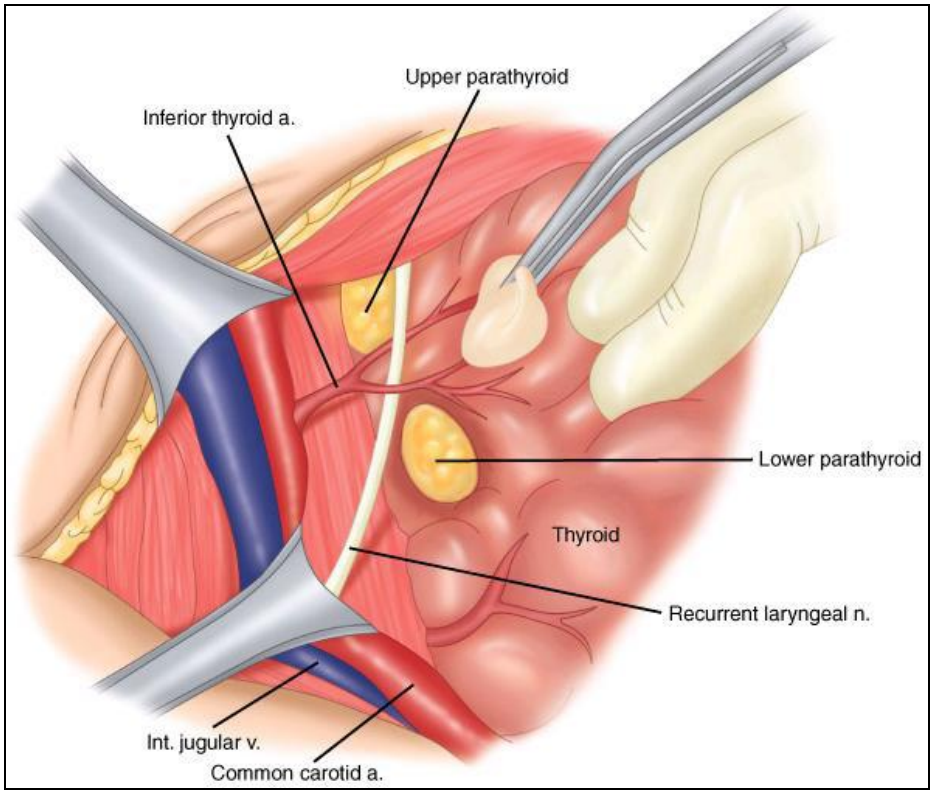

Physiology of thyroid

Thyroid hormone synthesis begins in the fetus at 11 weeks of gestation.

TSH is the important stimulator of thyroid gland and also a marker for thyroid dysfunction.

TSH works by negative endocrine feedback system. TSH production occurs by pulsatile manner and it reaches peak value at night.

Thyroid hormone acts by its nuclear receptor.

Ultimobronchial bodies gives to thyroid medullary C cells that produce calcitonin. C cells aggregated at upper 2/3 lower 1/3 of thyroid gland

THYROID HORMONE SYNTHESIS

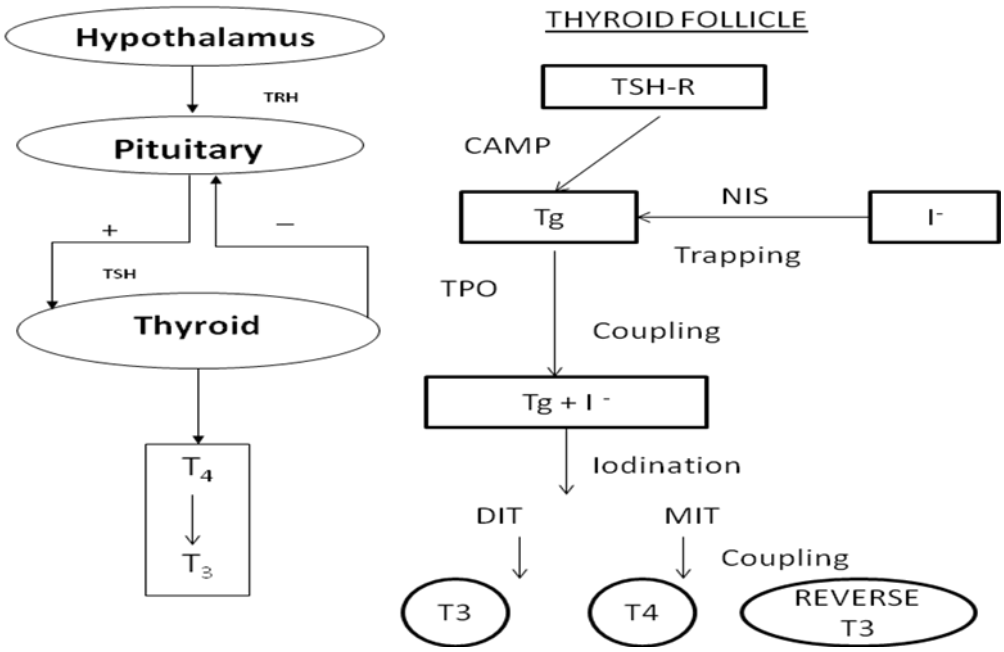

Spectrum of thyroid disease

1. **Functional** abnormality of the thyroid is grossly classified in to

   Hypo thyroid and hyper thyroid.

   In both conditions medical management in the mainstay of treatment

2. **Inflammatory** conditions of the thyroid are called as thyroiditis
   a. Acute thyroiditis is due to Bacterial infection and fungal infection, radiation thyroiditis and drug induced (amiodarone).
   b. Sub acute thyroiditis includes viral, that is otherwise called as granulomatous thyroiditis, silent thyroiditis, TB thyroiditis.
   c. Chronic thyroiditis includes Hashimoto's, Reidel's Thyroiditis
3. **Goiter and Nodular** thyroid Disease

   Nodular thyroid disease are common clinical thyroid problems

Pathology of nodule formation

Persistent growth stimulation can cause diffuse hyperplasia which is reversible. Then fluctuating stimulation leads to areas of active and inactive lobules. The active lobules are more vascular leading to haemorrhage into follicle will cause necrosis leaving surrounding active follicles. Necrotic lobules unite to form nodules filled colloid or mass of inactive follicles.This process continues will cause nodule formation.

1. Diffuse non toxic simple goiter (colloid goiter)

- cause : iodine deficiency (Endemic goiter)
- treatment is medical

2. Single solitary nodular goiter
3. Multi nodular goiter

Complications

a. Toxicity
b. Malignancy
c. Retrosternal extension
d. Pressure effects
e. calcification

4. Thyroid malignancy
   - differentiated thyroid cancer includes papillary and follicular variety and hurthle cell carcinoma.
   - Undifferentiated thyroid cancer includes anaplastic and medullary carcinoma of thyroid.

Clinical features of thyroid disorders

In thyroid disorders, age of the patient should be significantly considered. Simple Goiter is observed in pubertal girls. MNG, SNG and colloid goiters are seen in females of 20s and 30s. Papillary carcinoma is seen in young girls and follicular carcinoma seen in middle aged women.

Anaplastic carcinoma is the disease of old age. Primary toxic goiter is seen in young females whereas Hashimoto's thyroiditis is seen in middle aged middle aged women.

Areas where there is iodine deficiency there will be the occurrence of endemic goiter. Most of the thyroid disorders present with swelling in front of the neck. The inflammatory conditions of thyroid are painful. The malignant conditions of thyroid gland are initially painless to start with and then later on become painful.

Pressure effects

Thyroid swelling may compress on the trachea to produce dyspnoea or it can compress on oesophagus to produce dysphagia. Hoarseness or change in voice is commonly due to infiltration of the recurrent laryngeal nerve by the malignant thyroid.

Symptoms of primary hyperthyroidism

The most notorious symptom of primary thyrotoxicosis is loss of weight inspite of good appetite. Cold preference, heat intolerance and excessive sweating are the next prominent symptoms. Neurological symptoms such as nervous excitability, irritability, insomnia, tremors in hand, muscle weakness are more pronounced in primary thyrotoxicosis. Eye signs such as exopthalmous, staring or protruding eyes, difficulty in

closing the eyes, chemosis are usually associated with this condition. Some females have amenorrhea.

Symptoms of secondary throtoxicosis

When a longstanding colloid gotre, SNG or MNG shows manifestations of throtoxicosis this condition is called as secondary throtoxicosis. The brunt of attack falls more on cardiovascular system than nervous system. Palpitations, ectopic beat, cardiac arythmia, dyspnoea on exertion and chest pain are prominent symptoms. Even patient may have congestive cardiac failure at later stages. Ophthalmic symptoms and nervous symptoms are mild or absent.

Symptoms of hypothyroidism

Increase of weight, inspite of poor appetite is the significant symptom. Cold intolerance, preference for warmth, dry skin puffiness of face, pouting lips, dull expressions, loss of hair, muscle fatigue, lethargy, failing memory, hoarseness of voice, constipation and oligomenorrhoea are the other symptoms of hypothyroidism.

Regarding past history patient should be questioned about anti thyroid drugs, any previous history of neck swelling, neck surgery. Patient should be asked about the intake of goitrogens such as cabbage,

kale and rape. And family history of any thyroid disorders should also be sought for.

Physical examination

- General survey
- Build and state of nutrition

In thyrotoxicosis the patient is usually thin and underweight. The patient sweats a lot with wasting of muscles and in hypothyroidism the patient is obese and overweight. In case of carcinoma of thyroid there will be signs of anaemia and cachexia.

Facies

In thyrotoxicosis one can see the facial expression of excitement, tension, nervousness or agitation with or without variable degree of exophthalmos. In hypothyroidism one can see puffy face without any expression(mask - like face).

Mental state and intelligence - Hypothyroid patients are naturally dull with low intelligence. This is more obvious in cretins.

Not only the pulse rate becomes rapid, but it becomes irregular in thyrotoxicosis. Irregularity is more of a feature of secondary thyrotoxicosis. Particularly sleeping pulse rate is a very useful index to

determine the degree of thyrotoxicosis. In case of mild thyrotoxicosis, it should be below 90, where as in case of moderate or serve thyrotoxicosis it should be between 90 to 110 and above 110 respectively. In hypothyroidism the pulse becomes slow.

Skin

The skin is moist particularly the hands in case of primary thyrotoxicosis. The clinician while feeling for the pulse should take the opportunity to touch the hand as well. Hot and moist palm is came across in primary thyrotoxicosis. Skin is dry and inelastic in myxoedema.

Local examination

Inspection

Normal thyroid gland is not obvious on inspection. It can be seen only when the thyroid gland is swollen. To render inspection easier one can follow Pizzillo's method in which the hands are placed behind the head and the patient is asked to push her head backwards against her clasped hands on the occiput. The thyroid swelling may be uniform or isolated nodules of different sizes. A thyroid swelling moves upwards on deglutition. This is due to the fact that the thyroid gland is fixed to the larynx. Such movement of the thyroid becomes greatly limited when it is fixed by inflammation or malignant infiltration.

In retrosternal goiter patient should be asked to raise both the arms over his head until they touch the ears. This position is maintained for a while. Congestion of face and distress become evident in case of retrosternal goiter due to obstrucation of the great veins at the thoracic inlet.

A thyroglossal cyst also moves upwards on deglutition. But the pathognomonic features is that it moves upwards with protrusion of the tongue.

Palpation

The thyroid gland should always be palpated with the patient's neck slightly flexed. The gland may be palpated from behind and from the front. Careful assessment of the margins of the thyroid gland is important, particularly the lower margin.

Palpation of each lobe is best carried out by Lahey's method. The examiner stands in front of the patient. To palpate the left lobe properly, the thyroid gland is pushed to the left from the right side by the left hand of the examiner. This makes the left lobe more prominent so that the examiner can palpate it thoroughly with his right hand.

Slight enlargement of the thyroid gland or presence of nodules in its substance can be appreciated by simply placing the thumb on the thyroid gland while the patient swallows. (Crile's method)

During palpation the following points should be noted:

- Whether the whole thyroid gland is enlarged or not.
- When a swelling is localized
- Mobility

To get below the thyroid gland is an important test to discard the possibility of retrosternal extension.

Pressure effect – pressure may be on the trachea or larynx, which may lead to stridor and later on dyspnoea. Pressure may be on the oesophag us which may lead to dysphagia. Pressure may be on the recurrent laryngeal nerve, which may lead to hoarseness of voice. If pressure on trachea is suspected, slight push on the lateral lobes will produce stridor(Kocher's test). This test, if positive, indicates an obstructed trachea.

Narrowing of the trachea i.e. scabbard trachea becomes quite obvious in skiagram. A malignant thyroid may engulf the carotid sheath completely and pulsation of the artery cannot be felt. Sympathetic trunk may also be affected by thyroid swelling. This will lead to Horner's syndrome.

- Enophthalmos
- Pseudoptosis
- Miosis, Anhidrosis

Palpation of cervical lymph nodes

This is extremely important particularly in malignancy of thyroid. Papillary carcinoma of thyroid is notorious for early lymphatic metastasis when the primary tumour remains quite small.

Percussion

This is employed over the manubrium sterni to exclude the presence of a retrosternal goiter.

Auscultation

In primary toxic goiter a systolic bruit may be heard over the goiter due to increased vascularity.

General examination

Eye signs

1. **Lid retraction** – This sign is caused by over-activity of the involuntary part of the levator palpebrae superioris muscle. When the upper eye lid is higher than normal and the lower eyelid is in its normal position this condition is called lid retraction.
2. **Exophthalmos** – when eyeball is pushed forwards due to increase in fat or oedema or cellular infiltration in the retro-orbital space the

eyelid are retracted and sclera becomes visible below the lower edge of the iris first followed by above the upper edge of the iris.

i. **Von Graefe's sign** – The upper eyelid lags behind the eyeball as the patient is asked to look downwards.

ii. **Joffroy's sign** – Absence of wrinkling on the forehead when the patient looks upwards with the face inclined downwards.

iii. **Stellwag's sign** – This is staring look and infrequent blinking of eyes with widening of palpebral fissure.

iv. **Moebius's sign** – This means inability or failure to converge the eyeballs.

v. **Dalrymple's sign** – This means the upper sclera is visible due to retraction of upper eyelid.

3. **Ophthalmoplegia** – there may be weakness of the ocular muscles due to oedema and cellular infiltration of these muscles.

4. **Chemosis** is caused by obstruction of the venous and lymphatic drainage of the conjunctiva by the increased retro-orbital pressure.

Tachycardia or increased pulse rate without rise of temperature is constantly present in primary toxic goiter. Sleeping pulse rate is more confirmatory in thyrotoxicosis.

Tremor of the hands is almost always present in a primary thyrrotoxic case.

Moist skin particularly of the hands and feet are quite common in primary thyrotoxic cases.

Thyroid bruit is also quite characteristic in Graves' disease (primary thyrotoxic). This is due to increased vascularity of the gland.

Secondary thyrotoxicosis auricular fibrillation is quite common. Signs of cardiac failure such as oedema of the ankles, orthopnoea, dyspnoea while walking up the stairs may be observed. Exophthalmos and tremor are usually absent.

INVESTIGATIONS OF THYROID DISORDERS [4,5,6,7,8,9,10,11,12,13]

The various investigations for diagnosing thyroid diseases can be divided as follows

1.Tests of thyroid function

2.Thyroid autoantibodies

3.Thyroid imaging

4.Cytology

Tests of Thyroid function:

The improved sensitivity and specificity of TSH assays have greatly improved laboratory measurement of thyroid function. A rational approach to thyroid testing is to determine if TSH levels are increased, decreased or normal. A normal TSH level excludes a primary

abnormality of thyroid function in rare occasions. Immune radiometric assays one of the tools used to determine the thyroid function which are very sensitive. The widespread use of TSH IRMA has rendered the TRH stimulation test outdated. The finding of an atypical TSH level should be followed by measurement of circulating thyroid hormone levels to prove the diagnosis of hyperthyroidism(suppressed TSH) or hypothyroidism(elevated TSH).T3 and T4 are highly protein bound and numerous factors can manipulate protein binding. It is useful therefore to measure free or unbound hormone levels.

For most patients the unbound T4 level is sufficient to confirm thyrotoxicosis but elevated T3 levels(T3 thyrotoxicosis) seen in 2% of individuals .Thus unbound T3 levels be required to be measured in those with suppressed TSH levels with normal unbound T4 levels. [4]

In thyroid cancer patients, Serum thyroglobulin levels is used in the follow up. After total thyroidectomy and radio-ablation it should be undetectable. Levels greater than 1-2ng/ml suggest inadequate ablation or recurrent cancer.

Thyroid auto-antibodies: Autoimmune thyroid disease is detected most easily by detecting circulating antibodies against thyroid peroxidise (TPO) and Thyroglobulin(Tg).Almost all patients with autoimmune

hypothyroidism and upto 80% of those with Graves Disease have TPO antibodies at high levels.

Thyroid Imaging:

1. **Chest and Thoracic Inlet Radiography**

Simple Radiographs of the chest and neck will demonstrate if there is any retrosternal extension of goitre or significant tracheal compression.Pulmonary metastasis might also be detectable.

2.Radiography of Neck

Plain radiographs of neck in both antero-posterior and lateral views are taken to look for-

- Position of Trachea
- Pretracheal soft tissue shadow
- Evidence of retrosternal extension
- Any compression of trachea
- Calcification of soft tissue
- Status of cervical spine

3.Indirect Laryngoscopy(IDL)

This is done preoperatively to look for vocal cord movements. Some patients will have asymptomatic paralysis of recurrent laryngeal nerves. So this examination is very important from medico-legal aspect.

4.Ultrasound Scanning [USG]

Now USG is considered as extension of the clinical examination. One of the basic investigation for thyroid swelling.

a. Differentiate benign from malignant nodule
b. The ultrasonography can demonstrate sub clinical nodularity and identify deep non-palpable thyroid nodules.
c. Size of the nodule can be measured
d. It can also differentiate solid from cystic swellings
e. Sono guided FNAC can be done
f. Identify cervical lymph nodes
g. Identify multicentricity.

Features of Benign Lesion in USG

1. Hyperchoic nodule
2. Significant cystic component
3. Peripheral egg shell like calcification
4. A sonolucent rim (halo) around the nodule
5. Well – defined nodule margin

Feature of Malignant Lesion in USG

1. Hypoechoic
2. Cystic component need not be there

3. Microcalcifications
4. No halo
5. Poorly defined margin
6. Taller than wide lesion
7. Increased central vascularity

USG Showing Normal Thyroid

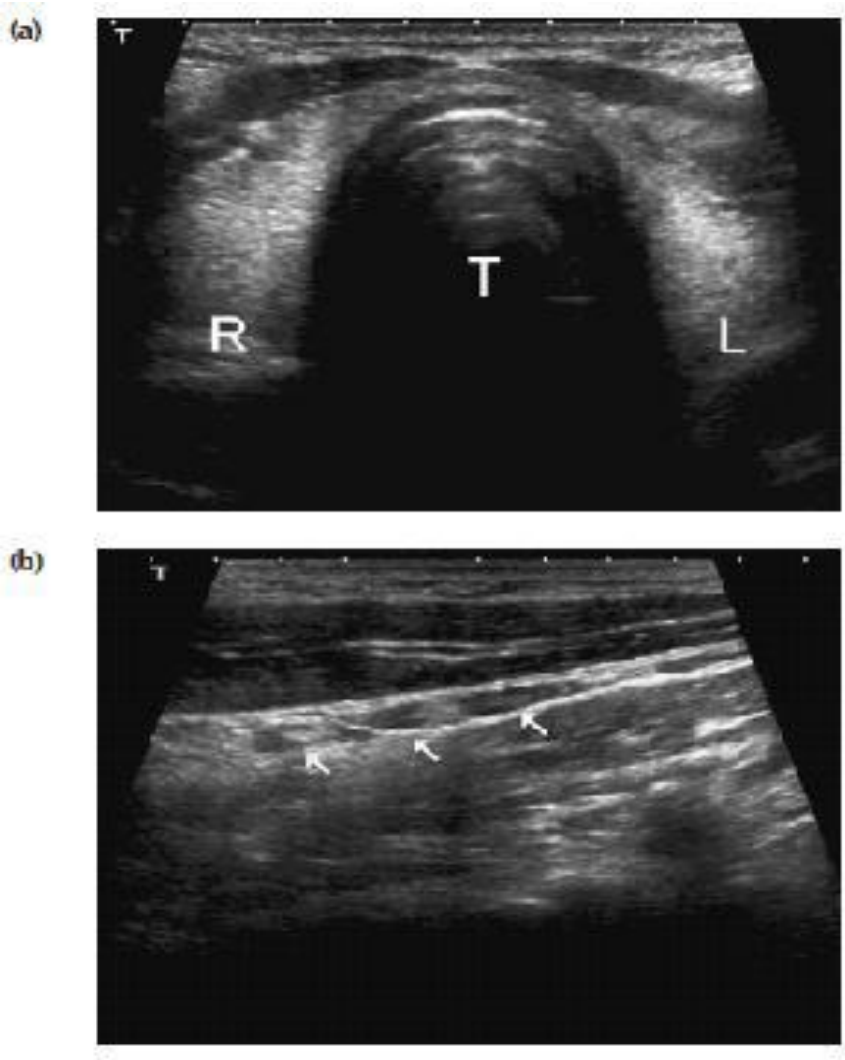

- USG Guided placement of the needle during a thyroid FNAC biopsy.

Ultrasound uses a high frequency probe in the 7.5-12MHz range. Ultrasound devices have become portable enough to allow use in the clinic and operating room. [5]

USG Showing Solid and cystic Components

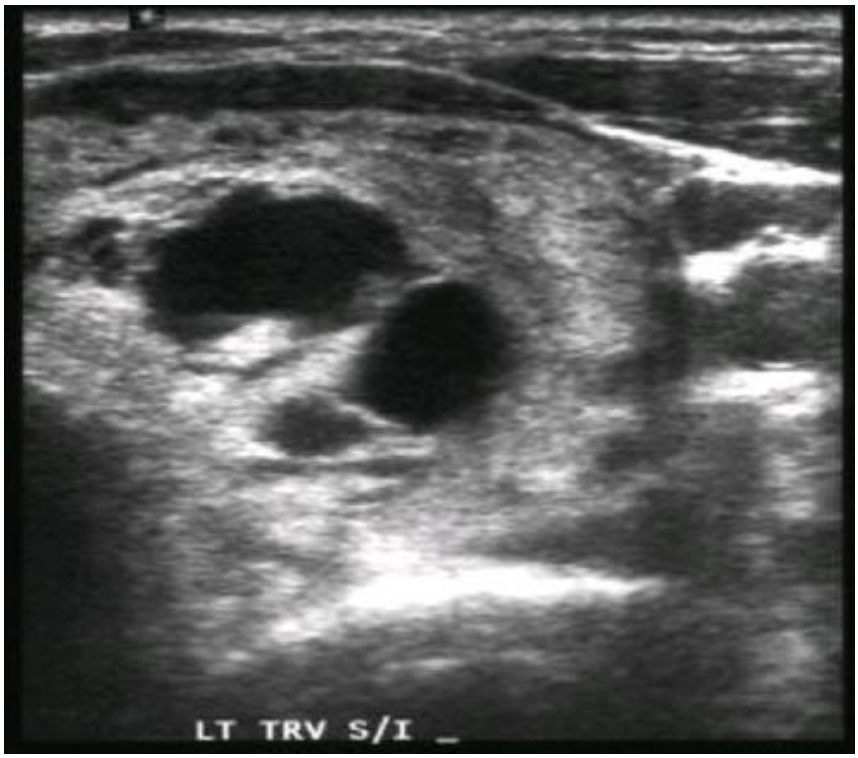

5.Radioisotope Scanning [10]

Radionuclide imaging serves to confirm the presence of the nodule within the thyroid, identifies the functional characteristics of the nodule.

The only absolute indication in thyrotoxicosis for isotope scanning is for the diagnosis of Autonomous Toxic Nodules

Toxicity with nodularity is an indication. It can identify hypofunctioning nodule(cold). Cold nodule in Graves' is likely to be malignant.

It is the only method by which one can definitely differentiate primary, secondary and toxic nodules.

Isotope scan can also differentiate hyper thyroidism from toxicosis due to other causes. (to differentiate hyperthyroid thyrotoxicosis from non- hyperthyroid thyrotoxicosis). The radioactive iodine uptake (RAIU) is increased in hyperthyroidism whereas toxicosis because of extrathyroidal causes the RAIU is decreased (eg. thyroiditis)

Other indications for isotope scan are:

1. To identify ectopic thyroid tissue.
2. To identify recurrence and metastases in thyroid carcinoma.
3. ^{99m}Tc is the isotope of choice for diagnostic purposes. It is cheap and the radiation is less than radioiodine. Twenty minutes after intravenous injection of ^{99m}Tc, scanning is done over the thyroid.
4. If radioactive iodine is used I123 is the isotope of choice for diagnostic purposes.
5. Carcinoma concentrates technetium and therefore a hot nodule need not necessarily be benign.
6. A nodule which is warm on technetium scanning and cold on radioiodine scanning is called discordant scan. This is suggestive of malignancy.

Surgery is generally required to provide a definitive diagnosis, although needle biopsies have been used in some major medical centers. [10]

Another indication for radioisotope thyroid scanning was in the treatment of thyroglossal cyst before excision to rule out the possibility of an ectopic thyroid. [11]

Pertechnetate ion is selectively concentrated in the thyroid gland, salivary glands and stomach. In normal subjects, up to 2 % of the radioactivity from intravenously injected pertechnetate-99m is accumulated by the ion-concentrating mechanism of the thyroid at 1 hr. Thirty min after administering 1 me of pertechnetate-99m intravenously, good scans of the thyroid are obtainable. [12]

Iodine123 and Iodine131 scintigraphy is also used to evaluate the functional status of the thyroid gland. Both are trapped by active follicles and organified.123I has a shorter half life(12-13hrs) and gives a quicker image and low dose of radiation(30 mrad).It is a good choice for suspecting lingual thyroid or substernal goitre.

131I has longer half life (8 days) and emits higher levels of radiation. It is the screening modality of choice for evaluation of distant metastasis.

It is generally accepted that glucose metabolism is increased, particularly in poorly differentiated carcinomas. FDG PET is therefore thought to be more effective for the detection of undifferentiated thyroid carcinoma, with a low sensitivity of 131Iwhole-body scan. [13]

6. CT and MRI

CT and MRI do not add significantly to the work up of uncomplicated thyroid nodules. Either modality may be helpful in the evaluation of local extension of advanced thyroid carcinoma. It is also appropriate for the evaluation of suspicious (or biopsy proven cancer) with palpable cervical lymph nodes. Additionally either can be used in the follow up of recurrent disease. It can also be used for large goiter with tracheal deviation to rule out substernal extension. Consideration must be given to the use of IV contrast for CT evaluation of a possible cancer. The iodine may interfere with postoperative plans for 131I scanning.

7. Fine Needle Aspiration Cytology (FNAC):

Because of the risk of neoplasia, the single most important investigation of choice is Fine Needle Aspiration Cytology (FNAC).

An adequate smear should have at least six clusters of cells each containing about 20 cells.

The overall diagnostic accuracy is about 95%

The diagnostic sensitivity of 83% and specificity of 92%

FNAC reports

a. Benign – adundant colloid and typical follicular cells
b. Malignant
c. Indeterminate – little colloid and many follicular cells or Hurthle cells (Follicular neoplasm suspicious)
d. Inadequate – Cystic lesions, degenerating adenomas.

Classification

Thy 1 – Non – diagnostic

Thy 2 – Non – neoplastic

Thy 3 – Follicular

Thy 4 – Suspicious of malignancy

Thy 5 – Malignant

In future, FNAC differentiation may be possible by the following techniques:

a. Ploidy study of the DNA material: polyploidy for benign and aneuploidy for carcinoma
b. Benign tumors are monoclonal and malignant tumors are polyclonal (monoclonal antibody MOAB 47)
c. Magnetic resonance spectroscopy
d. Thyroimmunoperoxidase estimation

Definite diagnosis by FNAC

1. Colloid nodule
2. Thyroiditis
3. Papillary carcinoma
4. Medullary carcinoma
5. Anaplastic carcinoma
6. Lymphoma

For aspiration, the neck was extended, supported by a small pillow and a 10 ml syringe with a 23 gauge needle was used. Two or three separate aspirations were made with several passes through the lesion. The aspirates were air-dried on microscope slides and stained with May-Greenwald-Giemsa stain.

FNAC can often suggest a precise diagnosis of a thyroid lesion but, from the point of view of management, the important issue is whether the findings suggest cancer. The possibility of the false negative has always to be borne in mind for it has averaged about 5-14% in most studies. If the tumour contains much colloid, which may occasionally happen in follicular cancers, then on cytological evidence alone it may be regarded as a colloid nodule.

Its discriminating value is relatively high compared with the scanning methods and it is much less consuming of time and expensive

equipment. Moreover if the nodule proves to be a simple cyst, the diagnostic procedure can be combined with that of treatment, namely cyst aspiration, and, if necessary, sclerosant injection which is usually curative. [6]

Medical management of thyroid disorders

Hypothyroidism – replacement dose 100 microgram

(TSH)Suppression dose 300 microgram

Hyperthyroidism

1. Propylthiouracil 100 to 200 mg TDS

Inhibitis thyroid peroxidase, and peripheral conversion

Can be given in the pregnancy

2. Carbimazole 10 to 20 mg thrice daily

   Active component methimazole

   Most effective drug

3. Propranalol 20 to 40 mg

   Inhibit peripheral conversion

4.RAI

Used in ablation of remnant thyroid tissue

Contra indicated in pregnancy, younger individuals

Approach to PT with Thyroid Nodule

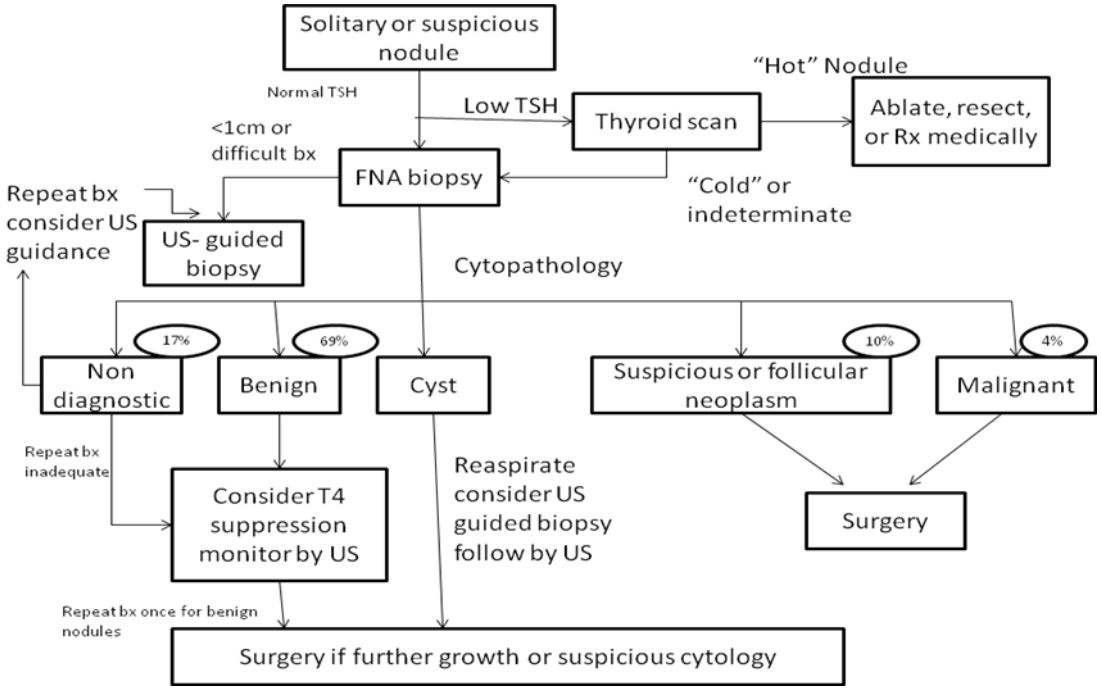

ElectroSurgery, Energy Sources:

Electrosurgery means the cutting and coagulation of tissue using high-frequency electrical current[15]. Electro surgery used by surgeons must be well known about its physics and mechanism of action and also prevention and management of potential complications,

However, the current needs to exit the patient to complete the cycle, and will invariably choose the path of lowest resistance in seeking to return to an electron reservoir, such as the ground. Now, most operating rooms use an isolated-generator system with a dispersive electrode pad that is attached to the patient in relative proximity to the surgical site. This creates a set path for the current to exit the patient. To minimizing

the risk of skin burns The large surface area of the dispersion pad results in low current density at the attachment site. However, if the dispersion pad becomes loose-fitting with only partial skin attachment, the current density increases which leads to potential risk of skin burns.

The pad should be applied to well- perfused, dry, hairless skin over a large muscle and away from bone and metal for maximum safety. Variables such as keloids, metal, hair, and poor perfusion distal to a tourniquet will increase impedance, which can result in burns. Various ESUs have sensors that assess pad-to-skin contact and current density; these instruments sound an alarm and shut down the current if contact is poor.

Older ground referenced systems had the potential for the current to take alternative routes to exit the patient, such as through an intravenous fluid pole lying up against the patient's arm and causing a burn at this site. Other contact points may include EKG leads, stirrups , towel clips, and temperature probes.

- Bipolar surgery – In bipolar surgery, the electrical current created in the ESU is limited to the tissue between the two electrodes of the surgical instrument. The electrodes may be types of forceps, blades of scissors, or graspers. No need for separate return electrode (ie, dispersion pad) for the current to exit.

Cutting and coagulation currents — The surgeon chooses the output setting for the ESU. The main settings are 'cutting' and 'coagulation':

- Cutting mode – In the cutting mode, the ESU generates a continuous (or unmodulated), low-voltage current, concentrating the energy on a small area (high current density). The cutting mode results in more rapid tissue heating than the coagulation mode. If tissue is heated rapidly, the oscillation of the AC current causes intense vibration and heat within the cells, which leads them to explode and form smoke (plume). This is called vaporization, and is the mechanism whereby tissue is cut [19]. To cut tissue, the tip of the electrode is held very near to the tissue, but not in direct contact, to concentrate current at the tip.
- Coagulation mode – In the coagulation mode, the ESU generates an interrupted (or modulated), high-voltage current, dispersed over a large surface area (low current density). As an example, the current may flow about 6 percent of the time and be off 94 percent of the time, and these proportions can be adjusted. The modulated current allows the tissue to cool slightly, so tissue heating is slower than with the cutting mode. This results in coagulation, which is a dehydration effect (loss of cellular fluid and protein denaturation) rather than vaporization. Dehydration is not as effective as

vaporization for cutting tissue, but is ideal for sealing blood vessels. However, the modulated current requires a high power setting (higher voltage) to achieve dehydration, which causes more tissue damage and more thermal spread, increasing the risk of potential complications. For this reason, most authorities recommend that the cut setting be used most of the time, and reserve the coagulation setting for select circumstances, such as in a vascular environment where coagulation is important, and when dealing with tissue with poor conductivity, such as fatty tissue and dry tissue [19]. In these situations, the higher voltage on the coagulation setting provides better tissue penetration.

In addition, several "blend" options are available, combining various proportions of the two main modalities. These blends allow the enhancement of the ability of cutting currents to coagulate small bleeders during dissection, and coagulation currents to dissect tissue during hemostasis.

Desiccation, vaporization, and fulguration — As electrical current comes in contact with tissue, heat is created because of the inherent resistance of tissue. Heat causes desiccation, vaporization, or fulguration, depending upon the ESU setting and the amount of contact between the tissue and surgical instrument.

Desiccation can be produced using either the cutting or coagulation mode. It is produced by direct contact of the instrument and the tissue. Slow, superficial tissue heating results in protein denaturation, which causes the tissue to appear white. At higher temperatures, both dehydration and protein denaturation occur, resulting in desiccation. Tissue that is completely desiccated has very high resistance and does not conduct electrical current. Thus, loss of conductivity on the ESU's flow meter is an indication of complete desiccation, which is useful information during tubal sterilization or ablation of endometriosis implants. Continued application of heat with no or minimal tissue penetration results in superficial carbonization (char).

Vaporization and fulguration are noncontact methods of electrosurgery. To cut tissue, the tip of the electrode is held at the tissue surface; the high heat generated by the current vaporizes tissue immediately adjacent to the tip of the electrode without the need to press the electrode against the tissue. Since the cells "explode," no char is produced.

The electrode is held a bit further away when fulgurating tissue; in this situation, electrical current (sparks) jumps or arcs between the electrode tip and the nearby tissue, which causes it to char. Fulguration is used to control bleeding over a wide area. Fulguration is a particularly

useful technique to control diffuse bleeding from raw surfaces of solid vascular organs, such as the liver bed, following cholecystectomy.

Time, power, tissue, and electrode — The shape and size of electrode, the time it is in contact with tissue (dwell time), the type of tissue, and the power setting of the ESU are other variables that impact electrosurgical results. The power output of the ESU is usually displayed in Watts (Watt = voltage times current). Generally, a surgeon should use the lowest possible power setting to effectively complete a procedure. A common initial setting for cutting and coagulation is 40 Watts, although there is wide individual surgeon preference and some surgeons have reported excellent results using a much higher initial setting for cutting (70 to 90 Watts) [20].

Thermal spread — Application of electrosurgery with different electrosurgical devices results in varying degrees of thermal spread. Thermal spread can cause tissue necrosis at the site of application, which may result in delayed healing and postoperative recovery [21]. Thermal spread can also cause injury to adjacent organs, eg, ureter, bladder, or bowel. It is therefore important for surgeons to understand the potential thermal spread from specific electrosurgical devices.

One comparative study used monopolar and bipolar electrocautery, the Harmonic® Scalpel and LigaSure on porcine muscle [22]. The degree of lateral thermal spread diverse with power setting, instrument type, and application time. Monopolar diathermy resulted in the highest temperatures and the maximum degree of thermal spread in tissues.

The expected thermal spread from several devices that are commonly used in surgery are:

- Traditional bipolar device – 2 to 22 mm [23-25]
- Ultrasonic cutting and coagulation device – 0 to 3 mm with the Harmonic Scalpel [23,24,26,27]; however, this is dependent on application time and setting, and thermal spread of up to 25 mm being reported in an animal model (with continuous ultrasonic dissection for 10 to 15 seconds at the highest level) [28]
- Vessel sealing devices
  - 1.1 mm for the EnSeal Tissue Sealing and Hemostasis System [29]
  - 1.8 mm with the 10 mm LigaSure device to 4.4 mm with the 5 mm LigaSure device [30]
  - 6.3 mm with the Gyrus Plasma Trissector

One comparative study found less thermal spread with the EnSeal® Tissue Sealing and Hemostasis System compared with the

Gyrus Plasma Trissector, LigaSure, and SonoSurg [29]. However, another study found that the Harmonic Scalpel® was associated with less thermal spread than EnSeal® Tissue Sealing and Hemostasis System, LigaSure, or Gyrus Plasma Trissector [31].

High-quality comparative studies are needed to evaluate the relative thermal damage caused by each device.

Smoke plume — The smoke plume generated by electrosurgical destruction of tissue contains potentially toxic substances. In high concentrations, these substances can irritate the eyes and respiratory tract of any individuals in the operating room, and can even transmit viruses. For this reason, smoke should be captured and evacuated using suction and smoke evacuation devices.

CLINICAL USE — It is important that the surgeon be aware of the principles discussed above, as different clinical situations require different usage of electrosurgical instruments.

Monopolar electrosurgery — Either the cutting (low voltage) or coagulation (high voltage) mode may be used to achieve the desired tissue effect. The cut mode is preferred when thermal spread is undesirable, such as in close proximity to the ureter, bowel or other vital structures. It might also be prudent to use the cut mode during desiccation

of a deep endometriosis lesion since the electrical current penetrates deeper into the tissue during the cut mode. Due to higher voltage, the coagulation mode achieves better penetration through high-resistance areas, such as fatty tissue and scar tissue, and is also more applicable when fulgurating a large surface area with superficial bleeders, as might be encountered following ovarian cystectomy or laparoscopic cholecystectomy.

Bipolar electrosurgery — Bipolar electrosurgery is generally performed at low voltage (cutting mode) since tissue resistence is comparatively low due to the proximity of the two electrodes. For this reason, these instruments are less effective for cutting tissue since adequate vaporization is difficult to achieve. Attempts to cut tissue can result in excessive dehydration, rather than vaporization, causing the tissue to char and stick to the surgical instrument. One way to avoid this and to obtain better tissue penetration of energy is to apply the energy in a pulsatile fashion and to let go of the tissue just before stopping the flow of current.

Bipolar electrosurgery is ideal when dealing with vascular areas or 3 to 7 mm blood vessels, such as the uterine artery. Effective hemostasis can be achieved by coapting and thermally welding the blood vessels. In contrast, monopolar energy disperses the electrical current in the intravascular fluid, causing inadequate tissue damage at the vessel lumen

[32]. This creates a potentially dangerous situation, since the surgeon might think the vessel is sealed judging from its outer appearance, only to encounter brisk bleeding once the vessel is cut.

COMPLICATIONS — Electrosurgery related complications are relatively common, occurring in 2 to 5 per 1000 procedures [33,34]. The complication rate appears to be related to surgical experience, reaching a plateau after approximately 60 procedures [17].

One of the most serious complications is injury to the small or large bowel, which can have fatal consequences, especially if undetected. Symptoms of bowel perforation secondary to thermal injury usually appear 4 to 10 days postoperatively, depending upon the severity of the coagulation necrosis. These injuries have distinct histopathological findings, which distinguish them from other causes of bowel perforation.

As discussed above, a higher power setting (higher voltage) causes more tissue damage and more thermal spread, increasing the risk of potential complications. Surgeons need to keep this in mind when working close to structures, such as the bowel or ureter, which are prone to serious complications if subjected to thermal injury. Whitening of tissue surrounding the tip of the electrosurgical instrument suggests thermal spread. Looking at the bubbles that form during heating of tissue

can help guide the application of energy. These bubbles represent water vapor; thus, the tissue is dry (desiccated) when the bubbles disappear, so it is time to stop the application of electrosurgical energy.

Severe burns can occur if the dispersive electrode pad becomes partially detached from the patient as a result of increased current density on the smaller surface area of the skin. This problem can be averted with the use of a return electrode monitoring system (see below).

Patients with electrical implants require special precautions, especially when using monopolar devices. Although many of these implants are designed to be shielded from electrical currents in the environment, it is prudent to use bipolar devices and check the function of the electrical implants during and after surgery.

The surgeon may become a recipient of electrical current through his/her surgical gloves if they have a hole, or by capacitive coupling.

Certain electrosurgical complications are more prevalent during laparoscopic surgery.

- Direct coupling – Direct coupling results from inadvertent contact of two noninsulated instruments (such as a metal trocar and a metal grasper). Electrical current flows from the primary

to the secondary instrument, which acts as a second conductor. This can lead to severe injury if the second conductor is in contact with bowel or other sensitive structures [15]. In laparoscopic cholecystectomy, monopolar electrosurgical energy is associated with delayed, remote common bile duct injuries due to direct coupling [35].

- Capacitive coupling – Capacitive coupling is another threat during laparoscopic surgery, and has also been reported to occur during hysteroscopic monopolar surgery [36]. A capacitor is defined as two nearby conductors separated by a nonconducting medium. A prime example of a capacitor would be monopolar scissors with an insulation layer placed through a metal cannula. The alternating current flowing through the scissors induces unintended stray current in any conductor in close proximity with the monopolar instrument. The magnitude of the current induced depends on the proximity and insulation of the two conductors and the amount and duration of voltage used [37]. Hybrid trocar sleeves are prone to induce capacitive coupling, since the plastic locking anchor prevents the capacitive current from dissipating in the abdominal wall, resulting in electrical current passing through nearby structures, such as bowel [19].

- Insulation failure – Insulation failure results from breakdown of the insulation covering the shaft of the active electrode. This can happen during the sterilization process or during the surgical procedure. These defects are not rare [38]. Up to 20 percent of reusable laparoscopic instruments may have an insulation failure due to defects developed during handling and cleaning. The distal one-third of the laparoscopic instrument is the most common site of insulation failure. Insulation failure can also occur from inappropriate repeated use of disposable equipment.

INTERVENTIONS TO ENHANCE SAFETY — Several safety mechanisms have been developed to minimize the potential risks of electrosurgery. Nevertheless, no safety mechanism will replace sound surgical judgment and proper use of surgical instruments.

Return electrode monitoring system — A return electrode monitoring system monitors the resistance between the patient's body and the dispersion pad, interrupting the power in case the contact area and/or the conductivity are reduced [15]. This helps to prevent patient injury at the site of the dispersion pad.

Active electrode monitoring — Active electrode monitoring prevents electrosurgical burns due to stray currents by adding a second layer of insulation and a conductive sheath to the surgical instrument. The system

continuously monitors stray currents and automatically shuts off the ESU if the amount or character of the stray currents becomes abnormal [39]. This is the only safety tool that effectively prevents electrical burns from capacitive coupling and insulation failure that occur during the surgical procedure.

Computer-controlled tissue feedback systems — We do not suggest the use of an ammeter as a safety tool, since this can result in overzealous use of energy and potential complications [32]. However, computer-controlled tissue feedback systems can be useful safety tools, since they can automatically sense tissue resistance and adjust the output voltage accordingly [33]. This can result in decreased use of energy and decreased thermal spread [40].

Visual inspection — Monopolar instruments can be visually inspected for insulation failure prior to surgery. However, microscopic insulation defects can be missed, and, because of high current density, can cause severe burns. Visual inspection also will not prevent insulation failure during surgery, and will not prevent capacitive coupling from occurring.

Testing wands — Special testing wands that can detect even microscopic insulation defects have been developed; however, they do not prevent

insulation failure from occurring during surgery and will not prevent capacitive coupling.

Body piercing — Although there have been no reported electrosurgical injuries in the literature in relation to body piercing, the general recommendation is to remove umbilical and labial body piercing prior to surgery, as well as other metal objects that are close to the surgical site [41]. Theoretically, faulty instrument insulation can allow current to go from the surgical instrument to the metal object causing a skin burn. It is not necessary to remove piercing or other metal jewelry distant from the operative site, since these objects are too far away from the active electrode to receive substantial electrical current.

PREVENTION OF ELECTROSURGICAL INJURIES — To avoid the electrosurgical injuries discussed above, we suggest the following [15,16,39]:

Monopolar surgery

- Use Power setting likely as lowest
- Use a low voltage waveform (cut)
- Use concise, discontinuous activation
- Open circuit should not be activated

- Do not activate in close proximity or direct contact with another instrument
- Bipolar electrosurgery can be used where it appropriate
- Use an all-metal or all-plastic cannula system (not metal-plastic hybrids)
- Use a return electrode monitoring system
- Use active electrode monitoring to eliminate concerns regarding insulation failure and capacitive coupling during laparoscopic electrosurgical procedures

If the desired tissue effect is not achieved at usual power settings, the surgeon should check all of the equipment, including removing excessive char on the electrode, before increasing the power setting to high levels.

Bipolar surgery

- Current should be terminated at the end of vapor phase
- Current should be applied in pulsatile fashion
- Avoid the use of an in-line ammeter
- Alternate between desiccation and incision

Prevention of electromagnetic interference — If the planned procedure is likely to interfere with the function of the pacemaker in an individual

who is highly dependent upon the device, alternative methods of cautery and hemostasis can be used including [42]:

- Bipolar electrosurgery – Bipolar electrosurgery minimizes the electrical field affecting the pacing system by limiting current between the tips of the forceps.
- Ultrasonic dissector – For tissue dissection and hemostasis of moderate size vessels, the ultrasonic dissector is an alternative to electrosurgery.
- Topical hemostatic agents – A variety of topical agents can be used to effect hemostasis of small vessels, minimizing the use of electrosurgery.

EMERGING TECHNOLOGY — Several developments in electrosurgical technology have been emerging in the last few years and include:

Bipolar vessel sealing devices — The bipolar vessel sealing system (LigaSure) applies a precise amount of bipolar energy and pressure to fuse collagen and elastin within the vessel walls. This results in a permanent seal that can withstand three times the normal systolic pressure, and seals vessels up to 7 mm [46]. The sealing is achieved with minimal sticking and charring; thermal spread to adjacent tissues is

approximately 2 mm [26]. The generator for this device uses a feedback-controlled response system to ensure adequate tissue sealing [46]. The LigaSure system has been used successfully in a variety of procedures, such as vaginal hysterectomy [47] and laparoscopic oncology surgery [48]. The LigaSure device has been used effectively in laparoscopic colectomy, hepatectomy, and even splenectomy. The main disadvantage in using this system over standard bipolar technology is cost, especially since these devices are disposable. Non disposable devices that use similar technology have been introduced with promising initial results [49].

PlasmaKinetic tissue management system — Another system employing advanced bipolar technology is the PlasmaKinetic tissue management system. This system delivers pulsed bipolar energy through the instrument to the tissue, allowing intermittent tissue cooling, which limits lateral thermal spread and tissue sticking [40]. The system has an instrument identification feature that automatically detects the optimal settings for the specific instrument, as well as an impedance monitor with visual and audible tissue impedance indicators. The system has two different modes, the vapor-pulse coagulation mode and the PlasmaKinetic tissue-cutting mode. In the vapor-pulse mode, high energy is delivered to grasped tissue, creating vapor zones. The current then travels around the

high-impedance vapor zones, following the path of least resistance. The vapor zones subsequently collapse, and with each new energy pulse more and more tissue between the instrument jaws is coagulated, ultimately resulting in uniform coagulation of tissue. The PlasmaKinetic tissue-cutting mode allows the surgeon to cut tissue using bipolar energy, which allows for simultaneous cutting and coagulation of tissue [50].

EnSeal — This system provides vessel sealing by combining a compression mechanism with thermal energy control in a bipolar sealing device. The instrument is capable of achieving seal strengths up to seven times the normal systolic pressures on vessels up to 7 mm with a typical thermal spread of approximately 1 mm. Although there have been few publications about this device in the medical literature [51,52], it is already in widespread use among surgeons.

The compression mechanism applies uniform pressure along the full length of the instrument jaw, achieving compression forces similar to those of a linear stapler. Compression is combined with controlled energy delivery utilizing NanoPolar™ thermostats to reach collagen denaturation temperatures in seconds, which are maintained at approximately 100ºC throughout the power delivery cycle. The device also has a cutting mechanism to allow one-step sealing and transection of vessels and soft tissues.

ALTERNATIVE ENERGY SOURCES

Two important alternative energy sources are, the harmonic scalpel and lasers, will be discussed here.

Ultrasonic cutting and coagulating device

Hemostatic Principles in Relation to Active Surgical Temperatures

Creation of heat inside a cell will increase intracellular temperature with Regardless of the mechanism. 40°C is the threshold temperature which cell can tolerate without significant cell damage. Cellular processes terminate and enzymatic activity at temperatures 50°C which ceases in a reversible fashion dependent on the duration of heating. There is irreversible cell damage (denaturation) can occur at temperatures exceeds 50°C. When the denaturation occurs the tissue will blanch and proteins disorganize to create a coagulum that seals vessels. We all know boiling point of water is 100°C which implies cell water also which leads to cell water changes from the liquid to vapor phase, then cell wall ruptures, and tissue is dessicated.

When the temperature reaches 200°C the dehydration of tissue will leads to carbonization (turn black) of tissue and no further current can go through it. As the tissue burns causes Eschar formation. Electro surgery and laser energy denature protein to form a Hemostatic coagulum that

tamponades and completely seals vessels. The mechanism of action of Electric Current(electrocautery) or light (laser) is used relocate electrons or photons to tissue that results in excitation of the electron orbitals of molecules. When the electrons come back to their resting state, heat is generated which causes protein denaturation to form coagulum.

The ultrasonic cutting and coagulating surgical device (eg, Harmonic Scalpel®) converts ultrasonic energy into mechanical energy at the functional end of the instrument. A piezoelectric crystal in the handpiece generates vibration at the tip of the active e blade at 55,500 times per second over a variable excursion of 50 to 100 micrometers. This results in rupture of hydrogen bonds and produces heat, which leads to denaturation of proteins and, eventually, separation of tissue. These effects are reached at tissue temperatures of 60 to 80ºC, resulting in coagulum formation without the desiccation and charring caused by temperatures of 80ºC and higher associated with traditional electrosurgical methods.

The advantages of this technology include minimal thermal spread, decreased tissue charring and smoke formation when compared with traditional electrosurgical instruments, and no risk of electrical injury due

to the absence of electrical current within the patient [55]. It is also a versatile instrument, allowing the surgeon to dissect, cut, and coagulate using one instrument.

The main disadvantages are: the limited ability to coagulate vessels larger than 3 to 5 mm [56], increased cost of disposable instruments, potential for extensive thermal spread at high energy levels (level 5) for more than five seconds [28], and the user-dependent nature of the instrument. The surgeon has to be able to modify surgical technique when using this instrument, depending on the tissue type and the wanted effect.

The instrument has five levels, with most generators being preset to use level 3 for cutting and level 5 for coagulation. The difference between level settings is the blade excursion length, with longer excursion on higher levels. When the blade travels longer distances with each vibration, more heat is generated and the mechanical effect is more pronounced, resulting in faster separation of tissue and decreased coagulation ability. The amount of tissue tension is also of crucial importance, and inexperienced surgeons can develop an initial aversion to using this instrument, having placed too much tension on a vascular pedicle, allowing premature tissue separation and bleeding.

Laser

Light Amplification and Stimulated Emission of Radiation (LASER) is a commonly used alternative to electrosurgery, and offers a precise application of energy without the inherent risks of lateral tissue damage and stray current associated with standard electrosurgery. Laser energy is generated when electrons jump from higher to lower energy levels during their circuits around the nucleus. The energy created induces molecular vibration and thermal energy upon contact with the target tissue.

The laser consists of an energy source, a gating/focusing mechanism and radiating medium. The type of medium (as an example, carbon dioxide [CO_2], argon, potassium-titanium-phosphate [KTP], neodymium:yttrium aluminum garnet [NdYAG]) determines the wavelength emitted [57]. The CO_2 laser passes from the generator through a series of mirrors to the target tissue, allowing the surgeon to change the spot size for a desired effect. The argon, KTP and NdYAG lasers use quartz fibers for delivery of the beam [58].

Although lasers are widely used in ophthalmologic and dermatologic surgery, their popularity in general and gynecologic surgery may have declined somewhat [59], possibly due to the advent of

alternative energy sources. Some useful applications of laser energy in gynecologic surgery include cervical conization, laparoscopic excision of endometriosis, and treatment of vulvar intraepithelial neoplasia [59,60].

OPERATIVE SURGERY OF THYROID GLAND[14]

PREOPERATIVE PREPARATION:

Informed consent

As with any operation, the surgeon should have a thorough discussion with the patient about the indications, alternate treatment options, and potential complications of thyroidectomy. Complications for thyroid lobectomy include injury to the recurrent laryngeal nerve, resulting in a hoarse voice, and external branch of the superior laryngeal nerve, leading to an inability to reach the high octaves when singing.

The parathyroid glands could also be inadvertently injured. This does not pose a problem with a thyroid lobectomy (since the contralateral two parathyroids would be sufficient), but increases the risk of hypoparathyroidism should future thyroid or parathyroid surgery be required since the remaining parathyroid glands would be at risk.

Postoperative bleeding and subsequent hematoma formation is a potential life threatening complication that must be carefully monitored during the postoperative period. Wound infections are uncommon. The

most common wound complication is seroma formation that usually resolves spontaneously.

Patients should be aware that after total or near-total thyroidectomy they will be required to take lifelong thyroid hormone replacement. When patients are stratified into three groups based on their preoperative TSH measurement (<1.5, 1.51 to 2.5, and >2.51 μIU/mL), the rate of hypothyroidism after thyroid lobectomy increases signifcantly at each level .Thus, preoperative TSH levels can be used to predict the likelihood of postoperative hypothyroidism.

Preoperative testing:

In all patients undergoing thyroid surgery, to check the preoperative calcium and parathyroid hormone level to rule out hyperparathyroidism, and to obtain a baseline value for comparison. In patients who are diagnosed with hyperparathyroidism, to perform parathyroidectomy at the time of thyroidectomy. If the patient has a hoarse voice preoperatively or if has had a previous operation that placed the vagus or recurrent laryngeal nerve at risk, he or she should have direct or indirect laryngoscopy preoperatively to assess the status of the recurrent laryngeal nerves. A paralyzed nerve may alter operative plans and should definitely be discussed when obtaining informed consent. A

procedure planned on the side contra lateral to a nerve injury risks bilateral nerve injury and the need for tracheostomy.

Perioperative considerations:

Patients should urinate immediately preoperatively so that there is no need for a Foley catheter. As thyroidectomy is classified as a “clean” operative procedure, prophylactic antibiotics are not required unless the patient has a special medical condition warranting their administration. Compression stockings and sequential compression devices are used selectively for deep vein thrombosis (DVT) prophylaxis.

SURGICAL TECHNIQUE:

Definition of terms: [76]

- Lobectomy is defined as the complete removal of one lobe without disturbing the capsule and isthmus preservation.
- Hemithyroidectomy means that removal of one lobe with its capsule and isthmus.
- Total thyroidectomy means removal of Rt and Lt lobe with its isthmus
- Subtotal thyroidectomy is defined as removing thyroid gland leaving 4 gram of tissue on either side of the thyroid gland.
- Near-total thyroidectomy is defined as removing thyroid gland leaving behind 2 gram of thyroid tissue on the whole.

General Principles:

Following principles apply to all thyroid surgeries.

- Good exposure of the gland.
- Proper identification of anatomic structures.
- Bleeding to be kept to minimum.
- Diathermy (even bi-polar) to be avoided in the area of laryngeal nerves.

Technical aspects

Thyroid lobectomy-

Following the induction of general anaesthesia, the patient remains in the supine position, arms straight and tucked at their sides, and generous padding is placed at the elbows to prevent nerve injury. The patient's neck is midline and extended. This neck extension is performed with extreme caution and with the assistance of the anaesthesia team to ensure that the endotracheal tube is secured and that the cervical spine is not overextended or suspended. Preoperative assessment should include asking the patient to fully extend his or her neck, so that the person positioning the patient knows the level of natural neck extension.

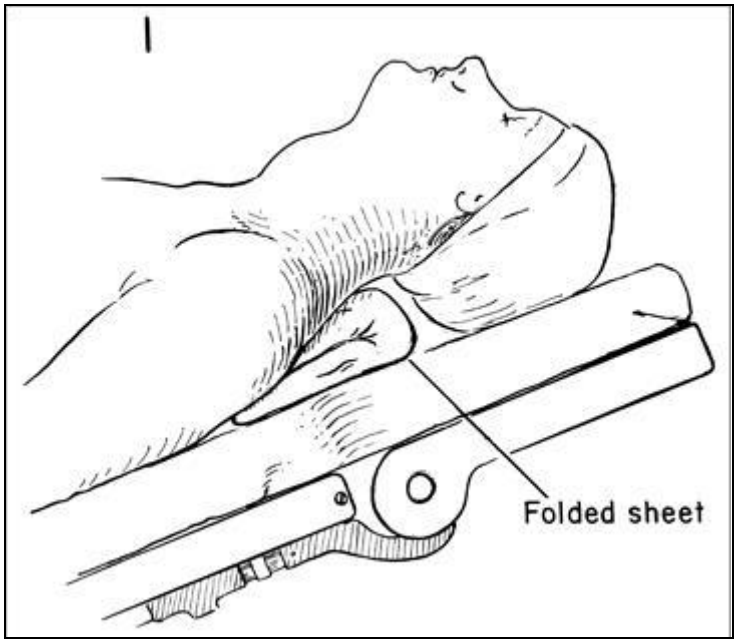

Increased postoperative pain and a slight risk of spinal cord damage are due to hyperextension of the neck . Perfect alignment of the head and body must be ensured to prevent incorrect placement of the cervical incision. The isthmus of the thyroid overlies the second and third tracheal rings just caudal to the cricoid cartilage appropriate positioning of neck and shoulder. A deflated IV bag is placed under the patient's shoulders to extend the neck and support the shoulders and lower cervical spine. The bag is then inflated to produce the appropriate amount of neck extension. The head ring will give good support io head . A headlight facilitates lighting and exposure through the limited incisions. During the operation, the table is placed in a Trendelenburg position to decrease the cervical venous pressure.

The location of the cricoid cartilage is made out by palpation. The skin incision is placed in a skin crease approximately 2cm above the suprasternal notch and 1 cm below the cricoids cartilage. The orientation of the incision should be along the lines of Langer, since crossing the normal skin lines may lead to more prominent scarring. It is of supreme importance to place the incision in a neck crease whenever possible, as neck creases have the least amount of tension. An incision made too below will result in prominent scar formation, and then dissection of the superior pole is very difficult, or per-haps missing the thyroid entirely. Incisions made too high can be cosmetically unpleasant and will make it difficult to remove lymph nodes in the superior mediastinum if indicated.

The skin incision should be made with a deliberate sweep of the scalpel, dividing the skin and subcutaneous tissue simultaneously. Hemostasis is achieved with electrocautery. The incision is deepened to the areolar tissue plane just deep to the platysma muscle where an avascular plane is reached. Once the incision is made and deepened through the platysma, the superior and inferior subplatysmal planes are developed. Using two Allis clamps, the superior edge of the platysma muscle or dermis is grasped and placed under tension . This permits vertical retraction of the flap while countertraction with the surgeon's

finger or Kitner exposes a natural bloodless plane. Ideally, dissection should proceed within the relatively avascular plane between the platysma, muscle fibres and the anterior jugular veins. Utilizing a combination of blunt and sharp dissection within this plane alternatively. For raising the skin flap electrocautery is acceptable. The flap raised above upto thyroid cartilage and below upto suprasternal notch. Don't go beyond the suprasternal notch due to inadverdent injury to communicating anterior jugular veins.

Care should be taken to not buttonhole injury to the retracted skin and to avoid the anterior jugular veins, which should remain on the anterior surface of the sternothyroid muscle. The anterior jugular veins symmetrically flank the midline raphe of the neck. Special care must be taken to avoid injury to these veins, as active bleeding and danger of air embolus have been reported with openings made into the anterior jugular vein. The skin flaps are held apart with a help of suture or by self retaining Sippel or spring retractor.

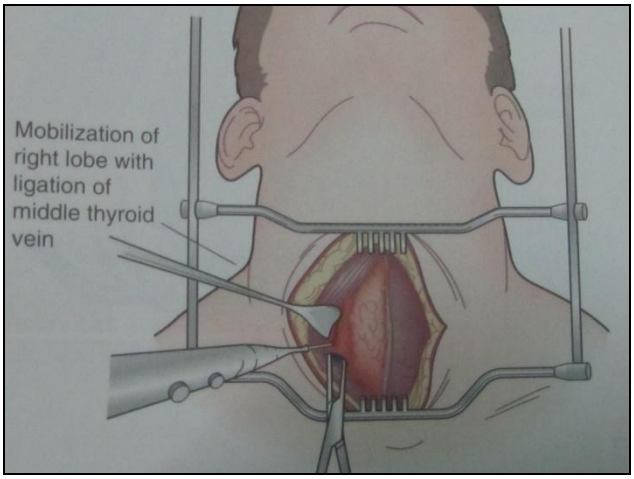

The investing layer of deep fascia now exposed. The deep fascia now opened vertically by scissors or with electrocautery superiorly upto thyroid notch and interiorly upto suprasternal notch. The strap muscles are separated away from the mid line by using blend dissection or with cautery. Now the thyroid with intact capsule hold by babcocks forceps and the strap muscles are dissected away. When need to transect strap muscles the transaction done at superior level to prevent injury to Ansa cervicalis which supplies the strap muscles

.

There are frequently crossing veins at both the superior and inferior aspects of the midline and care must be taken to avoid bleeding. The ipsilateral strap muscles are then grasped with a Babcock clamp and gently dissected of the thyroid capsule with electrocautery and blunt dissection with a Kitner or a teardrop suction device. This avascular plane between the strap muscles and the thyroid gland can be bluntly dissected

until the internal jugular vein is identified. Development of the correct cleavage plane will permit lateral mobilization of the sternohyoid and sternothyroid muscles. This is only performed on the side ipsilateral to the lobe to be excised.

Raised Subplatysmal flap

Once the thyroid lobe is exposed, the initial step is to divide the superior pole vessels to mobilize the upper lobe. The superior pole vessels are then dissected free laterally. Blunt dissection is employed to sweep the areolar tissue and remaining strap muscle fibers from the lateral superior thyroid pole. This pole is then separated from the cricothyroid muscle .Extreme care is taken to keep all medial dissection close to the thyroid lobe so as to not place the external branch of the superior laryngeal nerve at risk. This nerve can lie on the lateral surface of the cricothyroid muscle, in close proximity to the superior pole blood vessels.

As the superior thyroid lobe is mobilized, care must be taken to avoid injuring the underlying superior parathyroid gland. After mobilization and rotation of the upper lobe medially, the remaining thyroid lobe is then mobilized from lateral to medial. To achieve exposure, the gland is retracted anteriorly and medially with the surgeon's index finger and the strap muscles are held laterally with a retractor. Blunt dissection clears areolar tissue from the lateral aspect of the thyroid lobe. The middle thyroid vein is divided between clamps and tied with 2-0 silk sutures.

This dissection permits full medial rotation of the thyroid lobe. With the lateral and superior aspect of the thyroid dissected free, the thyroid can now be mobilized medially and anteriorly, out of the operative wound. The thyroid lobe is then retracted in this antero-medial position for the remainder of the procedure, and is best held under slight tension with the surgeon's index finger covered with a sponge. With this manoeuvre, the recurrent laryngeal nerve can now be identified, as can the parathyroid glands.

About 85% of the parathyroid glands are found within 1 cm of where the recurrent laryngeal nerve crosses the inferior thyroid artery, with the superior parathyroid gland located posterior to the nerve and the inferior gland located anterior to the nerve .The superior parathyroid

gland is more likely to be in direct contact with the thyroid capsule posteriorly (near the tubercle of Zuckerkandl at the level of the cricoid cartilage), and can be identified once the thyroid is retracted medially. After careful dissection to create a plane between the thyroid capsule and superior parathyroid gland, blunt dissection with a Kitner can push the parathyroid back on a broad pedicle, safely away from the operative field. Surgical clips can mark the parathyroid glands for future identification and provide hemostasis with minimal manipulation of the gland's blood supply.

The recurrent laryngeal nerve should be always identified during the lobectomy. It should run directly medial to the superior parathyroid, and can be visualized after pushing the superior parathyroid gland laterally. The right recurrent nerve travels laterally in the lower neck and then travels obliquely toward the midline at an angle approximately 30 degrees to the tracheoesophageal groove. During this course, it can pass behind, between, or anterior to the main branches of the inferior thyroid artery. The left nerve, on the other hand, travels in the tracheoesophageal groove for its entire cervical course. The recurrent nerves can be identified in the inferior aspect of the operative field if there is associated inflammation or scarring closer to the thyroid. In order to protect the nerves, only tissue that is transparent and/or definitively identified to be

vascular or lymphatic should be divided. After identification of the recurrent nerve along its entire course, the lower parathyroid is located.

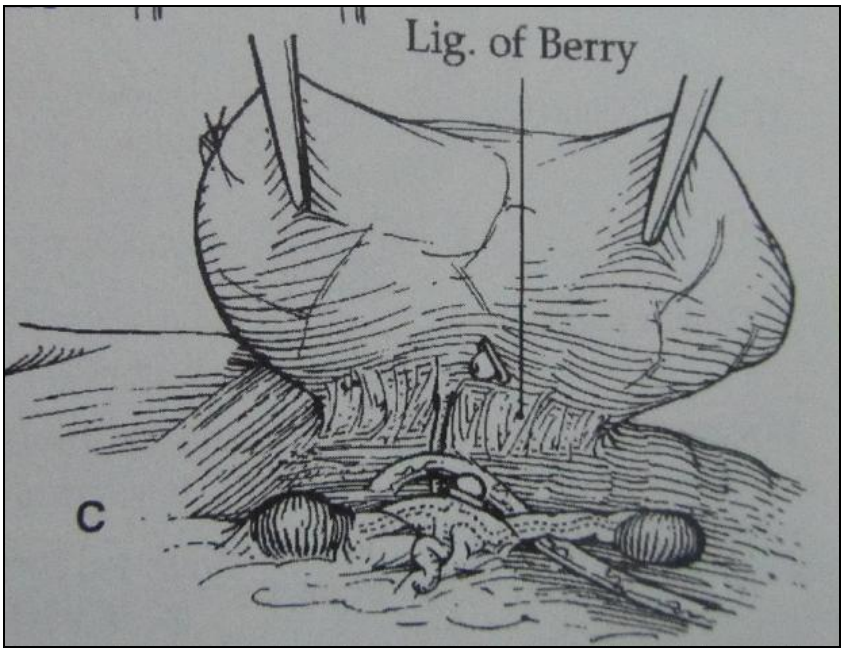

The inferior pole vessels are the blood supply to the inferior parathyroid glands and most superior parathyroid glands, which is why only the terminal branches directly entering the thyroid should not be divided . Branches of the inferior thyroid artery are divided as close to the thyroid gland as possible to avoid devascularizing the parathyroids.

The final dissection of the anterolateral aspect of the trachea, through the remainder of the ligament of Berry, should be performed carefully since this is the area where the nerve is at greatest risk of injury. Once on the anterior aspect of the trachea, this is an avascular plane.

The thyroid isthmus is mobilized of the anterior trachea with electrocautery to the intersection with the contra lateral lobe. The thyroid isthmus is then divided.

With the specimen excised, it is re-examined to ensure that no parathyroid tissue has been inadvertently removed. If a normal parathyroid gland is identified on the excised thyroid specimen, it should be auto-transplanted immediately .The operative field is irrigated and hemostasis ensured. Surgicel is useful when there is minimal bleeding immediately adjacent to the recurrent laryngeal nerve, which is often just as the nerve enters the larynx posterior to the cricothyroid muscle. The strap muscles are then reapproximated in the midline with a running 2-0 vicryl suture. The platysma is reapproximated with a running 3-0 vicryl suture. Drains are inserted although in some centers they are not used. Skin closure is with a 5-0 Prolene suture.

Subtotal thyroidectomy- In a traditional subtotal thyroidectomy, 2 to 3 g of thyroid tissue is left bilaterally. This is no longer recommended, because recurrent disease can occur bilaterally and reoperation would place both recurrent laryngeal nerves and all functioning parathyroid glands at risk.

Sub Total Thyroidectomy

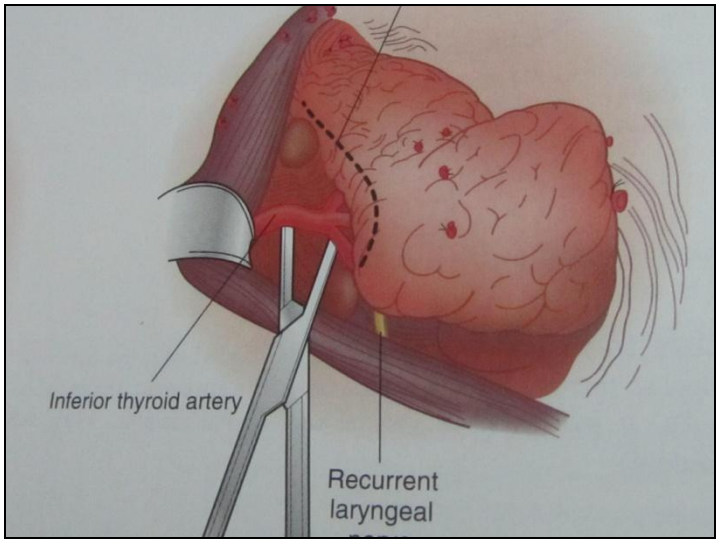

Instead, a Hartley–Dunhill subtotal thyroidectomy is now recommended if residual thyroid tissue is left in situ. This involves a total lobectomy and isthmusectomy on the most diseased side and a subtotal resection (leaving approximately 4 g) on the contra lateral side. Subtotal thyroidectomy should not be performed for patients with malignant disease as thyroid tissue left in situ on the side of the primary tumor is at risk for recurrent disease, higher doses of radioactive iodine (RAI) are required after subtotal thyroidectomy, and thyroglobulin assays are less sensitive for predicting tumor recurrence.

When a subtotal thyroidectomy is planned, a thyroid lobectomy should be performed on the most diseased lobe. On the side of the subtotal resection, the upper pole vessels and the inferior pole vessels are mobilized and divided. The middle thyroid vein is then divided and the

thyroid lobe is mobilized out of the wound. The recurrent nerve is identified. However, branches of the inferior thyroid artery are not ligated. The postero-lateral resection margin through the thyroid is selected so that an appropriate volume of thyroid tissue is left in situ, while keeping the dissection plane safely anterior to the recurrent laryngeal nerve and the parathyroid glands. Thyroid tissue is transected. Additional hemostasis can be achieved with pressure and electrocautery, when safe to do so. The incision is then closed in the same manner as during a thyroid lobectomy.

Total thyroidectomy- A total thyroidectomy is the treatment of choice for the majority of thyroid cancers. A near-total thyroidectomy leaves less than 1 g (1 cm) of thyroid tissue on one side of the neck. It is performed when a total thyroidectomy is planned, but a minute portion of thyroid is purposely left in situ, in close proximity to the recurrent laryngeal nerve or parathyroid gland, when it is deemed unsafe to do otherwise. A total thyroidectomy is essential performing a thyroid lobectomy on each side, without transecting the isthmus.

Separating Thyroid from Trachea

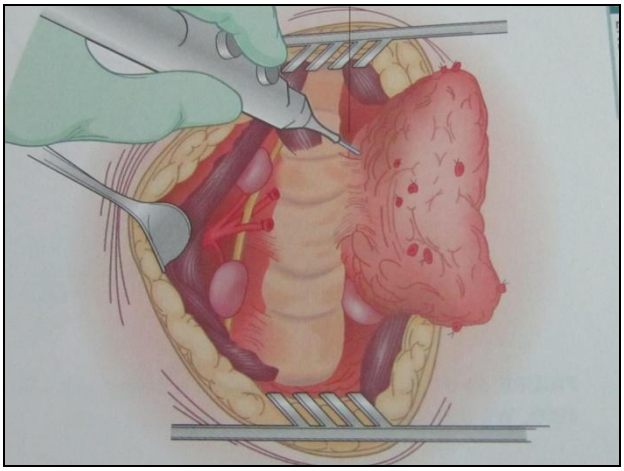

One should perform the operation on the most abnormal side of the thyroid first, so that if the nerve is inadvertently injured or invaded by thyroid cancer, a less extensive procedure can be performed on the opposite side to ensure that the contra lateral nerve is preserved. Bilateral recurrent laryngeal nerve palsy should be avoided at all costs, as this often requires a tracheostomy to protect the patient's airway.

If a near-total or total thyroidectomy is being performed as a "completion" thyroidectomy, it should usually be performed within 5 days of the original thyroid lobectomy or at least 2 to 3 months afterward. Operating within this intervening time period is associated with reactive scar tissue and more bleeding.

Parathyroid implantation- To auto transplant a parathyroid gland, confirmation that it is normal parathyroid tissue should first be established histologically with a frozen section of a small portion of the

gland, especially if the patient has thyroid cancer. While being evaluated, the remaining parathyroid tissue should be minced into pieces and placed in saline solution. Once confirmed to be normal parathyroid, the minced parathyroid tissue is placed in a pocket created in the ipsilateral sternocleidomastoid muscle and secured with a 3-0 silk figure-eight suture that closes the muscle fascia. The site is then marked with two surgical clips. Any parathyroid gland considered to be at risk should be autotransplanted, regardless of the status of the other glands. Each parathyroid gland should be treated as if it were the only remaining functioning parathyroid tissue.

POSTOPERATIVE COMPLICATIONS OF THYROIDECTOMY

Haemorrhage [77]

A tension haematoma deep to the cervical fascia is usually due to reactionary haemorrhage from one of the thyroid arteries; occasionally, haemorrhage from a thyroid remnant or a thyroid vein may be responsible. This is a rare but desperate emergency requiring urgent decompression by opening the layers of the wound, not simply the skin closure, to relieve tension before urgent transfer to theatre to secure the bleeding vessel. A subcutaneous haematoma or collection of serum may form under the skin flaps and require evacuation in the following 48

hours. This should not be confused with the potentially life threatening deep tension haematoma.

Respiratory obstruction

This is very rarely due to collapse or kinking of the trachea (tracheomalacia). Most cases are caused by laryngeal oedema. The most important cause of laryngeal oedema is a tension haematoma. However, trauma to the larynx by anaesthetic intubation and surgical manipulation are important contributory factors, particularly if the goitre is very vascular, and may cause laryngeal oedema without a tension haematoma. Unilateral or bilateral recurrent nerve paralysis will not cause immediate postoperative respiratory obstruction unless laryngeal oedema is also present but it will aggravate the obstruction.

If releasing the tension haematoma does not immediately relieve airway obstruction, the trachea should be intubated at once. An endotracheal tube can be left in place for several days; steroids are given to reduce oedema and a tracheostomy is rarely necessary. Intubation in the presence of laryngeal oedema may be very difficult and should be carried out by an experienced anaesthetist.

Repeated unsuccessful attempts may aggravate the problem and, in a crisis, it is safer to perform a needle tracheostomy as a temporary

measure; a large bore 12G intravenous cannula (diameter 2.3 mm) is satisfactory.

Recurrent laryngeal nerve paralysis and voice change

RLN injury may be unilateral or bilateral, transient or permanent. Early routine postoperative laryngoscopy reveals a much higher incidence of transient cord paralysis than is detectable by simple assessment of the integrity of the voice and cough. Such temporary dysfunction is not clinically important, however, but voice and cord function should be assessed at the first follow-up 4 weeks postoperatively. An audit of the British Association of Endocrine Surgeons revealed an RLN palsy rate of 1.8% at 1 month declining to 0.5% at 3 months for first-time operations. Permanent paralysis is rare if the nerve has been identified at operation. Injury to the external branch of the superior laryngeal nerve is more common because of its proximity to the superior thyroid artery. This leads to loss of tension in the vocal cord with diminished power and range in the voice. Patients, particularly those who use their voices professionally, must be advised that any thyroid operation will result in change to the voice even in the absence of nerve trauma. Fortunately, for most patients the changes are subtle and only demonstrable on formal voice assessment.

Thyroid insufficiency

Following subtotal thyroidectomy this usually occurs within 2 years; however, there is a small but progressive annual incidence over many years, which is often insidious and difficult to recognise. The incidence is considerably higher than was previously thought and rates of 20–45% at 10 years have been reported. This results from a change in the autoimmune response, from stimulation to destruction of the thyroid cells. There is a definite relationship between the estimated weight of the thyroid remnant and the development of thyroid failure after subtotal thyroidectomy for Graves' disease. Thyroid insufficiency is rare after surgery for a toxic adenoma because there is no autoimmune disease present.

Parathyroid insufficiency

This is due to removal of the parathyroid glands or to infarction through damage to the parathyroid end artery; often, both factors occur together. Vascular injury is probably far more important than inadvertent removal. The incidence of permanent hypoparathyroidism should be less than 1% and most cases present dramatically 2–5 days after operation; however, very rarely the onset is delayed for 2–3 weeks or a patient with marked hypocalcaemia is asymptomatic.

Thyrotoxic crisis (storm)

This is an acute exacerbation of hyperthyroidism. It occurs if a thyrotoxic patient has been inadequately prepared for thyroidectomy and is now extremely rare. Very rarely, a thyrotoxic patient presents in a crisis and this may follow an unrelated operation. Symptomatic and supportive treatment is for dehydration, hyperpyrexia and restlessness. This requires the administration of intravenous fluids, cooling the patient with ice packs, the administration of oxygen, diuretics for cardiac failure, digoxin for uncontrolled atrial fibrillation, sedation and intravenous hydrocortisone. Specific treatment is with carbimazole 10–20 mg 6-hourly, Lugol's iodine 10 drops 8-hourly by mouth or sodium iodide 1 g intravenously. Propranolol intravenously (1–2 mg) or orally (40 mg 6-hourly) will block β-adrenergic effects.

Wound infection

Cellulitis requiring prescription of antibiotics, often by the general practitioner, is more common than most surgeons appreciate. A significant subcutaneous or deep cervical abscess is exceptionally rare and should be drained.

Hypertrophic or keloid scar

This is more likely to form if the incision overlies the sternum and in dark-skinned individuals. Intradermal injections of corticosteroid

should be given at once and repeated monthly if necessary. Scar revision rarely results in significant long-term improvement.

Stitch granuloma

This may occur with or without sinus formation and is seen after the use of non-absorbable, particularly silk, suture material. Absorbable ligatures and sutures must be used throughout thyroid surgery. Some surgeons use a subcuticular absorbable skin suture rather than the traditional skin clips or staples. Skin staples, if used, can be removed safely in less than 8 hours because the skin closure is supported by the platysma stitch.

Materials and Methods

Between September 2013 to September 2014, 33 patients underwent thyroidectomy (Hemi / Total) performed using Harmonic Scalpel for vessel control included in the study. All patients had routine preoperative workup for their disease and comorbidities evaluation and the same anesthetic and hospital care regardless of the surgical technique performed. A complete preoperative assessment was obtained for all patients. A 3-7 cm skin incision was made. The flaps were raised and then strap muscles were separated in the midline and laterally reflected. The superior thyroid vessels and inferior thyroid vessels and middle thyroid vein, were divided with the HS. For total thyroidectomy the same steps were repeated for removal of the contra lateral lobe. Finally, the wound was irrigated and closed using interrupted 3-0 vicryl sutures to approximate the strap muscles and the platysmal layer. The skin was closed subcutaneously.

- The operative time was calculated by measuring time taken from skin incision to skin closure.
- Post operative drainage fluid volume was calculated by redivac suction drain over period for 24 hours.
- Post operative pain was calculated by using Visual Analogue Scale. We used pain during initial deglutition and early feeding and

pain from operative field as our end point excluding cervical distress.

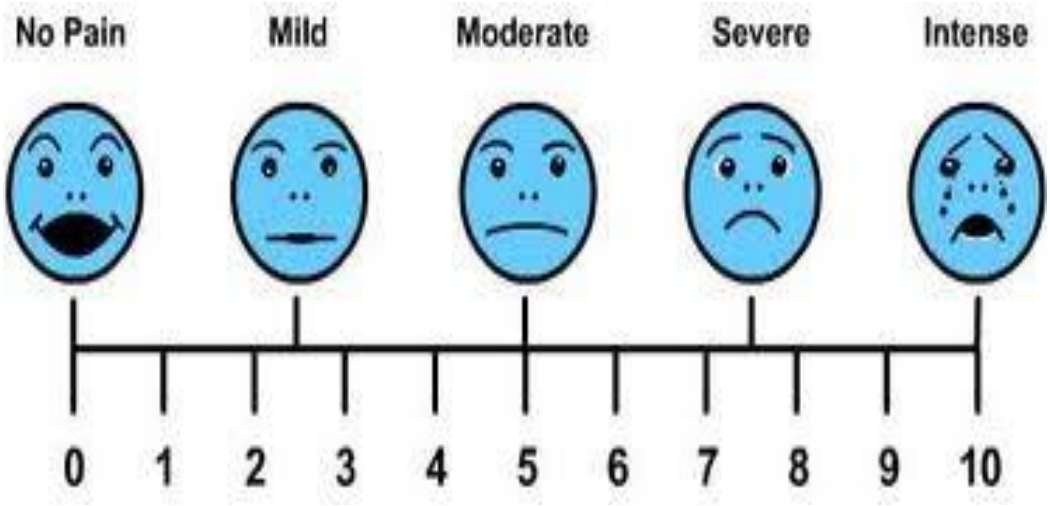

- **Post operative Transient HypoCalcemia** was measured by serum calcium levels were obtained during the 1st POD , and 3rd POD and once in every 4 weeks. Serum calcium level below 8mg/dl is considered Hypocalcemia.
- RLN injury assessed by vocal cord status post operatively after extubation by direct laryngoscopy by anesthesiologist and clinically in post operative ward.

Incision

Device

Device with Handle

Exposing Superior Pedicle

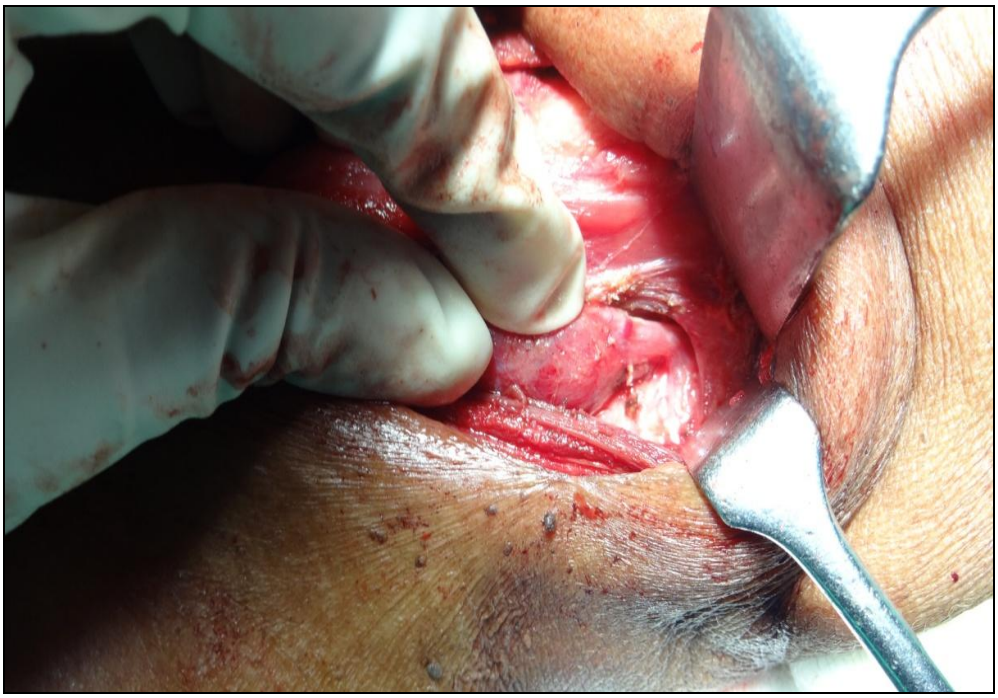

Harmonic Ligation of Pedicle

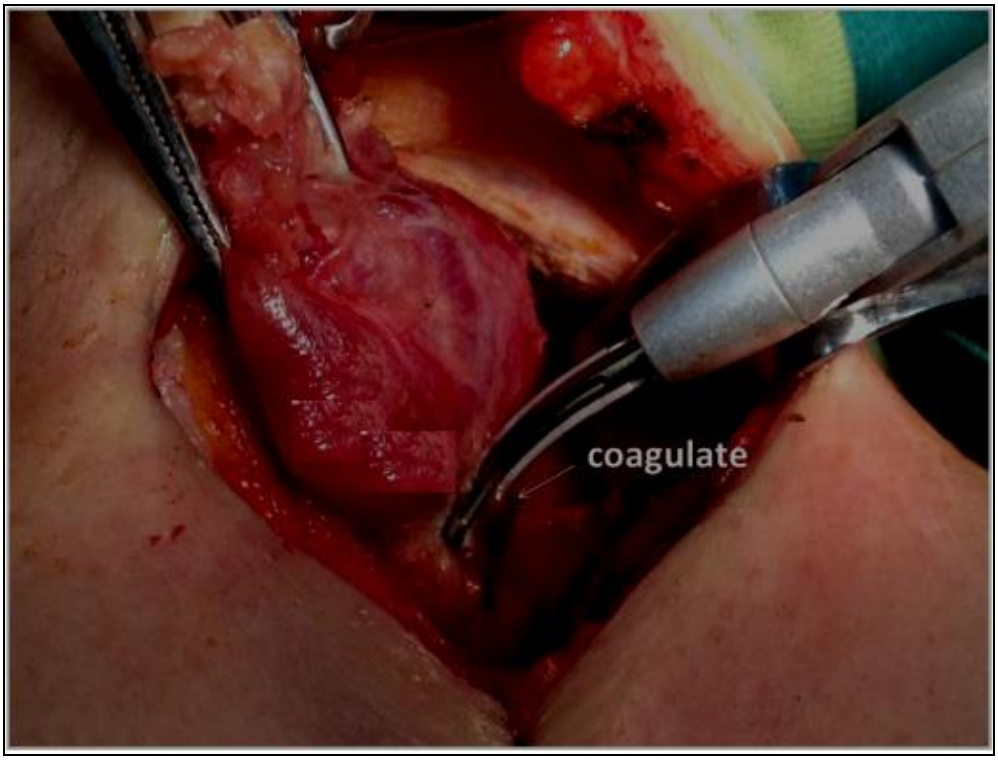

After thyroidectomy

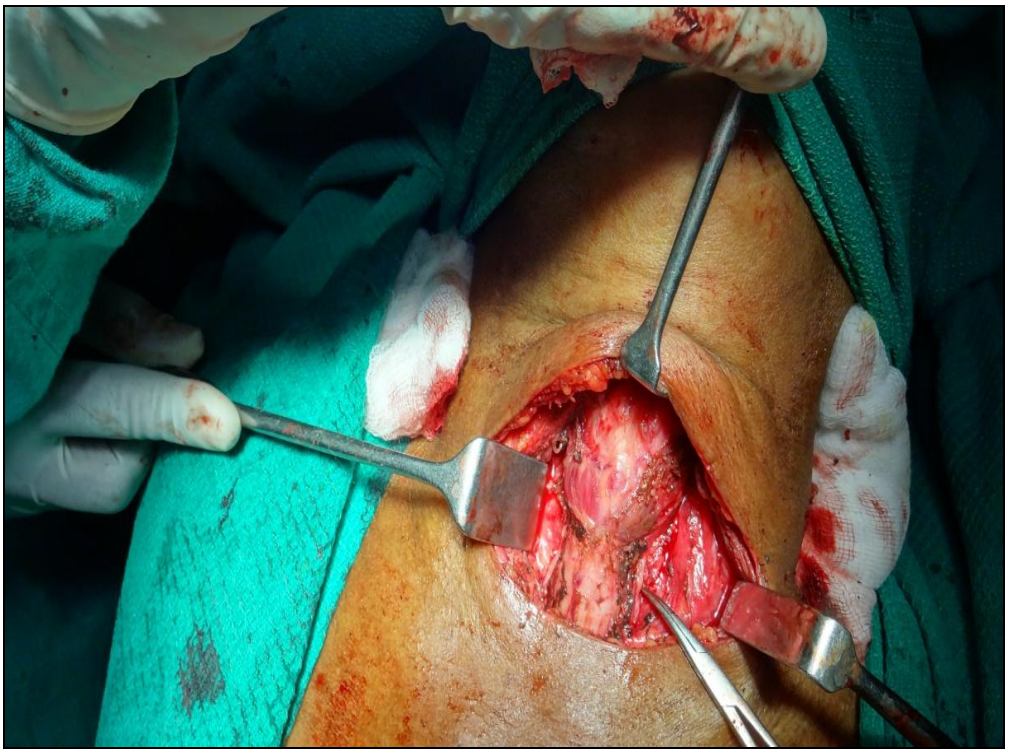

RESULTS

Totally 33 Patients underwent thyroidectomy (Hemi / Total) using Harmonic Scalpel for vessel control and following conclusions were drawn.

1. AGE WISE DISTRIBUTION

Age in years	No.of cases	Percentage (%)
< 30	11	33.3
31- 45	14	42.4
46-60	6	18.2
> 60	2	6.1

In our study totally 33 patients was studied, out of it 11 patients are age less than 30 yrs, only two of them more than 60 yrs, others or in between.

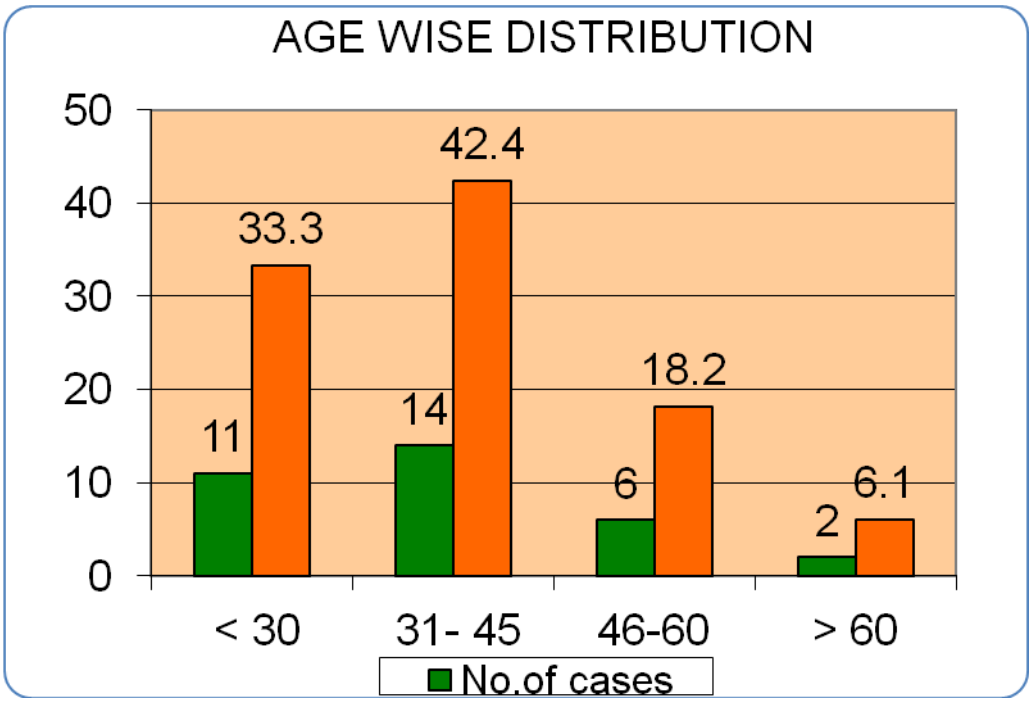

2. Diagnosis and Treatment

Diagnosis	Surgery	No.of cases	Percentage(%)
MNG	Total thyroidectomy	16	48.5
SNG LT	Left Hemi thyroidectomy	6	18.2
SNG RT	Right Hemi thyroidectomy	11	33.3

In our study 16 patients underwent total thyroidectomy, 6 patients underwent Left hemithyroidectomy and 11 patients right hemithyroidectomy was done.

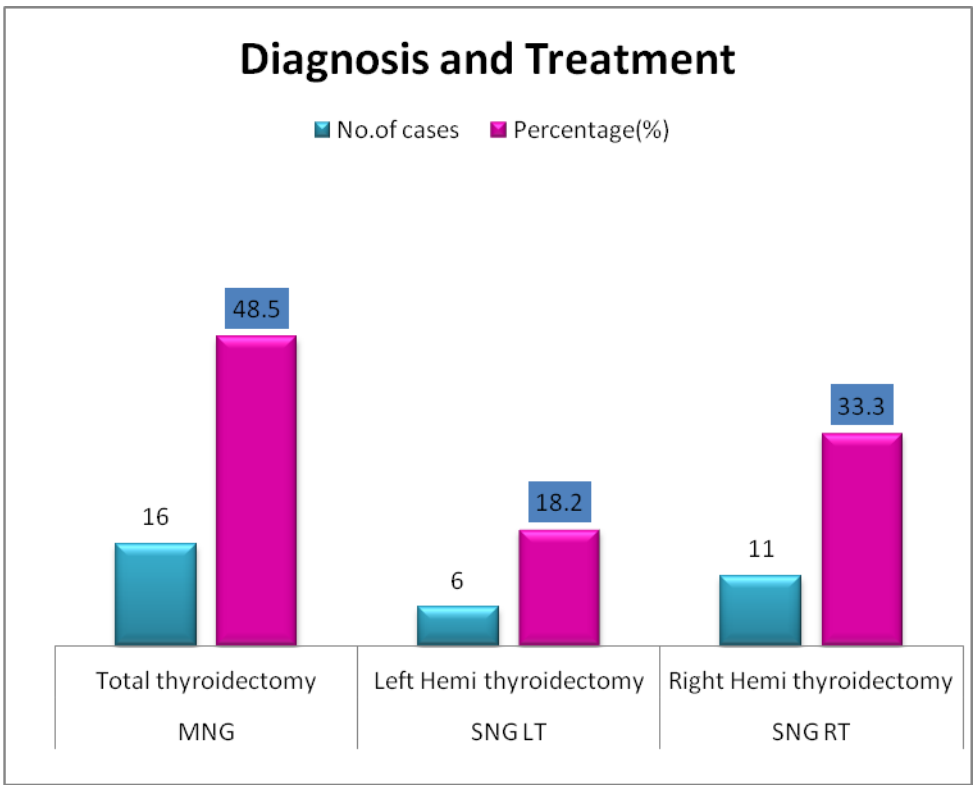

3. POSTOPERATIVE HPE

Post op	No.of cases	Percentage(%)
Adenomatous goitre	6	18.2
Colloid goiter	4	12.1
Follicular adenoma	5	15.2
MNG	10	30.3
Nodular colloid goitre	2	6.1
Nodular Goitre	6	18.2

In our study carcinomas are excluded. The same was proved by post operative HP. Out of 33 Adenomatous Goitre 6 patients, 4 patients had colloid goiter, 5 patients had follicular adenoma, 6 patients had nodular goiter.

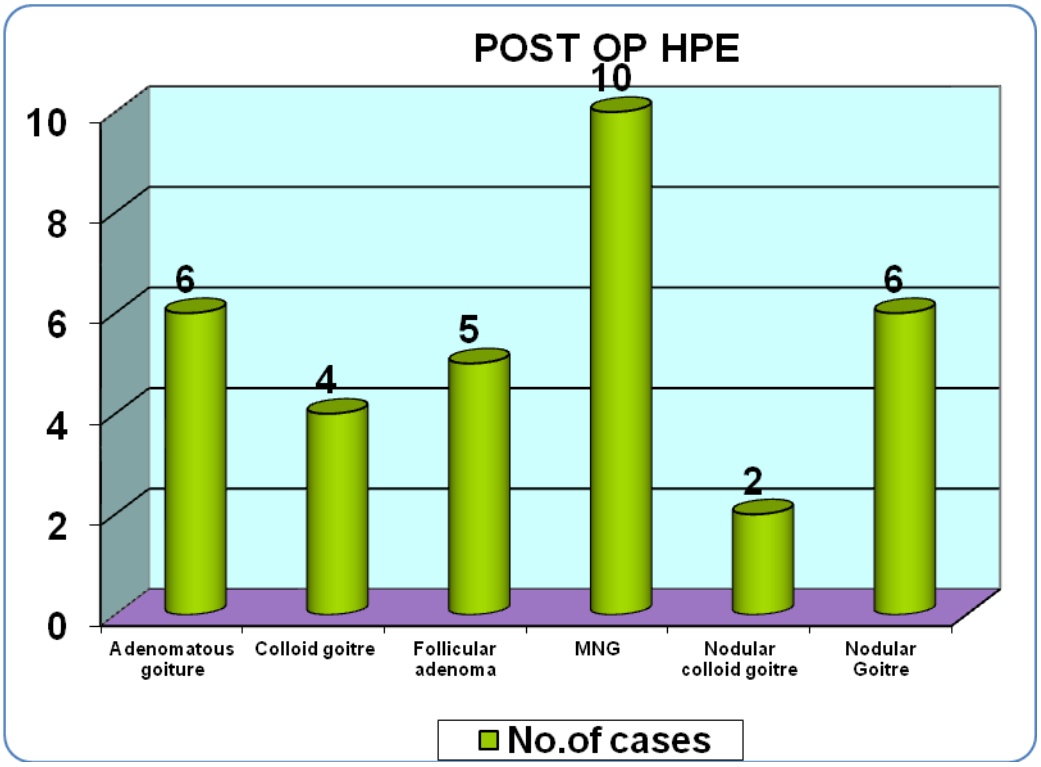

Duration:

By using harmonic scalpel operative time was significantly shorter. For Hemithyroidectomy mean duration 63.5 min and for Total thyroidectomy 101.1 min. highest time taken for Total thyroidectomy 126 min. Minimun duration was taken to Hemi thyroidectomy 55 min.

4. DURATION OF SURGERY

TYPE OF SURGERY	NO OF PATIENTS	DURATION (MIN)
Mean	33	81.75
Hemi Thyroidectomy	17	63.5
Total Thyroidectomy	16	101.1

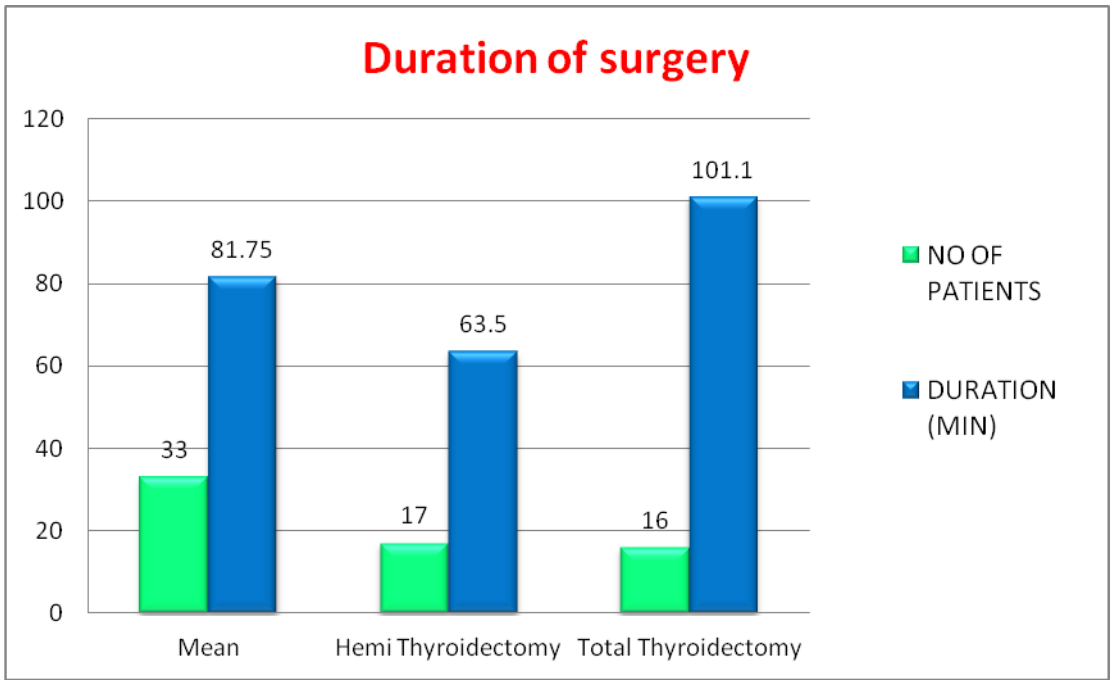

Post operative pain score- By Visual Analogue scale pain severity assessed. According to VAS patients in the HS group experienced

significantly less pain. In total 33 patients, 14 patients had no pain. They are pain free post operative period. 14 patients had mild pain. 5 patients had pain score 4 or more had moderate pain.

5. PAIN SCORE

SEVERITY	NO. OF PATIENTS	SCORE	PERCENTAGE (%)
No Pain	14	0	43
Mild Pain	14	2	42
Moderate Pain	5	4	15

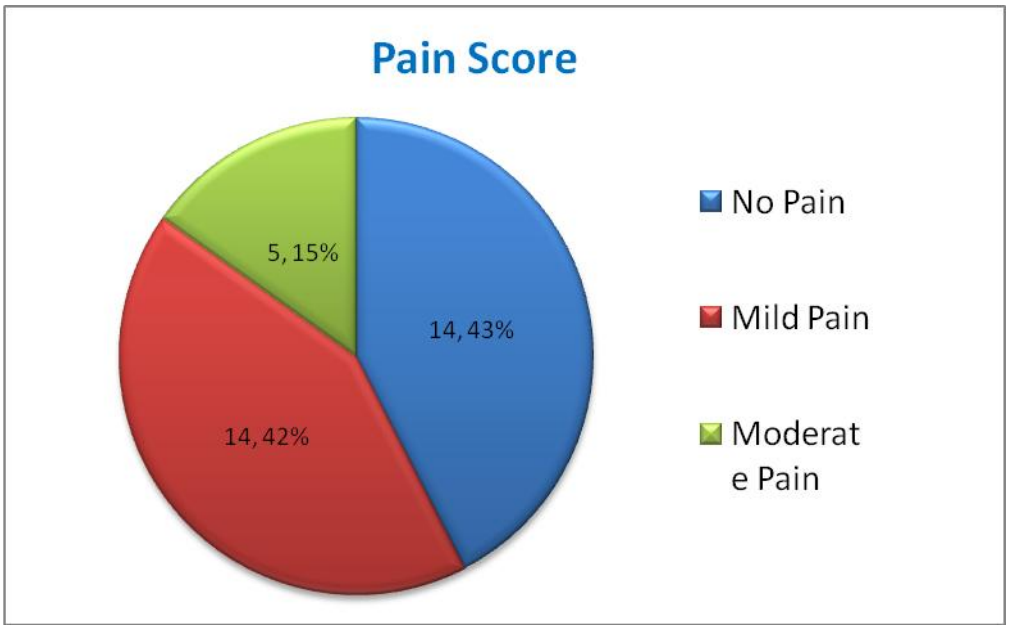

Possible explanation is that the HS causes reduced tissue injury with no neuromuscular stimulation and HS would allow reduced traction and reduced manipulation of the thyroid.

Post operative Drainage fluid volume

By using ready vac suction drain from first 24 hours mean drainage fluid volume 25.4 ml. Second day mean drain volume is 14.4±5 ml

6. DETAILS OF DRAINAGE [ml]

Day	Mean	Low	High
1st day	25.4	15	45
2nd day	14.4	5	32

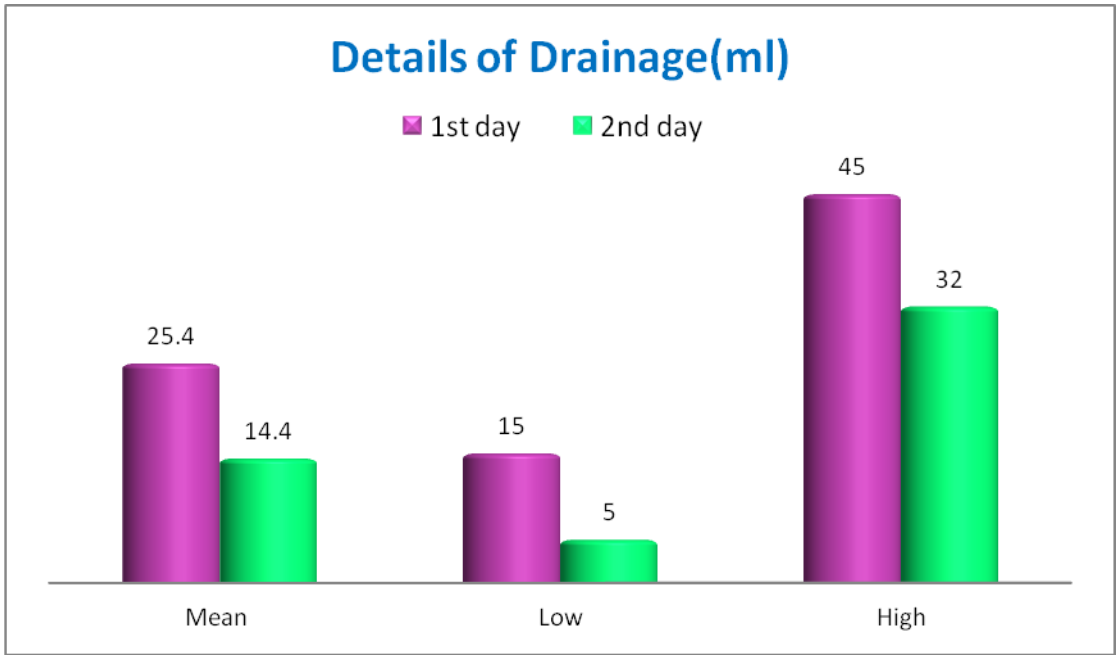

Hypocalcemia

In our study 4 patient showed clinical symptoms of hypocalcemia and their serum calcium levels are <8.0mg/dl. They require calcium supplementation temporarily. All patients recovered completely and no permanent hypoparathyroidism was registered.

7. TRANSIENT POSTOPERATIVE HYPOCALCEMIA

HYPOCALCEMIA	PATIENTS	PERCENTAGE (%)
Yes	4	12.12
No	29	87.88

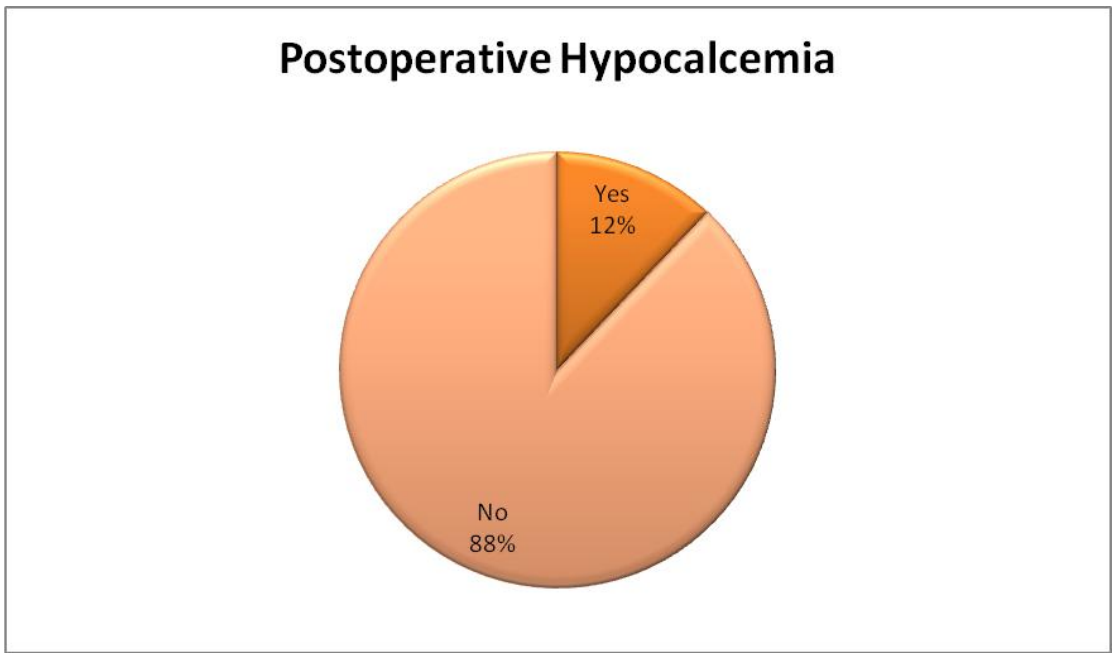

RLN Injury

In our study no cases suffered any RLN injury. In all patients, vocal cord status normal post operatively.

DISCUSSION

The results of our study were compared with the available previous similar studies.

Duration of surgery

In study done by Hallgrimsson (2008) mean operative time was 134.7 min in 27 patients. Lombardi (2008) reported mean duration was 53.1min in 100 patients. Frazzetta (2005) study shows mean duration 56min in 60 patients. In our study, mean duration in 81.75min.

8. Mean Duration of Surgery Discussion

Study	Year	No.Of Patients	Duration Surgery	SD
Defechereux	2003	17	70.7	18.3
Ortega	2004	57	86	20
Cordon	2005	7	104	29
Frazzetta	2005	60	56	18
Miccoli	2006	50	40	6.8
Kilic	2007	40	47.1	8.2
Hallgrimsson	2008	27	134.7	5.6
Lombardi	2008	100	53.1	20.7
Yildirim	2008	50	77.9	12.5
Present study	**2014**	**33**	**81.75**	**21.19**

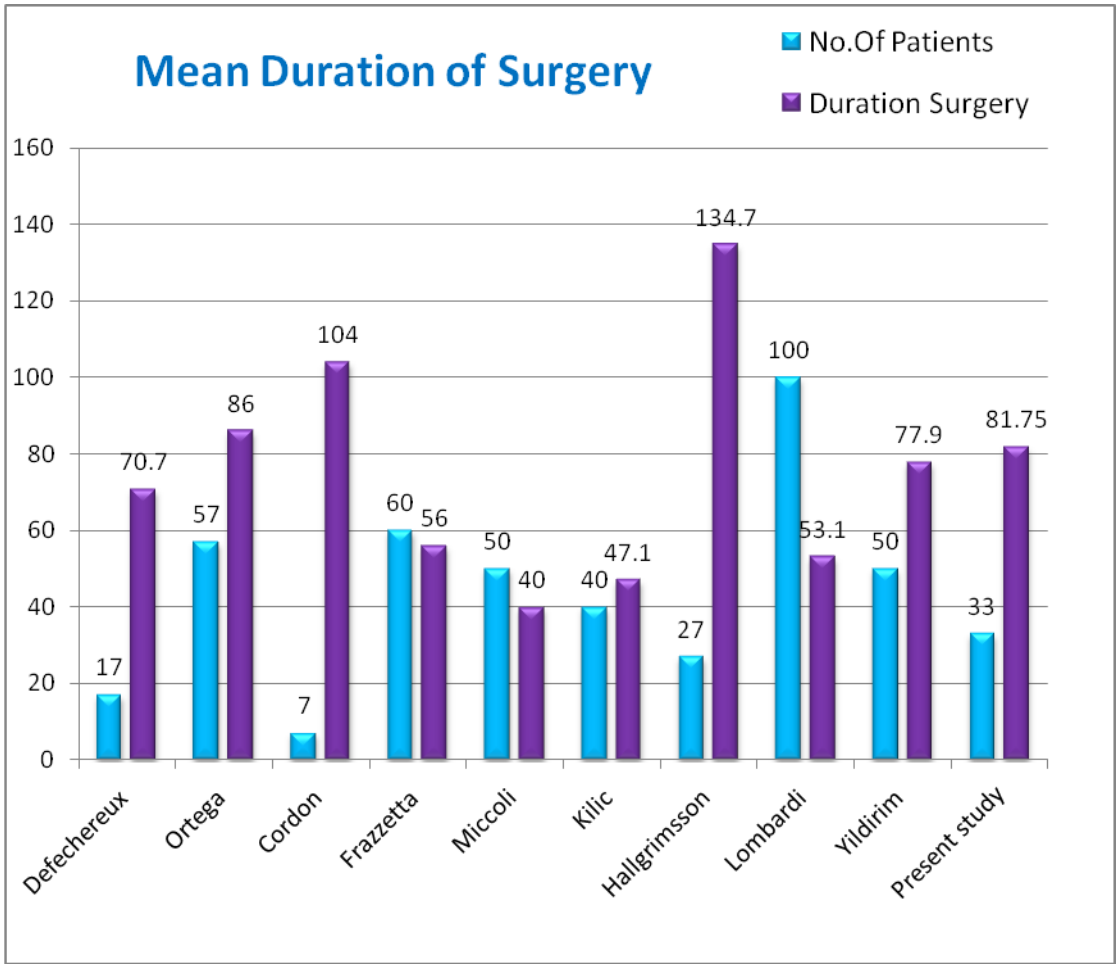

Pain Score

In 2011 Emanuele Ferri done the study shows mean Pain score of 1.97±0.97 and in 2006 Paolo Miccoli done the Harmonic Scalpel in thyroid surgery, mean pain score was 3.9±1.15. Subsequently Ahmedereza (Dehran university, Iran) study shows mean pain score value of 2.3±1.23. In our study, mean pain score 1.45±1.43 which is comparable to the study done earlier.

9. Mean Pain Score

Author	Year	No.Of Patients	Pain Score	SD
Paolo Miccoli	2006	50	3.9	1.15
Emanuele Ferri	2011	50	1.99	0.97
Ahmedereza Soudush	2013	33	2.3	1.23
Present study	**2014**	**33**	**1.45**	**1.43**

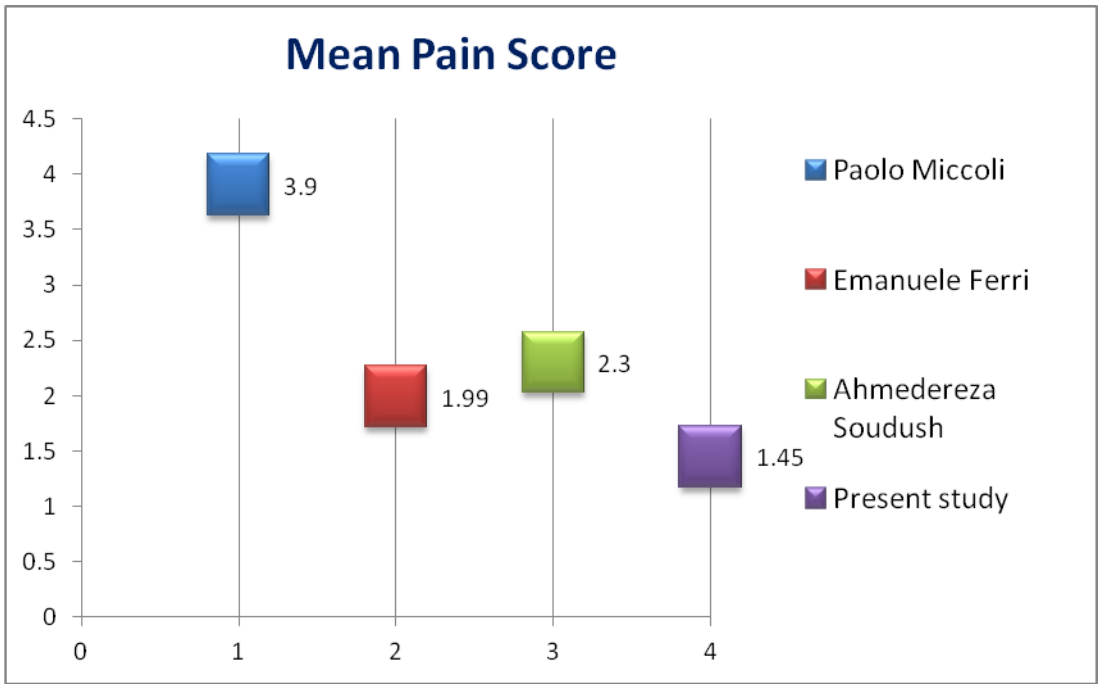

Drainage Volume

In our study mean drainage volume after 24 hrs was 26ml±9.39ml which is comparable to the previous studies shown in tables.

In our study 2nd 24 hrs mean drainage volume in 14.9±8.5ml, but comparison could not be made out because no large scale shown the 2nd 24 hrs drainage volume statistically.

10. Mean Drainage Volume Comparison

Author	Year	No.Of Patients	Drainage(ml)	SD
Petrakis IE	2004	270	21	15
Paolo Miccoli	2006	50	40.1	7.9
Emanuele Ferri	2011	50	37.4	2.4
Oktay Yener	2012	42	37.4	2.4
Ahmedereza Soudush	2013	33	33.43	8.07
Present study	**2014**	**33**	**26**	**9.39**

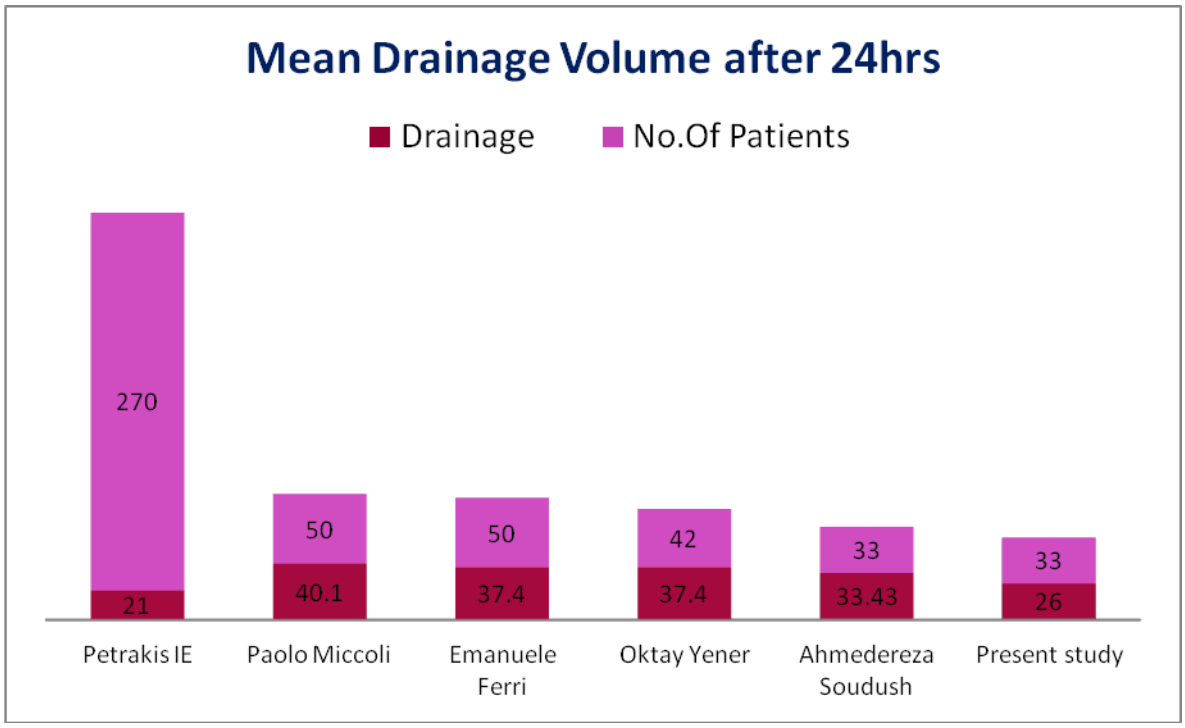

Post Operative Transient Hypocalcemia

From the Literature rates of post operative Hypocalcemia are approximately 5% it resolves in 80% of cases in one year. This results comparable to our study.

11.Transient Hypocalcemia Discussion

Author	Year	No.Of Patients	Transient Hypocalcemia
Petrakis IE	2004	270	3
Paolo Miccoli	2006	50	5
Kilic	2007	40	2
Lombardi	2008	100	28
Emanuele Ferri	2011	50	7
Yun-fei Duan	2013	332	14
Present study	**2014**	**33**	**4**

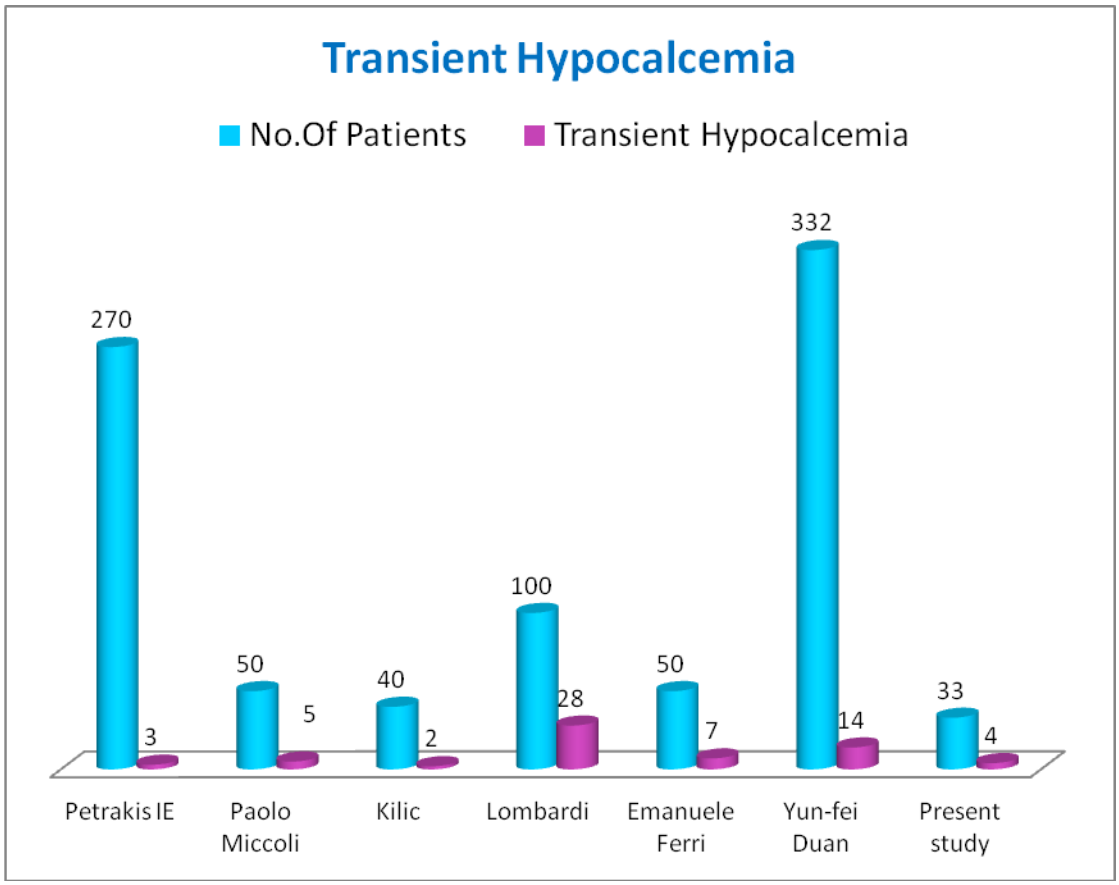

In our study4 cases suffered from transient hypocalcemia a treated by oral calcium and Vit. D tablets. But all of them recovered from the hypocalcemia in Petrakis IE study lowest rate of Hypocalcemia (1.1%) and in Lombardi study 28% of patient suffered from the hypocalcemia.

CONCLUSION

The present analytical study of advantages of harmonic scalpel in thyroid surgery has been carried out in Govt. Rajaji Hospital, Madurai during period of Sep 2013 to Sep 2014 .

Based on the data and results obtained in the present study the following conclusion can be drawn.

- The average total duration of surgery is less by using HS in thyroid surgery.
- The post operative total drainage fluid volume will be less by using HS in thyroid surgery.
- The post operative pain is less in patients using HS for hemostasis in thyroid surgery.
- Post operative transient hypocalcemia was less in HS patients.
- No RLN injury found in the study.

SUMMARY

Analysis of Harmonic scalpel usage in thyroid surgery of 33 cases of thyroid swelling admitted to GRH, Madurai. During the period of Sep 2013 to Sep 2014 has been made summarized below

- ✓ 33 female patients with SNG and MNG thyroid undergoing thyroidectomy included in the study
- ✓ Out of 33 patient undergoing thyroidectomy by harmonic scalpel for vessel control, 16 patients were in Hemi thyroidectomy group, 17 patient were in Total thyroidectomy.
- ✓ Mean duration for hemi thyroidectomy is 63.5 min
- ✓ Mean duration for total thyroidectomy is 101.1 min
- ✓ Mean duration for (Hemi + Total) thyroidectomy is 81.75 min
- ✓ Post Operative drainage volume in the first 24 hrs is 26 ml
- ✓ Post Operative drainage volume in the second 24 hrs is 14.90 ml
- ✓ Mean Pain score is 1.45
- ✓ Transient hypocalcemia seen in 12% of patients, but no permanent hypocalcemia recorded.
- ✓ None of the case affected by RLN Injury.

BIBLIOGRAPHY

1.Geeta Lal,Orlo H.Clark.Thyroid Parathyroid and Adrenal.F Charles Brunicardi.Schwartz's Principles Of Surgery,9th edition.United States of America,The McGraw Hill Companies,2010;1344.

2. A.Mohebati, A.R. Shaha. Anatomy of thyroid and parathyroid glands and neurovascular relations**.** Clinical Anatomy Special Issue: Special Issue on Head and Neck. 2012;25:19-31

3. Philip W.Smith, Leslie J.Salomone, John B. Hanks, Thyroid, Beauchamp. Evers. Mattox, Sabiston, 19th Edition. Townsend, 888, 8889

4. J.Larry Jameson,Anthony P.Weetman.Diseases of the Thyroid gland.Dennis L.Kasper. Harrison's Principles of Internal Medicine ,16th edition.United States of America,Chapter ,The Mcgraw Hill Companies,Inc.;2005;2108-9.

5. WebMD.com [Internet].Available from:http:/www.webmd.com/ a-to-z-guides/thyroid and parathyroid ultrasound

6. A.J. Jones, T.J. Aitman, C.J. Edmonds, M. Burke, E. Hudson ,M. Tellez. Comparison of fine needle aspiration cytology, radioisotopic and ultrasound scanning in the management of thyroid nodules. Postgrad Med J 1990; 66:914 -7

7. D. N. Poller, E. B. Stelow, C. Yiangou. Thyroid FNAC cytology: can we do it better. Cytopathology 2008;19:4-10

8. MA Tabaqchali, JM Hanson, SJ Johnsont, V Wadehrat, TWJ Lennard, G Proud. Thyroid aspiration cytology in Newcastle: a six year cytology/histology correlation study. Ann R Coll Surg Engl 2000; 82: 149-55

9. Nicholas J. Screaton, Laurence H. Berman, John W. Grant. US-guided Core-Needle Biopsy of the Thyroid Gland. Radiology 2003;226:827-32.0

10. J.A. Patton, M.P. Sandler, C.L. Partain. Prediction of Benignancy of the Solitary "Cold" Thyroid Nodule by Fluorescent Scanning. J Nucl Med 1985;26:461-464.

11. C Brewis, M Mahadevan, CM Bailey, DP Drake. Investigation and

treatment of Thyroglossal cysts in children. J R Soc Med 2000;93:18-21

12. George Andros, Paul V. Harper, Katherine A, Lathrop, Robert J. Mccardle. Pertechnetate-99m Localization in Man with Applications to Thyroid Scanning and the Study of Thyroid Physiology. The Journal of Clinical Endocrinology & Metabolism 1965;25:1067-76.

13. June-Key Chung, Young So, Jae Sung Lee, Chang Woon Choi, Sang Moo Lim, Dong Soo Lee, Sung Woon Hong, Yeo Kyu Youn, Myung Chul Lee, Bo Youn Cho. Value of FDG PET in Papillary Thyroid Carcinoma with Negative 131 I WholeBodyScan. J NucIMed 1999;40:986-92.

14.Herbert Chen.Fine Needle Aspiration Biopsy Of The Thyroid: Thyroid Lobectomy And Subtotal And Total Thyroidectomy.Josef E.Fischer.Fischer's Mastery Of Surgery ,6th Edition;1.Gurgaon,Wolters Kluwer Health/Lippincott Williams and Wilkins,2012;468-78.

15. Massarweh NN, Cosgriff N, Slakey DP. Electrosurgery: history, principles, and current and future uses. J Am Coll Surg 2006; 202:520.

16. Mayooran Z, Pearce S, Tsaltas J, et al. Ignorance of electrosurgery among obstetricians and gynaecologists. BJOG 2004; 111:1413.

17. Tucker RD. Laparoscopic electrosurgical injuries: survey results and their implications. Surg Laparosc Endosc 1995; 5:311.

18. Tucker RD, Schmitt OH, Sievert CE, Silvis SE. Demodulated low frequency currents from electrosurgical procedures. Surg Gynecol Obstet 1984; 159:39.

19. Wu MP, Ou CS, Chen SL, et al. Complications and recommended practices for electrosurgery in laparoscopy. Am J Surg 2000; 179:67.

20. Redwine DB, Wright JT. Laparoscopic treatment of complete obliteration of the cul-de-sac associated with endometriosis: long-term follow-up of en bloc resection. Fertil Steril 2001; 76:358.

21. Lu S, Xiang J, Qing C, et al. Effect of necrotic tissue on progressive injury in deep partial thickness burn wounds. Chin Med J (Engl) 2002; 115:323.

22. Sutton PA, Awad S, Perkins AC, Lobo DN. Comparison of lateral thermal spread using monopolar and bipolar diathermy, the Harmonic Scalpel and the Ligasure. Br J Surg 2010; 97:428.

23. Matthews BD, Pratt BL, Backus CL, et al. Effectiveness of the ultrasonic coagulating shears, LigaSure vessel sealer, and surgical clip application in biliary surgery: a comparative analysis. Am Surg 2001; 67:901.

24. Landman J, Kerbl K, Rehman J, et al. Evaluation of a vessel sealing system, bipolar electrosurgery, harmonic scalpel, titanium clips, endoscopic gastrointestinal anastomosis vascular staples and sutures for arterial and venous ligation in a porcine model. J Urol 2003; 169:697.

25. Kinoshita T, Kanehira E, Omura K, et al. Experimental study on heat production by a 23.5-kHz ultrasonically activated device for endoscopic surgery. Surg Endosc 1999; 13:621.

26. Goldstein SL, Harold KL, Lentzner A, et al. Comparison of thermal spread after ureteral ligation with the Laparo-Sonic ultrasonic shears and the Ligasure system. J Laparoendosc Adv Surg Tech A 2002; 12:61.

27. Phillips CK, Hruby GW, Durak E, et al. Tissue response to surgical energy devices. Urology 2008; 71:744.

28. Emam TA, Cuschieri A. How safe is high-power ultrasonic dissection? Ann Surg 2003; 237:186.

29. Abstracts of the Global Congress of Minimally Invasive Gynecology, 34th Annual Meeting of the American Association of Gynecologic Laparoscopists, Chicago, Illinois, USA, November 9-12, 2005. J Minim Invasive Gynecol 2005; 12:S1.

30. Campbell PA, Cresswell AB, Frank TG, Cuschieri A. Real-time thermography during energized vessel sealing and dissection. Surg Endosc 2003; 17:1640.

31. Lamberton GR, Hsi RS, Jin DH, et al. Prospective comparison of four laparoscopic vessel ligation devices. J Endourol 2008; 22:2307.

32. Brill AI. Energy systems for operative laparoscopy. J Am Assoc Gynecol Laparosc 1998; 5:333.

33. Nduka CC, Super PA, Monson JR, Darzi AW. Cause and prevention of electrosurgical injuries in laparoscopy. J Am Coll Surg 1994; 179:161.

34. Hulka JF, Levy BS, Parker WH, Phillips JM. Laparoscopic-assisted vaginal hysterectomy: American Association of Gynecologic Laparoscopists' 1995 membership survey. J Am Assoc Gynecol Laparosc 1997; 4:167.

35. Humes DJ, Ahmed I, Lobo DN. The pedicle effect and direct coupling: delayed thermal injuries to the bile duct after laparoscopic cholecystectomy. Arch Surg 2010; 145:96.

36. Vilos GA, Newton DW, Odell RC, et al. Characterization and mitigation of stray radiofrequency currents during monopolar resectoscopic electrosurgery. J Minim Invasive Gynecol 2006; 13:134.

37. Vilos G, Latendresse K, Gan BS. Electrophysical properties of electrosurgery and capacitive induced current. Am J Surg 2001; 182:222.

38. Yazdani A, Krause H. Laparoscopic instrument insulation failure: the hidden hazard. J Minim Invasive Gynecol 2007; 14:228.

39. Vancaillie TG. Active electrode monitoring. How to prevent unintentional thermal injury associated with monopolar electrosurgery at laparoscopy. Surg Endosc 1998; 12:1009.

40. Presthus JB, Brooks PG, Kirchhof N. Vessel sealing using a pulsed bipolar system and open forceps. J Am Assoc Gynecol Laparosc 2003; 10:528.

41. Jacobs VR, Morrison JE Jr, Paepke S, Kiechle M. Body piercing affecting laparoscopy: perioperative precautions. J Am Assoc Gynecol Laparosc 2004; 11:537.

42. American Society of Anesthesiologists. Practice advisory for the perioperative management of patients with cardiac implantable electronic devices: pacemakers and implantable cardioverter-defibrillators: an updated report by the american society of anesthesiologists task force on perioperative management of patients with cardiac implantable electronic devices. Anesthesiology 2011; 114:247.

43. Pearson, M, McClurken, M, Thompson, R. Saline enhanced thermal sealing of tissue. Potential for bloodless surgery. Min Invas Ther Allied Technol 2002; 11:265.

44. Di Carlo I, Barbagallo F, Toro A, et al. Hepatic resections using a water-cooled, high-density, monopolar device: a new technology for safer surgery. J Gastrointest Surg 2004; 8:596.

45. Yim AP, Rendina EA, Hazelrigg SR, et al. A new technological approach to nonanatomical pulmonary resection: saline enhanced thermal sealing. Ann Thorac Surg 2002; 74:1671.

46. Kennedy JS, Stranahan PL, Taylor KD, Chandler JG. High-burst-strength, feedback-controlled bipolar vessel sealing. Surg Endosc 1998; 12:876.

47. Levy B, Emery L. Randomized trial of suture versus electrosurgical bipolar vessel sealing in vaginal hysterectomy. Obstet Gynecol 2003; 102:147.

48. Dubuc-Lissoir J. Use of a new energy-based vessel ligation device during laparoscopic gynecologic oncologic surgery. Surg Endosc 2003; 17:466.

49. Richter S, Kollmar O, Schilling MK, et al. Efficacy and quality of vessel sealing: comparison of a reusable with a disposable device and effects of clamp surface geometry and structure. Surg Endosc 2006; 20:890.

50. Wang CJ, Yuen LT, Yen CF, et al. Comparison of the efficacy of the pulsed bipolar system and conventional bipolar electrosurgery in laparoscopically assisted vaginal hysterectomy. J Laparoendosc Adv Surg Tech A 2005; 15:361.

51. Sahin DA, Kusaslan R, Sahin O, et al. Comparison of Ligasure, SurgRx, and suture techniques in intra-abdominal adhesions that occur after liver resection in rats: an experimental study. Int Surg 2007; 92:20.

52. Sahin DA, Kusaslan R, Sahin O, et al. Histopathological effects of bipolar vessel sealing devices on liver parenchyma and comparison with suture method: an experimental study. Eur Surg Res 2007; 39:111.

53. Gil-Moreno A, Puig O, Pérez-Benavente MA, et al. Total laparoscopic radical hysterectomy (type II-III) with pelvic lymphadenectomy in early invasive cervical cancer. J Minim Invasive Gynecol 2005; 12:113.

54. Ou CS, Harper A, Liu YH, Rowbotham R. Laparoscopic myomectomy technique. Use of colpotomy and the harmonic scalpel. J Reprod Med 2002; 47:849.

55. Amaral, JF, Chrostek, C. Depth of thermal injury: Ultrasonically activated scalpel vs electrosurgery. Surg Endosc 1995; 9:226.

56. Bubenik LJ, Hosgood G, Vasanjee SC. Bursting tension of medium and large canine arteries sealed with ultrasonic energy or suture ligation. Vet Surg 2005; 34:289.

57. Verdaasdonk RM, van Swol CF. Laser light delivery systems for medical applications. Phys Med Biol 1997; 42:869.

58. Singh S, Maxwell D. Tools of the trade. Best Pract Res Clin Obstet Gynaecol 2006; 20:41.

59. Sutton CJ, Ewen SP, Jacobs SA, Whitelaw NL. Laser laparoscopic surgery in the treatment of ovarian endometriomas. J Am Assoc Gynecol Laparosc 1997; 4:319.

60. Penna C, Fallani MG, Fambrini M, et al. CO2 laser surgery for vulvar intraepithelial neoplasia. Excisional, destructive and combined techniques. J Reprod Med 2002; 47:913.

61. Calderelli DD, Holinger LD: Complications and sequelae of thyroid surgery. Otolaryngolclin North Am 1980; 13:85.

62. Davies TF, Larsen PR. Thyrotoxicosis. In: Larsen PR, Kronenberg HM, Melmed S, Polonsky KS, editors. Williams Textbook of Endocrinology. Saunders;2002. p.374-422.

63. Kahky MP, Weber RS. Complications of surgery on the thyroid and parathyroid glands. SurgClin North Am 1993;73:307.

64. Bentrem DJ, Rademaker A, Angelos P. Evaluation of serum calcium levels in predicting hypoparathyroidism after total/near-total thyroidectomy or parathyroidectomy. Am J Surg 2001;67(3):249-52.

65. Glinoer D, Andry G, Chantrain G. Clinical aspects of early and late hypocalcemia after thyroid surgery. Eur J SurgOncol 2000;26:571-7.

66. Netterville JL, Aly A, Ossoff RH. Evaluation and treatment of complications of thyroid and parathyroid surgery. OtolaryngolClin North Am 1990;23:529.

67. Kaplan EC. Surgery of the thyroid gland. In: Becker KC, edt. Principles and practice of endocrinology and metabolism. Lippincott Williams & Wilkins; 2001. p.440-444.

68. Waldstein SS, Medical complication of thyroid surgery. OtolaryngolClin North Am 1980;13:99.

69. Djohan RS, Rodriguez HE, Connolly MM. Intraoperative monitoring of recurrent laryngeal nerve function. Am J Surg 2000;66(6):595-97.

70. Eltzschig HK, Posner M, Moore FD Jr. The use of readily available equipment in a simple method for intraoperative monitoring of recurrent laryngeal nerve function during thyroid surgery: initial experience with more than 300 cases. Arch Surg 2002;137(4):452-57.84

71. Misiolek M, Waler J, Namyslowski G. Recurrent laryngeal nerve palsy after thyroid cancer surgery: a laryngological and surgical problem. Eur Arch Otorhinolaryngol 2001;258(9):460-62.

72. Sturniolo G, D'Alia, Tonante A. The recurrent laryngeal nerve related to thyroid surgery. Am J Surg 1999;177(6):485-88.

73. Kaplan EL, Sugg SL. Surgery of the thyroid. In: DeGroot LJ, Jameson JL, editors. Endocrinology, 4th ed, Vol.2, Philadelphia: Saunders; 2001.p. 1567-1585.

74. Sessions RB, Diehl WL. Thyroid cancer and related nodularity. In: Myers EN, Suen JY, edts. Cancer of the Head and Neck, 2nd ed. Churchill Livingstone; 1989.p.735-90.

75. Peele ME, Wartofsky L. Complications of thyroid surgery:

thyrotoxic storm. In:Falk SA editor: Thyroid disease: endocrinology, surgery, nuclear medicine, and radiotherapy, New York, 1990, Raven Press.

76. Krukowski ZH. The thyroid gland and thyroglossal tract. Chapter 53 In: Russel RCG, Williams NS, Bulstrode CJK, edts. Bailey and Love's Short Practice of Surgery. 24th ed. London: Arnold Publication; 2004.p.787.

77. Zygmunt H.Krukowski, Thyroid Bailey & Love 25th Edition, RCG.Russell norman S. Williams & Chirstopher P.796-797

ANNEXURE-1

Name IP No:

Age Date of Admission:

Sex Date of Surgery:

Occupation Date of Discharge:

Address

Chief complaints:

Duration:

Swelling in the Right / Left side of thyroid:

HISTORY OF PRESENT COMPLAINTS:

Duration/Progression

Local Effects

Pressure symptoms- dyspnoea / dysphagia / dysphonia

Symptoms of hyperthyroidism / hypothyroidism

Symptoms suggestive of malignancy

Other symptoms

Past History:

History of previous thyroid disorder

History of goitrogen intake.

Drug history /Radiation exposure

Treatment history

Menstrual History:

Family History:

History of Thyroid disease

History of Diabetes, Hypertension , malignancies

Personal history:

Diet Appetite

Sleep Bowel/Bladder

Habits

General physical examination:

Appearance, build, nutritional assessment

Pallor: Clubbing

Icterus Edema

Cyanosis Lymphadenopathy

Vitals: BP/ Respiratory Rate

Pulse

1. Rate
2. Rhythm

3. Character
4. Volume

Local examination

1. Inspection

a. Site b. Size

c. Shape d. Surface

e. Extent f. Margins

g. Skin over the swelling h. Distended veins/pulsations

i. Movement with deglutition j. Position of trachea

2. Palpation

a. Local temperature b. Tenderness

c. Site, size, shape and extent d. Surface

e. Borders f. Consistency

g. Mobility h. Fixity to skin

i. Plane of swelling j. Examination of lymph nodes

k. Tracheal position

l. Carotid pulsation

2. Percussion

3. Auscultation

Systemic examination

1. CVS 2. RS

3. CNS 4. Per Abdomen

5. Skull and spine.

Investigations

Routine Investigations:

a. Blood Routine: b. Serology: HIV / HBsAg / VDRL

c.ECG d. Chest X-Ray PA view

e. X ray of neck AP and lateral view

f. Indirect Laryngoscopy

Specific Investigations:

a. Thyroid profile- TSH, T3, T4

b. USG neck c. FNAC d. Others

Final Diagnosis:

Treatment

Preoperative Management:

OPERATIVE TREATMENT :

Date : Procedure :

Post-op. diagnosis : Anaesthesia :

Findings :

OPERATIVE DETAILS :

Total lobectomy

Lobectomy / Hemithyroidectomy

Subtotal thyroidectomy

Near total thyroidectomy

Total thyroidectomy

Total thyroidectomy with parathyroid autotransplantation

a. Vocal cords visualization at extubation :

b. Postoperative complications

1. Pain
2. Drainage Volume
3. Hypocalcemia
4. Voice Change.

Follow Up

TSH measurement

Serum Calcium Level

VLE (Video LaryngoScopy)

KEY TO MASTER CHART

IPNO	In Patient Number
DOA	Date Of Admission
DOD	Date Of Discharge
EU	Euthyroid
MNG	Multi Nodular Goiter
SNG	Solitary Nodular Goiter
Rt Hemi	Right Hemithyroidectomy
Lt Hemi	Left Hemithyroidectomy
HPE	Histo Pathological Examination
AG	Adenomatous Goiter
FA	Follicular Adenoma
NG	Nodular Goiter
CG	Colloid Goiter
NCG	Nodular Colloid Goiter

S.No	Name	Age/ Sex	IP NO	DOA	DOD	Diagnosis	Profile	Surgery Thyroidectomy	Post OP HPE	Operative Duration (mins)	Pain Score	Drain 1st day (ml)	Drain 2nd day (ml)	Transient Hypocalcemia	RLN Injury
1	Chellammal	60/ F	75831	29.10.13	17.11.13	MNG	Eu	Sub total	AG	105	4	26	10	NO	NIL
2	Indirani	55/F	79495	08.11.13	14.12.13	MNG	EU	Total	MNG	96	2	36	20	NO	NIL
3	Panchavarnam	55/F	84387	26.11.13	05.12.13	SNG Rt	Eu	Rt Hemi	FA	66	2	20	14	NO	NIL
4	Lakshmi	33/F	85776	29.11.13	07.12.13	MNG	EU	Near Total	MNG	112	2	25	20	NO	NIL
5	Kaleeswari	30/F	90489	17.12.13	01.01.14	SNG Lt	Eu	Lt Hemi	NG	56	0	15	10	NO	NIL
6	Pappathi	50/F	90548	17.12.13	05.01.14	MNG	EU	Total	AG	90	0	34	15	NO	NIL
7	Revathi	30/F	90496	26.12.13	28.12.13	MNG	Eu	Total	NG	90	2	40	32	NO	NIL
8	Chellammal	65/F	94252	31.12.13	21.01.14	SNG Rt	EU	Rt Hemi	AG	64	0	26	10	NO	NIL
9	Mariyammal	50/F	7055	28.01.14	21.02.14	MNG	Eu	Total	MNG	102	0	24	15	NO	NIL
10	Kavitha	27/F	9368	06.02.14	24.02.14	MNG	EU	Total	CG	108	2	36	30	NO	NIL
11	Devi	26/F	10678	11.02.14	04.03.14	SNG Lt	Eu	Lt Hemi	NG	70	2	20	5	NO	NIL
12	Shanmuga Valli	25/F	20136	24.03.14	19.04.14	MNG	EU	Total	MNG	118	2	40	25	YES	NIL
13	Saraswathi	32/F	22897	07.04.14	29.04.14	SNG Rt	Eu	Rt Hemi	MNG	62	2	18	5	NO	NIL
14	Thamilselvi	41/F	23972	12.04.14	26.04.14	MNG	EU	Total	MNG	94	0	20	10	NO	NIL
15	Jeya Rani	36/F	27622	30.04.14	11.05.14	MNG	Eu	Total	NCG	85	2	24	20	YES	NIL
16	Jeya	37/F	25636	21.04.14	10.05.14	SNG Lt	EU	Lt Hemi	FA	62	0	18	5	NO	NIL
17	Chithra	37/F	27066	28.04.14	15.05.14	SNG Lt	Eu	Lt Hemi	NG	68	0	15	5	NO	NIL
18	Pandiselvi	29/F	28497	05.05.14	27.05.14	SNG Lt	EU	Lt Hemi	FG	58	0	15	5	NO	NIL
19	Rajeswari	64/F	28539	05.05.14	27.05.14	SNG Rt	Eu	Rt Hemi	NG	64	2	20	8	NO	NIL
20	Bakiyam	40/F	29866	12.05.14	05.06.14	SNG Rt	EU	Rt Hemi	MNG	74	0	30	20	NO	NIL
21	Sumathi	35/F	32124	22.05.14	05.06.14	MNG	Eu	Total	AG	100	4	40	24	NO	NIL
22	Chithra Pandi	23/F	32839	26.05.14	10.06.14	MNG	EU	Total	AG	126	4	45	30	YES	NIL
23	Praveena	18/F	33638	29.05.14	09.06.14	SNG Lt	Eu	Lt Hemi	FA	55	0	20	5	NO	NIL
24	Thangam	50/F	38852	23.06.14	07.07.14	SNG Rt	EU	Rt Hemi	NG	66	2	18	5	NO	NIL
25	Ramjun Begum	29/F	39438	25.06.14	09.07.14	MNG	Eu	Total	MNG	92	2	28	20	NO	NIL
26	Muthumari	40/F	42687	10.07.14	24.07.14	MNG	EU	Total	MNG	86	2	40	24	YES	NIL
27	Malliga	17/F	43318	14.07.14	24.07.14	SNG Rt	Eu	Rt Hemi	CG	58	0	20	15	NO	NIL
28	Panchu	40/F	43644	16.07.14	31.07.14	SNG Rt	EU	Rt Hemi	FA	55	0	15	5	NO	NIL
29	Pothumponnu	37/F	45819	28.07.14	07.08.14	SNG Rt	Eu	Rt Hemi	CG	65	0	18	15	NO	NIL
30	Meenambal	36/F	46254	30.07.14	26.08.14	MNG	EU	Total	CG	98	4	24	10	NO	NIL
31	Panchavarnam	35/F	46824	20.08.14	01.09.14	MNG	Eu	Total	MNG	116	4	45	30	NO	NIL
32	Palaniyammal	29/F	46999	20.08.14	08.09.14	SNG Rt	EU	Rt Hemi	NCG	70	0	18	10	NO	NIL
33	Maheswari	32/F	48051	23.08.14	10.09.14	SNG Rt	Eu	Rt Hemi	AG	67	2	25	15	NO	NIL

Ref.No.6506/E1/5/2014

Madurai Medical College,
Maduai -20. Dated: 11.09.2014.

Institutional Review Board/Independent Ethics Committee
Capt.Dr.B.Santhakumar,MD (FM). deanmdu@gmail.com
Dean, Madurai Medical College &
Government Rajaji Hospital, Madurai 625 020 . Convenor

Sub: Establishment – Madurai Medical College, Madurai-20 – Ethics Committee Meeting – Meeting Minutes - for August 2014 – Approved list – reg.

The Ethics Committee meeting of the Madurai Medical College, Madurai was held on 05th August 2014 at 10.00 Am to 12.00 Noon at Anaesthesia Seminar Hall at Govt. Rajaji Hospital, Madurai . The following members of the Ethics Committee have attended the meeting.

1.Dr.V.Nagarajan,M.D.,D.M(Neuro) Ph: 0452-2629629 Cell No.9843052029 nag9999@gmail.com.	Professor of Neurology (Retired) D.No.72, Vakkil New Street, Simmakkal, Madurai -1	Chairman
2.Dr.Mohan Prasad, MS.M.Ch. Cell.No.9843050822 (Oncology) drbkcmp@gmail.com	Professor & H.O.D of Surgical Oncology (Retired) D.No.32, West Avani Moola Street, Madurai.-1	Member Secretary
3. Dr.L.Santhanalakshmi, MD (Physiology) Cell No.9842593412 dr.l.santhanalakshmi@gmail.com.	Vice Principal, Prof. & H.O.D. Institute of Physiology Madurai Medical College	Member
4.Dr.K.Parameswari, MD(Pharmacology) Cell No.9994026056 drparameswari@yahoo.com.	Director of Pharmacology Madurai Medical College.	Member
5.Dr.S.Vadivel Murugan, MD., (Gen.Medicine) Cell No.9566543048 svadivelmurugan_2007@rediffmail.com.	Professor & H.O.D of Medicine Madurai Medical College	Member
6.Dr.A.Sankaramahalingam, MS., (Gen. Surgery) Cell.No.9443367312 chandrahospitalmdu@gmail.com	Professor & H.O.D. Surgery Madurai Medical College.	Member
7.Mrs.Mercy Immaculate Rubalatha, M.A., Med., Cell.No.9367792650 lathadevadoss86@gmail.com	50/5, Corporation Officer's Quarters, Gandhi Museum Road, Thamukam, Madurai-20.	Member
8.Thiru.Pala.Ramasamy, B.A.,B.L., Cell.No.9842165127 palaramasamy2011@gmail.com	Advocate, D.No.72,Palam Station Road, Sellur, Madurai-20.	Member
9.Thiru.P.K.M.Chelliah, B.A., Cell No.9894349599 pkmandco@gmail.com	Businessman, 21 Jawahar Street, Gandhi Nagar, Madurai-20.	Member

The following Project was approved by the Ethical Committee

Name of P.G.	Course	Name of the Project	Remarks
Dr.K.Vasanthan drvasanthanms@gmail.com	PG in MS (General Surgery), Madurai Medical College & Govt. Rajaji Hospital, Madurai.	**Analytical study of advantages of harmonic scalpel in thyroid surgery**	**Approved.**

Please note that the investigator should adhere the following: She/He should get a detailed informed consent from the patients/participants and maintain it Confidentially.

1. She/He should carry out the work without detrimental to regular activities as well as without extra expenditure to the institution or to Government.
2. She/He should inform the institution Ethical Committee, in case of any change of study procedure, site and investigation or guide.
3. She/He should not deviate the area of the work for which applied for Ethical clearance. She/He should inform the IEC immediately, in case of any adverse events or Serious adverse reactions.
4. She/He should abide to the rules and regulations of the institution.
5. She/He should complete the work within the specific period and if any Extension of time is required He/She should apply for permission again and do the work.
6. She/He should submit the summary of the work to the Ethical Committee on Completion of the work.
7. She/He should not claim any funds from the institution while doing the work or on completion.
8. She/He should understand that the members of IEC have the right to monitor the work with prior intimation.

Member Secretary
Ethical Committee

Chairman
Ethical Committee

11.9.14
DEAN/Convenor
Madurai Medical College &
Govt.Rajaji Hospital, Madurai- 20.

11/9/14

To
The above Applicant
-thro. Head of the Department concerned

Digital Receipt

This receipt acknowledges that Turnitin received your paper. Below you will find the receipt information regarding your submission.

The first page of your submissions is displayed below.

Submission author:	221211123.ms General Surgery VAS.
Assignment title:	TNMGRMU EXAMINATIONS
Submission title:	ADVANTAGES OF HARMONIC SCA..
File name:	Harmonic_Scalpel.docx
File size:	5.37M
Page count:	105
Word count:	15,093
Character count:	84,377
Submission date:	15-Sep-2014 02:34AM
Submission ID:	450981446

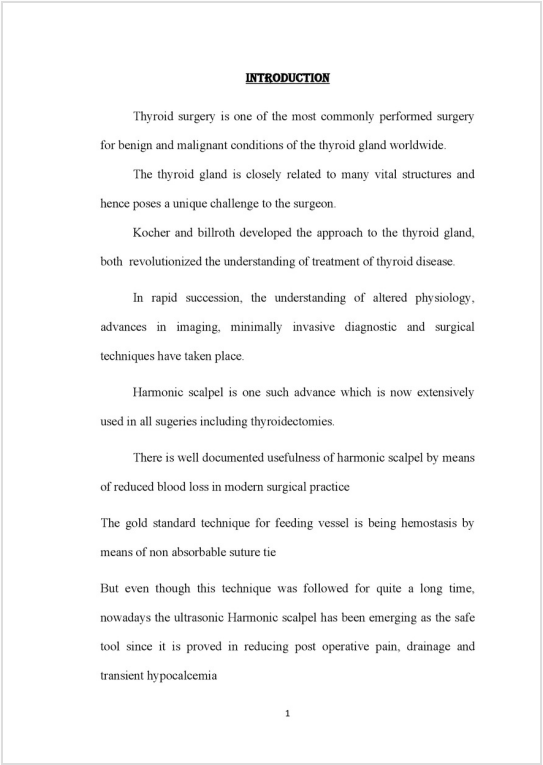

INTRODUCTION

Thyroid surgery is one of the most commonly performed surgery for benign and malignant conditions of the thyroid gland worldwide.

The thyroid gland is closely related to many vital structures and hence poses a unique challenge to the surgeon.

Kocher and billroth developed the approach to the thyroid gland, both revolutionized the understanding of treatment of thyroid disease.

In rapid succession, the understanding of altered physiology, advances in imaging, minimally invasive diagnostic and surgical techniques have taken place.

Harmonic scalpel is one such advance which is now extensively used in all sugeries including thyroidectomies.

There is well documented usefulness of harmonic scalpel by means of reduced blood loss in modern surgical practice

The gold standard technique for feeding vessel is being hemostasis by means of non absorbable suture tie

But even though this technique was followed for quite a long time, nowadays the ultrasonic Harmonic scalpel has been emerging as the safe tool since it is proved in reducing post operative pain, drainage and transient hypocalcemia

1

ADVANTAGES OF HARMONIC SCALPEL IN THYROID SURGERY

BY 221211123.MS GENERAL SURGERY VASANTHAN K

INTRODUCTION

Thyroid surgery is one of the most commonly performed surgery for benign and malignant conditions of the thyroid gland worldwide.

The thyroid gland is closely related to many vital structures and hence poses a unique challenge to the surgeon.

Kocher and billroth developed the approach to the thyroid gland, both revolutionized the understanding of treatment of thyroid disease.

In rapid succession, the understanding of altered physiology, advances in imaging, minimally invasive diagnostic and surgical techniques have taken place.

Harmonic scalpel is one such advance which is now extensively used in all sugeries including thyroidectomies.

There is well documented usefulness of harmonic scalpel by means of reduced blood loss in modern surgical practice

The gold standard technique for feeding vessel is being hemostasis by means of non absorbable suture tie