

“EVALUATION WITH DIFFUSION WEIGHTED MAGNETIC RESONANCE IMAGING IN STAGING AND GRADING OF URINARY BLADDER CANCER”

Dissertation submitted to

THE TAMILNADU DR. M.G.R. MEDICAL UNIVERSITY

*in partial fulfillment of the requirements for
the award of the degree of*

M.Ch (UROLOGY) – BRANCH – IV



THE TAMILNADU DR.M.G.R. MEDICAL UNIVERSITY

CHENNAI

AUGUST 2014

DECLARATION

I solemnly declare that this dissertation titled “**EVALUATION WITH DIFFUSION WEIGHTED MAGNETIC RESONANCE IMAGING IN STAGING AND GRADING OF URINARY BLADDER CANCER**” was prepared by me in the Department of Urology, Madras Medical College & Rajiv Gandhi Government General Hospital, Chennai under the guidance and able supervision of Prof. R. Jeyaraman, M.Ch , Professor & Head of the Department, Department of Urology, Madras Medical College & Rajiv Gandhi Government General Hospital, Chennai. This dissertation is submitted to the Tamil Nadu Dr.MGR Medical University, Chennai in partial fulfillment of the university requirements for the award of the degree of M.Ch. Urology.

Place: Chennai

Date:

DR.RAMKUMAR J

CERTIFICATE

This is to certify that the dissertation entitled “**EVALUATION WITH DIFFUSION WEIGHTED MAGNETIC RESONANCE IMAGING IN STAGING AND GRADING OF URINARY BLADDER CANCER**” is a bonafide work done by **Dr.Ramkumar.J**, Madras Medical College, Chennai, in partial fulfillment of The Tamil Nadu Dr.M.G.R. Medical University rules and regulations for award of MCh (Urology) Degree under my guidance and supervision during the academic year 2011-2014.

Prof.R.Jeyaraman MS, MCh
Guide,
Department of Urology,
Madras Medical College & RGGGH
Chennai – 600003

Prof.R.Jeyaraman MS, MCh
Professor & HOD
Department of Urology,
Madras Medical College & RGGGH
Chennai - 600003

Dr.R.Vimala, MD.,
Dean,
Madras Medical College & RGGGH,
Chennai - 600003

CERTIFICATE

This is to certify that the dissertation titled **“EVALUATION WITH DIFFUSION WEIGHTED MAGNETIC RESONANCE IMAGING IN STAGING AND GRADING OF URINARY BLADDER CANCER”** submitted by **Dr.RAMKUMAR J** appearing for **M.Ch. (Urology)** degree examination in August 2014, is a bonafide record of work done by him under my guidance and supervision in partial fulfillment of requirement of the Tamil Nadu Dr.M.G.R. Medical University, Chennai. I forward this to the TamilNadu Dr.M.G.R. Medical University, Chennai.

Prof.R.Jeyaraman, M.S. M.Ch,
Professor & Head of the Department,
Department of Urology,
Madras Medical College and
Rajiv Gandhi Government General Hospital,
Chennai- 600 003.

Dr. R.Vimala M.D
The Dean,
Madras Medical College and
Rajiv Gandhi Government General Hospital,
Chennai- 600 003.

ACKNOWLEDGEMENTS

First of all, I would like to thank my patients, who subjected themselves for my dissertation work.

I whole heartedly thank **The Dean**, Madras Medical College and **Rajiv Gandhi** Government General Hospital, Chennai for allowing me to avail the facilities needed for my dissertation work.

I am very grateful to my esteemed teacher and guide **Prof. R.Jeyaraman**, M.Ch, Professor and Head of the Department of Urology, for inspiring me to work on this subject. His boundless enthusiasm, encouragement and constant support, constructive criticism and valuable guidance at every step were instrumental in the completion of this study. I consider myself extremely fortunate to have worked under his expert guidance.

I would like to thankfully acknowledge **Prof.V.Kamaraj** and **Prof. RM. Meyyappan**, Professors in the Department of Urology, for their constant help in the dissertation work.

I sincerely thank the Director, Barnard Institute of radiology for helping in completing my dissertation.

I owe my special thanks to the Director, Institute of Pathology, MMC for helping in completion of my study.

I sincerely thank the Assistant Professors in the Department of Urology for their continuous inspiration and support in carrying out my dissertation.

I would also like to thank my parents, my wife, my son and all my family members for their love, sacrifice, prayers and support throughout my career.

Last, but not the least, I thank my fellow past and present postgraduates who helped me in carrying out my work and preparing this dissertation.

INDEX

S NO	CONTENTS	PAGE NO
1	Introduction	1
2	Aim and Objectives	3
3	Review of Literature	4
4	Materials & Methods	26
5	Observation & Results	30
6	Discussion	44
7	Conclusion	52
8	Bibliography	
9	Appendices 2009 TNM Staging & 2004 WHO grading Consent Form & Information Sheet Proforma Master Chart Ethical committee approval Abbreviations Plagiarism	

INTRODUCTION

Bladder cancer is a common genitourinary tract malignancy. Following prostatic adenocarcinoma, it represents the second most common tumour of urological malignancy in the world¹. Urothelial tumours are cancers of the environment and advanced age. Bladder cancer is associated with old age and exposure to industrial toxins and smoking. It occurs most commonly in males than compared to female patients with ratio of 3:1 and is rare in the population less than 40 years of age.

According to WHO 2004 classification, urothelial tumours are categorized to muscle non-invasive and muscle invasive, based on invasion of detrusor muscle. Eighty percent of urothelial cancers are non-muscle invasive in nature and present with various types of growth pattern. Muscle-invasive tumour is defined by high grade and cancer cells invading through the lamina propria into the deeper muscle layers. Histologically, urothelial carcinoma constitutes 90 percent of bladder cancers, five percent are squamous cell carcinoma and less than five percent are adenocarcinoma or other types of tumours.

The management of bladder cancer varies according to muscle non-invasive and muscle invasive nature of the cancer. Muscle non-invasive tumours are managed with transurethral resection (TUR) and intravesical immunotherapy /

chemotherapy. The treatment options for muscle invasive bladder cancer are radical cystectomy, radiation therapy, chemotherapy, or a combination. Thus it would be prudent to diagnose and differentiate between these two categories preoperatively by imaging techniques which helps in planning the treatment and in identifying the prognostic factors.

Though contrast-enhanced computed tomography (CECT) and magnetic resonance imaging (MRI) are primarily used for diagnostic imaging, dynamic MRI has been found to be superior to CT for staging. With dynamic MRI, the primary drawback is the overstaging². Contrast agents can have adverse effects and also can impair renal function. Contrast agents are contraindicated with raised renal parameters as there is risk of contrast induced nephropathy with iodine based agents used for CT or nephrogenic systemic fibrosis with gadolinium based contrast agents used for MRI. Diffusion-weighted MRI (DW-MRI) is a recent technical development in MRI which is noninvasive and based on the visualization of the molecular diffusion in biologic tissues. DW MRI is useful for depicting malignant tumors. Apparent diffusion coefficient (ADC), is a quantitative parameter calculated from the DW MRI which combines the effects of capillary perfusion and water diffusion in the extracellular extravascular space. ADC can characterize tumor grades and thus aids in determining prognosis.

AIM AND OBJECTIVES

- To predict the pathological stage and grade of bladder cancer preoperatively by using Diffusion weighted Magnetic Resonance Imaging.
- To study the correlation of Diffusion Weighted MRI findings with clinical, radiological and pathological findings.

REVIEW OF LITERATURE

The bladder urothelium is made up of transitional cells, which can be transformed into various benign and malignant tumours. Bladder cancer is associated with advanced age and exposure to environmental toxins, primarily cigarette smoking. Total of 68810 new cases are diagnosed in United States and account for seven percent of all cancers. It is three times more common in males than in females and rare in age group less than 40 years. The median age for diagnosing a bladder tumour is seventy years and morbidity and mortality rate increase with advanced age.

It is caused by hereditary abnormalities, industrial toxins³, cigarette smoking⁴, dietary deficiencies, chronic infection, inflammation, stone disease and chemoradiotherapy. The risk factors are hereditary and race which is explained by the presence of disease in first-degree relatives of patients with bladder cancer have a twofold increased risk of developing bladder cancer themselves, but high-risk of bladder cancer families are relatively rare. It most commonly occurs in Whites than compared with Africans-Americans.

Bladder cancer most commonly occurs in males than compared to female patients with ratio of 3:1 and rare in age less than 40 years, the reasons for the aged male prevalence are unclear but may be associated with large residual urine in the

bladder. Advanced age increases risk of cancer and most commonly present in the seventh decade of life.

RISK FACTORS FOR UROTHELIAL TUMOUR:

Cigarette smoking is one of the most important causes for development of bladder cancer. Smokers have a two to six fold risk compared to non-smokers, with respect to development of bladder cancer and subsequent recurrences⁵. Cigarette smoke contains the carcinogens like 4-aminobiphenyl and 2-naphthylamine. Slow hepatic acetylation of 4-aminobiphenyl by N-acetyltransferase and glutathione S-transferase appear to increase urinary carcinogenic exposure of the urothelium⁶.

Approximately twenty five percent of all urothelial cancers are related with occupational exposure to carcinogenic agents especially aromatic hydrocarbons. Aromatic amines bind with DNA and induce carcinogenesis. Usually a latent period of ten to twenty years occurs between toxin exposure and carcinogenesis⁷.

Chemical agents commonly implicated for formation of carcinoma bladder are 4-Aminobiphenyl, Benzopyrene, Benzidine and β -Naphthylamine. These carcinogenic agents enter the system through skin absorption and inhalation. It can also be caused by consumption of large quantities of acetaminophen, chemotherapeutic agent like cyclophosphamide and pelvic radiotherapy.

Urinary bladder is storage organ, many micro nutrients and their end products have long duration of contact with urothelium. These micronutrients play the most important role in preventing the carcinogenesis. Various fresh vegetables and fruits specifically like carrots, apples, lemon, tomatoes and cruciferous vegetables contain various substances that are vital role in degradation carcinogenic agents. The molecules such as antioxidants, coenzymeQ and vitamins are preventing oxidative damage of DNA.

Increased fluid intake prevents concentration carcinogenic agent's contact with urothelium. Various studies showed increased fluid intake associated with lesser incidence of urothelial tumors compared with less fluid intake⁸.

Alcohol

Alcohol intake is associated with various cancers like stomach, liver, oral cavity, oesophagus and larynx. Analysis from various literatures showed no positive correlation between alcohol intake and urothelial cancers⁹.

Artificial sweetener

Various studies in animals and humans have shown no association between consumption of artificial sweeteners and bladder cancer.

Drugs

Acetaminophen is the metabolite of phenacetin. It is most commonly used for fever and analgesics purposes. Intake of phenacetin around five to fifteen kilograms over the ten years associated increased risk of bladder and renal cancers⁴.

Inflammation/Infection

Chronic infection and inflammation is a contributor to the development of squamous cell carcinoma. Patients infected with *Schistosoma hematobium*, human papilloma virus and B K virus are associated with squamous cell carcinoma. HPV virus encodes E6, E7 oncoproteins, which have influence on bladder cancer and its progression¹⁰. Previous gonorrhea infections associated with high risk for development of invasive cancer than noninvasive cancer¹¹.

Patients with long term indwelling catheters and stones have high risk of development of bladder cancer. Chronic inflammation of bladder mucosa by vesical calculus and other nidus including a long standing indwelling Foley's catheter are associated with transformation to squamous cell carcinoma¹².

The process of carcinogenesis is due to production of nitrosamines by chronic urinary tract infections. These carcinogenic agents are produced by chronic infections with *E.coli* and *pseudomonas* organisms¹³.

Radiation

Radiation is rare cause of development of bladder cancer. It mostly follows treatment with radiotherapy for prostatic and cervical cancers. The latency period for development of carcinogenesis is from 15 to 30 years¹⁴. Radiation from more than 6 computed tomogram scan in a year is associated with secondary malignancies

Chemotherapy

Chemotherapy used to treat the cancers to destroy the malignant cells and also cause damage to normal cells. Cyclophosphamide is the chemotherapeutic agent implicated in carcinoma bladder by means of direct relation to its duration and dose. The main mutagenic metabolite responsible for the development of cancer in patients who exposed to cyclophosphamide is phosphoramidate mustard¹⁵.

Pathogenesis

The bladder urothelium is multi-layered structure. It contains six cell layer thicknesses with umbrella cells. Most of the primary bladder cancers are malignant and of epithelial in origin. The urothelium is capable of transforming into different histopathological types of cancers¹⁵. Nearly ninety percent tumors of urinary bladder are transitional cell type and remaining 7% include squamous cell carcinoma, adenocarcinoma and undifferentiated tumors.

In Egypt and Middle East countries, Schistosomiasis infection is common and implicated for development of cancer. These patients develop squamous cell carcinoma of the bladder and constitute 55% to 80% of all bladder cancers. Secondary bladder cancers are mostly metastatic adenocarcinoma from gut, prostate, kidney and ovary.

Premalignant lesions of bladder Cancer

Precursor lesions are developed in a regular fashion from hyperplasia to cellular atypia to dysplasia and development of cancer.

Hyperplasia

Urothelial hyperplasia is defined by thickened mucosa and presence or absence of atypical cellular changes. The bladder urothelium contains greater than seven cells layer thickness and disorganization of cellular structure present. It is associated with low grade cancers and no increased risk of development of cancer.

Atypia

Reactive atypia histopathologically defined by large cells, nucleus abnormality and presence of abnormal nucleoli. It may be associated with infection, stones, previous instrumentation and intravesical therapies.

Dysplasia

Urothelial dysplasia is histologically defined by presence of cohesive cells and abnormality in the nucleus. The urothelium is greater than seven cells thickness and nuclear changes include nucleus crowding, prominent nucleoli, and abnormal mitotic figures present. Umbrella cells are normally seen in dysplastic urothelium and absent in cases of carcinoma in situ. Dysplastic urothelium is indicator of urothelial cell instability and associated with transformation of high grade lesions.

Urothelial Cancer Histology

WHO graded the Non- muscle invasive bladder cancer into three categories. It includes 25 % of papillary urothelial neoplasia of low-malignant potential, fifty percent of low grade and twenty five percent of high grade lesions. The WHO 2004 grading/2009 TNM staging of bladder cancer as in (Annexure).

Carcinoma in situ (CIS)

All CIS are high grade lesions. It is characterized as flat, red velvety and nonpapillary lesion, histologically characterized by loss of umbrella cells, noncohesive cellular structure, loss of cellular polarity and severe nuclear atypia. The genetic abnormalities include alterations in the RB, TP53, and PTEN genes. It is immunohistochemically stained for cytokeratin 20. It is a precursor lesion for all

invasive tumours. It spreads to underlying urothelium, distal ureters and prostatic urethra by direct invasion of tumour cells.

Papillary urothelialneoplasia of low-malignant potential

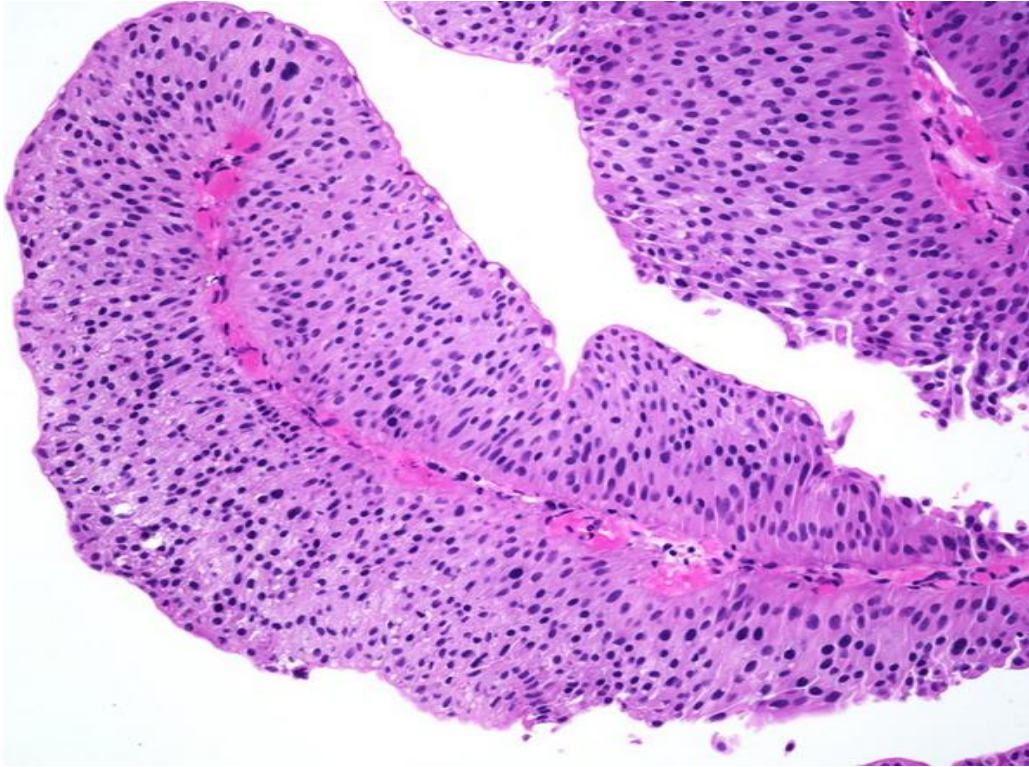
PUNLMP is a solitary, papillary growth with thin papillary stalk usually located at trigone of bladder. Histologically characterized by more than seven cells layer thick with minimal cytological atypia and nucleus is mildly enlarged.

Low-grade bladder carcinoma:

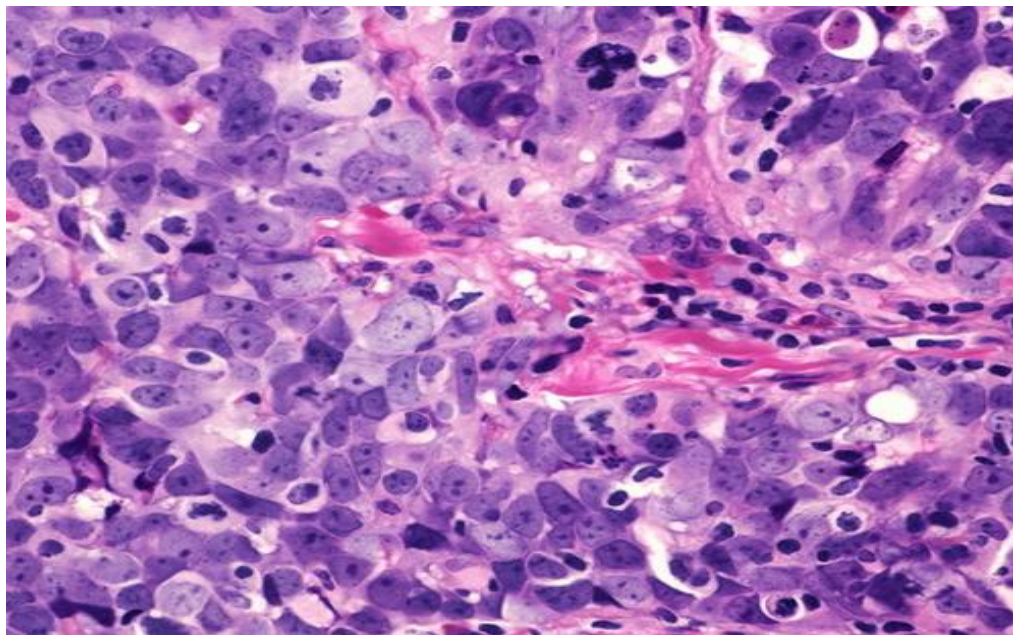
Low-grade lesions are characterized by papillary pattern with thin fibrovascular pedicle and branching fronds present, histologically characterized by large cellular size, atypical nucleus changes and mitotic figures. Lymphovascular spread occurs once tumour invades the lamina propria because it contains rich vascular network.

High-grade Papillary Urothelial Cancer

It is macroscopically characterized by fusion of papillary growth, with high-grade lesions in the urothelium. Histologically characterized by altered growth pattern, pleomorphic cells, increased mitotic figures and exaggerated nuclei, more than 80% of these cancers will infiltrate the underlying structures if patient is not treated.



HPE above showing Low-grade papillary urothelial carcinoma



HPE above showing High -grade papillary urothelial carcinoma

Muscle-invasive bladder cancer

It is defined by high grade cancer cells infiltrating both lamina propria and detrusor muscle layer. It may also spread to adjacent perivesical tissues. Tumour spreads by direct tumour extension to detrusor muscle, prostate, urethra, ureteric orifices, uterus, vagina, perivesical fat, bowel and pelvic side walls. Lymphatic spread occurs into obturator and iliac group of lymph nodes. Blood borne metastasis commonly occurs into liver, lung, adrenal and bones.

Clinical features

Symptoms

Main clinical symptom is total painless hematuria is usually seen in 85% of patients and microscopic hematuria occurs in all cases¹⁶. Patients with carcinoma in situ or invasive tumours present with urinary frequency, urgency and dysuria. Bladder cancer may cause symptoms of acute urinary retention, bladder outlet obstruction, suprapubic discomfort and suprapubic mass. It can also present with intractable hematuria or clot retention of urine.

Patients with metastasis presented with systemic symptoms of anorexia, weight loss, jaundice, pathological fractures, pelvic pain or weakness.

Signs

On clinical examination, patients have pallor due to blood loss and chronic renal impairment. Jaundice or hepatomegaly occurs due to liver metastasis. Abdominal examination may reveal palpable mass in suprapubic region in case of locally advanced disease. Digital rectal examination may reveal palpable mass above or involving the prostate.

Laboratory investigation

According to AUA guide lines patients with hematuria are evaluated with urine cytology, urethroscopy and upper tract imaging. This guide line recommends consideration of reevaluation in low risk patients and obligatory reevaluation in high risk patients after six months. Those with high risk patients are age more than 40 years, history of gross hematuria, history of smoking, industrial toxin exposure, analgesic abuse, irritating voiding symptoms, pelvic radiation and prior Cyclophosphamide therapy.

Routine urine examination

It shows plenty of red blood cells on microscopic examination.

Urine Cytology

Cytological examination of urine is a widely accepted test and a first line investigation in high risk patients with hematuria and irritative urinary symptoms.

It involves microscopic examination of stained smears of urine. It is used as diagnostic test to identify malignant cells and to monitoring the patients in postoperative follow up periods. Urine cytology has low sensitivity but high specificity for high-grade lesions and CIS.

Urinary markers

Urinary markers tests used to replace or complement the urinary cytology to diagnose the urothelial cancers. It has been developed to detect blood group antigens, tumour associated antigens, extracellular matrix proteins and growth factors.

BTA test

The human complement factor H-related protein detected by quantitative BTA TRAK and qualitative BTA stat tests. The sensitivity of these tests range from 50% to 80%, and the specificity ranges from 50% to 75%. Compared with urinary cytology BTA test is more sensitive test to detect urothelial tumours. A false positive result occurs in patients with hematuria infection and inflammation.

ImmunoCyt

It is immunofluorescent assay and a hybrid of cytology. Three fluorescent labelled monoclonal antibodies are targeted at bladder cancer variant of CEA and two urinary bladder mucins. The Sensitivity of the test is 86% and specificity of

the test is 79 % in detecting urothelial cancers. It is not affected by benign conditions and its results are operator dependent

NMP22 Bladder Chek Test

The test is used principles of identification of nuclear matrix protein 22 from urine. It is a portion mitotic apparatus released from nucleus during apoptosis of urothelial cells. NMP22 level are raised in patients with urothelial cancers¹⁷. A false positive result occurs in patients with hematuria, urinary tract infection, stones and post endoscopic procedures. The sensitivity of the test ranges from 68.5% to 88.5% and specificity from 65.2% to 91.3%. The test is more sensitive than urine cytology but overall specificity less.

UroVysion

It is a cytology-based test, that utilises FISH of DNA probes” chosen to detect certain chromosomal foci. The probes used to detect aneuploidy of chromosomes 3, 7, and 17. The test got very high specificity to detect the urothelial tumors with currently available urinary markers¹⁸. The test will identify any chromosomal abnormalities before the development of clinical tumours. False positive results occur in patients with stones, inflammation and hematuria.

Serum markers

Several studies evaluated the serum levels of CA-125, CA19.9 and carcinoembryonic antigen (CEA) with muscle invasive and metastatic tumours¹⁹. These markers were elevated in patients with extravesical disease and distant metastatic disease. Following chemotherapy the tumour responsiveness also correlated with serum marker levels²⁰.

Other serum markers

Patients with muscle invasive and metastatic bladder cancers are associated elevated serum levels of various cytokines and growth factors. The growth factors are transforming growth factor beta-1 insulin growth factor-1 and IGF binding protein3,

E-cadherin

It is a proteolytic derivative of cell adhesion molecule. Carcinoma bladder with loss of expression of E-cadherin molecules associated with high risk of cancer progression.

The presence of circulating tumours cells associated with various stages of invasive tumours and metastatic disease.

Tissue Markers

Patients with fifty per cent of high grade lesions are associated with altered levels of retinoblastoma gene and p53 gene. Loss of expression E-cadherin molecules associated with advanced pathologic stage and poor outcome after radical cystectomy. Proliferation markers like as Ki-67 markers of angiogenesis and markers of apoptosis like Caspase 3, survivin, bcl-2 associated with poor outcomes.

All patients with microscopic or macroscopic haematuria require investigation of upper urinary tracts, bladder, and urethra. It includes renal ultrasound, flexible cystoscopy, followed by intravenous urogram and contrast enhanced computed tomogram.

Computed tomogram

Plain and contrast enhanced computed tomogram is the first-line of radiological investigation in case of carcinoma bladder. It is more sensitive and faster than intravenous urogram and ultrasound in the detection of bladder tumours. CT findings suggestive of perivesical stranding and hydroureteronephrosis indicate muscle invasive tumours²¹.

Hydroureteronephrosis can also be caused by tumour infiltrating the ureteric orifice or ureteric obstruction by enlarged lymphnode. It can also identify

involvement of adjacent structures like bowel and pelvic side walls. It provides imaging of the obturator, internal iliac, external iliac, common iliac and retroperitoneal lymphnodes. The presence of pelvic and retroperitoneal lymphnodes indicates muscle invasive nature of the tumour.

Metastatic workup

Chest X ray is more important for evaluation of secondary deposits in the lungs and mediastinal lymphadenopathy. Chest CT is performed any abnormality detected in chest X-ray, muscle invasive tumours, node positive disease and presence of solid organ metastasis.

Bone scan indicated in high risk patients, new onset of skeletal pain and raised alkaline phosphatase. An MRI scan is useful in patients with history of contrast allergy and doubtful lesions in the bone scan. The new ferromagnetic nanoparticles used as contrast agent can be taken up by macrophages and detect as small as 3 mm metastatic foci.

Positron emission tomography is used to identify patients with lymph nodal and distant metastatic disease in muscle invasive urothelial tumours. It is useful in monitoring and assesses tumour responsiveness to the chemotherapy and radiotherapy.

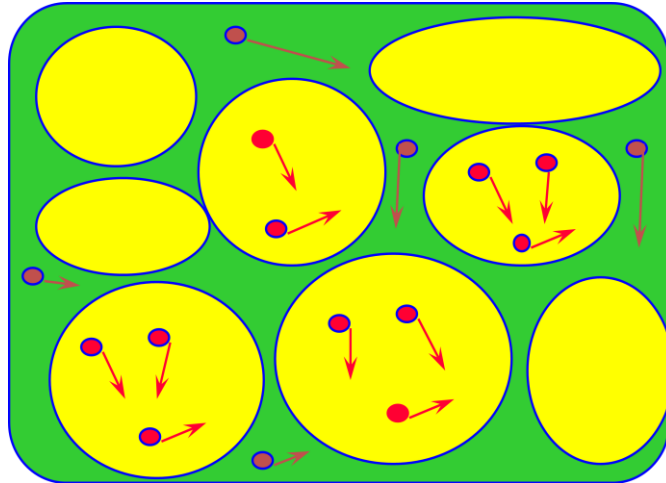
Magnetic Resonance Imaging (MRI)

The excellent soft tissue resolution provided by MRI makes it superior to CT²². This helps in detecting adjacent organ involvement. On T1-weighted images, there is striking inherent contrast between the intermediate-signal-intensity bladder wall and bright perivesical fat. Dynamic MRI using contrast agents identifies the tumour better and stages the tumour better²³. Perivesical involvement is identified using fat suppression techniques after enhancement²³. Overstaging with dynamic MRI is seen in about 30% of cases². The interval between the imaging procedure and TUR had not changed the accuracy of staging. According to Barentsz study, tumor T staging accuracy was 73%-96% of cases, and the nodal and metastatic staging accuracy was 73%-98% of cases²⁴.

DIFFUSION WEIGHTED MAGNETIC RESONANCE IMAGING

(DW MRI)

Diffusion-weighted imaging (DWI) is a recent technical development in the field of MRI, based on diffusion mobility of water molecules the tissue characteristics are obtained and these differ from T1 weighted or T2 weighted images. Brownian motion or the movement of the water molecules forms the basis of the diffusion weighted MRI²⁵. It is the restriction to the movement of protons in the water molecules.



Restricted Diffusion = Bright

The mobility of the protons is quantitatively measured with the parameter the apparent diffusion coefficient (ADC). ADC depends on the environment where the protons are situated which is both qualitatively and quantitatively assessed. In tumors which are highly cellular and which has higher density of cell membranes there is restricted motions of proton molecules. DW MRI is used in clinical practice by measuring the signal intensity and the ADC values and the restricted motion of protons is seen as high signal intensity on DW MRI images with a corresponding low ADC²⁶.

DW MRI has been used as a diagnostic tool for a number of years in the field of neuroradiology²⁷. In the hyperacute phase of cerebral ischemia, DW sequences play an important part in the diagnosis. The practical value of DW MRI is used to differentiate between the tumors and ischemia. Various studies have

shown that ADC values of malignant lesions of renal, prostatic, colonic, hepatic, and uterine cervical origin were lower than those of normal tissue or benign lesions^{28,29,30,31,32}.

Recently DW MRI has been used in extracranial organs both to monitor treatment response and tissue characterization and in evaluating function of different organs. Due to extreme sensitivity to motion which is from breathing and bowel movements and artefacts, which results in a high signal to noise ratio and did not permit to obtain thin-slice imaging, hence the role of DW MRI was initially limited to the cranial cavity. Takahara in his study has reported abdominal DW MRI with free breathing, made it possible to obtain images with the help of high-quality multiplanar display with more adequate thin slices with multiple signal averaging, higher signal-to noise ratio³³.

Mastuki in his study retrospectively had demonstrated DW MRI can differentiate bladder cancers from the surrounding non neoplastic structures due to the presence of high signal intensity and low ADC values. Other studies have shown DW MRI is superior in staging organ-confined tumors compared to T2-weighted sequences²⁶. Takeuchi in his study has shown the superior staging accuracy of DW MRI and helps in predicting histologic grade of tumor with ADC values³⁴.

MANAGEMENT OF BLADDER CANCER:

To discuss the management of carcinoma bladder, after local staging workup, patient is subjected for transurethral resection of bladder tumour and it provides definitive histological diagnosis. Cystoscopic appearance of infiltrating tumour includes size more than 5 cm, solid, sessile lesion and associated with bullous edema and ulceration.

It is usually done under spinal or general anaesthesia and bimanual examination is necessary before and after TURBT. Obturator nerve block is indicated in those patients undergoing TURBT under regional anaesthesia³⁵. It includes resection of tumour as well as resection of underlying detrusor muscle to assess the muscle invasion. Areas of red velvety patches around the tumours and prostatic urethra are biopsied if planned for reconstructive procedures. On histopathological examination careful observation is done for tumour type, grade, and presence or absence of detrusor muscle invasion. Grade of the tumour is the most important prognostic factor.

Re- TURBT is indicated in patients with incomplete initial resection, biopsy report shows absence of muscle tissue and definitive high grade lesions. It is done two to six weeks after initial TURBT.

After TURBT patients with solitary, primary, low grade lesions require immediate intravesical instillation of 40 mg of Mitomycin C. Various chemotherapeutic agents administered intravesically like Adriamycin, thiotepa, epirubicin and gemcitabine. It will prevent the implantation of tumour cells and reduce the recurrence rate of tumour.

Intravesical BCG is indicated in recurrent, multiple low grade tumors, T1 tumors and CIS lesions. Dosing schedule of intravesical therapy includes both induction as well as maintenance regimen. Induction therapy comprises six weekly instillation 80 mg of BCG, followed by maintenance therapy including three weekly administrations at third, six month followed by every six months upto three years. It is absolutely contraindicated immediately after TURBT and with history of BCG sepsis, hematuria, traumatic catheterization and in immunocompromised patients and incontinent patients.

Management of muscle invasive tumour

Radical cystectomy with bilateral pelvic lymphadenectomy and urinary diversion is standard line of management in patients with muscle invasive urothelial tumors. The aim of therapy is complete removal of primary tumour and regional lymph nodes. It includes removal of the bladder, perivesical soft tissues, seminal vesicles and prostate in male patients.

In female patients along with bladder specimen, adjacent organs such as uterus, cervix, ovaries and anterior vagina are also removed. Recent studies suggest that metastatic disease is uncommon in female internal organs and preservation of these organs provide good support for pelvic floor and neobladder.

Pelvic lymph nodal metastasis is present in 20% to 25% of patients with urothelial tumours. Positivity in lymph nodes patients is associated with poor prognosis and reduced recurrence free survival compared with node negative patients.

Boundaries of standard pelvic lymphadenectomy include laterally from genitofemoral nerve upto the internal iliac artery medially, Cooper ligament inferiorly, and common iliac artery superiorly. Extended lymph node dissection includes removal of lymphnodes upto bifurcation of aorta or inferior mesenteric artery.

American joint committee on cancer seventh edition manual describes nodal metastasis cranial to common iliac nodes denote metastatic disease. It recommends at least twelve lymphnodes should be removed. Various multicentre studies reports suggest that sensitivity of lymph node dissection is improved if number of nodes removed is between 15 and 30.

PATIENTS AND METHODS

STUDY DESIGN

Prospective cross-sectional diagnostic study

PLACE OF STUDY

This study was conducted in the Department of Urology, Rajiv Gandhi Government General Hospital, Madras Medical College, Chennai - 3.

STUDY PERIOD

March 2013 to March 2014

ETHICAL CLEARANCE

The institutional ethical review board at our hospital approved the study.
(No 33032013)

INCLUSION CRITERIA

All new patients presented with total hematuria were evaluated initially with ultrasonography of abdomen and pelvis and diagnosed cases of Carcinoma bladder were included.

EXCLUSION CRITERIA

1. Patients with Previous TURBT
2. Previously received intravesical therapy, systemic chemotherapy and external beam radiotherapy.

METHOD OF STUDY

Informed consent obtained from all the patients after explaining details of the study. All details were recorded in a proforma as an inpatient procedure. Analysis was done with the collected details prospectively.

PATIENT EVALUATION

All cases of carcinoma bladder was evaluated by clinical examination, renal function tests, urine cytology, imaging studies in the form of USG/CECT KUB. DW MRI of KUBU region was taken at the time of hospital admission. The TUR procedure was done within one week from the imaging procedure.

MR Imaging

Before obtaining DW MRI, bladder distension was necessary. MR imaging was performed with 1.5-T clinical MR systems (Magnetom Siemens Medical Solutions, Germany) with body phased-array coils using eight elements. MR images were initially taken with axial T2-weighted images of the kidney, ureter and urinary bladder region, using band width = 40 – 80 kHz, TE = 90–100 msec,

TR = 8000 msec, slice thickness of 3 to 5 mm, with intersecting gap of around 1mm. Then DW MRI was taken by using parameters of band width = 142 kHz, TE minimum, TR = 8000 msec, slice thickness of 3 to 5 mm without intersecting gaps, with b values of 0 and 800 sec/mm², upto 54 slices were obtained within 1 to 2 minutes.

ADC CALCULATIONS

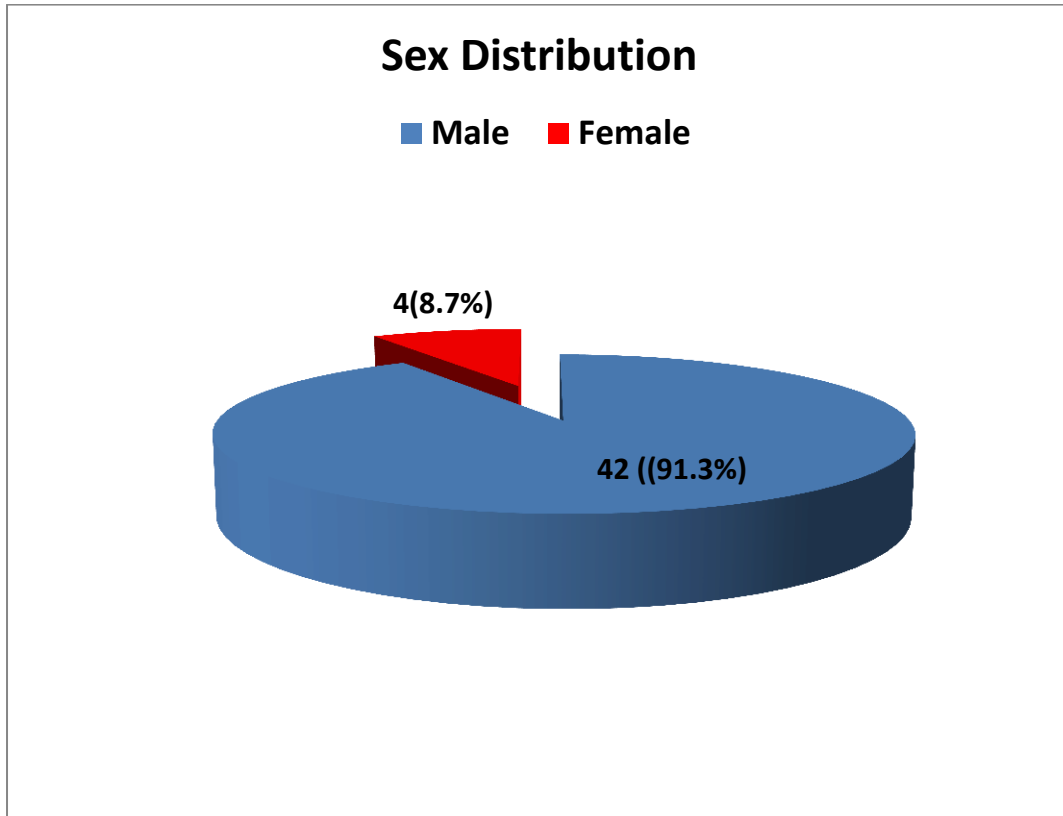
ADC mapping is done at the console of the MRI. With linear regression analytic function the ADC values were calculated. The tumor boundaries were selected based on the appearance of tumor on T2-weighted imaging. We also measured the ADC values of bladder tumours and surrounding structures i.e, the seminal vesicles, prostate, urine and normal urinary bladder wall. The mean ADC values of the tumours were measured and atleast two or three ADC measurements per lesion were taken depending upon the size of the lesion.

Patients will then undergo Transurethral Resection of Bladder Tumour / cystectomy within one week after the imaging procedure. After the procedure the specimen was sent for histopathological examination. Then DW MRI findings were correlated with Clinical, Imaging and the pathological findings.

STUDY ANALYSIS

The Statistical Package for the Social Sciences (SPSS) version 11.5, SPSS Inc, Chicago, IL, USA was used for the statistical analysis. Using multivariate analysis, the ADC values of bladder tumour, normal bladder wall, urine, seminal vesicle and prostate were compared. A p value of less than or equal to 0.05 was considered to be statistically significant.

OBSRVATIONS & RESULTS:



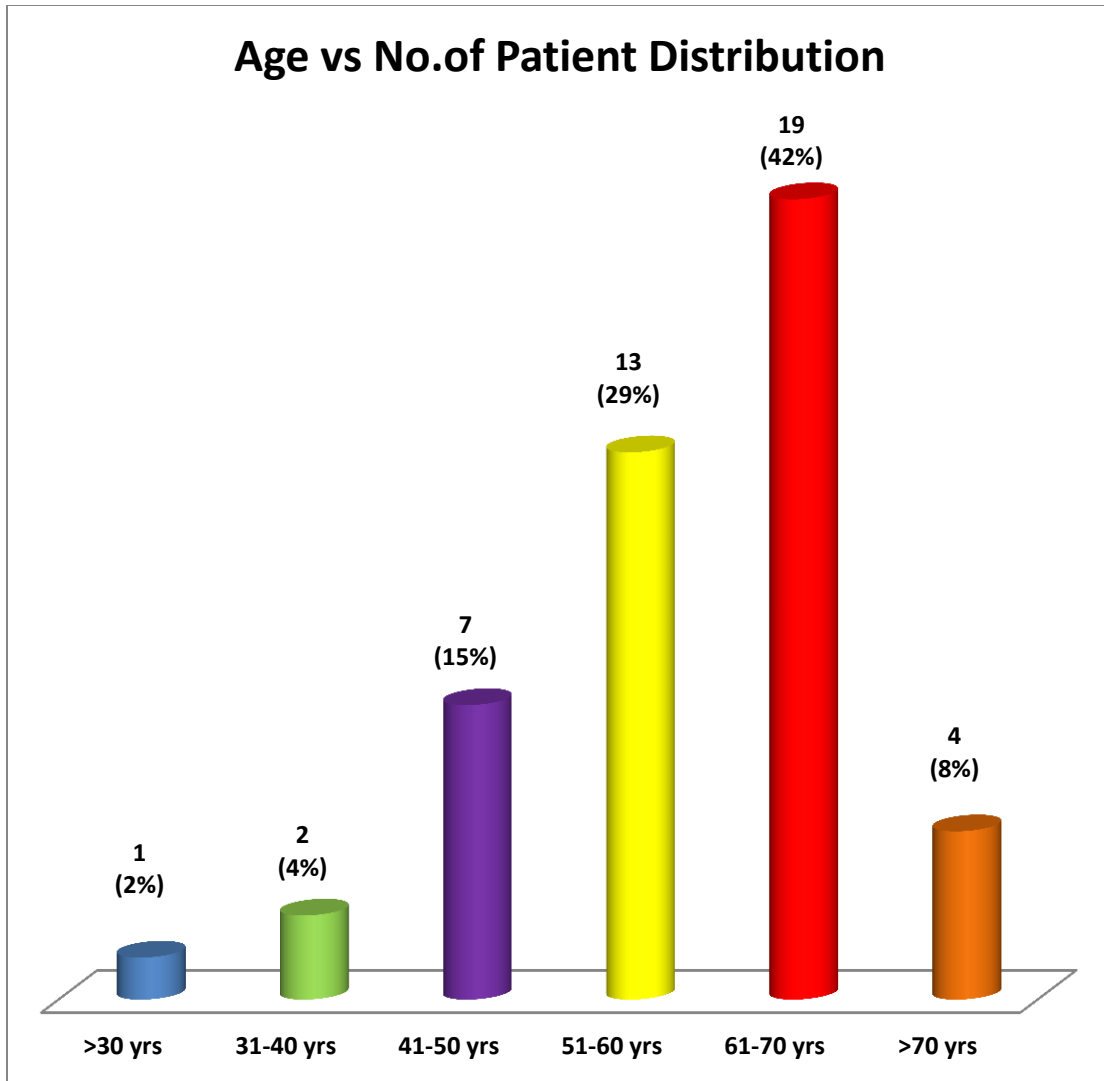
Our total study group included,

Total - 46 patients,

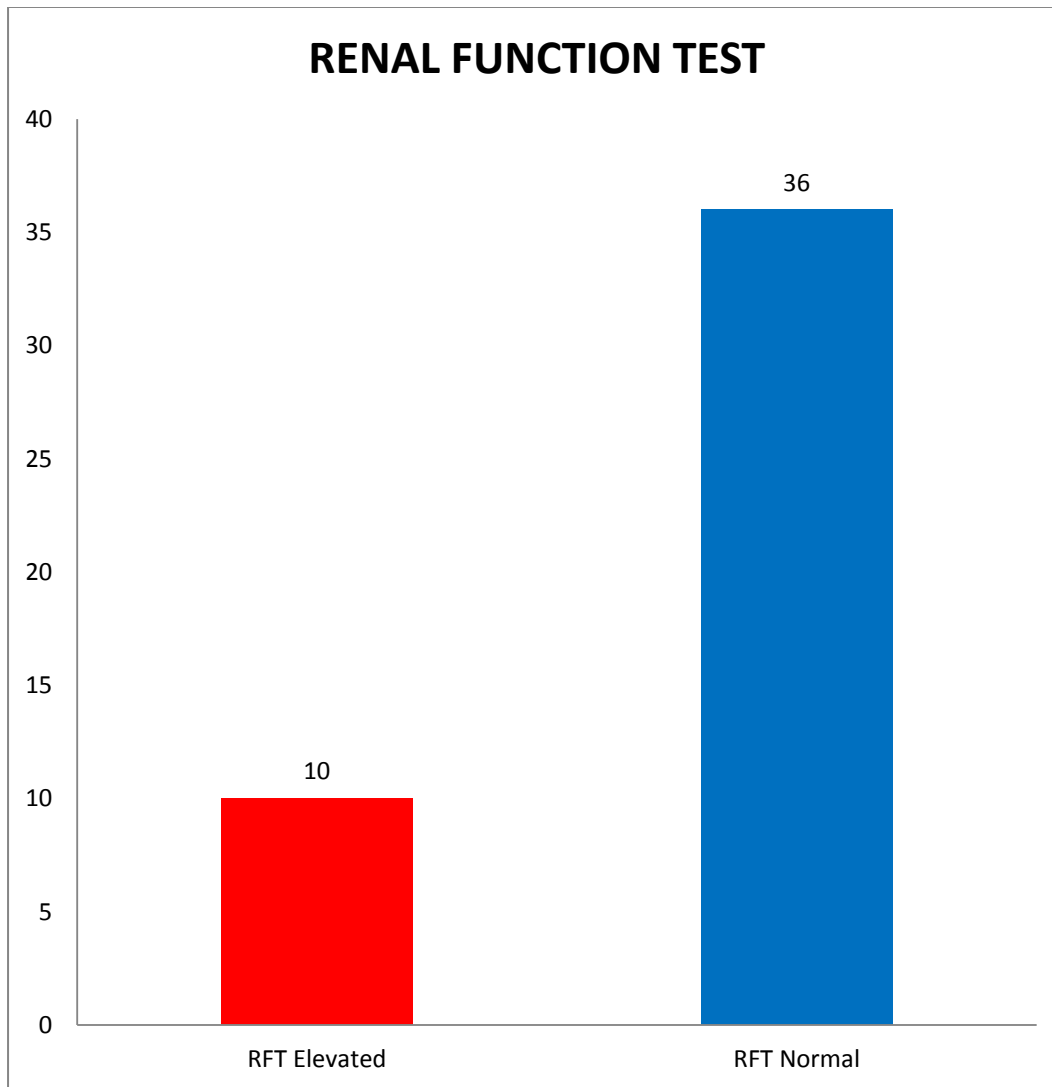
Males – 42 (91.3%) and

Females – 4 (8.7%)

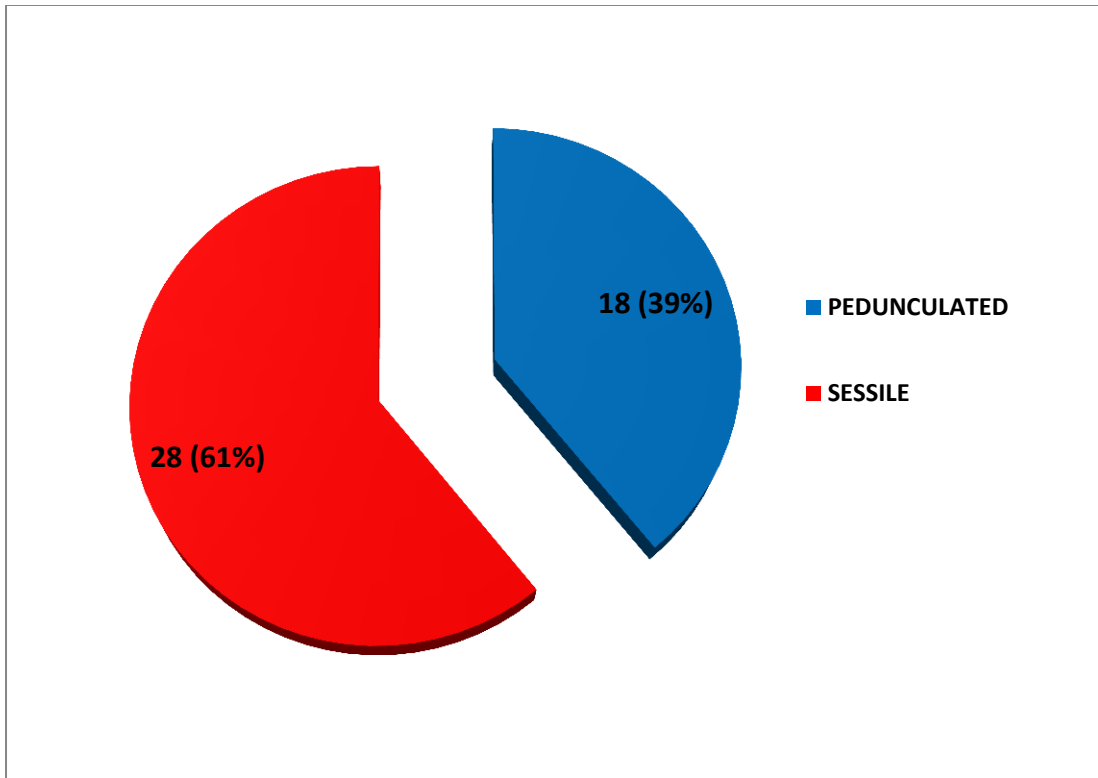
Male: Female Ratio was 10.5: 1



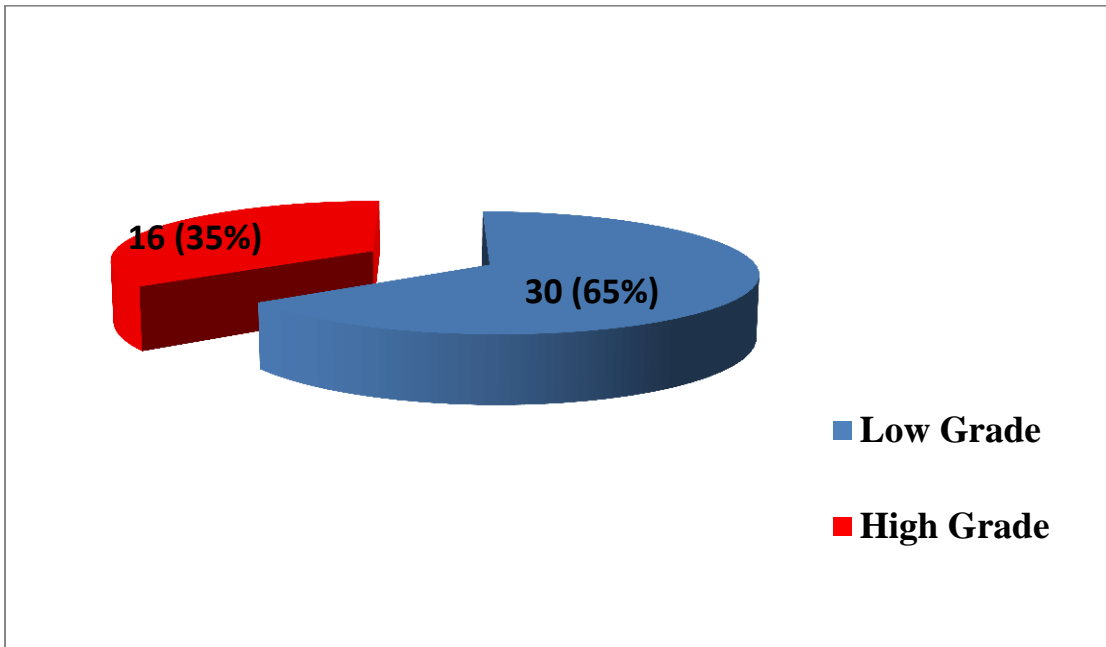
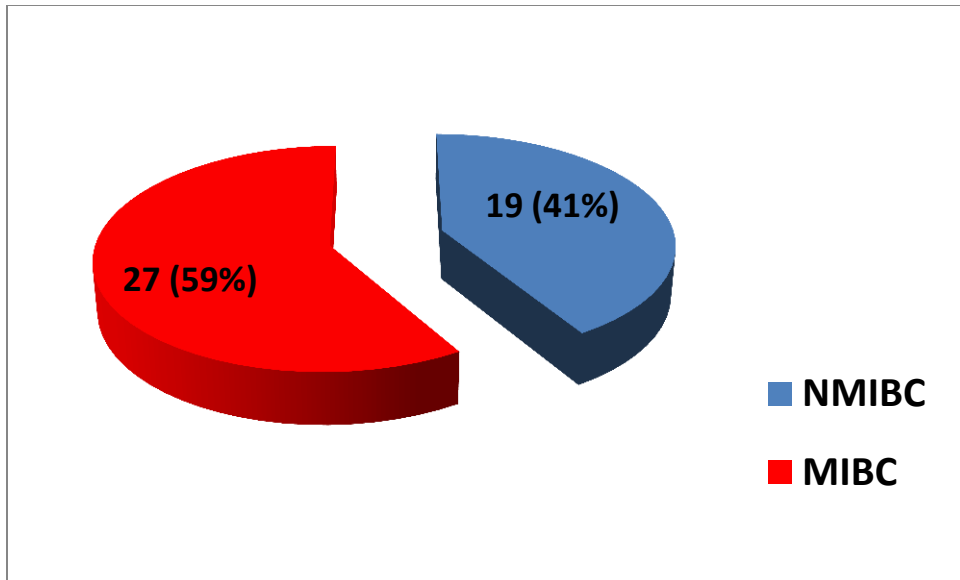
The above chart shows the age distribution of our study group which ranged from 28 to 76 years. The mean age was 59.6 ± 10.7 years. More than 50% of the patients were beyond 60 years of age.



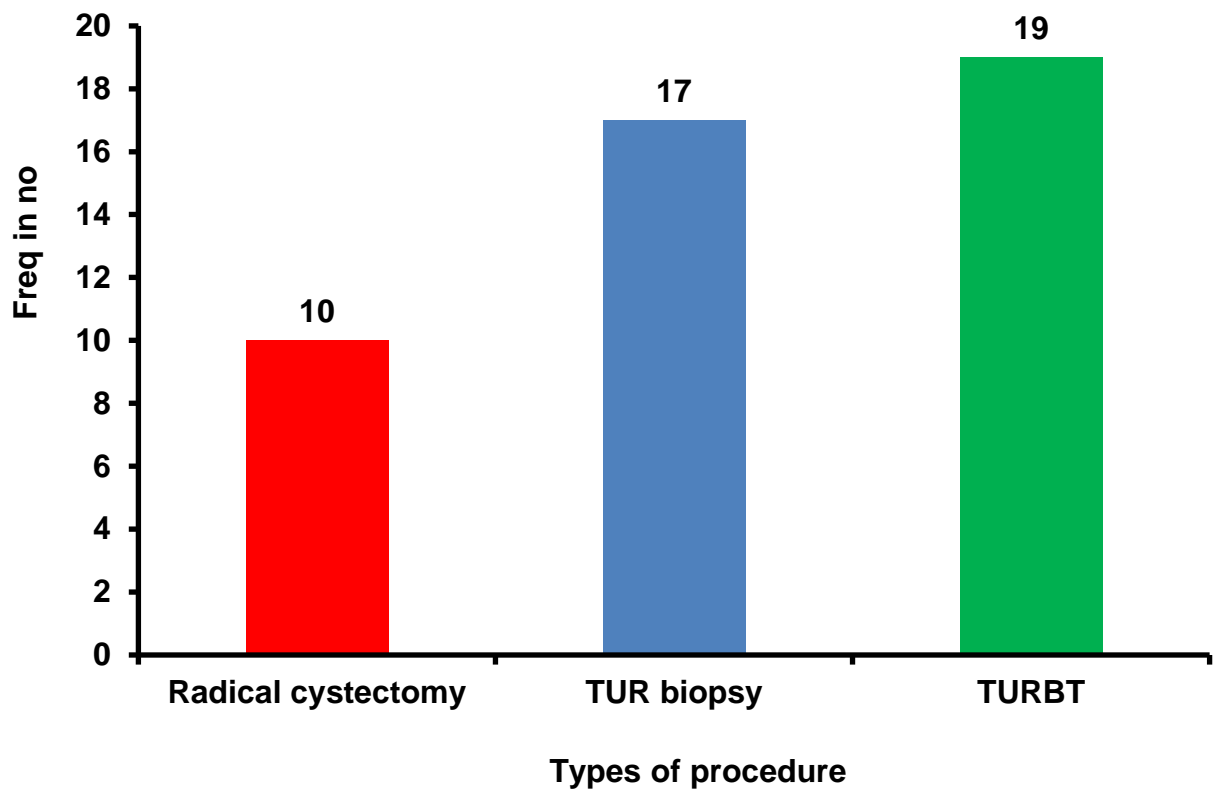
Of the total 46 patients, 10 (21.7%) had elevated renal parameters. They had bilateral hydronephrosis. These patients were not administered with contrast agents during imaging and the pre-operative staging was done with DW MRI. Of the 10 patients, all had muscle invasive bladder cancer.



- Tumor base was sessile in 28 patients (61%) and pedunculated in 18 (39%),
- Tumor measurement ranged from 2 to 12 cms (mean 4.7 cms).
- Histologic findings revealed urothelial carcinoma in all 46 patients (100%).
- Muscle invasion by the malignancy was present in 27 patients (58.7 %), while the remaining 19 (41.3 %) had lamina invasion.



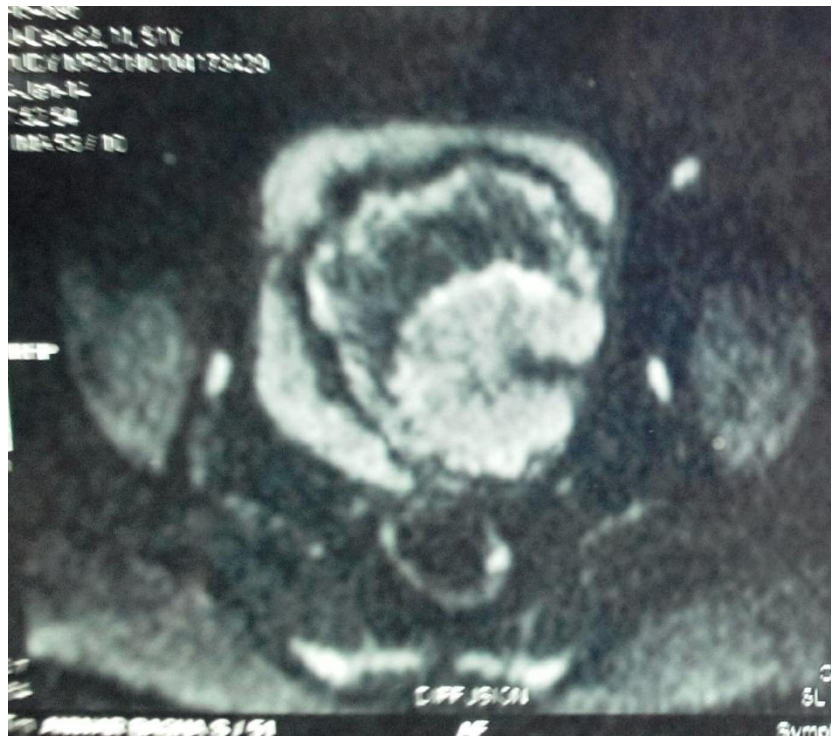- Of the 46 patients low grade tumour was present in 30 (65%) and high grade tumour was present in 16 (35%) patients.



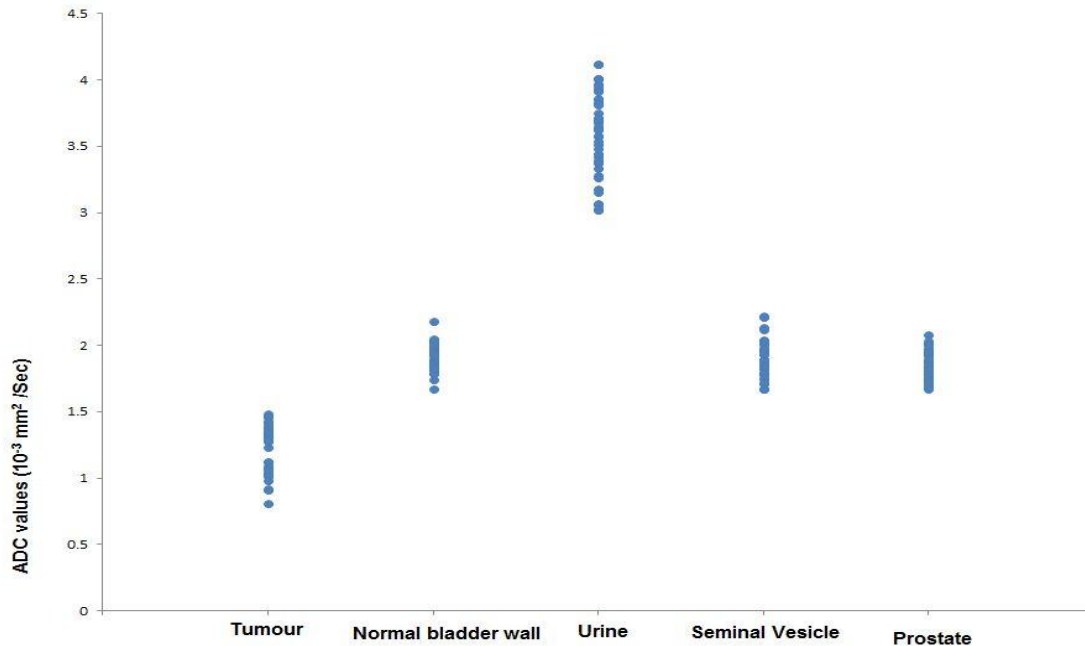
Of the 46 patients,

- 19 (41.3%) patients who had T1 tumours following by TUR of tumour were subjected to intravesical immunotherapy,
- 27 (58.7%) patients had muscle invasive bladder tumour, of which 10 (21.7%) were subjected to radical cystectomy and urinary diversion procedure, of the remaining 17 patients - 10 patients (21.7%) were not willing for definitive surgical procedure and 7 (15.2%) were unfit for major surgical procedure and was advised palliative radiotherapy.

DW MRI images of the 46 patients were reviewed; the tumours were seen as high signal intensity (SI) compared to the other surrounding structures. There were no false-positive cases. The positive predictive values of DW imaging were 100% in terms of correctly detecting the carcinomas.



Tumour mass showing high signal intensity



ADC values ($\times 10^{-3} \text{mm}^2/\text{sec}$)	N	Minimum	Maximum	Mean	Std. Deviation
ADC of Tumour	46	0.81	1.48	1.23	0.18
ADC of Normal Bladder wall	46	1.67	2.18	1.91	0.09
ADC of urine	46	3.02	4.12	3.61	0.32
ADC of Seminal vesicle	46	1.67	2.22	1.90	0.13
ADC of prostate	46	1.67	2.08	1.85	0.11

The ADC values ($\times 10^{-3} \text{mm}^2/\text{sec}$) ranged:

for tumours from 0.81 to 1.48,

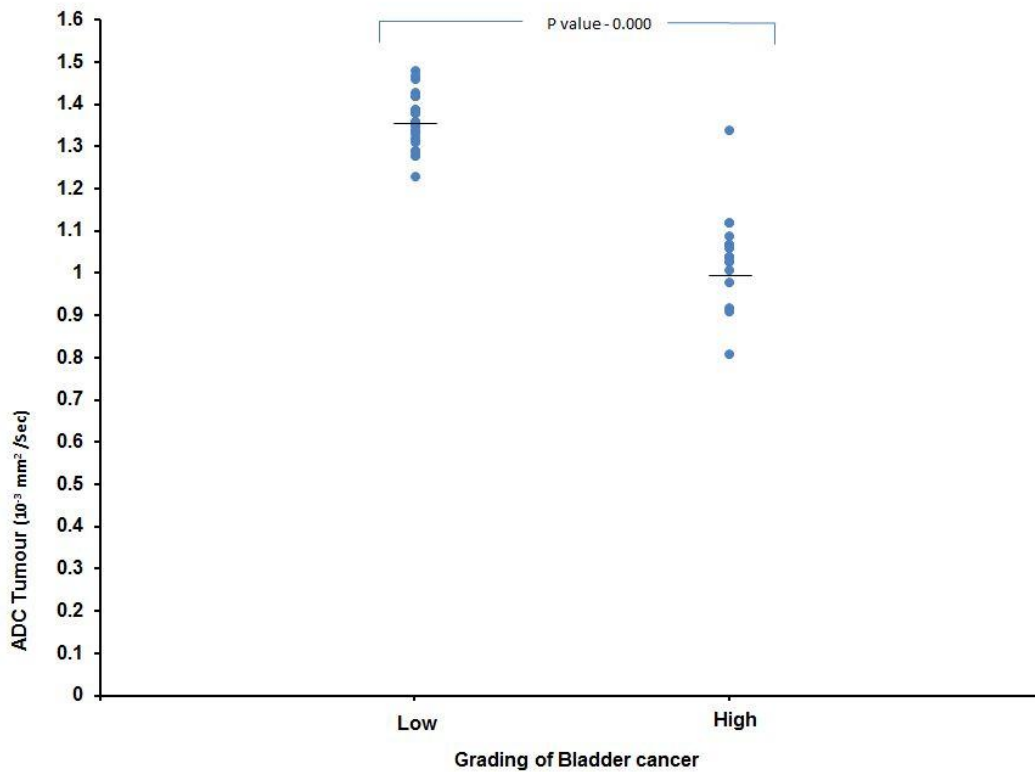
for normal bladder wall from 1.67 to 2.18,

for urine from 3.02 to 4.12 ,

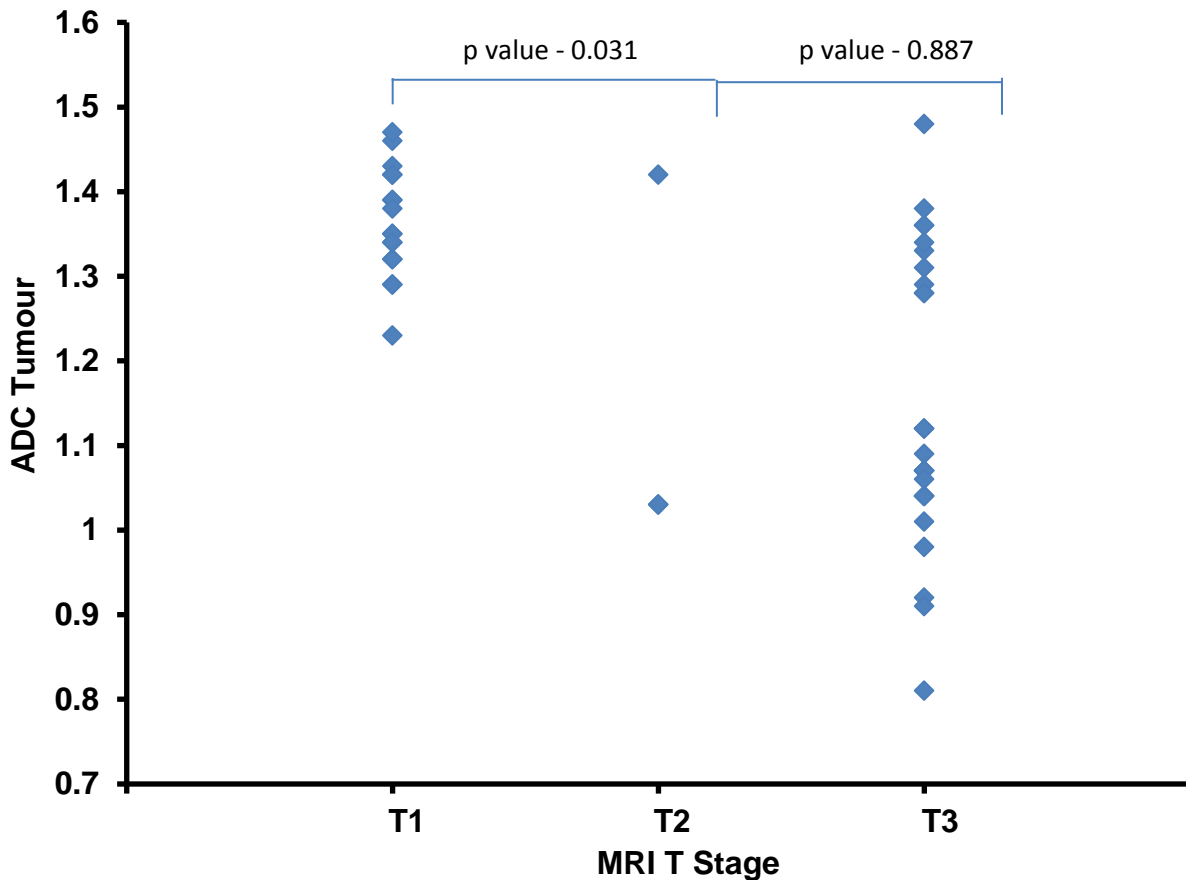
for seminal vesicle from 1.67 to 2.22 and

for prostate from 1.67 to 2.08.

From the preceding table of the ADC values, the ADC value of urine was never in the range of the ADC value of tumours. In some patients, the ADC values of the prostate, seminal vesicles, or normal bladder wall had values which overlapped but did not overlap the ADC value of tumours. This shows that a clear cutoff lies between the tumour ADC values and surrounding structures ADC values. By multivariate analysis showed that the ADC values of the tumours was significantly lower compared to normal bladder wall ($p < 0.001$), urine ($p < 0.001$), prostate ($p < 0.001$), and seminal vesicle ($p < 0.001$).

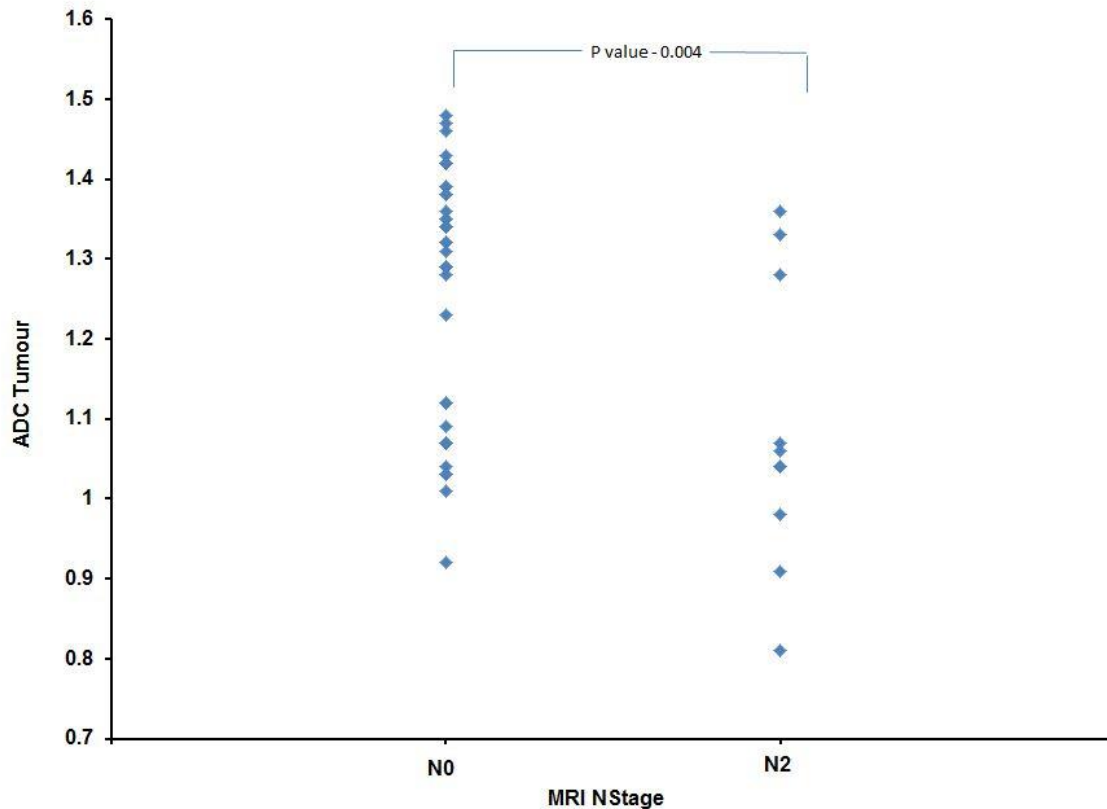


- ADC values for histological subtypes of high grade were ($n = 16$), $0.81 - 1.34 [1.04 \pm 0.10]$ and low grade were ($n = 30$), $1.23 - 1.48 [1.36 \pm 0.06]$. Thus there is a statistically significant difference for the ADC values of high grade and low grade tumours.
- The ADC values of the tumours were correlated with the histopathological T and N stage but they did not show any significant correlation but it varied according to the grade of the tumour.



Here as shown with the scatter plot above, ADC values did not show significant correlation between different tumour T stages and ADC values but between T1 and

T3 there was significance because in T3 group there were 12 out of 16 (66%) patients of the high grade tumours.



Here as shown with the scatter plot above, ADC values of tumour shows significant correlation between different tumour N stages and this significance is because in N2 group there were 6 out of 9 (66.6%) patients of the high grade tumours.

The DW MRI imaging findings and the histopathological findings of the tumour T staging were correlated and it is shown in the table below:

DW-MRI T staging	HPE		Total	P value
	T1	T2,T2,T3		
T1	18	0	18	0.000
T2,T2,T3	1	27	29	
Total	19	27	46	

The MRI imaging in detecting T stage was showing:

Sensitivity 94.4%
 Specificity 100.0%
 PPV 100.0%

Thus with DW MRI images for diagnosing tumor T stage, p value was < 0.001 and was statistically significant. Thus the accuracy was determined for T staging.

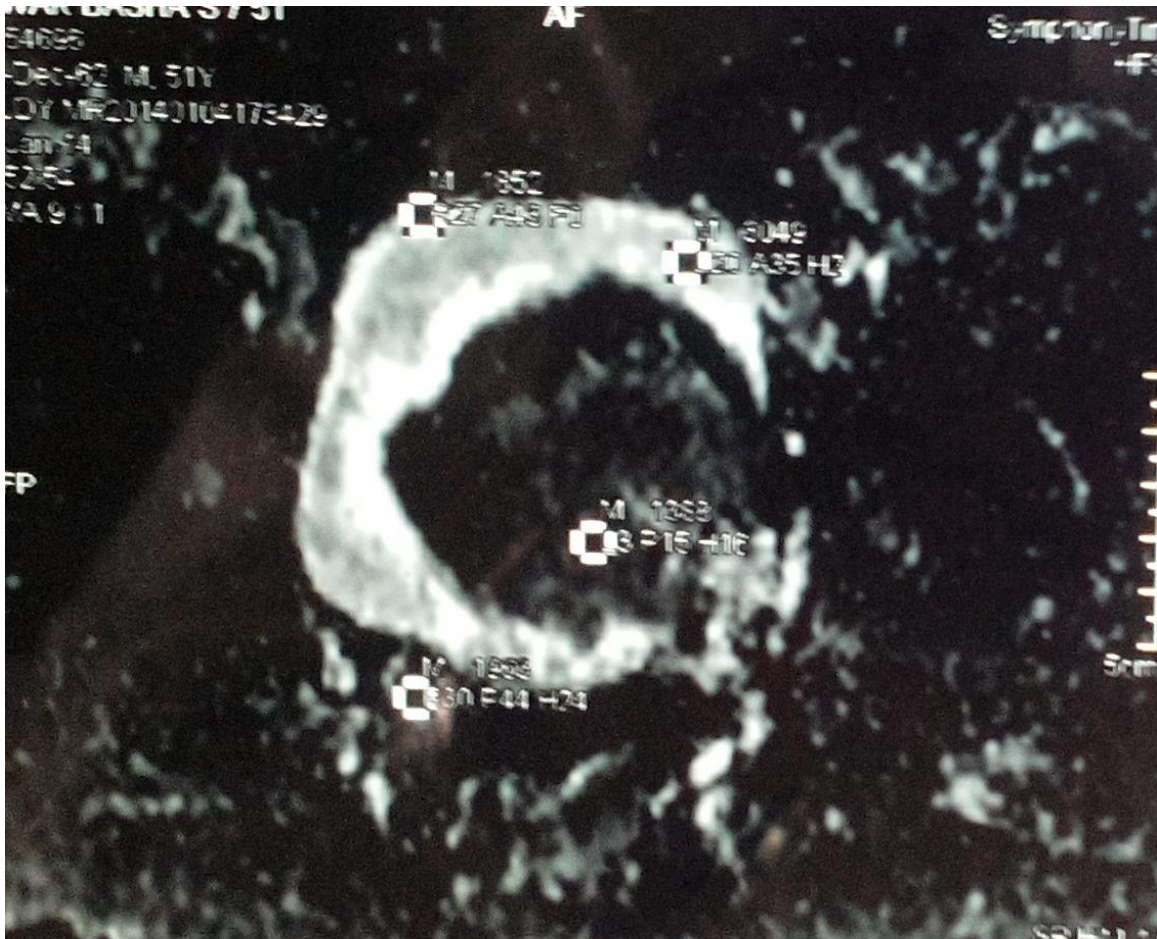The DW MRI imaging findings and the histopathological findings of the tumour Nodal staging were correlated and it is shown in the table below

MRI N staging	HPE		Total	P value
	N0	N2		
N0	36	0	36	0.000
N2	1	9	10	
Total	37	9	46	

The MRI imaging in detecting T stage was showing:

Sensitivity	97.3%
Specificity	100.0%
PPV	100.0%

Thus with DW MRI images for diagnosing tumor N stage, p value was < 0.001 and was statistically significant. Thus the accuracy was determined for N staging.



ADC Mapping showing tumour with low SI

DISCUSSION

The urothelium of the bladder is traditionally considered to be lined by transitional cells, which, as suggested by the name, can transform into a variety of benign and malignant tumors. Following prostatic adenocarcinoma carcinoma bladder represents second most common urological malignancies¹. In literatures it is described as disease of environment and advanced age. It is three to four times common in males than compared to females and peak incidence occurs in seventh decade of life. The most common histologic sub type is urothelial carcinoma worldwide whereas in Egypt, squamous cell carcinoma is common due to endemicity of Schistosomiasis. Urothelial tumors are broadly divided into Non-muscle invasive tumour and Muscle invasive tumour based on invasion of detrusor muscle fibers.

It is proven that grade of the tumour is more important in predicting the prognosis rather than stage in Urothelial cancers. The size of the tumour, multifocality, nature of the tumour and the presence or absence of angiolymphatic permeation also determines the prognosis. Bladder tumour has increased chance for recurrence after the primary treatment and this is mainly based on the prognostic factors.

Under anaesthesia, cystoscopic assessment followed with transurethral resection (TUR) of bladder tumour provides pathological assessment of bladder tumour. TUR is essential to obtain histologic diagnosis but there are increased chances of underestimating the local extent of the tumour³⁶. If histopathological report suggestive of Non-muscle invasive tumour these patients were managed with either intravesical therapeutic agents or high risk patients with aggressive therapies. Patients with muscle invasive tumours were categorized into organ confined disease, locally advanced disease and distant metastatic disease. The management of bladder cancer varies according to muscle non-invasive and muscle invasive nature of the cancer. Muscle non-invasive tumours are managed with transurethral resection (TUR) and intravesical immunotherapy / chemotherapy. The treatment options for muscle invasive bladder cancer are radical cystectomy, radiation therapy, chemotherapy, or a combination³⁷.

DW MRI is a recent technical development in the field of MRI, based on diffusion mobility of water molecules the tissue characteristics are obtained and these differ from T1 weighted or T2 weighted images. Brownian motion or the movement of the water molecules forms the basis of the diffusion weighted MRI²⁵. The ADC, as a quantitative parameter is calculated from the DW MR images, combines the effects of water diffusion and capillary perfusion in the extracellular extravascular space. The mobility of the protons is quantitatively measured with

the parameter the apparent diffusion coefficient (ADC). ADC depends on the environment where the protons are situated which is both qualitatively and quantitatively assessed²⁶. In tumors which are highly cellular and which has higher density of cell membranes there is restricted motions of proton molecules. DW MRI is used in clinical practice by measuring the signal intensity and the ADC values and the restricted motion of protons is seen as high signal intensity on DW MRI images with a corresponding low ADC. Thus DW MRI gives details on diffusion and perfusion at the same time. DW MRI differentiates normal and abnormal structures of tissues better.

DW MRI has been used as a diagnostic tool for a number of years in the field of neuroradiology²⁷. In the hyperacute phase of cerebral ischemia, DW sequences play an important part in the diagnosis. The practical value of DW MRI is used to differentiate between the tumors and ischemia. Various studies have shown that ADC values of malignant lesions of renal, prostatic, colonic, hepatic, and uterine cervical origin were lower than those of normal tissue or benign lesions^{28.29.30.31.32}.

Recently DW MRI has been used in extracranial organs both to monitor treatment response and tissue characterization and in evaluating function of different organs. Due to extreme sensitivity to motion which is from breathing and bowel movements and artifacts, which results in a high signal to noise ratio and did

not permit to obtain thin-slice imaging, hence the role of DW MRI was initially limited to the cranial cavity. Takahara in his study has reported abdominal DW MRI with free breathing, made it possible to obtain images with the help of high-quality multiplanar display with more adequate thin slices with multiple signal averaging, higher signal-to noise ratio³³.

Currently various radiological imaging are available to detect the pathological staging preoperatively. In our study, 46 patients were evaluated with blood tests, radiological imaging and DW MRI. After complete evaluation 18 patients were found to have non-muscle invasive bladder tumour (NMIBC) and 28 patients were diagnosed as muscle invasive tumour (MIBC) by DW MRI. Then patients underwent TURBT for histological diagnosis. After TURBT both tumour and deeper muscle tissues were sent to histopathological examination in separate containers. Histopathological examination showed 19 patients were non-muscle invasive bladder cancer, 27 were muscle invasive bladder cancer. Thus the correlation between DW MRI and histopathological examination had a sensitivity of 94.4%, specificity 100% and PPV of 100% and the diagnostic accuracy was statistically significant.

Patients with muscle invasive bladder tumours were counseled for radical cystectomy with bilateral pelvic lymphadenectomy and urinary diversion. Of the

46 patients, 19 (41.3%) patients who had T1 tumours following by TUR of tumour were subjected to intravesical immunotherapy, 27 (58.7%) patients had muscle invasive bladder tumour, of which 10 (21.7%) were subjected to radical cystectomy and urinary diversion procedure, of the remaining 17 patients - 10 patients (21.7%) were not willing for definitive surgical procedure and 7 (15.2%) were unfit for major surgical procedure and was advised palliative radiotherapy.

Postoperative report showed 19(41%) patients had NMBIC and 27 (59%) patients had MIBC. Of the 10 patients who had underwent radical cystectomy 9 (90%) had lymph nodal metastasis but by DW MRI all had lymph nodal involvement.

The feasibility of using DW MRI under free breathing as suggested by Takahara was tested by Matsuki et al for the detection of urinary bladder tumours in 15 patients. In their study, sensitivity, specificity and PPV of DW MRI were 100% in detecting bladder cancers and all carcinomas had high SI relative to the surrounding non neoplastic structures²⁶. The ADC value of the tumour was lower compared with that of the ADC values of surrounding structures and the urine. In our study, all patients were evaluated with DW MRI before the biopsy and prospective evaluation of local staging and grading was done. All urinary bladder cancers showed high SIs and the ADC value of the carcinoma was lower compared ADC values of the surrounding normal structures. These results are similar to those

reported by Matsuki. The sensitivity, specificity and positive predictive values of diagnosis bladder carcinoma were 100% similar to previous results. In our study, invasion to the surrounding structures and nodal metastasis was clearly demonstrated with high SI of the tumors in comparison to the surroundings.

Also there was no overlap between the ADC values of the tumors and the urine, but in some cases there was an overlap between the ADC values of the tumors and normal bladder wall, prostate or seminal vesicles. These findings are similar to those reported by Matsuki. The role of DW MRI in characterizing bladder tumours and a correlation, if any, with histological analysis of tumors could not be made since all the patients had urothelial carcinomas. The sensitivity, specificity and positive predictive values in our study were 100% in diagnosing patients of bladder cancers evaluated for total hematuria. Mastuki's study was a retrospective study with small sample size.

In Ahmed El study with 43 patients, they showed urinary bladder cancers showed high SIs in all cases and the ADC value of the carcinoma was lower compared with that of urine, the normal bladder wall, the prostate, and the seminal vesicles³⁸. In our study there was no overlap of ADC values of the tumour with surrounding structures. The correlation of lower ADC values in high grade tumours in relation to low grade tumours which was significant was not assessed in Mastuki and Ahmed El study.

Takeuchi et al in their study showed the mean ADC of G3 tumors was significantly lower than that of G1 and G2 tumors all G3 tumors had an ADC less than $1.0 \times 10^{-3} \text{ mm}^2/\text{sec}$. and overall T-stage accuracy increased from 67% using T₂W-MRI alone to 88% when DWMRI was added³⁴. Our study also showed similar result but we had two groups one with low grade and the other with high grade tumours and ADC values of high grade tumours had mean of $1.04 \pm 0.10 \times 10^{-3} \text{ mm}^2/\text{sec}$.

Our study had limitations, with a mean tumor size of 4.7 cms and predominantly with large size tumours it would be critical to assess more of small tumours and superficial tumours. Our study had a smaller sample size in relation to surgery and it would be critical to assess the local staging with a larger study group. Post chemotherapy and post radiotherapy patients were not assessed with DW MRI and it would be necessary to assess scars and reactive tissue and differentiate from the tumor tissue.

Our study was a prospective study with adequate sample size other than the limitations as discussed above we found that DW MRI findings significantly correlate with histopathology in differentiating T1 from T2, T3, T4 and also in local nodal staging. Grading of bladder tumour could be assessed with DW MRI as high grade tumours had significantly lower ADC values compared to low grade tumours.

DW MRI images are obtained quickly and DW MRI technique does not need any contrast agents, hence can be used in patients with contrast allergy, and with compromised renal function. Thus DW MRI can be used preoperatively to effectively stage and grade the tumor and thus can help in planning the treatment.

CONCLUSIONS

DW MRI findings significantly correlate with histopathology in differentiating non muscle invasive bladder tumours from muscle invasive bladder tumours and also in local nodal staging.

Grading of bladder tumour could be assessed with DW MRI as high grade tumours had significantly lower ADC values compared to low grade tumours.

Hence in the preoperative evaluation of bladder cancers, DW MRI is a useful diagnostic imaging study both for grading and local staging of bladder cancers.

BIBLIOGRAPHY

- 1) Dr. D. Max Parkin, Paola Pisani, J. Ferlay et al. Global cancer statistics, *Cancer journal for clinicians*. Volume 49, issue 1, pages 33-64, January/February 1999
- 2) Tekes A, Kamel I, Imam K, et al. Dynamic MRI of bladder cancer: evaluation of staging accuracy. *AJR Am J Roentgenol*. 2005;184(1):121-127.
- 3) Reulen RC, Kellen E, Buntinx F, Brinkman M, Zeegers MPA meta-analysis on the association between bladder cancer and occupation. *Scand J Urol Nephrol Suppl*. 2008 Sep;(218):64-78
- 4) Bryan RT, Zeegers MP, van Roekel EH, Bird D, Grant MR, Dunn JA, Bathers S, Iqbal G, Khan HS, Collins SI, Howman A, Deshmukh NS, James ND, Cheng KK, Wallace DM. A comparison of patient and tumour characteristics in two UK bladder cancer cohorts separated by 20 years. *BJU Int*. 2013 Mar 4.
- 5) Burch JD et al Risk of bladder cancer by source and type of tobacco exposure: a case-control study. *Int J Cancer*.1989

- 6) Zeegers MP et al Prediagnostic toenail selenium and risk of bladder cancer..
Cancer Epidemiol Biomarkers Prev. 2002
- 7) Dryson E, 't Mannetje A, Walls C, McLean D, McKenzie F, Maule M, Cheng S, Cunningham C, Kromhout H, Boffetta P, Blair A, Pearce N. Case-control study of high risk occupations for bladder cancer in New Zealand.
Int J Cancer. 2008 Mar 15;122(6):1340-6
- 8) Braver DJ, Modan M, Chêtrit A, Lusky A, Braf Z et al, Drinking, micturition habits, and urine concentration as potential risk factors in urinary bladder cancer, Natl Cancer Inst. 1987 Mar;78(3):437-40
- 9) Maurice P. A. Zeegers,¹ Alex Volovics,² Elisabeth Dorant,¹ R. Alexandra Goldbohm,³ and Piet A. van den Brandt¹, Alcohol Consumption and Bladder Cancer, American Journal of Epidemiology, 38Vol. 153, No. 1
- 10) Westenend PJ, Stoop JA, Hendriks JG et al. Human papillomaviruses 6/11, 16/18 and 31/33/51 are not associated with squamous cell carcinoma of the urinary bladder.BJU Int. 2001 Aug;88(3):198-201.
- 11) Michaud DS, Platz EA, Giovannucci E et al, Gonorrhoea and male bladder cancer in a prospective study, Br J Cancer. 2007 Jan 15;96(1):169-71. Epub 2006 Dec 12.

- 12) Kantor AF, Hartge P, Hoover RN, Narayana AS, Sullivan JW, Fraumeni JF Jr et al, Urinary tract infection and risk of bladder cancer, *Am J Epidemiol.* 1984 Apr;119(4):510-5
- 13) Abol-Enein H et al. Infection and bladder cancer. *4.Scand J Urol Nephrol Suppl.* 2008 Sep;(218):79-84, SourceUrology and Nephrology Center, Mansoura University, Mansoura, Egypt.
- 14) Nikolaos Koletsas, Dimitris Kikidakis, and Konstantinos Paschalidis et al,Secondary malignancies following radiotherapy for prostate cancer, *Ther Adv Urol.* 2010 June; 2(3): 119–125
- 15) Donald L. Lamm, William R. McGee, Kaye Hale et al, Bladder Cancer: Invasive low-grade papillary urothelial carcinoma: a clinicopathologic analysis of 41 cases. *Current Optimal Intravesical Treatment,* 2005;25(5):323-332*Am J Surg Pathol.* 2012 Jul;36(7):1081-6
- 16) Khadra MH, Pickard RS, Charlton M, Powell PH, Neal DEA prospective analysis of 1,930 patients with hematuria to evaluate current diagnostic practice.*J Urol.* 2000 Feb;163(2):524-7 Keese SK, Briggman JV, Thill G, Wu YJ. Utilization of nuclear matrix proteins for cancer diagnosis.*Crit Rev Eukaryot Gene Expr.* 1996;6(2-3):189-214

- 17) Keesee SK, Briggman JV, Thill G, Wu YJ. Utilization of nuclear matrix proteins for cancer diagnosis. *Crit Rev Eukaryot Gene Expr.* 1996;6(2-3):189-214
- 18) Kipp BR et al. A systematic approach to identifying urothelial cells likely to be polysomic by fluorescence in situ hybridization. *Anal Quant Cytol Histol*
- 19) Izes JK, Dyer MW, Callum MG, Bankes P, Libertino JA, Caffrey JA. Ca 125 as a marker of tumor activity in advanced urothelial malignancy. *J Urol.* 2001 Jun;165(6 Pt 1):1908-13.
- 20) Hegele A, Mecklenburg V, Varga Z, Olbert P, Hofmann R, Barth P. CA19.9 and CEA in transitional cell carcinoma of the bladder: serological and immunohistochemical findings. *Anticancer Res.* 2010 Dec;30(12):5195-200.
- 21) Resorlu B, Baltaci S, Resorlu M, Ergun G, Abdulmajeed M, Haliloglu AH, Gogus C, Beduk Y. Prognostic significance of hydronephrosis in bladder cancer treated by radical cystectomy. *Urol Int.* 2009;83(3):285-8. Epub 2009 Oct 13.
- 22) Vikram R, Sandler CM, Ng CS. Imaging and staging of transitional cell carcinoma: part 1, lower urinary tract. *AJR Am J Roentgenol.* 2009;192(6):1481-1487.

- 23) Zhang J, Gerst S, Lefkowitz RA, Bach A. Imaging of bladder cancer. *Radiol Clin North Am.* 2007;45(1):183-205.
- 24) Barentsz JO, Ruijs SH, Strijk SP. The role of MR imaging in carcinoma of the urinary bladder. *AJR Am J Roentgenol.* 1993;160(5):937-947.
- 25) Le Bihan, D., Breton, E., Lallemand, D., Aubin, M.L., Vignaud, J., and Laval-Jeantet, M. (1988) Separation of diffusion and perfusion in intravoxel incoherent motion MR imaging. *Radiology* **168**, 497–505.
- 26) Matsuki M, Inada Y, Tatsugami F, Tanikake M, Narabayashi I, Katsuoka Y. Diffusion-weighted MR imaging for urinary bladder carcinoma: initial results. *Eur Radiol.* 2007;17(1):201-204.
- 27) Buckley, B.T., Wainwright, A., Meagher, T., and Briley, D. (2003) Audit of a policy of magnetic resonance imaging with diffusion-weighted imaging as first-line neuroimaging for inpatients with clinically suspected acute stroke. *Clin. Radiol.* **58**, 234–237.
- 28) Taouli, B., Vilgrain, V., Dumont, E., Darie, J.L., Fan, B., and Menu, Y. (2003) Evaluation of liver diffusion isotropy and characterization of focal hepatic lesions with two single-shot echo-planar MR imaging sequences: prospective study in 66 patients. *Radiology* **226**, 71–78.

- 29) Cova, M., Squillaci, E., Stacul, F., Manenti, G., Gava, S., Simonetti, G., and Pozzi-Mucelli, R. (2004) Diffusion weighted MRI in the evaluation of renal lesions: preliminary results. *Br. J. Radiol.* **77**, 851–857.
- 30) Thoeny, H.C., De Keyzer, F., Oyen, R.H., and Peeters, R.R. (2005) Diffusion-weighted MR imaging of kidneys in healthy volunteers and patients with parenchymal diseases: initial experience. *Radiology* **235**, 911–917.
- 31) Issa, B. (2002) In vivo measurement of the apparent diffusion coefficient in normal and malignant prostatic tissues using echo-planar imaging. *J. Magn. Reson. Imaging* **16**, 196–200. Sato, C., Naganawa, S., Nakamura, T., Kumada, H., Miura, S., Takizawa, O., and Ishigaki, T. (2005)
- 32) Differentiation of non-cancerous tissue and cancer lesions by apparent diffusion coefficient values in transition and peripheral zones of the prostate. *J. Magn. Reson. Imaging* **21**, 258–262.
- 33) Takahara, T., Imai, Y., Yamashita, T., Yasuda, S., Nasu, S., and Cauteren, M.V. (2004) Diffusion weighted whole body imaging with background body signal suppression (DWIBS): technical improvement using free breathing, STIR and high resolution 3D display. *Radiat. Med.* **22**, 275–282.

- 34) Takeuchi M, Sasaki S, Ito M, Okada S, Takahashi S, Kawai T, Suzuki K, Oshima H, Hara M, Shibamoto Y. Urinary Bladder Cancer: Diffusion weighted MR Imaging—Accuracy for Diagnosing T Stage and Estimating Histologic Grade: Radiology. 2009 Apr; 251(1):112-21.
- 35) Nieder AM et al Management of stage T1 tumors of the bladder: International Consensus Panel.. Urology. (2005)
- 36) Babjuk M, Oosterlinck W, Sylvester R, et al. EAU guidelines on non-muscle-invasive urothelial carcinoma of the bladder, the 2011 update. Eur Urol 2011;59:997–1008.
- 37) Stenzl A, Cowan NC, De Santis M, et al. Treatment of muscle-invasive and metastatic bladder cancer: update of the EAU guidelines. Eur Urol 2011;59:1009
- 38) Ahmed El-Assmy, Mohamed E. Abou-El-Ghar, Huda F. Refaie, Tarek El-Diasty. Diffusion-Weighted MR Imaging in Diagnosis of Superficial and Invasive Urinary Bladder Carcinoma: A Preliminary Prospective Study: TheScientificWorldJOURNAL (2008) 8, 364–370

2009 TNM CLASSIFICATION OF URINARY BLADDER CANCER

T - Primary tumour

TX Primary tumour cannot be assessed

T0 No evidence of primary tumour

Ta Non-invasive papillary carcinoma

Tis Carcinoma *in situ*: 'flat tumour'

T1 Tumour invades subepithelial connective tissue

T2 Tumour invades muscle

T2a Tumour invades superficial muscle (inner half)

T2b Tumour invades deep muscle (outer half)

T3 Tumour invades perivesical tissue:

T3a Microscopically

T3b Macroscopically (extravesical mass)

T4 Tumour invades any of the following: prostate, uterus, vagina, pelvic wall,
abdominal wall

T4a Tumour invades prostate, uterus or vagina

T4b Tumour invades pelvic wall or abdominal wall

N - Lymph nodes

NX Regional lymph nodes cannot be assessed

N0 No regional lymph node metastasis

N1 Metastasis in a single lymph node in the true pelvis (hypogastric, obturator, external iliac, or presacral)

N2 Metastasis in multiple lymph nodes in the true pelvis (hypogastric, obturator, external iliac, or presacral)

N3 Metastasis in common iliac lymph node(s)

M - Distant metastasis

MX Distant metastasis cannot be assessed

M0 No distant metastasis

M1 Distant metastasis

WHO grading in 1973 and in 2004

1973 WHO grading

Urothelial papilloma

Grade 1: well differentiated

Grade 2: moderately differentiated

Grade 3: poorly differentiated

2004 WHO grading

Flat lesions

Hyperplasia (flat lesion without atypia or papillary aspects)

Reactive atypia (flat lesion with atypia)

Atypia of unknown significance

Urothelial dysplasia

Urothelial CIS

Papillary lesions

Urothelial papilloma (completely benign lesion)

Papillary urothelial neoplasm of low malignant potential

Low-grade papillary urothelial carcinoma

High-grade papillary urothelial carcinoma

INFORMED CONSENT FORM

Title of the study: “EVALUATION WITH DIFFUSION WEIGHTED MAGNETIC RESONANCE IMAGING IN STAGING AND GRADING OF URINARY BLADDER CANCER”

Name of the Participant:

Name of the Principal Investigator: Dr. RAMKUMAR J

Name of the Institution: Rajiv Gandhi Govt.General Hospital, Chennai -3.

Documentation of the informed consent

I _____ have read the information in this form (or it has been read to me). I was free to ask any questions and they have been answered. I am over 18 years of age and, exercising my free power of choice, hereby give my consent to be included as a participant in **“EVALUATION WITH DIFFUSION WEIGHTED MAGNETIC RESONANCE IMAGING IN STAGING AND GRADING OF URINARY BLADDER CANCER”**

1. I have read and understood this consent form and the information provided to me.
2. I have had the consent document explained to me.
3. I have been explained about the nature of the study.
4. I have been explained about my rights and responsibilities by the investigator.
5. I have been informed the investigator of all the treatments I am taking or have taken in the past 3 months including any native (alternative) treatment.
6. I have been advised about the risks associated with my participation in this study.
7. I agree to cooperate with the investigator and I will inform him/her immediately if I suffer unusual symptoms.
8. I have not participated in any research study within the past 6 month(s)

10. I am aware of the fact that I can opt out of the study at any time without having to give any reason and this will not affect my future treatment in this hospital.

11. I am also aware that the investigator may terminate my participation in the study at any time, for any reason, without my consent.

12. I hereby give permission to the investigators to release the information obtained from me as result of participation in this study to the regulatory authorities, Govt. agencies, and IEC. I understand that they are publicly presented.

13. I have understand that my identity will be kept confidential if my data are publicly presented

14. I have had my questions answered to my satisfaction.

15. I have decided to be in the research study.

I am aware that if I have any question during this study, I should contact the investigator. By signing this consent form I attest that the information given in this document has been clearly explained to me and understood by me, I will be given a copy of this consent document.

For adult participants:

Name and signature / thumb impression of the participant (or legal representative if participant incompetent)

Name _____ Signature_____

Date_____

Name and Signature of impartial witness (required for illiterate patients):

Name _____ Signature_____

Date_____

Address and contact number of the impartial witness:

Name and Signature of the investigator or his representative obtaining consent:

Name _____ Signature_____

Date_____

INFORMATION TO PARTICIPANTS

Sponsor: Nil

Investigator: Dr.RAMKUMAR J

Name of Participant:

Institution: Madras Medical College and Rajiv Gandhi Government General Hospital

Title: “EVALUATION WITH DIFFUSION WEIGHTED MAGNETIC RESONANCE IMAGING IN STAGING AND GRADING OF URINARY BLADDER CANCER”

1. We are conducting the above study on Urinary bladder Cancer patients among patients attending Government General Hospital, Chennai
2. You are being asked to participate in this study being conducted in Madras Medical College and Rajiv Gandhi Government General Hospital Chennai-3.
3. You are invited to take part in this study. The information in this document is meant to help you decide whether or not to take part. Please feel free to ask if you have any queries or concerns.

4. You will be investigated by DIFFUSION WEIGHTED MAGNETIC RESONANCE IMAGING of the abdomen in which you will undergo MRI imaging without any contrast administration and there will be no risks associated with the procedure and the findings will be correlated with other imaging and histopathological reports.

5. The purpose of this study is to evaluate the stage and grade of urinary bladder cancer using Diffusion Weighted Magnetic Resonance Imaging.

6. The privacy of the patients in the research will be maintained throughout the study. In the event of any publication or presentation resulting from the research, no personally identifiable information will be shared.

7. Taking part in this study is voluntary. You are free to decide whether to participate in this study or to withdraw at any time; your decision will not result in any loss of benefits to which you are otherwise entitled.

8. The results of the special study may be intimated to you at the end of the study period or during the study if anything is found abnormal which may aid in the management or treatment.

Signature of investigator

Signature of participant

Date:

Systemic examination

CVS:

RS:

Abdomen examination:

External Genetalia:

DRE:

Laboratory evaluation

CBC:

RFT:

UREA

CREATININE

LFT:

Serum Calcium:

URINE Microscopy:

URINE C/S:

URINE CYTOLOGY:

RADIOLOGICAL parameters

X-ray KUBU:

USG KUB:

CECT scan:

Tumor size

Growth pattern

Perivesical stranding

Lymphadenopathy

Adjacent organ involvement

Distal metastasis

MRI Findings of T2 Weighted Images & DW Images:

Tumor size

Growth pattern

Perivesical stranding

Lymphadenopathy

Adjacent organ involvement

Signal Intensity

ADC Values of

Bladder masses:

Urine:

Normal bladder wall:

Seminal vesicle:

Transition and peripheral zones of prostate:

Cystoscopic examination:

GROWTH PATTERN- PAPILLARY/SESSILE/ PEDUNCULATED

Presence of CIS

Intraoperative findings

Tumour size

Location

Extravesical extension

Pelvic lymphadenopathy

PATHOLOGICAL REPORT:

Tumor size

Grade

Lymphovascular invasion

Muscle invasion

Lymph node

Perivesical involvement

ABBREVIATIONS

WHO	World Health Organization
TUR	Transurethral Resection
CECT	Contrast-Enhanced Computed Tomography
MRI	Magnetic Resonance Imaging
DW MRI	Diffusion-weighted MRI
ADC	Apparent Diffusion Coefficient
SI	Signal Intensity
HPV	Human Papilloma Virus

ஆராய்ச்சி ஒப்புதல் படிவம்

ஆராய்ச்சி தலைப்பு

“பரவல் கனத்த காந்த ஒத்ததிர்வு படமாக்கல் மூலம் சிறுநீரகப்பை
புற்றுநோயின் நோய்க்குறி கட்டம் அறிவதற்கான ஆய்வு”

ஆராய்ச்சி நிலையம் : சிறுநீரியல் துறை,
சென்னை மருத்துவக் கல்லூரி மற்றும்
ராஜீவ் காந்தி அரசு பொது மருத்துவமனை, சென்னை.

பங்கு பெறுவரின் பெயர் :

பாலினம் :

பங்குபெறபவரின் எண் :

பங்கு பெறுபவர் இதனை (✓) குறிக்கவும்

மேலே குறிப்பிட்டுள்ள மருத்துவ ஆய்வின் விவரங்கள் எனக்கு விளக்கப்பட்டது. என்னுடைய சந்தேகங்களை கேட்கவும், அதற்கான தகுந்த விளக்கங்களை பெறவும் வாய்ப்பளிக்கப்பட்டது.

நான் இவ்வாய்வில் தன்னிச்சையாகதான் பங்கேற்கிறேன். எந்த காரணத்தினாலோ எந்த கட்டத்திலும் எந்த சட்ட சிக்கலுக்கும் உட்படாமல் நான் இவ்வாய்வில் இருந்து விலகி கொள்ளலாம் என்றும் அறிந்து கொண்டேன்.

இந்த ஆய்வு சம்பந்தமாகவோ, இதை சார்ந்த மேலும் ஆய்வு மேற்கொள்ளும் போதும் இந்த ஆய்வில் பங்குபெறும் மருத்துவர் என்னுடைய மருத்துவ அறிக்கைகளை பார்ப்பதற்கு என் அனுமதி தேவையில்லை என அறிந்து கொள்கிறேன். நான் ஆய்வில் இருந்து விலகிக் கொண்டாலும் இது பொருந்தும் என அறிகிறேன்.

இந்த ஆய்வின் மூலம் கிடைக்கும் தகவல்களையும், பரிசோதனை முடிவுகளையும் மற்றும் சிகிச்சை தொடர்பான தகவல்களையும் மருத்துவர் மேற்கொள்ளும் ஆய்வில் பயன்படுத்திக்கொள்ளவும் அதை பிரசுரிக்கவும் என் முழு மனதுடன் சம்மதிக்கின்றேன்.

இந்த ஆய்வில் பங்கு கொள்ள ஒப்புக்கொள்கிறேன். எனக்கு கொடுக்கப்பட்ட அறிவுரைகளின்படி நடந்து கொள்வதுடன் இந்த ஆய்வை மேற்கொள்ளும் மருத்துவ அணிக்கு உண்மையுடன் இருப்பேன் என்று உறுதியளிக்கிறேன். எனது உடல் நலம்பாதிக்கப்பட்டாலோ அல்லது எதிர்பாராத வழக்கதிற்கு மாறான நோய்க்குறி தென்பட்டாலோ உடனே அதை மருத்து அணியிடம் தெரிவிப்பேன் என உறுதி அளிக்கிறேன்.

இந்த ஆய்வில் எனக்கு இரத்தம், சிறுநீர், எக்ஸ்ரே, ஸ்கேன் மற்றும் தசை பரிசோதனை செய்துகொள்ள நான் முழு மனதுடன் சம்மதிக்கிறேன்.

பங்கேற்பவரின் கையொப்பம் இடம்..... தேதி.....
கட்டைவிரல் ரேகை

பங்கேற்பவரின் பெயர் மற்றும் விலாசம்

ஆய்வாளரின் கையொப்பம் இடம்..... தேதி.....

ஆய்வாளரின் பெயர்

தகவல் படிவம்

உபயத்தார் : இல்லை
ஆய்வாளர் பெயர் :
பங்கேற்பாளர் பெயர் :
ஆய்வு செய்யப்படும் தலைப்பு : பரவல் கனத்த காந்த ஒத்ததிர்வு படமாக்கல்
மூலம் சிறுநீரகப்பை புற்றுநோயின் நோய்க்குறி
கட்டம் அறிவுதற்கான ஆய்வு

1. இந்த ஆய்வு

தங்களுக்கு சிறுநீரகப்பை புற்றுநோய் ஏற்பட்டு உள்ளது. அதற்கு சிகிச்சை அளிக்கும் முன் உங்களின் நோய்க்குறிய கட்டத்தை அறிய வேண்டி உள்ளது. அதன்பொருட்டு தாங்கள் பரவல் கனத்த காந்த ஒத்ததிர்வு படமாக்கல் மூலம் பரிசோதனை செய்து நோய்க்குறி கட்டத்தை அறியலாம். எனவே அதற்காக பரவல் கனத்த காந்த ஒத்ததிர்வு படமாக்கல் ஆய்விற்கு சம்மதம் தருமாறு தெரிவித்துக் கொள்கிறேன்.

இந்த ஆய்வில் பங்குபெறுவது நோயாளிகளின் சொந்த விருப்பத்திலேயே ஆகும். இந்த ஆய்வையொட்டி எந்தவிதமான சந்தேகங்களுக்கும் விளக்கம் பெற நோயாளிகளுக்கு உரிமை உள்ளது. இந்த ஆய்வின் முடிவுகள் இறுதியில் பிரசுரிக்கப்படும்.

பங்கேற்பவரின் கையொப்பம் இடம்..... தேதி.....

கட்டைவிரல் ரேகை

பங்கேற்பவரின் பெயர் மற்றும் விலாசம்

ஆய்வாளரின் கையொப்பம் இடம்..... தேதி.....

ஆய்வாளரின் பெயர்

MASTER CHART

S. No	Name	Age	Sex	RFT	MRI T STAGE	HPE T STAGE	MRI N STAGE	HPE N STAGE	TUMOUR APPEARANCE	Signal intensity	ADC Tumour	ADC Normal wall	ADC urine	ADC Seminal vesicle	ADC prostate	Procedure	HPE Grade	HPE TYPE
1	Lakshmanan	67	m	N	T3	T3	N0	N0	PEDUNCULATED	High	1.01	1.81	3.02	1.82	1.93	TUR biopsy	High	Urothelial
2	Narayanan	55	m	N	T1	T1	N0	N0	PEDUNCULATED	High	1.23	2.03	4.12	2.22	1.89	TURBT	Low	Urothelial
3	Chinnaraj	50	M	N	T1	T1	N0	N0	PEDUNCULATED	High	1.39	1.87	3.58	1.84	1.71	TUR biopsy	Low	Urothelial
4	Jallaludeen	70	M	Raised	T3	T3	N2	N2	SESSILE	High	0.81	1.85	3.62	1.83	1.76	TUR biopsy	High	Urothelial
5	Raja	73	m	N	T1	T1	N0	N0	SESSILE	High	1.32	1.79	3.71	1.86	2.01	TURBT	Low	Urothelial
6	Selvarasu	46	m	N	T3	T3	N0	N0	SESSILE	High	1.04	1.94	3.42	1.98	1.82	TUR biopsy	High	Urothelial
7	Chinnasamy	65	m	N	T2	T3	N2	N2	SESSILE	High	1.28	1.88	3.86	2.03	1.88	Radical cystectomy	Low	Urothelial
8	Velusamy	70	m	N	T3	T3	N2	N2	SESSILE	High	1.33	1.96	3.18	1.97	1.98	Radical cystectomy	Low	Urothelial
9	Krishnan	68	m	Raised	T3	T3	N0	N0	SESSILE	High	1.07	1.99	3.68	1.89	2.03	TUR biopsy	High	Urothelial
10	Kannan	40	m	N	T3	T3	N0	N0	SESSILE	High	1.12	1.89	3.07	1.96	1.95	Radical cystectomy	High	Urothelial
11	Kathavarayan	60	m	N	T1	T1	N2	N0	PEDUNCULATED	High	1.32	1.99	3.97	2.12	1.87	TURBT	Low	Urothelial
12	Kuppan	68	m	Raised	T3	T3	N0	N2	SESSILE	High	0.98	1.86	3.15	1.96	2.01	TUR Biopsy	High	Urothelial
13	Rajendran	44	m	n	T3	T3	N0	N0	SESSILE	High	1.36	1.99	3.51	2.13	1.96	Radical cystectomy	Low	Urothelial
14	Jagadeesan	75	m	N	T3	T3	N2	N2	SESSILE	High	1.04	1.94	3.33	1.79	1.88	TUR biopsy	High	Urothelial
15	Jothikannu	55	f	N	T1	T1	N0	N0	PEDUNCULATED	High	1.34	2.04	3.93	2.21	2.01	TURBT	Low	Urothelial
16	Duraisamy	55	m	N	T1	T1	N0	N0	PEDUNCULATED	High	1.29	1.94	3.69	2.04	2.08	TURBT	Low	Urothelial
17	Samanan	63	m	N	T1	T1	N0	N0	PEDUNCULATED	High	1.35	2.18	4.01	2.02	1.93	TURBT	Low	Urothelial
18	UMA MAHESWARI	40	F	N	T3	T3	N0	N0	SESSILE	High	1.38	1.89	3.71	1.78	1.92	Radical cystectomy	Low	Urothelial
19	ANBALAGAN	55	M	N	T3	T3	N0	N0	SESSILE	High	1.31	1.93	3.37	1.96	2.01	TUR Biopsy	Low	Urothelial
20	Veerappan	56	m	N	T3	T3	N2	N2	SESSILE	High	1.04	1.98	3.63	2.03	1.78	Radical cystectomy	High	Urothelial
21	Subramani	57	M	Raised	T3	T3	N0	N0	SESSILE	High	1.29	1.85	3.06	2.01	1.88	Radical cystectomy	Low	Urothelial
22	Kuppan	52	M	N	T1	T2	N0	N0	PEDUNCULATED	High	1.33	1.88	4.01	1.95	1.67	TURBT	Low	Urothelial
23	Masilamani	65	M	Raised	T3	T3	N0	N0	SESSILE	High	1.29	1.97	3.65	1.79	1.84	TUR BIOPSY	Low	Urothelial
24	Nagaraj	52	M	N	T1	T1	N0	N0	PEDUNCULATED	High	1.43	2.02	3.44	1.89	1.79	TURBT	Low	Urothelial
25	Swaminathan	65	M	N	T3	T3	N0	N0	SESSILE	High	1.07	1.87	3.39	1.71	1.84	TUR BIOPSY	High	Urothelial
26	Sudharshan	28	M	N	T1	T1	N0	N0	PEDUNCULATED	High	1.35	1.93	3.28	1.85	1.74	TURBT	Low	Urothelial
27	Arumugam	70	M	Raised	T3	T3	N0	N0	SESSILE	High	0.92	1.89	3.03	1.67	1.73	TUR BIOPSY	High	Urothelial
28	Doss	45	M	N	T3	T3	N0	N0	SESSILE	High	1.34	1.96	3.54	1.94	1.78	TUR BIOPSY	High	Urothelial
29	Subramani	57	M	N	T3	T3	N0	N0	SESSILE	High	1.28	1.85	3.26	1.79	1.93	Radical cystectomy	Low	Urothelial
30	Arjunan	65	M	N	T1	T1	N0	N0	SESSILE	High	1.42	1.79	3.75	1.67	1.93	TURBT	Low	Urothelial
31	Ramakrishnan	50	M	N	T1	T2	N0	N0	PEDUNCULATED	High	1.03	1.74	3.92	1.94	1.74	TURBT	High	Urothelial
32	Amsaveni	75	F	Raised	T3	T3	N2	N0	SESSILE	High	1.07	1.92	4.01	1.67	1.82	TUR BIOPSY	High	Urothelial
33	Mahalingam	61	M	N	T1	T1	N0	N0	PEDUNCULATED	High	1.39	1.87	3.85	1.85	1.73	TURBT	Low	Urothelial
34	Saradhammal	70	F	Raised	T3	T3	N2	N0	SESSILE	High	1.07	1.96	3.48	1.89	1.78	TUR BIOPSY	High	Urothelial
35	Shanmugam	70	M	N	T3	T3	N0	N0	SESSILE	High	1.36	1.84	3.58	1.98	1.79	TUR BIOPSY	Low	Urothelial
36	Krishnamoorthy	68	M	N	T2	T2	N0	N0	SESSILE	High	1.42	1.97	4.12	1.79	1.81	TURBT	Low	Urothelial
37	Desingu	65	M	N	T1	T1	N0	N0	PEDUNCULATED	High	1.29	1.84	3.39	1.93	1.89	TURBT	Low	Urothelial
38	Patchyappan	59	M	N	T3	T3	N0	N0	SESSILE	High	1.48	1.95	3.02	1.75	1.93	Radical cystectomy	Low	Urothelial
39	Ramu	65	M	N	T1	T1	N0	N0	PEDUNCULATED	High	1.38	2.01	4.01	2.03	1.79	TURBT	Low	Urothelial
40	Rajkumar	50	M	N	T3	T3	N2	N2	SESSILE	High	1.06	1.94	3.83	1.84	1.95	Radical cystectomy	High	Urothelial
41	Rajadurai	70	M	Raised	T3	T3	N0	N0	SESSILE	High	1.38	1.84	3.95	1.79	1.68	TUR biopsy	Low	Urothelial
42	Anwar Basha	55	m	N	T1	T1	N0	N0	PEDUNCULATED	High	1.46	2.05	3.63	1.88	1.74	TURBT	Low	Urothelial
43	Raman	50	M	N	T1	T1	N0	N0	PEDUNCULATED	High	1.34	1.83	3.82	1.75	1.82	TURBT	Low	Urothelial
44	Sadhullah	57	M	N	T1	T1	N0	N0	PEDUNCULATED	High	1.47	1.93	3.71	1.84	1.72	TURBT	Low	Urothelial
45	Ramasamy	76	M	Raised	T3	T3	N2	N2	SESSILE	High	0.91	1.67	3.81	1.72	1.69	TUR biopsy	High	Urothelial
46	Balasundaram	70	M	N	T1	T1	N0	N0	PEDUNCULATED	High	1.42	1.83	3.91	1.94	1.69	TURBT	Low	Urothelial

EVALUATION WITH DIFFUSION WEIGHTED MAGNETIC RESONANCE IMAGING IN STAGING AND GRADING OF URINARY BLADDER CANCER

ORIGINALITY REPORT

12%

SIMILARITY INDEX

3%

INTERNET SOURCES

11%

PUBLICATIONS

0%

STUDENT PAPERS

PRIMARY SOURCES

1

Mitsuru Matsuki. "Diffusion-weighted MR imaging for urinary bladder carcinoma: initial results", *European Radiology*, 01/08/2007

Publication

3%

2

Wood, David P.. "Urothelial Tumors of the Bladder", *Campbell-Walsh Urology*, 2012.

Publication

2%

3

Giannarini, G.. "Potential and Limitations of Diffusion-Weighted Magnetic Resonance Imaging in Kidney, Prostate, and Bladder Cancer Including Pelvic Lymph Node Staging: A Critical Analysis of the Literature", *European Urology*, 201202

Publication

1%

4

Lerner, Seth P., and Cora N. Sternberg. "Management of Metastatic and Invasive Bladder Cancer", *Campbell-Walsh Urology*, 2012.

Publication

1%



Digital Receipt

This receipt acknowledges that Turnitin received your paper. Below you will find the receipt information regarding your submission.

The first page of your submissions is displayed below.

Submission author:	18112507 . M.ch. Urology RAMKUMAR J . JOTHIMAYACHARI
Assignment title:	Medical
Submission title:	EVALUATION WITH DIFFUSION WEIGHTED MAGNETIC RESONANCE IMAGING IN STAGING AND GRADING OF URINARY BLADDER CANCER
File name:	corrected_THESIS_PLAG.docx
File size:	2.11M
Page count:	53
Word count:	7,018
Character count:	39,948
Submission date:	29-Mar-2014 05:07AM
Submission ID:	410322837

INTRODUCTION

Bladder cancer is a common genitourinary tract malignancy. Following prostatic adenocarcinoma, it represents the second most common tumour of urological malignancy in the world. Urothelial tumours are cancers of the environment and advanced age. Bladder cancer is associated with old age and exposure to industrial toxins and smoking. It occurs most commonly in males than compared to female patients with ratio of 3:1 and is rare in the population less than 40 years of age.

According to WHO 2004 classification, urothelial tumours are categorized to muscle non-invasive and muscle invasive, based on invasion of detrusor muscle. Eighty percent of urothelial cancers are non-muscle invasive in nature and present with various types of growth pattern. Muscle-invasive tumour is defined by high grade and cancer cells invading through the lamina propria into the deeper muscle layers. Histologically urothelial carcinoma constitute 90 percent of bladder cancers, five percent are squamous cell carcinoma and less than five percent are adenocarcinoma or other types of tumours.

The management of bladder cancer varies according to muscle non-invasive and muscle invasive nature of the cancer. Muscle non-invasive tumours are managed with transurethral resection (TUR) and intravesical immunotherapy /