

**ROLE OF DYNAMIC MRI IN REPLACING THE  
ISOTOPE RENOGRAM IN THE FUNCTIONAL  
EVALUATION OF PUJO**

*Dissertation submitted in partial fulfillment of the requirement for the  
degree of*

**M.Ch (UROLOGY) – BRANCH – IV**



**THE TAMILNADU Dr.M.G.R. MEDICAL UNIVERSITY  
CHENNAI**

**AUGUST 2010**

## DECLARATION

I solemnly declare that this dissertation titled “ ROLE OF DYNAMIC MRI IN REPLACING THE ISOTOPE RENOGRAM IN THE FUNCTIONAL EVALUATION OF PUJO” was prepared by me in the Department of Urology, Government General Hospital, Chennai under the guidance and supervision of **Prof. R. Jeyaraman, M.Ch .**, Professor & Head of the Department, Department of urology, Government General Hospital, Chennai. This dissertation is submitted to the Tamil Nadu Dr. MGR Medical University, Chennai in partial fulfillment of the university requirements for the award of the degree of M.Ch. Urology.

Place: Chennai

Date:

DR.T.CHANDRU

## **CERTIFICATE**

This is to certify that the dissertation titled “Role of Dynamic MRI in replacing the Isotope Renogram in the functional evaluation of PUJO” submitted by **Dr.T.Chandru** appearing for **M.Ch. (Urology)** degree examination in August 2010, is a bonafide record of work done by him under my guidance and supervision in partial fulfillment of requirement of the Tamil Nadu Dr.M.G.R.Medical University, Chennai. I forward this to the Tamil Nadu Dr.M.G.R.Medical University, Chennai.

**Prof.R.Jeyaraman, M.S. M.Ch,**

Professor & Head of the Department,

Department of Urology,

Government General Hospital,

Madras Medical College,

Chennai -600003.

**The Dean**

Madras Medical College &

Government General Hospital ,

Chennai -600003

## ACKNOWLEDGEMENT

First of all, I would like to thank my patients, who subjected themselves for my dissertation work

I owe my thanks to the **Dean**, Madras Medical College and Government General Hospital, Chennai for allowing me to avail the facilities needed for my dissertation work.

I would like to express my humble gratitude to **Prof. R.Jeyaraman**, Professor and Head of the Department of Urology for his expert guidance and help rendered for the conduct and completion of my dissertation work.

I would like to thankfully acknowledge **Prof. V.Kamaraj** and **Prof. RM. Meyyappan**, Professors in the Department of Urology, for their constant help in the dissertation work.

I sincerely thank the Director, Barnard Institute of Radiology for his help in completing my dissertation.

I sincerely thank the Asst professors in the Department of Urology for their continuous inspiration and support in carrying out my dissertation.

Last, but not least, I thank my fellow past and present postgraduates who helped me in carrying out my work and preparing this manual.

INSTITUTIONAL ETHICAL COMMITTEE  
GOVERNMENT GENERAL HOSPITAL & MADRAS MEDICAL COLLEGE,  
CHENNAI-600 003.

Telephone: 044-2530 5000  
Fax : 044 - 25305115

L.Dis.No.14598/P & D3/Ethics/Dean/GGH/09

Dated:12.06.2009

Title of the work : " Role of Dynamic MRI in replacing Isotope Renogram in the Functional evaluation of PUJO"

Principal Investigator : Dr. T. Chandru MCh., PH


Department : urology, MMC ch-3.

The request for an approval from the Institutional Ethical Committee (IEC) was considered on the IEC meeting which is held on 23<sup>rd</sup> June at 2 P.M in Government General Hospital, Deans, Chamber, Chennai-3.


The members of the Committee, the Secretary and the Chairman are pleased to approve the proposed work mentioned above, submitted by the principal investigator.

The principal investigator and their term are directed to adhere the guidelines given below:

1. You should get detailed informed consent from the patients/participants and maintain confidentiality.
2. You should carry out the work without detrimental to regular activities as well as without extra expenditure to the Institution or Government.
3. You should inform the IEC in case of any change of study procedure, site and investigation or guide.
4. You should not deviate form the area of the work for which I applied for ethical clearance.
5. You should inform the IEC immediately, in case of any adverse events or serious adverse reactions.
6. You should abide to the rules and regulations of the institution(s)
7. You should complete the work within the specific period and if any extension of time is required, you should apply for permission again and do the work.
8. You should submit the summary of the work to the ethical committee on completion of the work.
9. You should not claim funds from the Institution while doing the work or on completion.
10. You should understand that the members of IEC have the right to monitor the work with prior intimation.

  
SECRETARY  
IEC, GGH, CHENNAI

  
CHAIRMAN  
IEC, GGH, CHENNAI

  
DEAN  
GGH & MMC, CHENNAI

# DISSERTATION

Sl.No	CONTENTS
1.	Introduction
2.	Aim and Objectives
3.	Review of Literature
4.	Imaging of Pelvi -Ureteric Junction Obstruction
5.	Materials & Methods
6.	Observation & Results
7.	Discussion
8.	Conclusion
9.	Bibliography
10.	Appendix
	Appendix 1. Consent Form
	Appendix 2. Proforma
	Appendix 3. Master Chart.

## INTRODUCTION

Pelviureteric Junction obstruction is one of the most common cause of Hydronephrosis and continues to present a challenge to Radiologists and Urologists, who are unable to accurately predict which patient will benefit from surgery <sup>(1)</sup>. Traditional imaging tests have emphasized detection and grading of Hydronephrosis with Sonography and determination of Renal function and obstruction with Scintigraphy. The classification of the kidney as obstructed does not predict progressive loss of function and does not identify which patient will benefit from surgery <sup>(2)</sup>.

The increase in the detection of asymptomatic Pelvi -Ureteric Junction Obstruction , because of the increasingly widespread USG has exacerbated this problem. Although, pain and recurrent infections are independent indications for surgery, these are much less commonly seen. In many cases, Pelvi- Ureteric Junction Obstruction is self limited, with no long term sequelae.

As a result of this variable outcome, Management of Pelvi - Ureteric Junction Obstruction is controversial, with some authors recommending early surgery and others advocating simple observation <sup>(3)</sup>.

Most surgeons monitor Hydronephrotic kidney with Sonography, and use decreasing function or worsening Hydronephrosis as an indicator for surgical intervention. The problem with this approach is that some obstructed kidneys will deteriorate while under observation. It would be better to identify and surgically correct the condition in those patient before Nephron loss occurs.

Previous studies have shown that dynamic contrast enhanced MR Urography has several advantages in the evaluation of Pelvi - Ureteric Junction Obstruction, because, it combines both anatomic and functional information in single test that does not use Ionizing Radiation . MRI has progressed significantly in recent years because



of the development of both hardware and software that are used to generate high resolution images.

## **AIM & OBJECTIVES**

The aim of this study is to

- To find out the Extent of obstruction in Pelvi - Ureteric Junction Obstruction.
- To find out the functional potential of the Hydronephrotic Kidney.
- To determine, if dynamic contrast enhanced MR Urography could replace Isotope Renogram in the functional evaluation of Pelvi - Ureteric Junction Obstruction.

## REVIEW OF LITERATURE

MRI of the Hydronephrotic system has been reported in several animal studies as well as smaller human studies <sup>(10)</sup> . Wen et al used Gd-DTPA enhanced MRI in rats, and believed that it provided the necessary information to distinguish between an obstructed and non obstructed collecting system <sup>(10)</sup>.

Rodriguez et al reported on 3 patients with Pelvi - Ureteric Junction Obstruction evaluated by MRI and recommended it as an alternative to the combination of studies currently used to evaluate Hydronephrosis. <sup>(11)</sup>.

Marcos R. Perez -Brayfield, J. Damien Grattan - smith <sup>(12)</sup>. reported, the largest series to date using MR Urography in the evaluation of Hydronephrosis in children. In this series of 96 patients, MR Urography accurately defined anatomical detail and differential renal function in a single study without Ionizing Radiation. The

calculation of relative renal function by MR Urography revealed excellent correlation with Renal Scintigraphy ( $r^2=0.83$ ).

Nils Hackstein, <sup>(13)</sup> from Germany, has studied 28 adult patients, he compared GFR as measured by Plasma clearance using a small bolus injection of Iopromide with that of Gd-DTPA enhanced MRI. He found good correlation between the method. Pearsons correlation coefficient was  $r =0.86$ , S.D. was 14.8 ml/mt.

Tarek A. El-Diasty, Abou EL. Ghas <sup>(14)</sup> from Egypt, has conducted, a study, involving 46 patients with symptomatic Pelvi - Ureteric Junction Obstruction. They found that the mean MR clearance of the obstructed unit was 32.8 ml/mt while, the Radio Isotope clearance was 31.6 ml/mt and there was a strong correlation between them ( $r=0.82$ ,  $P <0.001$ ). Time intensity curves plotted for dynamic MRI and Diuretic Renography gave similar results for the diagnosis of obstruction.

Rohrscheneider <sup>15</sup> et al from Germany, has studied 62 patients of Hydronephrosis with MRI. He has quoted that Image quality is good or excellent in 95% of cases. For split Renal function, DMRI and DRS showed significant correlation ( $r = 0.92$  ,  $P < .001$ ). For urinary excretion, MR Urography & DRS showed strong agreement ( $k=0.67$ ).

Damien Grattan - Smith et al have studied the utility of Dynamic Magnetic Resonance Imaging in Pelvi - Ureteric Junction Obstruction in children. The author has noted that anatomic evaluation combined with Renal transit time classification provides a reliable parameter for the identification of obstruction. The ability of MR Urography to identify crossing vessels offers distinct advantages over other techniques. Individual renal functional assessment with attention to the peak medullary signal intensity, distal tubular peak, seems to identify the earliest signs of functional derangement in obstructed systems.

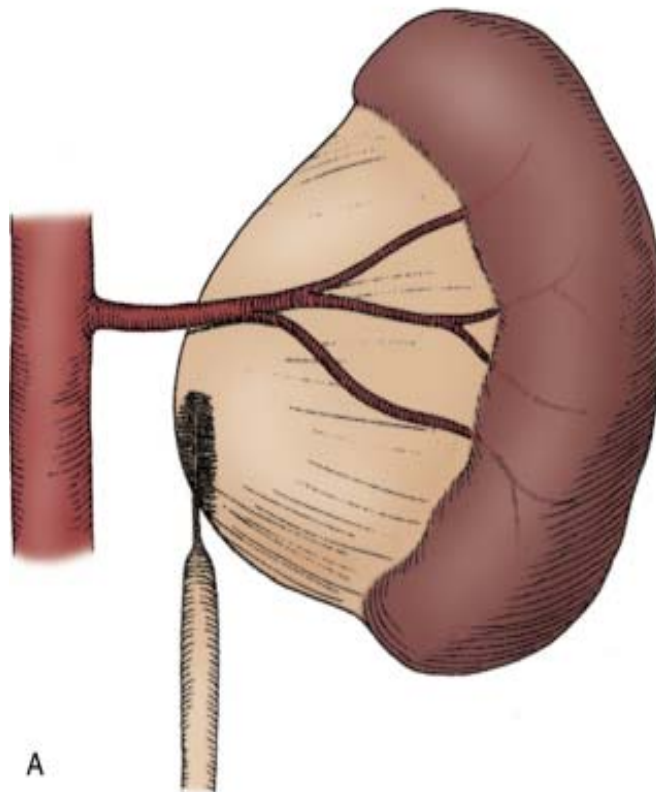
## PUJO

Congenital UPJ obstruction most often results from intrinsic disease. A frequently found defect is the presence of an aperistaltic segment of the ureter. In these cases, histopathologic studies reveal that the spiral musculature normally present has been replaced by abnormal longitudinal muscle bundles or fibrous tissue. This results in failure to develop a normal peristaltic wave for propagation of urine from the renal pelvis to the ureter.

Recognition that this type of segmental defect is often responsible for UPJ obstruction is of utmost importance clinically because such ureters may appear grossly normal at the time of surgery, and, in fact, may often be calibrated to 14 Fr or greater.

Further investigations in the etiology of UPJ obstruction have shown decreased interstitial cells of Cajal at the UPJ. In addition, the cytokine produced in the urothelium has also been proposed to

exacerbate UPJ obstruction . Other experimental studies have implicated Transforming growth factor- $\beta$ , Epidermal growth factor expression, Nitric oxide, and Neuropeptide Y in UPJ stenosis . A less frequent intrinsic cause of congenital UPJ obstruction is true ureteral stricture. Such congenital ureteral strictures are most frequently found at the UPJ, although they may be located at sites anywhere along the lumbar ureter. Abnormalities of Ureteral musculature have been implicated as electron microscopy has demonstrated excessive collagen deposition at the site of the stricture .



Significant controversy persists regarding the potential role of “aberrant” vessels in the etiology of UPJ obstruction. Significant crossing vessels have been noted in as many as 40% of cases of UPJ obstruction but as little as 20% of cases of normal kidneys. In fact, the true etiology is an intrinsic lesion at the UPJ or proximal ureter that causes dilatation and ballooning of the renal pelvis over the polar or aberrant vessel.

UPJ obstruction, although most often a congenital problem, can present clinically at any time of life. In older children or adults, intermittent abdominal or flank pain, at times associated with nausea or vomiting, is a frequent presenting symptom. Hematuria, either spontaneous or associated with otherwise relatively minor trauma, may also be an initial symptom.

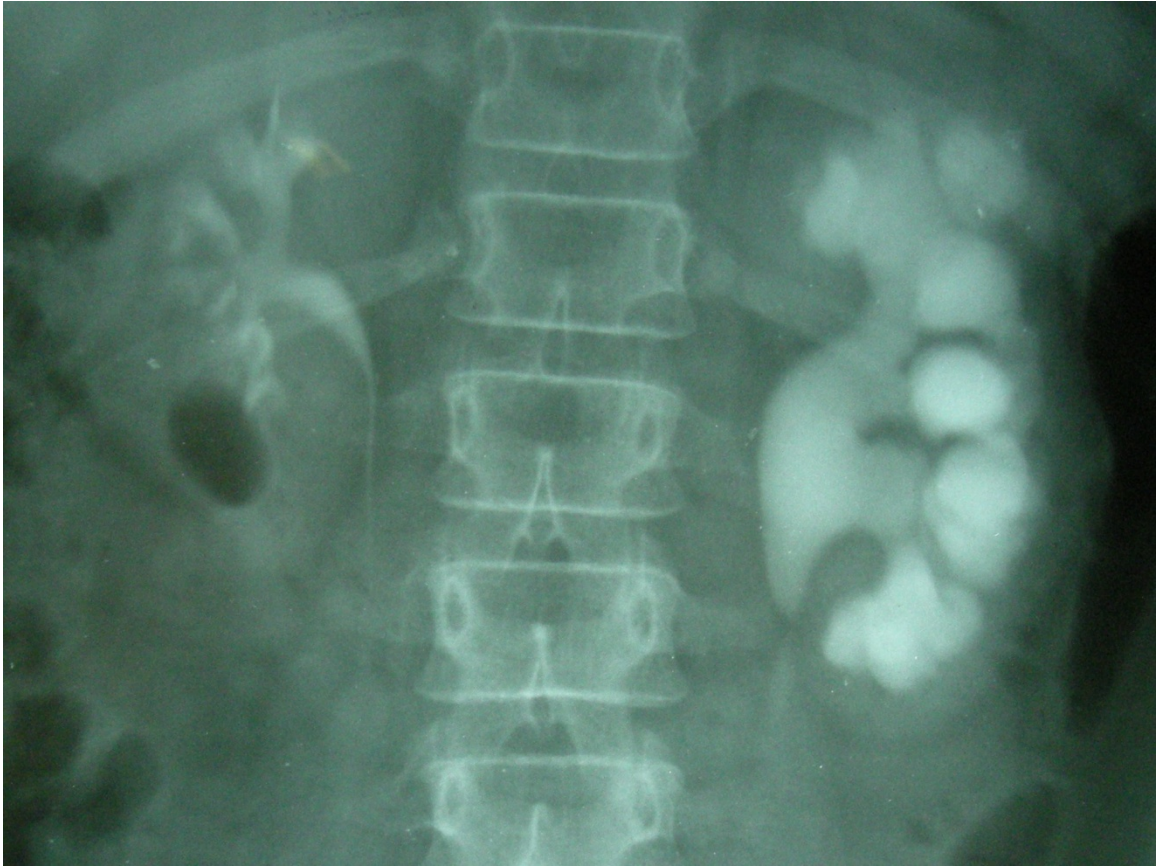Laboratory findings of microhematuria, pyuria, or frank urinary tract infection might also bring an otherwise asymptomatic patient to the urologist. Rarely, hypertension may be a presenting



finding , Riehle and Vaughan, 1981.

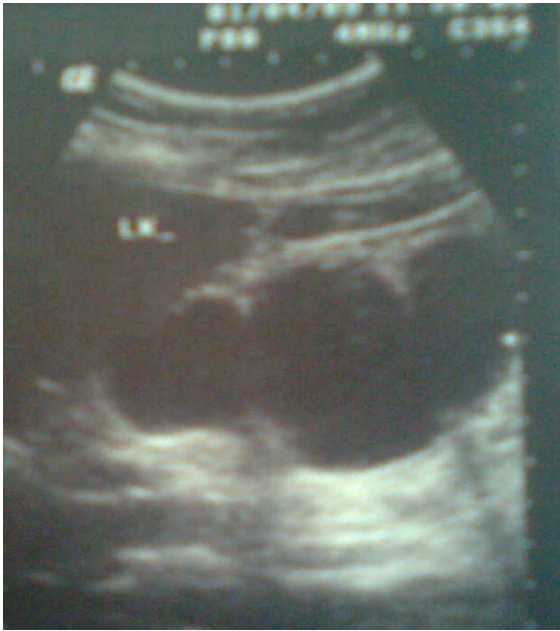Radiographic studies should be performed with a goal of determining both the anatomic site and the functional significance of an apparent obstruction. Excretory urography remains a reasonable first-line option for radiographic diagnosis. Classically, findings on the affected side include delay in function associated with a dilated pelvicalyceal symptom . If the ureter is visualized, it should be of normal caliber. In some patients, symptoms may be intermittent and intravenous pyelography between painful episodes may be normal. In such cases, the study should be repeated during an acute episode When the patient is symptomatic.

In some, provocative testing with diuretic urogram may allow accurate diagnosis. The patient should be well hydrated and the study then performed by injecting furosemide, 0.3 to 0.5 mg/kg, intravenously at the time of intravenous urography Malek, 1983 .

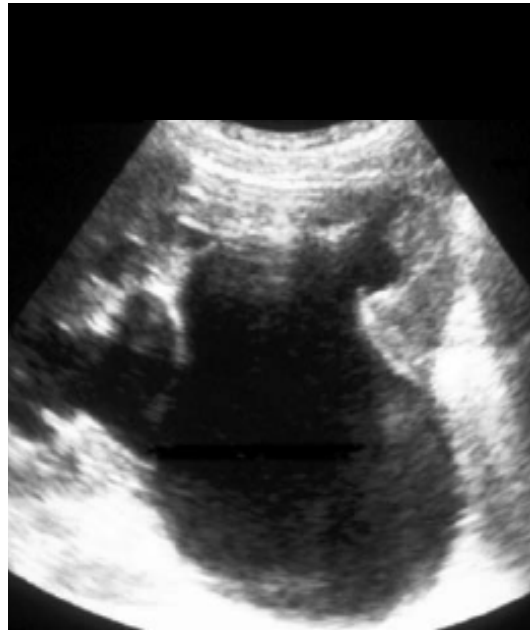


**IVU Showing Lt PUJO**

Ultrasonography has also maintained an important role in diagnosis. Although it is a valuable initial diagnostic study under any circumstances in which overall renal function is inadequate to give intravenous contrast, ultrasonography may also be performed in any patient in whom an initial intravenous urogram reveals nonvisualization of the affected collecting system to differentiate ureteral obstruction from alternate causes of nonvisualization.

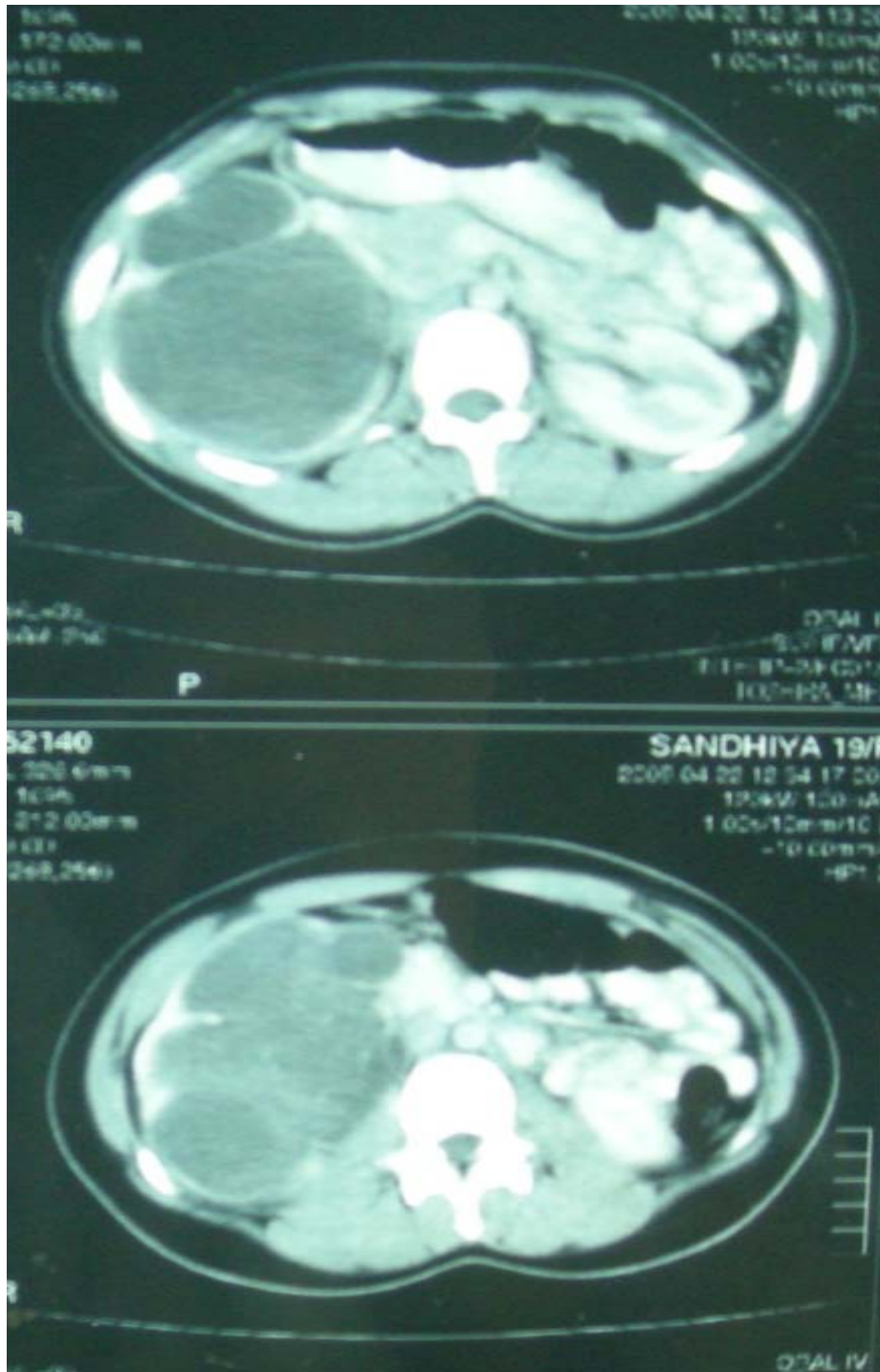


**USG Showing Lt HN**

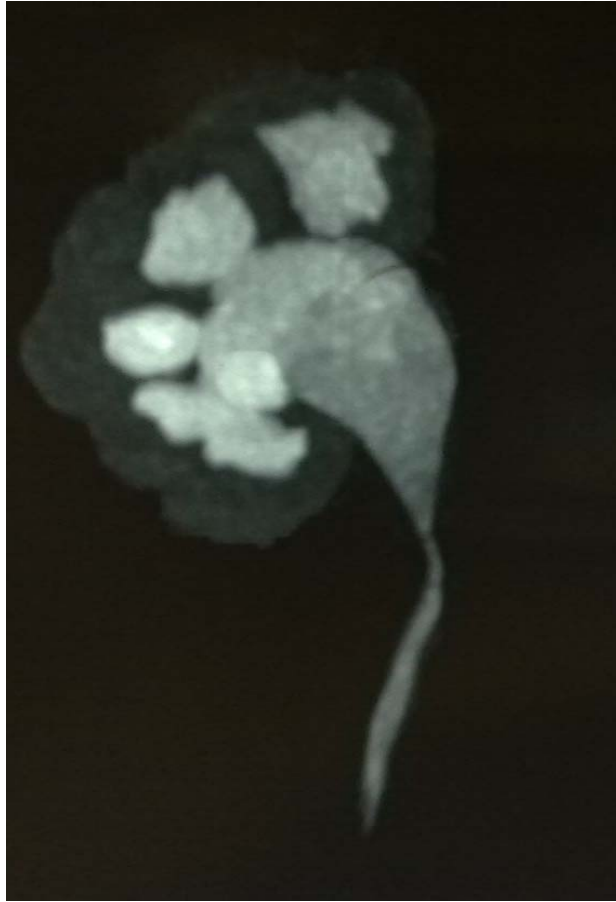

**Rt HN**

Despite this, CT is now the first imaging technique generally obtained for any patient presenting with acute flank pain , Fielding et al, 1997 . Both ultrasonography and CT also have a role in differentiating acquired causes of obstruction such as radiolucent calculi or urothelial tumors.



Rt PUJO with thinned out Cortex

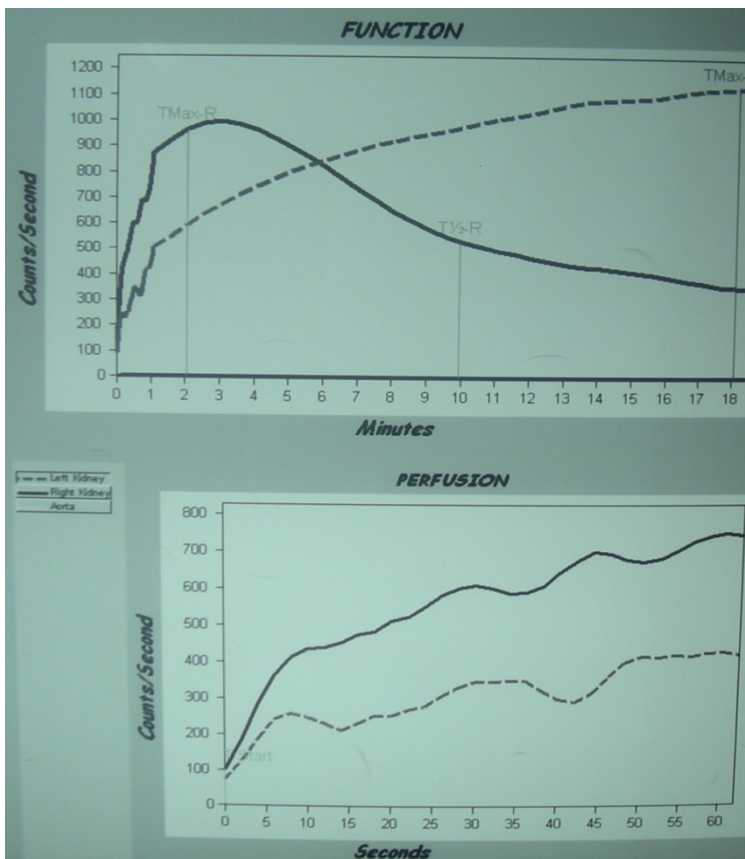


**Reconstructed Image of Rt PUJO**

Diuretic renography is effective in predicting recoverability of function in cases in which intravenous urography has revealed nonvisualization. Diuretic renography allows quantification of the degree of obstruction and can help differentiate the level of obstruction. Today,  $^{99m}\text{Tc}$ -MAG3 is the preferred isotope because of favorable imaging and dosimetry considerations over  $^{99m}\text{Tc}$ -DTPA or radioiodinated Hippuran , Roarke and Sandler, 1998 . Presently,



diuretic renography is a commonly utilized study for diagnosing both UPJ and ureteral obstruction, because it provides quantitative data regarding differential renal function and obstruction, even in hydronephrotic renal units. Diuretic renography is noninvasive and readily available in most medical centers. It ideally can be used to follow patients for functional loss, but it is most effective when a standard protocol is used.



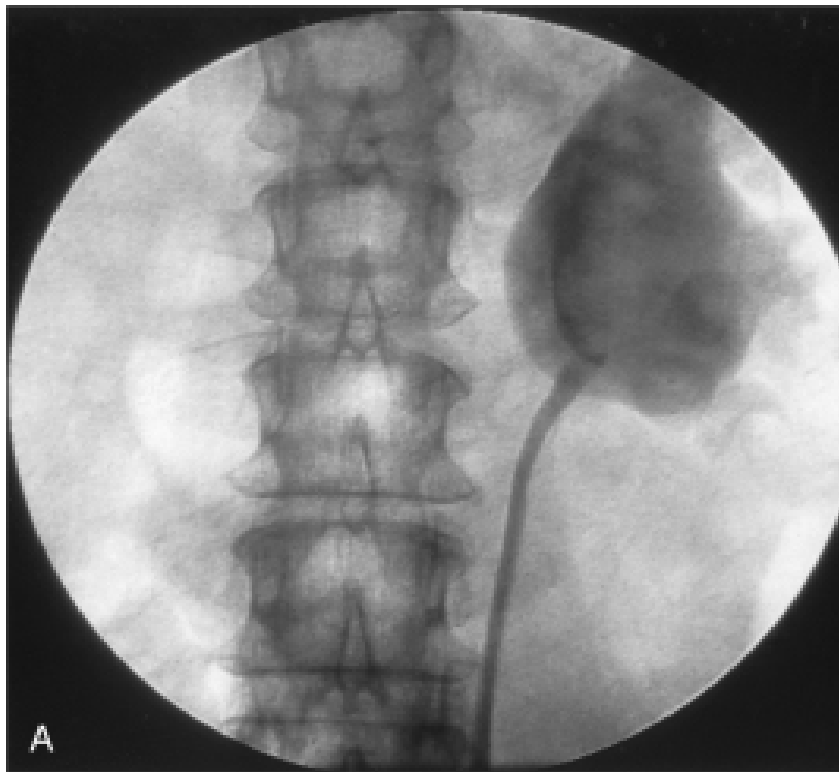
**Time Intensity Curve - Lt PUJO**

The diuretic is given 20 minutes into the study to allow time for filling of the collecting system. One study found diuretic renography to be useful in children to rule out concomitant UPJ obstruction with associated high-grade reflux , Stauss et al, 2003. There is evidence that the diuretic renography using  $^{99m}\text{Tc}$ -MAG3 is a most accurate study for patients with UPJ obstruction

Retrograde pyelography thus retains a role for confirmation of the diagnosis and for demonstration of the exact site and nature of obstruction before repair. In most cases this study is performed at the time of the planned operative intervention to avoid the risk of introducing infection in the face of obstruction.

Retrograde pyelography is indicated emergently whenever the UPJ obstruction requires acute decompression, such as in the setting of infection or compromised renal function. In cases in which cystoscopic retrograde manipulation has been unsuccessful or may be hazardous, particularly in neonates or infants, placement of a percutaneous nephrostomy is an excellent alternative.

This allows the performance of antegrade studies that will help define the nature and exact anatomic site of obstruction. It also allows decompression of the system in cases of associated infection or compromised renal function and allows assessment of recoverability of renal function after decompression. When there remains some doubt as to the clinical significance of a dilated collecting system, placement of a percutaneous nephrostomy tube allows access for dynamic pressure perfusion studies.





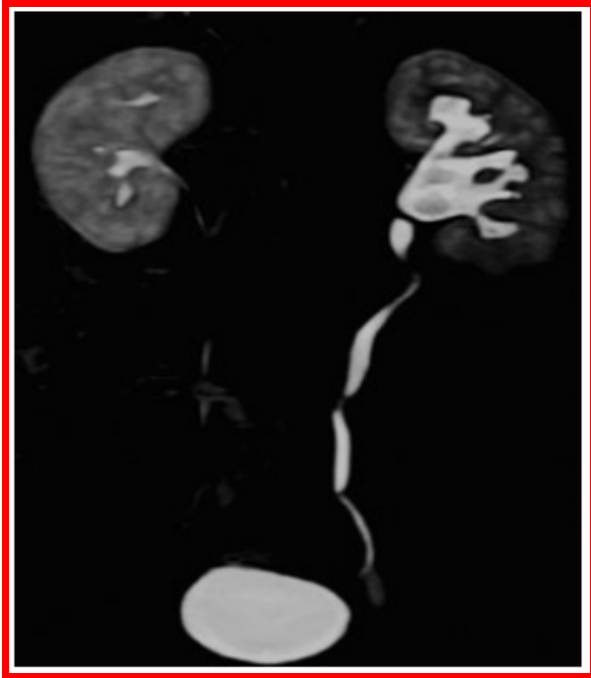Much like the work that was done to define the utility of nuclear renography in the evaluation of PUJO , MRI urography is being investigated to define urinary tract anatomy, calculate differential renal function, and assess urinary tract obstruction , Grattan-Smith et al, 2003 . In comparison with ultrasonography and nuclear renography, dynamic contrast enhanced MRI is superior . The differential renal function, as determined by calculating the volume of enhancing renal parenchyma, is comparable to that determined by nuclear renography. When assessing the utility of each modality, as determined by the decision to proceed with surgery or not, MR urography has been shown to be as sensitive, more specific, and of greater diagnostic efficiency than renal scintigraphy. Because there is no absolute test that exists to define obstruction precisely, the surgery itself becomes the endpoint, Grattan-Smith et al, 2003 .

Further refinements in dynamic contrast material enhanced MR urography include the calculation of renal transit time . This

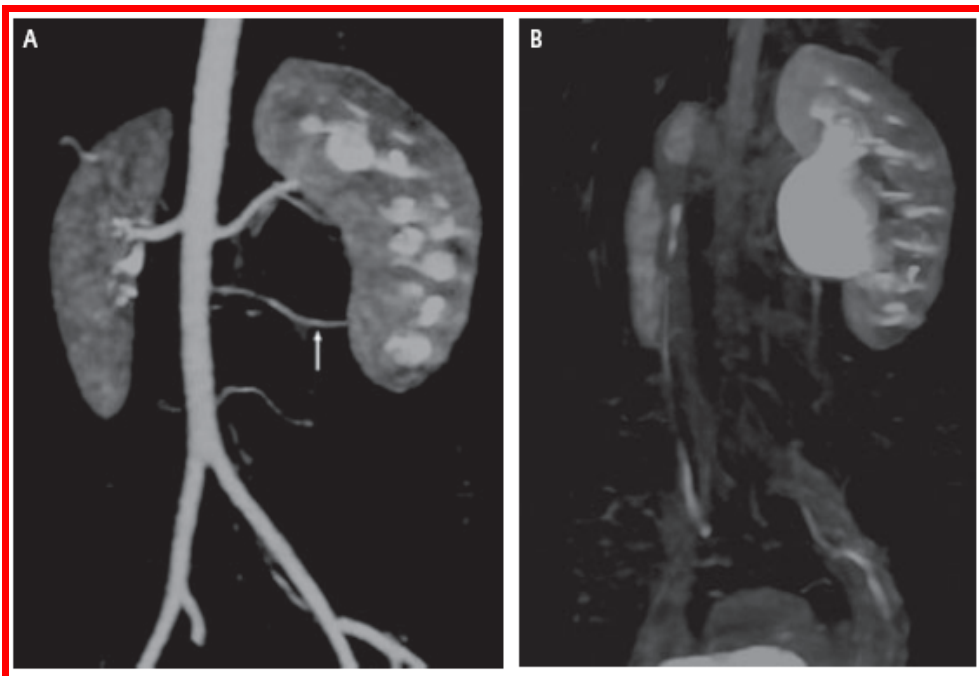
calculation complements the determination of differential renal function.

MRI and nuclear medicine studies are equally sensitive in detecting obstruction, but the definition of obstruction becomes somewhat arbitrary because there is no reference test to define obstruction. MRI does not involve ionizing radiation so that multiple follow-up studies can be performed to monitor hydronephrosis. This must be balanced with the higher expense, need for sedation, and higher frequency of adverse reactions to the contrast agent. Further refinements in the technique and more widespread application to other centers will be forthcoming.

Further refinements in dynamic contrast material enhanced MR urography include the calculation of renal transit time , Jones et al, 2004 . This calculation complements the determination of differential renal function.



**Gadodiamide enhanced MRU shows mild Lt hydronephrosis with a filling defect at the PUJ secondary to a crossing vessel**



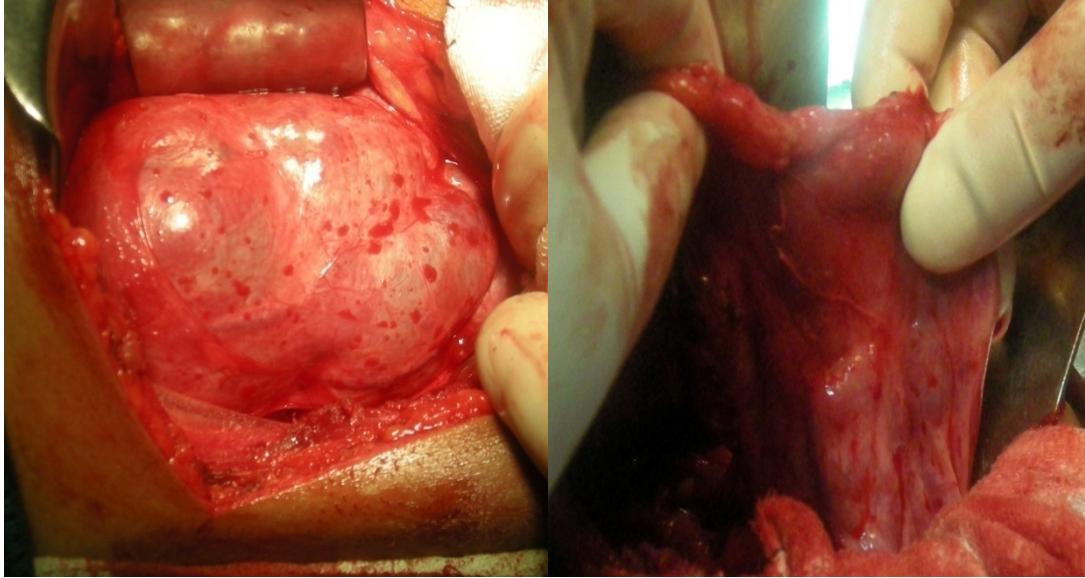
**MRA shows a vessel crossing the dilated nonopacified Lt pelvis to the lower pole**

Contemporary indications for intervention for UPJ obstruction include the presence of symptoms associated with the obstruction, impairment of overall renal function or progressive impairment of ipsilateral function, development of stones or infection, or, rarely, causal hypertension.

The primary goal of intervention is relief of symptoms and preservation or improvement of renal function. Traditionally, such intervention should be a reconstructive procedure aimed at restoring nonobstructed urinary flow. This is especially true for neonates, infants, or children in whom early repair is desirable, because these patients will have the best chance for improvement in renal function after relief of obstruction , Bejjani and Belman, 1982 . However, timing of the repair in neonates remains controversial.

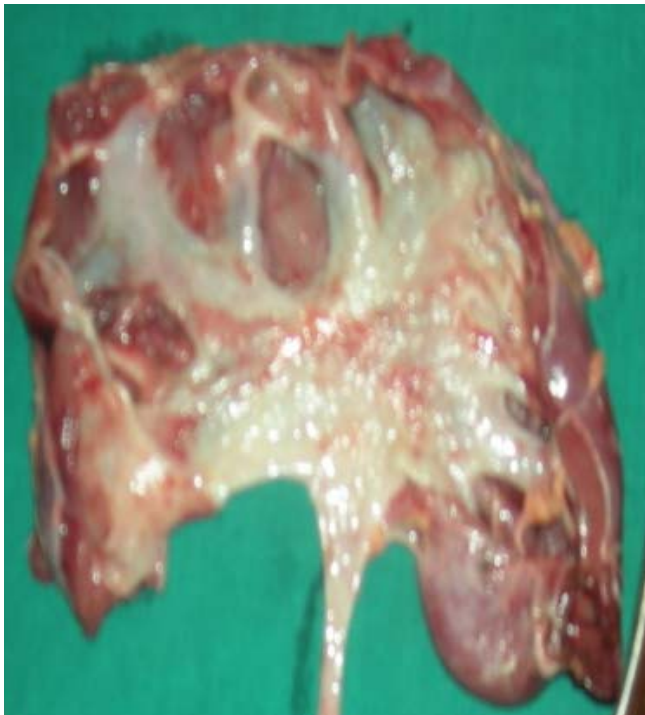UPJ obstruction may not become apparent until middle age or later , Jacobs et al, 1979. Occasionally, if the patient is asymptomatic and the physiologic significance of the obstruction seems indeterminate, careful observation with serial follow-up studies may

be appropriate, typically using diuretic renography.

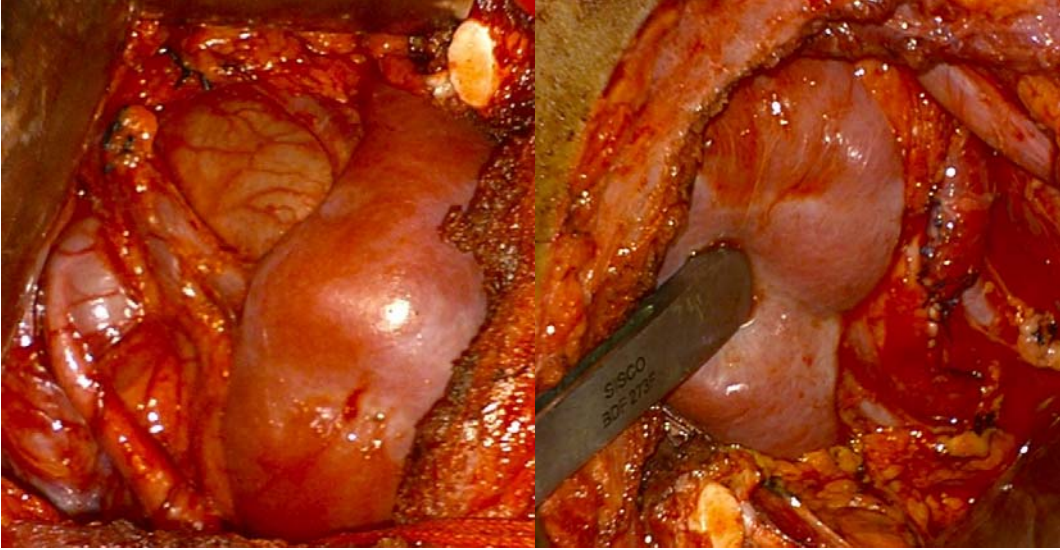


**Per OP Pictures showing Thinned out cortex**

**Nephrectomy Picture**



## Open Pyeloplasty



## FUNCTIONAL IMAGING OF PUJO

Imaging of Pelvi – Ureteric Junction Obstruction includes Renal USG, IVU, Diuretic Renal Scintigraphy, and Retrograde Ureteropyelography. Newer methods eg. Multiphasic helical CT and Endoluminal USG have also been used for detecting the cause of obstruction by identifying adjacent anatomy <sup>(17)</sup>.

The whitaker test is often considered the reference test for detecting and grading obstruction, but this invasive test is infrequently performed, provides no information on renal function, lacks objective criteria, and uses nonphysiologic flow rates <sup>(18)</sup>.

Thus, the default standard is Diuresis Renal Scintigraphy, which uses either Technetium -99m DTPA (Diethylenetriamine Penta acetic acid) as a glomerular tracer or 99m Tc mercapto acetyl triglycine (MAG3) as a tubular tracer and an injection of furosemide to provide a diuretic challenge to the kidney. A number of protocols

have been developed for Diuresis Renal Scintigraphy using different timing for the administration of furosemide relative to the injection of the tracer <sup>(5)</sup>. Regardless of which protocol is used, time activity curves are derived for each kidney and these are characterized by indexes such as the rate of washout of the tracer.

The principal limitations of DRS are that it relies on projection images, that it provides limited anatomic assessment of the urinary tract, and that it needs depth correction of counts and background subtraction.

MR Urography provides anatomic images of the kidneys and ureters with excellent spatial and contrast resolution, and this can be combined with dynamic contrast enhanced MR Urography and which uses high temporal resolution to follow the passage of a contrast agent through out the kidney. Dynamic MR Urography can accurately assess the split renal function <sup>(15,19)</sup> and provide useful information on renal function. However, the interpretation of the images is not straight forward and often involves extensive post



processing <sup>(15,19)</sup> .Patient is scanned first and then Furosemide and contrast is injected together and then rescanned. The Renal Transit time is defined as the time between the arrival of contrast material in the cortex and its arrival in the ureter. The Renal transit time has been shown to be well correlated with the half life - washout time, which is widely used to characterise diuresis renal scintigraphy studies <sup>(20)</sup>.

The advantages of MRI over other Radiological techniques are : high soft tissue characterisation, capability of direct multiplanar and three dimensional reformatting, use of Non-Ionizing Radiation and a non nephrotoxic contrast medium .

The main problem for DMRI has been the cost. However, the cost is offset by the fact that a single MRI examination provides anatomic and functional information and an assessment of vasculature.

## MATERIALS AND METHODS

### *Title of study*

Role of Dynamic MRI in replacing Isotope Renogram in the functional evaluation of Pelvi - Ureteric Junction Obstruction.

### *Period of Study*

January 2008 - March 2010

### *Type of Study*

Prospective Study

### *Source of patients*

Patients with PUJO, who presented to the Department of Urology, Madras Medical College, Government General Hospital, Chennai.

## **Patient Selection**

### *Inclusion Criteria*

- All those patients diagnosed to have Pelvi - Ureteric Junction Obstruction based on USG, IVU, CT.
- Symptomatic patients with Pelvi - Ureteric Junction Obstruction were included in our study.

The Institutional review board at our hospital approved the study and informed consent was obtained from all the patients. All these patients were investigated with Isotope Renogram and subsequently, subjected to Dynamic MRI.

### *Exclusion criteria*

- Patients with structural defects like Duplex system, Horse - shoe kidney.
- Patients with B/L PUJO.

- Previous surgery.
- Patients with Pacemaker & Metallic Implants.
- Claustrophobic patients.

### *Patient preparation*

No specific preparation

### *Patient position*

Supine

### **Imaging Examination**

#### *Isotope Renogram*

DRS was performed and results evaluated according to current recommendations <sup>(4)</sup> Scintigraphy followed by IV injection of 12  $\mu$ ci / kg Technetium - 99m MAG-3, with a minimum activity of 150  $\mu$ ci. A

large field of view gamma camera equipped with a low energy all purpose collimator was used. The window was placed over the photo peak of the tracer and was opened by 20%. A 128 x 128 image matrix was used. Data were collected in 12 second time frames.

The scintigraphic examination lasted 40 minutes and furosemide was administered along with the tracer (F+0) . ROIs were placed by an experienced technician who prepares the imaging material for medical evaluation. Rectangular background ROIs near the upper & lower pole were automatically selected by the system software and manually corrected, if necessary.

The area was, on average, one fourth that of the kidney ROI and was prorated to correspond to the area of the kidney ROI.

Time activity curves were generated from the background corrected count rates.

## *MR Imaging*

All MRI was conducted on a 1.5T Siemens scanner, with the use of a phased- array torso surface coil. The procedure started by obtaining a coronal localizer (scout image) to identify the abdominal aorta and the origins of the renal arteries, followed by a coronal T2 weighted sequence for the whole of both kidneys and six coronal fast spoiled gradient (FSPGR) images at the centre of the kidney.

Then, dynamic MRI was performed by IV injection with 0.1 mmol / kg gadodiamide (Gd- DTPA) at 3 ml/sec and the coronal scan series was repeated every 30 sec for 5 minutes. Furosemide (0.3 mg/kg) was injected along with the contrast to assess the contrast medium excretion in response to the diuretic. The total amount of contrast was 20-30ml according to body weight.

Finally, Excretory MR urography was performed using contrast enhanced T<sub>1</sub> weighted 3 D- FSPGR acquisition at 7-10 min after gadodiamide injection to visualize the collecting system and the ureter <sup>(21)</sup>.

Maximum intensity projection images were obtained, and using the coronal and sagittal MIP images, the anatomy of the pelvicalyceal system and ureter identified.

For DMRI, we started by visually interpreting the images, comparing the series before and after contrast medium, to determine the degree of parenchymal enhancement, and the excretory power of each renal unit.

The DMRI curve was generated by drawing a region of interest, over the kidney, excluding the Renal pelvis, using Functional software, that merges all series, a curve resembling that from Isotope Renography was obtained. The DMRI curve plots the enhancement units vs time and from the curve, the time to peak, the relative maximum units of enhancement and the response to diuretic were obtained. The mean post processing time was 60 (45-70) min.

## Image Analysis

### *Isotope Renogram*

The activity and the  $T_{1/2}$  of renal signal decay after furosemide administration of each kidney was categorized as being normal, equivocal, or obstructed, with Normal kidney having  $T_{1/2}$  of less than 10 minutes, Equivocal kidneys had a  $T_{1/2}$  between 10 & 20 minutes, Obstructed kidneys has a  $T_{1/2}$  more than 20 minutes. Glomerular filtration rate and split renal function calculated.

### *MR Images*

MR findings were evaluated with regard to the Glomerular filtration rate, the intra Renal Transit time of the contrast material. Time intensity curve is then plotted using in built software.

MR Renogram exhibited three typical phases, similar to Scintigraphic time activity curves. The first segment increases steeply, reflecting contrast material bolus delivery to the kidney by



means of blood circulation. The second segment shows a slower, almost linear increase to a peak maximum. This segment represents parenchymal transfer and continues to increase while more contrast material is extracted from the blood into the kidney than is excreted by the tissue into the collecting system. This segment is used to calculate the single kidney function <sup>(22,23,24)</sup>. The third segment is characterised by a prompt decline and reflects contrast material elimination from the parenchyma into the collecting system.

For each patient, Renal transit time <sup>(20)</sup> is used to classify the kidney as being -

Normal : < 245 sec

Equivocal : > 245 - < 490 sec

Obstructed : > 490 sec

Visualization of the distal ureter is also noted down.

If there is gross discrepancy between the Isotope Renogram and MR findings, then, to assess the salvageability of that Renal unit, PCN to be done and PCN fluid analysis to be done after 1 month. Planned

procedure, Either Pyeloplasty or Nephrectomy to be decided based on salvageability results of PCN fluid analysate.

## **Surgical findings**

Surgery was planned according to the conventional Isotope Renogram, and then, if needed, the planned surgical procedure was changed according to the operative findings.

## ***Statistical Analysis***

Statistical software (SPSS. Version 17) was used to analyse the data. The findings from Isotope Renogram and Dynamic MRI were correlated individually with the surgical finding. The accuracy of Isotope Renogram and Dynamic MRI were individually determined and compared. Linear Regression analysis was performed to correlate the imaging and surgical procedure done.

## OBSERVATION AND RESULT

Total No of patients studied : 45.

The patients ranged in age from 17 to 45 years, with a mean age of 31.21 years.

Two patients had Pyonephrosis, hence PCN done, one patient had Renal calculus , & hence excluded from our study.

### 1) Imaging Findings

In all the 42 patients, evaluated with Isotope Renogram, the Intrarenal transit of Radiotracer was calculated. Total GFR calculated and split Renal functions deduced.

Out of the 42 cases, 9 cases were conservatively managed, as they had good split renal function and unobstructed flow pattern in Time intensity curves. These cases are under follow up.

33 cases was taken up for surgical intervention.

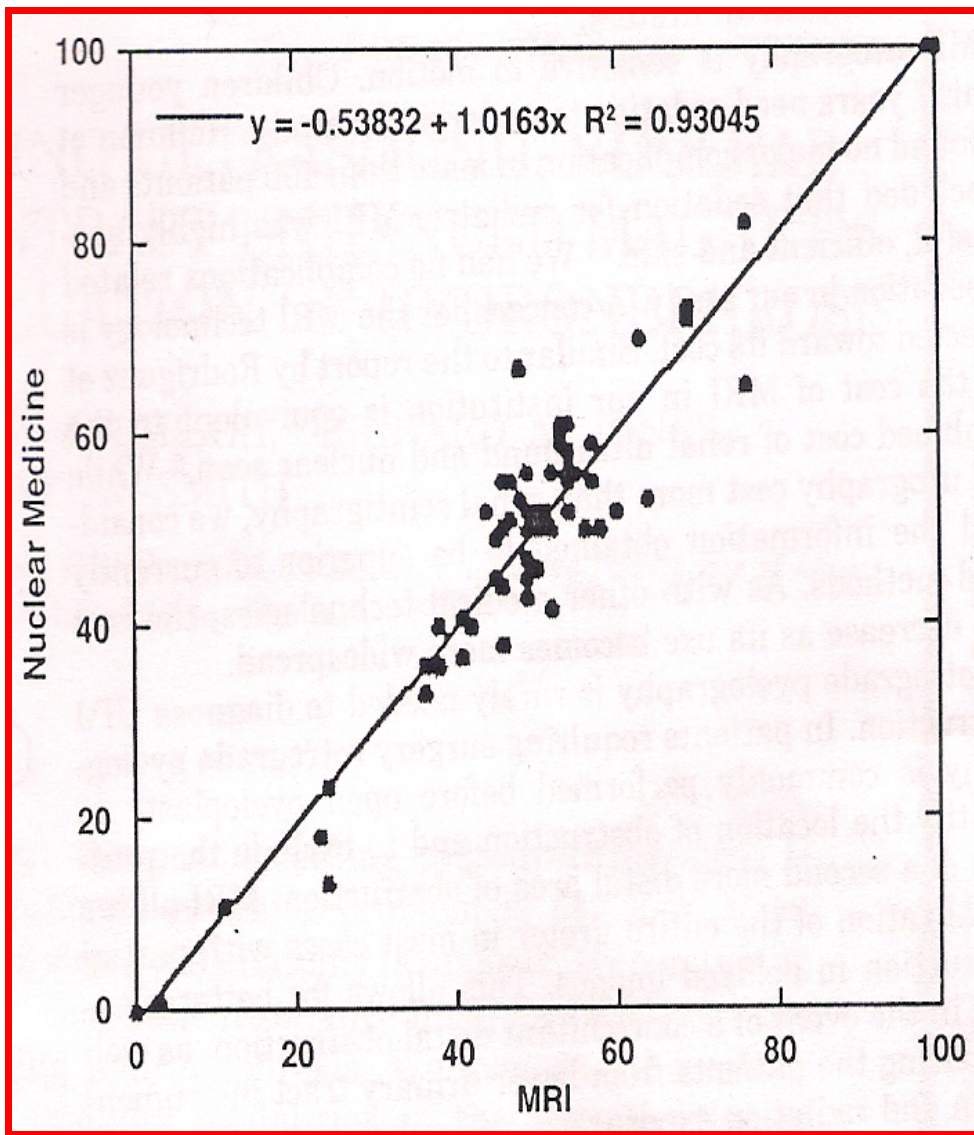
With Isotope Renogram, no information was obtained about the Renal parenchymal thickness. Post contrast T<sub>1</sub> weighted coronal images and SPGR were taken. ROI was plotted and Time intensity curves obtained with the help of in built software.

## 2) GFR

GFR Estimation	Mean	SD
Isotope Renogram	22.5	4.2
Dynamic MRI	23.8	3.1

The mean GFR as measured by Isotope Renogram was 22.5 with a standard deviation of 4.2. The mean GFR as estimated by Dynamic MRI was 23.8 with a standard deviation of 3.1. The calculation of

GFR by Isotope Renogram, showed good correlation with that of Dynamic MRI with correlation coefficient 0.93.



3) Accuracy of Imaging compared to surgery

**Accuracy of Isotope Renogram compared to surgery**

Isotope Renogram	Freq	%
Accurate	30	90.9
Non Accurate	3	9.1

**Accuracy of Dynamic MRI compared to surgery**

Dynamic MRI	Freq	%
Accurate	31	93.93
No Interpretation	2	6.07

There was an error in the calculation of GFR using Isotope Renogram, due to the evaluation of counts using Gamma camera. The Isotope study and the Dynamic MRI were done by the same technician respectively for all the cases.

Three patients had discrepancy of GFR between Isotope Renogram and Dynamic MRI. To decide on the surgical modality to be undertaken, PCN was done on that Renal unit. PCN fluid analysis done after 4 weeks of PCN drainage. All the three patients had poor quality of PCN fluid and these patients were deemed to have irreparable renal tubular damage and hence, surgical decision to proceed with Laparoscopic Nephrectomy was planned. Thus, in these cases, Isotope Renogram has over estimated the GFR.

Two patients could not be evaluated using MRI one due to motion artifact, one due to incidental stone. No information was obtained for the same.

#### 4) Surgical Approach

Surgical procedure	Freq	%
Pyeloplasty	21	63.63
Nephrectomy	12	36.36

Of 33 patients taken up for surgical intervention, 12 of the patient underwent Laparoscopic Nephrectomy, while, 21 of the patient underwent Pyeloplasty.

#### 5) Surgical approach intended in relation to the GFR estimated using Isotope Renogram.

Surgical Approach planned	Mean	SD
Pyeloplasty	33.5	3.8
Nephrectomy	11	2.1



*Surgical approach intended in relation in the GFR estimation by Dynamic MRI.*

Surgical Approach planned	Mean	SD
Pyeloplasty	35.4	5.2
Nephrectomy	10.8	2.4

GFR estimation as detected by Dynamic MRI correlated with that of Isotope Renogram with correlation coefficient 0.93.

## 6) Renal Transit time

	Isotope Renogram	Dynamic MRI
< 245 sec	7	7
245 - 490	2	2
> 490 sec	33	33

Renal Transit time detected by either imaging was correlated with each other. 7 patient had normal Transit time, and were conservatively managed with regular follow up. 2 patients had Renal Transit time fallen in the equivocal group. These patients were selected for follow up. Remaining 33 patients were deemed obstructed and taken up for surgical intervention.

## 7) Visualisation of Distal ureter

D.MRI

Visualised	22
Not visualized	11

Sensitivity 66%

The ureter distal to the obstruction was well visualized in 22 out of 33 patients in MR imaging. This obviates the role of Bulboureterogram to look for patency or to rule out the double obstruction.

This allows for better planning in the event of a concomitant distal obstruction as well as sparing the patient from lower urinary tract instrumentation and Radiation exposure. While, Anatomic imaging of the ureter was not possible with Isotope Renogram.

### 8) Accuracy of Imaging

Imaging	Proposed Procedure		$\chi^2$	pValue
	Pyeloplasty	Nephrectomy		
Isotope Renogram	24	9	0.629	0.4279
D. MRI	20	11	0.000	1.000
Surgery done	21	12		

#### Isotope Renogram

		+ve	-ve	
MRI	+ve	30	1	33
	-ve	0	2	

Sensitivity : 100%

Specificity : 66%

Positive predictive value : 96.7%

Negative Predictive value : 100%

Dynamic MRI was able to pick up the functional status of the Renal unit accurately. Dynamic MRI had no false positivity, with 20 patients of 21, deemed for Pyeloplasty and 11 of 12, deemed for Nephrectomy. Correlating with the surgery, the DMRI had a  $\chi^2$  0.000, with p Value 1.000, having no statistical significance for the difference compared with surgery.

Isotope Renogram has a p value of 0.4279 with respect to surgery, again showing no statistical significance for the difference in number.

Comparing DMRI with Isotope Renogram, DMRI has a significant p value of 0.00 with good negative predictive value. Thus it outscores Isotope Renogram in sensitivity.

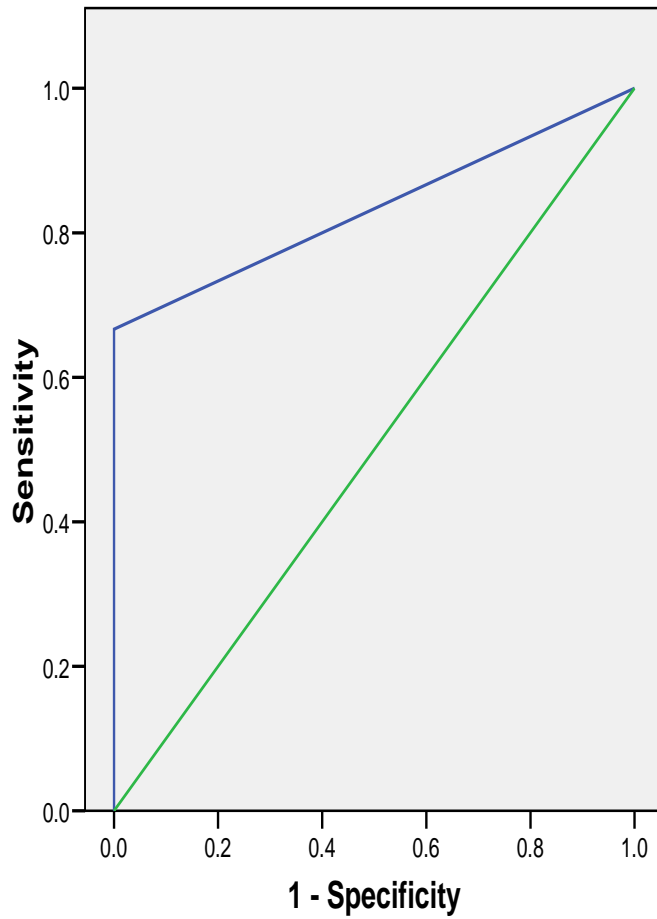
### Chi-Square Tests

	Value	df	Asymp. Sig. (2-sided)	Exact Sig. (2-sided)	Exact Sig. (1-sided)
Pearson Chi-Square	21.290 <sup>b</sup>	1	.000		
Continuity Correction <sup>a</sup>	11.191	1	.001		
Likelihood Ratio	11.271	1	.001		
Fisher's Exact Test				.006	.006
Linear-by-Linear Association	20.645	1	.000		
N of Valid Cases	33				

a. Computed only for a 2x2 table

b. 3 cells (75.0%) have expected count less than 5. The minimum expected count is .18.

## ROC Curve



Diagonal segments are produced by ties.

### Area Under the Curve

Test Result Variable(s): MRI

Area
.833

The test result variable(s): MRI has at least one tie between the positive actual state group and the negative actual state group. Statistics may be biased.

## DISCUSSION

Standardised protocols for obtaining Dynamic Radionuclide studies have been proposed <sup>(4,5)</sup> However, in practice, local protocols are often followed which causes problems in the comparison of results between different centers. Even the details of how these [ DRF,  $t_{1/2}$ , Time to peak activity] parameters are calculated can affect the classification of the drainage pattern (6).

Despite its widespread use, Diuretic Renal scintigraphy is not a Reference standard for the diagnosis of obstruction, since the presence or absence of obstruction cannot be distinguished with this modality in atleast 15% of dilated system <sup>(7,8)</sup>.

Renal Scintigraphy estimate overall and differential renal function. Difficulties in the evaluation of patients with poor Renal function [sr cr >4 mg/dl] and patients with capacious collecting systems are the main limitations of these techniques, along with exposure to Ionizing Radiation.



Additionally, operator variability in the determination of regions of interest can affect the accuracy of the differential Renal function (7,25)

In this study, we calculated the volume of enhancing renal parenchyma and used this value to estimate split Renal function. The calculation of relative renal function by MR urography revealed excellent correlation with Renal scintigraphy ( $r^2=0.93$ ).

The vivid contrast enhancement of the renal parenchyma enabled us to separate kidney from background even in cases of relatively poor renal function and to differentiate renal parenchyma from a dilated collecting system. Differences between the MR urography and nuclear estimation of split renal function occurred in cases with significant parenchyma loss or massive dilatation of collecting system.

In these instances, MR urography was thought to be more accurate because, its greater contrast and spatial resolution allowed

us to separate the kidney from back ground and dilated collecting systems. MR Urography was able to detect Focal cortical scarring in addition to diffuse parenchyma loss.

Pressure flow studies are reserved for patients with equivocal evidence of obstruction or when the aforementioned studies fail to show obstruction convincingly. It is an invasive procedure that requires a renal puncture, general anesthesia, and adapted urodynamic equipment. This makes the test difficult to use in patients who would need serial studies <sup>(7)</sup>.

**The advantages of MRI are :**

- (1) High soft tissue characterisation
- (2) Capability of direct multiplanar and three dimensional reformatting.
- (3) Use of Non Ionizing Radiation
- (4) Non Nephrotoxic contrast medium.

**The Disadvantages are :**

- (i) Motion artifact.
- (ii) Cost.
- (iii) Long post image processing time.

Similar to the report by Rodriguez <sup>(11)</sup> et al, the cost of MRI in our institution is equivalent to the combined cost of Renal USG & Nuclear scan.

**Indications for MRI :**

- (i) Pregnant conditions.
- (ii) Pediatric patients.
- (iii) Raised Renal function.
- (iv) Follow up imaging.

## CONCLUSION

Using Dynamic MRI, analysis of Renal function is similar to Renal Scintigraphy, because of superior spatial and contrast resolution. MR Urography may be more sensitive than Renal Scintigraphy in analyzing poorly functioning system. While MR Urography, costs more than renal Scintigraphy, the information obtained is superior to currently used methods. As with other medical technologies, the cost will decrease as its use becomes more widespread.

Different MRI techniques can be combined to establish a “one stop imaging examination” that can replace different imaging methods used for morphological, etiological and functional evaluation of Pelvi -Ureteric Junction Obstruction.

## BIBLIOGRAPHY

1. Neste MG, DU Cret RP et al Post operative Diuresis Renography and ultrasound in patients undergoing pyeloplasty : Predictors of surgical outcome. Clin Nucl Med 1993;18:872 – 876
2. MacNeily AE, Maizels M, conway JJ. Does early Pyeloplasty really avert loss of Renal function ? A Retrospective view. J. urol 1993; 150 : 769 – 773
3. Gonzales R, schimke CM, Pelvic-Ureteric Junction Obstruction in Infants and children. Paediat. Clin. North AM. 2001 ; 48 : 1505 – 1517.
4. Conway JJ, Maizels M. The ‘ well tempered’ Diuretic renogram : a standard method to examine the asymptomatic neonate with Hydronephrosis.J. Nucl. Med 1992 ; 33 : 2047 – 2051.
5. O’ Reilly P, Aurell M, Britton K, et al. Consensus on Diuresis Renography for investigating the dilated upper urinary tract. J. Nucl Med 1996 ; 37 : 1872 – 1876.

6. Connolly LP, Zurakowski D, Peters CA et al, Variability of Diuresis Renography interpretation due to method of post Diuretic Renal Pelvic clearance half time determination J. urol 2000; 164 : 476 - 471.
7. Dacher J, Pfeister C, Thoumas D, et al short comings of diuresis scinigraphy in evaluating urinary obstruction : comparison with pressure flow studies. Paediatr Radiol 1999 ; 29 742 - 747.
8. Peters c. urinary tract obstruction in children. J urol, 1995 ; 154 : 1874 - 1883.
9. Ryan Pc Maher K, Hurley GD, et al. The whitaker test : Experimental analysis in a canine model of partial ureteric obstruction J. urol 1989 ; 141 : 387 - 394.
10. Wen, J.G, Chen, y; Ringgard S etal Evaluation of Renal function in normal and Hydroneprotic kidneys in rats using Gd- DTPA enhanced dynamic magnetic Resonance Imaging. J urol 2000 ; 163 : 1264.
11. Rodriguez, L.V., spielman, D. etal. Magnetic Resonance imaging for the evaluation of Hydronephrosis. J. urol 2001; 160 : 1023.
12. Marcos R. Perez - Bray field, Andrew J. Kirsch, J. Damien Grattian smith. A prospective study comparing USG, nuclear

- scintigraphy and Dynamic contrast enhanced MRI in the evaluation of hydronephrosis. *J. urol* 2003 ; 170 : 1330 - 1334.
13. Nils Hackstein, Jan Heckrodt, Wigbert S. Rav. *J. Magnet. Reson Imag* 2003 ; 18 : 714 - 725.
14. Ahmed R. El-Nahas, Abou EL - Ghas, Tarek A. EL Diasty et al. MRI in the evaluation of Pelvic -Ureteric Junction Obstruction an all in one approach. *BJUI* 2007 ; 99 : 641 - 645.
15. Wiltrud K. Rohrschneider, Satine Hanfe, Manfred wiesel, Jochen Troger et al. *Radiology* 2002 ; 224 : 683 - 694.
16. Benjamin B. Mc Daniel, Richard A. Jones, J. Damien Grattan simth et al Dynamic Contract entranced MR urography in the evaluation of Pediatric Pelvi -Ureteric Junction Obstruction *AJR* 2005 ; 185 : 1608 - 1614.
17. Wolf JS Jr. Siegel CL, Clayman RV Imaging for Pelvic -Ureteric Junction Obstruction. *J. Endourol* 1996 ; 10 : 93 - 104.
18. Wahlin N, Magnusson A, Person AF, et al. A pressure flow measurement of hydronephrosis in children a new approach to definition and quantification of obstruction. *J. urol* 2001, 166 - 1842 - 1847.

19. Taylor J, Summers PE, Keevis SF et al, Magnetic Resonance Renography ; optimization of pulse sequence parameters & Gd - DTPA dose. Magn Reson Imaging 1997 ; 15 : 637 - 649.
20. Jones RA, Peres - Brayfield MR, Kirsch AJ, Grattan Smith JD. Renal Transit time with MR urography in children. Radiology 2004 ; 233 ; 41 - 50.
21. EL - Diasty , EL -Ghar ME, Shokeir AA et al. MRI as a sole method for the morphological and functional evaluation of live kidney donors. BJUI 2005 ; 96 : 111 - 116.
22. Rohrschneider WR, Becker K, Hoffend J, et al combined static dynamic MR Urography for the simultaneous evaluation of morphology and function in urinary tract obstruction - II Paediatr Radiol 2000 ; 30 : 523 - 532.
23. Rohrschneider WK, Becker K, Hoffend J, et al combined static-dynamic MR urography for the simultaneous evaluation of morphology and function in urinary tract obstruction - I evaluation of the normal status in an animal model. Pediatr Radiol 2000 ; 30 : 511 - 522.
24. Brown SCW. Nuclear medicine in the clinical diagnosis and treatment of obstructive uropathy Edinburgh, Scotland : Churchill Livingstone, 1998 ; 291 - 313.



25. Rossleigh, MA Renal cortical scintigraphy and diuresis Renography in Infants and children J. Nucl Med 2001 ; 42 : 91.
26. O' Reilly, P.H. Diuresis Renography Recent advances and Recommended protocols BJU 1992 ; 69 : 113.

## Consent Form

### சுய ஒப்புதல் படிவம்

#### ஆய்வு செய்யப்படும் தலைப்பு

காந்த கதிர் வலை கருவியின் மூலம் சிறுநீரக அடைப்பின் செயல்பாட்டின் திறனை அறிதல்.

சிறுநீரக அறுவை சிகிச்சை பகுதி : அரசு பொது மருத்துவமனை, சென்னை  
பங்கு பெறுபவரின் பெயர் :  
பங்கு பெறுபவரின் எண் :  
பங்கு பெறுவர் இதனை (✓) குறிக்கவும் :

மேலே குறிப்பிட்டுள்ள மருத்துவ ஆய்வின் விவரங்கள் எனக்கு விளக்கப்பட்டது. என்னுடைய சந்தேகங்களை கேட்கவும், அதற்கான தகுந்த விளக்கங்களை பெறவும் வாய்ப்பளிக்கப்பட்டுள்ளது என அறிந்து கொண்டேன். ( )

நான் இவ்வாய்வில் தன்னிச்சையாக தான் பங்கேற்கிறேன். எந்த காரணத்தினாலோ எந்த சட்ட சிக்கலுக்கும் உட்படாமல் நான் இவ்வாய்வில் இருந்து விலகி கொள்ளலாம் என்றும் அறிந்தும் கொண்டேன். ( )

இந்த ஆய்வு சம்பந்தமாகவோ, இதை சார்ந்த மேலும் ஆய்வு மேற்கொள்ளும் போதும் இந்த ஆய்வில் பங்குபெறும் மருத்துவர் என்னுடைய மருத்துவ அறிக்கைகளை பார்பதற்கு என் அனுமதி தேவையில்லை என அறிந்து கொள்கிறேன். ( )

இந்த ஆய்வின் மூலம் கிடைக்கும் தகவலையோ, முடிவையோ பயன்படுத்திக் கொள்ள மறுக்கமாட்டேன். ( )

இந்த ஆய்வில் பங்குகொள்ள ஒப்புக்கொள்கிறேன். எனக்கு கொடுக்கப்பட்ட அறிவுரைகளின்படி நடந்து கொள்வதுடன் இந்த ஆய்வை மேற்கொள்ளும் மருத்துவ அணிக்கு உண்மையுடன் இருப்பேன் என்றும் உறுதியளிக்கிறேன். என் உடல் நலம் பாதிக்கப்பட்டாலோ அல்லது எதிர்பாராத வழக்கத்திற்கு மாறான நோய்குறி தென்பட்டாரோ உடனே இதை மருத்துவ அணியிடம் தெரிவிப்பேன் என உறுதி அளிக்கிறேன். ( )

பங்கேற்பவரின் கையொப்பம் ..... இடம் ..... தேதி  
கட்டைவிரல் ரேகை

பங்கேற்பவரின் பெயர் மற்றும் விலாசம் .....

ஆய்வாளரின் கையொப்பம் ..... இடம் ..... தேதி  
ஆய்வாளரின் பெயர் .....

# ROLE OF DYNAMIC MRI IN REPLACING ISOTOPE RENOGRAM IN THE FUNCTIONAL EVALUATION OF PUJO

## PROFORMA

Name :

Age/Sex :

Address :

Phone No :

MRD No :

Clinical History :

a :Pain - Site , Character , Duration , Aggravating &  
Relieving Factors

b :LUTS

c :Hematuria

d :Fever / Vomiting

Past History :

Comorbid Illness :

Previous Surgery :

## **General Physical Examination :**

Systemic Examination :

DRE :

## **Blood Investigations :**

- a.Hemoglobin
- b.Packed Cell Volume
- c.Blood Urea
- d.Sr.Creatinine
- e.Sr.Electrolytes

## **Urine Investigations :**

- a.Urine R/E
- b.Urine C/S

X-Ray - KUBU

USG KUB

IVU

CECT KUB

**Isotope Renogram**

Consent

Bowel Preparation

Dynamic MRI

Follow Up

## Master Chart

S.No	Name	Age	Sex	R.T.T.		GFR		Visualisation of Distal ureter.		Surgery
				Isotope Renogram (sec)	DMRI (sec)	Isotope Renogram (ml/mt)	DMRI (ml/mt)	Isotope Renogram	DMRI	
1.	Anand	18	M	1320	1300	11	11	-	No	N
2.	Baby	20	F	720	726	29	34	-	Yes	P
3.	Nagabushnam	30	F	205	205	42	42	-	-	C
4.*	Nivedha	29	F	660	1200	44	13	-	Yes	N
5.	Anandhan	17	M	1200	1200	10	8	-	No	N
6.	Anitha	36	F	350	380	44	45	-	-	C
7.	Raj	17	M	210	210	42	42	-	-	C
8.	Sandhya	40	F	840	840	30	35	-	Yes	P
9.	Soundrapandi	23	M	1080	1080	<5	9	-	No	N

S.No	Name	Age	Sex	R.T.T.		GFR		Visualisation of Distal ureter.		Surgery
				Isotope Renogram (sec)	DMRI (sec)	Isotope Renogram (ml/mt)	DMRI (ml/mt)	Isotope Renogram	DMRI	
10.‡	Mallickarjun	22	M	780	774	33	-	-	Yes	P
11.	Ranjitham	44	F	1140	1140	9	11	-	No	N
12.	Madhavi	42	F	220	220	42	44	-	-	C
13.	Indumathi	20	F	720	780	36	38	-	Yes	P
14.	Desamma	40	F	840	900	28	32	-	Yes	P
15.	Srinivasan	37	M	1260	1200	12	10	-	No	N
16.	Ponnusamy	31	M	900	840	33	37	-	Yes	P
17.	Sarangapani	45	M	206	206	42	41	-	-	C
18.	Bharathkumar	30	M	800	810	26	30	-	Yes	P

S.No	Name	Age	Sex	R.T.T.		GFR		Visualisation of Distal ureter.		Surgery
				Isotope Renogram (sec)	DMRI (sec)	Isotope Renogram (ml/mt)	DMRI (ml/mt)	Isotope Renogram	DMRI	
19.	Dadappan	36	M	960	990	15	11	-	No	N
20.	Balu	37	M	780	720	34	39	-	Yes	P
21.	Ravi	23	M	420	400	44	43	-	-	C
22.	Raja	25	M	780	780	36	38	-	Yes	P
23.	Periyasamy	26	M	840	840	33	35	-	Yes	P
24.	Anbu	45	M	215	215	46	45	-	-	C
25.	Antony	40	M	860	840	31	33	-	Yes	P
26.	Partibhan	32	M	840	840	30	35	-	Yes	P



S.No	Name	Age	Sex	R.T.T.		GFR		Visualisation of Distal ureter.		Surgery
				Isotope Renogram (sec)	DMRI (sec)	Isotope Renogram (ml/mt)	DMRI (ml/mt)	Isotope Renogram	DMRI	
27.‡	Prasad	38	M	1200	1140	10	-	-	No	N
28.	Chitra	36	F	780	774	35	35	-	Yes	P
29.	Shanmugam	37	M	210	210	46	43	-	-	C
30.	Kala	21	F	780	780	36	38	-	Yes	P
31.	Malliga	32	F	550	600	32	35	-	Yes	P
32.	Krishnaveni	30	F	600	620	32	35	-	Yes	P
33.*	Sarangi	40	M	930	950	38	12	-	No	N
34.	Kanniappan	38	M	1080	1080	15	13	-	No	N

S.No	Name	Age	Sex	R.T.T.		GFR		Visualisation of Distal ureter.		Surgery
				Isotope Renogram (sec)	DMRI (sec)	Isotope Renogram (ml/mt)	DMRI (ml/mt)	Isotope Renogram	DMRI	
35.	Manikandan	19	M	780	780	36	35	-	Yes	P
36.	Shalini	28	F	720	720	34	35	-	Yes	P
37.	Suprabha	37	F	230	230	44	43	-	-	C
38.*	Srividhya	20	F	860	890	36	10	-	No	N
39.	Kannan	43	M	760	750	32	35	-	Yes	P
40.	Manimaran	26	M	780	720	34	36	-	Yes	P
41.	Sakthi	40	M	640	620	36	38	-	Yes	P
42.	Sekar	21	M	1140	1140	12	11	-	No	N

# *INTRODUCTION*

*AIM*

*REVIEW OF  
LITERATURE*

*PUJO*

*FUNCTIONAL  
IMAGING OF PELVI-  
URETERIC JUNCTION  
OBSTRUCTION*

*MATERIALS AND  
METHODS*



*OBSERVATION &  
RESULTS*

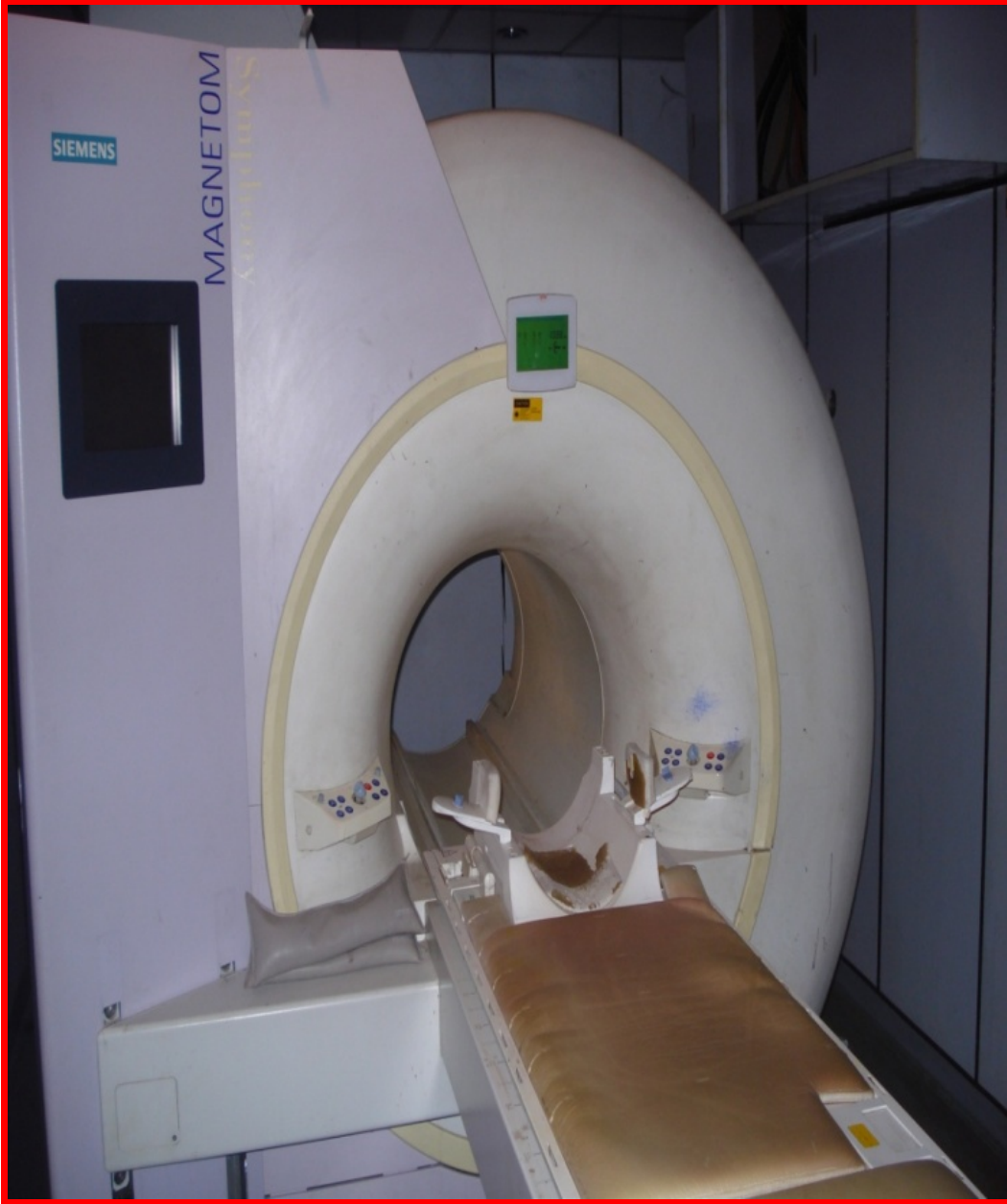# *DISCUSSION*

# *CONCLUSION*

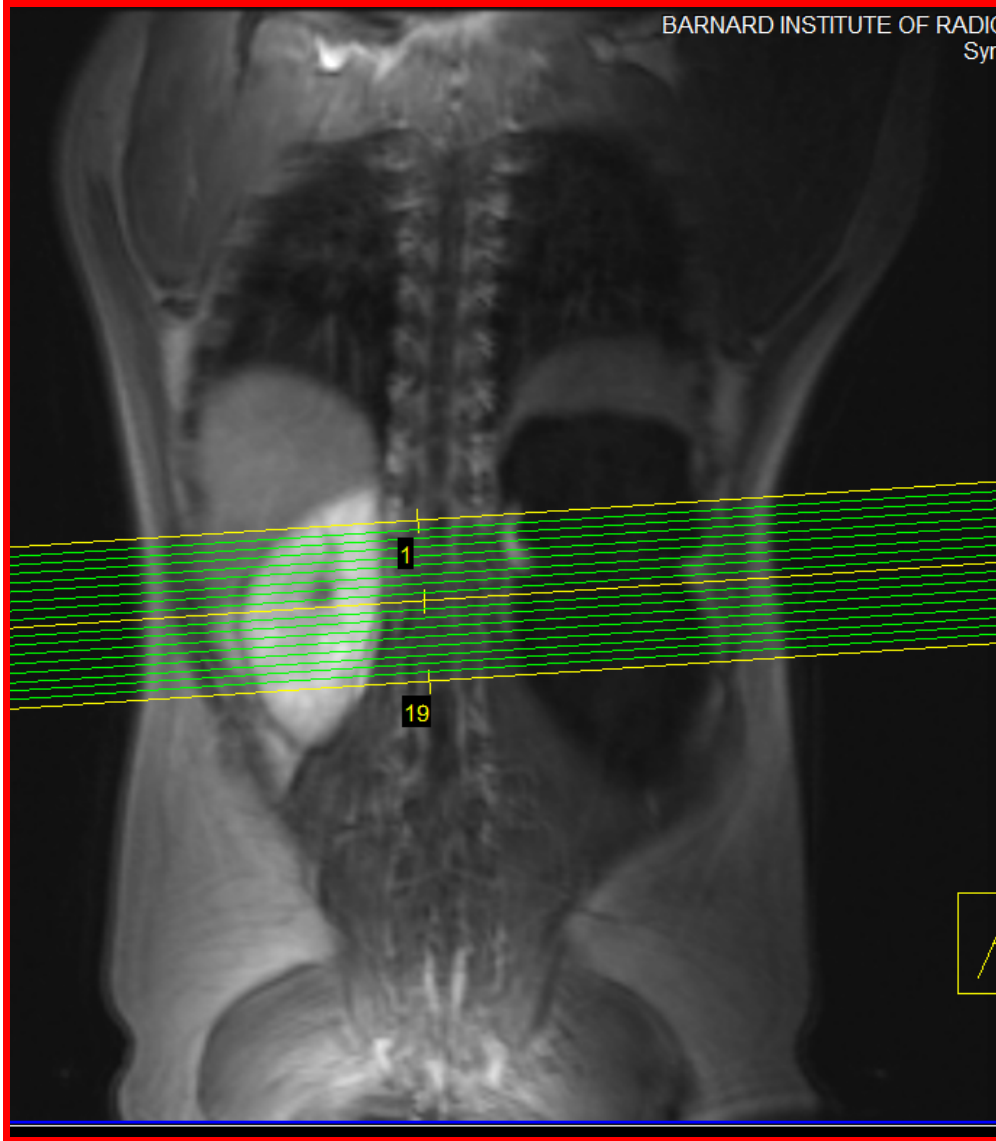
# *BIBLIOGRAPHY*

# *ANNEXURE*



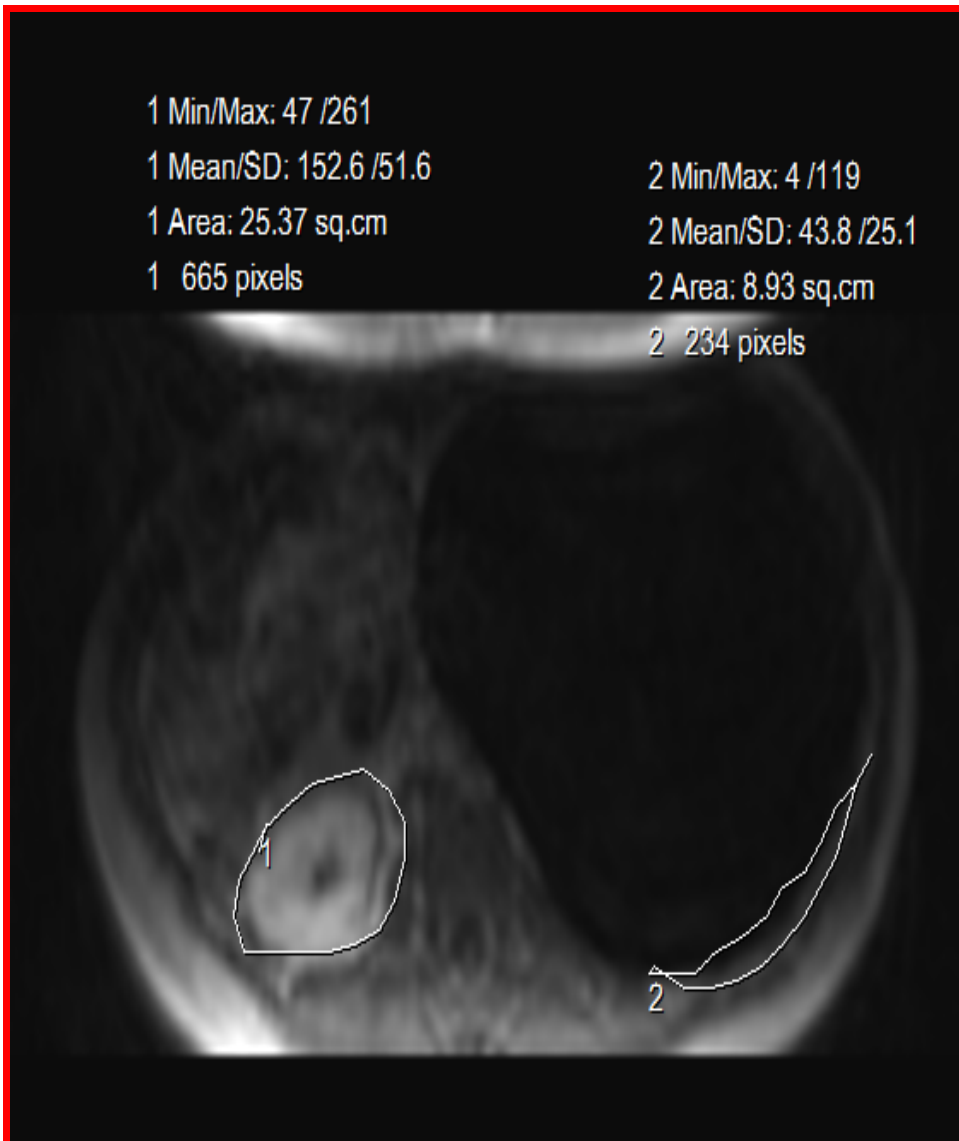


**1.5 t MRI Machine**

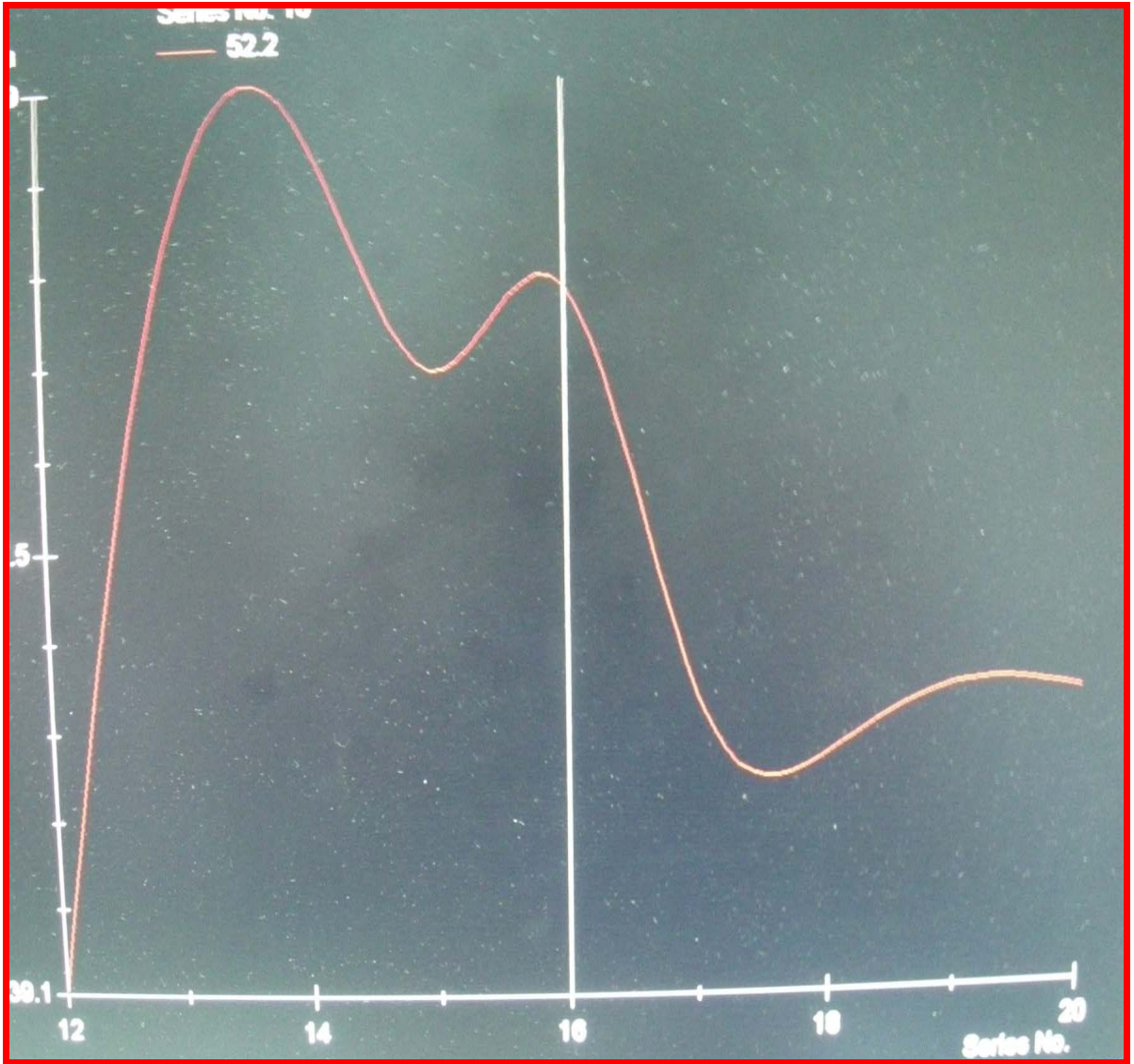


**Post Contrast T1 W Images**

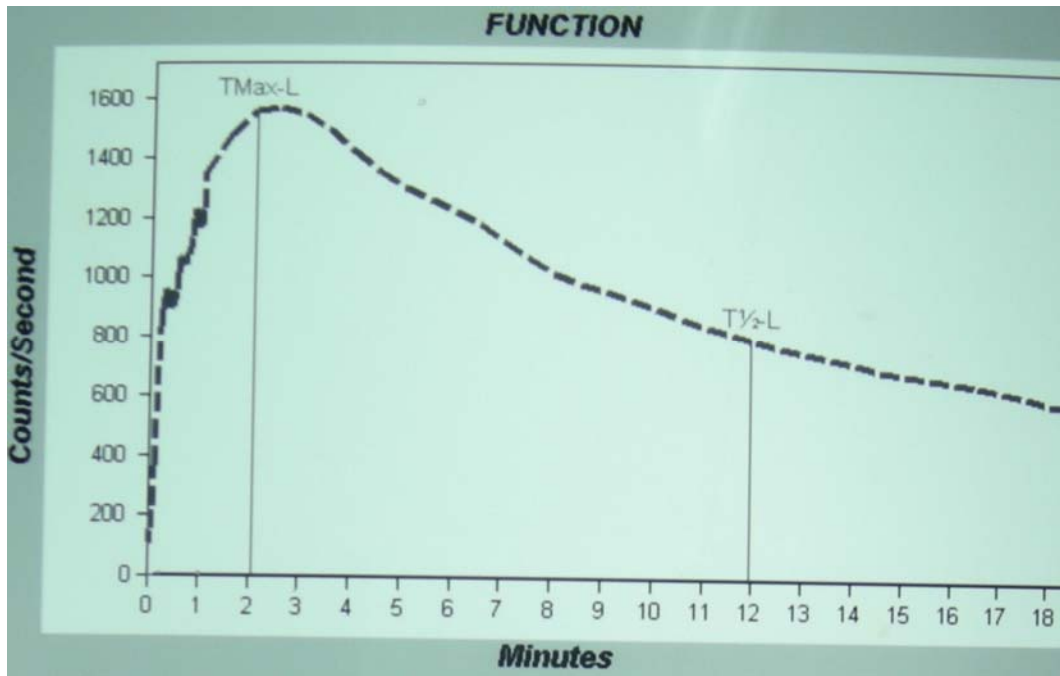




**Functional Tissue being plotted using Reoriented axial images**



**Normal D MRI Curve**



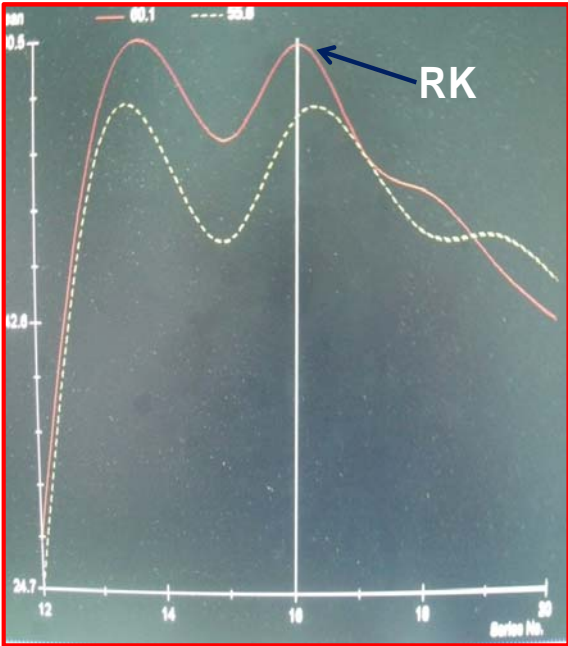
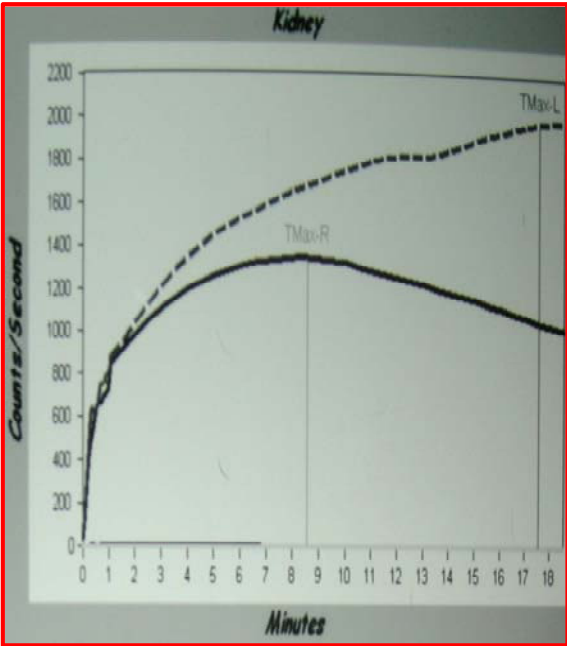
**Normal Isotope Curve**

LK : 48 %    RK : 52 %

RTT : 240 Sec

LK : 45 %    RK : 55 %

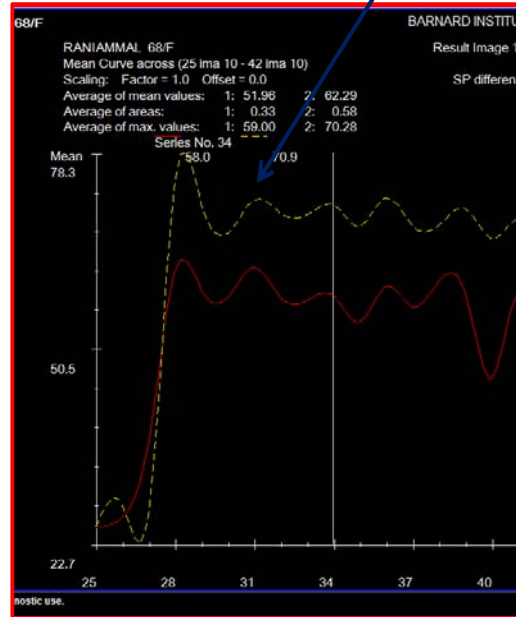
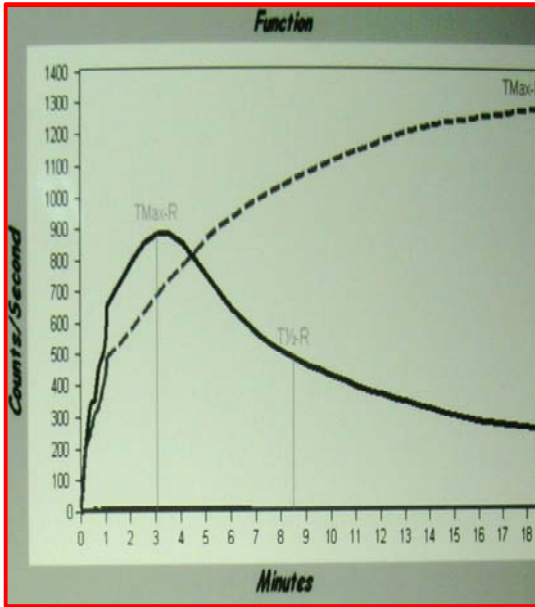
RTT : 260 Sec



**Conservatively Managed**

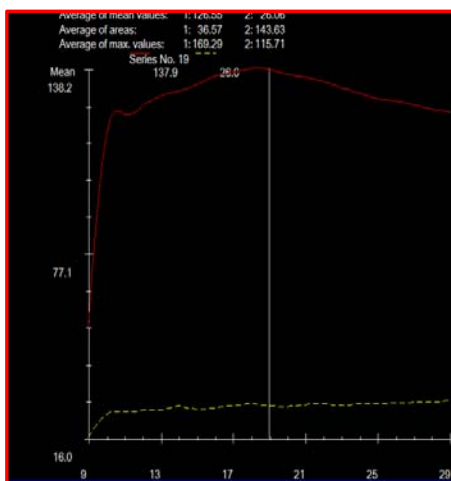
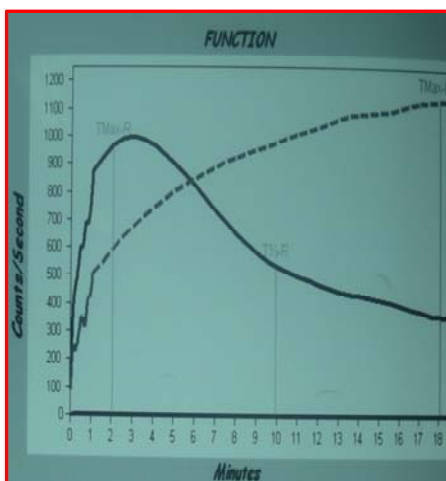
LK : 36 % RK : 64 %

LK : 34.65 % RK : 65.35 %



**Pyeloplasty**

## Discrepancy among Imaging



NIVEDHA 10/F

Result Table 1

Mean Curve across (10 ima 10 - 32 ima 10)

Scaling: Factor = 1.0 Offset = 0.0

Series No.	ROI 1			ROI 2			ROI 3			ROI 4		
	Mean	SDev	Area	Mean	SDev	Area	Mean	SDev	Area	Mean	SDev	Area
10	110.9	31.7	39.1	23.0	16.6	136.2						
11	119.2	26.4	39.1	25.2	18.9	136.2						
12	124.3	23.3	39.1	26.5	20.5	136.2						
13	128.7	22.8	39.1	26.0	19.5	136.2						
14	129.3	23.3	39.1	26.0	19.5	136.2						
15	131.6	23.3	39.1	26.3	19.6	136.2						
16	132.5	24.6	39.1	26.5	19.6	136.2						
17	132.8	27.2	39.1	26.2	19.3	136.2						
18	133.5	27.1	39.1	27.0	20.5	136.2						
19	134.7	26.8	39.1	26.4	19.6	136.2						
20	134.0	25.8	39.1	26.4	19.6	136.2						
21	132.6	24.6	39.1	26.7	19.6	136.2						
22	131.5	23.5	39.1	27.0	19.5	136.2						
23	129.7	24.8	39.1	27.0	19.5	136.2						
24	127.9	25.3	39.1	27.1	19.4	136.2						
25	126.3	25.7	39.1	27.3	19.3	136.2						
26	125.0	26.4	39.1	27.4	19.3	136.2						
27	123.9	26.6	39.1	27.5	19.2	136.2						
28	123.2	26.4	39.1	27.9	19.1	136.2						
29	121.9	26.4	39.1	28.2	18.9	136.2						
30	121.2	27.2	39.1	28.7	18.8	136.2						
31	120.2	28.3	39.1	28.7	18.6	136.2						
32	119.9	27.7	39.1	29.5	18.8	136.2						

## dMRI

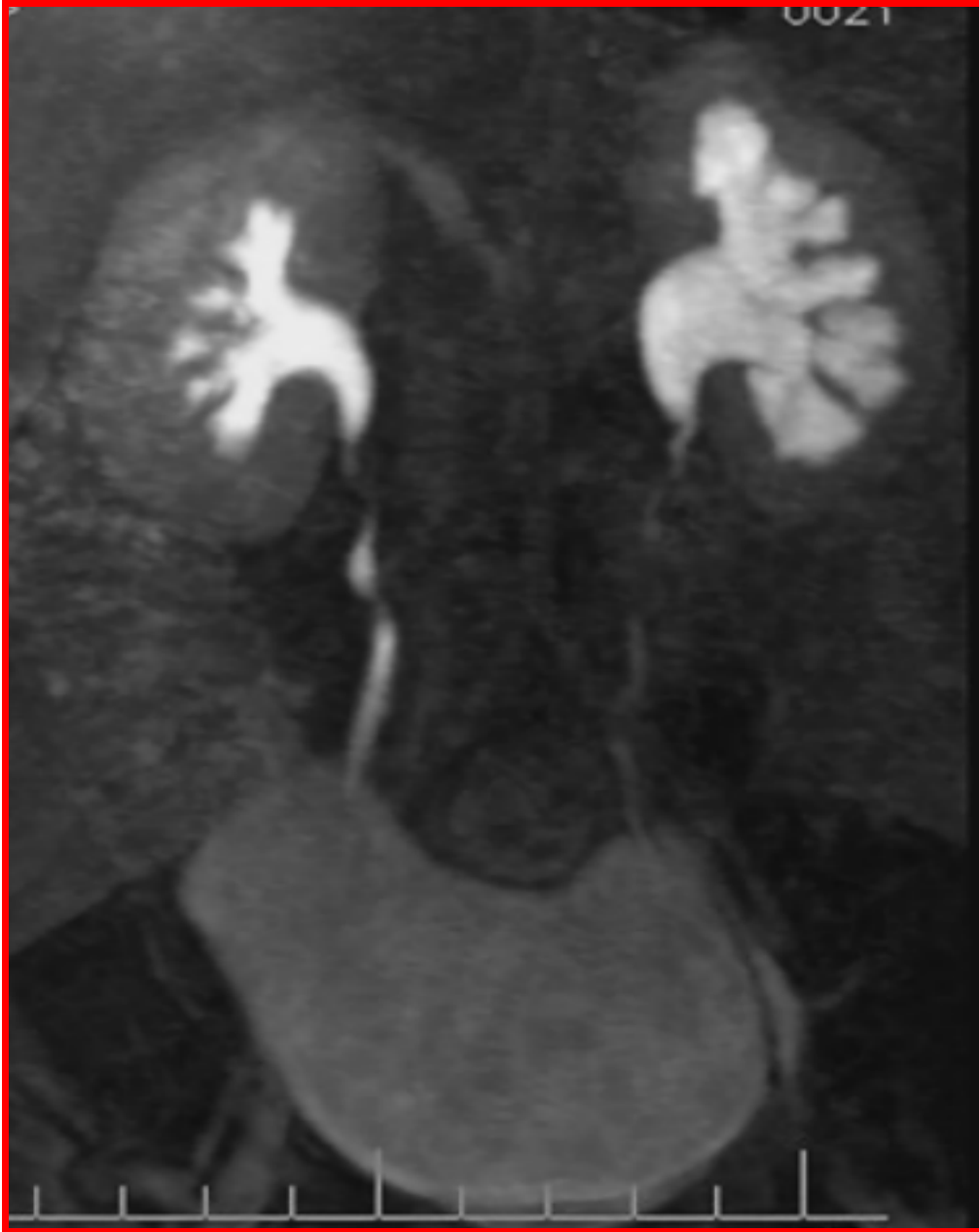4.58	3.92
9.98	4.01
9.00	3.51
9.57	6.36
11.49	6.72
14.15	6.14
14.98	5.51
16.98	5.84
15.80	5.68
19.37	7.27
19.53	5.07
18.79	4.20
25.65	9.79
19.92	7.93
18.98	9.27
20.44	8.73
16.87	6.49
16.37	5.64
10.70	5.78

## Isotope Renogram

RK	LK
62 %	38 %

	RK	LK
Area plotted	437.32	334.52
Area under the Curve	0.7	0.2
	218.66	33.45
GFR	87.53	12.47





**Visualisation of Distal Ureter**

MRA shows a vessel crossing the dilated nonopacified Lt pelvis to the lower pole

