DISSERTATION ON PREDICTORS

OF LOCAL RECURRENCE AFTER RADIOFREQUENCY ABLATION OF LIVER TUMORS

Dissertation

Submitted in partial fulfillment of the Regulation of

M. Ch. DEGREE EXAMINATION
BRANCH VI IN SURGICAL GASTROENTEROLOGY,

INSTITUTE OF SURGICAL GASTROENTEROLOGY
GOVT. STANLEY MEDICAL COLLEGE &HOSPITAL,
Chennai – 600 001

THE TAMILNADU DR.M.G.R. MEDICAL UNIVERSITY

CHENNAI

AUGUST 2008

DECLARATION

I**,** Dr.G.Rajarathinam, solemnly declare that

dissertation titled, "**Predictors of Local Recurrence After Radiofrequency Ablation of Liver Tumors** " is the bonafide work done by me at Govt. Stanley Medical College and Hospital during the period September 2005 to February 2008 under the expert guidance and supervision of **Prof. R. Surendran, M.S., M.N.A.M.S.,M.Ch. Head of the Department,** Institute of Surgical Gastroenterology.

The dissertation is submitted to the **Tamil Nadu Dr. MGR Medical University** towards partial fulfillment of requirement for the award of M.Ch Degree (Branch VI) in Surgical Gastroenterology**.**

Dr. G.Rajarathinam

Place: Chennai

Date : 21.05.08 **.**

CERTIFICATE

This is to certify that this dissertation entitled " **Predictors of Local Recurrence After Radiofrequency Ablation of Liver Tumors** " is a bonafide original work of **Dr.G.Rajarathinam** in partial fulfillment of the requirement for **M.Ch (Branch VI) Surgical Gastroenterology examination** of the Tamil Nadu Dr.MGR Medical University to be held in August 2008

.

Dr.A. Sundaram, MD.,
Dean (I/c)
Govt. Stanley Medical College and Hospital
Chennai - 1.

Prof.R.Surendran, M.S.,MNAMS.,M.Ch.,
Head of the Department
Institute of surgical Gastroenterology
Govt.Stanley Medical college&Hospital
Chennai-1

Place: Chennai

Date : 29.05.08

ACKNOWLEDGMENT

I profusely thank **Dr. Sundaram MD.,** Dean, Govt. Stanley Medical college, Chennai, who permitted to pursue research work and to utilize the case material.

I express my sincere gratitude to my chief, **Prof.R.Surendran, M.S.,M.N.A.M.S.,M.Ch.** Head of the Department, Department of Surgical Gastroenterology**,** Chennai for his keen interest, constant encouragement, guidance and valuable suggestions throughout this study.

I am extremely thankful to my Assistant Professors **Dr.S.Jeswanth, M.S.,M.Ch, Dr.P.Ravichandran,M.S,M.Ch, Dr.V.Vimalraj,M.S,M.Ch, Dr.S.RajendranM.S.,M.Ch, Dr.D.Jothybasu,MS, Dr.Sukumar,M.D, Dr.KannanM.S.,M.Ch, Dr.T.G.BalachandarM.S.,M.Ch,** for their unstinted encouragement, guidance and valuable suggestions throughout the period of study.

I am extremely thankful to **Mr. Venkatesh statistician** for analyzing the results.

I take this opportunity to thank my parents, wife, and my children for their support.

Predictors of Local Recurrence After Radiofrequency Ablation of Liver Tumors

CONTENTS

Introduction

RADIOFREQUENCY (RF) energy has become a popular means of tumor ablation in recent years. Radiofrequency ablation (RFA) has been used to destroy malignant lesions of the lung, kidney, bone, adrenal glands, spleen, breast, lymph nodes, pelvis, prostate, neural tissue, and liver.1-8 The concept of tumor ablation has been used for more than 100 years. Many ablation modalities have been used, including cryoablation, alcohol ablation, laser, and microwave energy.9 Most recently, the use of RF energy for tumor ablation is becoming commonplace, most likely owing to its ease of use and availability, the multiple approaches of probe delivery, the wide range of applications, and the effectiveness of treatment.10

Hepatic resection offers the greatest potential for cure in patients with primary and metastatic liver tumors. Unfortunately, advanced stage, inadequate functional liver reserve, extrahepatic disease, or medical comorbidities render most patients with hepatic malignancy inoperable. Although complete surgical resection of HCC offers the best chance of long-term survival, cirrhosis may limit the amount of parenchymal resection that will be tolerated and increases the risk of postoperative liver failure and death.(11)

In most patients with cirrhosis and HCC confined to the liver, resection is not safe, and local tumor-ablation therapies are considered as alternative treatment options.Liver-directed therapies encompass a broad range of modalities from transarterial chemotherapy to intratumoral chemical injection and thermal destruction.

At present, the most popular and widely practiced local treatment modality is radiofrequency thermal ablation. RFA is a relatively new and minimally invasive therapy for primary and metastatic liver tumors. Early studies have suggested that

this is an effective and safe technique for treating liver tumors (12–17). As a result, RFA is gaining popularity as the preferred modality of local ablation for unresectable liver tumors in many centers. (18-20) with its technical simplicity and safety, RFA has even been proposed as an alternative to hepatic resection for small liver tumors (15, 17).

Radiofrequency ablation (RFA) is a thermal treatment technique designed to produce localized tumor destruction by heating tumor tissue to temperatures that exceed 50°C. When tumor cells are heated to temperatures above 45° to 50°C for more than 3 minutes, intracellular protein denaturation and melting of lipid bilayers results in direct tumor cell death. (21-24) RFA uses alternating current passed across needle electrode arrays placed directly into the tumor. Ionic stimulation induced by the alternating current in tissue surrounding the electrode array produces gradual frictional heating, and the tissue temperature rise to 80° to 110°C, which results in coagulative necrosis of the of the tumor tissue in proximity to the electrode.

The great majority of patients with colorectal liver metastases present with unresectable disease, The primary obstacles to complete resection in the majority of patients that present with colorectal liver metastases are the need to treat bilobar or bulky disease and the need to leave sufficient residual functional hepatic parenchyma after resection to support posthepatectomy hepatic function. Neoadjuvant chemotherapy, preoperative portal vein embolization, and 2-stage resection approaches contribute to an increase in the number of patients who can undergo potentially curative treatment (25-29).

Despite these innovative strategies, the great majority of patients with liver-only metastases from colorectal carcinoma are not candidates for complete surgical resection. To compliment resectional strategies when complete resection of all metastases is not possible, a number of tumor ablative techniques have been explored. Currently, the most widely used tumor ablative technique for treatment of colorectal

liver metastasis is radiofrequency ablation (RFA), RFA combined with resection has recently been proposed as an option for unresectable patients. Thus, RFA has been reserved as an adjunctive tool to resection, when complete resection is not possible, either alone or in combination with resection (30).

Adequate ablation of hepatic tumors is feasible using RF energy. Percutaneous, laparoscopic, and open surgical approaches can be used to deliver RF probes to hepatic tumors. Multiple factors will affect patient survival, such as histological findings of the tumor, the use of adjuvant chemotherapy, and proper tumor staging. High-resolution CT and magnetic resonance imaging have clearly improved, increasing the sensitivity of these examinations

Local recurrence rate after radiofrequency coagulation (RFC) of liver tumors varies widely between 2% and 68%. While nearly all authors agree that tumor size is an important risk factor for local recurrence, little is known about the impact of other factors, such as tumor pathology, tumor location, or approach (31).

A meta-analysis of the published reports demonstrates that the size of the tumor to be treated is the most important factor in determining whether complete local ablation can be achieved. This largely stems from our current limitations of the extent of achievable coagulation from a given RF application, coupled with the need for treating a 0.5- to 1.0-cm surgical margin surrounding the target lesion. For lesions measuring 3.5 to 5.0 cm, 50% to 70% have been completely treated.33.Location also influences the possibility of achieving complete ablation of a tumor. If a tumor is near large vessels (ie, 5-10 mm, or those visible by means of CT), all of the malignant cells adjacent to the vessel are unlikely to be completely eradicated because of the previously described perfusion-mediated tissue cooling.36, 37

Other factors include the type of tumor, with greater clinical success reported in treating HCC33, 34, and breastmetastases38 compared with colorectal metastases. The tumor subtype can be equally important in determining outcome. The underlying parenchyma is also important, as previously described, with cirrhotic tissue serving to insulate the hepatomas, thereby promoting better thermal coagulation.33 Initial reported success with RFA in liver tumors is coupled with its low morbidity rate of 7.1% for significant omplications.32, 34,35

Aim of the Study

The aim of this study was to identify and analyze the factors that may influence local recurrence to determine treatment efficacy, safety, local tumor control, and patterns of failure, treatment-related complications and outcome and overall survival in patients treated with Radiofrequency ablation for primary and metastatic liver tumors.

Review Of Literature

Hepatic resection offers the greatest potential for cure in patients with primary and metastatic liver tumors. Unfortunately, advanced tage, inadequate functional liver reserve, extrahepatic disease, or medical comorbidities render most patients with hepatic malignancy inoperable. Clearly, other treatment strategies are necessary for those patients with

unresectable tumors.Liver-directed therapies encompass a broad range of modalities from transarterial chemotherapy to intratumoral chemical injection and thermal destruction.

At present, the most popular and widely practiced local treatment modality is radiofrequency thermal ablation. Radiofrequency ablation (RFA) involves the insertion of a needle-type electrode into tumor tissue. An alternating current is then generated between the implanted electrode and a dispersive skin electrode, resulting in ionic agitation, frictional heating, and ultimately coagulation necrosis of the tumor tissue [1].

With increasing use of RFA, a large body of data has accumulated on the safety and efficacy of this modality. However, most of the available studies consist of small nonrandomized trials or patient series (level 2 evidence). Few randomized, well-controlled studies (level 1 evidence) have been published. Thus, it is difficult to compare RFA with other ablative modalities or the gold standard of surgery. The purpose of this review is summarize the available literature on RFA for hepatic malignancy.

Radiofrequency Ablation

Studies evaluating RFA in hepatocellular carcinoma

For patients with advanced cirrhosis who may not be able to tolerate resection, hepatic transplantation has emerged as the preferred treatment option. However, transplantation is largely reserved for hepatocellular carcinoma (HCC) and has several limitations, including strict selection criteria, limited availability of donor organs, and the need for lifelong immunosuppression. Thus, the majority of patients with unresectable hepatic tumors receive nonsurgical liver-directed therapies. A plethora of studies exist on the use of RFA in HCC.

Studies of RFA alone:

Early RFA studies focused on its use as a stand-alone therapy for patients with unresectable HCC. While these trials contained valuable information regarding treatment safety and response, they lacked sufficient follow- up to define important long-term outcomes such as

survival. Only recently have survival data become available on RFA-treated HCC patients. Large clinical series from Europe, the United States, and Asia have demonstrated 5-year post-RFA survival rates between 33% and 55%, comparable to those seen in series of hepatic resection [2–5].Several studies have evaluated long-term outcome and prognostic factors for patients with unresectable HCC treated by conventional RFA.

In Italy, Lencioni et al performed a prospective, intention-to-treat analysis on 206 patients with unresectable HCC. These patients had Childs-Pugh A or B cirrhosis of

predominantly hepatitis C origin; 187 patients were considered for RFA and 19 patients were excluded from RFA

treatment on the basis of unfavorable tumor location. The authors observed favorable overall 5-year survival rates in both the intention-to-treat (41%) and actual treatment group (48%). Through multivariate analysis,they identified Childs-Pugh class and tumor multiplicity as the significant predictive variables for survival [3].

Similarly, Guglielmi et al found Childs-Pugh class to be a significant predictor of survival in RFA-treated patients. These authors performed percutaneous RFA on 53 patients with HCC from primarily hepatitis C virus (HCV)-induced cirrhosis. While overall 3-year survival in all patients was 45%, the 3-year survival rate of Childs-Pugh A cirrhotics was significantly better than that of Childs-Pugh B cirrhotics (83% vs 31%) [6].

In addition to conventional RFA, the Italian literature has also addressed the role of novel radiofrequency technologies in the management of HCC. Two clinical series evaluated the use of expandable and internally cooled electrode designs in RFA of primary hepatic tumors. Buscarini et al compared conventional RFA electrodes with expandable electrodes for the ablation of unresectable HCC.

In this series, 88 patients were treated via percutaneous RFA, using either conventional or expandable electrodes. The majority of patients had Childs-Pugh A or B cirrhosis due to hepatitis C infection. Five-year overall and disease-free survival rates were 33% and 3%, respectively. While mean number of treatment sessions and local recurrence rates were lower in the expandable electrode group, no significant differences in overall or disease-free survival were appreciated between the 2 electrode designs [2].

In another study, Giovannini et al evaluated the efficacy of internally cooled electrodes in 56 patients with HCC. The majority of patients had Childs-Pugh A or B cirrhosis; alcohol was the most common etiology of cirrhosis, followed by HCV and

hepatitis B virus (HBV) infection. Overall and disease-free 3-year survival rates of 94.2% and 70.3%, respectively, were observed. Interestingly, patients with alcoholic cirrhosis fared better than those with a viral etiology: 2-year survival rates were 77.7% in the alcoholic cirrhosis group versus 57.7% in the viral-induced cirrhotic group [7]. While the aforementioned study shows that internally cooled electrodes prolong survival relative to historical untreated controls, more mature data are necessary to assess the efficacy of internally cooled electrodes versus other electrode designs.

In Japan, Shibata et al performed a randomized trial comparing internally cooled electrodes and expandable electrodes. A total of 74 patients with unresectable HCC underwent RFA: 38 with internally cooled electrodes and 36 with expandable electrodes. The authors found no difference between the 2 treatment groups in terms of overall and disease-free survival [8]. Thus, the aggregate data from Japan and Italy suggest that with respect to long-term and disease-free survival, all currently available electrode designs are equivalent.

In the United States, the role of open and laparoscopic RFA approaches as well as combination resection–RFA therapy has also been explored. Raut et al reported a large series of 194 HCC patients who were treated by percutaneous or open RFA at the M.D. Anderson Cancer Center in Texas. Patients included those with unresectable HCC (median tumor diameter 3.3 cm) and Childs-Pugh A, B, or C cirrhosis due primarily to HCV. Of the 194 HCC patients, 140 received percutaneous RFA, while 54 underwent anopen, intraoperative approach. Of the 54 patients treated with open RFA, 22 underwent concurrent resection of additional hepatic lesions. Local recurrence developed in 53% of the 194 patients, the majority of which was intrahepatic. The overall complication rate was 12%, while overall 5-year survival was 55.4% [4]. Interestingly, a subset analysis of the percutaneous RFA, open RFA, and combined RFA and hepatic resection group showed no significant difference in 5-year survival among the groups. However, early survival in the combined RFA/surgery group was

significantly lower, likely corresponding to the increased morbidity and mortality associated with resection in cirrhotic patients.

Unlike the experience with the open approach, laparoscopic RFA has produced less promising results. Berber et al observed an overall 3-year survival of only 38% in patients with unresectable HCC treated by laparoscopic RFA [9].In addition to the Western experience, a large volume of data has accumulated from East Asia on the use of RFA in HCC.

In Japan, Tateishi et al published an extensive series on RFA for HCC; 664 HCC patients from all Childs-Pugh classes were treated by RFA. The primary cause of cirrhosis in most patients was HCV infection. Patients with tumors larger than 2 cm underwent pretherapy transarterial embolization.Of note, the study divided the patients into two groups, based on previous therapy. Those patients who received no prior treatments for their tumor were deemed naive (319 patients), while those who underwent previous interventions were classified as non-naive (345 patients). Five-year overall survival rates in the naive and non-naive groups were 54.3% and 38.2%, respectively [5]. Importantly, the study observed a higher incidence of needle track tumor seeding, likely reflective of the failure to perform tract cauterization.

Another study in Hong Kong evaluated the use of RFA in patients with subcapsular, surface tumors. Poon et al conducted a prospective, nonrandomized trial of 80 patients with unresectable HCC. The majority of patients had Childs-Pugh A or B cirrhosis from HBV infection. In that series, 48 patients had subcapsular tumors, and 32 had nonsubcapsular lesions. While patients with subcapsular tumors tended to have larger tumors, higher alpha-fetoprotein (AFP) levels, and lower platelet counts, they still had equivalent outcomes after RFA. One-year overall survival rates of 88.3% and 79.4% were observed in the nonsubcapsular and subcapsular patient groups, respectively. Equivalent morbidity, mortality, and recurrence rates were also noted.

Unlike other series, this study reported no incidences of needle track seeding or intraperitoneal metastasis associated with RFA of subcapsular tumors; the authors attributed their favorable results to their technique. Specifically, rather than puncture the tumor perpendicularly, the authors inserted the radiofrequency needle obliquely through a layer of nontumorous hepatic tissue; they also meticulously thermocoagulated the needle tract. Thus, procedural differences appeared to account for the lower recurrence rate observed in this study [10] (Table 1).

Studies comparing RFA with other ablative modalities:

Several comparative trials also have been conducted evaluating RFA against other conventional ablative modalities. The majority of these studies originated in East Asia and compare RFA to the standard chemical ablation techniques— ethanol and acetic acid injection.

In Taiwan, Lin et al performed a randomized controlled trial comparing RFA with percutaneous ethanol injection (PEI) and percutaneous acetic acid injection (PAI). A total of 187 patients with HCC less than 3 cm in size were randomized to receive RFA (62 patients), PEI (62 patients), or PAI (63 patients). Patients had primarily HBV induced Childs-Pugh A or B cirrhosis. End points of the study included tumor response, recurrence, survival, and complication rate. RFA-treated

patients demonstrated significantly better recurrence and survival rates than their chemically ablated counterparts.

Further, the number of treatment sessions required to induce complete response was significantly less in the RFA treatment group. While RFA was superior to chemical ablation in terms of inducing responses, limiting recurrence, and prolonging survival, it was associated with a higher complication rate. In this series, 3 major complications, including 2 hemothoraces requiring thoracostomy drainage and 1 gastric bleed/perforation, were observed in the RFA treatment group; in contrast, no complications were noted in the chemical ablation groups.Of note, the authors also conducted multivariate analysis to identify predictive variables for long-term outcome. Tumor size (≥2 cm), Edmondson grade (I and II), and treatment method all correlated significantly with longterm survival and local recurrence [11].

In another large randomized trial, Lin et al compared RFA with both conventional and high-dose PEI regimens.Single-session PEI has been advocated as a viable therapeutic option for large HCCs not amenable to small-volume conventional ethanol treatment. In this study, the authors randomized 157 patients with HCC less than 4 cm in diameter into 3 treatment groups: conventional PEI (52 patients), high-dose PEI (53 patients), and RFA (52 patients). All patients had Childs-Pugh A or B cirrhosis predominantly from HBV infection. As with their other study, the authors demonstrated significantly better long-term outcomes in the RFA-treated group. Compared to conventional and high-dose PEI, RFA required fewer treatment sessions to ablate tumors completely. It also was associated with lower local tumor progression rates and higher long-term survival rates [12].

The superiority of RFA over chemical ablation was confirmed in a Japanese study by Shiina et al. In this series, 232 patients with HCC (_3 cm in diameter and fewer than 3 in number) were randomized to receive either RFA (118 patients) or ethanol injection (114 patients). Of note, the patient population of this study differed

in that the majority of patients had cirrhosis secondary to HCV rather than HBV. No significant difference in complication rates was reported between the RFA and PEI groups.

However, as with the Taiwanese studies, the authors did observe decreased number of treatment sessions and increased long-term survival in the RFA cohort [13]. In another Japanese study, Omata et al retrospectively analyzed 1,238 patients treated with percutaneous ablation via ethanol injection, microwave coagulation therapy (MCT), or RFA. They noted superior 5-year survival rates in treatment-naive patients who underwent RFA as opposed to other percutaneous ablative therapies [14].

To assess the efficacy of combined ablative modalities in the management of HCC, a Chinese study compared the use of RFA and PEI versus RFA alone. A total of 86 patients with single HCC less than 5.0 cm in diameter were randomized to receive either combination RFA-PEI (45 patients) or RFA alone (41 patients). No significant difference in survival was noted between the 2 treatment groups. Interestingly, a subset analysis of tumors greater than 3 cm in diameter revealed that the combination therapy group had higher local recurrence-free survival when compared to RFA-only treated patients [15].

While the majority of comparative trials have analyzed RFA against chemical ablation, one study by Lu et al compared percutaneous RFA with microwave coagulation therapy (MCT). In this series, 102 patients with HCC and Childs-Pugh A or B cirrhosis of predominantly HBV origin underwent either RFA (n _ 53) or MCT (n _ 49) [16]. Analysis of outcomes in the 2 groups revealed equivalent complete ablation rates, local recurrence rates, major complication rates, and long-term survival rates. However, this study was limited by several methodological flaws, including inhomogenous patient distribution and selection bias. Further study is needed to

assess the relative efficacy of RFA and MCT to establish the role of each of these modalities in the algorithm of hepatic tumor management (Table 2).

Studies comparing RFA with surgical resection*:*

Most studies evaluating RFA versus surgical resection show equivalent long-term outcomes with either treatment. Chen et al published a randomized controlled trial in which 112 patients with single HCC less than 5 cm in diameter received either resection (65 patients) or percutaneous RFA (47 patients). No significant differences in local recurrence, overall survival, or disease-free survival were detected between the 2 treatment groups [17].Several nonrandomized studies also demonstrated equivalent outcome with RFA and surgery [18,19].

In Italy, Montorsi et al conducted a prospective, nonrandomized trial comparing laparoscopic RFA with surgery. The study population consisted of 98 patients with single HCC less than 5 cm in diameter and Childs-Pugh A or B cirrhosis of predominantly HCV etiology. Fifty-eight patients received RFA; 40 underwent resection. While long-term (4-year) survival was equivalent in both treatment groups, RFA resulted in significantly higher intrahepatic recurrence rates than resection. Multivariate analysis identified AFP level, treatment, and etiology of cirrhosis as independent risk factors for intrahepatic recurrence, whereas AFP level alone predicted survival.

Of note, local recurrence rates were significantly lower in RFA-treated patients in this study relative to others. The authors attributed this to improved heat efficiency from inflow occlusion performed during laparoscopy [20]. Another Italian study by Vivarelli et al compared surgical resection with percutaneous RFA. Unlike the majority of comparative trials, this study showed that long-term survival was higher in the surgical resection group, particularly in that subset of patients with tumors greater than 3.0 cm in diameter and early-stage cirrhosis [21]. However, these data are to be interpreted with caution as this study contained significant selection bias; most patients who underwent RFA had more advanced tumors and worse liver function than their resected counterparts (Table 3).

Studies evaluating RFA for colorectal liver metastasis

RFA has been increasingly used for the treatment of colorectal liver metastases (CRLM). Herein, we present the available data on RFA for CRLM. As in our analysis of RFA for HCC, the relevant literature is grouped into 3 categories: (1) studies evaluating RFA alone, (2) studies

evaluating RFA plus surgical resection, and (3) studies evaluating RFA with other modalities.

Studies evaluating RFA alone*:*

One of the earliest studies on RFA for CRLM was a clinical series published by Curley et al at M.D. Anderson Cancer Center. The authors reported 123 patients with unresectable primary and metastatic hepatic tumors who underwent RFA by either a percutaneous or open surgical approach. Sixty-one of the 123 patients had unresectable CRLM. In these patients, local recurrence rate was 1.8%, while new metastatic disease developed in 27.6% of patients. No deaths were reported, and the complication rate was 2.4%. The lack of long-term survival rates is a

significant drawback to this study; nonetheless, the series does demonstrate a favorable safety profile for RFA in unresectable hepatic metastases. Furthermore, the study also shows an impressively low local recurrence rate when compared to similar studies published by other authors. This is likely a factor of patient/tumor selection; the median diameter of treated lesions was only 3.4 cm. Similarly, the rate of new metastatic disease is one of the lowest reported; rates typically range between 40% and 80% [22].

In 2000, De Baere et al presented data on 68 patients treated with RFA, 58 of whom had unresectable CRLM. Rates of local tumor progression and major complication were 16% and 4.4%, respectively. Although both percutaneous and open approaches were used, comparisons could not be made between the 2 approaches due to significant differences in lesion diameter between the 2 groups. Nevertheless, this study provides valuable information regarding the potential etiology of local recurrences after RFA treatment. According to the authors, the use of a single needle instead of a cluster needle for RFA of lesions greater than 2.5 cm could have been related to the number of local recurrences. However, there is no evidence from other clinical series demonstrating that cluster needles produce a more efficient or more complete ablation of lesions greater than 2.5 cm, as compared to conventional single-needle designs [23].

In 2001, Guilliams et al from the United Kingdom analyzed 69 patients with unresectable CRLM treated by percutaneous RFA. Eighteen of the 69 patients (26%) had undergone previous hepatic resection, and 20 (29%) had extrahepatic disease at the time of treatment. Of note, this is one of the first studies to present long-term survival data following RFA; median survival was 27 months, with a 4-year overall survival rate of 22%. The authors reported significantly better median survival in patients with

fewer than 4 lesions, each smaller than 5 cm in diameter, compared to those patients with multiple, larger tumors (33 months vs 15 months) [24].

A second series by Guilliams et al showed similar long-term survival data. In this study, the authors used percutaneous RFA to treat 73 patients with unresectable CRLM. Median survival after RFA was 31 months, and 5-year survival rate, 25% [24,25]. Of note, some patients received other therapies prior to RFA, including systemic chemotherapy (80%), liver resection (19%), and laser interstitial therapy (13%). While it is difficult to assess the effect of RFA alone on survival, this is one of the few studies with RFA that contains any long-term survival data.

Adding to the European experience, an Italian group published a study documenting long-term outcomes after RFA for CRLM. In 2001, Solbiati et al presented data on 117 patients with colorectal hepatic metastases, all treated by RFA through a percutaneous approach. Median survival was 36 months and 3-year survival rate, 46%. No significant correlation was found between the number or size of the lesion and the time until death. Local recurrence rate was 39.1%; new hepatic metastases appeared in 57% of patients.Despite finding a significant association between lesion size and timing and frequency of tumor local recurrence, survival rates remained unaffected by lesion size [26].

An interesting finding mentioned by this study is the effect of repeat treatment on patient survival. In this series no significant relationship was found between survival rates and repeated treatment of lesions; however, a non-significant trend toward longer survival was observed. This raises some interesting questions: Would using a larger sample size enable the detection of a significant survival advantage from re-treatment? If so, should re-treatment of locally recurrent tumors become the new paradigm? Should new hepatic lesions in previously treated patients also

be ablated? Larger, more rigorous clinical trials are needed to answer these questions (Table 4).

Studies evaluating RFA plus resection:

The role of RFA combined with surgical resection has also recently been explored. In 2003, Pawlik et al published a prospective analysis of 124 patients with multifocal CRLM who underwent combination RFA and resection. RFA and resection were performed during a single operation; median number of tumors excised was 2, and median number of tumors

ablated was 1. Patients underwent a wide range of resections depending on location of the lesion. RFA was performed for unresectable lesions. The overall complication rate from RFA plus resection was 19.8%, while overall mortality was 2.3%, falling within the range of mortality (0–3%) reported for hepatic resection alone; 2 of the 4 deaths were related to liver failure [1,27]. The local recurrence rate (8.2%) was comparable to other studies. Multivariate analysis determined that only the number of tumors (_10) was significantly associated with a short time to recurrence; factors such as age, position of metastasis, and size of metastasis were not significant. Median survival was 45.5 months, with lesions greater than 3 cm associated with significantly higher mortality than smaller ones.

In 2004, a second study from M.D. Anderson was published, evaluating the use of RFA plus resection in the treatment of CRLM. Abdalla et al presented 428 patients who underwent treatment for colorectal liver metastases: 348 patients received resection (55%), resection plus RFA (29%), or RFA (16%) alone, whereas 70 patients were

treated with chemotherapy alone. Of note, this study is the first and only published trial comparing resection, RFA, and RFA plus resection with chemotherapy in unresectable CRLM patients.

The overall recurrence rate varied significantly between treatment arms, with the highest rate of recurrence of any kind occurring in the RFA only group (84%), followed by RFA plus resection (63%) and resection only (52%). Similarly, local recurrence was more common after RFA only (9%), compared with RFA plus resection (5%) and resection only (2%). Long-term survival was higher in the resection-only group; however, no significant difference was detected between the RFA plus resection and RFA-only groups [28].Of note, multivariate analysis revealed tumor number to be significantly predictive of survival. Overall survival was best for patients with solitary tumors, intermediate for patients with 2 or 3 tumors, and worst for patients with more than 3 tumors.

In this study, when the survival rate of all patients that had RFA as a component of their therapy was compared to the survival rate of the chemotherapy control group, a significant difference was detected in favor of RFA treatment. To be fair, any conclusions drawn from this study must take into account the significant differences in patient characteristics among the treatment groups. A future randomized study would be helpful to control for differences in patient characteristics.

In addition to the US studies, a French group headed by Elias et al reported their experience with 63 patients with CRLM receiving combination surgical and RFA therapy. Anatomic hepatic resection was used for large or multiple tumor clusters; wedge resection for superficial, small or scattered metastases, and RFA for small, central metastases. The authors observed a median overall survival of 36 months, with a 3-year survival rate of 47%. The local recurrence rate after RFA was 7.1%, similar to the local recurrence rate observed after wedge resection (7.2%) and formal hepatectomy (9%). Poor clearance margins likely contributed to the higher local recurrence rate observed with RFA in this study compared to

others [29]. As expected, the local recurrence after RFA was significantly higher for lesions close to vascular structures and those with diameter greater than 3 cm [30] (Table 5).

Studies evaluating RFA plus other therapies:

The role of RFA with hepatic arterial chemotherapy and systemic chemotherapy also has been the subject of recent investigation. Cheng et al compared patients receiving laparoscopic RFA (LRFA) alone, laparoscopic hepatic arterial infusion pump therapy (LHAIP) alone, and a combination of the 2 therapies. A total of 45 patients were included in the analysis: 20 in LRFA-alone group, 10 in the LHAIP plus LRFA group,

and 15 in the LHAIP group. All patients had unresectable CRLM and no evidence of extrahepatic disease. Of note, patients receiving LHAIP did have more diffuse tumor, increased evidence of vascular invasion, and a higher frequency of multiple segments involved. Otherwise, the treatment

groups did not vary significantly in terms of patient or laboratory characteristics. A Kaplan-Meier estimate of survival for the 3 treatment groups revealed the following: the actuarial survival rates were 70%, 67%, and 50% for the LRFA-alone, LRFA plus LHAIP, and LHAIP-alone groups, respectively. Mean follow-up was 11.5 months only. Estimated mean survival time in the LRFA group was 25.8 months, in the combined group, 15.2 months, and in the LHAIP alone group, 12.6 months [31].

In 2002, Scaife et al at M.D. Anderson, in collaboration with Pascale National Tumor Institute in Italy, conducted a prospective study examining the feasibility of adjuvant HAI after RFA alone or RFA plus resection for CRLM. Included in the analysis were patients with 7 or fewer metastatic lesions not amenable to resection but amenable to RFA or those with smaller tumors amenable to RFA and larger tumors amenable to resection. A total of 51 patients underwent RFA with 31 of those receiving

hepatic resection. Median follow-up was 20 months and only 62% of the patients completed the course of chemotherapy [32]. The authors concluded that RFA with HAI is feasible. The study did not comment on differences in long-term survival between the resection and non-resection group.

In 2006, Machi et al reported their results with combination RFA and systemic chemotherapy. In their study, 100 patients with CRLM were treated by RFA; 55 underwent RFA followed by systemic chemotherapy, while the remainder received systemic chemotherapy first, then RFA. The initial chemotherapeutic regimen consisted of fluorouracil and leucovorin; this was later supplanted by the newer agents oxaliplatin and irinotecan. While local recurrence rate was 6.7%, new intrahepatic and extrahepatic metastasis occurred in 87% of patients.

Univariate and multivariate analysis showed that the following factors correlated significantly with overall survival: age, total tumor size, extrahepatic disease, RFA approach, previous therapeutic chemotherapy, and carcinoembryonic antigen (CEA). Patients treated by RFA via a laparoscopic approach had the longest survival, although significant differences existed in patient and tumor characteristics among the various procedural approach groups. Overall 5-year survival rate for all patients was 30.5%. Of note, a significant difference was observed in the median survival time between the group that received chemotherapy after RFA and the group that received chemotherapy before RFA (48 months vs 22 months, respectively) [33] (Table 6).

The role of RFA in treatment of hepatic malignancy

Radiofrequency ablation and hepatocellular carcinoma

In the management of HCC, RFA is typically used as a stand-alone alternative to resection in unresectable patients or as an adjunct to surgery and/or other ablative modalities in total cancer therapy.

RFA as an alternative to other ablative modalities in unresectable HCC*:*

Chemical ablation by ethanol injection was once touted as the treatment of choice for patients with unresectable HCC. However, with improvements in technology, RFA has now become the preferred ablative modality for unresectable hepatocellular cancer. Long-term survival and recurrence rates are superior with percutaneous RFA compared to conventional chemical ablation (ethanol or acetic acid injection) [5,8,13]. While some studies show a higher complication rate with RFA, this does not translate to an increase in mortality [11,12].

RFA as an alternative to surgical resection:

Both level and 2 evidence show that survival rates after RFA are comparable to those of surgical resection [17–20]. However, the local recurrence rates after RFA treatment appear uniformly higher than that of surgery alone [9,17,18,20]. The significance of these results remains to be determined. First, local recurrence rates after RFA vary significantly

among studies, particularly those of different geographic regions. This is likely reflective of multiple factors including extent and etiology of cirrhosis, which themselves correlate with geographical location. In the West and Japan, HCV is more prevalent, whereas in China HBV is the predominant etiologic agent of cirrhosis. The 2 viral types produce significantly different patterns of local recurrence and disease progression, with HCV tending to produce multifocal cirrhotic nodules. Even more important, the higher local recurrence rate observed with RFA does not negatively impact long-term survival. Thus, the bulk of the literature on RFA and resection show the 2 treatments to be equivalent in terms of meaningful outcomes such as survival.

RFA as an adjunct to surgery or other ablative modalities:

Limited data exist on the use of RFA in conjunction with surgery or other ablative modalities. The only study that compared percutaneous RFA, open RFA, and combination RFA–surgical resection found no difference in long-term survival or local recurrence rate among the treatment groups. Interestingly, this study showed an increase in early mortality in the combination surgery–RFA group, likely reflective of the morbidity and mortality associated with major hepatic resection [4]. Given that the combination of RFA and surgery is usually reserved for select patients with multifocal lesions, it is difficult to compare this use of RFA with other indications, as inherent selection bias already exists. Nevertheless, RFA appears to be a promising adjunct to resection in patients with multifocal lesions who would otherwise not be able to tolerate resection alone.The use of RFA plus other ablative therapies like PEI also has been studied. The combination of RFA with PEI appears to offer no significant survival advantage over RFA alone. However, for larger lesions between 3.1 and 5.0 cm, combination therapy produces better local recurrence-free survival [15]. Thus, while the combination of thermal andchemical ablation does not affect long-term overall survival in HCC patients, it may reduce local recurrence. Further study is needed to confirm this.

The use of RFA as a bridge to transplantation also has been explored in HCC patients. Liver transplantation offers significant advantages over resection and ablation in that it ensures complete removal of all hepatic foci tumor and cures the underlying disease process (cirrhosis). RFA has

been shown to be a safe and effective bridge to hepatic transplantation, inducing responses in the majority of lesions. However, no comparison of transplantation rates and post-transplantation survival rates have been performed between RFA-treated and non–RFA-treated patients; further study is needed.

Summary of evidence-based recommendations for RFA in HCC

The following are acceptable uses for RFA:

1. Primary therapy for unresectable HCC less than 3.0 cm in size:

   level 1 and 2 evidence.

2. A potential alternative to surgery for resectable HCC:

   level 1 and 2 evidence.

3. Combination treatment with surgery for multifocal HCC:

   level 2 evidence.

4. Combination treatment with chemical ablation for large HCC (_3 cm):

   level 2 evidence.

Review of the literature supports the following conclusions:

1. No available electrode design offers significant advantages over another in terms of long-term and disease-free survival. Level 2 evidence.

2. Procedural approach to RFA (percutaneous versus open) does not significantly impact long-term outcome in HCC therapy. Level 2 evidence.

3. For surface lesions, the RF needle should be inserted obliquely through a layer of nontumorous hepatic tissue, and the needle tract should be thermocoagulated to minimize the risk of hemorrhage and needle tract seeding. Level 2 evidence.

4. Childs-Pugh score is the most commonly identified determinant of survival after RFA for HCC. Level 1and 2 evidence.

5. RFA is a safe and promising bridge to transplantation; however, insufficient evidence exists to determine if RFA improves transplantation rates and post-transplantation

RFA and colorectal liver metastases

RFA has emerged as the most widely accepted ablative modality for the treatment of CRLM. However, to date, all of the data on RFA for CRLM consists of level

2 studies. There is currently no level 1 evidence (randomized controlled trials) comparing RFA with surgical resection or

other ablative therapies. In the following discussion, the previously presented data on RFA in CRLM is analyzed for patterns in local recurrence, survival, and complications. Specific recommendations are then provided, based on this analysis.

Local recurrence:

Unlike in HCC, local recurrence and intrahepatic progression are related to survival in patients with unresectable CRLM. Several factors have been identified as determinants of local recurrence and hepatic progression, including tumor size, proximity to large vessels, and radiofrequency probe design. Tumor size is the most commonly reported variable affecting local recurrence [26,34 –36]. The critical cutoff at which recurrence rates appear to dramatically increase is between 2.5 and 3.0 cm; this is likely reflective of the maximum diameter of ablation achievable with current RFA technology.

New probe designs have been developed in an attempt to overcome limitations in ablation size. Ahmad et al compared the local recurrence and survival rates in CRLM patients ablated with a newer probe design versus conventional designs; they observed an improvement in median disease-free survival and margin recurrence rate with the newer probe design [37]. However, significant bias exists in this study as those patients treated by the new RFA probe design also received newer and presumably more effective systemic chemotherapeutic regimens. Thus, lesions larger

than 3 cm, particularly those between 5 and 7 cm, are most susceptible to local recurrence due to limitations in current RFA technology.

Another factor often cited as a crucial determinant of local recurrence after RFA is the proximity of tumor to large blood vessels. The “heat sink” effect of blood flow reduces temperature and prevents complete ablation by RFA. The end result is local recurrence at the margin between tumor and blood vessel. As mentioned previously, local recurrence rates vary markedly between studies. Several reasons account for this including differences in data collection, patient characteristics, and tumor biology. Rates of local recurrence range from 1.8% in 1 study to as high as 44% due to marked differences in data collection time.

Other authors report local recurrence rates between 9 and 21% [23,24]. Though it is difficult to determine, it appears that the use of RFA as part of multimodal cancer therapy (ie, RFA _ HAIP or RFA _ systemic chemotherapy) reduces local recurrence more than RFA alone. Recurrence rates after RFA combined with systemic or hepatic chemotherapy range from 4% to 7.1% [28,33,36] in general, lower than those observed with RFA alone.

Overall survival:

Lack of long-term survival data, coupled with differences in treatment regimens (ie, RFA alone vs RFA plus other therapies), makes overall survival difficult to analyze in patients with unresectable CRLM treated by RFA.The first study containing long-term outcomes data for RFA in CRLM showed 2-, 3-, and 5-year survival rates of 60%, 34%, and 22%, respectively. While lower than the 58% 5-year survival rate reported by Abdalla et al for resection, these rates were clearly higher than systemic chemotherapy alone (22% to 27% at 2 years with traditional 5-fluorouracil– based regimens) [24,28,30,38,39].

Improvements in RFA technology and application as well as patient selection have led to some improvement in survival rates after RFA, with 5-year survival rates in more recent studies ranging from 25% to 30.5% [28,33]. Still, these rates remain lower than those observed with resection alone; thus, the level 2 evidence supports the use of RFA for unresectable liver metastasis, but not as an alternative to resection in appropriate surgical candidates with resectable disease.

Complications:

Overall, RFA is a safe modality for the ablation of unresectable CRLM. Minor and major complication rates from RFA alone range between 2.4%–12% and 0–5.8%, respectively, with only 1 death reported. When RFA is combined with systemic chemotherapy, both minor and major complication rates (12.3% and 4.8%, respectively) do not appear to increase. Similarly, the use of RFA in conjunction with surgery does not appear to increase the rate of major complications (3.5%–4%), although minor complication rates (6%–16%) and risk of death (4 total deaths) may be higher [40]. Most deaths from combined RFA and resection are due to liver failure, indicating that functional hepatic reserve is an important consideration when selecting patients to undergo combined RFA and resection.

Another important consideration with respect to preventing or reducing complications from RFA is procedural approach. Current thought favors the open and laparoscopic approach for several reasons, including improved staging accuracy with intraoperative ultrasound, less risk of injury to adjacent organs, and less potential for fatal complications. However, the use of a percutaneous approach by experienced radiologists has shown minor and major complication rates (4% and 6%–12%, respectively) that are comparable to the complication rates of open approaches [41,42].

Thus, in experienced hands, percutaneous RFA is as safe as open or laparoscopic RFA, and in fact is ideal for select circumstances such as patients who are poor candidates for general anesthesia or tumors located in the periphery of the liver. Based on the aforementioned analysis of RFA in CRLM,the authors provide the following recommendations for the use of RFA in CRLM.

Summary of evidence-based recommendations for RFA in CRLM

The following are acceptable uses for RFA:

1. Primary therapy for unresectable CRLM less than 3.0 cm in size: level 2 evidence.
2. Combination treatment with surgery for unresectable CRLM: level 2 evidence.
3. Combination treatment with HAIP for unresectable CRLM: level 2 evidence.
4. Combination treatment with systemic chemotherapy for unresectable CRLM: level 2 evidence.
5. RFA may be feasible in the treatment of recurrent CRLM; however limited or no data is available to assess outcome benefits.

.

Patients And Methods

Between June 2005 and June 2007, 23 patients with 55 hepatic tumors underwent RFA at the Department of Surgical gastroenterology,Govt Stanley medical college hospital ,Chennai. Among these, 18 were male and 5 were female. Mean age of patients was 67 years (range 36–82). All patients were diagnosed by biopsy at least on one lesion. Twelve were hepatic cellular carcinoma (HCC) patients (25 tumors), with mean diameter of 3.3 cm (range, 2-7 cm). Of these 12 HCC patients, 8 were cirrhotic. Eleven patients (17 tumors) had metastatic liver carcinomas (MLCs) with mean diameter of 2.5 cm (range, 1.5- 4 cm). The primary tumors were from colorectal tract (*n*=6), neuroendocrine

(*n*= 2),gastrointestinal stromal tumors(*n* = 3)respectively(**Table1)**.

Equipment

All RFA treatments were performed under a standard protocol .The RF system used in this study was a 460-kHz impedance-controlled radiofrequency generator Berthold (Tuttlingen,Germany) has a monopolar electrode that contains small holes for saline perfusion. Perfusion reduces tissue impedance and allows larger zone of ablation. That is capable of delivering a maximum power of 150 W through a 14-G electrode. The electrode contained prongs that could be deployed from the cannula, when the cannula was inserted into the surface of the tumor. The high-frequency electric current was passed through the deployed prongs to the tumor tissue, causing the vibration and friction of ions in the tissue, resulting in the temperatures of up to 100, which produced a sphere like coagulation area of 2.0-3.0 cm in diameter. The time to produce a 5-cm ablation sphere was about 20 min. If multiple-overlapping ablations were required to ablate large tumors, much more time was needed.

Team Approach

To concentrate and strengthen expertise of the treatment and to facilitate research on this new treatment modality, a team comprising hepatobiliary surgeons with substantial experience in the management of liver cancers and interventional radiologist with experience in interventional procedures in the liver was responsible for this treatment in our institution.

Size

Patients with≤3 tumors, each ≤ 5 cm in diameter, were considered the favorable candidates for RFA. However, we also offered RFA to selected patients with more than 3 tumor nodules or tumors larger than 5 cm (up to 7 cm) if no other effective treatment options were available and if the liver function was satisfactory. Ablation was performed with a curative intent, aiming to achieve a margin of 1 cm. The ablation area should cover the tumor and at least 0.5-1.0 cm of the surrounding tissue, and the margin should even be more than 1 cm when the tumor border was unclear.

Technique

The treatment protocol was decided according to the ablation range. The hepatic tumor treated was identified by means of Ultrasound .The RF probe was then advanced to the desired margin of the tumor. Baseline tissue impedance was measured. In larger tumors, the RF electrode was then repositioned into a new site of the tumor under image guidance and with continuous temperature monitoring. When the temperature of the new position was near the cytotoxic threshold of 55°C, a second

ablation was performed to create overlapping zones of thermocoagulation. The echogenic response during US guidance was also used as a rough approximation of the size of the ablation sphere when repositioning the electrode into a new region of the untreated tumor. During the ablation process, real-time ultrasound scan was performed to monitor the electrode placement and the ablation, and post-ablation ultrasound was performed to find the potential complications so that the corresponding measures could be carried out in time.

Table 1. Characteristics of Patients who underwent Radiofrequency Ablation

Variable	Number (n)	Percentage (%)
Gender		
Male	18	78
Female	5	22
Age (year)		
<60	17	74
>60	6	26
Pathology		
HCC	12	52
CRLM	6	26
NELM	2	9
GIST	3	13
Cirrhosis		
Yes	8	35
No	15	65

Hepatic resection		
Yes	9	39
No	14	61
PVL		
Yes	6	26
No	17	64

Approach

The decision for the ablation approach used was made between the surgeon and interventionist and was based on the patient's performance status and the size, location, numbers,and histological features of the tumor. Patients with small tumors located in a position amenable to percutaneous RFA were treated with this approach. Open approach was offered in the following situations: (1) large tumors that require multiple ablations even with the clustered probe; (2) tumors located near the dome of the liver, for which percutaneous ablation will cause pneumothorax or damage to the diaphragm; or (3) tumors located near the visceral organs such as the gallbladder, colon, or stomach.

In selected patients without previous upper abdominal operation, laparoscopic approach was used instead of the open approach if the tumor position was favorable. All patients were reviewed by the team before the approach of RFA was decided. Tumor pathology was confirmed by percutaneous fine needle aspiration cytology for patients undergoing percutaneous RFA, and by core-needle biopsy for those undergoing laparoscopic or open RFA. A dose of intravenous antibiotics (Third generatin cephalosphorin) was given just before RFA.

Anesthesia

All patients underwent RFA under general anesthesia or conscious sedation. Percutaneous ablation was performed with ultrasound guidance under local anesthesia. Intravenous sedation was routinely given before insertion of the needle probe in addition to local anesthesia. The abdomen and chest were prepared and draped under sterile conditions. Local anesthetic was injected at the skin puncture sites. The RF probes were passed percutaneously into the hepatic tumors with realtime image guidance. Full sedation was provided only after the ablation process had been started, which usually caused more pain than the needle puncturing itself.

Table. 2. Tumor Characteristics and Approach of RFA

	(n)	(%)
No. of tumors		
Solitary	5	22
Multinodular		
2-3	13	57
>3	5	22
Size of the tumor		
≤3	17	74
>3	6	26
Approach of ablation		
Percutaneous	11	48
Open	10	43
Laparoscopic	2	9

Ablation

All open or laparoscopic ablations were performed by the surgeons under the guidance of intraoperative or laparoscopic ultrasound under general anesthesia. The ablation was performed using an automatic impedance control mode in which the current output was automatically adjusted according to the impedance at the needle tip. Temperature at the needle tip was also monitored. The needle tip was continuously perfused with cold saline via an internal channel inside the needle throughout the ablation to maintain the temperature below 20°C, thus preventing charring around the needle tip.The duration of each ablation cycle was set at 15 minutes according to the recommendation of the manufacturer of the RFA system.

Assessment of therapeutic efficacy

To evaluate the tumor response to RFA therapy, contrast enhanced CT was performed 1 month post-ablation and the complete ablation of the tumor was considered to be achieved if the scans revealed: (1) the ablation zone was beyond the tumor borders, (2) the margin of the ablation zone was clear and smooth, and (3) no contrast enhancement was detected within or around the tumor. Subsequently, the patients were monitored regularly for intrahepatic recurrence in the outpatient clinic by a follow-up protocol including serum α-fetoprotein (AFP) Carcino embryonic antigen(CEA), abdominal Ultrasound(US) and Contrast enhanced CT every 2-3 months for the first year, and then AFP,CEA every 2-3 mo, abdominal US and enhanced CT every 4-6 months after the first year.Postprocedural adjuvant systemic chemotherapy was offered to patients on the basis of their performance status and the histological features of their disease.

All patients were followed up to detect acute or chronic complications related to the RFA treatment. Suspected intrahepatic recurrence was confirmed by percutaneous fine needle biopsy. Local recurrence was defined as tumor recurrence within or at the periphery of the ablated lesion in the follow-up CT scan.Distant intrahepatic recurrence referred to a new tumor that appeared in the liver separated from the ablated area. Patients were followed-up for 6-34 months.

Clinical data

To prospectively evaluate the results of the treatment, the clinical data of all patients were prospectively collected in a computerized database. The Institutional Review Board of our institution approved the treatment protocol and the collection of data. The initial 23 consecutive patients with liver tumors treated with RFA in our institution over a period of 24 months were the subjects of this study.

Statistical Analysis

In univariate analysis, recurrence rates were compared between groups by a x2 or Fisher exact test. Comparison between groups was performed using x2 test with Yates correction (or Fisher exact test where appropriate) for nominal variables. All statistical analyses were performed using the SPSS 10.0 for windows statistical package (SPSS Inc., Chicago, IL). A P value of ≤ 0.05 was considered to be statistically significant.

Results

Patient Demographics

During the study period 23 patients underwent RFA procedures to ablate 12 patients with hepatocellular carcinoma (52%) and 11 with metastatic (48%) hepatic tumors (Table 1) shows the clinical characteristics of the patients. The most common indication for RFA was HCC (52%). Colorectal metastasis was the most common type of liver secondaries treated (6 patients). Other types of liver secondaries included metastases from neuroendocrine tumor (2 patients), and gastrointestinal stromal tumor (3 patient). The majority of patients with HCC had underlying cirrhosis in association (8/12). These patients underwent 44 radiofrequency sessions, which were used to treat 53 tumors (25 -primary, 28-metastatic). The series included 18 men and 5 women, mean age 67 years (range 36-82). Mean follow-up was 21.3 months (range 1-34 months).

Hepatic resection, and Portal vein Ligation

Out of 23 patients 9 had previous hepatic resection, and RFA was employed to treat intrahepatic tumor recurrences and tumors in remnant liver. Eight patients underwent hepatectomy, major hepatectomy for five (Right hepatectomy for three left hepatectomy for two)and left lobectomy and non anatomical resections for three. Portal vein ligation was performed in 9 patients either open RFA or hepatic resection.

Tumor characteristics

For the 53 tumors treated in 23 patients 5patints (22%) had solitary tumors,multinodular in 18 patients(78%)[2-3(13),>3(5)].Size of the tumor ≤3cm in 17 patients(74%)and >3 in 6 patients(26%). Mean tumor size was 23 mm (range 15-70 mm) in HCC and 25mm(range 15-40 mm) in metastatic tumors.

Radiofrequency procedure

For the 53 tumors treated in 23 patients, 11 were treated percutaneously(48%)and 12 via a surgical approach (52%) (Laparoscopic approach for two). Ultrasound guidance was used for all sessions for a percutaneous procedure.Intraoperative Ultrasound used for open surgical approach.Mean duration of the radiofrequency sessions was 20.8± 12.7 minutes (range 6-88 min). Median duration was 16.7 minutes. Overall, complete tumor ablation was observed in 18 of the 23 patients (78 %) who had the post ablation CT scan assessment. Five patients had incomplete ablation, 3 after percutaneous RFA and 2 after open RFA. Among these 5 patients, 3 had residual tumor at the deep margin. These patients were reablated after CT assessment.

Hospital stay

Mean hospital stay was 7.3 ±5.2 days (range 2-24 days).For the 11 percutaneous procedures, mean hospital stay was 5 ±3.8 days. For the 12 surgical procedures, mean hospital stay was 11.2 ±5 days.

Table. 3. Complications After Radiofrequency Ablation (5/23)

Complication	Number (n)	Percentage (%)
Liver dysfunction	2	9
Intraperitoneal bleeding	1	4
Bilioma	1	4
Liver Abscess	1	4

Morbidity and mortality

Five patients presented with complications during their hospital stay, giving a hospital morbidity of 22%. Post procedural liver dysfunction occurred in 2 patients (9%), Bleeding in 1 patient (4%)one patient developed liver abscess and bilioma in one patient **(Table. 3).** One patient (4.3%) died due to liver dysfunction giving a hospital mortality of 4%. This cirrhotic patient underwent hepatic resection for hepatocellular carcinoma and died 28th day after procedure from liver failure.

Survival

Patients were divided into two groups for the survival analysis: hepatocellular carcinoma or metastasis from colorectal and other prrmaries. Overall survival rates for

the hepatocellular carcinoma group were 83%, 66%, 42%, at 6months,1, and 2 years respectively. For the metastasis group the overall survival rates were 91%, 90%, 64%, at 6months 1, and 2 years respectively .Patients who had recurrence had a significantly lower survival rate (P = 0.04) (**TABLE 4)**

Recurrence

At 2 years 17 of the 53 tumors treated by radiofrequency ablation recurred in 14 patients (26.4%). In the metastasis group (considering all types of primary tumors) 7 of 28 tumors recurred (25%). In the hepatocellular carcinoma group, 7 of 25 tumors recurred (30%).**(Table 5)**Univariate analysis was performed to evaluate the effect of factors that may potentially influence the treatment and recurrence rate. The following factors did not significantly affect the recurrence rate: patient age , sex , underlying cirrhosis , tumor pathology (primary versus metastasis) , size of the tumor (_3 versus _3 cm; , number of tumors ablated, approach of ablation, sub capsular location.

At univariate analysis size of the tumor (>3cm)(p=0.02),number of tumors more than 3 (P = 0.04) and tumor proximity to major vessel. (P = 0.04)were significantly associated with recurrence. On follow up after two years seven patients were died which was significantly associated with recurrence (P = 0.05). Tumor pathology (Primary or secondary) (P = 0.94),sub capsular location, type of approach were not significantly associated with recurrence. Cirrhosis associated with high mortality (P = 0.001)

TABLE 4. Treatment Outcomes

Duration of ablation	16.7 min (6-88)	
Hospital stay (days)	7.3 +5.2 days (2-24)	
Complete ablation	18	78%
Morbidity	7	30%
Hospital mortality	1	4%
Recurrence	14	61%
Reablation	6	26%
Overall Survival	21 months (1-34)	

Discussion

The management of HCC and liver metastases is challenging.HCC and liver metastases from other solid tumors are major causes of morbidity and cancer-related death worldwide. Surgical resection provides the greatest potential for cure in patients with liver metastases or primary liver tumors.Unfortunately, many patients either have unresectable disease that is surgically inaccessible or have a large tumor burden or inadequate hepatic reserve Unfortunately, systemic chemotherapy is rarely effective and often associated with significant toxicity , with few complete responses and rare long-term progression-free survival, and usually do not significantly improve overall patient survival[22-24]. As previously noted, the majority of patients with primary or metastatic liver tumors are not candidates for resection; however, because potentially curative or palliative benefit may be derived from destruction of the liver tumors, in situ ablative techniques like PEI, cryoablation and RFA were developed.

TABLE 5. Local Recurrence Rate: Univariate Analysis of Factors

Factor	Category	% of	No. of	No. of	P
Diameter (cm)	<3cm	53	17	9	
	>3cm	83	6	5	p=0.02
	Total	61	23	14	
No.Of tumors	<3	50	18	9	
	>3	100	5	5	p=0.04
	Total	61	23	14	
Pathology	HCC	58	12	7	
	CRLM	67	6	4	
	NELM	100	2	2	p=0.94
	GIST	33	3	1	
	Total	61	23	14	
Proximity major vessel	Yes	88	8	7	
	No	47	15	7	p=0.04
	Total	61	23	14	
Location	Subcapsular	67	9	6	
	Nonsubcapsular	57	14	8	p=0.31
	Total	61	23	14	
Approach	Percutaneous	64	11	7	
	Open	50	10	5	p=0.13
	Laparoscopic	100	2	2	
	Total	61	23	14	

RFA with other ablative modalities

RF thermal ablation has proved to be safe and effective for the treatment of hepatic tumors in patients who are considered to be unsuitable for surgical intervention and recently has attracted much attention. It has some merits compared with the other percutaneous techniques: The treatment time is shorter than that with the more popular percutaneous ethanol injection [25], the thermal lesions are larger than those obtained with a microwave electrode[26], and it is less expensive and easier to perform than interstitial laser photocoagulation, in which multiple fiber insertions are always required[27], and It is more safer and lower complications than cryotherapy[28].

HCC

HCC with cirrhosis responded best to treatment with RFA than liver metastases. Large lesions over 3 cm were treated showing lesion stability on CT scan and a dramatic fall in AFP levels. The reason for a good response in this group of tumors is probably due to the characteristic features of hepatocellular carcinomas, which offer better heat conduction. It is clear that RFA is a useful primary therapy in patients with unresectable HCC, especially in cases with a poor liver reserve from cirrhosis and with multiple and deep-sited lesions. Prior experience treating small HCC described the “oven effect” [25], whereby cirrhotic liver surrounding individual HCC nodules acts as a thermal insulator that increases tissue heating during RF therapy.

Colorectal liver metastases

Colorectal liver metastases are usually hard. Patients with colorectal liver metastases usually have no cirrhosis, and as they have good liver reserve, most patients without extrahepatic spread are suitable for liver resection. Unresectability is commonly due to extensive multiple, bilateral disease or central lesions. Resection in combination with RFA in selected patients has been associated with a favorable long-term survival. The application of RFA has a number of potential advantages in patients with otherwise unresectable liver malignancies. The procedure is relatively safe and well tolerated, and its complication rates in most series have been low.

Importance of Local Recurrence

In the present study, a minimum follow-up of 6 months for each tumor and/or a mean follow-up of at least 12 months for the whole series were required for inclusion. A local recurrence seriously jeopardizes the chances of cure, as re-treatment is often impossible or has a high risk of failure. In an exhaustive review of 153 reports on RFC up until January 1, 2004, found only 18 authors (12%) who reported an attempt at local re-treatment. In total, of 64 recurrent tumors, only 35 (55%) were re-treated and a complete coagulation was obtained in only 23 cases (36%). One report described 64 patients with local recurrences, of which only 34 received re-treatment.

For example, in a series of 364 hepatocellular carcinomas (HCC) smaller than 3.5 cm,(29) percutaneous session achieved a complete coagulation at immediate post-RFC CT in 77% of tumors. Immediately after the second session in the incompletely treated cases, 99.7% of tumors appeared completely coagulated on CT.(34)Local recurrence rate after RFC of liver tumors varies widely between 2%1 and 68%.(30) The local recurrence rate in the present study was 60%. After re ablation recurrence rate was 35%.

Tumor-Dependent Factors

Number of Tumors

What counts for a patient, however, is the patient-based local recurrence rate. The more tumors a patient has, the more he is at risk for having at least one local recurrence. The deleterious effect of every factor that increases local recurrencerate on a single tumor level is being amplified in patients with multiple tumors. In this present study more than 3 number of tumors associated with high recurrence rate (p=0.04)

Size

Nearly all authors agree that size is an important factor determining local recurrencerate,Several factors may contribute to the higher local recurrence rate for larger tumors. First, the fact that the size of individual RFC lesions is limited. A single coagulation may be sufficient to cover a small tumor and its 1-cm safety margin at both sides, but not to cover a large tumor. Unfortunately, when more than one treatment session is needed to obtain a complete coagulation, a higher risk of local recurrence has been described.(31)Our study also shows higher recurrence rate when the tumor size is more than 3cm(p=0.04) For large tumors, a large number of precisely calculated overlapping coagulations is necessary.

The technique of overlap is not easy: using ultrasound, it is difficult to visualize the tumor after the first coagulation session due to the appearance of a hyperechogenic microbubble cloud(33). As a result, nests of viable tumor cells will remain in the clefts between the incompletely fused coagulation zones. As an alternative to overlapping coagulations, new electrodes that claim to produce larger coagulation zones in a single session have been introduced recently. (35) A second factor is that larger tumors more frequently have irregular borders than small tumors. This is true for colorectal metastases, as well as for HCC. (36) If the coagulation is

restricted to the main tumor without safety margin, spiky irregular extensions and satellites will be left untreated.

Pathology

The impact of pathology on local recurrence rate is unclear in the literature(32). Local recurrence rates for HCC and colorectal metastases were similar.Differences in local recurrence rate between various tumor types may be due to differences in the mean natural growth rate. Present study did not show any significant differences in recurrence and outcome in relation to tumor type.

Proximity of Large Vessels

The literature is not clear about the influence of the proximity of large vessels on the risk of local recurrence.Residual or recurrent tumor near large vessels was reported(37), and 3 comparative studies found an increased risk, This study, however, clearly confirms the impact of the proximity of large vessels on the risk of local recurrence.($p=0.04$)

Subcapsular Location

A subcapsular location was found to significantly increase local recurrence rate First, it is possible that in the percutaneous approach, subcapsular tumors have been undertreated for fear of burning adjacent organs, diaphragm, or the abdominal wall. Second, a percutaneous treatment of subcapsular tumors under local anesthesia with or without sedation can be painful, which may have prevented a correct complete

coagulation. Subcapsular location did not show significant higher recurrence rate in this study. In conclusion, a subcapsular location is probably not a risk factor for local recurrence per se, but only if RFC is performed percutaneously. For this reason, as well as for the increased risk of bleeding and seeding when treated percutaneously, a laparoscopic or open approach is favored for subcapsular tumors (28).

Physician-Dependent Factors

Approach

RFC was pioneered by interventional radiologists. When RFC was first introduced clinically, it was entirely experimental and considered as a palliative treatment.In that context, the percutaneous route was justified as it was the least invasive and a less costly approach. Even today, the majority of RFC procedures are still performed percutaneously.In one meta-analysis(21), a surgical approach (laparotomy or laparoscopy) clearly yielded statistically significantly (p = 0.001) superior results than a percutaneous approach,.Meta-analysis indicates that RFC by laparoscopy or laparotomy results in superior local control, independent of tumor size. In this study percutaneous approach was used in 48% of patients and open approach in 43% of cases.There is no significant difference in recurrence rate or outcome in relation to type of approach.

Morbidity

RFA is currently receiving the greatest attention, given its general availability and the recent technical advances facilitating its use and effectiveness. From the vast experience, reasonable safety of the procedure has been established, with mortality and morbidity in the largest series at 0.2% and 1.7%, respectively(39). The overall morbidity in this series is 22%, which is higher than in other published series. We believe the higher morbidity in this series reflects the aggressive treatment approach we have adopted.

Survival

After Overall 5-year survival rates for patients who undergo hepatic cryoablation for metastatic colorectal carcinoma is 20% to 25%, and for HCC,25% to 30%, in larger series.28-32 Thus, tumor ablation appears to positively affect long-term survival in these patient groups. Results of long-term follow-up have now been presented, with an overall survival of 93%, 62%, and 41% observed at 12, 24, and 36 months, respectively(40).

Adequate ablation of hepatic tumors is feasible using RF energy. Percutaneous, laparoscopic, and open surgical approaches can be used to deliver RF probes to hepatic tumors.The long-term survival data for this technology are still being gathered. In the present series overall survival rates for the hepatocellular carcinoma group (N = 6) were 66%, 42%, at 1, and 2 years respectively. For the metastasis group (N = 9), the overall survival rates were 90%, 64%, at 1, and 2 years respectively

Conclusion

In our experience, local recurrences were evident at a median follow-up time of 6 months and were associated with ablation of larger and multiple tumors.

Additionally, based on our limited experience, repeat RFA seems to be well tolerated. However, recurrence in the liver is frequently accompanied by extrahepatic disease, and careful preoperative staging is essential to select patients who could potentially benefit from repeat RFA.

Resection or ablation of liver tumors will not cure most patients with primary or metastatic malignant disease, although long-term disease-free survival rates of 20 % to 40 %

For patients with resectable CRLM whom are appropriate candidates to undergo resection (medical condition and comorbidities) resection remains the gold standard. Complete ablation with superior local control by RFA is achievable for lesions up to 3 cm in size.

Treatment with multimodality strategy is superior to single modality treatment for unresectable patients. Overall morbidity is related to patient selection and underlying co morbidities. We are very encouraged by our initial experience with RFA as a treatment for malignant liver tumors because it is safe, well tolerated, associated with few complications, and usually effective in controlling grossly or ultrasonographically evident in liver tumors.

RFA for liver tumors should not be viewed as a simple technique but rather a specialized treatment modality that should be undertaken only by clinicians with adequate knowledge and experience in interventional therapies for liver tumors.

When initiating the treatment, a team approach with close collaboration between surgeons and interventional radiologists may shorten the learning curve.

Currently, many centers are reporting their initial experience with RFA for liver tumors. With adequate experience, RFA can be used to ablate liver tumors with low morbidity, low mortality, and a high complete ablation rate

.

Reference

Introduction

1. Jeffrey SS, Birdwell RL, Ikeda DM, et al. Radiofrequency ablation of breast cancer:first report of an emerging technology. *Arch Surg.* 1999;134:1064-1068.

2. Dupuy DE, Zagoria RJ, Akerley W, Mayo-Smith WW, Kavanaugh PV, Safran H.Percutaneous radiofrequency ablation of malignancies in the lung. *AJRAmJ Roentgenol.*2000;174:57-59.

3. Dupuy DE, Hong RJ, Oliver B, Goldberg SN. Radiofrequency ablation of spinal tumors. *AJR Am J Roentgenol.* 2000;175:1263-1266.

4. Beitler AL, Urschel JD, Velagapudi SR, Takita H. Surgical management of adrenal metastases from lung cancer. *J Surg Oncol.* 1998;69:54-57.

5. Zlotta AR, Wildschultz T, Raviv G, et al. Radiofrequency interstitial tumor ablation (RITA) is a possible new modality for treatment of renal cancer: ex vivo and in vivo experience. *J Endourol.* 1997;11:251-258.

6. McGovern FJ, Wood BJ, Goldberg SN, Mueller PR. Radio frequency ablation of renal cell carcinoma via image guided needle electrodes. *J Urol.* 1999;161:599-600.

7. Gervais DA, McGovern FJ, Wood BJ, Goldberg SN, McDougal WS, Mueller PR. Radio-frequency ablation of renal cell carcinoma: early clinical experience. *Radiology.*2000;217:665-672.

8. Rossi S, Buscarini E, Garbagnati F, et al. Percutaneous treatment of small hepatic tumors by an expandable RF needle electrode. *AJR Am J Roentgenol.* 1998; 170:1015-1022.

9. Weaver ML, Ashton JG, Zemel R. Treatment of colorectal liver metastases by cryotherapy. *Semin Surg Oncol.* 1998;14:163-170.

10. Dupuy DE, Goldberg SN. Image-guided radiofrequency tumor ablation: challenges and opportunities, II. *J Vasc Interv Radiol.* 2001;12:1135-1148

11.Sean Garrean, Justin Hering, Abdul Saied, Radiofrequency ablation of primary and metastatic liver tumors:a critical review of the literature *Am J Surg.* 195 (2008) 508–520

12. Curley SA. Radiofrequency ablation of malignant liver tumors. Ann

Surg Oncol 2003;10:338–47.

13. Rossi S, Di Stasi M, Buscarini E. Percutaneous RF interstitial thermal

ablation in the treatment of hepatic cancer. *Am J Roentgenol.* 1996;167:

759–768.

14. Solbiati L, Goldberg SN, Ierace T, et al. Hepatic metastasis: percutaneous radio-frequency ablation with cool-tip electrodes. *Radiology.* 1997; 205:367–373.

15.. Allgaier HP, Deibert P, Zuber I, et al. Percutaneous radiofrequency

interstitial thermal ablation of small hepatocellular carcinoma. *Lancet.*

1999;353:1676–1677.

16. Curley SA, Izzo F, Delrio P, et al. Radiofrequency ablation of unresectable primary and metastatic hepatic malignancies: results in 123 patients.*Ann Surg.* 1999;230:1–8.

17. Livraghi T, Goldberg SN, Lazzaroni S, et al. Small hepatocellular

carcinoma: treatment with radio-frequency ablation versus ethanol injection.*Radiology.* 1999;210:655–661.

18. Cuschieri A, Bracken J, Boni L. Initial experience with laparoscopic

ultrasound-guided radiofrequency thermal ablation of hepatic tumours.

Endoscopy. 1999;31:318–321.

19. McGahan JP, Dodd GD III. Radiofrequency ablation of the liver: current status. *Am J Roentgenol.* 2001;176:3–16.

20. Poon RT, Fan ST, Tsang FH, et al. Locoregional therapies for hepatocellularcarcinoma: a critical review from the surgeon's perspective. *Ann Surg.* 2002;235:466–486.

21. Rossi S, Fornari F, Paties C, Buscarini L. Thermal lesions induced by 480-KHz localized current field in guinea pig and in pig livers. Tumori 1990; 76:54 –57.

22. Sanchez H, van Sonnenberg E, D'agostine H, et al. Percutaneous tissue ablation by radiofrequency thermal energy as a preliminary to tumor ablation. Minim Invasive Ther 1993; 2:299 –305.

23. McGahan JP, Browning PD, Brock JM, et al. Hepatic ablation using radiofrequency electrocautery. Invest Radiol 1990; 25:267–270.

24. Lounsberry W, Goldschmidt V, Linke C. The early histologic changes following electrocoagulation. Gastrointest Endosc 1995; 41:68 –70

25. Adam R, Avisar E, Ariche A, et al. Five-year survival following hepatic resection after neoadjuvant therapy for nonresectable colorectal. *Ann Surg Oncol.* 2001;8:347–353.

26. Bismuth H, Adam R, Levi F, et al. Resection of nonresectable liver metastases from colorectal cancer after neoadjuvant chemotherapy. *Ann Surg.* 1996;224:509–520.

27. Abdalla EK, Hicks ME, Vauthey JN. Portal vein embolization: rationale, technique and future prospects. *Br J Surg.* 2001;88:165–175.

28. Adam R, Laurent A, Azoulay D, et al. Two-stage hepatectomy: a

planned strategy to treat irresectable liver tumors. *Ann Surg*. 2000;232:

777–785.

29. Kianmanesh R, Farges O, Abdalla EK, et al. Right portal vein ligation:

a new planned two-step all-surgical approach for complete resection of

primary gastrointestinal tumors with multiple bilateral liver metastases.

J Am Coll Surg. 2003;164–170.

30 Abdalla EK, Vauthey JN, Ellis LM, et al. Recurrence and outcomes

following hepatic resection, radiofrequency ablation, and combined

resection/ablation for colorectal liver metastases. Ann Surg 2004;239:

818–25.

31 Mulier S,Ni Y Jamart J,Ruers T.Local recurrence after hepatic radiofrequency coagulation: multivariate meta-analysis and review of contributing factors.Ann Surg. 2005 Aug;242(2):158-71. Review

.

32 . Solbiati L, Livraghi T, Goldberg SN, et al. Percutaneous radio-frequency ablation of hepatic metastases from colorectal cancer. *Radiology.* 2001;221:159- 166.

33 . Livraghi T, Meloni F, Goldberg SN, Lazzaroni S, Solbiati L, Gazelle GS. Hepatocellular carcinoma. *Radiology.* 2000;214:761-768.

34 . Curley SA, Izzo F, Ellis LM, Nicolas Vauthey J, Vallone P. Radiofrequency ablation of hepatocellular cancer in 110 patients with cirrhosis. *Ann Surg.* 2000;232:381-391.

35 . de Baere T, Elias D, Dromain C, et al. Radiofrequency ablation of 100 hepatic metastases with a mean follow-up of more than 1 year. *AJR Am J Roentgenol.*2000;175:1619-1625.

36 . Goldberg SN, Hahn PF, Tanabe KK, et al. Percutaneous radiofrequency tissue ablation. *J Vasc Interv Radiol.* 1998;9(pt 1):101-111.

37 . Patterson EJ, Scudamore CH, Owen DA, Nagy AG, Buczkowski AK. Radiofrequency ablation of porcine liver in vivo. *Ann Surg.* 1998;227:559-565.

38. Livraghi T, Goldberg SN, Solbiati L, Meloni F, Ierace T, Gazelle GS. Percutaneous radio-frequency ablation of liver metastases from breast cancer: initial experience in 24 patients. *Radiology.* 2001;220:145-149.

REVIEW OF LITRATURE

[1] Curley SA. Radiofrequency ablation of malignant liver tumors. Ann

Surg Oncol 2003;10:338–47.

[2] Buscarini L, Buscarini E, Di Stasi M, et al. Percutaneous radiofrequency ablation of small hepatocellular carcinoma: long-term results.Eur Radiol 2001;11:914 –21.

[3] Lencioni R, Cioni D, Crocetti L, et al. Early-stage hepatocellular

carcinoma in patients with cirrhosis: long-term results of percutaneous

image-guided radiofrequency ablation. Radiology 2005;234:961–7.

[4] Raut CP, Izzo F, Marra P, et al. Significant long-term survival after

radiofrequency ablation of unresectable hepatocellular carcinoma in

patients with cirrhosis. Ann Surg Oncol 2005;12:616 –28.

[5] Tateishi R, Shiina S, Teratani T, et al. Percutaneous radiofrequency

ablation for hepatocellular carcinoma. An analysis of 1000 cases.

Cancer 2005;103:1201–9.

[6] Guglielmi A, Ruzzenente A, Battocchia A, et al. Radiofrequency

ablation of hepatocellular carcinoma in cirrhotic patients. Hepatogastroenterology 2003;50:480–4.

[7] Giovannini M, Moutardier V, Danisi C, et al. Treatment of hepatocellular carcinoma using percutaneous radiofrequency thermoablation: results and outcomes in 56 patients. J Gastrointest Surg 2003; 7:791– 6.

[8] Shibata T, Shibata T, Maetani Y, et al. Radiofrequency ablation for small hepatocellular carcinoma: prospective comparison of internally cooled electrode and expandable electrode. Radiology 2006;238: 346–53.

[9] Berber E, Rogers S, Siperstein A. Predictors of survival after laparoscopic radiofrequency thermal ablation of hepatocellular cancer: a prospective study. Surg Endosc 2005;19:710–4.

[10] Poon RT, Ng KK, Lam CM, et al. Radiofrequency ablation for subcapsular hepatocellular carcinoma. Ann Surg Oncol 2004;11: 281–9.

[11] Lin SM, Lin CJ, Lin CC, et al. Randomised controlled trial comparing percutaneous radiofrequency thermal ablation, percutaneous ethanol injection, and percutaneous acetic acid injection to treat hepatocellular carcinoma of 3 cm or less. Gut 2005;54:1151– 6.

[12] Lin SM, Lin CJ, Lin CC, et al. Radiofrequency ablation improves prognosis compared with ethanol injection for hepatocellular carcinoma _ or _4 cm. Gastroenterology 2004;127:1714 –23.

[13] Shiina S, Teratani T, Obi S, et al. A randomized controlled trial of

radiofrequency ablation with ethanol injection for small hepatocellular carcinoma. Gastroenterology 2005;129:122–30.

[14] Omata M, Tateishi R, Yoshida H, et al. Treatment of hepatocellular carcinoma by percutaneous tumor ablation methods: ethanol injection therapy and radiofrequency ablation. Gastroenterology 2004;127: S159–66.

[15] Chen MS, Zhang YJ, Li JQ, et al. [Randomized clinical trial of percutaneous radiofrequency ablation plus absolute ethanol injection compared with radiofrequency ablation alone for small hepatocellular carcinoma]. Zhonghua Zhong Liu Za Zhi 2005;27:623–5.

[16] Lu MD, Xu HX, Xie XY, et al. Percutaneous microwave and radiofrequency ablation for hepatocellular carcinoma: a retrospective comparative study. J Gastroenterol 2005;40:1054–60.

[17] Chen MS, Li JQ, Liang HH, et al. [Comparison of effects of percutaneous radiofrequency ablation and surgical resection on small hepatocellular carcinoma]. Zhonghua Yi Xue Za Zhi 2005;85:80 –3.

[18] Cho CM, Tak WY, Kweon YO, et al. [The comparative results of radiofrequency ablation versus surgical resection for the treatment of hepatocellular carcinoma]. Korean J Hepatol 2005;11:59 –71.

[19] Hong SN, Lee SY, Choi MS, et al. Comparing the outcomes of radiofrequency ablation and surgery in patients with a single small hepatocellular carcinoma and well-preserved hepatic function. J Clin Gastroenterol 2005;39:247–52.

[20] Montorsi M, Santambrogio R, Bianchi P, et al. Survival and recurrences after hepatic resection or radiofrequency for hepatocellular

carcinoma in cirrhotic patients: a multivariate analysis. J Gastrointest

Surg 2005;9:62–7.

[21] Vivarelli M, Guglielmi A, Ruzzenente A, et al. Surgical resection

versus percutaneous radiofrequency ablation in the treatment of hepatocellular carcinoma on cirrhotic liver. Ann Surg 2004;240:102–7.

[22] Curley SA, Izzo F, Delrio P, et al. Radiofrequency ablation of unresectable primary and metastatic hepatic malignancies: results in 123

patients. Ann Surg 1999;230:1– 8.

[23] De Baere T, Elias D, Dromain C, et al. Radiofrequency ablation of

100 hepatic metastases with a mean follow-up of more than 1 year.

AJR Am J Roentgenol 2000;175:1619 –25.

[24] Guilliams AR, Lees WR. Survival after percutaneous, image-guided,

thermal ablation of hepatic metastases from colorectal cancer. Dis

Colon Rectum 2000;43:656–66.

[25] Guilliams AR, Lees WR. Radiofrequency of colorectal liver metastasis.

Abdom Imaging 2005;30:419 –26.

[26] Solbiati L, Livraghi T, Goldberg SN, et al. Percutaneous radiofrequency

ablation of hepatic metastases from colorectal cancer:

long-term results in 117 patients. Radiology 2001;221:159–66.

[27] Curley SA. Outcomes after surgical treatment of colorectal cancer

liver metastases. Semin Oncol 2005;32:S109 –11.

[28] Abdalla EK, Vauthey JN, Ellis LM, et al. Recurrence and outcomes following hepatic resection, radiofrequency ablation, and combined resection/ablation for colorectal liver metastases. Ann Surg 2004;239: 818–25.

[29] Dematteo RP, Palese C, Jarnagin WR, et al. Anatomic segmental hepatic resection is superior to wedge resection as an oncologic operation for colorectal liver metastases. J Gastrointest Surg 2000;4: 178–84.

[30] Elias D, Baton O, Sideris L, et al. Hepatectomy plus intraoperative radiofrequency ablation and chemotherapy to treat technically unresectable multiple colorectal liver metastases. J Surg Oncol 2005;90: 36–42.

[31] Cheng J, Glasgow E, O'Rourke, et al. Laparoscopic radiofrequency ablation and hepatic artery infusion pump placement in the evolving treatment of colorectal hepatic metastases. Surg Endosc 2003;17: 61–7.

[32] Scaife CL, Curley SA, Izzo F, et al. Feasibility of adjuvant hepatic arterial infusion of chemotherapy after radiofrequency ablation with or without resection in patients with hepatic metastases from colorectal cancer. Ann Surg Oncol 2003;10:348 –54.

[33] Machi J, Oishi AJ, Sumida K, et al. Long-term outcome of radiofrequency ablation for unresectable liver metastases from colorectal cancer: evaluation of prognostic factors and effectiveness in first- and

second-line management. Cancer J 2006;12:318 –26.

[34] Scaife CL, Curley SA. Complication, local recurrence, and survival rates after radiofrequency ablation for hepatic malignancies. Surg Oncol Clin N Am 2003;12:243–55.

[35] Kosari K, Gomes M, Hunter D, et al. Local, intrahepatic, and systemic recurrence patterns after radiofrequency ablation of hepatic malignancies. J Gastrointest Surg 2002;6:255– 63.

[36] Amersi FF, McElrath-Garza A, Ahmad A, et al. Long-term survival after radiofrequency ablation of complex unresectable liver tumors. Arch Surg 2006;141:581–7.

[37] Ahmad A, Chen SL, Kavanagh MA, et al. Radiofrequency ablation of hepatic metastases from colorectal cancer: are newer generation probes better? Am Surg 2006;72:875–9.

[38] de Gramont A, Figer A, Seymour M, et al. Leucovorin and fluorouracil with or without oxaliplatin as first-line treatment in advanced colorectal cancer. J Clin Oncol 2000;18:2938–47.

[39] Kerr DJ, McArdle CS, Ledermann J, et al. Intrahepatic arterial versus intravenous fluorouracil and folinic acid for colorectal cancer liver metastases: a multicentre randomised trial. Lancet 2003;361:368 –73.

[40] Pawlik TM, Izzo F, Cohen DS, et al. Combined resection and radiofrequency ablation for advanced hepatic malignancies: results in 172 patients. Ann Surg Oncol 2003;10:1059–69.

[41] Curley SA, Bilchik AJ, Fraker D, et al. Radiofrequency ablation of hepatic malignancies. Contemp Surg 2006;59:162–72.

[42] Tanabe KK, Curley SA, Dodd GD, et al. Radiofrequency ablation: the experts weigh in. Cancer 2004;100:641–50.

Discussion

1.Sean Garrean, Justin Hering, Abdul Saied, Radiofrequency ablation of primary and metastatic liver tumors:a critical review of the literature *Am J Surg*. 195 (2008) 508–520

2. Curley SA. Radiofrequency ablation of malignant liver tumors. Ann Surg Oncol 2003;10:338–47.

3. Rossi S, Di Stasi M, Buscarini E. Percutaneous RF interstitial thermal ablation in the treatment of hepatic cancer. *Am J Roentgenol*. 1996;167: 759–768.

4. Solbiati L, Goldberg SN, Ierace T, et al. Hepatic metastasis: percutaneous radio-frequency ablation with cool-tip electrodes. *Radiology*. 1997; 205:367–373.

5.. Allgaier HP, Deibert P, Zuber I, et al. Percutaneous radiofrequency interstitial thermal ablation of small hepatocellular carcinoma. *Lancet*. 1999;353:1676–1677.

6. Curley SA, Izzo F, Delrio P, et al. Radiofrequency ablation of unresectable primary and metastatic hepatic malignancies: results in 123 patients. *Ann Surg*. 1999;230:1–8.

7. Livraghi T, Goldberg SN, Lazzaroni S, et al. Small hepatocellular carcinoma: treatment with radio-frequency ablation versus ethanol injection.*Radiology*. 1999;210:655–661.

8. Cuschieri A, Bracken J, Boni L. Initial experience with laparoscopic ultrasound-guided radiofrequency thermal ablation of hepatic tumours. *Endoscopy*. 1999;31:318–321.

9. McGahan JP, Dodd GD III. Radiofrequency ablation of the liver: current status. *Am J Roentgenol*. 2001;176:3–16.

10. Poon RT, Fan ST, Tsang FH, et al. Locoregional therapies for hepatocellular carcinoma: a critical review from the surgeon's perspective. *Ann Surg*. 2002;235:466–486.

11. Rossi S, Fornari F, Paties C, Buscarini L. Thermal lesions induced by 480-KHz localized current field in guinea pig and in pig livers. Tumori 1990; 76:54 –57.

12. Sanchez H, van Sonnenberg E, D'agostine H, et al. Percutaneous tissue ablation by radiofrequency thermal energy as a preliminary to tumor ablation. Minim Invasive Ther 1993; 2:299 –305.

13. McGahan JP, Browning PD, Brock JM, et al. Hepatic ablation using radiofrequency electrocautery. Invest Radiol 1990; 25:267–270.

14. Lounsberry W, Goldschmidt V, Linke C. The early histologic changes following electrocoagulation. Gastrointest Endosc 1995; 41:68 –70

15. Adam R, Avisar E, Ariche A, et al. Five-year survival following hepatic resection after neoadjuvant therapy for nonresectable colorectal. *Ann Surg Oncol*. 2001;8:347–353.

16. Bismuth H, Adam R, Levi F, et al. Resection of nonresectable liver metastases from colorectal cancer after neoadjuvant chemotherapy. *Ann*

Surg. 1996;224:509–520.

17. Abdalla EK, Hicks ME, Vauthey JN. Portal vein embolization: rationale, technique and future prospects. *Br J Surg*. 2001;88:165–175.

18. Adam R, Laurent A, Azoulay D, et al. Two-stage hepatectomy: a planned strategy to treat irresectable liver tumors. *Ann Surg*. 2000;232: 777–785.

19. Kianmanesh R, Farges O, Abdalla EK, et al. Right portal vein ligation: a new planned two-step all-surgical approach for complete resection of primary gastrointestinal tumors with multiple bilateral liver metastases. *J Am Coll Surg*. 2003;164–170.

20 Abdalla EK, Vauthey JN, Ellis LM, et al. Recurrence and outcomes following hepatic resection, radiofrequency ablation, and combined resection/ablation for colorectal liver metastases. Ann Surg 2004;239: 818–25.

21 Mulier S,Ni Y Jamart J,Ruers T.Local recurrence after hepatic radiofrequency coagulation: multivariate meta-analysis and review of contributing factors.Ann Surg. 2005 Aug;242(2):158-71. Review

22 Doci R, Gennari L, Bignami P, Montalto F, Morabito A, Bozzetti F, Bonalumi MG. Morbidity and mortality after hepatic resection of metastases from colorectal cancer. *Br J Surg* 1995;82:377-381

23 Jamison RL, Donohue JH, Nagorney DM, Rosen CB, Harmsen WS, Ilstrup DM. Hepatic resection for metastatic

colorectal cancer results in cure for some patients. *Arch Surg* 1997;132:505-510

24 Stangl R, Altendorf-Hofmann A, Charnley RM, Scheele J. Factors influencing the natural history of colorectal liver metastases. *Lancet* 1994;343:1405-1410

25 Livraghi T, Goldberg SN, Lazzaroni S, Meloni F, Solbiati L, Gazelle GS. Small hepatocellular carcinoma: treatment with radio-frequency ablation versus ethanol injection. *Radiology* 1999;210:655-661

26 Shibata T, Iimuro Y, Yamamoto Y, Maetani Y, Ametani F, *Itoh K, Konishi J. Small hepatocellular carcinoma: comparison* of radio-frequency ablation and percutaneous microwave coagulation therapy.*Radiology* 2002;223:331-337

27 Heisterkamp J, van Hillegersberg R, Ijzermans JN. Interstitial laser coagulation for hepatic tumours. *Br J Surg* 1999; 86:293-304

28 Bilchik AJ, Wood TF, Allegra D, Tsioulias GJ, Chung M, Rose DM, Ramming KP, Morton DL. Cryosurgical ablation and radiofrequency ablation for unresectable hepatic malignant neoplasms: a proposed algorithm. *Arch Surg* 2000;135:657-664

29 . Curley SA, Izzo F, Delrio P, et al. Radiofrequency ablation of unresectableprimary and metastatic hepatic malignancies: results in 123patients. *Ann Surg*. 1999;230:1– 8.

30 . Kuvshinoff BW, Ota DM. Radiofrequency ablation of liver tumors:influence of technique and tumor size. *Surgery*. 2002;132:605– 611.

31 . Adam R, Hagopian EJ, Linhares M, et al. A comparison of percutaneous cryosurgery and percutaneous radiofrequency for unresectable hepatic malignancies. *Arch Surg*. 2002;137:1332–1339.

32 . Ossip MG, Kachura JR, Ho CS, et al. Radiofrequency ablation of liver

tumors: local progression-free survival and factors for failure of effectiveness.*J Vasc Interv Radiol*. 2004;15(suppl):208.

33 . Poon RT, Ng KK, Lam CM, et al. Learning curve for radiofrequency

ablation of liver tumors: prospective analysis of initial 100 patients in

a tertiary institution. *Ann Surg*. 2004;239:441– 449.

34 . Rossi S, Rosa L, Mongiovetti M, et al. Radiofrequency thermal ablation

(RFTA) of nonresectable hepatocellular carcinoma (HCC) nodules

in cirrhosis. *J Hepatol*. 2001;34(suppl 1):11..

35 . Mulier S, Ni Y, Miao Y, et al. Size and geometry of hepatic radiofrequency lesions. *Eur J Surg Oncol*. 2003;29:867– 878..

36 120. Maeda T, Takenaka K, Adachi E, et al. Small hepatocellular carcinoma of single nodular type: a specific reference to its surrounding cancerous area undetected radiologically and macroscopically. *J Surg Oncol*.1995;60:75–79..

37 . Scudamore CH, Shung IL, Patteron EJ, et al. Radiofrequency ablation

followed by resection of malignant liver tumors. *Am J Surg*. 1999;177:

411–417.

38 . Mulier S, Mulier P, Ni Y, et al. Complications of radiofrequency

coagulation of liver tumours. *Br J Surg*. 2002;89:1206 –1222

39 . Kainuma O, Asano T, Aoyama H, et al. Combined therapy with radiofrequencythermal ablation and intra-arterial infusion chemotherapy for hepatic metastases from colorectal cancer. *Hepatogastroenterology.* 1999;46:1071-1077.-1015.

40 . Solbiati L, Livraghi T, Goldberg SN, et al. Percutaneous radio-frequency ablation of hepatic metastases from colorectal cancer. *Radiology.* 2001;221:159-166

Table 1 -- Studies evaluating RFA alone for HCC

Authors	Year	No. of patients	Approach	Tumor size (cm)	Follow-up (mo)	Local recurrence	New liver or extrahepatic metastasis	Overall survival
Lencioni et al	2005	206	Perc	Mean < 5	24 ± 21	10%	49%	Median: 57 1y: 97% 2y: 71%
Guglielmi et al	2003	65	Perc	Mean: 4	mean: 18	6.8%	28.3%	1y: 87% 2y: 63%
Buscarini et al	2001	88	Perc	Mean: 3.5	mean: 34	CE: 29%	N/A	Median: 48 1y: 89%
Giovannini et al	2003	56	Perc	Mean: 4.1	mean: 14	7.1%	12.4%	3y: 94.2%
Shibata et al	2006	74	Perc	< 3	24	ICE 3y: 20%	N/A	3y: 94%
Raut et al	2005	194	Perc: 140 Open: 54	Median: 3.3	34.8	4.6%	48.5%	1y: 84.5%
Berber et al	2004	66	Lap	N/A	N/A	N/A	N/A	1y: 78% 2y: 48%
Tateishi et al	2004	664	Perc	Mean: 2.6	19	2.4%	54%	1y: 94.7%
Poon et al	2004	80	Perc	Median: 3.4	Median: 13	Sub: 4.3%	Sub: 31.9%	1y: 88.3%

RFA = radiofrequency ablation; HCC = hepatocellular carcinoma; Perc = percutaneous; Lap = laparoscopic; N/A = not available; ICE = internally cooled electrode; EE = expandable electrode; Sub = subcapsular tumor; No Sub = without subcapsular tumor; Tx = treatment.

Table 2 -- Studies evaluating RFA versus other ablative therapies for HCC

Authors	Year	No. of patients	Approach	Treatments	Tumor size (cm)	Follow-up (mo)	Local recurrence	New liver or extrahepatic metastasis	Overa surviv
Lin et al	2004	187	Perc	RFA (62) PEI (62) PAI (63)	Mean: 3	Mean: 35	RFA 3y: 14% PEI 3y: 34% PAI 3y: 31%	RFA 3y: 45% PEI 3y: 48% PAI 3y: 46%	RFA 3 PEI 3y PAI 3y

Authors	Year	No. of patients	Approach	Treatments	Tumor size (cm)	Follow-up (mo)	Local recurrence	New liver or extrahepatic metastasis	Overa surviv
Lin et al	2004	157	Perc	RFA (52) PEI (52) PEI HD (53)	Mean: 3	Mean: 23.5	RFA 14% PEI 35% PEI HD 24%	RFA 31% PEI 37% PEI HD 32%	RFA 3 PEI 3y
Shiina et al	2005	232	Perc	RFA (118) PEI (114)	Mean: 3	Mean: 37.2	RFA 1.7% PEI 11.4%	RFA 65% PEI 68%	RFA 4 PEI 4y
Omata et al	2004	1238	Perc	RFA (629) MWA (85) PEI (524)	RFA: 2.8 MWA: 2.9 PEI: 2.9	N/A	N/A	N/A	RFA 3 77.8% PEI 3y
Chen et al	2005	86	Perc	RFA (45) RF+PEI (41)	Mean < 5	N/A	RFA 2y: 43% RFA+PEI: 26%	N/A	RFA 2 RF+PE 2y:73%
Lu et al	2005	102	Perc	MWA (49) RFA (53)	Mean < 2.5	Mean: 25.1	MWA: 11.8% RFA: 20.9%	MWA: 69% RFA: 75%	MW 3 RFA 3

RFA = radiofrequency ablation; HCC = hepatocellular carcinoma; PEI = percutaneous ethanol injection; PAI = percutaneous acetic acid injection; MWA = microwave ablation; HD = high dose; N/A = not available.

Table 3 -- Studies evaluating RFA versus resection in HCC

Authors	Year	No. of patients	Approach	Tumor size (cm)	Follow-up (mo)	Local recurrence	New liver or extrahepatic metastasis	Overall survival	Co
Chen et al	2005	112	Perc	<5	36	Resec. 25% RFA 24%	N/A	Rese 3y: 67% RFA 3y: 65%	N/A
Montorsi et al	2005	98	Lap.	<5	RFA 28 Resec.22	RFA 53% Resec.30%	N/A	RFA 4y: 45% Resec.4y: 61%	N/A
Vivarelli et al	2004	158	Perc	>,<3	RFA 16 Resec. 29	N/A	N/A	RFA 3y: 33% Resec.3y: 65%	RF Re
Cho et al	2005	160	Perc/Open	<5	36	Resec. 10% RFA 18%	Resec. 33% RFA 28%	Resec 3y: 80% RFA3y:77%	N/A

RFA = radiofrequency ablation; HCC = hepatocellular carcinoma; Perc = percutaneous; Resec. = resection; N/A = not available.

Table 4 -- Studies evaluating RFA as a single therapy for CRLM

Authors	Year	No. of patients	Approach	Tumor size (cm)	Follow-up (mo)	Local recurrence per tumor	New liver or extrahepatic metastasis	Overall survival
Curley et al	1999	123 (crlm:61)	Perc: 31 Open: 92	3.4	15	2%	28%	1y: N/A
De Baere et al	2000	68 (crlm:58)	Perc: 47 Open: 21	1-4.2	13.7	9%	15%	1y: N/A
Guilliams et al	2001	69	Perc: All	1-8.0	27	N/A	58%	1y: 90% 2y: 60% 4y: 22%
Guilliams et al	2005	73	Perc: All	3.9	N/A	N/A	50%	Median: 1y: 91% 5yr: 25%
Solbiati et al	2001	117	Perc: All	: 2.6	6-52	39%	57%	Median: 1y: 93% 3y: 46%

RFA = radiofrequency ablation; Perc. = percutaneous; CRLM = colorectal liver metastasis; N/A = not available.

Table 6 -- Studies evaluating RFA plus other therapies

Authors	Year	No. of patients	Approach	Tumor size (cm)	Follow-up (mo)	Local recurrence per tumor	New liver or extrahepatic metastasis	Overall
Cheng et al	2003	45	Lap: All	N/A	11.5	N/A	N/A	RFA 7 RFA+ HAIP
Scafie et al	2003	50	Open: All	0.5-8.5	20	4%	30%	Median
Machi et al	2006	100	Open/Lap	1.1-4.2	24.5	6.7%	87%	Median 5y: 30.

Table 5 -- Studies evaluating RFA plus resection for CRLM

Authors	Year	No. of patients	Approach	Tumor size (cm)	Follow-up (mo)	Local recurrence per patient	New liver or extrahepatic metastasis	Over survi
Pawlik et al	2003	172 (crlm:124)	Open: All	Median: 1.8	22	8%	52%	Medi
Abdalla et al	2004	418 (3 groups) RFA: 57 RFA+Resec: 158 Resection: 190	Open: All	Median: 2.5	21	RFA 9% RFA+Resec.5%	RFA 40% RFA+Resec. 37%	RFA RFA 4y: 3
Elias et al	2005	63	Open: All	N/A	28	7%	71.4%	Medi 1y: 9 3y: 4

CRLM = colorectal liver metastasis; RFA = radiofrequency ablation; Resec. = resection; N/A = not available.

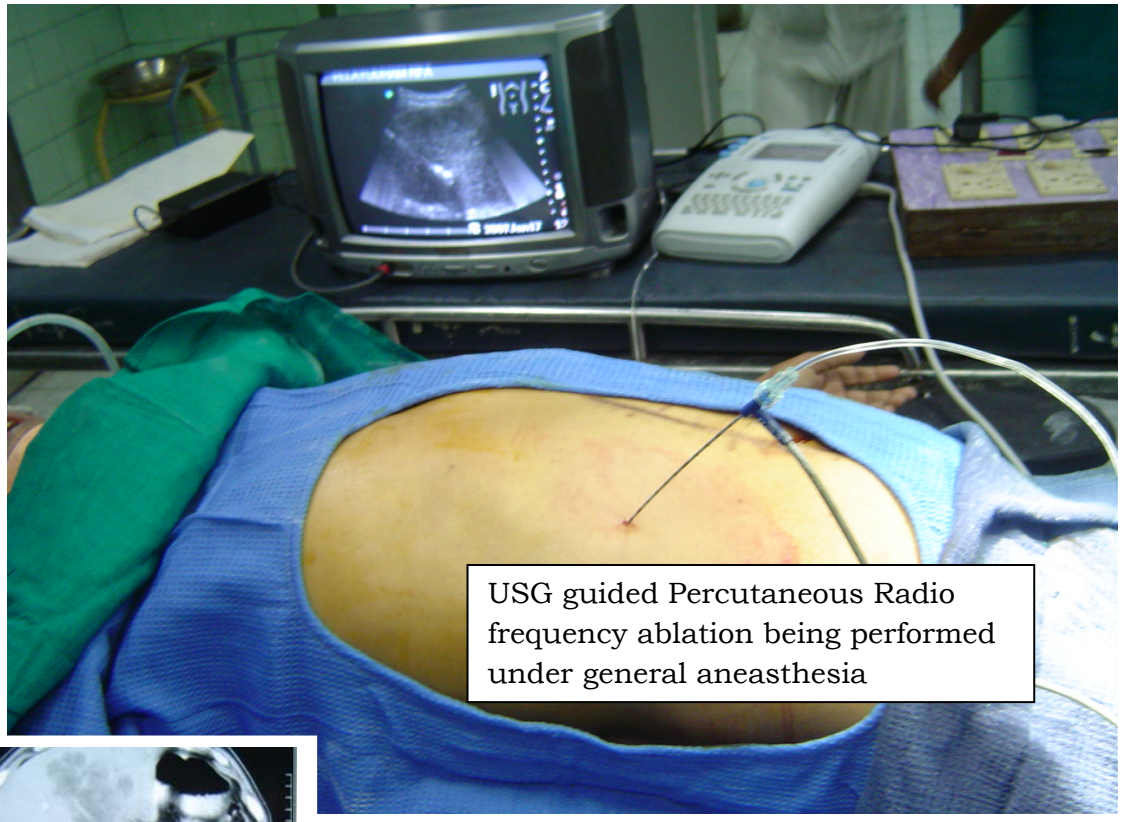

USG guided Percutaneous Radio frequency ablation being performed under general aneasthesia

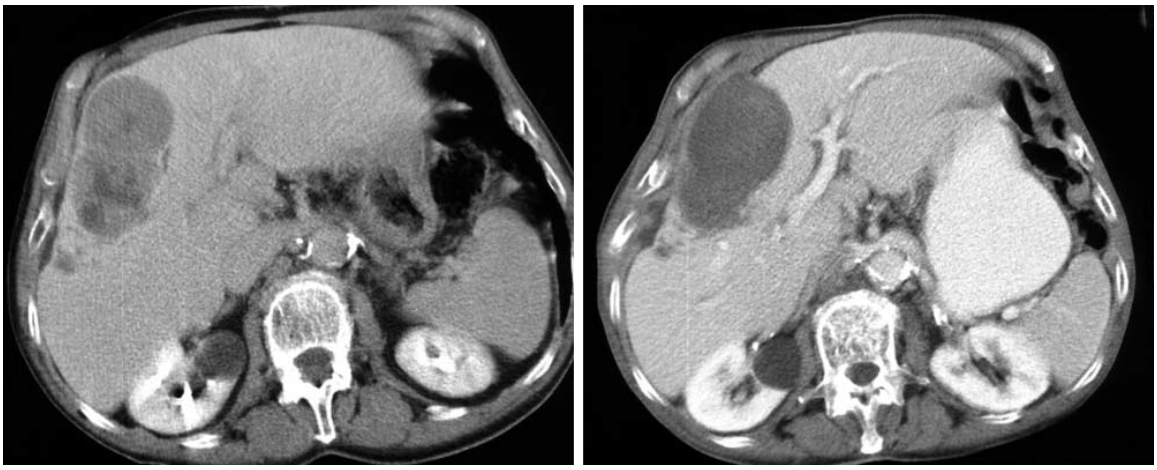

Figure 1. Radiofreqency ablation (RFA) of a large hepatocellular carcinoma. A, Preprocedural computed tomographic (CT) scan. B, A CT scan 2 months after RFA.

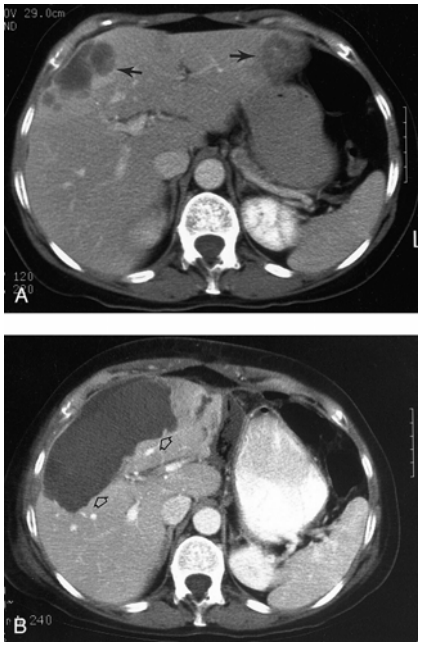

Figure 2. (A) Pretreatment CT scan in a patient with two large liver metastases (arrows) from colorectal cancer. (B) CT scan 1 month after resection of the left lobe lesion and RFA of the right lobe tumor. There is complete necrosis of the large right lobe lesion (open arrows)

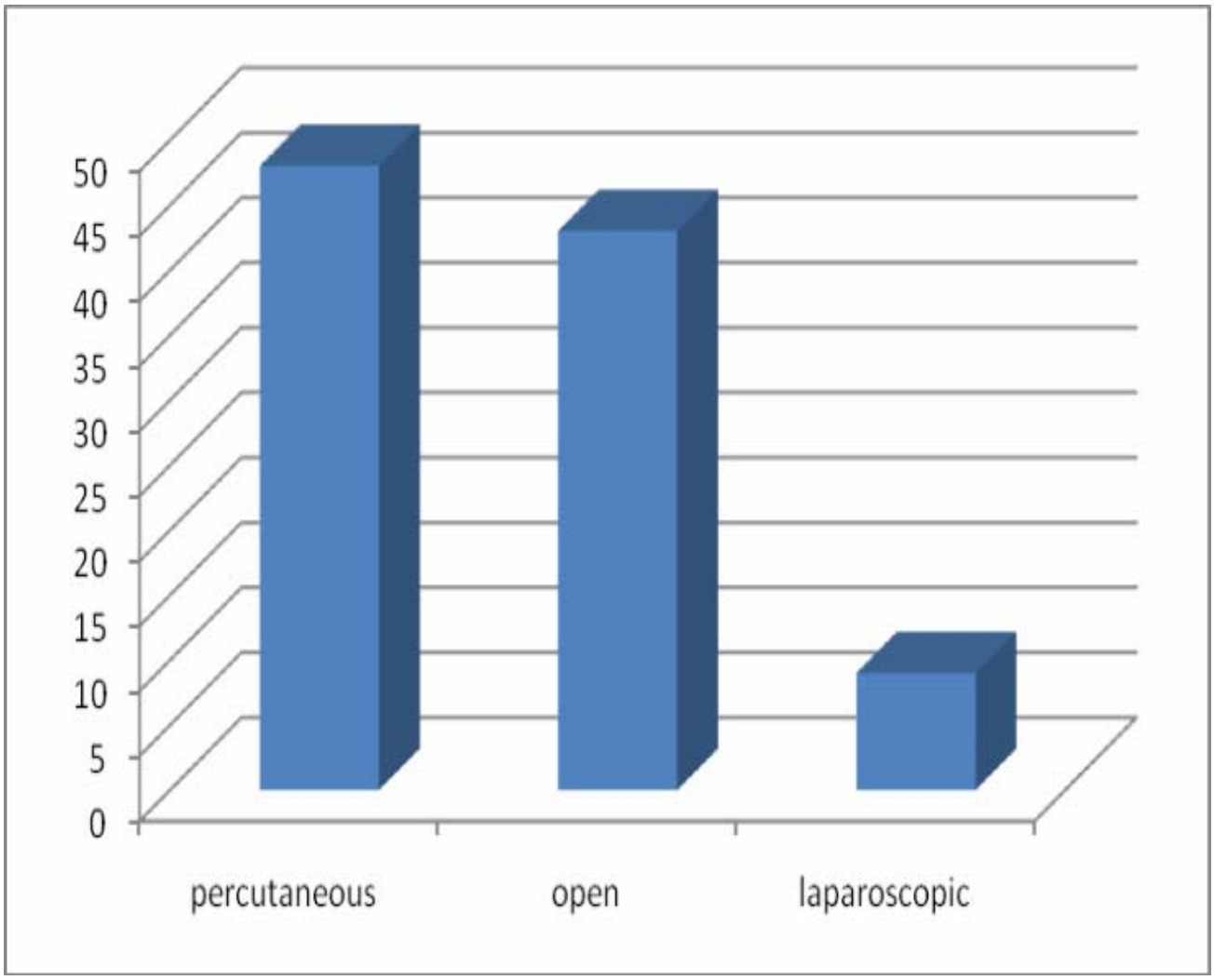

Approach for radio frequency ablation (%)

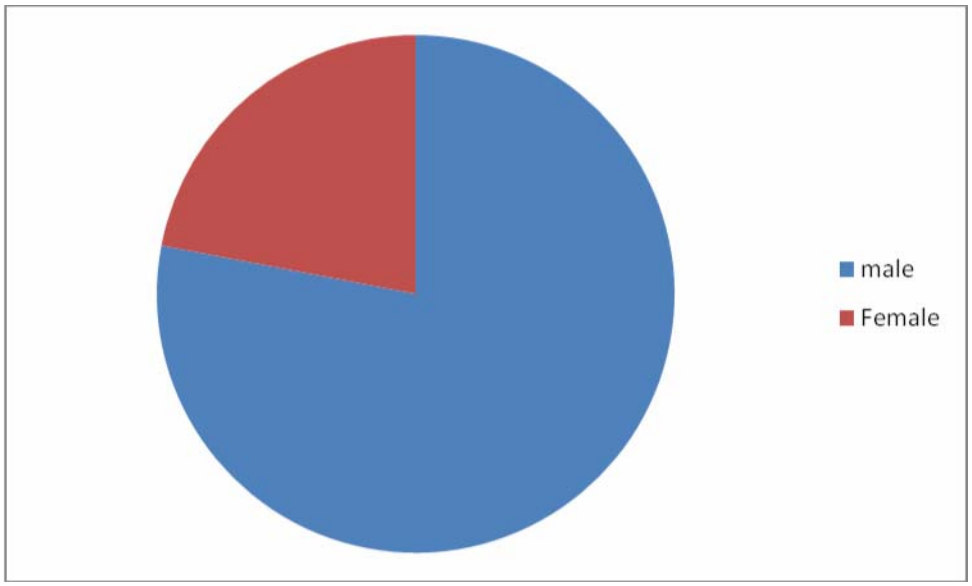

Demography

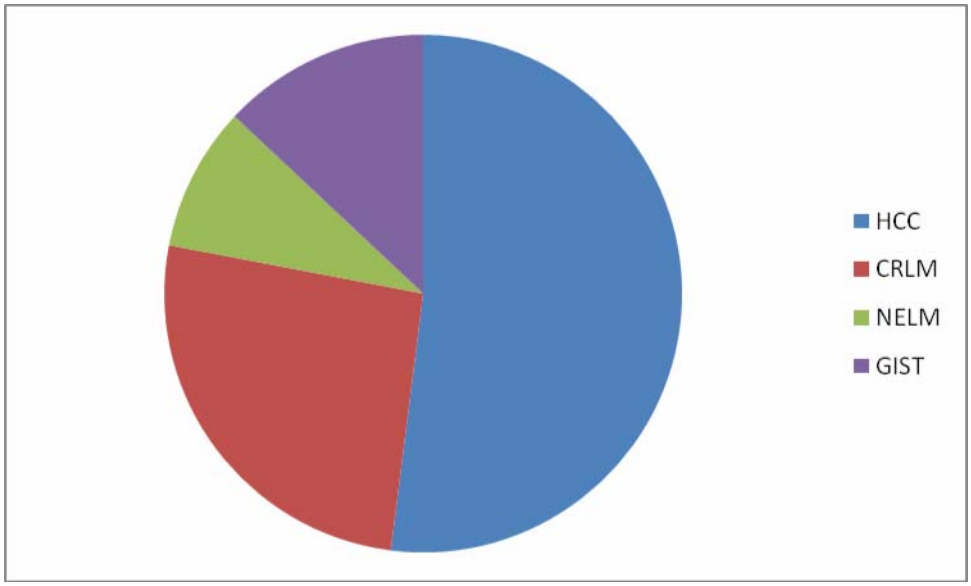

Tumour pathology

Master chart. Characteristics of Patients who underwent Radiofrequency Ablation

ender	Tumor pathology	Cirrhosis	Previous hepatic resection	No. of tumors	Size (cm)	No.of.RFA Sessions	Proximity major vessel	Sub capsular Location	Per cutaneous	Open	Laparoscopic	Complications	Recurrence	Foll Tt
nale	HCC	yes	no	1	6	3	yes	no	no	yes	no	no	yes	rec
male	HCC	no	yes	1	2	1	no	no	yes	no	no	no	no	
nale	HCC	yes	no	1	7	2	yes	no	yes	no	no	no	yes	
nale	CRLM	no	no	1	1.5	2	no	no	no	yes	no	no	no	
nale	GIST	no	yes	1	1.5	1	no	no	yes	no	no	yes	yes	rec
nale	HCC	no	yes	1	3	2	no	yes	no	yes	no	no	yes	rec
nale	CRLM	no	no	2	3.5	2	no	no	yes	no	no	no	yes	su
nale	HCC	yes	Yes	2	2	1	no	no	no	yes	no	no	no	
male	HCC	no	yes	2	2	1	yes	no	yes	no	no	no	no	
nale	HCC	yes	no	2	4	1	no	yes	no	yes	no	no	no	
nale	GIST	no	no	2	1.5	3	no	no	no	yes	no	no	no	
nale	GIST	no	no	2	3	2	no	yes	no	yes	no	no	no	
male	HCC	yes	no	2	5	2	yes	no	no	yes	no	no	yes	
nale	HCC	yes	no	3	3	2	no	yes	yes	no	no	yes	yes	rec
nale	NELM	no	yes	3	2.5	2	no	yes	yes	no	no	no	yes	rec
nale	CRLM	no	no	3	3	1	no	no	yes	no	no	no	no	
nale	NELM	no	no	3	2	2	no	yes	no	no	yes	no	yes	rec
male	HCC	yes	yes	3	2	2	yes	no	yes	no	no	yes	yes	rec
nale	HCC	yes	no	3	2.5	3	no	yes	yes	no	no	no	no	
nale	CRLM	no	yes	3	2	2	no	yes	no	yes	no	yes	yes	rec
nale	CRLM	no	no	4	3	2	yes	yes	no	no	yes	no	yes	rec

nale	CRLM	no	yes	4	4	2	yes	no	yes	no	no	yes	yes	rec
male	HCC	no	no	4	3	3	yes	no	no	yes	no	no	yes	rec

HCC-hepatocellular carcinoma, CRLM-colorectal liver metastasis, NELM-neuroendocrine liver metastasis,

GIST-gastrointestinal liver tumors,RFA-radiofrequecy ablation