MANAGEMENT OPTIONS IN VISCERAL ARTERY PSEUDO ANEURYSMS – A CRITICAL ANALYSIS AT A TERTIARY CARE REFFERAL CENTER:

Dissertation Submitted to

THE TAMIL NADU DR. M.G.R. MEDICAL UNIVERSITY

in partial fulfillment of the regulations

for the award of the degree of

M.Ch. DEGREE BRANCH -VI
(Higher Specialty)
SURGICAL GASTROENTEROLOGY AND PROCTOLOGY

GOVT. STANLEY MEDICAL COLLEGE & HOSPITAL
THE TAMIL NADU DR. M.G.R. MEDICAL UNIVERSITY
CHENNAI, INDIA.

FEBRUARY 2006

CERTIFICATE

This is to certify that **Dr. JOHNSON M.** has prepared the dissertation titled **"MANAGEMENT OPTIONS IN VISCERAL ARTERY PSEUDO ANEURYSMS - A CRITICAL ANALYSIS AT A TERTIARY CARE REFFERAL CENTER"** in partial fulfillment of the requirements for **M.Ch. DEGREE BRANCH-VI (Higher Specialty) SURGICAL GASTROENTEROLOGY AND PROCTOLOGY** Examination of the Tamilnadu Dr. M.G.R. Medical University to be held in February 2006. He has prepared this dissertation under my guidance and supervision. He has worked on a subject to my entire satisfaction. The period of study was from January 1998 to August 2005.

PROF. R. SURENDRAN ,
M.S;MNAMS;M.Ch.
Professor and Head of the
Dept. of Surgical Gastroenterology
and proctology,
Center for Gastrointestinal Bleed and
Division of Hepatobiliary-Pancreatic
Diseases
Govt. Stanley Medical College &
Hospital,
Chennai-600 001.

M.VASANTHA, M.D.,
DEAN
Govt. Stanley Medical College & Hospital,
Chennai-600 001.

DECLARATION

I, **Dr. JOHNSON M.** solemnly declare that dissertation titled, **"MANAGEMENT OPTIONS IN VISCERAL ARTERY PSEUDO ANEURYSMS – A CRITICAL ANALYSIS AT A TERTIARY CARE REFFERAL CENTER"** is a bonafide work done by me at Govt. Stanley Medical College & Hospital during 2003-2005 under the guidance and supervision of my Unit Chief **Prof. R. SURENDRAN , M.S;MNAMS;M.Ch Professor and Head of the Dept. of Surgical Gastroenterology and Proctology.**

The dissertation is submitted to Tamilnadu, Dr. M.G.R. Medical University, towards partial fulfillment of requirement for the award of **M.Ch. DEGREE BRANCH-VI (Higher Specialty) SURGICAL GASTROENTEROLOGY AND PROCTOLOGY**

Place : Chennai.

Date :

(Dr. JOHNSON M.)

ACKNOWLEGEMENT

I owe my thanks to the Dean, Govt. Stanley Medical College and Hospital, **Dr. M.VASANTHA, M.D.,** for allowing me to avail the facilities needed for my dissertation work.

I feel a sense of gratitude towards my respected professor, an excellent teacher and master surgeon Prof. R.Surendran M.S; MNAMS; M.Ch. I sincerely remember Prof. R.Surendran who carved out a surgeon from me like a sculpture, brought me to an accountable level by sprinkling his knowledge throughout my studentship under him. This entire study is outcome of his most kind, sympathetic and learned guidance without which I could not have endeavoured on a subject.

I deem it an honour to acknowledge my greatfulness to Dr. D.Kannan M.Ch, Dr. T.G. Balachandar F.R.C.S; M.Ch, Senior Assistant Professors of Surgical Gastroenterology for their healthy criticism and being a source of constant inspiration to me at all stages of this work.

I am sincerely thankful to Dr. S.Jeswanth M.Ch, Dr. S.Rajendran M.Ch, Dr.P.RavichandarM.Ch, Dr.Jothibasu, M.S., Assistant Professors of Surgical Gastroenterology for his constant encouragement, able guidance, valuable help, everreadiness to solve my problem arising unexpectedly at any time.

Last but not the least, my sincere thanks to all the patients who cooperated knowingly or unknowingly with me for this study, without whom this study could not have been possible.

CONTENTS

ACKNOWLEDGEMENT

I feel a sense of gratitude towards my respected professor, an excellent teacher and master surgeon Prof. R.Surendaran M.S; MNAMS; M.Ch. I sincerely remember Dr.R.Surendran who carved out a doctor from me like a sculpture, brought me to an accountable level by sprinkling his throughtout my studentship under him. This entire study is out come of his most kind, sympathetic and learned guidance without which I couldnot have endeavoured on a subject.

I deam it an honour to knowledge my greatfulness to Dr. D.Kannan M.Ch, Dr. T.G. Balachandar F.R.C.S; M.Ch, Assistant professor of Surgery for his healthy criticism and being a source of constant inspiration to me at all stages of this work.

I am sincerely thankful to Dr. S. Jeswanth M.Ch, Dr. S. Rajendran M.Ch, Dr. P. RavichandarM.Ch, Dr. Jothibasu M.S, consultant Gastroenterologist for his constant encouragement, able guidance, valuable help, everreadiness to solve my problem arising unexpectedly at any time.

At last, I am extreamly thankful to the patient and all who knowingly or unknowingly have helped me in the preparation of this dissertation work.

INTRODUCTION

Aneurysms of visceral arteries are unusual, although they have been reported with increasing frequency in recent years. Their prevalence has been estimated at 0.2%-1%[1,2] in the general population. Splenic artery aneurysms (SAAs) are the most common type (60%)[3] followed by hepatic(20%)[1,3]; superior mesenteric (5%)[4]; celiac trunk (4%)[5]; smaller celiac branches (gastric, pancreaticoduodenal, and gastroepiploic) (4%)[6,7]; and jejunal, ileal, and colic arteries(3%)[8] **[Fig.1]** .

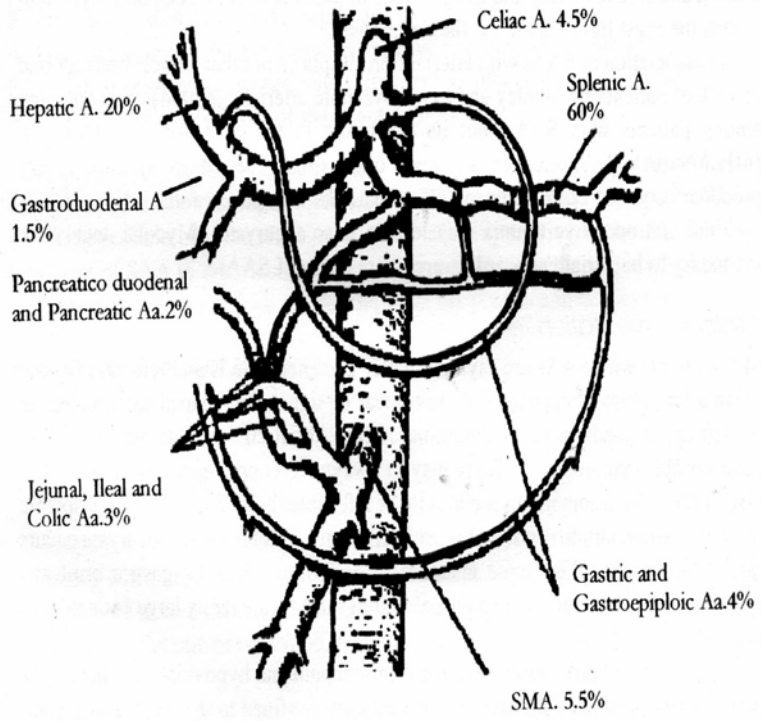

FIG 1. Incidence and distribution of splanchnic arterial aneurysms

They are clinically important because of the high complication rate associated with their rupture.Aetiological factors include atherosclerosis, trauma, surgery,

inflammation, infection and congential anomalies. These lesions are traditionally treated primarily by surgical means, but with the advent of newer imagining modalities, trans-catheter embolization is now emerging as a safe procedure[9]. A gastrointestinal surgeon is likely to encounter aneurysms of splanchnic vessels in one of the following situations:(1). Incidental discovery of an aneurysm of a visceral artery or vein;(2). A false aneurysm of visceral artery as a consequence of adjacent gastrointestinal pathology;(3) .A gastrointestinal complication of an abdominal aneurysm.

Splenic artery aneurysm(SAA) are the most frequent type, accounting for 60% of all splanchnic artery aneurysms[10]. Although giant aneurysms, defined as greater than 2.5 cm in greatest diameter, are rare, they have been reported[11].The major risk of SAAs and pseudoaneurysms is hemorrhage. Early literature demonstrated a falsely elevated risk for rupture as a result of under detection of SAAs[12]. More recent data suggest that the risk ranges from 3% to 10% and is higher for giant SAAs. The mortality rate after rupture has been estimated at 10% to25%[12,13]. Hemorrhage from spenic artery pseudoaneurysms has been reported in an many as 37% of patients[14].Given the risk for rupture, guidelines recommend resection of symptomatic SAAs, asymptomatic aneurysms larger than 2.0 cm, and all pseudoaneurysms, to avert rupture[15]. Pancreatitis with secondary pseudocyst formation is the most common cause of pancreatic pseudoaneurysms, although they are known to occur in the absence of a pseudocyst. Pancreatic or peripancreatic bleeding is one of the formidable and life-threatening complications of pancreatitis. The standard of care in dealing with pseudoaneurysms has been surgical intervention; however, many interventional radiologists have reported excellent outcome after angio- embolization.

Hemobilia (bleeding into the biliary tree) is a rare of condition that may be difficult to recognize but it is none the less important to include it in the differential diagnosis of gastrointestinal bleeding.

Hemorrhage into the pancreatic duct (Hemosuccus pancreaticus) causes bloods to flow through the duct and papilla into the duodenum. Hemosuccus pancreaticus is a rare clinical entity that poses considerable diagnostic and therapeutic challenge and should be considered in the differential diagnosis of any patient with obscure upper gastrointestinal bleeding[16]. Hemosuccus pancreaticus most commonly occurs in association with chronic pancreatitis and the formation of pseudoaneurysms in peripancreatic arteries.

AIM OF STUDY:

- To analyze the varied clinical presentation of bleeding visceral artery pseudo aneurysms and to highlight the need for increased awareness of such a rare clinical entity and a potentially lethal complication in patients presenting with obscure / overt gastro intestinal bleeding in the background of pancreatitis, liver trauma and previous pancreatic / biliary surgery.

- To asses the central role of mesenteric angiography in the management of pseudo- aneurysmal bleed.

- To evaluate the safety, efficacy and clinical outcome of non-surgical and surgical treatment options (embolization, ligation, resection) for pseudo aneurysmal bleeding from visceral arteries with an intent to draw inferences and to setup management guide lines/protocol.

REVIEW OF LITERATURE :

PANCREATIC PSEUDOANUERYSMS :

Problem :

Pancreatic pseudoaneurysms are uncommon vascular complications of pancreatitis that has have an uncertain evolution with poor prognosis and are frequently accompanied by rupture and bleeding (1.5 to 2.4 %)[17]. The origin of pancreatic duct haemorrhage is pancreatic in 60% to 80% of the cases, usually caused by the lytic effect of the pancreatic juice[17]. This affects the wall of neighbouring vessels which may burst into adjacent pancreatic ducts directly or after formation of a pseudoaneurysm. A pancreatic pseudocyst often acts as an intermediary link and the splenic vein may also be involved. Pancreatitis may also act through the formation of ductal calculi which erode into blood vessel which account for about 30% of the cases[17]. In 20% -40% of the cases, a primary aneurysm or pseudoaneurysm of an artery close to the pancreas ruptures into the duct of wirsung, leading to massive haemorrhage[17].

Incidence:

The incidence of acute hemorrhage secondary to a bleeding pseudocyst or pseudoaneurysm ranges from 2-8%[18] but may be as high as 17%[19] and is one of the most rapidly fatal complications of pancreatitis, with an associated mortality of 12 – 37%[20] in treated patients to more than 90% in untreated patients[21,22]. Pseudoaneurysm formation in patients with chronic pancreatitis who undergo angiography may have an incidence as great as 10%[20,22]. Some of the factors associated with pancreatic pseudoaneurysms include the following:

a) Severity and duration of pancreatitis
b) Presence of pseudocyst and associated splenic vein thrombosis and endoscopically visualized varices.

The splenic artery is the most commonly affected artery (30%-50%)[23] because of its proximity to the pancreas, followed by the gastroduodenal artery (10-15%)[24] and the inferior and superior pancreaticoduodenal arteries(10%)[25,26].Other blood vessels mentioned in the literature include the superior mesenteric artery[27,28], hepatic artery[29], left gastric artery[30], gastroepiploic artery[31] dorsal pancreatic artery[32], and middle colic artery[8]. The overall incidence of gastrointestinal bleeding secondary to acute pancreatitis are reported to occur in 1.5-2.5%[18,34] of patients, 7-14% in patients of chronic pancreatitis and in 6-31% of patients with pancreatic pseudocyst[34], but the mortality rate in acute pancreatitis is high 40-80%[18,34]. The mortality accompanying bleeding pseudoaneurysms and pseudocyst in chronic pancreatitis is reported to be between 12% and 40%[18] and thus is considerably lower than that associated with hemorrhage from acute pancreatitis, where sepsis and multiple organ failure are often also present.

Etiology:

The etiologic requisites of the dysplastic and aneurysmal changes characteristic of pancreatic pseudoaneurysm formation include the following: Acinar cell necrosis and or ductal disruption with peripancreatic accumulations of exudative fluid containing activated protelytic enzymes which autodigest and weaken the arterial wall and lead to pseudoaneurysm formation[18,33]. Severe inflammation of an infected pseudocyst leading to the same sequelae. Moderate-to-severe pancreatitis with or without pseudocyst/abscess is the major etiologic factor for pseudoaneurysm formation. Pseudoaneurysm formation may occur after biliopancreatic resection for cancer. Patients who have an anastomotic leak and develop intra-abdominal abscess

may subsequently be prone to delayed arterial hemorrhage. Focal sepsis erodes through vessels and causes pseudoaneurysm formation and delayed rupture and bleeding. Pancreatic transplantation is an occasionally reported third cause of pancreatic pseudoaneurysm formation[18].

Pathophysiology:

Pseudoaneurysms form when enzyme-rich peripancreatic fluid often within a pseudocyst, leads to enzymatic auto digestion by pancreatic enzymes (trypsin, elastases, collagenases) and weakening of the walls of adjacent arteries. The histologic changes in the affected vessels include splitting of internal elastic lamina, inflammatory thrombosis of nutritive vasavasorum in the arterial wall resulting in the development of necrotizing arteritis[18,33]. These arteries then undergo aneurysmal dilatation, with the aneurysmal bulge most often contained within the pseudocyst. Rupture of the aneurysm into the pseudocyst converts the pseudocyst into a pseudoaneurysm (defined as extravascular hematoma communicating with the intra-vascular space). In some instances, a pseudocyst can erode into a nearby artery, causing the conversion of pseudocyst into a pseudoaneurysm. A pseudocyst may erode the wall of the bowel with bleeding from from the mucosal surface inself. The pseudoaneurysm may then rupture into the pancreatic ductal system causing hemorrhage into the bile duct and hemobilia. the pseudoaneurysm may also rupture into the free peritoneal cavity or into the gastrointestinal tract[18,33].

Clinical Presentation:

Because pancreatitis is the most common underlying cause of pancreatic pseudoaneurysm, most patients are males with alcoholism (80-90%)[18,33] who have histories of episodic chronic pancreatitis and secondary pseudocyst formation. The diagnosis of visceral artery pseudoaneurysm should be considered in any patient with a pseudocyst and a significant abdominal bruit[18,33]. The pseudoaneurysm tends to enlarged when subjected to sufficient intracystic pressure and ultimately ruptures into the gastrointestinal tract, biliopancreatic ducts, pseudocyst, peritoneal cavity, or retroperitoneum[18,33].

Although highly variable, clinical symptoms are very suggestive and include the following:

a) Anemia of unexplained cause.
b) Recurrent or intermittent hematemesis or hemotochezia in patients who have pancreatitis, particularly when due to chronic alcohol abuse or trauma .
c) Rapid enlargement of a pseudocyst or a pulsatile abdominal mass, especially in the presence of abdominal bruit and hyperamylasemia.
d) The syndrome known as hemosuccus pancreaticus, characterized by bleeding from the ampulla of Vater, colicky pain, and jaundice[18,33].

Patients with pancreatitis may have the following symptoms:

I. Persistent or abrupt increase in abdominal pain. The acute onset of pain is thought to be caused by rapid dilatation of the pancreatic duct by bleeding, with resultant elevation of intraductal pressure. As the intraductal pressure exceeds the pressure of the blood vessel, it leads to

tamponade of the pseudoaneurysm and temporary cessation of bleeding occurs and the patients conditions stabilizes. The clot is then lysed a variable time later and the cycle repeats itself[16]. This process might recur infrequently over months to years or there may be an unrelenting deterioration and life threatening haemorrhage.

II. Decreasing hematocrit values and / or hemodynamic instability and or gastrointestinal bleeding with no obvious intraluminal cause.

The clinical picture may vary widely. The most common form of bleeding is probably rupture into a pseudocyst with eventual bleeding through the pancreatic duct and, subsequently, the ampulla of Vater if the pseudocyst is connected with the pancreatic duct. This "wirsungorrhagia" (ie, hemosuccus pancreaticus)[35] manifests as intermittent pain caused by sudden filling with blood and resultant distension of the pancreatic duct and may sometimes be accompanied by elevated levels of pancreatic enzymes. Once the intraductal pressure reaches a certain level, the bleeding stops a clot forms. The clot subsequently lyses at a later stage, leading the cycle to repeat itself. On the other hand, if the pseudocyst does not communicate with the duct of Wirsung, then blood accumulates in the pseudocyst, leading to sudden enlargement and causing abdominal pain and a drop in the hematocrit value[18,33].

Diagnostic evaluations:

Upper gastrointestinal endoscopy should be the initial investigation in order to rule out the more common non-pancreatic causes of gastrointestinal bleed particularly in alcoholic patients[35]. The CT finding of contrast enhancement within or adjacent to a non-enhancing pseudocyst is highly suspicious of pseudoaneurysm[32,36]. The finding of

increased attenuation within a fluid collection on a non-enhanced scan is also suspicious, indicating recent hemorrhage into pseudocyst[20,36]. Intravenous bolus injection of contrast medium during scanning defines a rapidly enhancing mass within a non-enhancing pseudocyst[36]. The pattern represents free-flowing blood surrounded by low-attenuation thrombus and is demonstrated in 80% of such patients[20,36].

Computed tomography may also demonstrate less specific findings, such as intraperitoneal or extra-peritoneal blood or splenic hematoma. The use of oral contrast should be avoided, so as not to interfere with subsequent visceral arteriography[18]. Intra-abdominal hemorrhage is easily identified by CT imaging as high- attenuation (40-50 HU) heterogenous fluid collections that may have fluid-fluid levels and may even exhibit evidence of extravascular extravasation of contrast material. Pseudoaneurysms present as sharply defined, I-contrast filled, round or oval lesions along or adjacent to a peripancreatic artery[36]. Contrast enhanced Dynamic / Helical CT is the best non invasive diagnostic modality for pancreatic arterial pseudoaneurysm with a reported sensitivity of 80-100%[37-38].

Ultrasound examination of a patient with a past history of pancreatitis should include pulsed or Colour Doppler interrogation of all cystic masses in or adjacent to the pancreas so as to distinguish a pseudocyst from a pseudoaneurysm[20]. Ultrasonography has the advantages of being portable and non-invasive, and the addition of Color Doppler permits conclusive demonstration of arterial blood flow within cystic lesions[20,36]. This may provide specific diagnosis and identification of the artery involved.

Angiography is currently the gold standard for diagnosing pancreatic pseudoaneurysm[32,39] except in situation of rapid clinical deterioration that mandates

immediate operative intervention. In hemodynamically stable patients, Contrast enhanced Helical /Dynamic CT followed by immediate celiac/ mesenteric angiography should be done to confirm the diagnosis[18]. Angiography defines the character-unique or otherwise-of the lesion and allows therapeutic planning. Angiography greatly facilitates identification of the location and serves as a topographical guide for the pseudoaneurysm, which aids in operative proximal and distal control of the bleeding vessel[32]. Preoperative angiography might constitute an opportunity to gain temporary control over the bleeding vessel by performing trans-catheter embolization, thus providing a time window for the surgeon to operate on a high-risk patient under optimal clinical conditions[40]. In patients with gastrointestinal or intraabdominal hemorrhage that is refractory to resuscitative measures, time-consuming efforts to establish an exact anatomical or etiologic diagnosis are detrimental and the only procedure should be immediate laparotomy and surgical exploration[18]. Fortunately, most patients with pancreatic hemorrhage can be stabilized, atleast temporarily, thus affording an opportunity for more precise pre operative diagnosis and possible potable non-operative control of the bleeding vessel[18]. In all such patients, the most important diagnostic procedure is immediate coeliac / superior mesenteric arteriography[18].

Review of the surgical and radiological literature indicates that, among 213 patients with pancreatic hemorrhage who underwent complete angiographic examination, 201 or 94% had accurate identification of the bleeding lesion. Thus, arteriography is extremely sensitive in confirming the diagnosis of pancreatic hemorrhage and in identifying the vessel responsible. It should be the initial and only imaging study in patients strongly suspected of having major hemorrhage secondary to pancreatitis and its sequelae[18]. Very small pseudoaneurysms remain a special problems because their size is beyond the spatial re solution of noninvasive imaging.

The incidence of these tiny arterial lesions are exceedingly low: according to white et al[41]. Very small pseudoaneurysms comprise 20% of all pancreatic pseudoaneurysms, with a prevalence of patients with chronic pancreatitis. In these circumstances, arteriography remains the only diagnostic tool capable of determining the source of the GI bleeding. However, indication for arteriography is usually dictated by the recurrence of hemorrhage and clinical symptoms[42].

Non-Surgical therapy:

Although occasional reports have alluded to the spontaneous thrombosis of some pancreatic pseudoaneurysms, the current consensus holds that all these malformations should be treated to prevent the complication of bleeding[317,32]. Nonsurgical management consists of trans-catheter arterial embolization with or without endoscopic stent placement[18,32] Simple pseudoaneurysms (i.e., those unrelated to pseudocysts) are effectively treated with embolization, with good results at long term follow-up regardless of the location of the pseudoaneuyrsm[43] . Angio-embolization is considered much less invasive than surgery. The procedure can be completed quickly and is comfortable for the patient. It also allows the performance of surgery under optimal conditions. Recent reports have shown that percutaneous angiographic embolization may be the therapy of choice with high technical success rates of 67% to 100%[39,87], low morbidity rates of 14% to 25% and death rates of 0% to 14%[32,38,42,44]. Most authorities agree that embolization is appropriate when bleeding is diffuse or emanating from the pancreatic head, for unsuccessful surgery or during postoperative bleeding[18].

Trans-catheter embolization should always be attempted immediately following angiographic demonstration of the bleeding vessel of pseudoaneurysm. As multiple pseudoaneurysms may be present in 10% of patients, complete visualization of the celiac and superior mesenteric arteries and their branches is mandatory[18]. Selective catheterization of the appropriate artery is then undertaken, with the intent of occluding it first distal and then proximal to the bleeding site or lesion[32,39]. In some instances, occlusion of the actual defect in the wall of the artery is made possible by the presence of a narrow-necked pseudoaneurysm. In cases of small pseudoaneurysms, the entire lumen can be filled with embolization material. Ideally, the technique of angiographic embolization is aimed at direct occlusion of the pseudoaneurysm by placement of steel micro coils within the neck of the lesion using coaxial super selective micro catheters. If the pseudoaneurysm cannot be reached, all feeding vessels should be occluded with micro coils[32,39,43,45]. A wide variety of materials have been to perform trans-catheter embolization, including wire coils, detachable balloons, gelatin sponge, autologous blood clot, polyvinyl alcohol particles, tissue adhesive, and biological glues[18,39,42]. The overall complications rate for trans-catheter embolization for pancreatic hemorrhage has been reported to be between 3% and 18% with the major risks including pancreatitis, pancreatic necrosis, splenic infarction, bowel ischemia, infection and contrast-induced acute renal failure[18,39,42] . Review of 125 cases reported in the literature indicated a failure rate of embolization of 24% and an overall mortality rate of 10%[18]. Failure results from an inability to selectively catheterise the bleeding vessel or the misplacement or poor placement of embolization material. In addition to rebleeding, complication of this

procedure includes rupture of the pseudoaneurysm during embolization, arterial perforation by the catheter, intestinal necrosis, and aortic thrombosis[42].

Surgical therapy:

Most patients with acute hemorrhagic pancreatitis respond to resuscitative measures with intravenous fluid infusion and transfusion of red blood cells and blood components. The very few with exsanguinating hemorrhage refractory to resuscitation require expeditious laparotomy and direct operative control of bleeding from a major artery[18]. The vast majority of such pancreatic have extensive pancreatic necrosis, with or without pancreatic abscess or infected necrosis. The operative approach is inevitably difficult. Because of inflammatory adhesions, phlegmonous swelling of the pancreas, and tissue hyperemia and friability, all of which obscure the bleeding source and distort the vascular anatomy[18,19,45]

Successful vascular control may require debridement or necrosectomy of pancreatic and peripancreatic tissue, drainage and exploration of abscess cavities, and occasionally, removal of other involved organs, such as the stomach, transverse colon, or spleen[46]. Although ideal, in most instances a clean dissection and accurate proximal and distal ligation of the bleeding vessel are technically not possible, because of inflammatory swelling. Therefore, direct suture ligation of the active bleeding site frequently must be relied upon. Partly as a consequence of the surgical exploration, bleeding sites are often multiple and complete control is extremely difficult to achieve. If during operation the patient becomes hypotensive, hypothermic, coagulopathic, or severely acidotic, packing of the bleeding area should be accomplished as quickly as possible, once all obvious arterial bleeding is

controlled[18]. The operation is then terminated with packs left in place. Such patients should be taken to the intensive care unit for volume restoration, rewarming and correction of acidosis and coagulopathy and the returned to the operating room in 24 to 48 hours in the removal of packs, further exploration and suture control of residual bleeding sites, and repacking or wide drainage of the retroperitoneum as required. The overall mortality rate associated with such heroic surgery as the sole treatment modality has been nearly 90%[18] .

In 1986, the efficacy of combined angiographic and surgical management of massive arterial hemorrhage in patients with acute pancreatitis was documented by investigators from the Massachusetts General Hospital[18]. Among 10 patients treated by the combined approach, complete hemostasis was achieved by embolization in six patients and the survival rate for the entire group was 40%. These results were distinctly superior to those previously obtained by surgery alone in these extremely high-risk patients[18]. In a recent review of 57 cases of massive bleeding in acute pancreatitis collected from the literature, the mortality rate was only 25% among 32 patients treated by embolization techniques[18,47]. It appears emergency arteriography with trans-catheter embolization offers the best hope for life-saving control of exsanguinating hemorrhage complicating acute pancreatitis[32,47].

Emergency exploratory laparotomy is always indicated once the diagnosis of bleeding pseudoaneurysm is confirmed arteriographically, or it is entertained in the case of hemodynamic instability caused by an exsanguinating hemorrhage that obviates the need for angiography. A major controversy concerns the best approach to control the bleeding. Arterial ligation on both sides of the bleeding sites, pancreatic resection, and intracystic / extracystic multiple ligatures are all suggested therapies.

Some pseudocyst drainage procedures have been frequently performed concomitantly with the primary hemostatic surgery[18].

Pre operative details:

The patient's hemodynamic status and co-morbid medical issues dictate the necessity for invasive hemodynamic monitoring. If the diagnosis of a ruptured pseudoaneurysm has been seriously entertained and the patient is haemodynamically stable, performing a pre operative angiogram has several benefits[32,39,47]. Identifying the bleeding vessels during surgery is difficult because of the friability, necrosis and severe inflammation caused by pancreatitis. Also because pre operative angiography identifies the bleeding vessel, it might dictate the optimal therapy. Performing arterial ligation or pancreaticoduodenectomy on bleeding vessels involving the pancreatic head has been demonstrated to carry a high mortality rate[18].

Intra operative details:

Multiple effective measures to gain rapid control of the actively bleeding pseudoaneurysms include manual tamponade, gauze packing, digital compression of the bleeding pseudoaneurysm or pseudocyst, and even supra celiac infradiaphragmatic cross-clamping of the aorta for brisk bleeding. Institute these measures especially in the actively bleeding haemodynamically unstable patient, while aggressive volume resuscitation is being undertaken by anaesthesia team[18,34]. Exposure of the bleeding can sometimes be challenging because the surrounding inflammation from pancreatitis obscures the visual field. Several adjunctive techniques have been listed to gain operative access to the bleeding pseudoaneurysm; these include Prepyloric gastrotomy, duodenotomy and major gastrectomy[18,34]. Once bleeding vessels identified

the surgeons may perform intracystic ligation without proximal/distal control or resection is not recommended because the friable tissues of the posterior pseudocyst wall do not hold sutures, and the feeding vessel that lies deep within the substance of the pancreas is still patent[18,34,68].

Post operative details:

The occurrence of post resectional hemorrhage is well documented in the literature, with a reported incidence of 5-19% and the mortality rate of 6-58%[18,34]. This may be the result of ongoing pancreatitis, continuous damaging of the arteries, iatrogenic trauma to the vessels, and/or inadequate control of the bleeding vessels. Some surgeons advocate surgical ligation of the bleeding vessel in the nonseptic patient and pancreatic resection those with abscess or established fistula[35], where as interventional radiologist strongly recommend angioembolization of postoperative hemorrhage[32,39].

Complications of pseudoaneurysms:

The frequency of arterial hemorrhage during pancreatitis varies from 5-10%. However, when pseudocysts are present, the bleeding rate rises to 15-20% of the cases[34,45]. The most common site of rupture is intracystic, and the incidence of spontaneous hemorrhage arising from a pancreatic pseudocyst reportedly ranges from 1.4-8.4%[34]. Other sites of rupture include the bilio-pancreatic duct, peritoneal cavity, retroperitoneum, and sometimes direct erosion into the duodenum and other parts of the gastrointestinal tract. Hemorrhage is a significant complication that carries a mortality rate of 13-40% and is almost always fatal if left untreated[18,34].

Outcome and prognosis:

The mortality rates following surgical treatment for arterial hemorrhage of pancreatic origin ranges from 28-56% and 12-64% according to the patient's clinical status, anatomic location of the pseudoaneurysm and site of bleeding, but not related to the surgical method[32,45,49]. Surgical intervention for treatment of pseudoaneurysm in the head of pancreas has a 43% mortality rate but only a16% mortality rate in the body or tail of the pancreas[18,34]. Patients treated with supportive measures have more than 90% mortality rate[18,]. The mortality rate with postoperative hemorrhage is nearby double (50-60%)[18]. For pseudoaneurysm in the head of pancreas, the surgical approach necessitates a whipple procedure, which likely contributes to the higher mortality rate. Embolotherapy has a high initial success rate of 90-100%[32,39,43], although some reports indicate a recurrence rate of 17-37%[50] and an overall mortality rate of 16%[40]. Embolotherapy is the preferred initial therapy for bleeding originating from the head of the pancreas[39,43].

Future and controversies regarding the operative management of bleeding pancreatic pseudocysts and pseudoaneurysms**:**

The major controversy surrounding the operative management of the bleeding pseudoaneurysm is whether to perform arterial ligation or pancreatic resection[18,38,47,49,51]. Proximal and distal arterial ligation is often technically difficult to accomplish, because of inflammatory changes and anatomical distortion. When effected , however, it usually achieves the goal of thrombosis of the bleeding site, equivalent to that obtained by proximal and distal trans-catheter embolization. It particularly useful in cases of splenic artery hemorrhage but distinctly more difficult

to accomplish when bleeding is from the head of the pancreas, where the extensive collateral circulation exists. Intracystic suture ligation is a less reliable means of achieving complete control and is attended by the higher bleeding rates of 50-75% in some reported series[18,45,49] . It should be augmented by extracystic arterial ligation whenever possible. For larger bleeding pseudocysts, the addition of some type of internal or external drainage is required to reduce the incidence of postoperative infection and abscess formation[49]. Distal pancreatectomy is relatively more easily accomplished and has been associated with a lower operative mortality than has pancreatoduodenectomy for bleeding from the head of the gland[18,47,49]. Review of 153 cases reported in the literature wherein the site and method of hemorrhage control were identified reveals the overall operative mortality rate for bleeding from the body and tail of the pancreas to be 12% compared 24% for bleeding from the head of the gland[18]. Another major controversy is whether transarterial catheter angioembolization should be the definitive approach or if it should always be followed by surgical intervention, especially if bleeding is located in the tail or body of the pancreas and/or is associated with a pseudocyst. A third controversy is the management of postoperative bleeding despite recent adoption of the operative option by more health care providers. A recent article describes the clinical success of ultrasound guided percutaneous thrombin–collagen injection into the pseudoaneurysm for treating splenic artery pseudoaneurysm in the background of chronic pancreatitis. [52]

HEMOBILIA :

Problem:

Hemobilia is a rare condition that is difficult to recognize and there fore a high index of clinical suspicion is needed for early diagnosis in patients presenting with obscure gastro intestinal bleeding particularly in the setting of liver trauma and following biliary tract surgery. Haemobilia occurs when there is a fistula between a vessel of the splanchnic circulation and the intrahepatic or extrahepatic biliary system[53]. In 50% cases of hemobilia, bleeding originates from the liver parenchyma, whereas the biliary ducts and the gall bladder are the source in approximately 45% of the cases. Hemobilia, due to pancreatic disease is rare[54].

Clinical presentation :

Quinke[53,55] described a triad of symptoms and signs with which haemobilia usually presents. These are upper abdominal pain, upper gastrointestinal bleeding and jaundice. All three may be present in up to 22 % of patients[53]. The bleeding may be rapid onset following liver trauma, or may be delayed by weeks. Occasionally it may be recurrent, with a prodrome of epigastric discomfort that is relieved at the onset of upper gastrointestinal bleeding. Previous reviews have found that 50 % of bleeding into the biliary tree in intrahepatic; the other 50 % is mostly from the extra hepatic bile ducts or gallbladder and rarely the pancreas[53,56]. The bleeding may be so rapid that the blood passes directly into the duodenum, appearing as haematemesis or melaena following erosion of hepatic artery pseudoaneurysm into the biliary tree[53].

Aetiology :

Trauma is by far the most common cause of hemobilia accounting for 50% of the cases[54]. The most commonly reported causes of haemobilia are iatrogenic trauma mostly as a consequence of biliary surgery or accidental liver trauma. Surgical exploration of the biliary tree for biliary stones may also cause haemorrhage as the intrahepatic ducts are in close proximity to the hepatic arteries[53,56]. Surgery of the hepatobiliary system may lead to haemobilia following injury to a hepatic artery by a suture needle, diathermy, clip or clamp. A pseudoaneurysm developing around the damaged vessel is the common lesion preceding the onset of haemobilia and the presentation may be delayed by many weeks. The incidence of haemobilia following major liver injury has been reported to be as high as 3 %[53].

Investigation :

For patients with upper gastrointestinal bleeding, oesophago-gastroduodenoscopy (OGD) is the first investigation of choice. If blood or clot is seen at the papilla of Vater, haemobilia is likely to be the cause of the bleeding. However as few as 12 % of these endoscopies may be diagnostic and further investigation may be required[53,56]. Many patients with haemobilia will have CT performed at some point, particularly those with blunt abdominal trauma, and further evidence of active or recent bleeding into the biliary tree and gallbladder may be identified by pooling of contrast medium, intraluminal clots and biliary dilatation[57,58]. Various risk factors for developing haemobilia can also be identified including cavitating lesions and pseudoaneurysms[53]. On Ultrasonography of the liver, immediately following a bleed into the biliary tract, with the formation of clot from 24 – 48 hours, a soft tissue mass may be seen, filling part of the duct with dilatation of the proximal duct with high echogenicity similar to that of the liver. Pseudoaneurysm of the hepatic arteries may be noted as well circumscribed anechoic masses; although they are not necessarily pulsatile. Doppler ultrasonography may show flow within it differentiating it from biloma or cyst[59]. Angiography is now recognized as the gold standard for confirming the site and aetiology of haemobilia[65]. Angiography can detect a vascular abnormality in over 90 % of cases of significant haemobilia as well as it can detect active bleeding from arteriobiliary fistula, arterioportal fistula and pseudoaneurysm[53,60]. There is a role for scintigraphy in the investigation of suspected haemobilia only if other investigations have proved normal[53].

Management :

The management of haemobilia is directed at stopping bleeding and relieving biliary obstruction. Trans-catheter arterial embolization(TAE) is indicated for those cases of major haemobilia requiring blood transfusion, if bleeding is prolonged or recurs despite correction of coagulopathy, and in cases of minor haemobilia causing anaemia[61-63]. It is also indicated if CT or ultrasonography indicates vascular injury. Surgery is indicated when TAE has failed, for cholecystitis, when there is hepatic and biliary sepsis and for failure to drain the biliary tree[62]. Surgery for bleeding involves ligation of the bleeding vessel or excision of the pseudoaneurysm. If haemorrhage from collateral vessels continues even after ligation of the common hepatic artery, resection of the affected liver segment (partial hepatectomy) may be necessary[64].

BLEEDING VISCERAL ARTERY PSEUDOANEURYSMS FOLLOWING PANCREATODUODENECTOMY :

Problem :

Pancreatic anastomotic leak, extensive surgical dissection during whipple's procedure with an intent to remove all neural and lymphatic tissue around hepatic arteries, sometimes results in life threatening complication of arterial hemorrhage with a mortality rate of 20 – 50 %[66,67].

Etiopathogenesis:

There are four predisposing factors for the formation of pseudoaneurysms after hepatobiliary pancreatic surgery. The first is leakage of pancreatic juice, intestinal juice and/or bile, which erodes the arterial wall by trypsin and elastase[18,33]. The second is localized infection and abscess formation in intra- abdominal space after surgery .The third is intraoperative injury of a small artery, especially during lymph node dissection. The fourth is a post operative intraabdominal haematoma that

fails to resorbe may serve as a nidus for infection near a peripancreatic vessel and form a pseudoaneurysm[69,70-73].

Pseudoaneurysm can develop in the gastroduodenal artery or the hepatic artery after hepatobiliary pancreatic surgery and also in intrahepatic branches of the hepatic arteries after surgery. These pseudoaneurysms present with hemorrhage as a late postoperative complication 2-10 weeks after surgery , as shown in the study by Rumstadt et al[72]. Brodsky and Turnbull[67] have reported that sentinel bleeding indicates local recognition of its significance and prompt response may prevent exsanguination.

Clinical presentation :

Majority of patients present with a warning minor sentinel bleed either via: the abdominal drains or gastrointestinal tract followed by massive arterial hemorrhage[69]**.**

Diagnostic evaluation :

Endoscopy is usually employed as the first diagnostic procedure in patients with minor sentinel bleed. Angiography is the first-step diagnostic method in patients with major arterial hemorrhage after pancreaticoduodenectomy[69]. Ultrasonography findings can be misinterpreted as hematomas where as dynamic CT are diagnostic of extrahepatic pseudoaneurysms[74].

Management :

Percutaneous trans-catheter super selective coil embolization is the initial treatment of choice as it can achieve temporary control of massive hemorrhage with a success rate of 63-79 %[69] and allows hemodynamic stabilization in the majority of cases and prevents the need for high risk emergency surgery. Surgery should be reserved for patients with uncontrolled intra-abdominal sepsis to avoid a possible recurrent bleeding[69]. During relaparotomy it will be technically difficult to reach the site of bleeding pseudoaneurysm because the tissues are edematous, friable and the tissue places are difficult to dissect owing to dense adhesions[69,72].

PATIENTS AND METHODS:

During the period between January 1998 to August 2005, 16 patients with bleeding visceral artery pseudo aneurysms were recognized and treated at our center for gastro intestinal bleed and division of Hepato biliary- pancreatic diseases, Department of surgical gastroenterology, Government Stanley Medical College and Hospital, Chennai-1. Of the 16 patients, 12 (75.0 %) were males with the median (range) age of the group was 40 (18-53) years; 4 (25.0 %) were females with the medium (range) age of 34 (12 – 40) years. The male: female ratio being 5.5: 2. Of the cohort of 16 patients, one developed pseudo aneurysmal bleeding during the course of severe acute alcoholic pancreatitis, 3 as a complication of chronic pancreatitis, 7 as a complication of pancreatic pseudocyst, two as a complication of laparoscopic cholecystectomy, two as a complication of blunt liver trauma and one as a complication of whipple's pancreatoduodenectomy. Data were recorded on demographic characteristics, co-morbid conditions, mode of clinical presentation, etiology, pseudo aneurysm characteristics, investigations, angiographic diagnoses and interventions, surgical interventions and final outcome including morbidity and mortality. The principal outcome measures were varied modes of clinical presentation, results and diagnostic yield of selective celiac / mesenteric angiography, efficacy and clinical outcome of therapeutic angiographic embolization and surgical interventions including their overall outcome. Demographic data are presented as median (range) unless otherwise indicated. Data for statistical comparison are presented as median (95 % confidence interval). The study population were outlined in tables1-5.

Table -1. PATIENTS TREATED WITH SURGERY AS FIRST LINE DEFINITIVE THERAPY WITHOUT PRIOR ANGIOGRAPHY: [Patients considered unsuitable for angioembolization] (n = 5)

Patient No.	Age Yrs	Sex	Disease Status	Pseudoaneurysm Size	Vessel	Operative procedure
Case 1	40	M	CP	7 cm	SA	Distal pancreatectomy
Case 2	42	M	CP	8 cm	SA	Distal pancreatectomy
Case 3	40	F	Blunt liver trauma	5 cm	RHA	Right hepatectomy
Case 4	32	F	Post Lap. Chole RHA – injury	9 cm	RHA	Suture repair of bleeding vessel
Case 5	47	M	AP	10 cm	MCA	RHC and external drainage

CP – Chronic pancreatitis, SA – Splenic artery, RHA – Right hepatic artery, RHC – Right hemicolectomy, MCA – Middle colic artery, Lap. chole – Laparoscopic cholecystectomy

Table – 2. PATIENTS TREATED WITH ANGIOGRAPHIC EMBOLIZATION AS FIRST LINE DEFINITIVE THERAPY (n=4)

Patient	Age Yrs	Sex	Disease Status	Pseudoaneurysm Size	Vessel	Embolic material	outcome
Case 6	31	M	CP	3 cm	GDA	Microcoils	Successful
Case 7	36	F	Post Lap. Chole	2 cm	RHA	Tungsten coils	Successful
Case 8	43	M	CP	2 cm	IPDA	Microcoils	Successful
Case 9	39	F	CP	2.5 cm	SPDA	Microcoils	Successful

CP – Chronic pancreatitis, GDA – Gastroduodenal artery, RHA – Right hepatic artery, IPDA – Inferior pancreaticoduodanal artery, SPDA – Superior pancreaticoduodenal arcade, Lap. chole – Laparoscopic cholecystectomy

Table -3.PATIENTS TREATED WITH SURGERY AS SECOND LINE THERAPY FOR UNSUCCESSFUL/FAILED ANGIOGRAPHIC EMBOLIZATION : (n = 5)

Patient	Age Yrs	Sex	Disease Status	Pseudoanerysm Size	Vessel	Operative procedure
Case 10	18	M	CP	8 cm	SA	Central pancreatectomy
Case 11	39	M	CP	9 cm	SA	Intracystic ligation
Case 12	12	F	CP	3 cm	SA	Distal pancreatectomy
Case 13	37	M	Blunt liver trauma	7.5 cm	RHA	Right hepatectomy
Case 16	53	M	Post-whipple PD	8 cm	HAP	Proximal arterial ligation

CP – Chronic pancreatitis, SA–Splenic artery, RHA – Right hepatic artery, PD – Pancreaticoduodenectomy, HAP – Hepatic Artery Proper

Table-4. PATIENTS TREATED WITH SURGERY AS SECOND LINE THERAPY FOR REBLEEDING AFTER EMBOLIZATION (n = 1)

Patient	Age Yrs	Sex	Disease Status	Pseudo aneurysm Size	Vessel	Embolic Material	Outcome of Embolization	Operative Procedure
Case 14	53	M	CP	7 cm	GDA	Micro Coils	Rebleeding	Intracystic ligation

CP – Chronic pancreatitis, GDA – Gastroduodenal artery.

Table-5. PATIENTS TREATED WITH SURGERY AS SECOND LINE THERAPY FOR SEPTIC COMPLICATION AFTER SUCCESSFUL ANGIOGRAPHIC EMBOLIZATION : (n = 1)

Patient	Age Yrs	Sex	Disease Status	PA Size	Vessel	Embolic Material	Outcome of Embolisation	Operative Procedure
Case 15	51	M	CP	8cm	SA	Autologous blood clot + Gelfoam	Infection of thrombosed PA, No Rebleed	External drainage

CP – Chronic pancreatitis, SA – Splenic artery, PA – Pseudoaneurysm

STUDY DESIGN:

A collective retrospective survey of a cohort of 16 patients treated in a single institution with bleeding as vascular complications of pancreatic inflammatory disease, liver trauma and following pancreatic/biliary surgery.

Inclusion criterion was the diagnosis of a pseudoaneurysm by means of Helical Computed Tomography (CT), Conventional angiography, CT angiography, Color Doppler Ultrasonography, Endoscopy or intra-operative findings. True aneurysms and renal artery pseudoaneurysms were excluded from the study. All available hospital medical records, imaging study reports and pathology reports were examined. Clinical follow up was complemented by review of the medical records and telephone contact with the patient and family or primary care physician.

All patients had blood investigations performed which comprises a full blood count, renal function tests, blood sugar and serum electrolytes and a liver function profile including prothrombin time. All patients had upper gastrointestinal (G.I) endoscopy and abdominal ultrasonography. Coeliac / mesenteric angiography was performed via femoral artery access using the seldinger's technique. All patients were followed up at two weeks, one month and then at 3-month intervals for atleast one year after angiographic embolization and surgical intervention.

Terms of reference and disease description for purpose of study:

Major pseudoaneurysmal bleeding was defined as hemorrhage comprising either gastrointestinal or intra-abdominal bleeds associated with an acute drop of haemoglobin concentration by more than 2g/dl requiring transfusion of atleast four units of packed red cells within the first 24 hours and / or significant hemodynamic deterioration in an otherwise stable patient that could not be attributed to any other causes[69].

A **pseudoaneurysm** was defined as a pulsatile extravascular hematoma that communicates with an artery via a disruption of the arterial wall[71]. **Nomenclature** for description of acute pancreatitis and it's complications were according to that of the current Atlanta consensus conference classification 1992 [75] as well as for chronic pancreatitis according to those proposed in Marseille 1984 [76].

A **positive angiogram** was defined as angiographic demonstration of extravasation of contrast and or the identification of a pseudoaneurysm[77]. **Technical success** of angioembolization was defined as cessation of blood flow in the target feeding vessel as demonstrated on post-embolization angiography with complete occlusion of the lesion and no recorded rebleed within 48 hours and no recorded rebleed within 48 hours[78]. **Clinical success** of angioembolization was defined as the cessation of clinical symptoms – melena, hematemesis or hematochezia – after embolization with no re-canalization and without any further surgical intervention during the post embolization follow-up period[78].

Urgent surgery was undertaken immediately (within 6 hours of angiography), usually because of on-going hemorrhage and hemodynamic instability[79]. **Elective surgery** was defined as an operation undertaken on a hemodynamically stable patient on a scheduled basis[79].

Rebleeding was defined as a recurrent episode of bleeding from the previously identified site after a period of hemodynamic stability for atleast 12 hours[79].

Peri operative mortality and morbidity were defined as deaths and significant complications occurring during the same hospitalization or within 30 days, if patients were discharged earlier[48]**.**

Technical details of selective mesenteric angiography:

All angiographic procedures were performed by consultant (attending) interventional radiologists within 24 hours of onset of bleeding. The transfemoral route was selected in all cases in this series. Indications for angiography were either evidence of a recent major bleed (as defined above), active bleeding or both. Data are recorded on angiographic findings, the use of angiographic hemostatic methods and on procedure-related complications. When angiographic embolization was planned it was performed as close as possible to the bleeding site using 3-5 mm stainless steel fibered coils (Cook Inc, Bloomington, USA), tungsten coils (Peripheral Free Spirales, Balt, France)[BALT.SPI-2-60P] or by a combination of autologous blood clot and gel foam/gelatin sponge (Spongistan; Johnston and Johnston Medical, Skipton, UK).A 5 French C_2 Cobra [Cook, Bloomington, Ind.] (or) Simon-1 (Cordis) angiographic catheter system sufficed in 4 cases; a 3 French super-selective micro catheter (Tracker

325, Target therapeutics, Boston Scientific, Cork, Ireland) with co-axial delivery system was required in two cases because of unstable position of the catheter. Bleeding from the gastroduodenal artery was routinely treated by both proximal and distal embolization. All other vessels were embolized proximal to the bleeding point. Infusion of vasoactive drugs was not employed in this study, either to elicit bleeding or to promote hemostasis. Completion angiography was performed routinely to confirm adequate embolization. Once bleeding had stopped and the hemoglobin level was maintained, patients were discharged atleast 72 hours after embolization. Post procedure Ultrasonography was done after 24 hours to look for splenic infarcts in case of splenic artery embolization. Colour Doppler was performed to confirm occlusion of the pseudoaneurysm once in every 3 months. CT scan and CT angiography were done at the end of 6 months.

RESULTS AND OBSERVATIONS:

Age distribution:

The most common age group affected in the present series was 30 -39 years comprising 53.3 % of study population with median (range) age of 39.5 (12 – 53) years. (Fig -2)

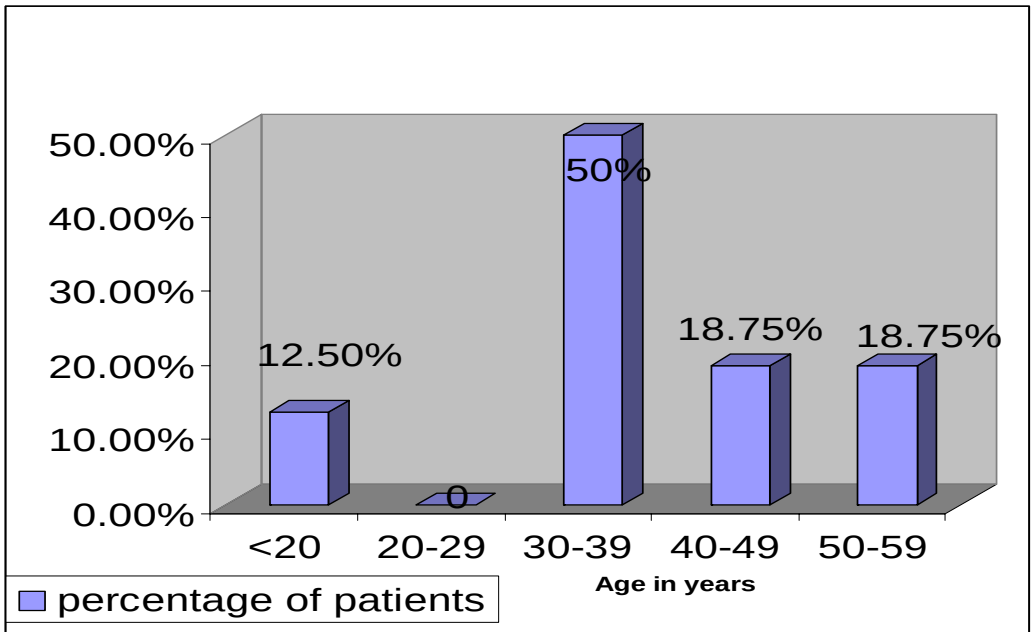

Fig.2 AGE DISTRIBUTION

Gender Distribution:

Majority of study patients were males (75.0 %) with females comprising only 25.0 %.

Demographic characteristics of patients based on disease category depicted in Table-6.

TABLE.6 DEMOGRAPHIC CHARACTERISTICS OF PATIENTS UNDER STUDY BY DISEASE CATEGORY:

Characteristic	Disease Status			Hemobilia		Post. Op after pancreato-duodenectomy
	AP	CP n = 10		Post.op after lap.chole	Post - traumatic after blunt liver trauma	
		With pseudocyst	Without pseudocyst			
No. of patients	1	7	3	2	2	1
M : F	One male	6 : 1	All males	3 : 1		One Male
Median Age (range) years	47	39 (12 – 53)	42 (39 – 51)	36.5 (32 – 40)		51

AP – Acute pancreatitis, CP – Chronic pancreatitis, Lap.chole- Lapasoscopic Cholecystectomy.

CLINICAL PRESENTAION: (Table 7)

Pancreatic pseudocysts 72.7 % (8/11) were the commonest mode of presentation of major vascular complications of pancreatitis in the present series. In the pancreatitis group, the most frequent type of clinical presentation was upper gastro intestinal bleeding (hematemesis and melaena) (9/11 (81.8%)). In the hemobilia group, the most frequent type of presentation was upper gastro intestinal bleeding which occurred in all patients (100 %) and one patient 1/4 (25.0 %) had triad of upper abdominal pain, upper gastro intestinal bleed and jaundice.

In the hemobilia group, the earliest presentation was 10 days after surgery with median (range) of 52.5 (10 – 90) days. In the post-pancreatoduodenectomy bleeding patients, the interval from initial surgery to major pseuoaneursymal bleed was 203 days. The interval from bleeding to angiography ranged from 10-24 hours with a median of 12 hours. Blood transfused before angiography / surgery in postoperative/post-traumatic bleeding group ranged from 4-10 units with a median of 4.5 units.

Table 7. VARIED CLINICAL PRESENTATION IN ALL PATIENTS WITH VISCERAL ARTERY PSEUDOANEURYSMS – CURRENT SERIES:

Presentation	Present Series (n = 16) (%)
Nausea and Vomiting	11 (68.75)
Chest pain	1 (6.25)
Back pain	11 (68.75)
Abdominal / flank pain	16 (100)
Abdominal pain and upper gastrointestinal bleed	14 (87.5)
Abdominal pain and jaundice	2 (12.5)
Hematemesis and melaena	12 (75.0)
Melaena alone	1 (6.25)
Massive gastrointestinal bleed	10(62.5)
Intermittent gastrointestinal bleed	6 (37.5)
Hemoptysis and hematochezia	1 (6.25)
Worsening anaemia	8 (50.0)
Hemobilia	4 (25.0)
Abdominal mass	7 (43.75)
Abdominal mass with audible bruit	3 (18.75)
Bleeding through persistent anterior abdominal wall sinus (post-pancreatoduodenectomy)	1 (6.25)

Laboratory investigations:
Evidence of cardiovascular compromise/ hemodynamic instability:

In the present study, the median (range) [95 % CI] serum hemoglobin prior to hemorrhage was 11.9 (10.2 – 13.3) g/dl. This fell to 7.1 (5.9 – 8.4) g/dl during the bleed. Median transfusion requirement was 7.5 (3 – 10) units of blood. Among 11 patients, 6 (54.5 %) patients had hemodynamic instability and required blood transfusion. In the hemobilia group (n = 4), the median (range) serum hemoglobin prior to bleed was 10.7 (9.6 – 11.4) g/dl. This fell to 6.3 (4.6 to 8.4) g/dl during the bleed. All patients with hemobilia presented with upper gastro intestinal bleed required aggressive resuscitation with crystalloids and blood transfusion. The median blood transfusion requirement was 5.5 (4-10) units.

Table. 8 CARDIOVASCULAR COMPROMISED / HEMODYNAMIC STATUS AND BLOOD TRANSFUSION REQUIREMENT IN PATIENTS WITH PSEUDOANEURYSMAL BLEED:

PANCREATITIS / PSEUDOCYST GROUP: (n = 11)

Parameter	Prior to bleed	During the blood (preoperative / pre-embolization period)
Serum hemoglobin level (g / dl)	11.9 (10.2 – 13.3)	7.1 (5.9 – 8.4)
Hemodynamic instability	n = 0	n = 6 (54 %)
Blood transfusion requirement median (range)	n = 0	No. of patients n = 6 (54.5 %) No. of units transfused 6.5 (3 – 10)

Table.9 HEMOBILIA GROUP: (n = 4)

Parameter	Prior to bleed	During the bleed (preoperative / pre-embolization period)
Serum hemoglobin level (g / dl)	10.7 (9.6 – 11.4)	6.3 (4.6 – 8.4)
Hemodynamic instability	n = 0	n = 4
Blood transfusion requirement medium (range)	n = 0	No. of patients n = 4 No. of units transfused 5.5 (4 – 10)

LIVER FUNCTION PROFILES:

In the pancreatitis / pseudocyst group (n = 11), one patient (case 8) jaundice and abnormal liver function tests (bilirubin level, Alkaline phosphatase level) due to a extrinsic compression of bile duct by a large infected pseudocyst at the level of

Table.10.LIVER FUNCTION PROFILES IN HEMOBILIA GROUP (n = 4)

Patient no.	S. Bilirubin (μ mol /l)	S.AST (IU/L)	S.ALT (IU/L)	SAP (IU)	Prothrombin Time	
					Control value (secs)	Test value (secs)
Case 3	26	22	20	190	16	20
Case 4	81	42	34	480	18	22
Case 7	38	30	26	210	12	16
Case 13	42	26	22	360	12	16

S. AST = Serum aspartate aminotransferase, S. ALT = Serum alanine aminotransferase, SAP = Serum alkaline phosphatase

pancreatic head and portahepatis. In the hemobilia group (n = 4), liver function profiles demonstrated a moderate increase in alkaline phosphatase (median 345 (range

190 – 480) IU; normal upto 150 IU) and mild increase in serum bilirubin level (median 59.5 (range 26 to 81) μ mol/l; normal upto 17 μ mol/l) were found to be normal levels normal upto 35 IU/L.

DIAGNOSTIC RADIOLOGIC / ENDOSCOPIC INVESTIGATIONS:

Upper Gastrointestinal (G.I) Endoscopy:

Upper GI endoscopy was performed as an initial diagnostic investigation patients (n = 15), which identified blood in the second part of duodenum in 3 (26.6 %) patients (two in hemosuccus pancreatitis group and one in hemobilia group) and in 12 (80 %) patients, endoscopic examination was found to be negative/ normal.

Abdominal Ultrasonography: (USG)

Abdominal USG was performed as an initial investigation in all patients (n = 15), but it dose not prove to be a useful diagnostic investigation to confirm the diagnosis. But it is particularly performed in patients presenting with hemobilia following blunt abdominal trauma to identify the solid visceral pathology that may have indicated the source of bleeding.

Colour Doppler Utrasonography:

Colour Doppler Ultrasonography in combination with CT angiography suggested the diagnosis of splenic artery pseudo aneurysm associated with chronic pancreatitis in one patient in the present series.

Helical Triple phase Computerized Tomography (CT):

Helical CT was performed in 12 (80 %) patients out of 15 patients under study. One of 12, in 6 (50 %) patients helical CT proved useful as diagnostic for diagnosis of pseudo aneurysms with a overall diagnostic yield rate of 40 % (6/15).

CT Angiography:

CT angiography in combination Colour Doppler USG was performed in one (6.6 %) patient out of 15 under study and it proved to be an useful diagnostic investigation in the same one patient for diagnosis of splenic artery pseudo aneurysms associated with chronic pancreatitis. Thus, CT angiography has a diagnostic yield rate of 100 % in the present series, even though it was done only in one patient.

Conventional Angiography:

Conventional angiography was performed in 10 (66.6 %) out of 15 patients. Angiogram was positive in localizing the bleeding point in 8 (80 5) out of 10 patients and is proved to be a useful diagnostic modality for diagnosis of bleeding pseudo aneurysms. Thus, conventional angiography has an overall diagnostic yield rate of 53.3 % (8/15).

Table11. DIAGNOSTIC INVESTIGATIONS PERFORMED IN PATIENTS WITH VISCERAL ARTERY PSEUDOANEURYSM – PRESENT SERIES:

Radiologic / endoscopic study performed	Current series n = 16
Conventional angiography	n = 11 (68.75 %)
Helical C T	n= 12 (75.0 %)
CT angiography+ Color Doppler USG	n = 1 (6.25 %)
Ultrasonography	n= 16 (100 %)
Plain radiography	n = 5 (31.25 %)
Upper gastrointestinal endoscopy	n = 16 (100 %)
Blood in the duodenum +	n = 3 (18.75 %)
Normal endoscopic examination	n = 13 (81.25 %)

Method of Diagnosis in Pseudo aneurysmal Bleed:

The most commonly performed initial diagnostic investigation in the present series was helical CT 12/16 (75 %) with a diagnostic yield rate of 50 % (6/12). The Next diagnostic investigation that follows helical CT in the present series was conventional angiography in 11/16 (68.75 %) patients with a diagnostic yield rate of 81.1% (9/11). Therefore, our study indicates that in hemodynamic stable patients presenting with pseudoaneurysmal bleed an initial helical CT followed by angiography would be a better diagnostic approach.

Table 12. METHOD OF DIGNOSIS OF VISCERAL ARTERY PSEUDOAMERYSM

Method of diagnosis	Current series n=16 (%)
Conventional angiography (positive)	n = 9/11 (81.8)
Helical CT	n = 6/12 (50)
CT angiography + color Doppler USG	n = 1/16 (6.25)
Ultrasonography (USG) and plain radiography	n = 0
Upper G.I Endoscopy	n = 0

CT Findings:

In pancreatitis group with concomitant pseudocyst (n = 8), the bleeding pseudocyst was located at head of pancreas in 3/8 (37.5 %), body of pancreas in 3/8 (37.5 %), tail in 2/8 (25 %), calcification were seen in 6/8 (75 %), pancreatic duct dilatation > 5 mm was seen in 3/8 (37.5 %), evidence of biliary obstruction was found in 1/8 (12.5 %) and evidence of gastric outlet obstruction was seen in two patients 2/8 (25 %). The median (range) size of pseudocyst in this group was 6 (3 -12) cm in present series.

In the chronic pancreatitis group without associated pseudocyst (n = 3) bleeding pseudo aneurysms involving splenic artery located at tail of pancreas was seen in 2/3 (66.6 %) and bleeding pseudo aneurysms located at head of pancreas was seen in one patient 1/3 (33.3 %). In this group, pancreatic duct dilatation > 5mm was not seen in any of 3 patients, pancreatic duct stent was seen in one patient with calcification of the entire pancreas in the same patient.

Table.13 CT FINDINGS IN PATIENTS OF CHRONIC PANCREATITIS WITHOUT ASSOCIATED PSEUDOCYST (n = 3)

Patient No.	Pancreatic calcifications	MPD dilations > 5 mm	Pseudoaneurysm location, size (cm)	Biliary obstruction
Case 2	+ Diffuse entire pancreas	- pancreatic duct stent in situ +	SA, tail 8 cm	-
Case 9	-	-	SPDA, head 2.5 cm	-
Case 15	-	-	SA, tail, 6 cm	-

SA- Splenic artery, SPDA- Superior pancreaticoduodenal arcade

In the hemobilia group, liver injury with pseudoaneurysm in right hepatic artery was seen in two patients 2/4 (50 %), one patient had a 7cm pseudoaneurysm of right hepatic artery with a large blood clot and biloma in right subhepatic space of

TABLE:14 COMPUTERISED TOMOGRAPHIC SCAN FINDINGS IN PATIENTS ACUTE / CHRONIC PANCREATITIS WITH CONCOMITANT PSENDOCYST: (n = 8)

Patient No.	Bleeding pseudocyst Location / Size, cm	Calcifications	MPD dilatation > 5 mm	Biliary Obstruction	G.O.O
Case 1	Tail; 4x5x4	+	-	-	-
Case 5	Body; 12x9x5	-	-	-	-
Case 6	Head; 3x3x5	+	+	-	-
Case 8	Head; 6x7x7 portahepatis	-	+	+	+
Case 10	Body; 7x8x9	+	-	-	-
Case 11	Body;6x5x5	+	-	-	-
Case 12	Tail; 4x3x3	+	-	-	-
Case 14	Head; 7x7x8	+	+	-	+

G.O.O-Gastric outlet obstruction

size 10 x 9 cm following laparoscopic cholecystectomy, and another one (25 %) had pseudoaneurysm of right hepatic artery of size 5cm following laparoscopic

cholecystectomy. The median (range) size of right hepatic artery pseudoaneurysm was 6.25 (2-9) cm and one patient had 8 x7 cm pseudoaneurysm of hepatic artery proper following pancreaticoduodenectomy.

TABLE:15 COMPUTERSIED TOMOGRAPHIC FINDINGS IN PATIENTS WITH HEMOBILIA:

Patient No. (n = 4)	CT grade- Liver injury (laceration)	Pseudoaneurysm Location/size	Biloma/blood clot size
Case 3	Grade II	Right hepatic artery, 5 cm	-
Case 4	-	Right hepatic artery, 7 cm	Biloma with large blood clot in right subhepatic space+, 10 x 9 cm
Case 7	-	Right hepatic artery, 2 cm	-
Case 13	Grade III	Right hepatic artery, 5 cm	-

Angiography findings at selective celiac/mesenteric angiography:

Conventional angiography demonstrated the site of bleeding (positive angiograms) in 9(81.8 %) patients out of 11 patients in whom angiographic interventions in this series. Two angiograms (18.1 %) were negative. Angiographic source of bleeding was identified in 9 patients – two from splenic artery (case 10, case 15); two from right hepatic artery (cases 7, 13); two from gastroduodenal artery (cases 6,14); and one from inferior pancreaticoduodenal artery (case 8) , one from superior pancreaticoduodenal arcade (case 9)and one from hepatic artery proper.

In general, a positive angiogram was taken as radiologic demonstration of pseudoaneurysm or active extravasation of contrast during the arterial phase. The positive angiographic findings included active contrast extravasation (n=1),pseudoaneurysm (n=6) and combination of contrast extravasation and pseudoaneurysm (n=2).

Etiology of pseudoaneurysmal bleed:

Most common pancreatic inflammatory disease associated with pseudoaneurysmal bleed in the present series was alcoholic chronic pancreatitis (43.75 %). Among 11 patients with pancreatitis; 8 (72.7%) patients had pseudocysts and 3(27.2 %) had pseudo aneurysmal bleed complicating CP in the absence of associated pseudocyst. In the pseudocyst group (n = 8) ,7(87.5 %) patients had recurrent episodes of pancreatitis with a median (range) of 3 (2 to 4) episodes and all these 7 patients had prior pseudocysts and in the remaining one (12.5 %) patient, pseudocyst formation and hemorrhage occurred with the first episode of acute pancreatitis itself. Thus the commonest cause for pseudoaneurysmal bleed was bleeding pseudocyst 6/8 (75 %) in the background of acute/chronic pancreatitis.

TABLE:16 ETIOLOGY OF PSEUDOANEURYSM-PRESENT SERIES:

Etiology	Total no. of Patients n=16
Acute alcoholic pancreatitis	1(6.25%)
Alcoholic chronic pancreatitis	7(43.75%)
Tropical chronic pancreatitis	2(12.5 %)
Iatrogenic trauma (n=4)	
Operative trauma	3 (18.75%)
. post pancreaticoduodenectomy	1(6.25 %)
. post laparoscopic cholecystectomy	2(12.5 %)
Procedural trauma	
. post pancreatic ESWL & Pancreatic duct stenting	1(6.25 %)
Accidental trauma	
. Blunt liver trauma	2(12.5%)

ESWL-Extracorporeal shockwave lithotripsy

Preoperative / Pre-embolization Diagnosis:

In the present series, most common preoperative or pre-embolization diagnosis in a patient presenting with pseudo aneurysmal bleed in the setting of chronic pancreatitis with or without associated pseudocyst is hemosuccus pancreaticus which accounts for 80.0 % (8/10). In the present study, endoscopic examination identified blood emanating from the ampulla of vater into the second part of the duodenum in 3(25.0%) patients[two (16.6 %) in hemosuccus pancreaticus group and one(8.3%) in

hemobilia group]. This indicates that upper gastrointestinal endoscopy may be useful in the diagnosis of hemosuccus pancreaticus in 16.6 % of cases.

TABLE:17 PRE–EMBOLIZATION / PREOPERATIVE DIAGNOSIS IN PATIENTS WITH PSEUDOANEURYSMAL BLEED – PRESENT SERIES

Diagnosis	**Total No. n = 16**
Hemosuccus pancreaticus	n = 8 (50.0%)
Hemobilia	n = 4(25.0 %)
Pancreatic pseudoaneurysmal bleeding complicating acute/chronic pancreatitis	n = 3 (18 75)
Bleeding pseudoaneurysm following pancreaticoduodenectomy	n=1(6.25%)

Previous Surgery / Procedure done in patients under study were depicted in table-18

TABLE-18 PREVIOUS SURGERY / PROCEDURE DONE IN PATIENTS UNDER STUDY:

Previous Surgery / Procedure	Total No. n = 6
Splenectomy for splenic cyst (chronic pancreatitis group)	n=1
Pancreatic duct Stenting + ESWL for pancreatic duct calculi (chronic pancreatitis group)	n=1
Biliary tract surgery (n=3)	
Open cholecystostomy + CBD exploration + T-tube drainage for blunt liver trauma (Hemobilia group)	n=1
Laparoscopic cholecystectomy for stone disease (Hemobilia group)	n=2
Pancreatic surgery	
Whipple's pancreaticoduodenectomy	n=1

Bleeding Vessel implicated in patients with Pseudo aneurysmal bleeding:

In the present series, splenic artery is the most commonly involved vessel 6 (37.5 %) followed by hepatic artery in 5 (31.25 %).[Table19]

Site of Pseudo aneurysmal bleeding according to location of Pseudo aneurysm.

In the present series, the commonest site of pseudo aneurysmal bleed was into the pseudo cyst in 6 (37.5 %) followed by biliary tract in 4 (25.0%).[Table 20]

TABLE-19 Blood vessel implicated in visceral artery pseudoaneurysmal bleeding – Comparative analysis of current series with published series.

Vessel involved	Current series n = 16 percentage	Stabile et al 1998 n = 344 Percentage	Carr et al n = 16 percentage	Beattie et al 2003 n = 19 percentage
Splenic artery	37.5	36.9	18.7	15.7
Gastroduodenal artery	12.5	18.0	37.5	21.0
Pancreatico duodenal artery	12.5	19.2	12.5	21.0
Hepatic artery	31.25	2.6	-	-
Left gastric artery	-	2.6	-	10.5
Right gastric artery	-	1.2	-	-
Dorsal pancreatic artery	-	7.0	-	-
Transverse pancreatic artery	-	3.5	-	-
Superior mesenteric artery	-	2.6	6.25	-
Middle colic artery	6.25	0.6	-	-

Features of Pseudoaneurysm:

In patients with chronic pancreatitis, the mean (range) size of pseudoaneurysm was 5.1 (2 to 10) cm and were contained by the pseudocysts in 7 out of 10 patients. In patient with acute pancreatitis, the size of the pseudo aneurysm was 10 cm which was contained by the pseudocyst in the vicinity of acute inflammation of pancreas. In patients with hemobilia, the mean (range) size of pseudo aneurysm was 5.8 (2-9)cm. In all the patients the number of pseudo aneurysm was single. The pseudo aneurysm sac was intact in 13 patients and it was ruptured in 2 patients (one in hemobilia group – right hepatic artery pseudo aneurysm ruptured into biliary tract and right sub hepatic

space and in another one patient in the acute pancreatitis group – middle colic artery pseudo aneurysm was ruptured into the leaves of right colon mesentery and presented as mesenteric hematoma.

The mean (range) size of the pseudoaneurysm in patients (n = 5) who underwent operative interventions as first line therapy without prior angiography was 7.8 (5-10)cm and in patients (n = 6) who required operative interventions as second line therapy for secondary complications or failure after angiographic embolization was 7.1 (3-9)cm in the present series.

TABLE-20 Site of pseudoaneurysmal bleeding according to the location of pseudoaneurysm.

Location of pseudoaneurysm	**Primary site of bleeding**
Splenic artery (n= 6)(37.5%)	Peritoneal cavity – 1 Pseudocyst - 2 (Intracystic) Wirsung duct - 1 Stomach - 1 Transverse colon and left lung -1
Right hepatic artery (n = 4)(25%)	Extrahepatic bile duct -2 Intrahepatic biliary tree – 2
Gastro duodenal artery (n = 2)(12.5%)	Pseudocyst – 2 (Intracystic)
Superior pancreaticoduodenal arcade (n = 1) (6.25%)	Wirsung duct
Middle colic artery (n = 1) (6.25%)	Pseudocyst (Intracystic, intra-abdominal)
Hepatic artery proper (n = 1) (6.25%)	Abdominal wall sinus

Thus, the overall mean (range) size of pseudoaneurysm that required operative intervention was 7.4 (3-10) cm in the present study. The mean (range) size

of the pseudoaneurysm in patients (n=4) who underwent angiographic embolization as first line definite therapy was 2.3 (2-3) cm in the present series.

TABLE-21 PSEUDOANEURYSM-FEATURES

Patient No.	Source of bleed/ vessel involved	Size Median (range) 5 (2-10) cm	Number (single/multiple)	Ruptured/Intact
1	SA	7	Single	Intact
2	SA	8	Single	Intact
3	RHA	5	Single	Intact
4	RHA	9	Single	Ruptured into right sub-hepatic space & biliary tract
5	MCA	10	Single	Ruptured into leaves of right colonic mesentery
6	GDA	3	Single	Intact
7	RHA	2	Single	ruptured
8	IPDA	2	Single	Intact
9	SPDA	2.5	Single	Intact
10	SA	8	Single	Intact
11	SA	9	Single	Intact
12	SA	3	Single	Intact
13	RHA	7.5	Single	Intact
14	GDA	7	Single	Intact
15	SA	8	Single	Intact
16	HAP	8	Single	Intact, Communicating with abdominal wall sinus tract

SA-Splenic artery, GDA – Gastroduodenal artery, RHA – Right hepatic artery, IPDA – Inferior pancreaticoduodanal artery, SPDA – Superior pancreaticoduodenal arcade, HAP-Hepatic artery proper

This indicates that for small pseudoaneurysm (< 3cm), angiographic embolo-therapy is often sufficient as a primary definite therapy in order to achieve permanent hemostasis but for large pseudoaneurysm (>7cm), PTAE is usually contemplated as an initial temporizing measure and it most often requires subsequent surgical intervention in the form of either excision or drainage procedure as soon as possible after PTAE. The mean size of the pseudoaneurysm in relation to underlying etiology of disease either pancreatitis related or trauma related is almost similar (5.75 to 5.80 cm) in both groups in the present study.

Comparative analysis of pancreatic pseudo aneurysm with / without associated pseudocyst:

In the present study, 8 (72.7%) patients had pancreatic pseudoaneurysm with concomitant pseudocyst. Interventions as successful therapy in this group included surgery in 75% and percutaneous trans-catheter angiographic embolization(PTAE) in 25%.In the present study, failure rate of PTAE was 66.6% in patients having pseudoaneurysm with associated pseudocyst ,with no embolization failure in patients without pseudocyst. The average size of pseudoaneurysm without associated pseudocyst in which embolization (PTAE) successful was 5.2cm with no failure of embolization. The average size of pseudoaneurysm with associated pseudocyst in which embolization failed was 6.75cm, compared with 2.5cm in those in which it was successful. None of the patients with pseudo aneurysm were managed conservatively in the present series. Based on the comparative sub group analysis, it was found that pseudoaneurysm associated with pseudocyst often requires surgical intervention in the form of resection, excision or ligation rather than trans-catheter angiographic embolization.

Angiographic interventions for hemostasis in pseudo aneurysmal bleed:

Angiography was performed in 11 (68.75%) of 16 patients in the present study. Angiographic catheter directed therapeutic embolization was attempted in 9 (81.8 %) of 11 patients and was successful in achieving hemostasis in 6 of 9 patients with an overall embolization rate of 66.6%. Percutaneous trans-catheter angiographic embolization (PTAE) as first line / initial definitive therapy with no further intervention for hemostasis was performed in 5/9 (55.5%) hemodynamically stable patients. PTAE as initial temporizing measure for hemostasis requiring subsequent operative therapy was achieved in one patient 1/6 (16.6 %).PTAE was achieved in 6 patients (selective n=4,superselective n=2)using embolic agents such as coils

(n=5);autologous blood clot and gelatin sponge (n=1).The embolized arteries were Splenic artery(n=1),gastroduodenal artery (n=2),superior pancreatico duodenal artery (n=1),inferior pancreatico duodenal artery (n=1) and right hepatic artery(n=1).[table 22]

TABLE:22 ANGIOGRAPHIC INTERVENTIONS FOR HEMOSTASIS IN PSEUDOANEURYSM BLEED:

Angiography performed n = 11/16 (68.75 %)	Total No. n=16
Therapeutic catheter directed embolization attempted	n = 9/11 (81.8 %)
PTAE technically successful	n=6/9(66.6%)
PTAE successful as first line / initial definitive therapy with no further intervention for hemostasis (permanent hemostasis)	5/9 (55.5 %)
PTAE as successful as initial temporizing measure for hemostasis requiring subsequent operative therapy for re-bleed (temporary hemostasis)	6(16.6%)
PTAE as second line / delayed definitive therapy after the initial failed surgery.	n = 0
PTAE attempted and failed as initial first line therapy (technical failures)	n = 3/9 (33.3%)

Surgical interventions for hemostasis in pseudo aneurysmal bleed:

Surgical interventions were required in 12 (75.0 %) of 16 patients. In the present study, surgery as first line/initial definitive therapy without prior angiography and with no further / subsequent intervention for hemostasis was achieved in 5/12 (41.6 %), 4 emergency and 1 elective.

In the present series, surgery as second line/delayed therapy for failure/complications of angiographic embolization was performed in 6/12 (50.0 %), 2 emergency and 4 elective. [Table 23]

TABLE: 23 SURGICAL INTERVENTIONS FOR HEMOSTASIS IN PSEUDOANEURYSM BLEED:

Surgical interventions n = 12/16 (75.0 %)	Total No. n = 12	Emergency / urgent surgery n= 6 (50.0 %)	Elective surgery n = 6 (50.0 %)
Surgery as first line / initial definitive therapy with no further intervention	5/12 (41.6 %)	4	1
Surgery as second line /delayed therapy for failure / complications of angiographic embolisation	6/12 (50.0 %)	2	4
Combined operative therapy and angiographic embolo therapy for rebleeding after embolisation.	1/12 (8.3 %)	-	1

Indications for Surgery:

The most common indication for urgent surgery as first line therapy in the present series was major bleeding with significant hemodynamic instability and rapid clinical deterioration due to continued bleeding in 4 patients.[Table24]

TABLE : 24 INDICATIONS FOR SURGERY:

Indications	Total No. n = 12/16 (75.0 %)
Active bleeding with significant haemodynamic instability and rapid clinical deterioration (unsuitable for angiography)	n= 4 (33.3 %) (all emergency surgery)
Failure of angiographic embolization Technical failures (n=3) Rebleeding (n=1)	n = 6 (50.0 %) (2 emergency, 4 elective)
Complication of angiographic embolization (Infection of thrombosed residual pseudoaneurysm with intra abdominal sepsis)	n = 1 (8.03 %) (elective surgery)
Post laparoscopic cholecystectomy combined right hepatic artery injury with bleeding pseudoaneurysm, worsening anaemia and major bile duct injury with biliary and intra abdominal sepsis.	n = 1 (8.03 %) (emergency surgery)

Operative Findings:

At surgery, morphological changes of acute pancreatitis with hematoma in right colon mesentry following rupture of middle colic artery pseudo aneurysm was seen in one patient (case5).

At surgery morphological changes of chronic pancreatitis with fibrosis in 4, calcification in 6, and mature pseudocysts in 5 patients in 5 patients respectively. At surgery, one patient (case 4) had biloma with a large 9 cm sized blood clot in right subhepatic space following rupture of right hepatic artery pseudo aneurysm due to post-laparoscopic cholecystectomy right hepatic artery injury and major bile duct injury.

TABLE : 25TYPES OF OPERATIVE PROCEDURES:

Operative procedure	Total No. n = 11
Central / middle segment pancreatectomy with excision of SA pseudoaneurysm	**n = 1 (case – 10)**
Transection of body of pancreas with intracystic ligation of gastro duodenal artery with excision of GDA pseudoaneurysm + external drainage of pseudocyst cavity, suture closure of proximal pancreatic stump with distal Roux-en-Y pancreatico jejunostomy.	**n = 1 (case 14)**
Intracystic ligation of splenic artery with excision of SA pseudoaneurysm and cystogastrostomy.	**n = 1 (case 11)**
Distal pancreatectomy and splenectomy with excision of SA pseudoaneurysm + suture closure of proximal pancreatic remnant.	**n = 2 (case) (1,2)**
Distal pancreatectomy and splenectomy with excision of SA pseudoaneurysm + proximal Roux-en-y pancreatico jejunostomy.	**n = 1 (case 12)**
External drainage of infected thrombosed residual SA pseudoaneurysm with retroperitoneal abscess.	**n = 1 (case 15)**
Right hepatectomy for RHA pseudoaneurysm(Hemobilia following blunt liver trauma	**n = 2 (case 3,13)**
Excision of RHA pseudoaneurysm with suture repair of bleeding vessel and bile duct intubation	**n = 1 (case 4)**
Right hemicolectomy with mesenteric hematoma evacuation, extracystic vessel ligation and external drainage of pseudocyst for rupture of middle colic artery pseudoaneurysm into acute pseudocyst.	**n = 1 (case 5)**
Excision of pseudoaneurysm, suture repair of bleeding vessel and proximal ligation of common hepatic artery for hepatic artery proper pseudoaneurysm following pancreaticoduodenectomy.	**n=1 (case 16)**

Another one patient (case 2) had a large 8 cm sized splenic artery pseudo aneurysm in the body of pancreas communicating with left lung through a rent in left dome of diaphragm and also had communication with transverse colon due to pseudo aneurysm erosion. Another one patient had a post pancreatico duodenectomy large 8 cm sized pseudoaneurysm (case16) arising from hepatic artery proper, which was located behind the Roux-en –Y jejunal limb of hepaticojejunostomy communicating with the anterior abdominal wall sinus through a sinus tract.

Operative Procedures:

The various operative procedures performed were depicted in the table- 24.

FLOWCHART-1 Results and outcome of diagnostic angiography and therapeutic angiographic embolization:

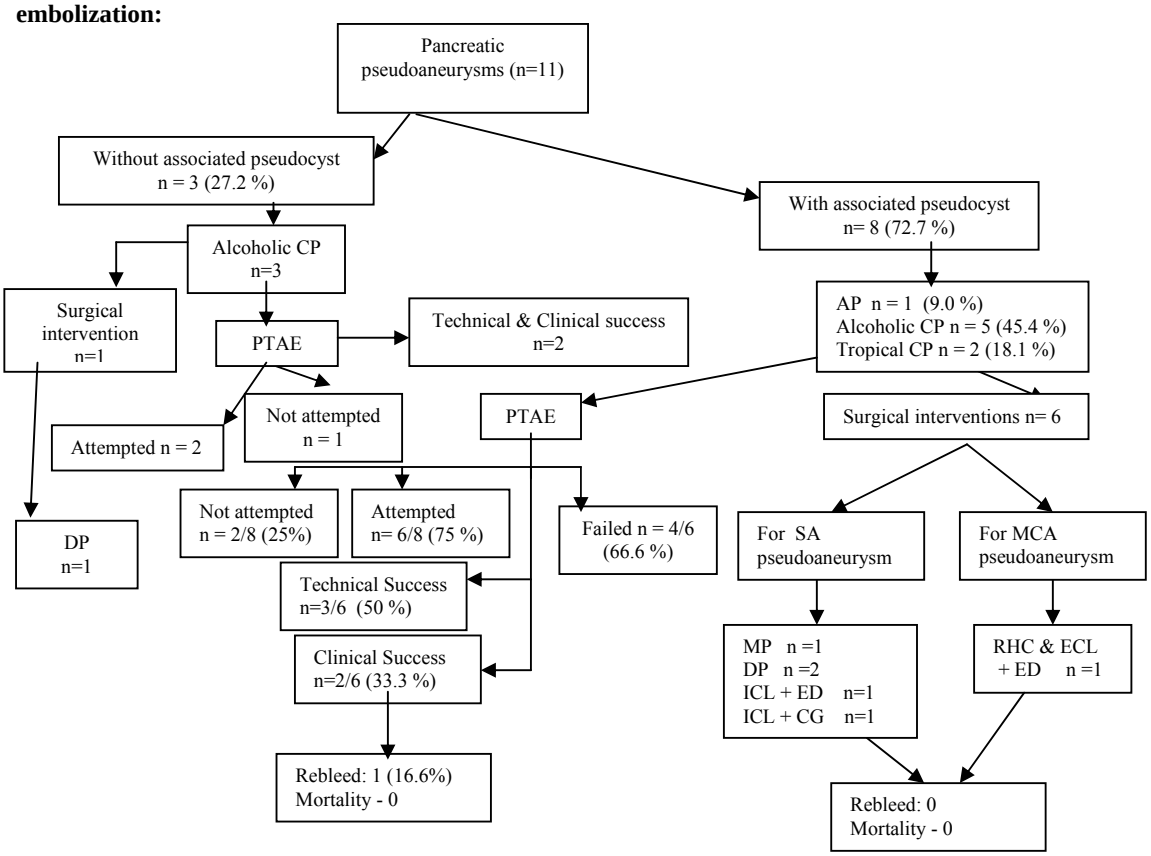

MP- Middle Segment/central pancreatectomy
DP- Distal pancreatectomy
ICL + ED - Intracystic ligation & External Drainage
ICl + CG - Intracystic ligation + cystogastrostomy
RHC & ECL + ED- Right hemicolectomy + Extracystic ligation and external drainage
SA- splenic artery
MCA - middle colic artery
AP – Acute pancreatitis
CP – Chronic pancreatitis
PTAE – Percutaneous Transcatheter Arterial Embolization

Results and outcome of angiographic interventions:

In the present series, 9(81.8%) of 11 patients who underwent coelic / mesenteric angiography, angiogram localized either a bleeding point in 33.3% (n=3)or a pseudo aneurysm in 66.6 % (n=6) and in 2 (18.1%) of patients angiography could not localize the bleeding point. Angiographic embolization was attempted in

9/11 (81.8 %) and was successful in 6/9 (66.6%) with an overall technical success rate or embolization rate of 66.6 % in the present series.[Flow chart 2]

TABLE-26 Outcome of angiographic embolization according to the type and number of embolic agents and method of coil deposition

Patient No:	Vessel involved	Embolization Material	Method of coil deposition / deployment			Size/ Number coils used	Immediate response	Clinical outcome
			Inside PA	On either side of PA (Proximal and distal to PA)	On the feeding artery			
Case 6	GDA	Microcoils	-	√	-	3mm, 3	Stop bleeding	Favorable
Case 7	RHA	Tungsten coils	-	-	√	3mm, 2	Stop bleeding	Favorable
Case 8	IPDA	Microcoils	-	-	√	2mm,2 3mm,3	Stop bleeding	Favorable
Case 9	SPDA	Microcoils	-	-	√	3mm,2	Stop bleeding	Favorable
Case 14	GDA	Microcoils	-	√	-	5mm,4	Stop bleeding	Rebleed (due to SMA collaterals to PA)
Case 15	SA	Autologous blood clot and gel foam pledgets.	√	-	-	-	Stop bleeding	Sepsis of residual thrombosed PA

PA - pseudoaaneurysm

5 of 11 patients who had positive angiograms required subsequent surgical interventions, in three patient with technical failure due to non–cannulation of bleeding artery and in two (18.1%) patient due to non -demonstration of angiographic source of bleeding with a overall technical failure rate of 33.3% (3/9) in the present series. In the present study splenic artery embolization is associated with a high

failure rate of 75%, and embolization of pancreaticoduodenal artery is associated with a success rate of 100%. [Table 27]

In the present series, coil embolization is associated with high success rate of 80% (4/5) when compared with other embolic agents[Table 26]. In the embolization group (n = 6), angiographic embolization was successful as primary definitive therapy for achieving permanent hemostasis with no further intervention for bleeding in 5 /9(55.5%) patients and one (16.6 %) patient had rebleeding after successful embolization requiring subsequent elective surgical intervention. Thus, the overall clinical success rate for embolization to provide definitive hemostasis was 55.5 % in the present series. None of the patients developed late rebleeds in the present series. One patient developed a complication related to embolization i.e infection of thrombosed residual pseudoaneurysm with retroperitoneal abscess and intra-abdominal sepsis 14 days after embolization and required subsequent elective surgical intervention.One patient with GDA pseudo aneurysm within a pseudocyst had rebleed 48 hours after embolization due to persistent leak into the pseudo aneurysm through superior mesenteric artery collaterals and subsequently required elective surgical intervention. Thus the overall morbidity rate, excluding technical failure following PTAE was 16.6 %(1/6) and rebleeding rate was 16.6% (1/6)in the present study with no mortality.[Table 28]

OUTCOME OF SURGICAL INTERVENTIONS:

None of the patients had rebleed after surgery either in the group of first line or second line operative therapy with an overall success rate of 100 %. Among 12 patients who underwent surgery, 6 emergency and 6 elective, none of the patients died in post operative period. The major surgical morbidity included, external pancreatic fistula in two (16.6 %) patients with a overall morbidity rate of 41.6% (5/12). The two patients who had external pancreatic fistula were managed conservatively and it healed spontaneously over a period of 3 months after surgery. [Table 29-30]

FLOW CHART -2 DEMONSTRATING OUTCOME IN RELATION TO ANGIOGRAPHIC FINDINGS:

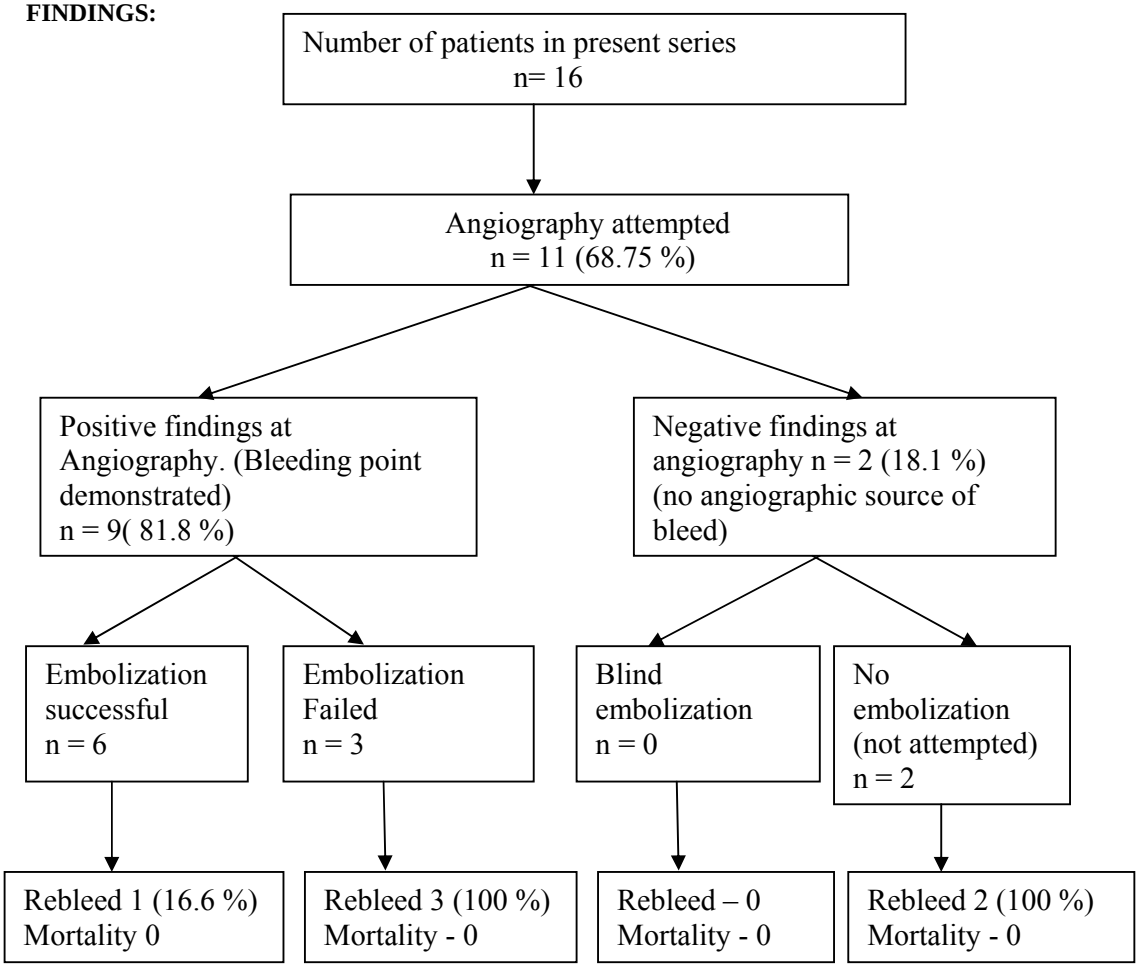

TABLE -27 Result of embolization according to the site of artery involved:

Artery involved	Total No:	Embolization Attempted	Embolization Successful	Failure rate
Splenic artery	n = 6	n = 4	n = 1	75%
Hepatic artery (RHA,HAP)	n = 6	n = 3	n = 1	33.3%
Gastro duodenal artery	n = 2	n = 2	n = 2	50% (Rebleed)
Pancreatico duodenal arcade	n = 2	n = 2	n = 2	0%

TABLE-28 RESULTS OF ANGIOGRAPHIC INTERVENTIONS IN PATIENTS WITH PSEUDOANEURYSMS:

Patient No	Disease Status	Active bleeding during angio	Angio findings	Vessels embolized	Embolic Material used	Rebleed	Urgent Surgery	Elective surgery	Outcome
Case 6	PS & CP	Yes Angio positive	Pseudo aneurysm GDA	GDA	Microcoils	No	No	No	Survived, resolution of pseudocyst at 3 months
Case 7	Post–Lap. Chole	Yes	Pseudo aneurysm RHA, Angio positive	RHA	Tungsten coils	No	No	No	Survived, resolution of pseudoaneurysm, no rebleed
Case 8	PS & CP	Yes	Pseudo aneurysm IPDA, Angio positive	IPDA	Microcoils	No	No	No	Survived,resolution of pseudocyst at 2 months after PCD
Case 9	CP	Yes, Angio positive	Pseudo aneurysm SPDA	SPDA,	Microcoils	No	No	No	Survived
Case 10	PS & CP	No	Angio negative	-	-	Yes	-	Yes	Survived
Case 11	PS & CP	Yes, Angio positive	Pseudoaneurysm SA	Failed cannulation of bleeding artery	None	Yes	Yes	No	Survived
Case 12	PS & CP	No	Angio negative	-	None	Yes	No	Yes	Survived
Case 13	Hemobilia Blunt liver trauma	Yes, Angio positive	Pseudo aneurysm RHA	Failed cannulation of bleeding artery	None	Yes	Yes	-	Survived
Case 14	PS & CP	Yes, Angio positive	Pseudo aneurysm GDA	GDA	Microcoils	Yes	No	Yes	Survived, resolution of pseudocyst at 5 months
Case 15	CP	Yes, Angio positive	Pseudo-aneurysm SA	SA	Autologous blood clot and gel foam particles	No	-	Yes	Survived, infection of thrombosed PA
Case 16	Post-PD	No	HAP pseudoaneurysm	Failed cannulation	-	No	-	Yes	survived

CP – Chronic pancreatitis, PS – Pseudocyst, SA – Splenic artery, GDA – Gastroduodenal artery, RHA – Right hepatic artery, IPDA – Inferior pancreaticoduodenal artery, SPDA – Superior pancreaticoduodenal arcade, HAP – hepatic artery proper, PCD-percutaneous catheter drainage PA-pseudoaneurysm

TABLE-29 OUTCOME OF PATIENTS WHO UNDERWENT SURGICAL INTERVENTIONS: (n = 12)

Patient No.	Morbidity/Mortality	Final Outcome	Results of F /U CT
Case 1	None, alive	No rebleed, chronic pancreatitis at 48 months	Evidence of chronic pancreatitis at 40 months
Case 2	None, alive	No rebleed, chronic pamcreatitis at 36 months	Evidence of chronic pancreatitis at 30 months
Case 3	None, alive	No rebleed, asymptomatic at 3 months	Good liver regeneration at 18 months
Case 4	None, alive	No rebleed, asymptomatic at 2 months	No evidence of biliary dilatation at 4 months
Case 5	External pancreatic fistula, alive	No rebleed, asymptomatic at 20 months	Resolution of pseudocyst at 16 months
Case 10	Alive, wound sepis	No rebleed, pain free at 12 months	Resolution of pseudocyst at 10 months
Case 11	None, alive	No rebleed, pain free at 11 months	Resolution of pseudocyst at 7 months
Case 12	None, alive	No rebleed, chronic pancreatitis at 36 months	Resolution of pseudocyst at 12 months
Case 13	Pneumonia, alive	No rebleed, asymptomatic at 3 months	Good liver regeneration at 14 months
Case 14	External pancreatic fistula, alive	No rebleed, asymptomatic pain free at 20 months	Resolution of pseudocyst at 19 months
Case 15	None, alive	No rebleed, asymptomatic at 28 months	Evidence of chronic pancreatitis at 18 months with a new pseudocyst(2.5cm) in tail
Case 16	None, alive	No rebleed	Resolution of pseudoaneurysm

OVERALL OUTCOME:

There were no post operative deaths in both angiographic and operative intervention groups of patients.Control of bleeding was successful in all patients (n = 10) treated by surgery. There were no recurrence of pseudoaneurysm or bleeding in any of the patient during follow up after mean follow up of 26.3 (45 – 59) months.[Table 28,29,30,31]

TABLE-30 Overall outcome of surgical interventions

Outcome parameter	n =12 (%)
Morbidity	
Pneumonia	1 (8.3)
Wound sepsis	1 (8.3)
External pancreatic fistula	2 (16.6)
Intra abdominal fluid collection	1 (8.3)
Mortality	0
Rebleeding	0
Success rate	100%
Overall morbidity rate	5(41.6)

TABLE-31 OVERALL OUTCOME OF ANGIOGRAPHIC INTERVENTIONS:

Result	Total No.n=11
Patients underwent celiac / mesenteric angiography	n = 11/16 (68.75 %)
Embolization attempted with positive angiogram	n = 9/11 (81.8 %)
Angiography localized either a bleeding point or a pseudoaneurysm (Detection rate)	n=9/11 (81.8%)
Technical success rate (embolization rate)	n = 6/9 (66.6%)
Technical failure rate	n= 3/9 (33.3 %)
Non-demonstration of bleeding point Non-cannulation of bleeding artery	n = 2/11 (18.1 %) n = 3/9 (33.3 %)
Complication related to embolization Infection of thrombosed residual pseudoaneurysm	n = 1/6 (16.6 %)
Overall clinical success rate of embolization with no further intervention for bleeding control	n= 5/9 (55.5 %)
Rebleeding after initial successful embolisation	n = 1/6 (16.6 %)
Morbidity rate	n = 1/6 (16.6 %)
Rebleeding rate	n = 1/6 (16.6 %)
Survival rate is embolisation group	n=6/6 (100 %)
Overall failure rate of PTAE including technical failure and rebleed	n=4/9 (44.4%)

Late Survival and Follow-Up:

Follow up data were available for 14of 16 survivors, with a mean follow up of 26.3 (range 45 – 59)months. Two patients (case 7, case 8) were lost to follow up at 5

and 11 months. Follow up CT scans were obtained in 8 patients at a mean interval of 12 months (range, 1- 40) months, which demonstrated resolutions of pseudocyst in 4 patients. In one patient (case 15), a new 2.5 cm pseudocyst was discovered at 18 months in a patient who has alcoholism and chronic pancreatitis. No pseudoaneurysm recurred in any patient during follow up. None of the patient had late rebleeds during follow up.[Tables 28,31]

DISCUSSION AND COMPARATIVE ANALYSIS:

Our series of 16 patients with visceral artery pseudoaneurysm is a small retrospective observational cohort study based on a single institutional experience at a tertiary care referral center. In itself this is a indicator of the relative infrequency of major vascular complication of pancreatitis and vascular trauma (iatrogenic / accidental) to visceral arteries. This low incidence of visceral artery pseudoaneurysm as it is a relatively uncommon disease and the urgent nature of major pseudoaneurysmal bleeding presenting as a rarely occurring rapidly fatal complication probably means that neither randomized trial nor case control methodologies are suitable for evaluating outcome and that evidence on optimal management will continue to accure from single- institutional, observational cohort series such as the present study.

Visceral artery pseudoaneurysm is a rare clinical entity. Over 7 years at our institution only 16 pseudoaneurysms were identified and 6 involved the splenic artery. Review of literature supports the rarity of these lesions. Although, more than 3000 visceral artery aneurysms have been reported in the literature, only 157 splenic artery pseudoaneurysms have been identified. Therefore, good understanding of the risk factors, presenting symptoms, diagnostic studies and treatment options is often necessary.

The mean age of presentation of pseudoaneurysmal bleed in our series was 37 years which is similar to other series[34,38,45] although presentation during childhood has also been reported [80,81] and one of our patient was a female child who presented with upper gastrointestinal bleed in the background chronic pancreatitis at age of 12 years. Clinical presentation varies according to the site and severity of haemorrhage.

Bleeding is usually brisk, but varies from short, repeated and self limiting episodes of haemorrhage, slow and chronic blood loss presenting as iron deficiency anemia, moderately severe and intermittent bleeding as a massive haemorrhage with life – threatening hypovolaemic shock requiring emergency surgery [48]. The most common type of clinical presentation in our series was upper gastro intestinal bleeding (81.8 %) in the pancreatitis group which is comparable to 60 – 69% in other series [40,45,48]. In the present series, the most common etiology associated with pancreatic pseudoaneurysm was pseudocyst in 75.0 % which is comparable to 60 to 100 % reported in other series [40,45].

Pseudoaneurysm formation in patients with pancreatitis is closely related to the intensity and duration of the disease [44,48]. The incidence of pseudoaneurysm varies between 10 – 17 % in chronic pancreatitis with bleeding and is 10 to21 % in patients with chronic pancreatitis without bleeding undergoing angiography [34,41,48], but the incidence of pseudoaneurysm was higher in patients with pancreatic pseudocyst reported as 10 – 31 % [34,38]. Most pseudoaneurysms are symptomatic and mostly develop in association with and in close proximity to pseudocyst.In general, vascular complications of acute pancreatitis occur late in the disease course and in post operative patients. In contrast, the data from the present study suggest that patients with vascular complications of chronic pancreatitis or of pseudocysts may be admitted to hospital with their vascular complication as a presenting symptom. In the present study also, post inflammatory peripancreatic pseudoaneurysm formation is mostly commonly encountered in alcoholic chronic pancreatitis with concomitant pseudocyst particularly in alcoholic men. Major

gastrointestinal haemorrhage was reported in 1.7 – 10 % of patients with pancreatitis and melaena [34,38]. Frank rectal bleeding / hematochezia and hemoptysis may be related to the rare case of rupture of a pseudocyst / pseudoaneurysm into the colon / lung [34,82] which occurred in one of our patient (case 2). The incidence of haemorrhagic complications were reported as 7 – 14 % in patients with chronic pancreatitis [19,21] 1-3 % in patients with acute pancreatitis and 6 – 31 % in patients with pancreatic pseudocyst [19,21,68,45]. Bleeding into the pseudocyst may arise from a ruptured pseudoaneurysm or from vessels within the wall of the pseudocyst. This in turn lead to rupture into the gastrointestinal tract (stomach, duodenum, colon), pancreatic duct, bile duct, peritoneal cavity or retro peritoneum[34,48] with serious consequences. In majority of cases of chronic pancreatitis, bleeding usually originated from a pseudoaneurysm or pseudocyst wall..In the present series, the most common site of pseudoaneurysmal bleeding was into the pseudocyst 37.5 % however, a substantial number of patients had bleeding into duct of wirsung, bile duct, stomach, colon and peritoneal cavity. In addition, 54.5 % of patients with bleeding are hemodynamically unstable at presentation.

Pancreatitis in both acute and chronic forms is the commonest cause of visceral artery pseudoaneurysm particularly in alcoholic males. Pancreatic and peri pancreatic vascular structures can become disrupted by the inflammation and enzymatic autodigestion of arterial wall by pancreatic enzymes such as trypsin and elastase liberated during on-going pancreatitis. Arteries, veins, vessels within the pseudocyst wall and the spleen may become involved. When pancreatic and peripancreatic vessels come in contact with activated proteolytic enzymes, it results in necrotizing arteritis with destruction of vessel wall architecture and the fragmentation

of its elastic tissue leads on to formation of pseudoaneurysm particularly in the presence of secondary infection [18,33]. Though the natural history of pseudoaneurysm is not well established, rupture is the most likely sequel. Rarely, spontaneous regression [23,34] of a visceral pseudoaneurysm may occur. The most commonly affected vessel in pancreatitis is the splenic artery [23,34,40] followed by, in descending order of frequency the gastroduodenal [34,40], pancreatico duodenal, gastric, hepatic and middle colic arteries [40]which is similar to the present series.

Post traumatic pseudoaneurysm formation in the hepatic artery have been documented following operative / accidental injury to hepatic artery presenting as hemobilia [53]. Accidental blunt liver trauma due to road traffic accident causes shearing of arteries, veins and bile ducts without capsular rupture resulting in acute presentation of hemobilia. Blunt trauma to the liver results in a central rupture that may leave a large cavity (cavitation effect) into which damaged bile ducts and blood vessels drain [53]. The resulting biloma or hematoma may continue to expand while liver healing is impaired. Necrosis of the cavity wall may cause erosion of adjacent structures particularly the hepatic artery resulting in formation of a pseudoaneurysm which may expand until it erodes into the biliary tree, again resulting in hemobilia.The incidence of hemobilia following major liver injury has been reported to be as high as 3% in one series [60] but in other reports the overall incidence is 0.18% or less [83] .Of 106 cases reviewed by Yoshida et al.[56] only one followed penetrating injury, but Croce et al. [84] reported that, of 482 patients with accidental liver injury, three cases of hemobilia followed blunt trauma and three followed penetrating trauma which is comparable to present series with two cases of hemobilia following blunt liver trauma out of 86 cases of accidental liver injury with a overall incidence of 2.3% (present series). Stewart et al [85] reported five cases of hemobilia following laparoscopic cholecystectomy and four of these were as a result of traumatic pseudoaneurysm of right hepatic artery which is comparable to the present series in

which two cases of post–laparoscopic cholecystectomy right hepatic artery pseudoaneurysm have been encountered and treated. There have been 29 cases of hemobilia following cholecystectomy reported in the English literature between January 1996 and December 1999. Percutaneous trans-catheter angiographic embolization (PTAE) was successful in stopping bleeding in 23 cases but failed in three. Two patients died from uncontrollable hemobilia[53].

FIG-3:AETIOLOGY OF HEMOBILIA – COMPARISON OF CURRENT SERIES WITH FOUR REVIEWS OF LITERATURE SINCE 1972

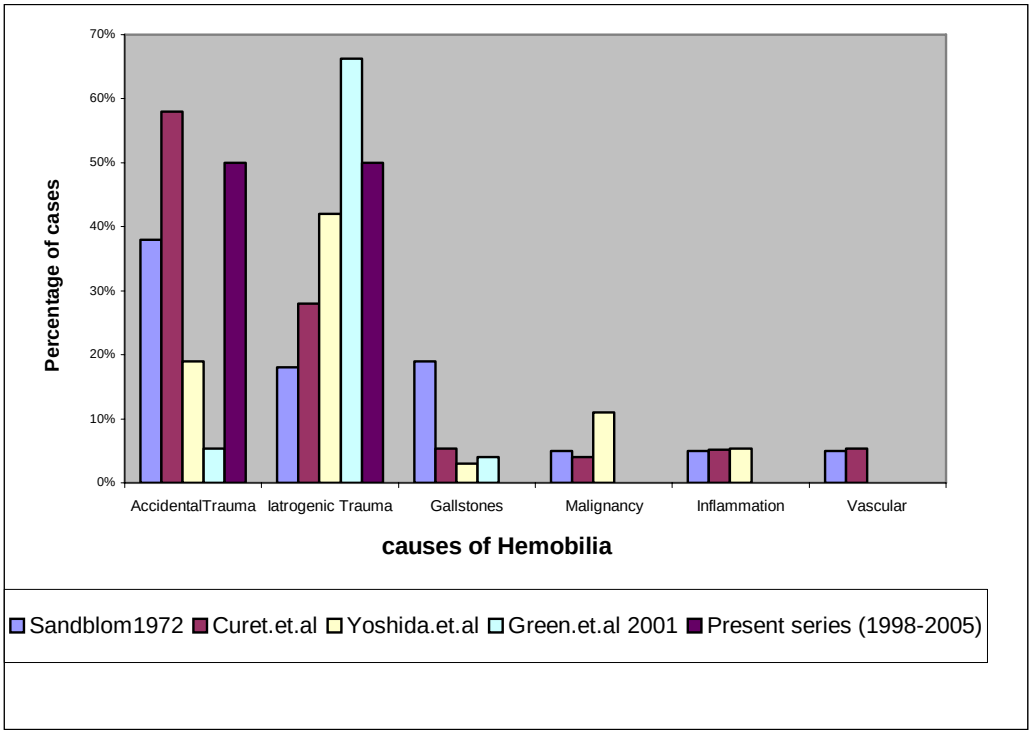

In patients with pancreatitis, the presence of a ruptured arterial pseudoaneurysm should be suspected and rapidly investigated whenever there is an association of the following criteria: (1) persisting or abrupt increase in abdominal pain and (2) decreasing haematocrit and / or hemodynamic instability, and or gastrointestinal bleeding with no obvious intraluminal cause. The diagnosis of hemobilia requires clinical suspicion in the appropriate clinical situation,that is

gastrointestinal bleeding without a demonstrable intestinal source in the presence of hepatic trauma or biliary tract surgery[53]. Investigations are indicated except in cases of massive bleeding with hemodynamic instability when immediate surgical arrest of bleeding becomes necessary. Upper gastrointestinal endoscopy remains the mainstay of diagnosis for those presenting with gastro intestinal bleeding or anemia of chronic blood loss [34,53].

Fig:4 CLINICAL PRESENTATION OF HEMOBILIA – COMPARISON OF CURRENT SERIES WITH LITERATURE: (VENN DIAGRAM)

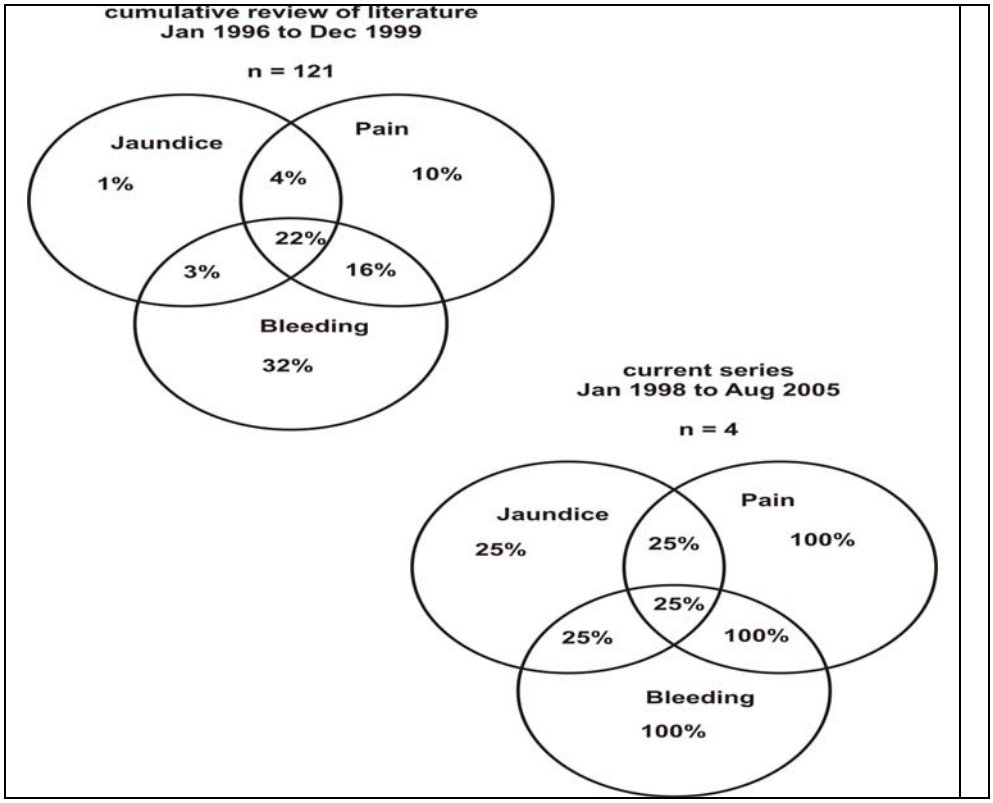

Endoscopy is useful as an initial diagnostic investigation in order to detect blood oozing from the papilla of vater that clinches the diagnosis of hemosuccus pancreaticus [34] particularly in patients presenting with hematemesis resulted from a

bleeding pseudocyst that communicated with pancreatic duct (hemosuccus pancreaticus) as exemplified in case14 of present study.

Erosion of a bleeding pseudocyst into the stomach may mimic bleeding gastric ulcer [34,86] at endoscopy as exemplified in case1 of present study. A negative upper gastrointestinal endoscopy may result from missed fundal gastric varices, intermittent bleeding through the duodenal papilla of vater [34,38] or a bleeding source beyond the reach of the gastroscope, as with intestinal varices or rupture of a pseudocyst into the small or large intestine. Endoscopy in a suspected case of hemobilia if it shows presence of blood or clot at the papilla of vater, hemobilia is likely to be the cause of bleeding. However, as few as 12% of these endoscopies may be diagnostic[53] and further investigations may be required.

Color Doppler ultrasound and contrast enhanced helical CT are often diagnostic, however, small pseudoaneurysms may be missed and both investigations does not offer the benefit of therapeutic interventions [42].

Abdominal ultrasound was used in all patients in the present study as it offers the benefit of greater availability, lower cost, real time capability and no need for contrast material. In addition color Doppler scanning enables confirmation of neck of the pseudoaneurysm, as Color Doppler flow studies can show whether blood in seen flowing into the pseudoaneurysm in systole and out in diastole[20]. The amount of flow can wax and wave, depending on the relative amounts of formed and lysed clot. Clotting tends to occur at the periphery, where flow is slower and stasis exists. If the entire pseudoaneurysm is filled with clot, no flow is detected on Colour Doppler imaging. Acute fresh clot tends to be hyperechoic with older clot becoming more hypoechic [20]. Ultrasound detects pseudoanermysm because of their pulsatile nature,

except when perianeurysmal fibrosis or thrombosis of pseudoaneurysm is present [20]. A pseudoaneurysm may be suggested on ultrasound if a pancreatic mass has a cystic component or if a cystic pancreatic mass rapidly enlarges or suddenly changes echogenecity or turbulent arterial flow on Doppler imaging. Duplex Doppler ultrasound can confirm the diagnosis of pseudoaneurysm and may identify the vessel of origin [20,23].

Helical CT with intravenous contrast enhancement enables identification of parenchymal and vascular abnormalities, such as pseudoaneurysm formation or haemorrhage into the pseudocyst or peri pancreatic fluid collection and it indicates the necessity for obtaining a subsequent angiography to be targeted. The CT finding of a homogeneously enhancing high density structure within or adjacent to a pseudocyst/peripancreatic fluid collection or contiguous with a vascular structure [20,23,32,48] is highly suggestive of clot within a pseudoaneurysm but the presence of a non enhancing complex cystic mass near the pancreas does not exclude the diagnosis of pseudoaneurysm [20].

Selective angiography is considered as the gold standard and most sensitive method for detecting a pseudoaneurysm[20,32,53] . The advantages of angiography [32,53] are (1) it detects active bleeding from an arterio-biliary fistula, an arterio-portal fistula and pseudoaneurysm (2) it detects and localizes a pseudoaneurysm to a specific vessel, and demonstrates anatomy thus facilitating the surgical management and also it provides a potential means of temporary or definitive hemostatic therapy via trans-catheter embolization following diagnosis. (3) it is

attractive because it can demonstrate the erosive vascular changes, it can identify vascular disruption and it can precisely define the pathology of smaller vessels (4) it confirms the site and etiology of hemobilia with a therapeutic intent to arrest the bleeding via embolization. Angiography may be negative particularly if the study is performed when there is no active bleeding [32]. Angiography is usually reserved for those with pancreatitis complicated by hemorrhage, occult blood loss, or a pulsatile mass suggested or confirmed by CT/Doppler ultrasound and in those with active bleeding if hemodynamically stable.ERCP may be useful in the semi – elective situation to demonstrate pancreatic duct abnormalities with associated pseudocyst in a patient with unexplained overt or occult gastro intestinal bleeding that suggests a diagnosis of hemosuccus pancreaticus[34] and should prompt to target angiography as pseudoaneurysm may be the culprit.

TABLE-32 CURRENT SERIES IN COMPARISON WITH PUBLISHED SERIES OF VASCULAR COMPLICATIONS IN PANCREATITIS WITH INDIVIDUAL PATIENT DATA

Author	Year	Country	Recruitment period	n	Presentation				Category			Mort
					Spont	PO	PP	NB	AP	CP	PS	(%)
Ammori BJ [34]	1998	UK	1993-1997	5	3	2	0	0	1	0	4	1 (20)
Rokke O [99]	1997	Norway	1986-1996	3	3	0	0	0	1	0	2	0 (0)
Carr JA [40]	2000	US	1988-1998	16	16	0	0	0	0	0	16	3 (19)
BalsarkarDJ[94]	2002	India		1	1	0	0	0	0	0	1	0 (0)
Koizumi J [95]	2002	Japan		1	1	0	0	0	0	1	0	0 (0)
Ukrami A [96]	2002	Japan		1	1	0	0	0	0	0	1	0 (0)
Present Series	**2005**	**India**	**1998-2005**	**11**	**10**	**0**	**1**	**0**	**1**	**3**	**7**	**0 (0)**

Spont = Spontaneous hemorrhage in the absence of prior surgery; PO = Post Operative; NB = Not bleeding; AP = Acute pancreatitis; CP = Chronic pancreatitis; PS = Pseudocyst; Mort = Mortality; PP = Post procedure (post pancreatic extra corporal shock wave lithotripsy)

Non invasive vascular imaging modalites such as Doppler Duplex ultrasound, Magnetic Resonance Angiography (MRA) and CT angiography are emergency as a promising rapid and non – invasive resolution diagnostic techniques that may offer better with dynamic imaging however, they do not allow concurrent therapeutic interventions[34]. All hemodynamically unstable patients are best managed in the operating room. However, these are many reports of successful transcatheter angiographic embolization even in hemodynamically unstable patients, indicating that this may a viable option in selected patients[32].

In several recent reports, PTAE is advocated as the sole therapy for the treatment of pancreatitis-associated pseudoaneurysms with high technical success rate (75% - 100%) and low morbidity (14% - 25%) and death rates (0% - 14%) [38,42,44] Most of these reports, however, are limited by small numbers of patients (3-14 each, 34 total) and short follow – up period.

TABLE-33 CURRENT SERIES IN COMPARISON WITH RECENT PUBLISHED SERIES OF PATIENTS WITH VASCULAR COMPLICATIONS OF PANCREATITIS:

First Author	Year	Period of publication	n	Aetiology			Surg first	Angio	Embo	Mort (%)
Sand JA [93]	1997	Institutional cohort 1991 – 1995	10	0	0	10	0	10	6	2 (20)
Reber PU [97]	1999	Institutional cohort 1994 - 1997	5	0	0	5	0	5	5	0 (0)
Rantala A [98]	1996	Institutional cohort 1979 – 1994	10	0	0	10	8	2	1	0 (0)
De Perrot M [48]	1999	Institutional cohort 1978 – 1997	10	4	0	6	2	8	3	1 (10)
Present Series	**2005**	**Institutional cohort 1998 – 2005**	**11**	**1**	**3**	**7**	**3**	**7**	**5**	0 (0)

Surg first = Surgery as first intervention; Angio = Angiography; Embo = Angiographic embolization successful; Mort = Mortality; AP = Acute pancreatitis; CP = Chronic pancreatitis; PS= pseudocyst

Gambiez et al[87] have the longest follow – up on14 patients who were treated with PTAE and surgical therapy. Observing no late recurrence of bleeding in a group

of six patient's treated with PAE alone after a mean follow-up of 35 months, they recommended PTAE as first – line therapy and the reservation of surgery for other secondary complications.

Salam et al [9] reported on 14 true visceral aneurysms and two pancreatitis induced pseudoaneurysms that were treated with PTAE with an 81% success rate; they advocated PTAE as the primary treatment modality. Huizinga et al [88] documented four patients with hemorrhage pseudocysts who were treated with PTAE alone with no complications and no death; they suggested that PTAE may obviate the need for emergency surgery[30-33].

TABLE- 34 CURRENT SERIES OUTCOME IN COMPARISON WITH RECENT PUBLISHED SERIES SHOWING OUTCOMES OF ANGIOGRAPHIC EMBOLIZATION FOR PSEUDOANEURYSMAL BLEEDING IN PANCREATITIS:

First author	Recruitment period (years)	Disease status of patients embolized	Number of patients in study (n)	Number of angiograms (n)	Embolization attempted (n)	Successful embolization (n)	Rebleed (n)	Survival of patients embolized successfully
Reber [97] 1999	3	PS	5	5	5	5 (100 %)	0	5 (100 %)
DePerrot[48] 1999	19	CP & AP	10	8	3	3 (100 %)	1(33 %)	2 (66 %)
Gambiez [87] 1997	11	PS & CP	14	14	14	11 (79 %)	0	9 (81 %)
Sand [93] 1997	5	PS	12	10	10	6 (100 %)	0	6 (100 %)
Present Series 2005	**7**	AP, CP, PS	**11**	**8**	**8**	**5 (62.5 %)**	**1 (12.5 %)**	**5 (100 %)**

Table 34. Mortality and Morbidity rates in literature :

Author	Year	Total Patients	Therapy	Patie-nts	Morta-lity	Complications
De Perrot[48]	1999	10	Embolization Surgery	3 7	33% (1/3) 14% (1/7)	1 recurrent hemorrhage / death 2 subphrenic abscesses
Gambiez[88]	1997	14	Embolization	14	7% (1/14)	3 embolization failed to control hemorrhage. 1 duodenal necrosis 1 arotic thrombosis / death
			Surgery	8	13% (1/8)	1 death 1 subphrenic abscess 1 septicemia
Sand[94]	1997	8	Embolization	6	0% (0/6)	1 elevated liver function tests 1 pseudocyst infection
			Surgery	2	0% (0/2)	None
Marshall[93]	1996	5	Embolization	5	0% (0/5)	1 access failure
			Surgery	4	0% (0/4)	1 angiogram failed to show bleeding none
Present Series	**2005**	**16**	EMBOLIZATION	**4**	**0% (0/4)**	**1 infection of thrombosed pseudoaneurysm** **1 recurrent hemorrhage /survived**
			SURGERY	**12**	**0% (0/12)**	**2 external pancreatic fistula/ survived** **1 Intra abdominal collection** **1 Pneumonia** **1 Wound sepsis**

Comparison of mortality and complications between embolization and surgery to control hemorrhage from pancreatitis- associated pseudoaneurysms in 4 case series in the literature.

Mandel et al [89] treated 19 patients with bleeding peripancreatic arterial aneurysms with embolization with a 79% success rate. Gambiez et al [87] treated 14 patients with bleeding pseudocysts complicating chronic pancreatitis by embolization with a success rate of 79%[Table-33]. Angiographic treatment has now been attempted in a few patients with arterial pseudoaneurysmal bleeding after pancreatic / biliary surgery with a success rate of 63% for pseudoaneurysm after pancreatectomy [69].In the present

study, the overall embolization rate was 66.6% with 55.5 % clinical success rate for achieving definitive hemostasis which is comparable to the published series[87-89].The findings of this study, however, do not support PTAE alone as an adequate sole therapy. In the present study, PTAE failed to control hemorrhage in 4 of 9 patients that required conversion to operative intervention. Thus PTAE was associated with a overall failure rate of 44.4% (4/9) in the present series. This failure rate of 44.4% does not support PTAE as an adequate sole primary definitive therapy for hemostasis. Furthermore, successful PTAE does not address the possible need for drainage of the residual thrombosed pseudoaneurysm. In the present series, 16.6% (1 of 6) patients who underwent angiographic embolization, developed a complication related to embolization, i:e infection of residual thrombosed pseudoaneurysm which subsequently required operative intervention in the form of external drainage of retroperitoneal abscess. Out of 6 patients who underwent successful embolization, 33.3% (two of six) patients (case 6, case 14) had pseudoaneurysm with concomitant pseudocyst and underwent PTAE without a drainage procedure. But follow-up CT scans showed spontaneous resolution of pseudocyst in all these 2 patients in the present series. Another one 16.6% (one of 6) patient (case 8) who had pseudoaneurysm with concomitant pseudocyst In this present series required ultrasound guided percutaneous catheter drainage (P.C.D) of infected pseudocyst after successful PTAE for pseudoaneurysm and the follow up CT at 2 months showed complete resolution of pseudocyst. However, Mauro et al [90] reported no further treatment is necessary after successful PTAE of a pseudoaneurysm. But in the current series, two of 6 (33.3%) patients who belong to the sucessful embolization group, ultimately required a pseudocyst / pseudoaneurysm drainage procedure for secondary

complications such as infection. In addition , the management of thrombosed pseudoaneurysm after successful PTAE remains controversial[40]. Elton et al[91] reported on three patients who were successfully treated with PTAE and endoscopic drainage of the pseudocyst, with short term follow up CT scans (2 and 6 months) in two patients demonstrating complete resolution of the pseudocyst. Huizinga.et.al[83] obtained follow up ultrasound scan examinations (at one and two months) in two of the four patients who had no surgical drainage, which showed thrombosed pseudocyst cavity "to be smaller", although two of the four also had recurrent pancreatitis. Success in six patients after PTAE alone prompted Gambiez et.al [87] to investigate the residual cystic cavities documenting that "the volume of pseudocyst decreased in all patients", but no size information was given.

The mean size of the pseudoaneurysm with secondary complication that required operative interventions after PTAE was significantly larger (8cm) than those which required angiographic embolotherapy as definitive therapy without secondary complications (2.3cm).

This would imply that the size of pseudoaneurysm is a factor in determining the need for surgical intervention (excision or drainage procedure) as standard surgical dictum states. We agree with De Perrot et a l[48] who view PTAE as a temporizing measure and suggest that surgical drainage follow as soon as possible, particularly for larger pseudoaneurysms > 10cm. The findings in this series, suggest that it is reasonable to proceed with surgical intervention as soon as possible after PTAE, particularly when the pseudoaneurysm is large >7cm. In the present study, size of the pseudoaneurysm may not be a predictor of success or failure of trans-catheter embolization (mean size 3.8cm versus 6.75cm in present series) which also supported

by Tessier et al study [23] on 10 cases of splenic artery pseudoaneurysm, where pseudoaneurysm diameter is not a predictor of success or failure of transcatheter embolization.

Pseudoaneurysm related to pseudocyst formation is often treated by surgery, rather than transcatheter embolization, because of the difficulty of embolizing large pseudocyst cavities [40]. In the present series, a substantial number of patients 72.7% have associated pseudocyst. From this group of patients, most 75% have undergone surgical intervention with no reported failure. In contrast, embolization failed in a substantial number of patients 50% with associated pseudocyst compared with no reported failure in patients without pseudocyst in the present series. This indicates that pseudoaneurysm associated with pseudocyst most often requires surgical intervention rather than angiographic embolization. But in patients with associated pseudocyst, transcatheter embolization may be appropriate for pseudoaneurysm that ruptures within the pseudocyst, to improve hemodynamic status, enabling less urgent surgical intervention[39,40] . If transcatheter embolization is chosen as therapeutic modality, most authors recommend embolization of only the inflow and outflow feeding vessels, which will result in thrombosis of pseudoaneurysm. For this procedure, the artery from which the pseudoaneurysm originates is selectively catheterized and embolized with coils. This effectively excludes the pseudoaneurysm from the circulation and enables thrombosis. In addition, because the pseudoaneurysm wall is thin, this method aviods the possible pseudoaneurysm rupture by the embolization resulted from inablity to selectively catherize the vessel because of arterial vasospasm, rupture of the pseudoaneurysm during embolization or arterial perforation by the catheter [39,40] . The complications after catheter embolization include pseudoaneurysm rupture,

traumatic dissection, inadvertent embolization of adjacent non bleeding vessels; pain, pancreatic abscess, splenic infarction, splenic abscess (splenic artery embolization); Duodenal necrosis,ischaemic duodenal perforation (Gastroduodenal artery embolization); fatal hepatic necrosis (Hepatic artery embolization); and infection of residual thrombosed pseudoaneurysm which was encountered in one of our patient (case 15) but all these complications are rare[39].

Pseudoaneurysm size is not a determinant of rupture, both the smallest (2cm) and largest (10cm) pseudoaneurysm reported in the present series were ruptured at presentation. In addition, only 2.5% of reported pseudoaneurysms are asymptomatic[23]. In the present series, all patients 100% had symptoms, with the average pseudoaneurysm size of 5.1 cm. (Range 2 – 10cm). Finally, because the natural history of asymptomatic pseudoaneurysms are not known, it is better to treat all pseudoaneurysms, regardless of size or symptoms[23].

In the present series, surgical interventions 75% (n= 12/16) has no reported failure (no recurrent hemorrhage, no recurrence of pseudoaneurysm). Arterial ligation alone for splenic artery pseudoaneurysm has a high failure rate of 43% in Tessier et al study[23]. Some authors achieve good results with arterial ligation and recommend this approach for lesions situated in head and body of the pancreas and for those easily accessible[34]. However, several authors report high rebleeding rates of upto 80%[34]. In our series no rebleeding occurred in two patients treated with trans-cystic suture ligation. The overall surgical morbidity rate was 41.6% (4/12) which is comparable to the reported complication rate of 0-29 % and 87% in the setting of necrotizing pancreatitis in the literature[34]. There were no post operative deaths in the present series but the reported peri operative mortality rate in the literature was 12 – 37% [34]

after surgery. Surgical approach to bleeding pseudoaneurysm is often hazardous or even unsuccessful owing to anatomical inaccessibility of bleeding vessels and in addition surgery is technically difficult because the tissues are hyperaemic, edematous, friable and the tissue planes are difficult to dissect owing to dense inflammatory adhesions[69].

There is still a debate about the best type of surgical procedure for bleeding pancreatic pseudoaneurysms, the two possibilities are resection of the affected pancreatic segment or extracystic / intracystic arterial ligation with external / internal drainage of coexisting pseudocysts[18,33]. The choice between ligation and pancreatic resection remains controversial, but is largely governed by site and accessibility of the bleeding vessel, associated pathology, previous internal drainage, patient condition, surgical experience, and a balance between risk of rebleeding and procedure mortality. Even though endoaneurysmorrhaphy seems more simple to perform, we would not recommend this method because of high rebleeding rates observed in several series[75.] This may be explained by the friability of the peripancreatic tissues and the possible persistance of the enzymatic digestion phenomenon even after pseudocyst drainage [75]and weakness of arterial sutures in these tissues.

Some authors recommend extracystic ligation of the bleeding artery when it is accessible [34]. On the other hand, when a radical surgical procedure is performed, in addition to the intraoperative difficulties, the main drawback of pancreatic resection is the risk of post-operative sepsis/ anastomotic leakage, especially when treating bleeding lesions in the head of the pancreas.Therefore, the present study recommends, intracystic arterial ligation and external drainage for bleeding lesions in the head of pancreas; distal pancreatectomy with splenectomy for bleeding lesions in the tail /

body of pancreas. External pancreatic fistula is the major postoperative complications occurred in 16.6% (present series) of patients which most often heals spontaneously with conservative management.

Long term results after PTAE for pancreatitis related pseudoaneurysm are scarce in the literature. Several authors have do documented recurrent hemorrhage after initial successful PTAE [32,40,79]. The incidence of recanalization requiring repeat PTAE for visceral aneurysms and pseudoaneurysms was reported to be 12% and 37% in two studies [32,79].

In the present series, follow up CT scans revealed no recurrent bleeding or no recurrence of pseudoaneurysm formation after PTAE in 5 patients, with resolution of pseudocyst documented in all 2 patients who underwent successful embolization in the pseudocyst group.

SUMMARY :

The limitations of this study are the small number of patients and the inherent deficiencies of retrospective study single institution observational cohort study. The development of a pancreatitis induced pseudoaneurysm and post – traumatic pseudoaneurysm following pancreatic / biliary surgery and blunt liver trauma are unusual vascular complications. Thus, it is difficult for a single institution to gather a large experience in the management of this uncommon problem.

The most common cause of visceral artery pseudoaneurysm in our study is pancreatic inflammatory disease; however operative / accidental trauma is also a common cause. The peak age incidence for pancreatitis – related pseudoaneurysm is third to fifth decade of life with an alcoholic male preponderance.

The most common pancreatic disease associated with pseudoaneurysm is the alcoholic chronic pancreatitis in the present study. The most frequent type of clinical presentation of pancreatitis – related and trauma – related pseudoaneurysm was gastrointestinal bleeding in the present study. Pseudocysts were the commonest mode of clinical presentation of pancreatitis – related major vascular complications. Majority of patients presenting with pseudoaneurysmal bleed required aggressive recusitation with crystalloids and blood transfusion both in hemosuccus pancreaticus and hemobilia groups. Upper gastro intestinal endoscopy and helical CT scan are the initial diagnostic investigations of choice as it allows subsequent angiography to be targeted in hemodynamically stable patients with suspected pseudoaneurysmal bleed.

The gold standard and most sensitive method for diagnosing bleeding visceral artery pseudoaneurysms is the conventional angiography as it confirms the site and etiology and also it provides the best method of initial treatment. Angiography should

be reserved for those patients shown to have pancreatitis, pancreatic / biliary surgery, liver trauma complicated by hemorrhage, occult blood loss or a pulsatile mass.

Most common bleeding vessel implicated in pseudoaneurysmal bleed is the splenic artery followed by hepatic artery in the present study. All patients with pseudoaneurysm are symptomatic in the present study with an average size of pseudoaneurysm of 5.1cm but only 2.5% are asymptomatic as reported in literature. Pseudoaneurysm size may not be a predictor of the success or failure of transcatheter embolization as there was significant difference in the average pseudoaneurysm diameter in patients in whom embolization was failed and those in whom embolization was successful. Pseudoaneurysm size is not a determinant of rupture as both smallest and largest size of pseudoaneurysms were ruptured at presentation.

Since natural history of asymptomatic visceral artery pseudoaneurysms are not known from our experience and the literature evidence, we recommend repair of all pseudoaneurysms, regardless of size or symptoms. Pseudoaneurysm with concomitant pseudocyst is often treated with surgical intervention rather than transcatheter embolization as it is associated with high failure rate of 50% in the present study. Transcatheter embolization carries a significant failure rate of 75% in the present study when used for treatment of splenic artery pseudoaneurysms, especially when there is associated pseudocyst. Transcatheter angiographic embolization may be ideal for pseudoaneurysm of pancreaticoduodenal arcade as it is associated with high success rate with coils as the embolic agent of choice in the present study.

Angiographic embolization cannot be considered as an adequate sole therapy for pseudoaneurysmal bleed as it is associated with a overall failure rate of 45% in the present series. Angiographic embolization should be considered as first line therapy in

all patients presenting with either sentinel or massive pseudoaneurysmal bleed after adequate resuscitation, as it can achieve temporary hemostatis in 16.6 % of cases and also permanent hemostasis in 83.3% of cases among the embolization group (n=6) in the present study. Surgery should be reserved as the second line therapy except in the setting of actively bleeding lesions with torrential hemorrhage.

The appropriate surgical procedure to treat bleeding lesion in head of pancreas would be intracystic ligation with external drainage and for bleeding lesion in the tail of pancreas is distal pancreatectomy as it has proved durable, save and effective and offers the best chance of cure with no failure to control bleed as exemplified in the present study.

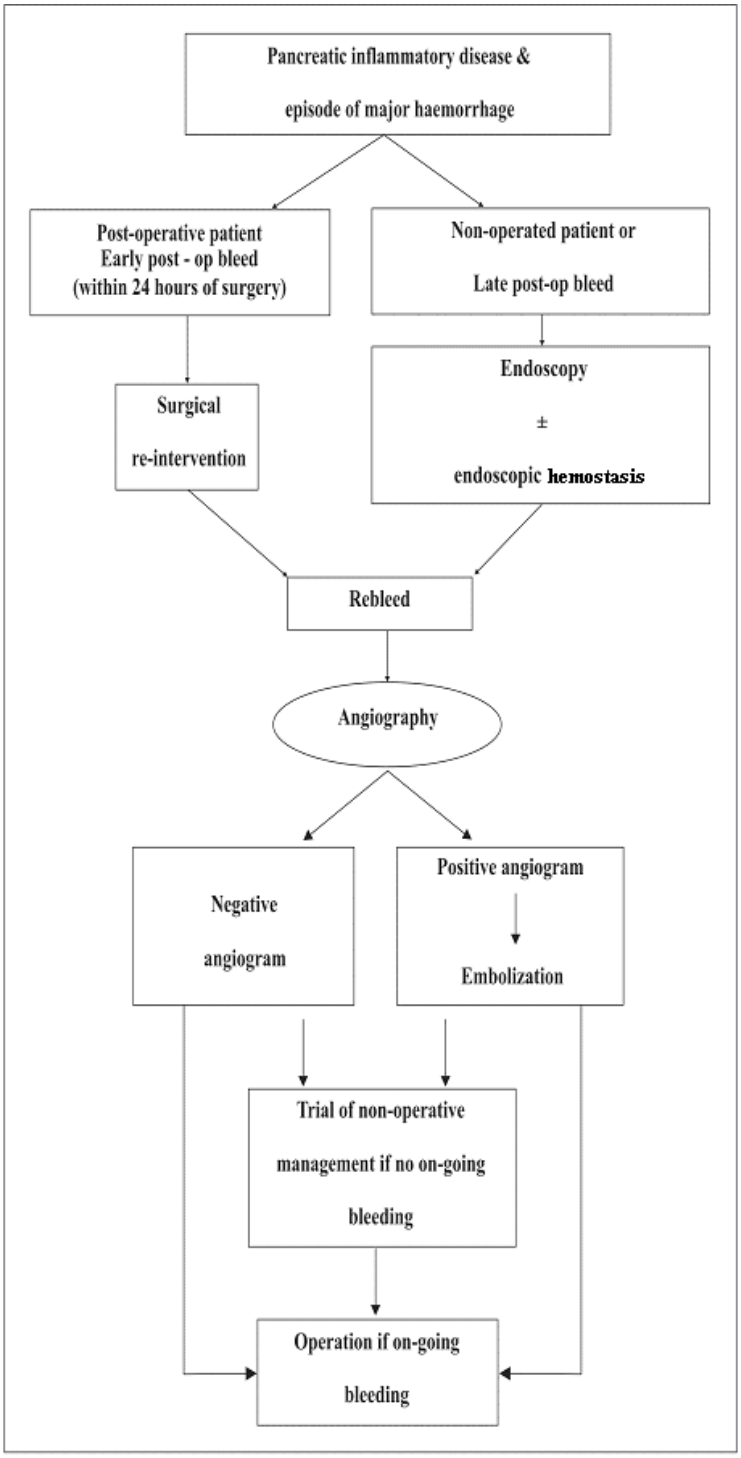

Flow chart-3
Algorithm for the management of patients with major bleeding on a background of pancreatic inflammatory disease.

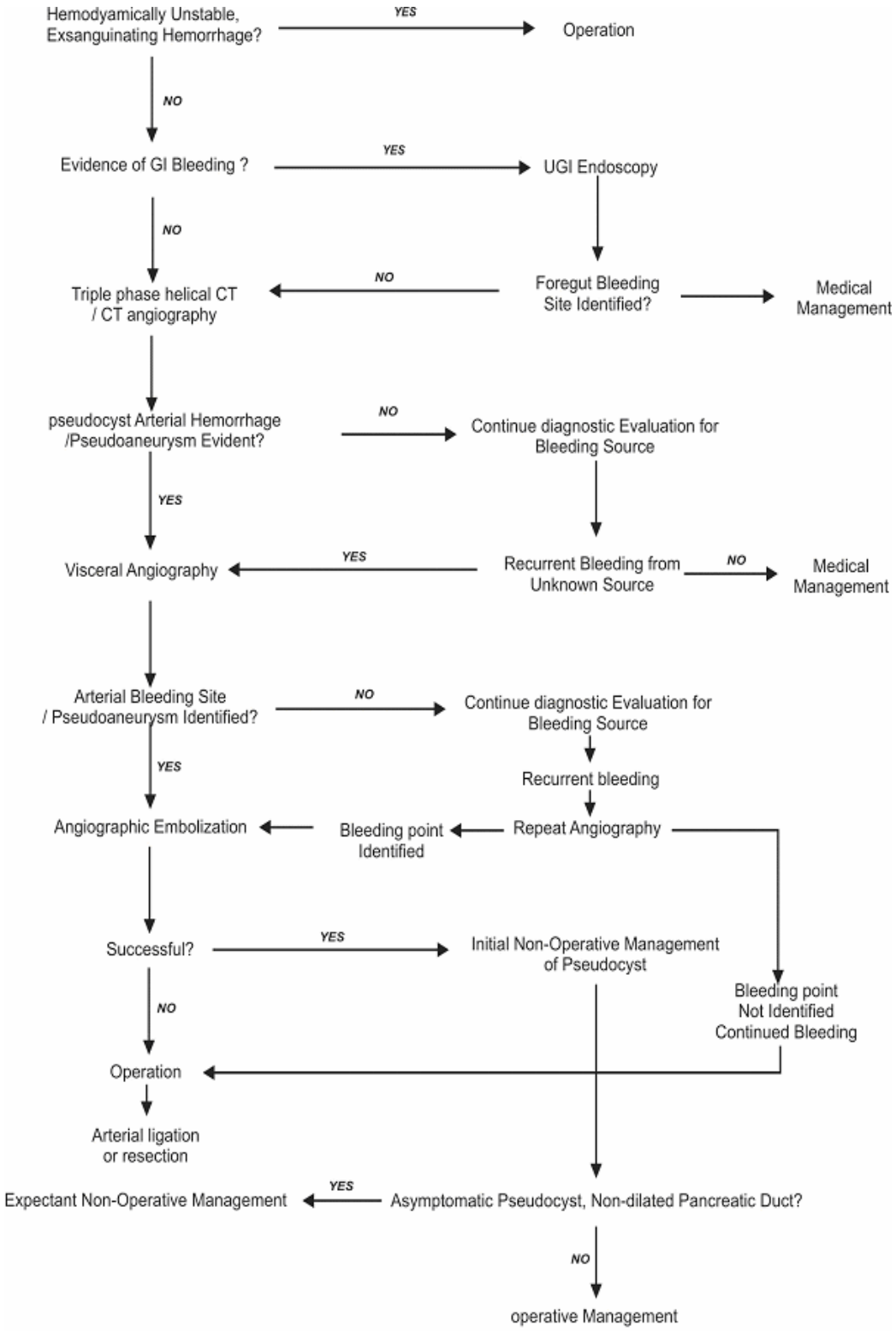

Flow Chart-4

Mannagement algorithm of patient suspected of pancreatic pseudocyst-associated hemorrhage

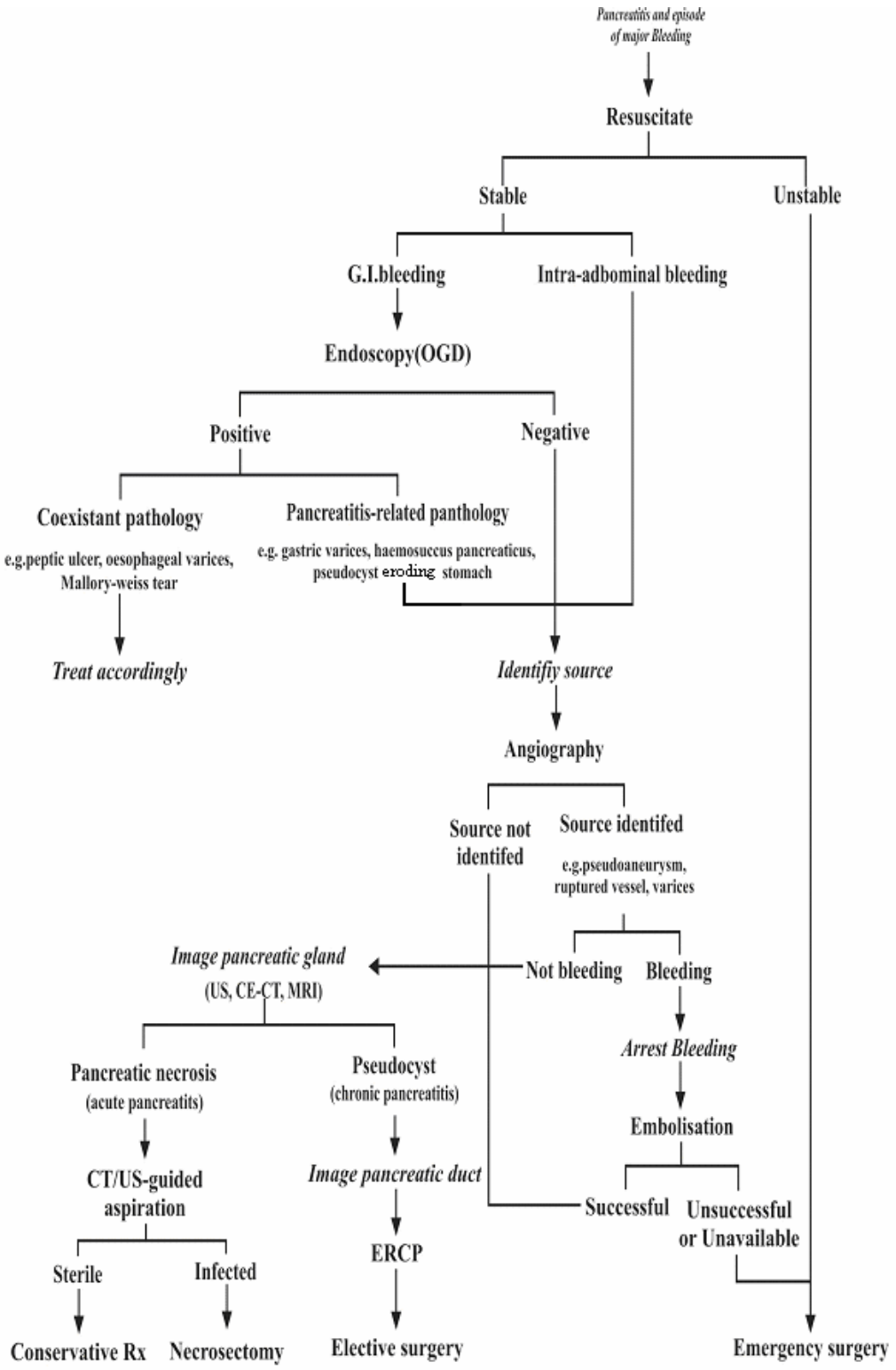

Flow chart-5

Flow chart summarising the management of patients presenting with haemorrhagic complications of pancreatitis.

CONCLUSION:

A high index of suspicion is essential for early prompt diagnosis of pseudoaneurysmal bleed with expeditious investigations and timed therapy in all patients presenting with obscure / overt gastrointestinal / intra abdominal bleeding particularly in the background of pancreatitis and liver trauma and in the postoperative setting of pancreatic / biliary surgery in order to reduce the morbidity and mortality. Non invasive imaging such as Colour Doppler Ultrasound, multislice Helical CT and CT angiography are useful in establishing, the early diagnosis of pseudoaneurysm. Surgery and PTAE play complementary management roles. Selective/Super-selective angiographic trans-catheter coil embolization should be considered as the first line treatment of choice in all patients presenting with sentinel or massive pseudoaneurysmal bleeding after adequate resuscitation because,(1)it is a safe ,minimally invasive and effective alternative therapy to surgery (2) it can achieve temporary hemostasis and sometimes even permanent hemostasis, (3) it allows hemodynamic stabilization and prevents the need for an urgent high risk surgery(converting a high risk emergency surgery with its attended high morbidity / mortality into an elective surgery with a more favourable outcome), (4) it has an impressive therapeutic success rate coupled with a negligible morbidity and mortality, (4) it is also prudent to regard angiographic embolization as“buying time” for careful disease re-evaluation in order to avoid inappropriate surgery in an emergency situation. Surgery should be reserved only for (i) actively bleeding lesions unsuitable for angioembolization with significant haemodynamic instability caused by and exsanguinating / torrential haemorrhage that obviates the need for angiography(ii) Unsuccessful / failed / non availability of therapeutic angiographic embolization. (iii) secondary complications such as extrinsic compression or sepsis.

Bibliography

1.Settembrini PG, Jausseran J-M, Roveri S, et al. Aneurysms of anomalous splenomesenteric trunk: Clinical features and surgical management in two cases. J Vasc surg 1996;24:687-92

2.Azhar Hossain, Ernaned.Reis, Sandeep P. Dave., B.s., Morris D.Kerstien, Larry H.Hollier, Visceral Artery Aneurysms : Experience in a Tertiary – Care Center. Am Surg 2001; 67(5): 432 – 437.

3. Messina LM, Shanley CJ, Visceral artery aneurysms. Surg Clin North Am 1997;77:425-42

4. Kopatsis A, D'Anna JA, Sithian N, Sabido F. Superior mesenteric artery aneurysm: 45years later. Am surg 1998;64:263-6

5.Whitehouse WM, Graham LM, Stanley JC. Aneurysms of the coliac, hepatic and splenic arteries. In: Bergan JJ, Yao JST Aneurysms: Diagnosis and treatment. New York: Grune & Startone, 1982;pp405-19.

6. Langlois NE, Miller ID. Intramural gastric hematoma from an atherosclerotic aneurysm of a gastric artery. Am J Gastroenterol 1993;88:613-4.

7. Quandalle P, Chambon JP, Marache P, et al. Pancreatico duodenal artery aneurysms associated with celiac artery stenosis: Report of two cases and review of the literature. Ann Vasc Surg 1990;4:540-5.

8. Natto A, Toyoto N, Ito K. Embolization of a ruptured middle colic artery aneurysm. Cardiocasc Intervent Radiol 1995;18:56-8.

9.Salam TA, Lumsden AB, Martin LG, Smith RB III. Non operative management of visceral aneurysms and pseudoaneurysms, Am J Surg 1992;164:215-19.

10. Stanley JC, Zelenock GB. Splanchic artery aneurysms. In: Rutherford RB, editor. Vascular surgery. 4th ed. Philadelphia (PA): Saunders;1995. p 1124-39.

11. Bornet P, Medjoubi S, Tissot A, Hibon J, Terris C. giant aneurysm of the splenic artery: a case report. Angiology 2000;51:343-7.

12. McDermott VG, Shlansky – Goldberg R, Cope C. Endovascular management of splenic artery aneurysm and pseudoaneurysms. Cardiovascular Intervent Radiol 1994;17:179-84.

13. DeSantis M, Ariosi P, Ferretti A, Casolo A, Manenti A, Romagnoli R. embolization of giant aneurysm and pseudoaneurysm of the splenic artery [letter]. Eur Radiol 2000;10:1032.

14. Lipuma JP, Sachs PB, Sands MJ, Stuhmiller S, Herbener TE. Splenic artery pseudoaneurysm associated with pancreatitis. AJR 1997;169:262-3.

15. Trastek VF, Paielero PC, Bernatz PE. Splenic artery aneurysms. World J Surg 1985;9:378-83.

16. Aiden M, Callinan, Jaswinder S, Samra and Ross C, Smith, Hemosuccus pancreaticus.

17. Suter M, Doenez F, Chapuis G, Gillet M, Sandblom P. hemorrhage into the pancreatic duct (Hemosuccus pancreaticus). Recognition and management. Eur. J Surg 1995;161:887-62.

18. Hans G Beger, AL Warshaw, MW Buchler, DL Carr –locke, JP Neoptolemos, MG Sarr. The pancreas, Blackwell science Ltd. First edition 1998;606-613

19. Bender JS, Bouwman DL, Levison MA, Weaver DW. Pseudocysts and pseudoaneurysms: Surgical strategy. Pancreas 1995;10:143-7

20. T Waslen, K Wallace, B Burbridge, S Kwauk, pseudoaneurysm secondary to pancreatitis presenting as GI bleeding Abdom Imaging 1998; 23:318-321

21. Juhani A. Sand, Seppo K, Seppanen, and Isto H. Nordback, Initial experience of a treatment protocol. Pancreas 1997;14(2):187-191

22. Woods MS, Traverso LW, Kozarek RA, Brandabur J, Hauptmann E, Successful treatment of bleeding pseudoaneurysms of chronic pancreatitis. Pancreas 1995;10:22-30

23. Tessier DJ, Stone WM. Fowl RJ. Abbs MA. Andrews JC. Bower TC. Gloviezki P Clinical features and management of splenic artery pseudoaneurysm: case series and cumulative review of literature. J Vasc Surg 2003;38:969-74.

24. Benoit L, Fraisse J. Cercueil JP, Cornet A. Cuisenier J. Gastroduodenal artery aneurysm and chronic pancreatitis. A case and review of the literature. Ann chir 1996;50:918-20.

25. Mortia R, Muto N, Konagaya M, Honda T. Miyazawa M, Nakazawa S, et al. successful transcatheter embolization of pseudoaneurysm associated with pancreatic pseudocyst. Am J Gastroenterol 1991;86:1264-7

26. Chiou AC, Josephs LG, Menzoian JO. Inferior pancreatico duodenal artery aneurysm: Report of a case and review of the literature. J Vasc Surg 1993;17(4):784-788.

27. Hama Y, Iwasaki Y, Kaji T. Hatsuse K, Kusano S. Coil caompaction after embolization of the superior mesenteric artery pseudoaneurysm. Eur Radiol 2002;12:S189-S191.

28. Cowan S, Kahn MB. Bonn J, Becker GJ, Dimizio P. Leichter R, Carabasi RA superior mesenteric artery pseudoaneurysm successfully treated with polytetrafluoroethylene covered stent. J Vasc Surg 2002;35:805-7

29. Fernandez –Cruz L, Pera M, Vilella A, Llovera JM, Navasa M, Teres J, Hemosuccus pancreaticus from a pseudoaneurysm of the hepatic artery proper in a patient with a pancreatic pseudocyst. Hepatogastroenterology 1992;39:149-51.

30. Kapoor S, Rao P, Pal S, Chattopadhyar TK. Hemosuccus pancreaticus: an uncommon cause of gastrointestinal hemorrhage. A case report JOP. J pancreas (online) 2004;5:373-6.

31. Funahanshi S, Yukizane T, Yano K, Yamaga H, Muto Y, Ikeda T, et al an aneurysm of the right gastroepiploic artery. J Cardiovasc surg 1997;38:385-8

32.Jafar Golzarian Nicole Nicaise, Jacques Deviere, Mare Ghysels et al.Transcatheter Embolization of pseudoaneurysms complicating pancreatitis. Cardiovasc Intervent Radiol (1997) 20: 435-440.

33. Jhon.M. Howard, Y.Idezuki, Ingemar Ihsc; R.A prinz,Surgical disease, of the Howard book.Pancreas: Third editioy 1998 williams& wilkins.(18,33) 311-312.

34. BJ Ammori FRCS, DJ Alexander, M Madan. Hemorrhagic complications of pancreatitis: presentation, diagnosis and management.

35. Yokoyama I, Hashmi A, Darasarathy S et al. Wirsungorrhagia or hemoductal pancreaticus: report of a case and review of the literature. Am J Gastroenterol.1984;79:764 -8

36. E.J.Balthazar Vascular and haemorrhagic complications of pancreatitis. Radiol Clin N Am 40 (2002) 1211 – 1227.

37. N-M Law, M.L. Freeman. Complications of pancreatic pseudocysts. Gastroenterol Clin N Am 32 (2003) 1183 – 1189.

38. Pitkadaranta P, Haapiainen R, Kivisaari L, Schroder L.Diagnostic evaluation and aggressive surgical approach in bleeding pseudoaneurysms associated with pancreatic pseudocysts. Scand J Gastroenterol 1991; 26:58-64.

39. Man Chung Han, Jae Hy ung Park – Interventional Radiology , Ilchokak 1999: 39 - 51.

40. Carr JA, Cho J, Shepard AS, Nypaver TJ, Reddy DJ. Visceral pseudoaneursyms due to pancreatic pseudocysts: rare but lethal complications of pancreatitis J Vasc Surg. 2000;32:722-730.

41. White AF, Baun S.Buranasir A.Aneurysm secondary to pancreatitis. AJR 1976 ; 127 : 393 – 6.

42. Savastano S, Feltsrin GP, Antonio T, Miotto D, Chiesura – Corona M, Castellan L. Arterial complications of pancreatitis : diagnostic and therapeutic role of radiology. Pancreas 1993; 6: 687 – 92.

43. Steckman ML.Dooley MC, Jaques PF, Powell DW.Major gastrointestinal hemorrhage from peripancreatic blood vessels in pancreatitis. Treatment by embolotherapy. Dig Dis Sci 1984; 29: 486 – 97.

44. Hofer BO, Ryan JA, freeeny PC. Surgicacl significance of vascular changes in chronic pancreatitis. Surg Gynecol Obstet 1987; 164: 499-505.

45. El Hamel A, Parc R, Adda G, Bouteloup PY, Huguet C, Malafosse M. Bleeding pseudocysts and pseudoaneurysms in chronic pancreatitis. Br J Surg 1991;78:1059-63

46. DeFilippi VJ, Vargish T, Block GE, Massive gastrointestinal hemorrhage in pancreatitis secondary to visceral artery aneurysms. Am Surg 1992;58:618-21.

47. Flati G, Salvatori F, Parowska B, et al. Severe hemorrhagic complications in pancreatitis. Ann Ital Chir 1995;66:233-7

48. M.de Perrot, T.Berney, L.Buhler, X.Delgadillo, G.Mentha and P.Morrel. Management of bleeding pseudoaneurysms in patients with pancreatitis. BJS 1999, 86, 29 – 32.

49. Stabile BE, Wilson SE, Dibas HT Reduced mortality from bleeding pseudocysts and pseudoaneurysms caused by pancreatitis. Arch Surg 1983 118: 45 – 51.

50. Boudghene F, L'Hermine C, Bigot JM. Arterial complications of pancreatitis: diagnostic and therapeutic aspects in 104 cases. J Vasc Interv Radiol 1993;4:551-8

51. Bresler L, Boissel P, Grosdidier J. Major hemorrhage from pseudocysts and pseudoaneurysms caused by chronic pancreatitis: surgical therapy. World J Surg 1991;15:649-53.

52. I-Hua Huang MD, Darryl A.Zuckerman, MD, and Jeffrey B.Mathews, MD, Cincinnati, Ohio. Occlusion of a giant splenic artery pseudoaneurysm with percutaneous thrombin collagen injection. J Vasc Surg 2004; 40:584 – 7.

53.M.H.A Green, R.M. Duell, C.D.Johnson and N.V.Jamieson. Haemobilia Review, BJS 2001; 88, 773 – 786.

54. Iannelli A, Karimdjee BS , fabiani EI et al. Hemobilia due to pseudoaneurysm of right hepatic artery following laparoscopic Cholecystectomy. Gastroenterol clin Biol. 2003; 27: 341-3.

55. Quinke H. Ein fall von aneurysm der leberarterie. Klin Wonchenschr 1871: 8: 349 – 51.

56. Yoshida J. Donahue PE, Nyhus LM.Hemobilia: review of recent experience with a world wide problem. Am Gastroenterol 1987; 82 : 448 – 53.

57. Sandblom P.Latrogenic hemobilia.Am Surg 1986: 151 : 754 – 8.

57. Samuels RS, Shriver M, patel NH.Hemobilia after a gunshot injury to the liver. AJR Am J Roentgenol 1996; 166: 1304

58. Kambayashi M, Yong W, Watanable K, Alam S.Hemobilia due to gallbladder contustion following blunt trauma – sonagraphy and CT scanning for early detection: case report. Trauma 1993; 34: 440 -2.

59. Sax SL, Arthey PA, Lamki N,Cadavid GA.Sonographic findings in traumatic hemobilia: report of two cases and review of the literature. Clin Ultrasound 1988; 16: 29 – 34.

60.Merrell SW, Schneider PD.Hemobilia – evolution of current diagnosis and treatment. West J Med 1991; 155: 621 – 5.

61. Nicholson T, Travis S, Ettles D.Dyet J, Sedman P, Wedgewood K et al. Hepatic artery angiography and embolisation for hemobilia following laparoscopic cholecystectomy. Cardiovasc Intervent Radiol 1999; 22: 20 - 4.

62. Dousset B, Sauvanet A, Bardou M, Legmann P, Vilgrain V, Belghiti J. Selective surgical indications for iatrogenic hemobilia. Surgery 1997: 121 : 37 – 41.

63. Horak D, Guseinov E, Adamyan A, Titova M, Danilov M, Trostenyuk N et al. Poly (2 – hydroxyethyl methacrylate) particles for management of hemorrhage of complicated origin: Treatment of hemobilia. J Biomed Mater Res 1996; 33: 193 – 7.

64. Hubens A, De Schepper A. Hepatic artery aneurysm: a pitfall in biliary surgey. Br J Surg 1976; 66: 259 – 61.

65. J.Moodley, B.Singh, S. Lalloo, S.Pershad and J.V.Robbs.Non – operative management of haemobilia: BJS 2001, 88, 1073 – 1076.

66. Van Berge Henegouwen MI, Allema JH, van Gulik TM,Verbeek PCM, Obertop H, Gouma DJ.Delayed massive haemorrhage after pancreatic and biliary surgery Br J Surg. 1995; 82 : 1527 – 1531.

67. Brodsky JT, Turnbull AD.arterial hemorrhage after pancreatoduodenectomy: the ” sentinel bleed.” Arch Surg. 1991; 126: 1037 – 1040.

68.Jeffrey S.Bender, David L. Bouwman, Marc A. Levison, and Donald W.Weaver. Pseudocysts and Pseudoaneurysms : Surgical Strategy : Pancreas 1995 ; 10 (2) 143 - 147.

69.Norithiro Sato, MD; Koji Yamaguchi, MD; Shuji Shimizu MD; Takashi Morisaki, MD; Kazunori Yokohata MD; Kazuo Chijiiwa, MD; Masao Tanaka,MD, Coil Embolization of bleeding visceral pseudoaneurysms following pancreatectomy: Arch Surg.1998; 133: 1099 – 1102.

70. Naoki Hashimoto, Seiji Haji, Hideaki Nomura, Mitio Kato, Harumasa Ohyanagi. Arterial Hemorrhage by pseudoaneurysms following pancreatoduodenectomy: Hepato – Gastroenterology 2004; 51 : 1847 – 1848.

71.Eseroghene Otah, Brain J. Cushin, Grogory N. Rozenblit, Richard Neff, Kenneth E.Otah, Avram M. Cooperman. Visceral artery pseudoaneurysms following pancreatoduodenectomy: Arch Surg. 2002; 137: 55 – 59.

72.Rumstadt B. Schwab M.Korth P, et al. Hemorrhage after pancreaticoduodenectomy, Ann Surg 1998; 227 : 236 – 41.

73. Okuno A, Miyazaki M, Ito H, et al. Non surgical management of ruptured pseudoaneurysm in patients with hepatobiliary pancreatic diseases : Am J Gastroenterol 2001 ; 96 (4) : 1067 – 71.

74.Peter U.Reber, Hans U.Baer, Ameet G.Patel, FRCS, Jurgen Triller, and Markus W.Buchler,PHD. Life – threatening upper gastrointestinal tract bleeding caused by ruptured extra-hepatic pseudoaneurysm after pancreatoduodenectomy: Surgery 1998; 124: 114 – 5.

75. Bradley EL III. A clinically based classification system for acute pancreatitis. Summary of the International Symposium on Acute pancreatitis, Atlanta 1992. Arch Surg 1993;128: 586-90.

76. Singer MV, Gyr K, Sarles H. Revised classification of pancreatitis. Report of the Second International Symposium on the Classification of pancreatitis in Marseille, France,28-30 Gastroenterology 1985; 89:683-5.

77. Srinivasan Balachandra, Ajith K. Siriwardena et al. Systematic appraisal of the management of the major vascular complications of pancreatitis. Am J Surg 2005; 190: 489-495.

78. Feong Kim, Fae –Kyu Kim, Woong Yoon, Suk- Hee Heo et al. Transarterial Emolization for postoperative Hemorrhage After Abdominal Surgery. J Gastrointest Surg 2005; 9: 393-399.

79. Garth C. Beattie, Jonathan G. Hardman, Doris Redhead, Ajith K. Siriwardena, et al. Evidence for a central role for selective mesenteric angiography in the management of the major vascular complication of pancreatitis. Am J Surg 2003; 185: 96-102.

80. Agarval .P, Phadke R.V. , Baijal.S.S, Yachha.S.k, Sharma B.C, Poddar.U. Calcific pancreatitis-induced gastroduodenal artery pseudoaneurysm: non-surgical management. Pediatr Radiol 1994; 24: 539-40.

81.Ehrensperger.J. Massive bleeding into the upper gastrointestinal tract in chronic calcifying pancreatitis in the child. Eur J Pediatr Surg 1992; 2: 141-3.

82. Santos JC Jr, Feres O, Rocho JJ, Aracava MM. Massive lower gastrointestinal hemorrhage caused by pseudocyst of the pancreas ruptured into the colon. Report of two cases. Dis Colon Rectum 1992; 35: 75-7.

83. Parks. RW, Chrysos. E, Diamond. T, Management of liver trauma. Br J Surg 1999; 86: 1121-35.

84.Croce. MA Fabian .TC, Spiers.JP, Kudsk KA. Traumatic hepatic artery pseudoaneurysm with hemobilia. Am J Surg 1994; 168: 235-8.

85. Stewart BT, Abraham Thomson KR, Collier NA. Postcholecystectomy haemobilia:enjoying a renaissance in the laparoscopic era ? Aust N Z J Surg 1995 ; 65: 185-8.

86. Starling JR, Crummy AB. Haemosuccus pancreaticus secondary to ruptured splenic artery pseudoaneurysm. Dig Dis Sci 1979;24:726-9.

87. Gambiez LP, Ernst OJ, Merlier OA, Porte HL. Arterial embolization for bleeding pseudocysts complicating chronic pancreatitis. Arch Surg 1997; 132:1016-21.

88. Huizinga WK, Kalideen JM, Byer JV, Bell PS, Baker LW. Control of major haemorrhage associated with pancreatic pseudocysts by transcatheter arterial embolization. Br J Surg 1984; 71:133-6

89. Mandel SR, Jaques PF, Sanofaky S, Mauro MA. Nonoperative management of peripancreatic arterial aneurysms: a 10- years experience. Ann Surg. 1987; 205:126-128.

90. Mauro MA, Jaques PF. Transcatheter management of pseudoaneurysms complicating pancreatitis. J Vasc Interv Radiol 1991; 2: 527-32.

91. Elton E, Howell DA, Amberson SM, Dykstra D. Combined angiographic and endoscopic management of bleeding pancreatic pseudoaneurysms. Gastrointest Endosc 1997; 46:544-9.

92. Marshall GT, Howell DA, Hansen BL, Anderson SM, Abourjaily GS, Bredeberg CE. Multidisciplinary approach to pseudoaneurysms complicating pancreatic pseudocysts. Arch Surg 1996;131:278-83.

93. Sand J, Seppanen SK, Nordback IH. Intracystic hemorrhage in chronic pancreatic pseudocyst: Initial experiences of a treatment protocol. Pancreas 1997;14:187-91.

94. Balsarkar DJ, Joshi MA. Rupture of splenic artery pseudoaneurysm presenting with massive upper gastrointestinal bleed. Am J Surg 2002; 183:197-8.

95. Koizumi J, Inoue S, Yonekawa H, et al. Hemosccus pancreaticus:Diagnosis with CT and MRI and treatment with transcatheter embolization. Abdom Imaging 2002; 27:77-81.

96.Urakami A, Tsunoda T, Kubozoe T, et al.Rupture of a bleeding pancreatic pseudocyst into the stomach. J Hepatobiliary Pancreat Surg 2002;9:383-5.

97. Reber P, Patel AG, Baer HU, et al. Acute hemorrhage in chronic pancreatitis: Diagnosis and treatment options including superselective microcoil embolization. Pancreas 1999;85:217-21.

98. Rantala A, Ovaska J. Major haemorrhage associated with a pseudocyst in chronic pancreatitis: A gastro-surgical challenge. Ann chir Gynaecol 1996; 18:399-402.

99. RØkke O, SØndenaa K, Amundsen SR, et al. Successful management of eleven splanchnic artery aneurysms. Eur J Surg 1997;163:411-7.

MASTER CHART - I

Patient	Age	Gender	Clinical Presentation													Blood Investigations									
			Nausea	vomit	back pain	abd. pain	Jaundice	H.em.	Malena	Hemop	H.chezia	Anemia	fever	SB via	MB via abd.	Hb 1	Hb 2	TC	S.Bili	S.AST	S.ALT	SAP	PT	B Obs.	GOO
1	40	M	2days	2days	1mon	2 yrs	---	+	+	-	-	+	--	--	--	10.2	5.9	10,600	17	26	22	102	N	--	--
2	42	M	2days	3days	6mon	5 yrs	---	--	--	+	+	+	--	--	--	10.8	6.2	10800	18	24	23	112	N	--	--
3	40	F	2days	3days	--	10 days	---	+	+	-	-	+	--	--	--	9.6	4.6	11000	26	22	20	126	N	--	--
4	32	F	2days	3days	---	3 monm	+	+	+	-	-	+	+	--	--	11.4	8.4	9800	81	42	42	480	N	+	--
5	47	M	3days	3days	10days	2 yrs	---	--	--	-	-	+	--	--	--	11.2	7.2	9600	17	24	30	136	N	--	--
6	31	M	--	--	3mon	2.5 yrs	---	+	+	-	-	-	--	--	--	11.6	8.2	9400	18	26	28	112	N	--	--
7	36	F	3days	3days	---	2 mon	---	+	+	-	-	-	--	--	--	12.6	8.2	10200	38	30	30	114	N	--	--
8	43	M	--	--	3mon	2 yrs	0	+	+	-	-	-	--	--	--	13.3	8	15000	65	20	58	306	N	+	+
9	39	M	--	--	2mon	3 yrs	---	+	+	-	-	-	--	--	--	12.4	7.8	12600	15	30	26	142	N	--	--
10	18	M	5days	2days	2mon	3 yrs	---	+	+	-	-	+	--	--	--	12.8	7.4	11400	17	35	24	138	N	--	--
11	39	M	2days	4days	3mon	3 yrs	---	+	+	-	-	-	--	--	--	11.4	7	12000	16	32	20	86	N	--	--
12	12	F	2days	3days	2mon	4 yrs	---	+	+	-	-	-	--	--	--	12	8.4	10400	17	33	22	116	N	--	--
13	37	M	2days	3days	---	1.5 mon	---	+	+	-	-	+	--	--	--	10.4	7.4	11600	42	42	26	118	N	--	--
14	53	M	2days	5days	3mon	4 yrs	---	+	+	-	-	-	--	--	--	13.2	7.9	9800	17	35	24	120	N	--	+
15	51	M	--	--	1mon	2 yrs	---	--	+	-	-	-	--	--	--	10.8	7.6	13600	16	34	22	96	N	--	--
16	53	M	--	2days	--	15 days	---	--	---	-	-	+	+	62 day	203 days	9.8	8.2	5800	22	24	20	86	N	--	--

Vomit- Vomitting in duration, Abd.pain - Abdominal pain, H.em – Hematemesis, Hemop – Hemoptysis, H.chezia – Hematochezia, SB - Sentinel Bleed, MB - Major Bleed, HB - Hemoglobin g/dl, TC - Total White Cell Count cells / cmm^3, S.Bili - Serum Bilirubin μmol/l, S.AST - Aspartate aminotransferase (IU/L), S.ALT - Alanine aminotransferase (IU/L), SAP - Serum Alkaline Phosphatase (IU), PT - Prothombin time (secs), B.Obs. - Biliary Obstruction, GOO - Gastric Outlet Obstruction

Case - 1 Splenic artery pseudoaneurysm
Distal pancreatectomy done

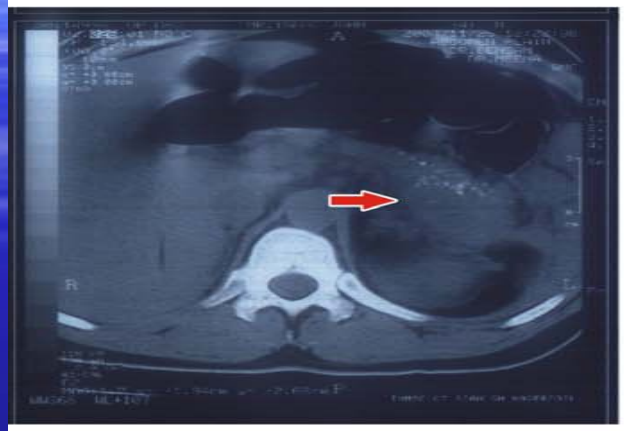

CT Scan Showing Splenic artery pseudoaneurysm in the tail of pancreas

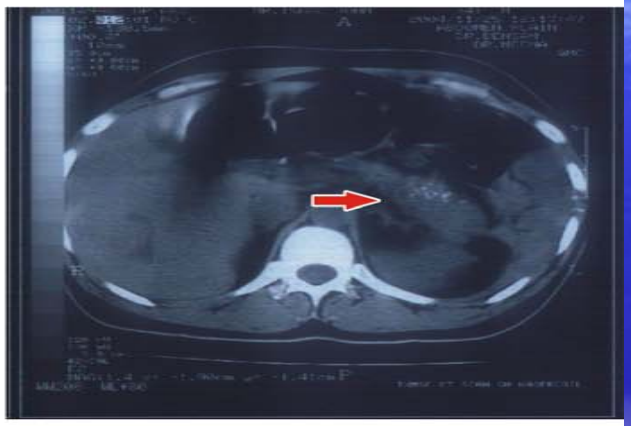

CT Scan Showing Splenic artery pseudoaneurysm in the tail of pancreas

Case 6: CT Angiogram showing splenic artery pseudoaneurysm

Case -2 Splenic artery pseudoaneurysm With hemoptysis

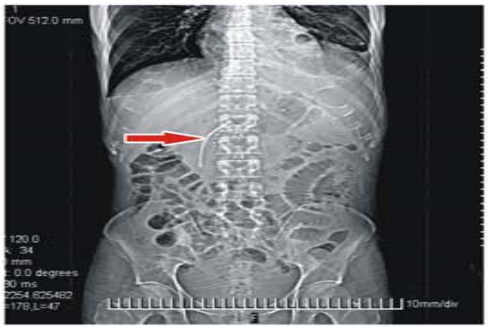

Scannogram Showing pancreatic duct stent in-situ following extracorporeal pancreatic lithotripsy for chronic pancreatitis

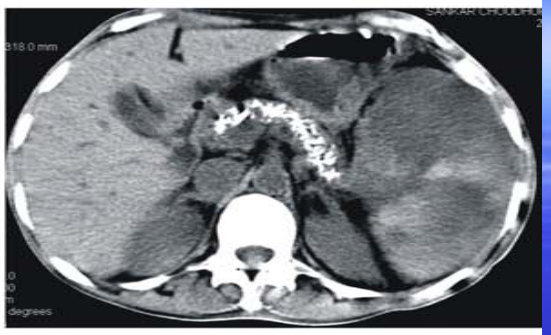

CT Scan Showing Multiple Diffuse Calcification in entire pancreas

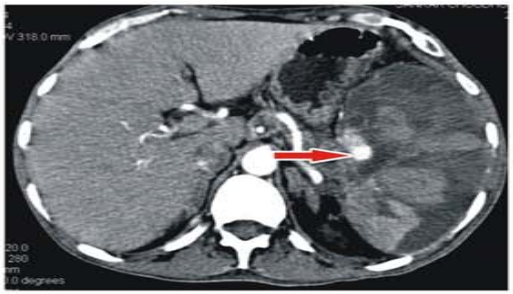

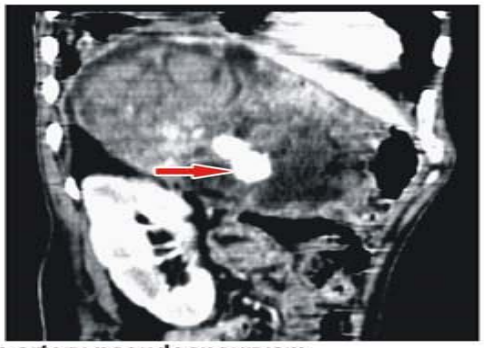

CT Angiogram showing Splenic artery pseudoaneurysm in tail of pancreas (Arrow)

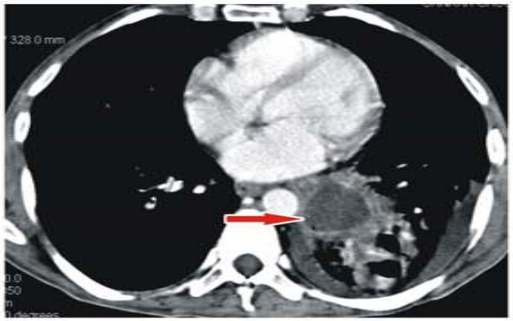

Plain and Contrast CT Chest Showing Communication of Splenic artery pseudoaneurysm With left lung(Arrow)

Case -2 Splenic artery pseudoaneurysm With hemoptysis - distal pancreatectomy done

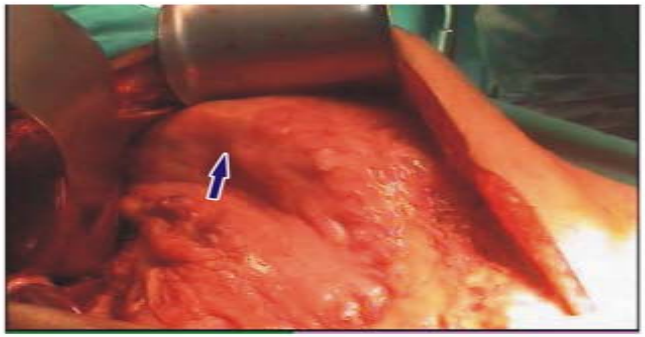

Splenic artery pseudoaneurysm

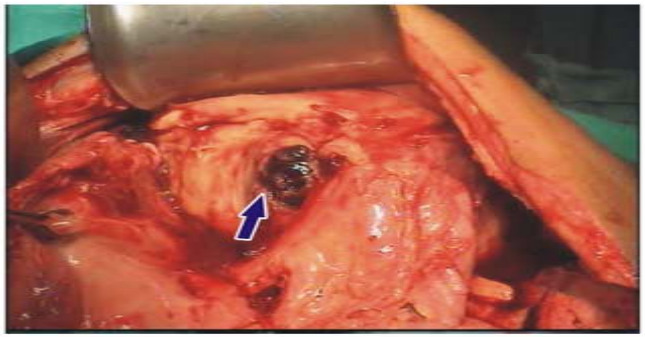

Blood clots seen within the pseudoaneurysmal sac

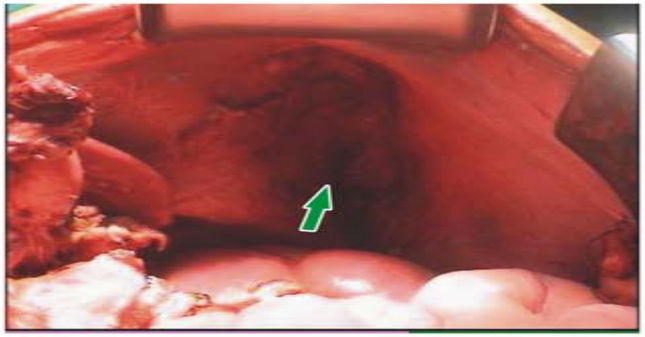

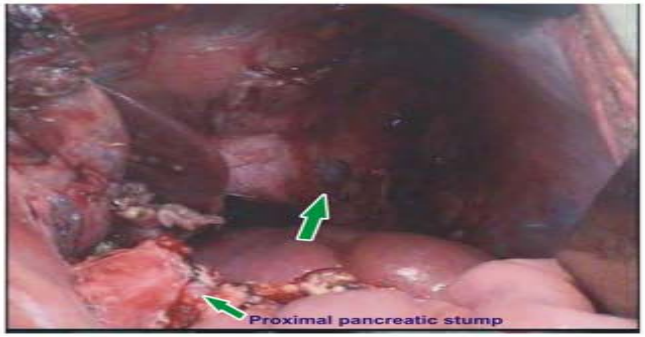

Splenic artery pseudoaneurysm seen eroding through left dome of diaphragm communicating with left lung

Specimen of Splenic artery pseudoaneurysm with blood clots

Case -3 Right Hepatic artery Pseudoaneurysm Following Blunt Liver Trauma

Patient underwent open cholecystostomy and common bile duct exploration with T-tube drainage and peritoneal drainage elsewhere for hemobilia following blunt liver trauma

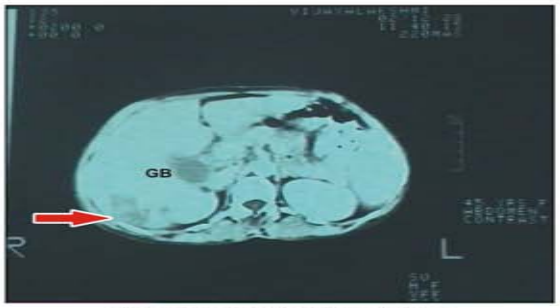

CT scan showing liver injury

T-tube Cholangiogram shows extravasation of contrast into liver

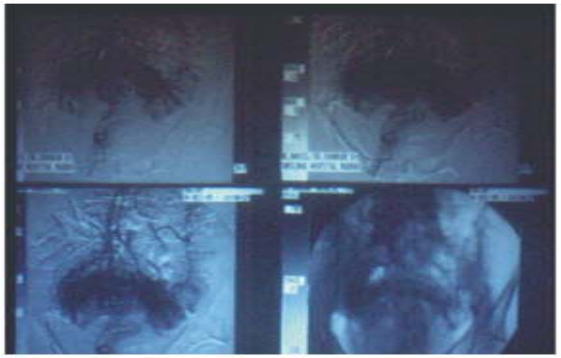

Angiographic embolization Attempted but failed

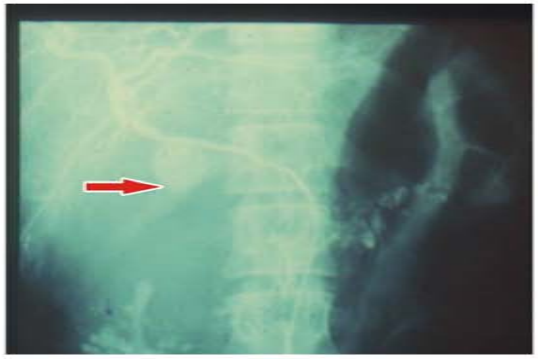

Coeliac angiogram showing Right Hepatic artery Pseudoaneurysm

Case -3 Right Hepatic artery Pseudoaneurysm Following Blunt Liver Trauma - Right Hepatectomy

Specimen of right hepatectomy showing Right Hepatic artery Pseudoaneurysm (Arrows)

Case -4 Right Hepatic artery Pseudoaneurysm Following Laparoscopic cholecystectomy

(Combined Right Hepatic artery and Major Bile duct injury)

CT Scan Shows a mixed density lesion due to a large blood clot in right subhepatic space

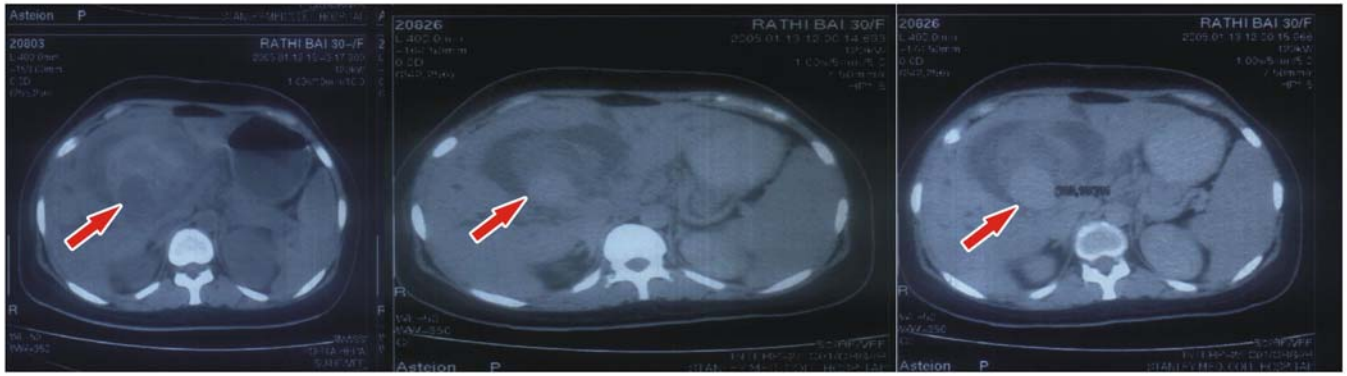

Dynamic CT Scan shows Right Hepatic artery Pseudoaneurysm- central area of hyperattenuation filled with contrast in the dalayed phase due to extravasation of contrast.(Arrow)

Case -4 Right Hepatic artery Pseudoaneurysm Following Laparoscopic cholecystectomy

(Combined Right Hepatic artery and Major Bile duct injury)

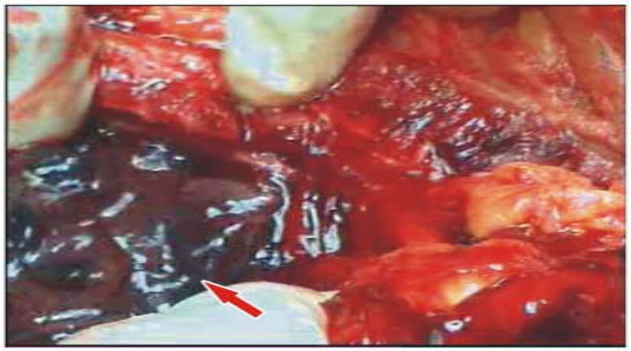

Large Blood Clot(Arrow) Seen in Right subhepatic space With Bilioma(Infected Bile)

Once clot is removed, figure shows torrential bleeding(Arrow) from Right Hepatic artery Pseudoaneurysm

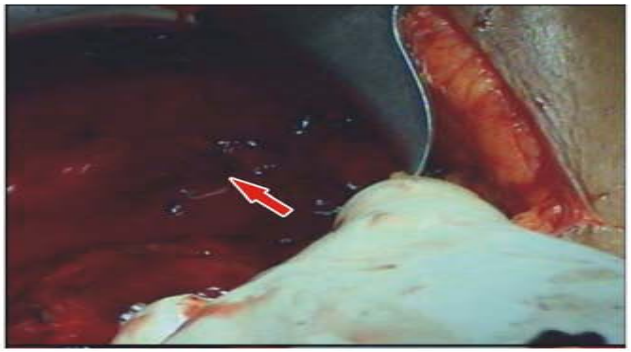

Actual site of Pseudoaneurysm(Arrow) after removal of blood clot surrounding it

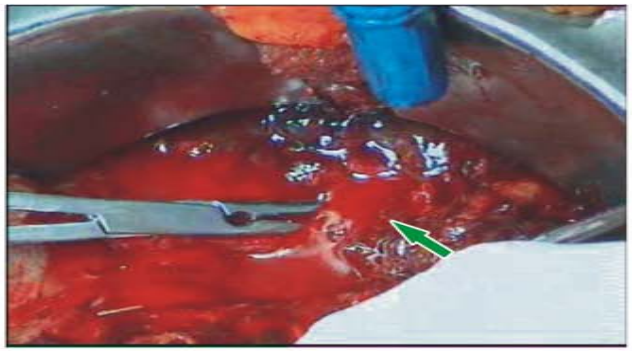

Vascular clamp applied at base of origin of Pseudoaneurysm(Arrow) for excision after suture ligation of bleeding vessel

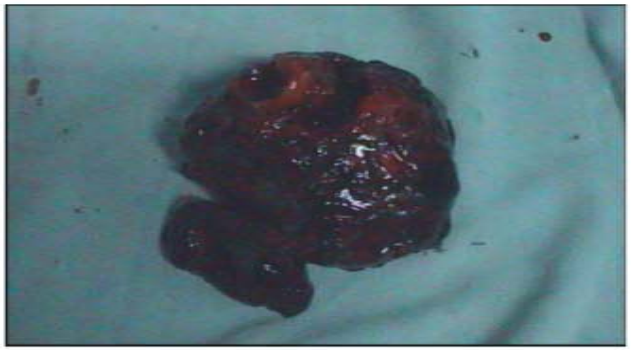

Excised specimen of Right Hepatic artery Pseudoaneurysm

Case - 5 Middle colic artery Pseudoaneurysm Following Acute alcoholic pancreatitis- right Hemicolectomy With Vessel ligation And external drainage of pseudocyst :

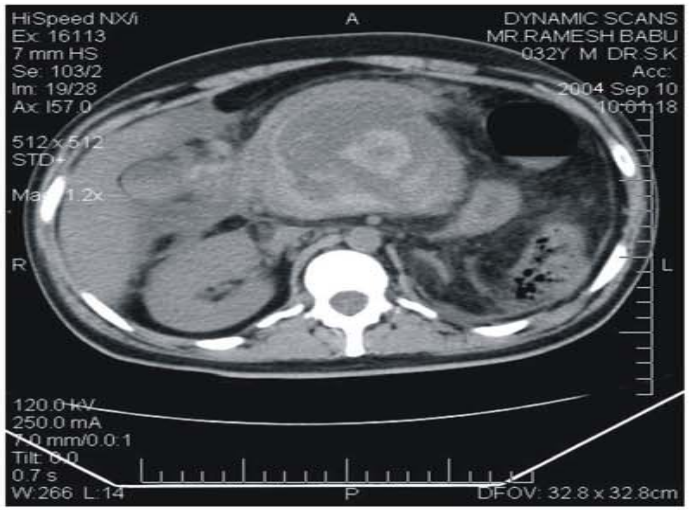

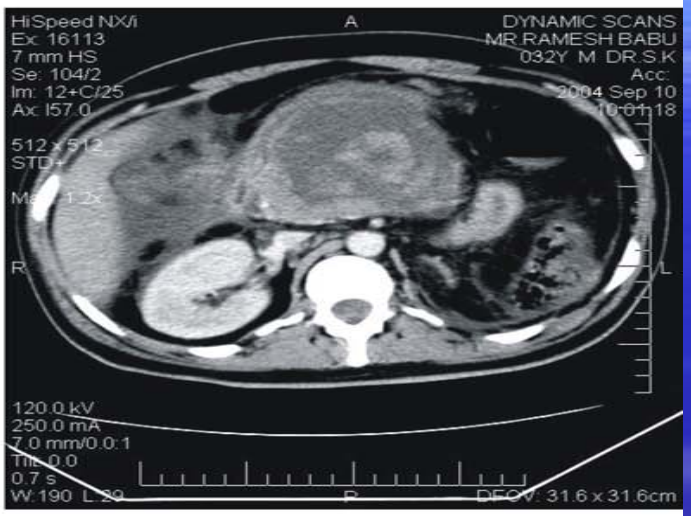

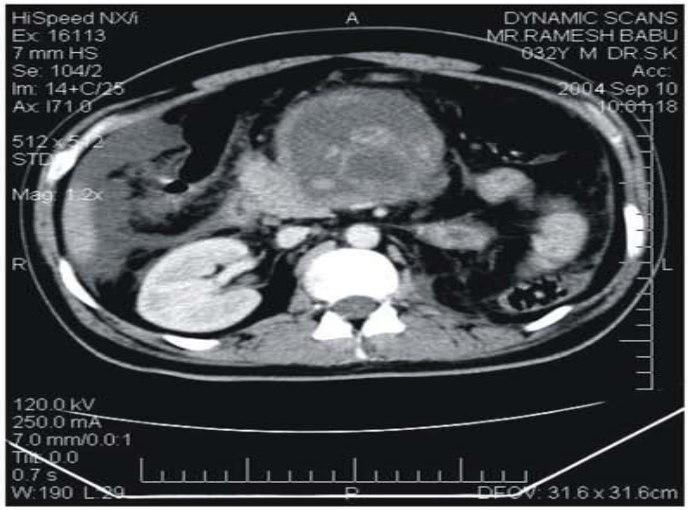

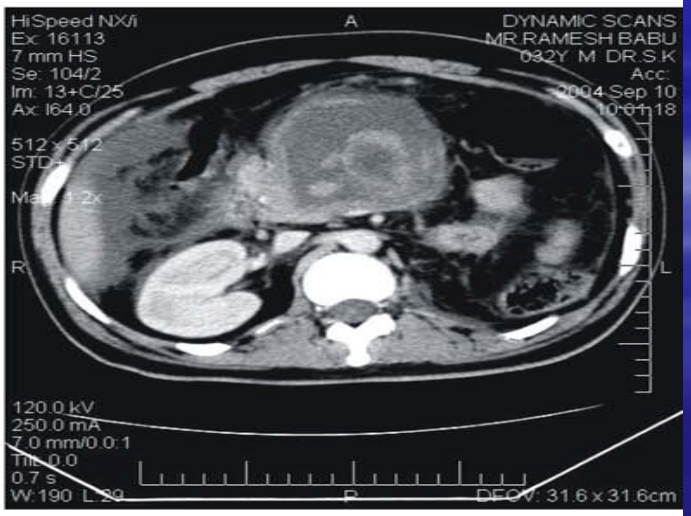

Bleeding into pseudocyst following Rupture of Middle colic artery Pseudoaneurysm

Case - 6 Gastroduodenal artery pseudoaneurysm-Angiographic Embolization Successful:

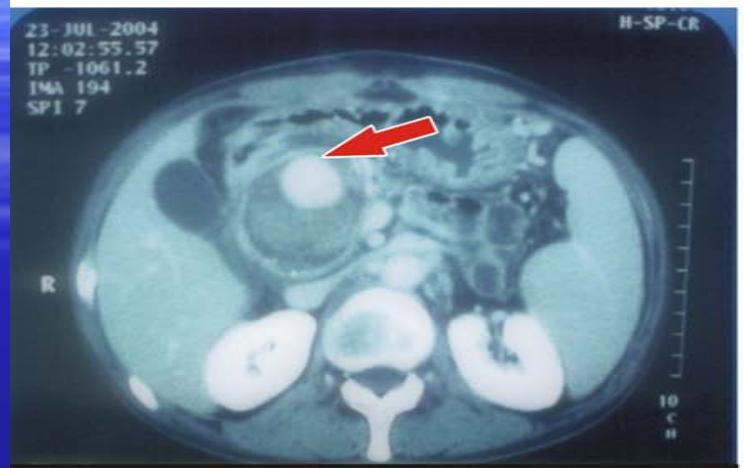

Case 3: CT Angiography showing Bleeding Gastroduodenal artery pseudoaneurysm

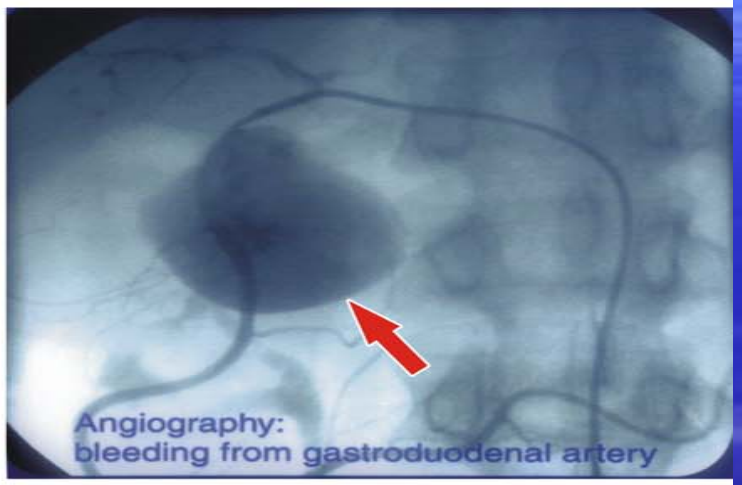

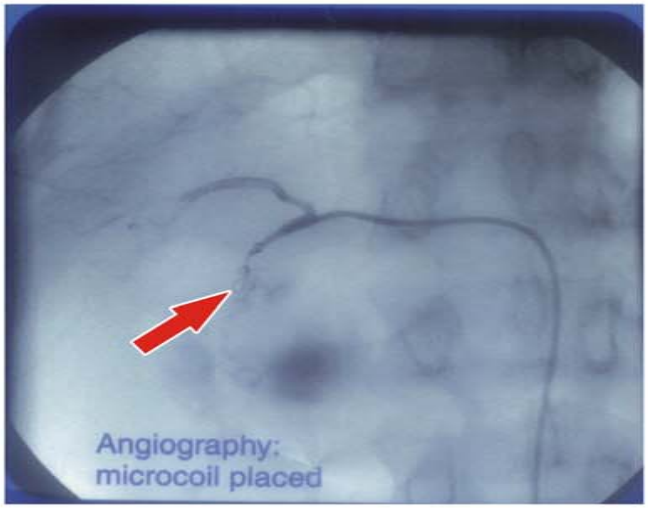

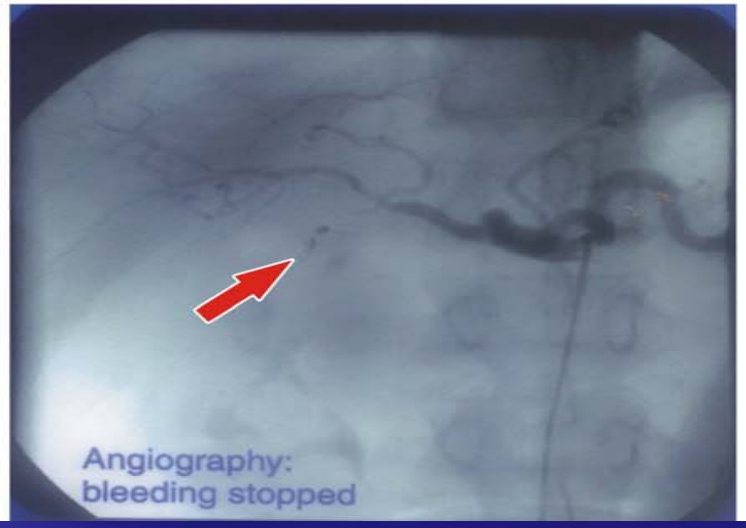

Case - 7 Post-Cholecystectomy Right Hepatic artery pseudoaneurysm Angiographic embolization Successful

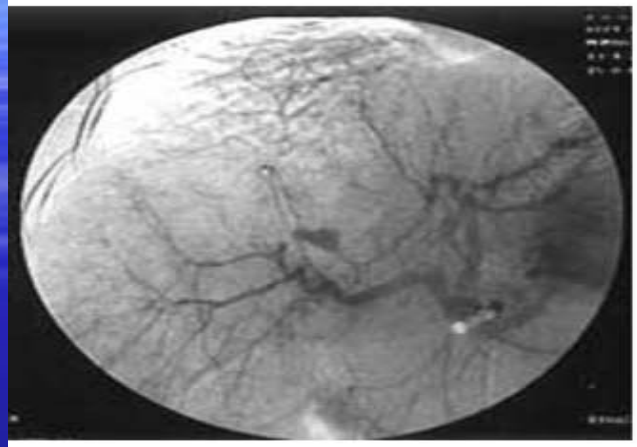

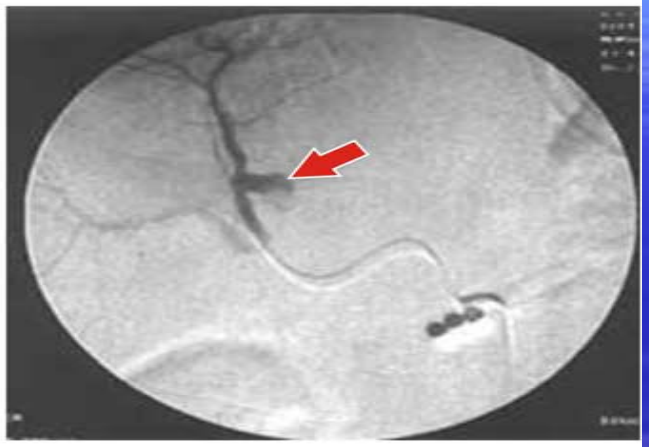

Coeliac angiogram shows a saccular Right Hepatic artery pseudoaneurysm with no evidence of arterio-venous or arterio-biliary fistula

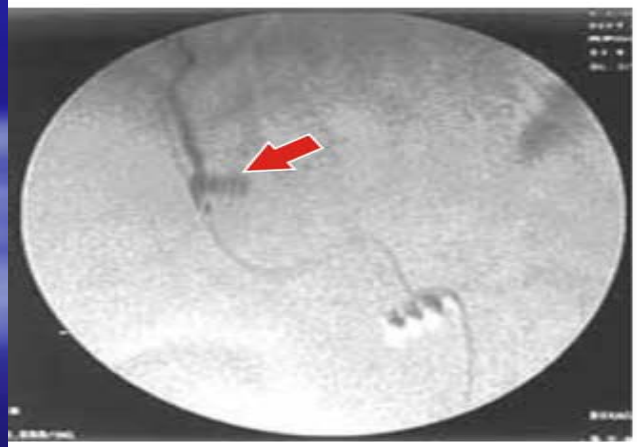

Super Selective Right Hepatic arteriogram Confirms the presence of a pseudoaneurysm

Selective coil embolization of the segmental right hepatic artery branch was done with tungsten coils(BALT SPI-2-60 P) Showed complete obliteration of pseudoaneurysm

Case -8 Inferior pancreatico duodenal artery Pseudoaneurysm- percutaneous transcatheter angiographic embolization Successful

CT Scan Shows a mixed - attenuation fluid collection in the region of pancreatic head(red arrow) with extension of a large low - attenuation collection of air and fluid at the level of porta hepatis(green arrow) consistent with an infected pseudocyst. The collection is obstructing the biliary tree, because dilatation of intrahepatic biliary radicles are seen.

An abscess drainage catheter is centred within the infected pseudocyst collection(red arrow)

Just caudad to the pancreatic head, CT angiogram shows an area of hyperattenuation (red arrow) within the pancreatic phlegmon, representing contained contast extrevasation suggestive of a Inferior pancreatico duodenal artery Pseudoaneurysm.

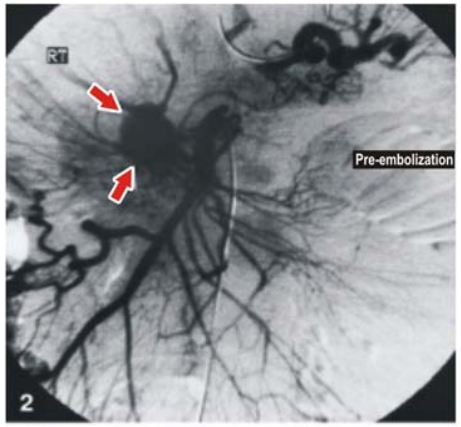

Superior mesenteric angiogram demonstrating extravasation of contrast from inferior pancreatico duodenal artery into the pseudoaneurysm. (red arrows)

Case -8 Inferior pancreatico duodenal artery Pseudoaneurysm- percutaneous transcatheter angiographic embolization Successful

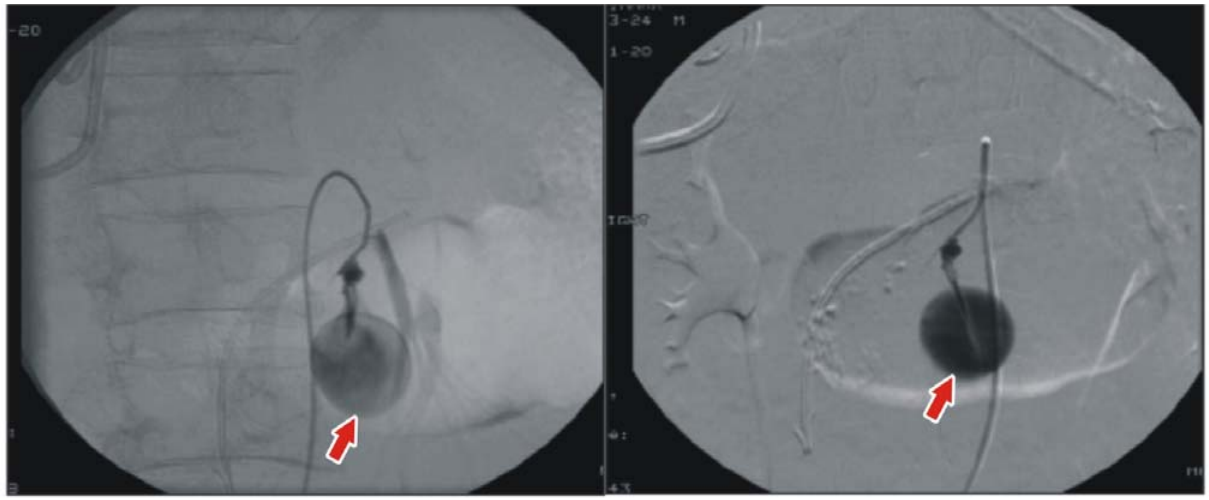

Selective angiography of Inferior pancreatico duodenal artery Shows a 3 cm pseudoaneurysm in both oblique and antero- posterior projections

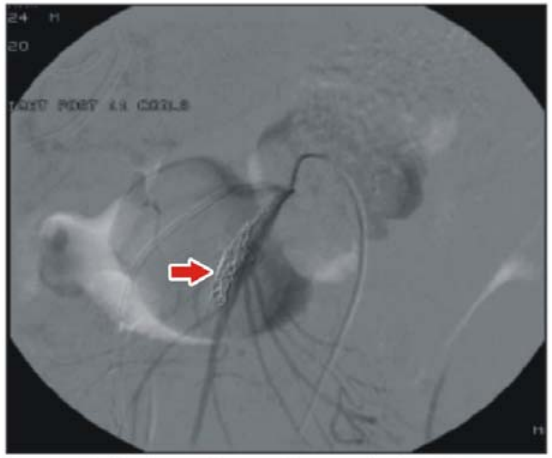

Post - embolization angiogram shows exclusion of the pseudoaneurysm from the vascular supply with multiple microcoils

Case -9 Superior pancreaticoduodenal arcade pseudoaneurysm- chronic pancreatitis

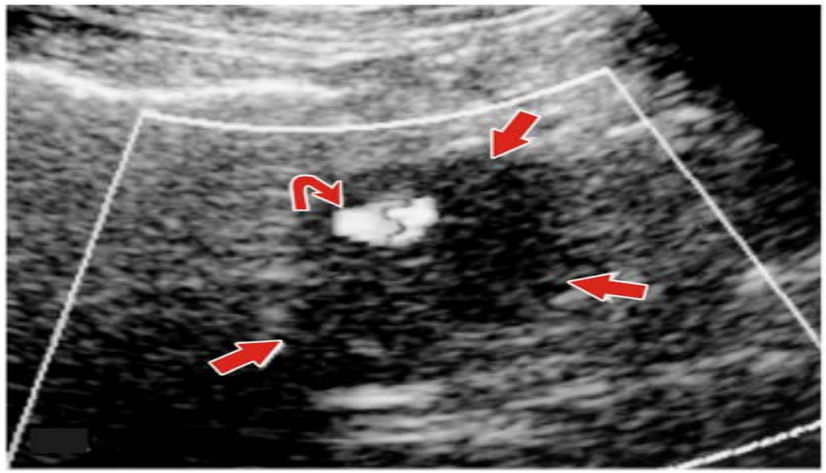

Ultrasound of the head of pancreas demonstrating a hypoechoic solid mass(stright arrows) with a round central area of blood flow on colour doppler(curved arrow), indicating the presence of a pseudoaneurysm

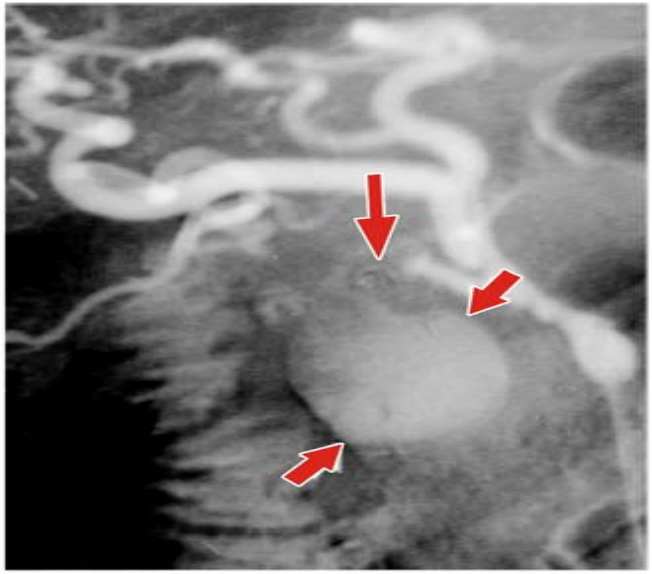

Hepatic artery angiogram revealed a pseudoaneurysm(small arrows) arising from the Superior pancreaticoduodenal arcade at the bifurcation of gastroduodenal artery. A coil(larg arrow) is placed at the origin of the pseudoaneurysm after embolization.

Case - 10 Splenic artery pseudoaneurysm- Angiographic Embolization failed :

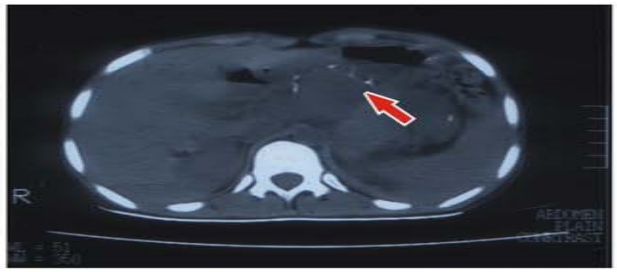

Computerized Tomography (2001) Showing Splenic artery pseudoaneurysm

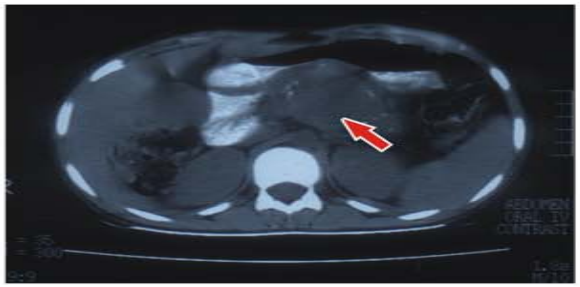

CT Scan(2002) Showing Splenic artery pseudoaneurysm within pseudocyst

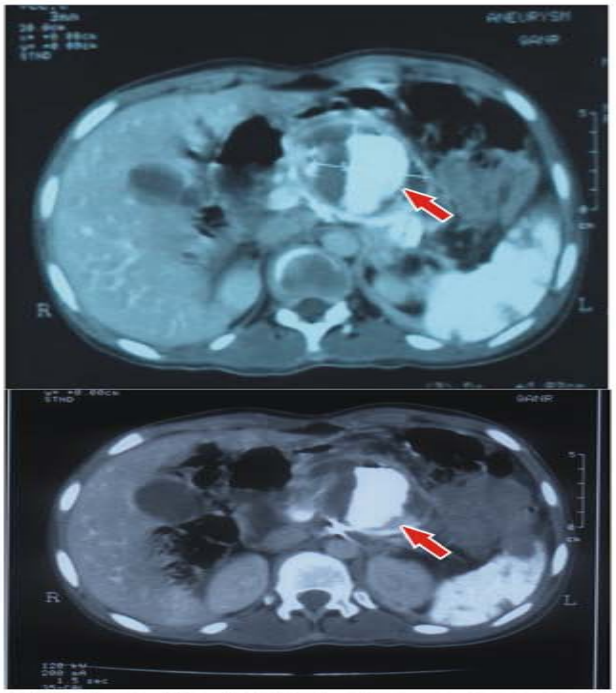

CT Angiogram Showing Splenic artery pseudoaneurysm within pseudocyst in the body of pancreas

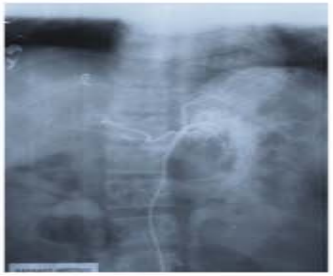

First Coeliac arteriogram(2001)- normal

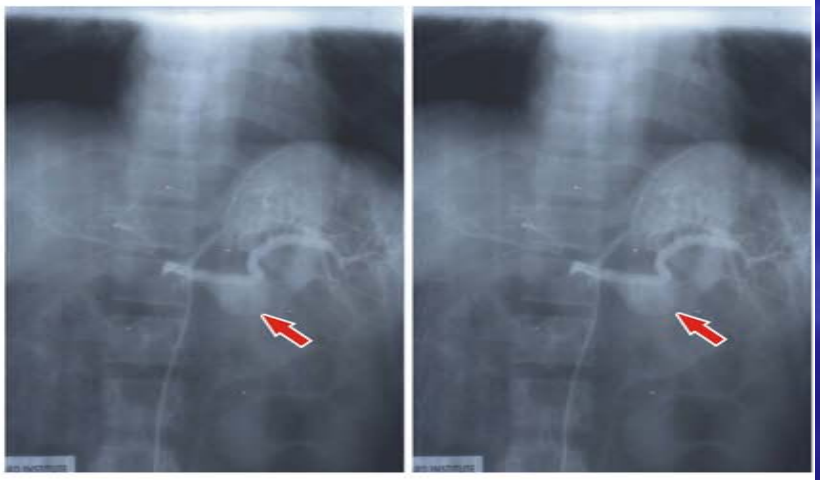

Second Coeliac arteriogram(2002)Showing Splenic artery pseudoaneurysm

Case - 10 Splenic artery pseudoaneurysm-Central Pancreatectomy-Operative Photographs

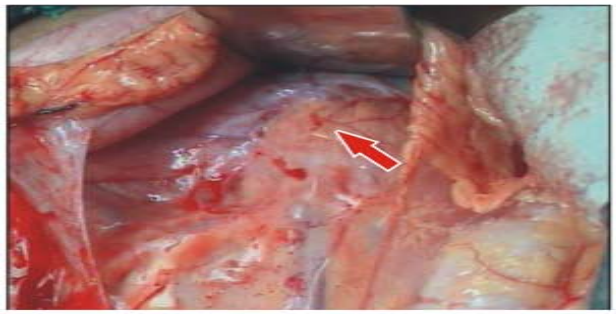

Splenic artery pseudoaneurysm

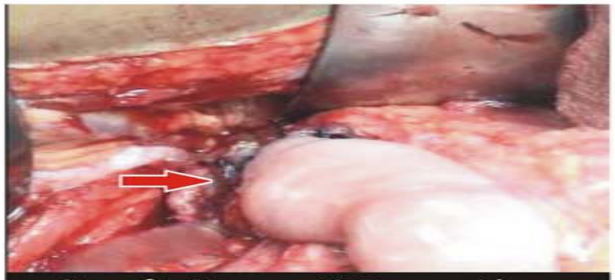

Case 2: Roux-en-Y Pancreatico-jejunostomy to the distal stump

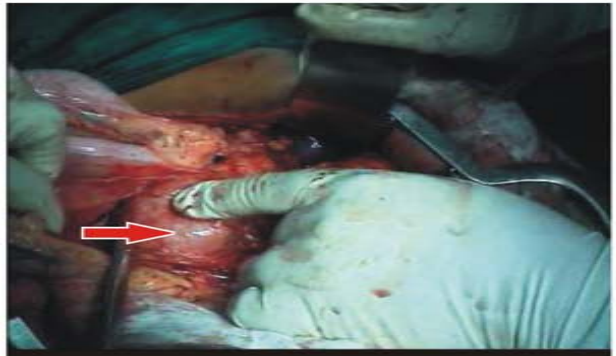

Case 2: Splenic Artery Pseudoaneurysm

Case 2: Proximal Stump closed after central Pancreatectomy

Case 2: Excision of Splenic Artery Pseudoaneurysm

Case 2: Specimen of Splenic Artery pseudoaneurysm with central pancreatectomy

Case - 11 Splenic artery pseudoaneurysm Trancystic Ligation, Excision of pseudoaneurysm and Cystogastrostomy Done

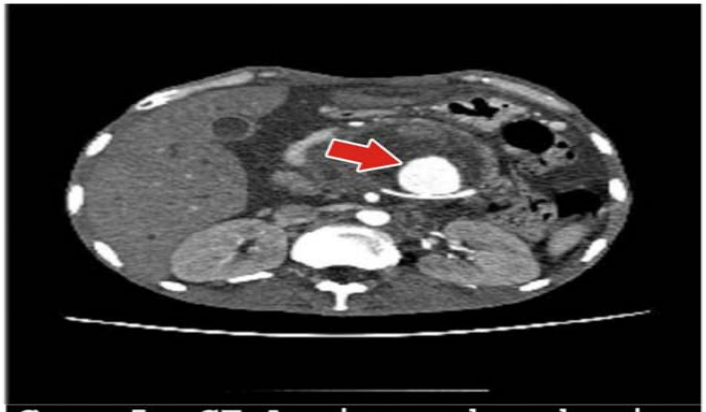

Case 5: CT Angiography showing splenic artery pseudoaneurysm

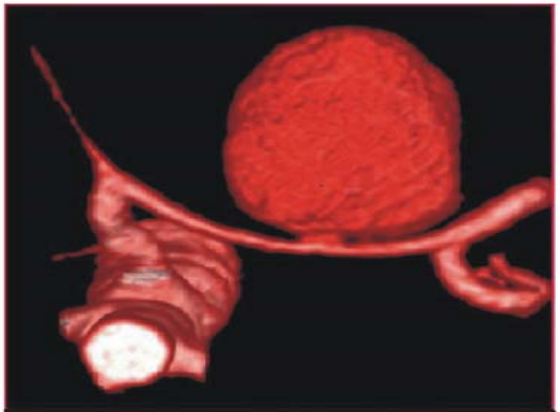

Case 5 : Multislice CT 3D Vascular Reconstruction Image showing Splenic artery pseudoaneurysm

Case 5: Color Doppler showing Splenic artery pseudoaneurysm

Case - 12 Splenic artery pseudoaneurysm Distal pancreatectomy done

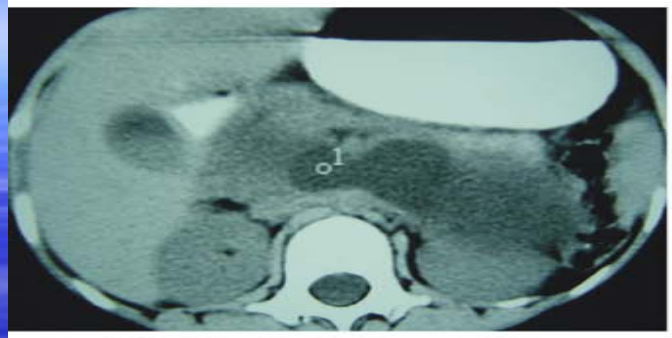

First CT Scan Showing Pseudocyst-tail of pancreas

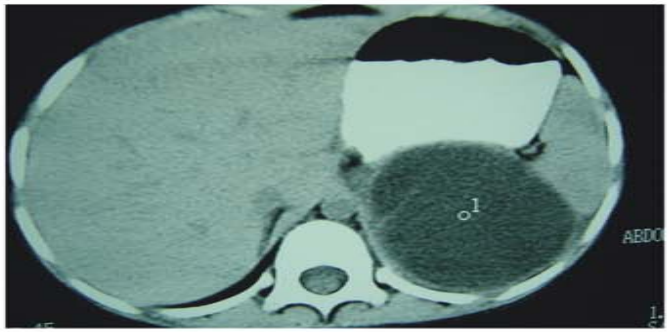

First CT Scan Showing Pseudocyst-tail of pancreas

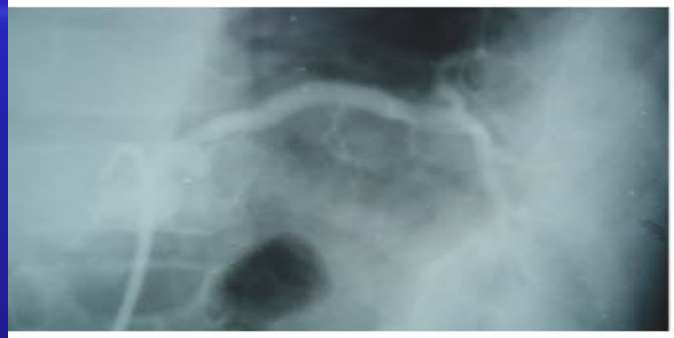

Normal splenic arteriogram

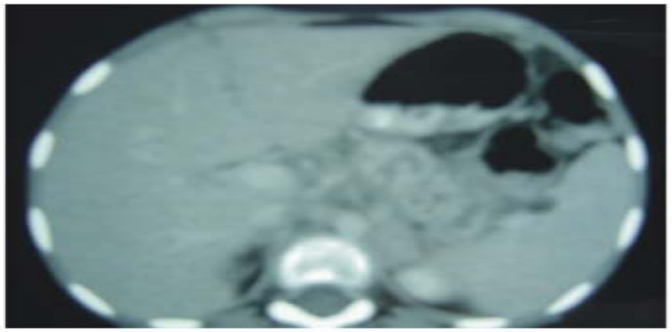

Second CT Scan Showing Multiple intrapancreatic fluid collections s/o acute on chronic pancreatitis after rupture of Pseudocyst

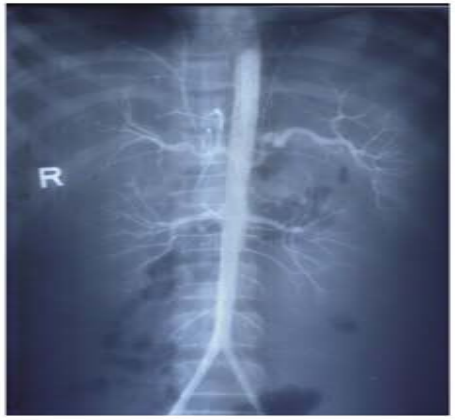

Repeat triple vessel visceral angiogram could not identify the site of pseudoaneurysmal bleed.

Case - 12 Splenic artery pseudoaneurysm Distal pancreatectomy done

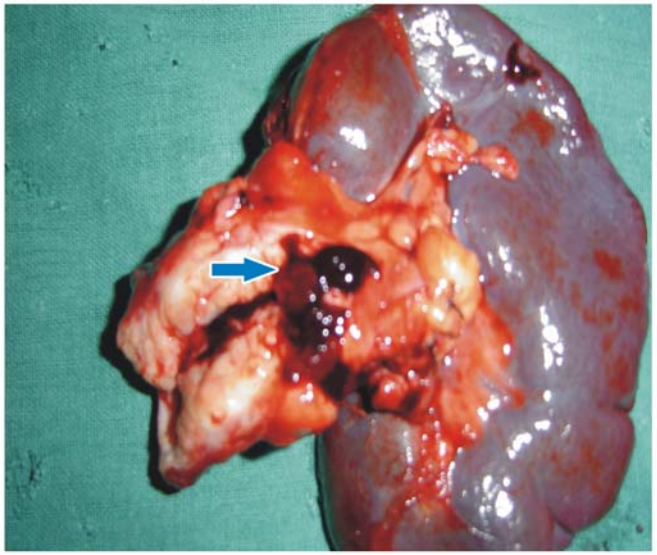

Specimen of Distal pancreatectomy Showing Communication of Splenic artery pseudoaneurysm with main Pancreatic duct(Arrow)

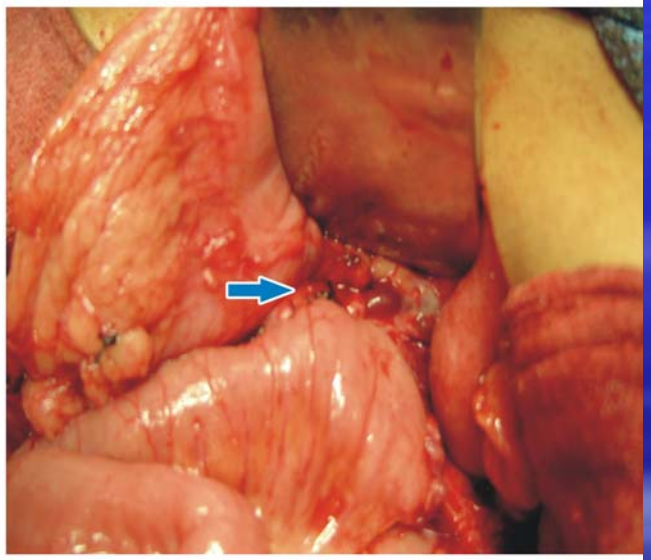

Roux-en-y pancreaticojejunostomy with proximal pancreatic remnant

Case -13 Right Hepatic artery Pseudoaneurysm Following Blunt Liver Trauma - Right Hepatectomy

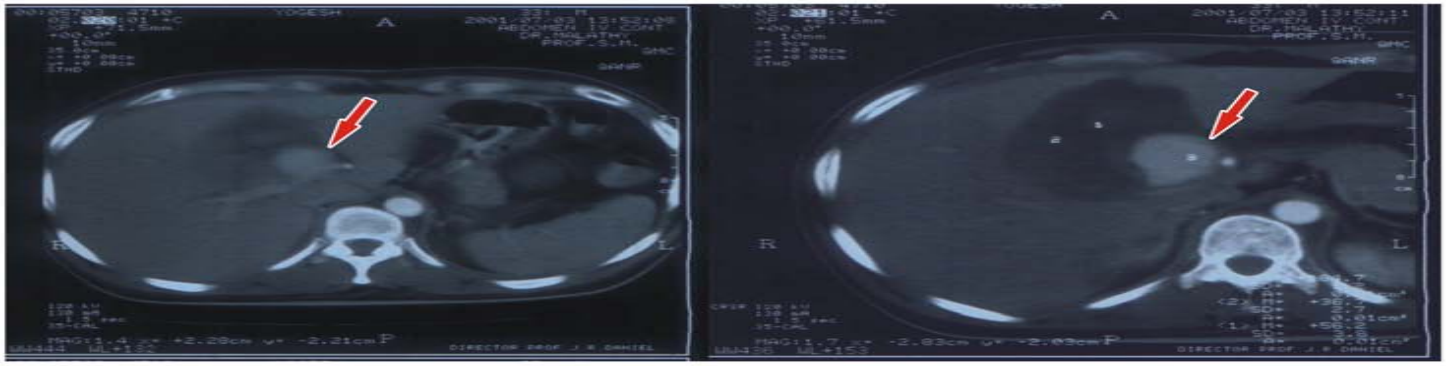

CT Scan Showing right hepatic artery pseudoaneurysm following blunt liver trauma

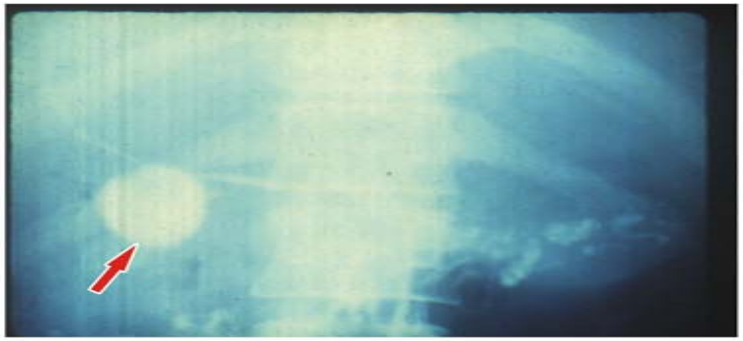

Coeliac arteriogram showing right hepatic artery pseudoaneurysm (Arrow)

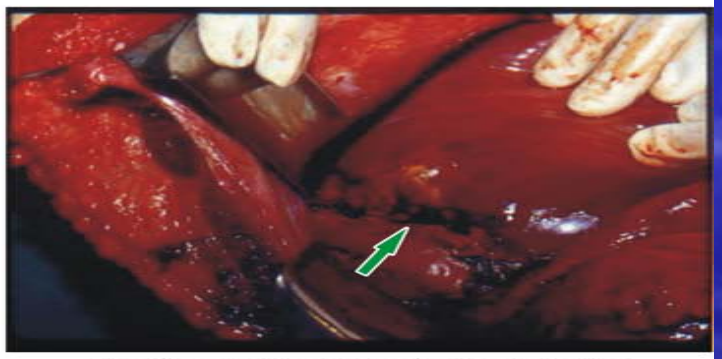

Operative photograph showing liver laceration

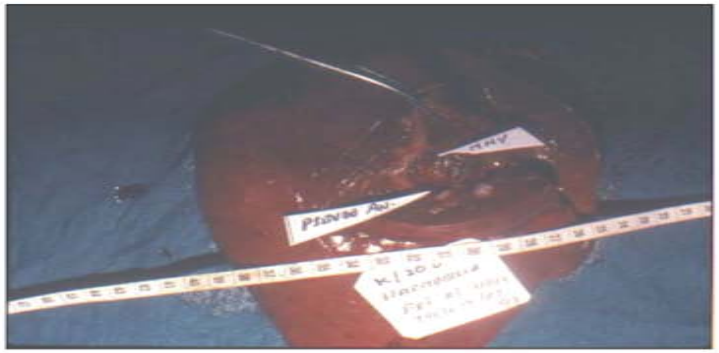

Specimen of Right Hepatectomy containing the pseudoaneurysm

Case - 14 Gastroduodenal artery pseudoaneurysm
Angiographic Embolization Failed

Case 4: CT Angiography showing
Gastroduodenal artery pseudoaneurysm

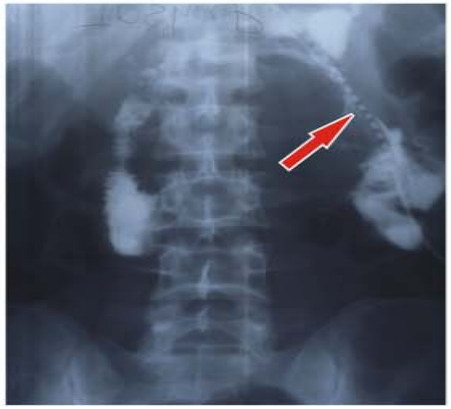

Post - Operative pancreatic Fistulogram Through an External Drainage tube Placed inside the Pseudocyst Cavity Shows Flow of Contrast into Duodenum

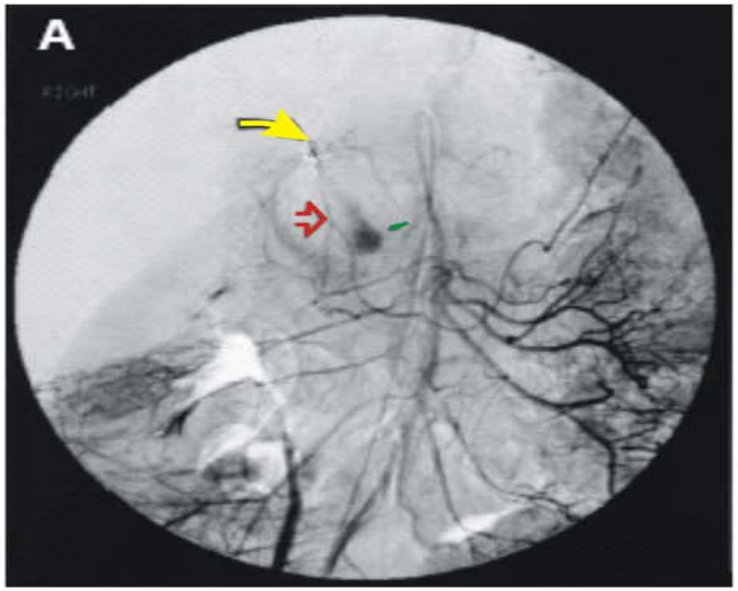

Percutaneous arterial coil embolization of the GDA (curved arrow) for a pancreatic pseudoaneurysm(small arrow). Angiogram picture shows persistent leak into the pseudoaneurysm through SMA collaterals(open arrow)

Case - I5 Splenic artery pseudoaneurysm- Angiographic Embolization successful

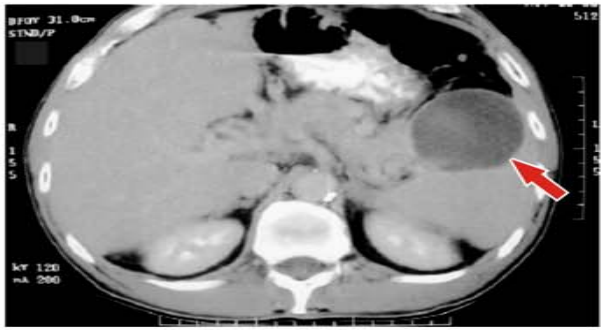

Computerized Tomography demonstrates a 6 cm Splenic artery pseudoaneurysm just anterior to the spleen

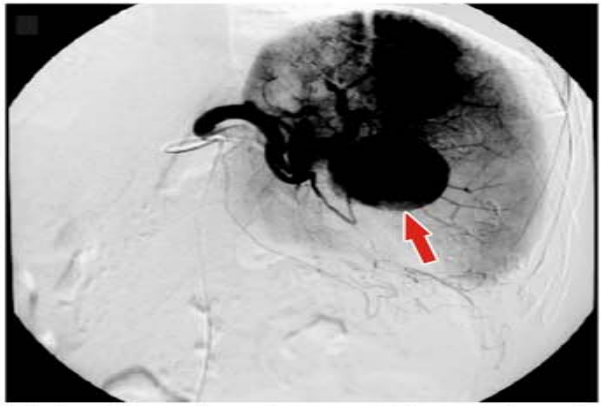

Splenic arteriogram shows a tortuous splenic artery and saccular pseudoaneurysm at the level of splenic hilum

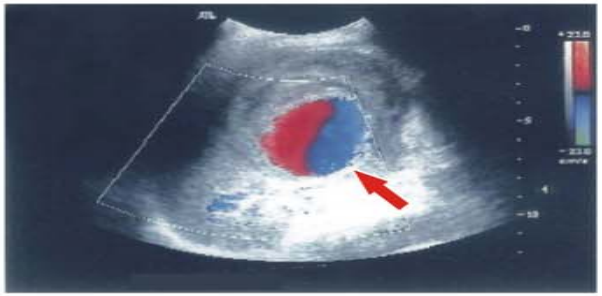

Doppler ultrasound scan shows blood flow within the Splenic artery pseudoaneurysm

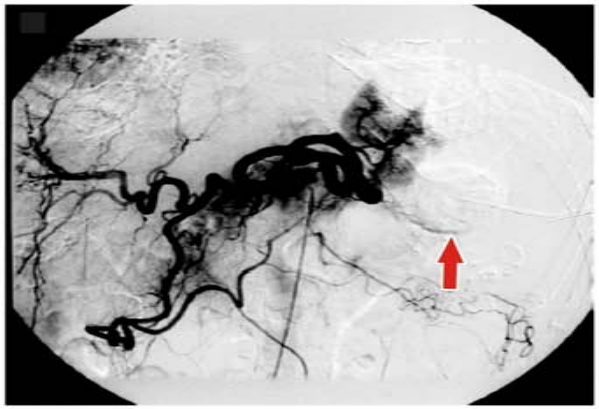

Immediately after injection of autologous blood clot and gel foam particles Splenic arteriogram demonstrates complete occlusion of the pseudoaneurysm

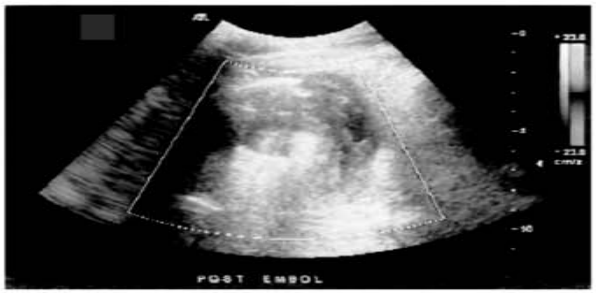

Post-injection Ultrasound scan show no flow within the pseudoaneurysm

Case -16 Pseudoaneurysm of Hepatic artery proper Following Pancreatoduodenectoany:

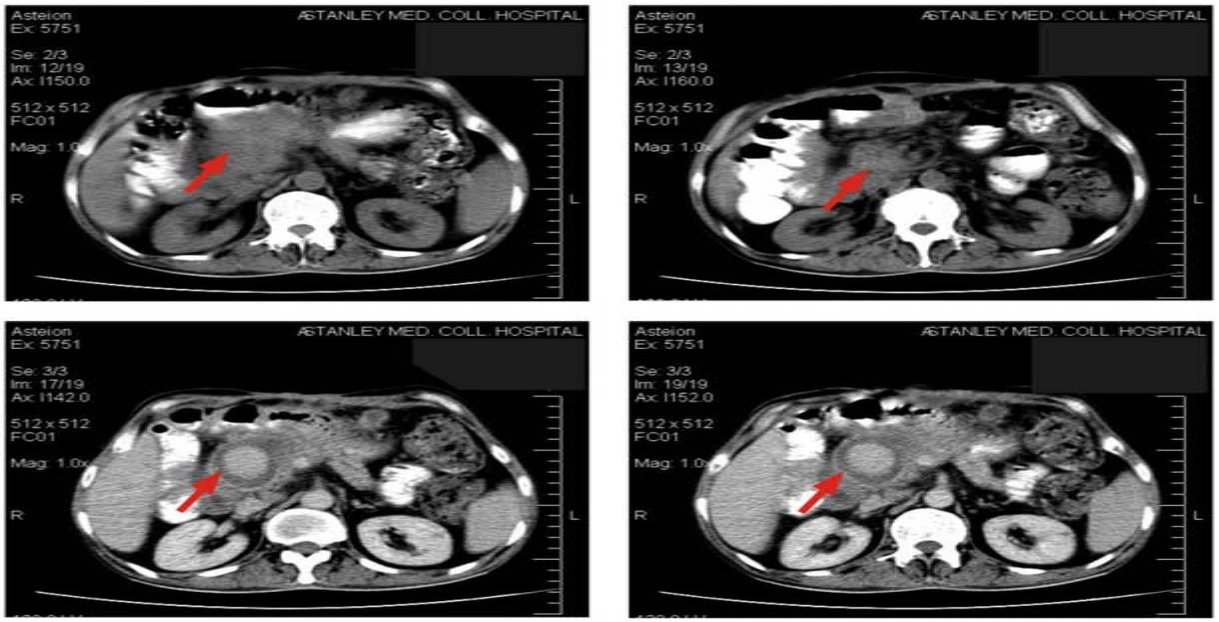

contrast enhanced CT scan showing Hepatic artery Pseudoaneurysm with contrast enhancement(arrow)

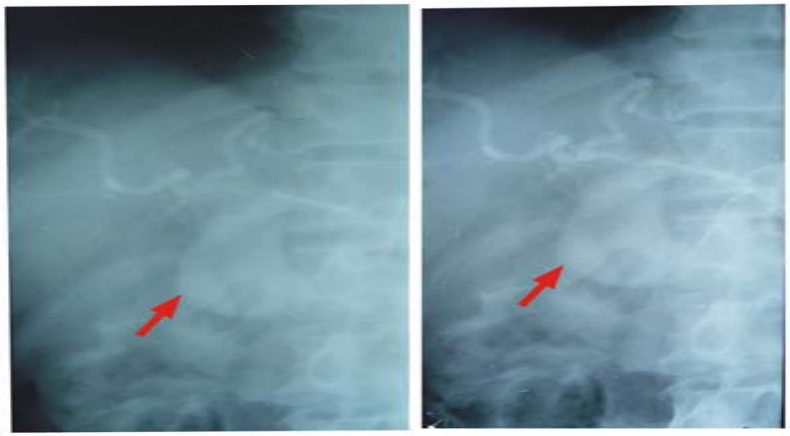

Coeliac Angiographic Picture showing pseudoaneurysm at hepatic artery proper with contrast extravasation (arrow)

Case -16 Pseudoaneurysm of Hepatic artery proper Following Pancreatoduodenectoany:

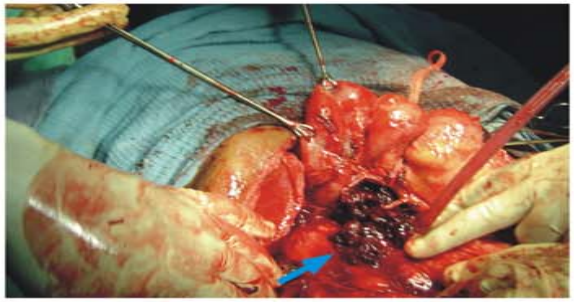

operative photograph showing

Hepatic artery Pseudoaneurysm cavity filled with blood clot(arrow)

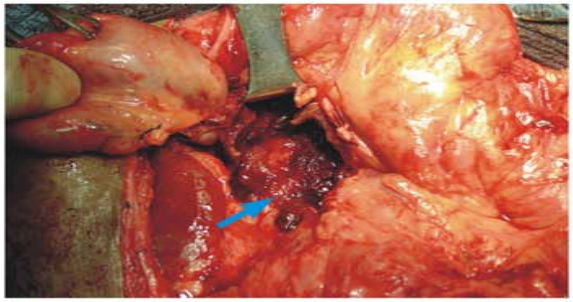

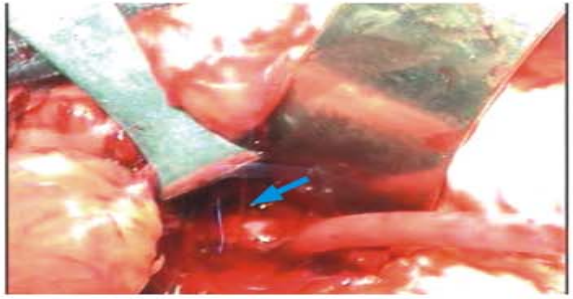

operative photograph showing

showing arterial spurter from the feeding vessel of pseudoaneurysm after evacuation of extravascular blood clot(arrow)

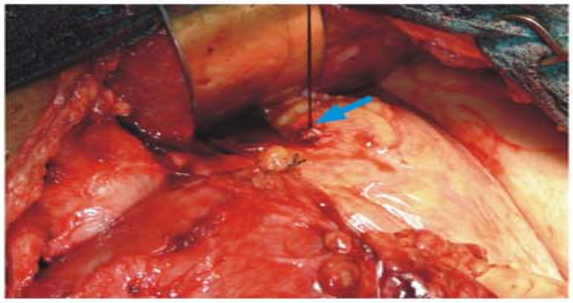

operative photograph showing

Proximal arterial ligation of common hepatic artery with silk ligature(arrow)

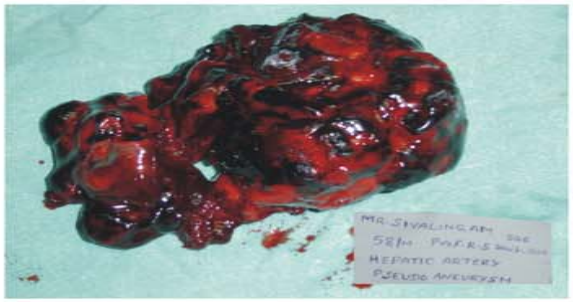

Excised specimen of pseudoaneurysmal blood clot(arrow)