A STUDY OF APONEUROTIC PTOSIS AND ITS MANAGEMENT

M.S. DEGREE EXAMINATION

BRANCH III – OPHTHALMOLOGY

Madras Medical College, Chennai

Dissertation Submitted to

THE TAMILNADU Dr. M.G.R. MEDICAL UNIVERSITY
CHENNAI.

MARCH – 2007

CERTIFICATE

This is to certify that Dr. **B.Kalaiselvi**, MS. Post Graduate Student in Ophthalmology, Regional Institute of Ophthalmology, Government Ophthalmic Hospital, Madras Medical College, carried out this dissertation titled **A Study of Aponeurotic ptosis and its management** by herself under my guidance and direct supervision during the period of May 2004 to March 2007. This dissertation is submitted to Tamil Nadu Dr. M.G.R. Medical University, Chennai in partial fulfillment of the award of MS Degree (Ophthalmology).

Prof. Dr. M. Radha Krishnan, MS, DO.,
Chief Orbit and Oculoplasty,
Regional Institute of Ophthalmology,
Government Ophthalmic Hospital,
Egmore, Chennai.

Prof. Dr.V. Velayutham, MS, DO.,
Director and Superintendent
Regional Institute of Ophthalmology,
Government Ophthalmic Hospital,
Egmore, Chennai.

Prof. Dr. Kalavathy Ponniraivan, BSc,MD.,
Dean
Madras Medical College,
Government General Hospital,
Chennai.

Date :
Place :

ACKNOWLEDGEMENT

I express my sincere thanks and gratitude to **Prof. Dr. Kalavathy Ponniraivan, BSc, MD,** Dean, Madras Medical College for permitting me to utilise the clinical materials of this hospital.

I am very grateful to **Prof. Dr. V. Velayutham, MS, DO,** Director, RIOGOH, Chennai for his valuable advice and guidance in conducting this study and throughout my post graduate course.

I am very grateful to my **Prof. Dr. M. Radhakrishnan, MS, DO,** my unit chief for his valuable guidance in conducting this study and guiding me throughout my post graduate course.

I am thankful to my Assistant Professors **Dr. Malarvizhi, MS,DO., Dr. Ravindran, MS,** for their assistance and help.

I thank all my professors, Assistant professors and colleagues who have helped me in bringing out this study.

Finally I am thankful to all my patients for their kind cooperation for completion of this study.

CONTENTS

INTRODUCTION

Blepharoptosis denotes droopiness of the eyelid often the term is abbreviated as ptosis, which typically denote droopiness of upper eye lid. A spectrum of conditions affect the upper eyelid height, but the most common in acquired is aponeurotic Ptosis. This study out lines aponeurotic ptosis incidence and its management at RIOGOH.

As ptosis leads to an unacceptable cosmetic appearance and defective vision, the fight against ptosis has been long one, various surgical techniques for the correction of ptosis are refined and improved in this modern era of oculoplasty.

ANATOMY OF EYELID

The upper eyelid is unique in that many important structures in several lamellae are contained within a thickness of approximately 2mm.

At a level 3mm above the eyelid margin these lamellae are defined from anterior to posterior as

1. Skin
2. Subcutaneuous tissue
3. Pretarsal orbicularis muscle
4. Post orbicular areolar tissue
5. Tarsal plate
6. Conjunctiva

At a level 15mm above the eyelid margin the lamellae are as follows

1. Skin
2. Subcutaneous tissue
3. Pretarsal orbicularis muscle
4. Post orbicular areolar tissue
5. Orbital septum
6. Preaponeurotic orbital pad of fat
7. Levator aponeurosis
8. Muller’s muscle
9. Conjunctiva

Skin

The eyelid skin is thinnest of the body and unique in having no subcutaneous fat layer, in both upper and lower eyelid. The pretarsal tissues are firmly attached to the underlying tissues, the preseptal tissues are loosely attached.

The upper eyelid crease approximates the attachment of levator aponeurosis to pretarsal orbicularis bundles and skin. This site is at the superior border of tarsus.

The Orbicularis muscle

Main protractor of the eyelid, contraction of this muscle, narrows the palpebral fissure and it is innerrvated by cranial nerve VII.

The orbicularis muscle is divided into pretarsal, preseptal and orbital parts. The pretarsal and preseptal parts are involved in involuntary eyelid movements (blink), orbital portion is involved in forced eyelid closure.

The pretarsal part of the upper and lower eyelid orbicularis arise from deep origins at the posterior lacrimal crest and superficial origins at the anterior limb of medial canthal tendon. The deep head (Hornes tensor tarsi) encircle both canaliculi to facilitate tear drainage. The pretarsal orbicularis fuse in the lateral canthal area to become lateral canthal tendon.

The preseptal part arises from the lacrimal sac and posterior lacrimal crest and medial canthal tendon and laterally from the lateral palpebral raphae.

The orbital part arises from the anterior limb of medial canthal tendon and surrounding periosteum and course over the zygoma covering the elevator muscle.

Orbital septum

It is a multilayered fibrous tissue arising from the periosteum over the superior and inferior orbital rim. In the upper eyelid the orbital septum fuses with the levator aponeurosis 2.5mm above the superior tarsal border. In the lower eyelid the orbital septum fuses in the capsulopalpebral fascia. Medially the orbital septum pass behind the lacrimal sac,blending with the fibres of the posterior crus of the medial canthal tendon to insert into the posterior lacrimal crest

Preaponeurotic Orbital Fat

Orbital septum serves as a barrier between the orbit and eyelid to limit the spread of infection.

The orbital fat lies posterior to the orbital septum and anterior to levator aponeurosis. The central orbital fat is important land mark in eyelid surgery and eyelid laceration repair.

Levator Palpebrae Superioris Muscle

Levator muscle takes origins from the apex of the orbit from the periorbita of the lesser wing of the sphenoid just above the Annulus of Zinn, muscular portion – 40mm long, the aponeurosis is 14 – 20mm length. The superior transverse ligament (Whitnalls ligament) is a condensation of levator muscle fibres is the area of transition from levator muscle to levator aponeurosis. The ligament acts as a fulcrum for the levator transferring its force from an anterior – posterior to a superior inferior direction. Medially Whitnalls attaches to connective tissue around the trochlea. Laterally it forms a septa through the stroma of the lacrimal gland and attaches to the lateral orbital wall.

The levator aponeurosis continues towards the tarsus and divides into an anterior and posterior portion. It fans out to occupy the entire width of eyelid (30 – 35mm). It fuses with the distal fibres of the orbital septum about 3 – 4mm above the tarsal plate and send fibrous slips forward which interdigitate between fibres of the orbicularis to insert into inter muscular septum and the over lying skin

The posterior portion of the aponeurosis inserts onto the anterior surface of the lower half of tarsus. Most firmly attached 2 – 3mm above the eyelid margin. Lateral horn divides the lacrimal gland into orbital and palpebral lobes, medial horn attaches to the medial canthal tendon and to the posterior lacrimal crest. The levator muscle is innerrvated by the superior division of the oculomotor Nerve.

Frontalis Muscle

Quadrilateral shaped muscle, arises by a convex upper border from epicranial aponeurosis mid way between the coronal suture and the orbital margin. It is inserted into the skin of the eyebrows mingling with the fibres of the orbicularis and the corrugator. Above there is a triangular interval between the two frontal muscles. Below, the medial fibres are joined and intermingle with the procerus. It is supplied by seventh cranial nerve. It elevates the eyebrows above the line of vision.

Muller's Muscle

Originates from the under surface of the levator aponeurosis at the level of Whitnalls ligament 12 – 14mm above the tarsal margin. It extends inferiorly to insert along the upper eyelid superior tarsal margin. It provides 2mm elevation of the upper eyelid. This muscle is firmly attached to the conjunctiva posteriorly. It is supplied by the sympathetic nerve.

Procerus and Corrugator Muscle

They are the protractor of the eyelid. The corrugator muscle draws the head of the eye brows to the nose and is responsible for vertical furrows on the bridge of the nose. Contraction of the procerus muscle depresses the head of the eyebrow resulting in horizontal furrows in the skin overlying the bridge of the nose.

Tarsus

Dense plate of connective tissue serves as the skeleton of the eyelid. The upper eyelid tarsal plate measure 10 – 12mm vertically, the lower eyelid measure -4mm. The Tarsal plate have rigid attachments to the periosteum. Tarsal plate is 1mm thick in the upper eyelid, the marginal arterial arcade lies 2mm superior to the margin near the follicle of the cilia. The lower eyelid has only one arterial arcade.

Conjunctiva

Composed of non-keratinizing squamous epithelium. This forms the posterior layer of the eyelid and contains the mucus secreting goblet cells and the accessary glands of Krause and wolfring.

Vascular Supply

Arterial Supply

The arterial supply comes from two main sources

1) Internal carotid artery by way of ophthalmic artery and its branches.

2) External carotid artery by way of arteries of the face (angular & temporal)

Venousdrainage

Divided into pretarsal and posttarsal. The pretarsal tissues drain into angular vein medially, and into the superficial temporal vein laterally.

Post tarsal drain into the orbital veins and deeper branches of the anterior facial vein and pterygoid plexus

Lymphatic drainage

Lymphatic vessel serving the medial portion of the eyelid drain into the submandibular lymph node. The lateral portion of the eyelid drain into the superficial preauricular node and then into the deeper cervical node.

Nerve supply

Sensory nerve supply to the eyelid is provided by branches of I & II division of V cranial nerve. Supraorbital nerve innervates the forehead and lateral periocular region. Maxillary nerve innervates the lower eyelid and the cheek

Motor supply is provided by the oculomotor nerve, Facial nerve and sympathetic nerve.

PHYSIOLOGY OF EYELID

Along with the orbital rim, eyebrows and peri orbital soft tissues, the eyelid serve to protect the anterior surfaces of the eye.

Eyelid motility

The upper and lower eyelid form a complex system of movements, which are two opposing motor systems, one for opening and one for closing the palpebral fissures. These systems involve both voluntary and involuntary control, via the oculomotor and facial nerve as well as the sympathetic nervous system.

Opening movements

The upper eyelid

The action of elevation of the upper eyelid is accomplished primarily via the voluntary skeletal muscle the levator palpebrae which is innervated by the superior branch of the oculomotor nerve. Muller's muscle which is innervated by sympathetic Nerve aid the levator in maintaining the eyelid position.

The levator muscles of both upper eyelid are bilaterally and equally innervated. Electromyography study shows complete absence of orbicular activity in different position of gaze. Frontalis also partly contributes to lid elevation which raises the eye brows above the line of vision in extreme upgazes.

Lower eyelid

The lower eyelid retractors are capsulo palpebral fascia and inferior palpebral muscles.

Supranuclear control

Corticobulbar and extra pyramidal system both contribute to the levator nucleus and levator tonus is related to the level of arousal. Levator action is linked to and parallel to that of the superior rectus muscles in all position of gaze. The exception is during forced lid closure, where the levator is inhibited while the superior rectus is activated. (Bell's phenomenon)

Eyelid closure

Voluntary and involuntary closure of the eyelid is produced by the action of the orbicularis muscle. The functional component of orbicularis, the pretarsal, preseptal and orbital division has specific function attributed to it.

Blinking

A blink is a brief closing of the palpebral apertures and refers to a bilateral action. The blink fibres of the pretarsal orbicularis are the principal units involved in this contractions. The mixed blink and volitional fibres of the preseptal orbicularis are involved in a blinking to a lesser extent.

Blinking may be either periodic, voluntary or reflex winking is a unilateral form of lid closure, in which the orbicularis and levator contract simultaneously.

Bell's phenomenon

The eyes turn upward and slightly outwards the lid are closed so that the cornea is removed from the region of the palpebral aperture, occurs bilaterally on closure of the eyes, the excursion of the globes being equal on both sides.

CLASSIFICATION OF PTOSIS

Beard's classification – 1981

I Congenital ptosis – 60%

a) With normal superior rectus functions

b) With superior rectus weakness

c) With blepharophimosis syndrome

d) Synkinetic ptosis (Marcus – Gunn Jaw-winking)

e) Misdirected third nerve ptosis

Acquired ptosis – 40%

A. Neurogenic ptosis

1) Traumatic opthalmoplegia

2) Lesion of third cranial nerve

3) Opthalmoplegic migraine

4) Horner's syndrome

5) Multiple sclerosis ptosis

B. Myogenic ptosis

1) Senile ptosis

2) Progressive external ophthalmoplegia

3) Hyperthyrodism

III Traumatic ptosis

IV Mechancial ptosis

1) lid tumor

2) Blepharochalasis

3) Cicatricial ptosis

V Pseudo ptosis

1) Due to anophthalmia, Microphthalmia, Pthisis bulbi
2) Due to hypotropia
3) Due to Dermatochalasis

SIDNEY – FOX'S Classification – 1972

Etiological classification of ptosis

1. CongenItal ptosis

- a) Simple
- b) Complicated
  - 1) By other lid anomalies
  - 2) Neurological
  - 3) By opthalmoplegia

2. Acquired

- a) Neurogenic
- b) Myogenic
  - 1) late spontaneous
  - 2) Myasthenia gravis
- c) Traumatic
- d) Senile

3) Heredo familial

a) At birth

Embryonic fixation (Mongoloid)

b) Late appearing

External opthalmoplegia

Freuch – B – Mechanistic Classification of ptosis – 1980

Importance of classification

Pseudo ptosis, Mechanical, need to be attended on aetiological basis levator muscle is not touched.

Neurogenic ptosis to be attended with others

Only myogenic and aponeurotic ptosis needs Surgical intervention

1. Pseudo ptosis

Orbital volume loss

Hypotropia

Blepharospasm and Hemifacial spasm

Chronic ocular surface irritative diseases

Contralateral eyelid Retraction

2. Neurogenic ptosis - 3rd Nerve palsy

misdirected III Cranial N fibres

Horner's syndrome

3. Myogenic ptosis Congenital developmental dystrophy

progressive external opthalmoplegia

Traumatic levator muscle injuries

oculopharyngeal muscular dystrophy

Myotonic dystrophy

Myasthenia gravis

Toxic myopathy

Late – acquired hereditary ptosis

Non – hereditary acquired myopathy

4. Aponeurotic ptosis

Aponeurotic dehiscence or disinsertion

Senile aponeurotic redundancy

5. Mechanical ptosis

Eyelid or orbital tumor

Eyelid oedema / infection, haematoma

Dermatochalasis

Brow ptosis

Upper eyelid skin disease

LITERATURE OF PTOSIS

Myogenic Ptosis:-

Congenital : - results from dysgenesis of the levator muscle. Instead of usual muscle fibres, fibrous or adipose tissue is present in the muscle belly. Congenital myogenic ptosis with an associated poor bell's phenomenon or vertical strabismus may indicate concomitant maldevelopment of the superior rectus(double elevator palsy) or monocular elevation deficiency.

Acquired myogenic ptosis is uncommon and result from localized or dffuse muscular disease such as myotonic dystrophy, chronic progressive external ophthalmoplegia, myasthenia gravis.

Aponeurotic ptosis:-

The levator aponeurosis transmits levator force to the eyelid. Thus any disruption in its anatomy or function can lead to ptosis. Congenital aponeurotic ptosis is caused by failure of the aponeurosis to insert in its normal position on the anterior surface of the tarsus characterised by good upper eyelid excursion and high upper eyelid crease. It is a rare case of congenital ptosis and is associated with birth trauma.

Acquired aponeurotic ptosis is the most common form of all form of ptosis caused by stretching, dehiscence or disinsertion of the levator aponeurosis from its normal position. Common causes are involutional

attenuation or repetitive traction of the eyelid. Aponeurotic ptosis may also be caused or exacerbated by intraocular surgery or eyelid surgery through multiple mechanism.

Eyelid with aponeurotic ptosis characteristically have a high or absent upper eyelid crease secondary to upward displacement or loss of the insertion of levator fibres into the skin.

The levator muscle itself being healthy, the levator function in aponeurotic ptosis is usually normal (approximately 15mm)

Comparison between congenital and acquired aponeurotic ptosis.

		Congenital Myogenic Ptosis	**Aponeurotic ptosis**
1	Palpebral fissure height	mild to severe ptosis	mild to severe ptosis
2	Upper eyelid crease	weak or absent crease	Higher than normal crease
3.	Levator function	reduced	Near normal
4.	ondown gaze	eyelid lag	Eyelid drop

Neurogenic ptosis:-

Congenital neurogenic ptosis is caused by innervational defects that occur during embryonic development congenital oculomotor nerve palsy manifest as Blepharoptosis associated with defective Extraocular movements

Congenital Horner's syndrome may case mild ptosis associated with miosis, anhidrosis and decreased pigmentation of the iris and areola on the involved side.

Congenital myogenic ptosis may also be synkinetic. Marcus Gunn jaw winking syndrome is the most common form. In this the unilaterally ptotic eyelid elevates with Jaw movement. This is thought to be caused by abberant connection between the motor division of cranial V and levator muscle.

Acquired myogenic ptosis is caused by acquired oculomotor nerve palsy.

Acquired Horner's syndrome lead to mild ptosis (2mm)

Mechanical ptosis

The condition in which a swelling in the upper eyelid pulls down the lid. It can be due to congenital abnormality such as plexiform neurofibroma or by an acquired neoplasm.

Traumatic ptosis

Blunt or sharp trauma to the levator aponeurosis or the levator muscle may also cause ptosis. Orbital and neurosurgical procedures also lead to traumatic ptosis.

EVALUATION OF PTOSIS

History

The patent's history usually distinguishes congenital from acquired ptosis. Ptosis in other family members should alert the observer the possibility of a familiar disorder.

Rapidity of onset should be questioned in all patients, gradual onset is most typical in acquired cases, but any association with diplopia or other neurologic symptoms requires further investigation.

A history of normal lid height in the morning progressing to moderate ptosis by evening, may indicate myasthenia gravis. History of previous surgery is important.

The patient should be questioned about previous episodes of eyelid oedema as with allergic angio neurotic oedema which can result in aponeurotic defect.

OBSERVATION

While taking the history the surgeon should observe the patients eyes and face. It should be noted whether the ptosis is unilateral or bilateral and whether there is any associated neuromuscular disorder such as facial muscle weakness or blepharospasm. The presence of concurrent anatomical deformities such as brow ptosis, dermatochalasis, Blepharophimosis should be recorded.

A head turn or tilt should lead to a careful evaluation of ocular motility to rule out the presence of associated strabismus. The ptotic eyelid is then more carefully observed, the degree to which the eyelid margin overlaps the pupil and the general contour of the eyelid is noted. The presence of any eyelid scar, mass lesion is noted. Retraction of the lower eyelid and / or the contralateral upper eyelid should raise suspicion of early thyroid opthalomopathy.

The lack of spontaneous eyelid movement may suggest progressive external ophthalmoplegia. The presence of anisocoria should raise the possibility of Horners syndrome, third nerve Injury or ocular trauma.

PHYSICAL EXAMINATION

1. Visual acuity.

The ocular examinations should include a record of best corrected visual acuity to evaluate the presence of amblyopia on the ptotic eye.

2. Vertical interpalpebral fissure height

This is measured at the widest point between the lower eyelid and the upper eyelid with the patent fixing on a distant object in primary gaze.

3. Margin reflex distance (MRD)

This is the distance from the upper eyelid margin to the corneal light reflex in primary position, the single most effective measurement in describing the amount of ptosis. MRD2 is the distance from the corneal light reflex to the lower eyelid margin, sum of MRD1 & MRD2 should equal the vertical interpalpebral fissure height.

Amount of ptosis may be classified

1. Mild ptosis - 2mm or less
2. Moderate ptosis - 3 mm
3. Severe ptosis - 4mm or more

4. Levator function:-

Estimation of levator function is the single most important aspect of ptosis evaluation for surgical planning.

Berkes method

Measures the excursion of the upperlid from extreme downgaze to extreme up gaze, with action of frontalis muscle blocked. The readings are recorded in millimeter. The measurement needs to be accurate.

The levator function is classified as

8mm or more	-	good
5-7 mm	-	Fair
4mm	-	Poor

Margin Crease distance :

The distance from the upper eyelid crease to the eyelid margin is measured. The upper eyelid crease is often shallow or absent in congenital ptosis. The crease is usually elevated in patients with involutional ptosis.

Pharmacologial test

Helpful in confirming the clinical diagnosis

Edrophonium or Tensilon Test

Tensilon test is used to diagnose myasthenia Gravis. Edrophonium chloride is an ultra short acting acetyl cholinergic agent. 10mg of edrophonium is prepared in a tuberculin syringe. The needle is left in situ after 2mg is injected intravenously over a 15-30 second period. If no untoward effects are noted within one minute, the remaining 8mg is slowly injected. If there is no improvement of ptosis in 1-5 minutes the patients probably does not have myasthenia gravis.

Adverse reaction

Pallor, lacrimation, salivation, flushing, abdominal cramping, bradycardia, an injection of 0.5mg of atropine is give intravenously.

Icepack test

Helps in the diagnosis of myasthenia gravis. The icepack test is a simple procedure with a few potential side effect. An icepack is applied to the patients eyelid for about 2 minutes. If MG is present the ptosis often improves because of the enhancement of neuromuscular transmission that occurs with inhibition of acetyl cholinesterase.

Phenylephrine test :

Phenylephrine 10% drops used in diagnosis of ptosis due to Horner's syndrome.

Laboratory Test

Myasthenia Gravis serum assay of acetyl choline receptor antibody.

CSF analysis – multiple sclerosis.

Chronic progressive external ophthalmoloplegia. – Electromyography, Electroretinography, Mitochondrial assay.

Thyroid eye disease – T3,T4 and TSH

Imaging techniques

May be required in

1. Neurological deficit and multiple sclerosis.
2. Horner's syndrome
3. Thyroid related ophthalmopathy
4. Myasthenia gravis

EVOLUTION OF MANAGEMENT OF PTOSIS

Numerous surgical procedures have been advanced for the correction of ptosis over the past one hundred and fifty years. Many represent minor variations of more standard techniques.

1. Non surgical methods or palliative measures

1. Lid Crutches

Gold Heieshen (1890) Kaufmann (1893), Meyer (1893) Dodge (1935).

2. Contact lens with a shelf

Dudragne (1946), Watillon and pivont (1957), Cochet (1967) and Barridson (1970).

3. Use of magnetic force

Conway 1973, suggested elevation of the lid by magnetic force

Surgical methods

1. Skin resection

Crescents of skin of the upper lid were removed by the Arabian surgeons. Von Graefe tried excision of skin and the underlying muscular tissue.

2. Tarsus Resection

Carried out in Trachoma IV stage with mechanical ptosis was the begining of this type of ptosis surgery. As recently as 1961 a type of tarsectomy for lesser of ptosis was reported by fasanella and servat.

3. Full thickness lid Resection

1996. Restivo, Mandridi and Valvo, 1975, Mecord. 1975, Mustarde did a split level lid resection

levator Muscle Utilisation

Bowman is credited with first levator muscle resection procedure (1857) via conjunctival approach upper border of tarsus excised with ¾ of levator aponeurosis and muscle.

1883, Everbusch, via the anterior approach, 1896, wolft, 1923 Blascovics via the conjunctival approach. Modification by Agatson 1924, Berke 1952, Jone 1964, Mustarde 1988, Shortened the levator by tucking it.

5. Resection of Mullers muscle and Conjunctiva

Putterman and urist 1975, treated small degree of ptosis by resection of mullers muscle and its overlying conjunctiva.

llif 1976 modified fasanella – servat procedure.

Suspension from Brow

Brow suspension by skin flaps

1866, Pavas, Tanscy 1895, Miachek 1915

Brow suspension by orbicularis oculi

Reese 1924

Brow suspension by Tendon

In some parts of England, Plantar tendons of the fifth toe is used Palmaris longus tendon is also used.

Brow Suspension by Collagen Strips

Illiff, 1963, used scleral slips.

Brow Suspension by fascia lata strips

Wright 1922, Lexer 1923, Rosenberg – 1990, Fox 1966, Mandeland and Crawford 1972, Craw ford 1966.

Brow Suspension by Non-Absorbable Sutures

1n 1880, Drarasard used non-absorbable sutures. Hess 1893 and Koster 1899 developed procedures Tillet and Tillet 1966 used a silicone rubber sling. Rama and peduzzi 1973, used 1 mm diameter silicone rod. Downes and collin, 1989, have described successful results in 17 ptotic lids corrected with mersilene slings.

MANAGEMENT OF PTOSIS

Non-Surgical

1. Ocular irritation / myasthenia Graves,
2. Eyelid movement obstruction / Orbital disorders
3. Crutch Glasses – CPEO

STANDARD SURGICAL PROCEDURES

Anaesthesia

Local anaesthesia is preferable to general anaesthesia if the patient will tolerate it, since the voluntary movement of the levator muscle aids in the identification of lid structures and a better operative assessment of lid level is possible.

Surgical Procedures

1. Myogenic ptosis 1- 2 mm ptosis with 8-15 mm action – minimal fasanella servat

2. Moderate to severe 3 – 8 mm action – levator resection to be done.

3. Severe ptosis with 0-2 mm frontalis sling surgery.

Aponeurotic advancement surgery

Indication:-

Mild to moderate ptosis with very good levator action (5-15mm) Good down gaze and high tarsal fold.

Procedure:-

Under local anaesthesia.

The skin incision marked along the eyelid crease is made symmetric to the contralateral crease. If bilateral – crease should be made 8-10 mm from the central lid margin.

The marking is extended nasally to the area just above the upper punctum to avoid the formation of undesirable webbing or redundant skin in the medial canthal area.

The incision is made along the skin line with a 15 Bard Parker blade. Incision should be deep enough to spread the skin and visualise the subcutaneous tissue. Dissection of an inferior skin flap in the central portion of the eyelid exposes the anterior surface the tarsus. Excess bleeding can occur due to damage to the underlying peripheral vascular arcade.

The edge of the dehiscent levator aponeurosis is seen as a white line of tissue superior to the upper border of tarsus between the orbital fat and mullers muscle. The entire orbital septum is incised horizontally.

Once the levator complex has been exposed the eyelid is lifted off the globe. A double armed suture is passed through the central tarsus with partial thickness bites 1 – 2 mm below the superior tarsal

border. A central 5mm broad based bite through the tarsus is recommended for better eyelid contour.

Both arm of suture passed through levator aponeurosis in a mattress fashion. The suture is tied temporarily to allow for adjustment. The patient opens both eyes and the surgeon assess the eyelid height and contour. An intra-operative over correction of 1mm should be aimed since the lid tends to droop in the post operative period. The suture is tied with a permanent square knot and the lid height is evaluated before skin closure.

Skin is closed by a running sub cuticular 6’0’ prolene suture for a seam less skin closure and painless removal.

Lubricants and antibiotic ointment is used post operatively.

Post – Operative care

With levator resection and sling procedures. Lagophthalmos is expected, the lower lid is pulled up to cover the cornea with a modified frost suture immediately after surgery. Antibiotic ointment and patch for 1 day.

After one week sutures can be removed.

COMPLICATION OF SURGERY

Under correction

Most frequent complication. This is not a complication but a fault of judgement and some times of techniques.

Over correction

Usually rare

Lid lag, lagophthalmos & Keratitis

Lid lag is seen to some degree after most ptosis surgery

Entropion and ectropion:

Loss of lashes – rare

Lid crease, lid fold abnormalities

A lid crease that is too high or too low results from a skin incision that has been too high or too low if the skin approach has been used.

Conjunctival prolapse

Prolapse of conjunctiva from the upper fornix is rare. It will usually retract spontaneously within a week or two.

Post operative haemorrhage

Rare : A few moment of pressure over the lid followed by a pressure dressing for a day or two may be enough

Infection

Infection is rare, when infection does occur it can be successfully treated with antibiotics except in brow suspension with a non – absorbable suture when infection recurs when the antibiotic is discontinued. Removal of the suture and resurgery is the procedure of choice.

AIM OF THE STUDY

Aponeurotic Ptosis the most commonest of acquired ptosis, its evaluation and management are analysed in this study.

MATERIAL AND METHODS

It is felt in the recent past, oculo plastic surgery particularly of lid and adnexa have been generally advancing. This may be due to the improved technology in the field of the plastic surgery and also the oculoplastic surgery has also become a subspeciality in the field of the ophthalmology.

The study was conducted at Regional Institute of Ophthalmology, Government Ophthalmic Hospital for a period of 24 months from August 2004 to August 2006.

Cases were from Chennai, referred from different parts of the state to this tertiary care hospital.

Incidence of ptosis in the Regional Institute during the study period was 109 cases of which congenital ptosis – 60 cases Aponeurotic Ptosis – 26 cases, Myogenic ptosis – 11 cases and post traumatic ptosis – 12 cases.

Only 26 cases of aponeurotic ptosis was taken up for study.

Inclusion Criteria

All patients with aponeurotic ptosis, with good levator function were taken up for this study.

Exclusion Criteria

- Congenital ptosis
- Myogenic ptosis
- Post traumatic ptosis
- Post inflammatory ptosis
- Mechanical ptosis and other causes.

A detailed history was taken in each case. Examination of the patient consisted of a detailed ocular examination, complete examination of the ptosis.

Ptosis was examined thoroughly as given on the proforma with special emphasis on the degree of ptosis, the amount of levator functions, Bells' phenomenon, orbicularis muscle Power, corneal sensation and staining. Adequate and appropriate investigations were also done before taking up the patient for surgery. Photographic documentation was done as a part of pre-operative as well post-operative evaluation.

Out of 26 patients, 7 patients had bilateral ptosis and so the number of ptosis evaluated was 33. Based on the amount of levator function and degree of ptosis, surgical procedures were planned and performed.

For all mild, moderate and severe ptosis with good levator function. Levator advancement surgery through the transcutaneous approach (external) was performed.

Post – operative evaluation was done on the first and fifth post – operative day, monthly follow up was done for about 2 months. Patients were evaluated 6 months after surgery to determine the success of surgery as well as to find out the incidence of recurrence.

ANALYSIS AND DISCUSSION

The prospective study on evaluation and surgical management of Aponeurotic Ptosis was conducted at Regional Institute of Ophthalmology Government Ophthalmic hospital, Chennai. The study was conducted between August 2004 and August 2006.

All cases of aponeurotic ptosis with good levator function – 26 patients were evaluated and were operated and taken up for this study. The various findings in this study were analysed and details are as follows:

Incidence

Incidence of ptosis in Regional Institute of Ophthalmology during the study period was 109 of which congenital ptosis – 60 cases(55%), aponeurotic ptosis – 26 (24%) cases, Myogenic ptosis – 11 (10%) cases and post traumatic ptosis – 12 (11%).

26 cases of aponeurotic ptosis were taken up for the study.

Table – 1

Incidence of Ptosis

Sl.No.	Congenital ptosis	aponeurotic ptosis	Myogenic ptosis	Post traumatic ptosis	Total
1.	60 (55%)	26 (24%)	11 (10%)	12 (11%)	109

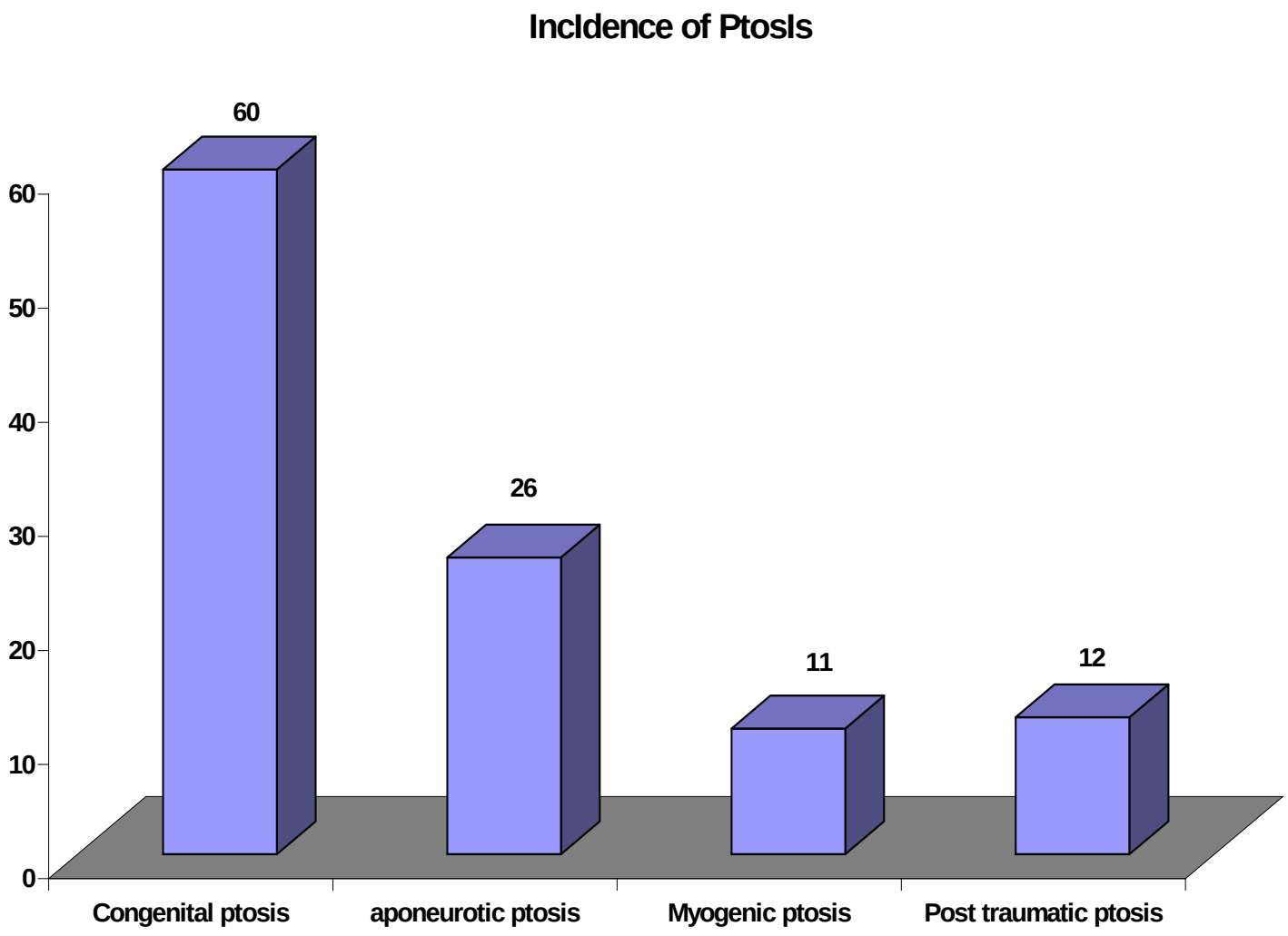
Incldence of Ptosls
60
26
11
12
60
50
40
30
20
10
0
Congenital ptosis
aponeurotic ptosis
Myogenic ptosis
Post traumatic ptosis

Gender distribution

Out of 26 patients taken up in this study 16 male patients (61.5%) and 10 female patients (38.5%)

Table – 2

Sl. No.	Male	Female	Total
1.	16 (61.5%)	10 (38.5%)	26

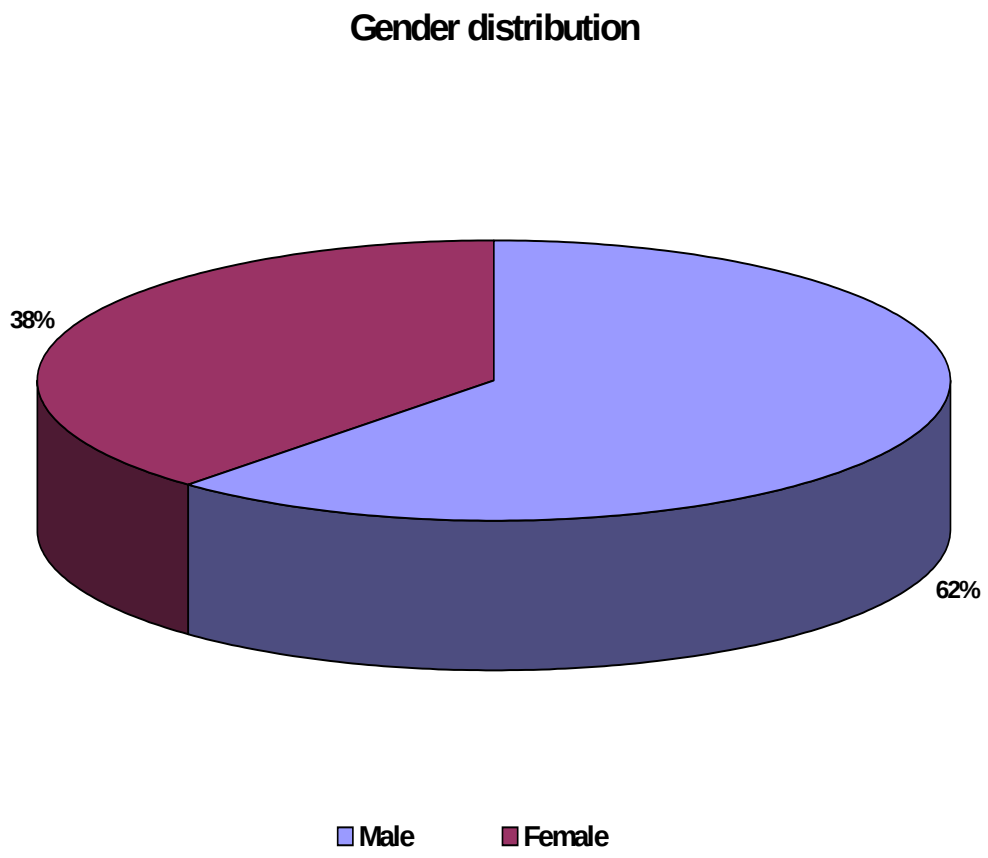
Gender distribution
38%
62%
Male
Female

Age

The age of the patient ranged from 11 years – 75 years of age in this study. Majority of the patients were in the age group 20 – 45 years. Between 15 years – 30 years of age (5 male patients and 3 female patients) and in the age group 31-45 years (3 male and 3 female patients) male predominance was found in this age group (8 patients) compared to female patient (7).

Table – 3

S. No.	**1–15 yrs**		**16-30yrs**		**31-45yrs**		**46-60yrs**		**61-75yrs**		**> 75 yrs**	
	M	**F**	**M**	**F**	**M**	**F**	**M**	**F**	**M**	**F**	**M**	**F**
1	3	-	5	3	3	3	4	1	1	1	-	1
Total	3		8		6		5		2		1	

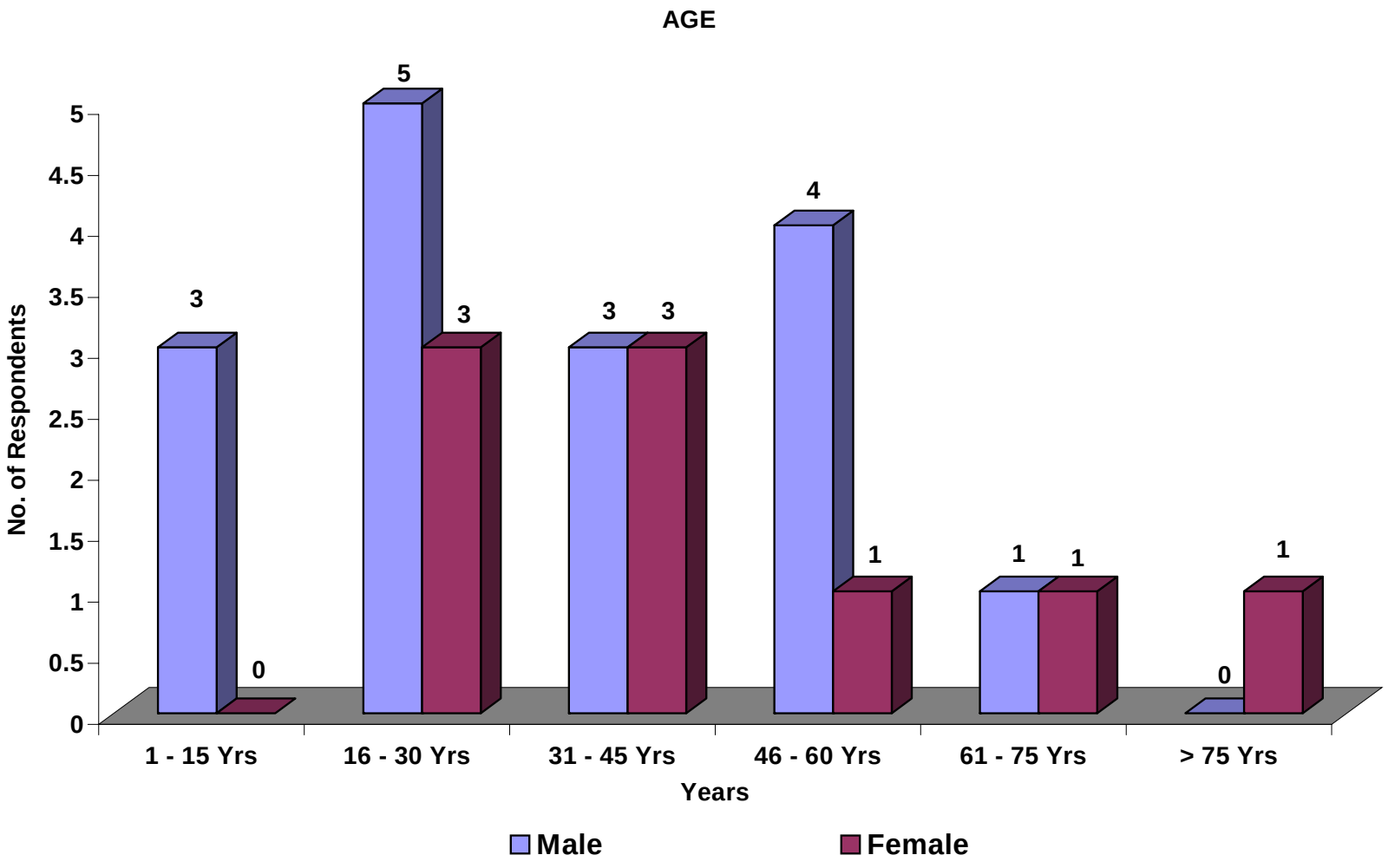
AGE
No. of Respondents
5
4.5
4
3.5
3
2.5
2
1.5
1
0.5
0
3
0
5
3
3
3
4
1
1
1
0
1
1 - 15 Yrs
16 - 30 Yrs
31 - 45 Yrs
46 - 60 Yrs
61 - 75 Yrs
> 75 Yrs
Years
Male
Female

Laterality

Among the 26 cases 19 patients had unilateral ptosis and 7 patients had bilateral ptosis. Right eye was involved in 10 cases and left eye was involved in 9 cases and both eyes were involved in 7 cases. Predominance of RE involvement was seen in the study compared to the left eye.

Table – 4 (a)

Laterality

Sl. No.	Unilateral Ptosis	Bilateral ptosis
1	19 73%	7 27%

Table – 4 (b)

Laterality

Sl. No.	Right Eye	Left Eye	Both Eye
1	10	9	7

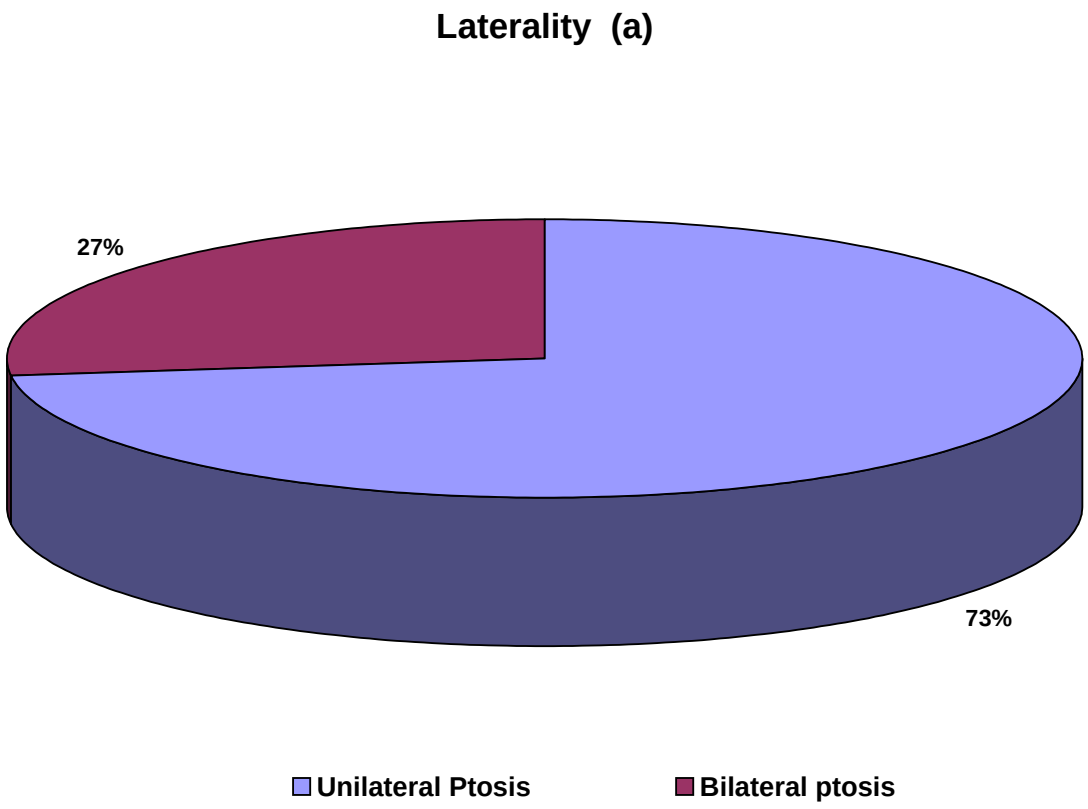
Laterality (a)
27%
73%
Unilateral Ptosis
Bilateral ptosis

Degree of Ptosis

Mild degree of ptosis (1-2mm) was found in 4 cases (15.40%), moderate degree (3mm) in 16 cases (61.50%) and severe ptosis (4mm and above) 6 cases (23.1%). Moderate degree of ptosis formed the majority of cases.

Table 5

Degree of ptosis

Sl. No.	Mild (1-2mm)	Moderate (3mm)	Severe (4mm)
1.	4 15.40%	16 61.50%	6 23.1%

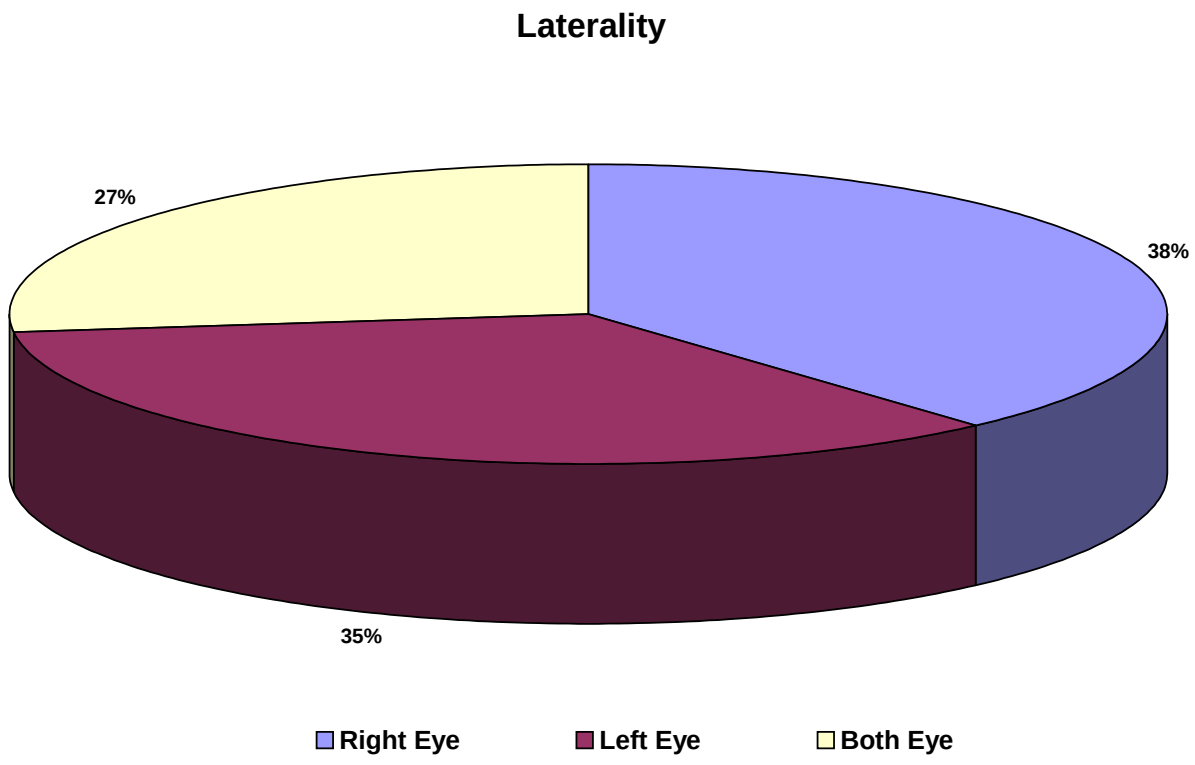
Laterality
27%
38%
35%
Right Eye
Left Eye
Both Eye

Management of Ptosis

Of 33 ptosis, of 26 patients 30 ptosis were corrected surgically, 3 cases of bilateral ptosis did not have the other eye operated. Of this 26 patients, 3 patients were operated under General anesthesia and all the other cases were operated under local anesthesia 4 mild ptosis cases, 16 moderate ptosis cases and 6 severe ptosis cases were corrected surgically.

16 cases were male and 10 were female majority belonging to the age group 20-45 year of age group. Most probably due to the awareness and cosmetic consciousness in this age group and also lack of interest for cosmetic correction in older age group.

All the patients were operated using the technique of levator aponeurotic advancement through transcutaneous approach.

Most of the case were operated under local anesthesia. It gives the greatest advantage to the surgeon, because on the table the eyelid skin incision which form future skin crease can be marked by comparing it with the contra lateral eyelid and also the final suture adjustment can also be made by asking the patient to open both eyes and the surgeon can assess the eyelid height and contour. (Anderson RI et al. in his study showed that local anesthesia during aponeurotic advancement surgery is advantageous)

Technique of levator aponeurotic advancement performed in this study was transcutaneous approach.

Pre-operative and on the table in all cases of unilateral ptosis the possibility of post operative ptosis in the contra lateral eyelid was assessed by lifting the ptotic eyelid to the desired level with one finger and observing any changes on the contra lateral eyelid height.

Attention was given to the eyelid crease and fold, especially when considering a blepharoplasty combined with ptosis surgery.

Accuracy of ptosis repair by levator advancement depends on the intra-operative co-operation of the patient in opening the eyes to verify the appropriate eyelid position.

The incision was marked along the eyelid crease symmetric to the contra lateral crease. The marking is extended nasally to the area just above the upper punctum to avoid redundant skin in the medial canthal area.

The incision is made with a 15 Bard parker blade. Incision is deep enough to spread the skin and visualize the subcutaneous tissue. Dissection of an inferior skin flap in the central portion of the eyelid exposes the anterior surface the tarsus.

The edge of the dehiscent levator aponeurosis is seen as a white line of tissue superior to the upper border of the tarsus between the orbital fat and mullers muscle. The entire septum is incised horizontally.

Once the levator has been exposed a double armed suture is passed through the central tarsus with partial thickness bites 1-2mm below the superior tarsal border. A central 5mm broad based bite is passed through the tarsus for better eyelid contour.

In 20 cases of our study three suture technique was used for levator advancement (Ibrar Hussain et al 3 suture technique gave good cosmetic results and also can be used in congenital ptosis with good levator function.)

6 cases of aponeurotic ptosis was performed using a single broad based mattress suture. This eliminates the need for medial and lateral suture. Making the procedure easier to perform and results in better contour of eyelid.

(liu-D et al – used single suture technique for levator advancement, the procedure is simple and effective and versatile used in the correction of involutional, post traumatic ptosis).

Most of the cases had a thinned out aponeurosis (Hosal Banu M.M.D et.al. measure thickness of levator aponeurosis using UBM and found that in, aponeurotic ptosis most common pathology is thinned out aponeurosis.).

Both arm of suture passed through the levator aponeurosis. The suture is tied temporarily to allow for adjustment. The patient is asked to open both eyes and the surgeon assess the eyelid height and contour and the permanent suture knot is applied.

Skin closed with a sub cuticular suture for a seamless skin closure and painless removal.

All the cases, mild, moderate and severe degree of ptosis were operated through anterior transcutaneous approach in this study (Anderson Rl et al, shovlin Jp et al. caraway Jh et al in their study have shown that anterior transcutaneous approach gave good results for all degree of ptosis)

Advantages of this technique being

1. Easier and better exposure of the tissues
2. Lid need not be averted
3. More access to levator aponeurosis
4. Conjunctiva need not be cut, hence cornea is not injured.
5. All tissues are freely visible and aponeurosis can be identified easily.
6. Lid fold, excess skin can be excised and forming a future lid crease is easier.
7. Blepharoplasty can be combined with levator advancement procedures.

One case was performed with combined procedure of leavtor advancement and blepharoplasty. Combined procedures can be done using a transcutaneous approach levator advancement. (Wilkins RB et al. did combined procedure levator advancement and blepharoplasty with good results cosmetically and functionally).

Complications

One patient had a conjunctival prolapse which did not get corrected within a week so it was corrected surgically by excising the prolapsed conjunctiva and suturing it.

One patient developed dermatochalasis after surgery which was more on looking up which was corrected by excising the excess skin.

Two patient had mild lid peaking.

CONCLUSION

1. Aponeurotic ptosis is the commonest among the acquired ptosis.

2. Majority of patients belong to the age group of 20-45 yrs of age.

3. Aponeurotic ptosis surgery – levator advancement, transcutaneous approach gives good results functionally and cosmetically.

4. In this procedure excess skin can be excised and forming a future lid crease is easier.

5. Levator advancement can be combined with Blepharoplasty.

6. This procedure can be performed not only by the plastic surgeon but also by the General ophthalmologist.

BIBLIOGRAPHY

Text books

1. Albert Hornblass.. carl.N. Honig – Oculoplastic and orbital Reconstructive surgery vol. I, 1988 william & wilkins.
2. Bosniak – Principle & Practice ophthalmic plastic and Reconstructive Surgery 1996 – Vol.- I.
3. Brhan G. Brazzo – Complications in ophthalmic plastic surgery 2003. Springer.
4. Byron C. Smith and Frank A. Ness – Practical Techniques in ophthalmic plastic surgery, 1981, C.V. Mosby Company.
5. Clinton D.MC Cord Jr. and Myron tanenbaum Oculoplastic Surgery second edition, 1987 Raven Press.
6. Collin JRO A. Manual of systematic eyelid surgery, Second edition, 1989, Churchill livingstone.
7. Crowell Beard – Ptosis, third edition, 1987 C.V. mosby and company.
8. Duke elder S. system of ophthalmology, Vol XII Part I st. Louis, CV. Mosby, 1974.
9. Frederic A. Jakobiec, Jesse sigelman – Advanced techniques in ocular surgery WB saunders, 1984.

10. Geoffrey J. Gladstone – oculoplastic surgery atlas 2002 – Springer.

10. Iliff CE, Iliff WJ. NT –Oculoplastic surgery WB saunders – 1979.

11. Mark R. leine – Manual of Oculoplastic Surgery

12. Mustarde S.C. – Repair and Reconstruction in the orbital region, third edition 1991. Churchil Livining Stone.

13. Paymen, Sanders and Goldberg – Principles and practice of ophthalmology, Vol. III First Edition 1987, W.B. Saunders and Company.

14. Ralph. E. Wesley Techniques in Ophthalmic plastic surgery, 1986 John Wiley and Sons.

15. Sidney A Fox – Surgery of Ptosis, 1980 William and Wilkins

16. Thomas D. Duane – Clinical Ophthalmology vol. 5 1986 Harper and Row publishers.

17. Yonoff – Orbit and Oculoplasty.

Journals

1. Anderson RL, Dixon RS – Levator aponeurotic advancement procedure of Choice for a acquired ptosis. Arch oph. 1979 June 97/6 (1123 – 8)

2. Barbara J. Rutledge Ptosis surgery in cosmetic Blepharoplasty; Cosmetic surgery Nov-Dec. 2004.

3. Bartley R. Freuh M.D. et al., New involutional ptosis correction Trans. am. oph. society 2004 Dec., 199 – 208.

4. Ben-simon GJ External levator advancement Vs Mullers conjunctival resection for correction of involutional ptosis Am.J. Oph. 2005 Sep. 40 (3) 426-32.

5. Carraway JH Levator advancement tuck for eyelid ptosis plastic reconstructive surgery 1986 March 77 (3)

6. Erb MH, Kersten RL, Effect of unilateral ptosis repair on contralateral eyelid position oph. plastic reconstructive surgery 2004 Nov. 20 (6)

7. Epstein G Putterman AM Acquired blepharoptosis secondary to contact lens wear AJO 91:634-638, 1987.

8. Harris WA – Levator tuck simplified procedure Ann. Opn. 1975 (Jun) 7(6) 873 – 8.

9. Hosal Banu M.MD – UBM Levator aponeurosis in congenital and acquired ptosis art. oph. & plastic Recons surgery July 2004.

10. Ibrar Hussain – Cosmetic outcome of 3 suture technique of aponeurotic ptosis repair Dept. of oph. Khyber treatment hospital.

11. Jone LT – Cure of ptosis –aponeurotic repair Arch. Oph. 1975 Aug. 629 – 34.

12. Kersten RL – Acquired Ptosis in young and middle age individuals oph. 1999 June 924-8.

13. Liu –D Ptosis repair by single suture technique oph. 1993 sep. 100, 1278-9

14. Martin DA – Congenital aponeurotic ptosis Aust. NZ J. Oph. 1988 Nov. 16 291-4.

15. Older JJ Levator aponeurosis tuck treatment for ptosis oph. surgery – 1978 Aug. 9 (4) 102 – 10.

16. Shovlin JP Aponeurotic approach for the amount of ptosis (Int. oph. clinic 1997 Summer 37(3) 133 – 50)

17. Steven C. Dressner M.D. Blepharoplasty cosmetic surgery.

18. Wilkins RD – Surgical repair of levator dehiscence simultaneously with a blepharoplasty Plastic reconstructive surg. 1982. Oct. (431 – 4)

PROFORMA

REGIONAL INSTITUTE OF OPHTHALMOLOGY,

EGMORE, CHENNAI - 600 008.

OCULOPLASTY NO.
DIAGNOSIS :

CODE NO:

NAME: AGE & SEX :

ADDRESS: OCCUPATION UNIT:

OP/IP

COMPLAINTS & DURATION :

HISTORY : BIRTH HISTORY / AGE & MODE OF ONSET :

TRAUMA - BURNS - CHEMICAL :

SURGERY / ENUCLEATION / PREVIOUS TREATMENT

LID INFECTION / RECURRENT ATACKS / LID EDEMA :

DIPLOPIA / DYSPHAGIA / INTERMITTANCY : JAW WINKING / USE OF STEROIDS :

DIABETES MELLITUS / HYPERTENSION / BLEEDING DIATHESIS:

PAST HISTORY :

FAMILY HISTORY :

LOCAL EXAMINATION :

HEAD POSTURE : FACICAL ASYMMETRY

ADNEXA

PALP FISSURE : E.O.M.

SOCKET:

ANT SEG : FUNDUS: V/A:RE

LE

UPPER LIDS RE

LE

EYEBROWS&FOREHEAD

PTOSIS: YES / NO

CONTOUR / SCAR / PIGMENTATION

SCARS : NATURE & EXTENT

EPICANTHUS

SPONTANEOUS LID MOVEMENTS

LEVATOR ON DOWNGAZE

EXTROPION / ENTROPION

LOWER LIDS :

ECTROPION/ ENTROPION

POSITION OF PUNCTUM

HORIZONTAL LID LAXITY

SCAR : EXTENT :

LOWER LID RETRACTORS :

PTOSIS MILD / MOD / SEVERE RE LE

LPS ACTION : GOOD / FAIR / POOR :

INJURIES :

EXTENT OF LID INJURY

LOSS OF TISSUE :

INVOLVEMENT OF CANALICULUS :

OTHER TESTS :

JAW WINKING

ORBICULARIS MUSCLE POWER

BELLS PHENOMENON

SCHIRMERS TEST

CORNEAL SENSATION / STAINING :

PROBING / SYRINGING OF DUCTS :

OTHER SYSTEMS :

INVESTIGATIONS :

FINAL DIAGNOSIS :

TREATMENT PLAN :

FOLLOW - UP:

PHOTOGRAPHS

PRE - OP

POST - OP

MASTER CHART

S. No	Name	Age	Sex	Eye	Ptosis	LPS mm	OMP	EOM	BP	CS	ST	CVA		Surgery	Complication
												RE	LE		
1	Dhinesh	11	M	RE	4 mm	10	N	F	+	Neg	Neg	6/9	6/6	Apo. Ad	
2.	Jai Kumar	11	M	RE	4 mm	10	N	F	+	Neg	Neg	6/9	6/6	RE, Apo, Ad with Blepharoplasty	Dermato chalasis
3.	Sarath kumar	13	M	LE	3 mm	11	N	F	+	Neg	Neg	6/6	6/6	Apo. Ad	
4.	Subash chandra Bose	21	M	LE	3 mm	11	N	F	+	Neg	Neg	6/6	6/6	Apo. Ad	
5.	Solochana	23	F	LE	3 mm	10	N	F	+	Neg	Neg	6/6	6/6	Apo. Ad	
6.	Radha	20	F	LE	2 mm	11	N	F	+	Neg	Neg	6/6	6/6	Apo. Ad	
7.	Muniappan	24	M	LE	3 mm	11	N	F	+	Neg	Neg	6/6	6/9	Apo. Ad	
8.	Selvi	25	F	BE	3 mm	10	N	F	+	Neg	Neg	6/9	6/12	Apo. Ad	
9.	Suresh	28	M	LE	3 mm	11	N	F	+	Neg	Neg	6/9	6/6	Apo. Ad	
10.	Sundar	21	M	RE	3 mm	12	N	F	+	Neg	Neg	6/9	6/6	Apo. Ad	
11.	Jayanthi	27	F	RE	4 mm	10	N	F	+	Neg	Neg	6/9	6/6	Apo. Ad	
12.	Jarina	33	F	RE	3 mm	11	N	F	+	Neg	Neg	6/6	6/9	Apo. Ad	
13.	Mohan	30	M	BE	3 mm	10	N	F	+	Neg	Neg	6/9	6/6	Apo. Ad	
14.	Senthil kumar	32	M	RE	2 mm	11	N	F	+	Neg	Neg	6/6	6/9	Apo. Ad	

MASTER CHART

S. No	Name	Age	Sex	Eye	Ptosis	LPS mm	OMP	EOM	BP	CS	ST	CVA		Surgery	Complication
												RE	LE		
15.	Selvi	38	F	BE	3 mm	10	N	F	+	Neg	Neg	6/9	6/6	Apo. Ad	Conjunction prolapse
16.	Shanmugam	31	M	LE	2 mm	11	N	F	+	Neg	Neg	6/6	6/6	Apo. Ad	
17.	Sekar	38	M	RE	4 mm	10	N	F	+	Neg	Neg	6/12	6/6	Apo. Ad	
18.	Saradha	40	F	RE	3 mm	12	N	F	+	Neg	Neg	6/6	6/6	Apo. Ad	
19.	Madana gopal	48	M	BE	3 mm	10	N	F	+	Neg	Neg	6/9	6/12	LE, Apo. Ad	
20.	Venkatesan	48	M	LE	3 mm	12	N	F	+	Neg	Neg	6/6	6/6	Apo. Ad	Lid. peaking
21.	Mohan	50	M	LE	2 mm	12	N	F	+	Neg	Neg	6/6	6/6	Apo. Ad	
22.	Govindammal	60	F	RE	3 mm	10	N	F	+	Neg	Neg	6/18	6/9	Apo. Ad	
23.	Audiappan	60	M	BE	3 mm	11	N	F	+	Neg	Neg	6/12	6/18	LE, Apo. Ad	
24.	Jayalakshmi	65	F	RE	4 mm	10	N	F	+	Neg	Neg	6/36	6/18	Apo. Ad	
25.	Kalya raman	72	M	BE	3 mm	11	N	F	+	Neg	Neg	6/12	6/12	Apo. Ad	Lid. peaking
26.	Gaja lakshmi	76	F	BE	4 mm	10	N	F	+	Neg	Neg	6/18	6/12	RE, Apo. Ad	

Key to Master Chart

F	-	Full
Ne	-	Negative
mm	-	millimetre
LPS	-	Levator Palpebrae Superioris
OMP	-	Orbicularis Muscle Power
EOM	-	Extra Ocular Movements
BP	-	Bell's Phenomenon
CS	-	Corneal Staining
ST	-	Schirmer's Test
CVA	-	Corrected Visual Acuity
APO	-	Aponeurotic
Ad	-	Advancement

LIST OF SURGERIES DONE

S.No	Date	I.P. No	Name	Age / Sex	Surgery
1	08/03/05	383641	Andal	55/F	RE ECCE with PI
2	15/03/05	384054	Palaniappan	65/M	RE ECCE with PCIOL
3	17/05/05	391952	Shantha	55/F	LE ECCE with PCIOL
4	31/05/05	393385	Duraisamy	55/M	LE ECCE with PCIOL
5	10/06/05	393165	Meenakshi	56/F	RE ECCE with PCIOL
6	24/06/05	392478	Lakshmi	55/F	RE ECCE with PCIOL
7	11/07/05	393670	Ramachandran	65/F	LE ECCE with PCIOL
8	08/08/05	393420	Saroja	50/F	LE ECCE with PCIOL
9	12/08/05	394544	Mayakrishnan	77/M	LE ECCE with PCIOL
10	21/08/05	394232	Chandra mohan	50/M	LE- DCT

LIST OF SURGERIES DONE

S.No	Date	I.P. No	Name	Age / Sex	Surgery
11	23/11/05	395281	Subramani	52/M	RE - ECCE with PCIOL
12	10/01/06	001098	Govindasamy	40/M	LE - Tarssoraphy
13	07/02/06	002853	Kuppan	50/M	RE - DCT
14	10.03.06	007856	Jayalakshmi	54/F	LE ECCE with PCIOL
15	24.03.06	007890	Murugan	50/M	RE - Evisceration
16	14.04.06	008506	Shanthi	52/F	RE SICS with PCIOL
17	08.06.06	009869	Ramanathan	51/M	LE SICS with PCIOL
18	13.07.06	110102	Lakshmi	60/F	RE - combined surgery
19	26.08.06	110116	Manoharan	54/M	RE SICS with PCIOL
20	09.09.06	110283	Ramachandran	52/M	LE SICS with PCIOL

5-4

upper eyelid
tal section.

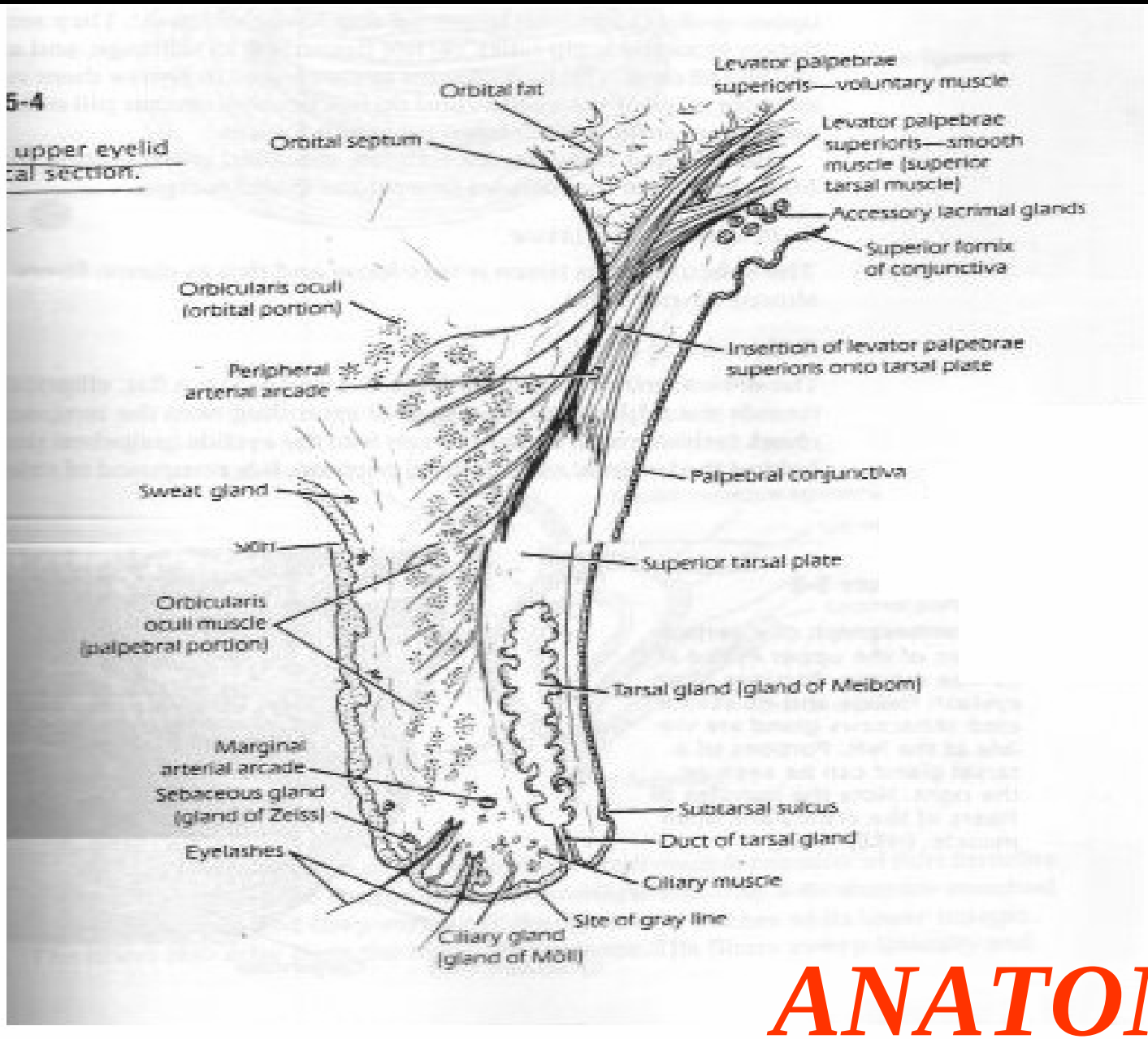

ANATOMY

COMPENSATORY LID RETRACTION

RE-MILD PTOSIS

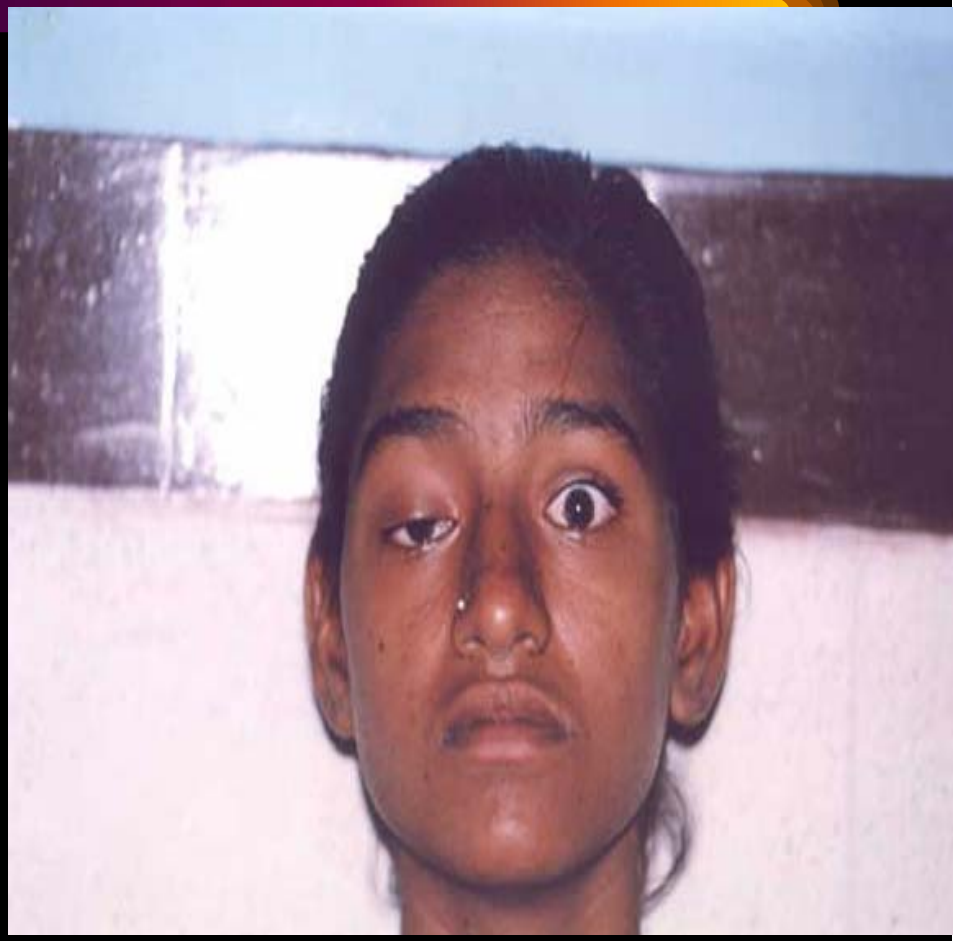

RE-SEVERE PTOSIS

MEASURING PTOSIS

PALP- APERTURE

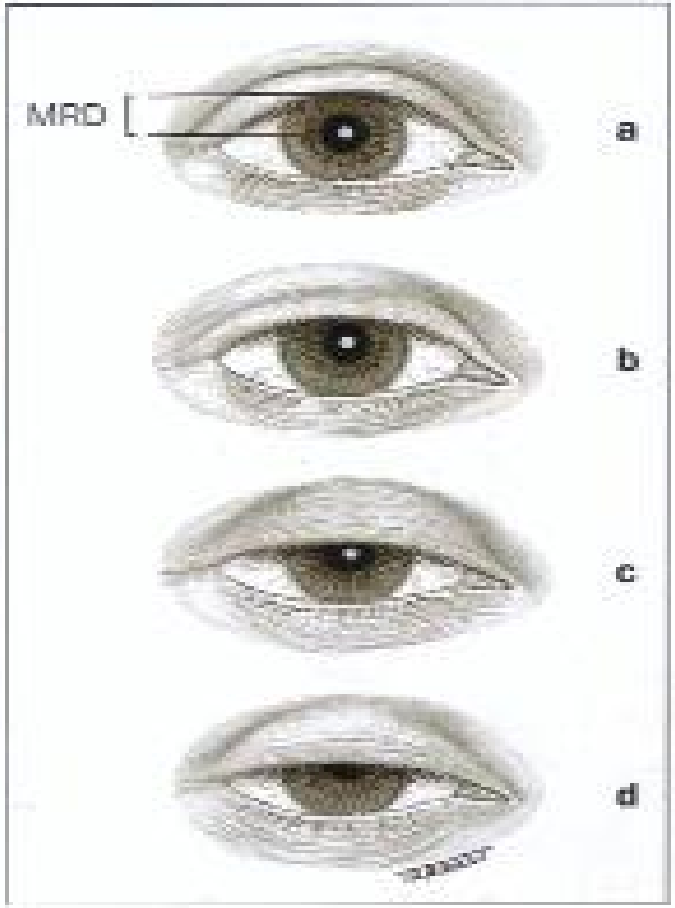

MRD

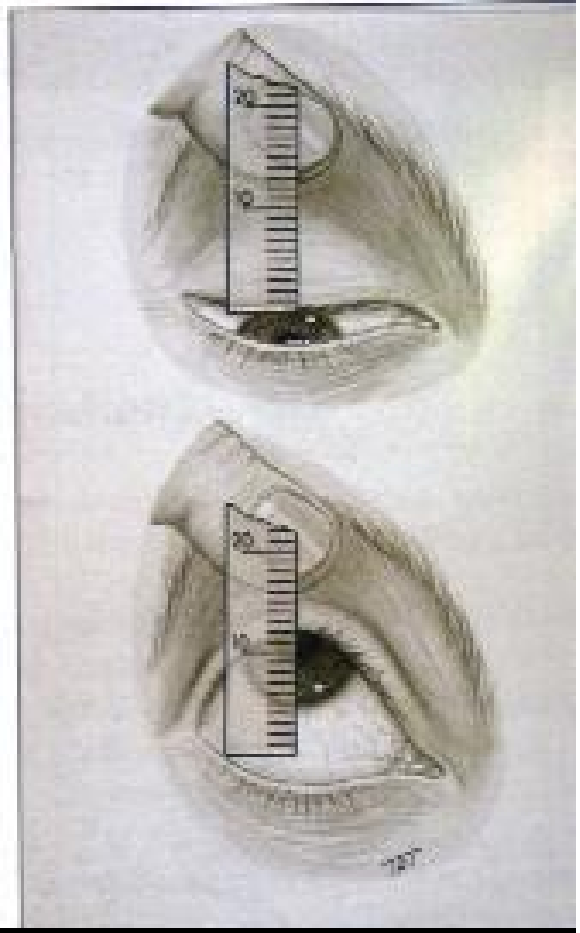

LEVAT-ACTION

APONEUROTIC REPAIR

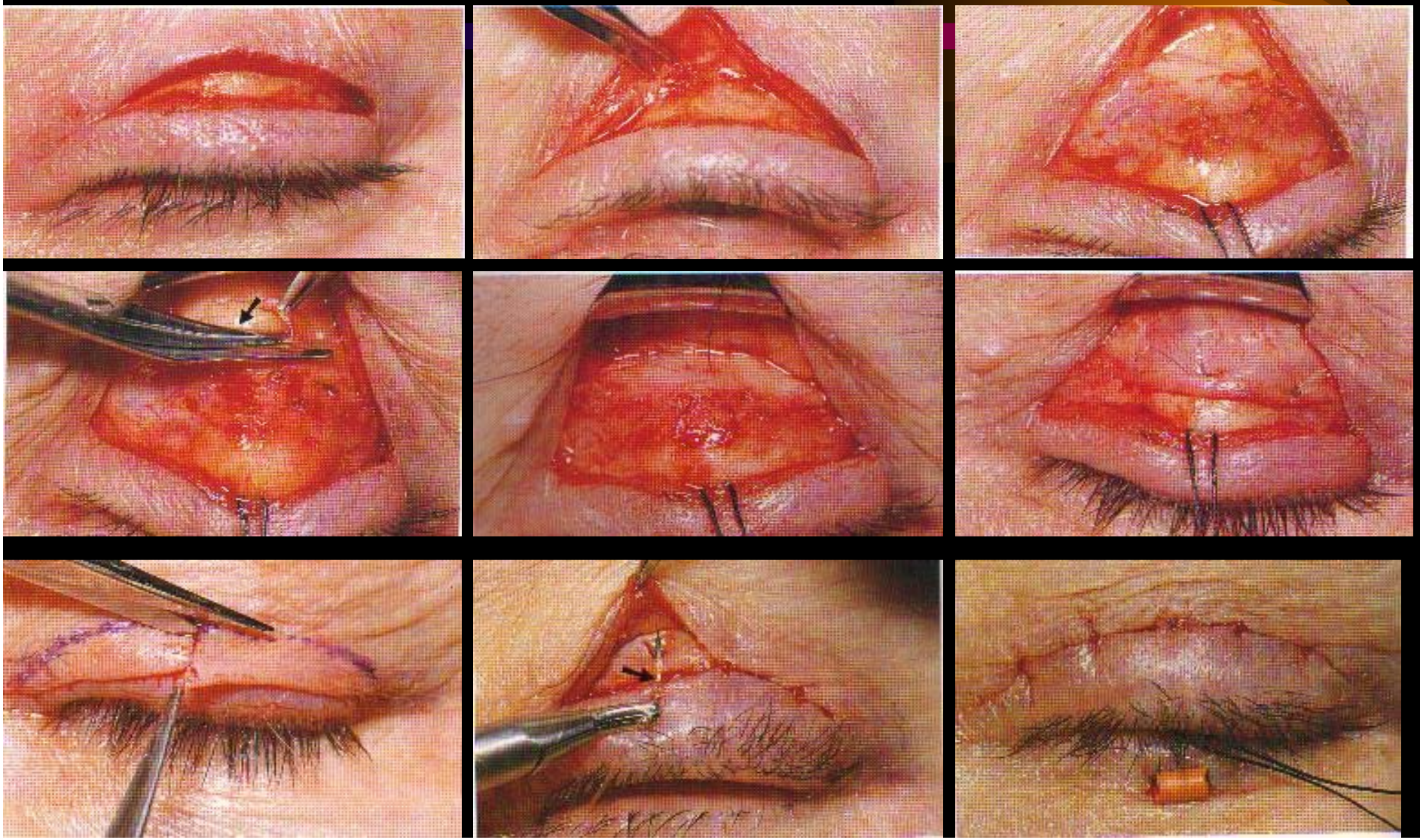

APONEUROTIC REPAIR