RADIOLOGICAL AND CADAVERIC STUDY OF MEDIAL AND LATERAL MENISCI OF KNEE JOINT IN ADULT AND FETUS IN SOUTH INDIAN POPULATION

Dissertation Submitted in

Partial fulfilment of the regulations required for the award of

M.D.DEGREE

In

ANATOMY- BRANCH V

THE TAMILNADU DR.M.G.R. MEDICAL UNIVERSITY

CHENNAI

May 2020

University Registration No. 201733251

Radiological and cadaveric study of medial and lateral menisci of knee joint in adult and fetus in South Indian population.

Dissertation submitted to

The Tamil Nadu Dr.M.G.R. Medical University, Chennai

In partial fulfillment of the university regulations for the award of degree

of

M.D Anatomy – Branch V

May 2020

PSG Institute of Medical Sciences & Research
Institutional Human Ethics Committee

Recognized by The Strategic Initiative for Developing Capacity in Ethical Review (SIDCER)
POST BOX NO. 1674, PEELAMEDU, COIMBATORE 641 004, TAMIL NADU, INDIA
Phone : 91 422 - 2598822, 2570170, Fax : 91 422 - 2594400, Email : ihec@psgimsr.ac.in

To
Dr K Evangeline Singh
Postgraduate
Department of Anatomy
Guide: Dr G Amudha
PSG IMS & R
Coimbatore

Ref: Project No. **17/380**

Date: December 28, 2017

Dear Dr Evangeline Singh,

Institutional Human Ethics Committee, PSG IMS&R reviewed and discussed your application dated 07.12.2017 to conduct the research study entitled *"Radiological and cadaveric study of medial and lateral menisci of knee joint in adult and fetus in South Indian population"* during the IHEC meeting held on 22.12.2017.

.The following documents were reviewed and approved:

1. Project submission form
2. Study protocol (Version 1 dated 07.12.2017)
3. Application for waiver of consent
4. Confidentiality statement
5. Data collection tool (Version 1 dated 07.12.2017)
6. Permission letter from concerned Head of the Department
7. Current CVs of Principal investigator, Co-investigator
8. Budget

The following members of the Institutional Human Ethics Committee (IHEC) were present at the meeting held on 22.12.2017 at IHEC Secretariat, PSG IMS & R between 10.00 am and 11.00 am:

Sl. No.	Name of the Member of IHEC	Qualification	Area of Expertise	Gender	Affiliation to the Institution Yes/No	Present at the meeting Yes/No
1	Mr R Nandakumar (Chairperson, IHEC)	BA., BL	Legal Expert	Male	No	Yes
2	Dr D Vijaya (Member – Secretary, IHEC)	M Sc., Ph D	Basic Medical Sciences (Biochemistry)	Female	Yes	Yes
3	Dr S Shanthakumari	MD	Pathology, Ethicist	Female	Yes	Yes
4	Dr Sudha Ramalingam	MD	Epidemiologist, Ethicist Alt. member-Secretary	Female	Yes	Yes
5	Dr G Subhashini	MD	Epidemiologist	Female	Yes	Yes

The study is approved in its presented form. The decision was arrived at through consensus. Neither PI nor any of proposed study team members were present during the decision making of the IHEC. The IHEC functions in accordance with the ICH-GCP/ICMR/Schedule Y guidelines. The approval is valid until one year from the date of sanction. You may make a written request for renewal / extension of the validity, along with the submission of

28/12/17

PSG Institute of Medical Sciences & Research
Institutional Human Ethics Committee
Recognized by The Strategic Initiative for Developing Capacity in Ethical Review (SIDCER)
POST BOX NO. 1674, PEELAMEDU, COIMBATORE 641 004, TAMIL NADU, INDIA
Phone : 91 422 - 2598822, 2570170, Fax : 91 422 - 2594400, Email : ihec@psgimsr.ac.in

status report as decided by the IHEC.

Following points must be noted:

1. IHEC should be informed of the date of initiation of the study
2. Status report of the study should be submitted to the IHEC every 12 months
3. PI and other investigators should co-operate fully with IHEC, who will monitor the trial from time to time
4. At the time of PI's retirement/intention to leave the institute, study responsibility should be transferred to a colleague after obtaining clearance from HOD, Status report, including accounts details should be submitted to IHEC and extramural sponsors
5. In case of any new information or any SAE, which could affect any study, must be informed to IHEC and sponsors. The PI should report SAEs occurred for IHEC approved studies within 7 days of the occurrence of the SAE. If the SAE is 'Death', the IHEC Secretariat will receive the SAE reporting form within 24 hours of the occurrence
6. In the event of any protocol amendments, IHEC must be informed and the amendments should be highlighted in clear terms as follows:
   a. The exact alteration/amendment should be specified and indicated where the amendment occurred in the original project. (Page no. Clause no. etc.)
   b. Alteration in the budgetary status should be clearly indicated and the revised budget form should be submitted
   c. If the amendments require a change in the consent form, the copy of revised Consent Form should be submitted to Ethics Committee for approval
   d. If the amendment demands a re-look at the toxicity or side effects to patients, the same should be documented
   e. If there are any amendments in the trial design, these must be incorporated in the protocol, and other study documents. These revised documents should be submitted for approval of the IHEC and only then can they be implemented
   f. Any deviation-Violation/waiver in the protocol must be informed to the IHEC within the stipulated period for review
7. Final report along with summary of findings and presentations/publications if any on closure of the study should be submitted to IHEC

Kindly note this approval is subject to ratification in the forthcoming full board review meeting of the IHEC.

Thanking You,

Yours Sincerely,

28/12/17

Dr D Vijaya
Member - Secretary
Institutional Human Ethics Committee

SECRETARY
PSG IMSR
COIMBATORE
INSTITUTIONAL HUMAN ETHICS COMMITTEE

URKUND

Urkund Analysis Result

Analysed Document:	thesis intro final (1) (1) (2).docx (D57278888)
Submitted:	10/19/2019 12:36:00 PM
Submitted By:	dr.evangelinesingh@gmail.com
Significance:	3 %

Sources included in the report:

https://scielo.conicyt.cl/scielo.php?script=sci_arttext&pid=S0717-95022004000300001
a2bfdb2e-ee73-43b9-9598-277046203f9c
https://www.researchgate.net/publication/9042633_The_normal_menisci_In_vivo_MRI_measurements
https://www.researchgate.net/publication/311989180_MORPHOMETRY_OF_LATERAL_MENISCUS_A_CADAVERIC_STUDY
https://www.researchgate.net/publication/312630059_Morphometric_analysis_of_menisci_of_adult_human_knee_joint_in_North_Indian_population

Instances where selected sources appear:

14

“RADIOLOGICAL AND CADAVERIC

0: https://www.researchgate.net/publication/311989180_MORPHOMETRY_OF_LATERAL_MENISCUS_A_CADAVERIC_STUDY
95%

STUDY OF MEDIAL AND LATERAL MENISCI OF KNEE JOINT IN ADULT

AND FETUS IN SOUTH INDIAN POPULATION” INTRODUCTION The Latin word ‘Menisci’ stems from a Greek word "meniskos" which denotes crescent. These intracapsular fibro cartilaginous structures are termed so because of their peculiar crescent moon like appearance. The menisci endows congruency between the irregular surfaces of femoral condyles and tibial plateaus, thereby ensuring the stability of the knee joint in a healthy person. They are rich in glycoproteins , collagen and proteoglycans and they intersperse with cells (Arnoczky SP et al (1992) , Ghadially FN et al (1983) , Herwig J et al (1984)). Cognizance of these prime intraarticular structures retrogrades to the times of Andreas Vesalius ,where he illustrated the structure of menisci in his book “De Humani Corporis Fabrica” in the year 1543(Figure 1)

Formerly, Menisci was referred as vestigial intra articular muscular remnants .This fact was later refuted after learning the correlation between the loss of menisci and the progression of premature osteoarthritis. Thenceforward, the anatomy of menisci and its variations have been entailed and contemplated exhaustively in various parts of the world in the domains of morphology,morphometry,physiology,diagnostics,pathology and Interventions particularly the meniscal tissue replacement. The vital functions of the knee joint include: • Transmission of load across the tibiofemoral junction. • Decreases the resultant stress placed on the articular cartilage. • Acts as a shock absorber. • Provides stability to the knee joint • Acts as lubricant Vascularity of knee menisci: The vascularity of knee menisci is exceptional in many aspects. Menisci procure blood supply predominantly from the superior and inferior lateral and medial geniculate arteries through the perimeniscal capillary plexus. In adult menisci, the vascularity is limited only to the peripheral 10% to 30% zone, unlike the prenatal period, where it is completely vascularised. This attributes to the high reparative ability of young menisci when comparing with that of the adult menisci. The Adult meniscus has 3 zones based on its vascularity (Figure 5): • Red zone – Outer third zone which is rich in blood supply. • Red-white zone – Middle third zone comprising less number of blood vessels • White zone – Inner third zone which has no vascular supply but nourished by synovial fluid, thus making it more vulnerable to degenerative lesions.

In case of structural degeneration of the menisci due to senescence, trauma or surgery it eventually leads to premature osteoarthritis of the knee joint.

Morphology and Biomechanics of Menisci: The morphology and geometry of the menisci contributes to the crucial load-bearing ability of the knee joint. The ‘Crescent’ shaped biological tissue minimizes the contact stress by the creation of hoop stresses or circumferential stresses. Voloshin AS et al (1983) have explained in their study that axial forces are created across the knee during weight bearing, which compress the menisci, resulting in

CERTIFICATE

This is to certify that the dissertation **“Radiological and Cadaveric Study of Medial and Lateral Menisci of Knee Joint in Adult and Fetus in South Indian Population"** is an original work done by **Dr.K.Evangeline Singh**, Post graduate student, Department of Anatomy, PSG Institute of Medical Sciences and Research, Coimbatore, under my supervision and guidance.

Dr.G.Amudha.M.S
Professor and HOD (Guide),
Department of Anatomy,
PSG IMS&R

Dr.S.Ramalingam. M.D
Dean,
PSG IMS&R.

DECLARATION

I solemnly declare that the dissertation **"Radiological and Cadaveric Study of Medial and Lateral Menisci of Knee Joint in Adult and Fetus in South Indian Population"** was done by me in the Department of Anatomy, PSG Institute of Medical Sciences and Research, Coimbatore, under the guidance of Dr.G.Amudha. M.S, Professor and HOD, Department of Anatomy, PSG Institute of Medical Sciences and Research, Coimbatore.

This dissertation is submitted to The Tamil Nadu Dr.M.G.R Medical University, Chennai in partial fulfillment of the university regulations for the award of degree of M.D Anatomy – Branch V examinations to be held in May 2020.

Place: Coimbatore **Dr.K.Evangeline Singh**

Date:

ACKNOWLEDGEMENT

First and foremost, praises and thanks to the God, the Almighty, for His showers of blessings throughout my research work to complete the research successfully.

I am extremely grateful to my parents **Mr.P.Kumar Singh and Mrs.Latha Mettilda** for their love, prayers and sacrifices that made me the person who I am today and not letting me down during the hardest phase of my life. I am very much thankful to my sisters **Dr.K.Caroline Singh, Anusha Singh and Nivetha Singh** for their priceless support to complete this research work. Also I express my thanks to my grandparents for their support and valuable prayers..

I would like to express my deep and sincere gratitude to my guide, **Dr. G. Amudha Mam,** for giving me invaluable guidance throughout this research and for being extremely patient in correcting my mistakes and helping me present this research work as clearly as possible.

My special thanks goes to my friend and sister, **Dr.Nandhini Aishwarya** for the keen interest and enormous support shown to complete this thesis successfully. I am extending my thanks to my Friends, Professors, Associate professor and Assistant professors for their constant encouragement. I express my special thanks to our lab technician and non-teaching staffs of my department.

URKUND

Urkund Analysis Result

Analysed Document:	thesis intro final (1) (1) (2).docx (D57278888)
Submitted:	10/19/2019 12:36:00 PM
Submitted By:	dr.evangelinesingh@gmail.com
Significance:	3 %

Sources included in the report:

https://scielo.conicyt.cl/scielo.php?script=sci_arttext&pid=S0717-95022004000300001
a2bfdb2e-ee73-43b9-9598-277046203f9c
https://www.researchgate.net/publication/9042633_The_normal_menisci_In_vivo_MRI_measurements
https://www.researchgate.net/publication/311989180_MORPHOMETRY_OF_LATERAL_MENISCUS_A_CADAVERIC_STUDY
https://www.researchgate.net/publication/312630059_Morphometric_analysis_of_menisci_of_adult_human_knee_joint_in_North_Indian_population

Instances where selected sources appear:

14

Radiological and Cadaveric Study of Medial and Lateral Menisci of Knee Joint in Adult and Fetus in South Indian Population

INTRODUCTION

The Latin word '*Menisci*' stems from a Greek word "*meniskos*" which denotes crescent. These intracapsular fibro cartilaginous structures are termed so because of their peculiar crescent moon like appearance.

The menisci endows congruency between the irregular surfaces of femoral condyles and tibial plateaus, thereby ensuring the stability of the knee joint in a healthy person. They are rich in glycoproteins, collagen and proteoglycans and they intersperse with cells (Arnoczky SP et al (1992), Ghadially FN et al (1983), Herwig J et al (1984).

Cognizance of these prime intraarticular structures retrogrades to the times of *Andreas Vesalius* , where he illustrated the structure of menisci in his book *"De Humani Corporis Fabrica"* in the year 1543***(Figure 1)***

Figure 1: Illustration of menisci by Andreas Vesalius

This was followed by exceptional illustrations by *Giovanni Battista Morgagni* in his book *"Adversaria Anatomica Prima* in 1706***(Figure 2)***, Leopoldo Caldani in his book of "*Icones Anatomicae"*in 1813***(Figure 3)***,Astley Cooper in the book of *"Treatise on dislocations and fractures of the joints" in* the year of 1826 ***(Figure 4)***.

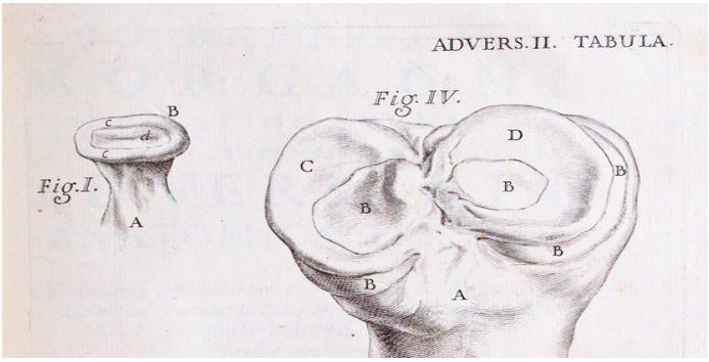

Figure 2: Illustration of menisci by Giovanni Battista *Morgagni*

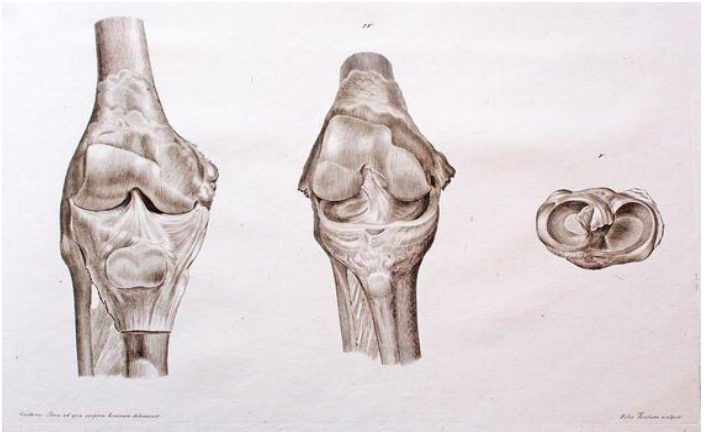

Figure 3: Illustration of menisci by Leopoldo Caldani

Figure 4: Illustration of menisci by Astley Cooper

Formerly, Menisci was referred as vestigial intra articular muscular remnants.This fact was later refuted after learning the correlation between the loss of menisci and the progression of premature osteoarthritis.

Thenceforward, the anatomy of menisci and its variations have been entailed and contemplated exhaustively in various parts of the world in the domains of morphology, morphometry, physiology, diagnostics, pathology and Interventions particularly the meniscal tissue replacement.

The vital functions of the knee joint include:

- Transmission of load across the tibiofemoral junction.
- Decreases the resultant stress placed on the articular cartilage.
- Acts as a shock absorber.
- Provides stability to the knee joint
- Acts as lubricant

Vascularity of knee menisci:

The vascularity of knee menisci is exceptional in many aspects. Menisci procure blood supply predominantly from the superior and inferior lateral and medial geniculate arteries through the perimeniscal capillary plexus. In adult menisci, the vascularity is limited only to the peripheral 10% to 30% zone, unlike the prenatal period, where it is completely vascularised. This attributes to the high reparative ability of young menisci when comparing with that of the adult menisci.

The Adult meniscus has 3 zones based on its vascularity ***(Figure 5):***

- **Red zone** – Outer third zone which is rich in blood supply.
- **Red-white zone** – Middle third zone comprising less number of blood vessels
- **White zone** – Inner third zone which has no vascular supply but nourished by synovial fluid, thus making it more vulnerable to degenerative lesions.

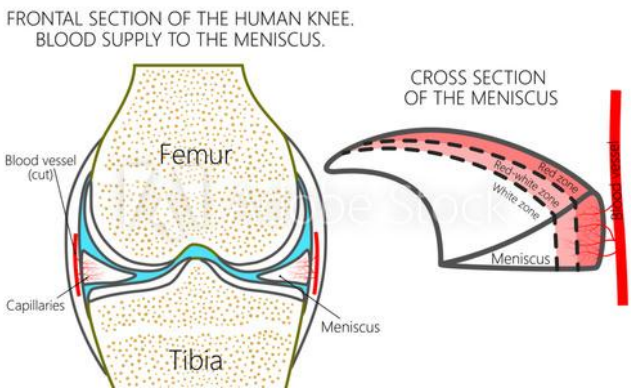

Figure 5: Vascular zones of menisci

In case of structural degeneration of the menisci due to senescence, trauma or surgery it eventually leads to premature osteoarthritis of the knee joint.

Morphology and Biomechanics of Menisci:

The morphology and geometry of the menisci contributes to the crucial load-bearing ability of the knee joint. The 'Crescent' shaped biological tissue minimizes the contact stress by the creation of hoop stresses or circumferential stresses. Voloshin AS et al (1983) have explained in their study that axial forces are created across the knee during weight bearing, which compress the menisci, resulting in "hoop" (circumferential) stresses ***(Figure6)*** on the collagen fibers of the menisci. Therefore, the shape of the meniscus is especially important in loading. .

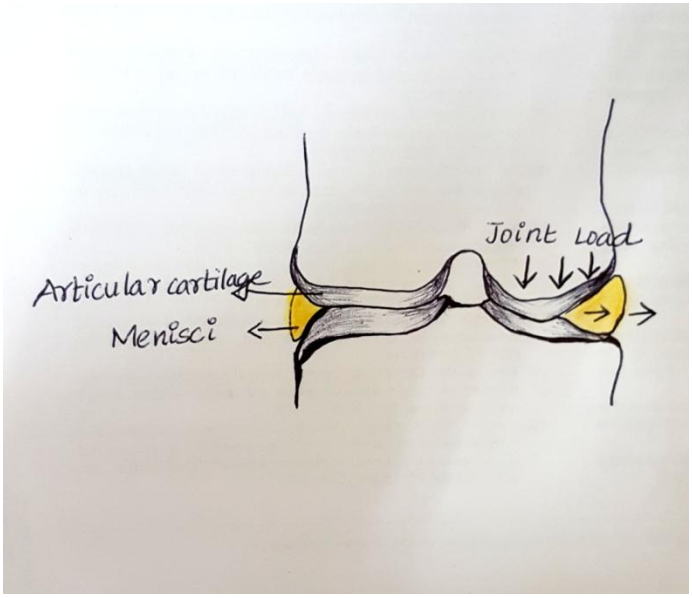

Figure 6: Transmission of Axial stress into Hoop stresses

Morphological variants particularly the discoid menisci were thought to be the ground for Knee pathologies as they alter the biomechanics of menisci.

The shape of menisci could be discoid and non-discoid menisci (Young et al 1889)and the discoid menisci could be sub classified as complete and incomplete discoid menisci (Watanabe et al 1979).The non discoid menisci has variants like sickle shaped , sided U shaped ,sided V shaped , crescentic (semi lunar) shaped and C shaped(Kale et al 2006) ***(Figure 7).***

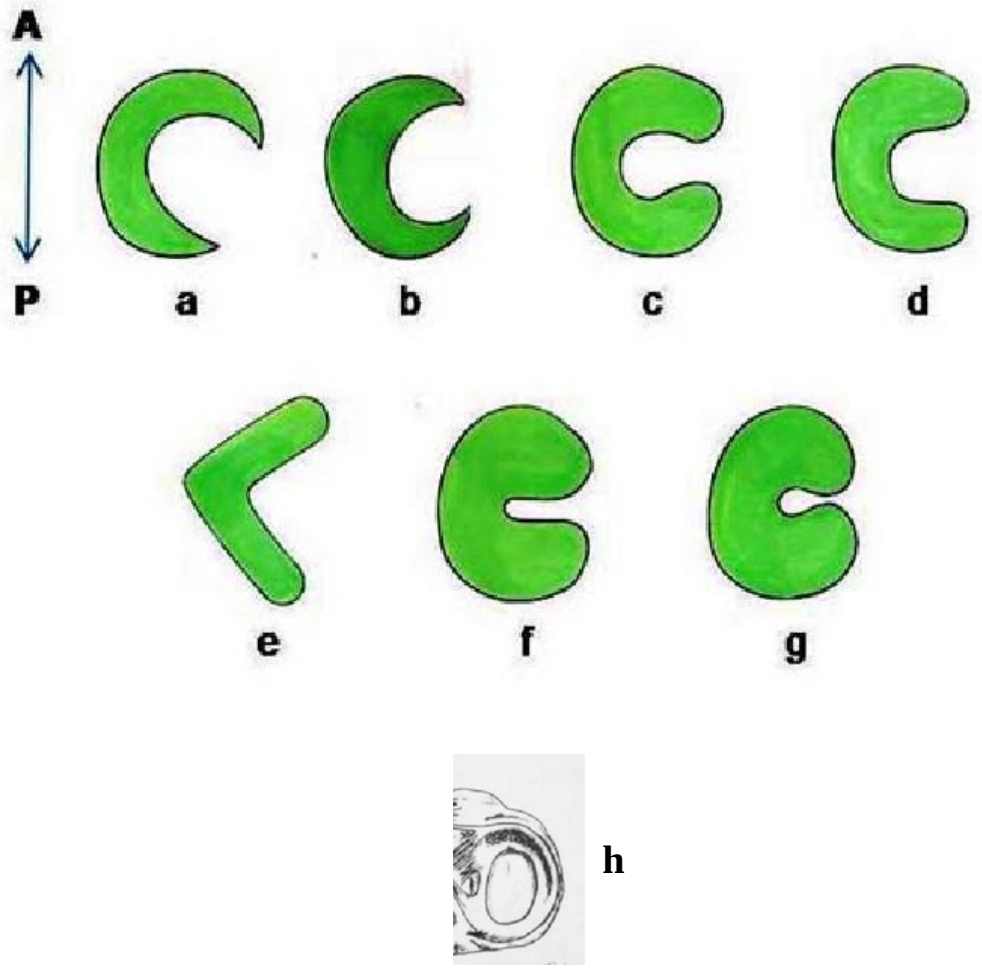

Figure7 :- a)Crescent Shape b)Sickle Shape c)C shape d)U Shape e)V shape f)Incomplete Discoid g)Complete Discoid h)Ring shaped

Arrangement of collagen fibers in the adult menisci:

The collagen fibrils (Type 1) are interspersed with each other and are arranged in 3 zones:

- -The outer third consists of randomly arranged collagen fibers to promote low friction motion between femoral condyles and tibial surface.
- -The middle third comprises of circumferentially arranged fibers to withstand compression during weight bearing.
- -In the inner third the fibers are arranged radially to withstand the axial stress, they are also found in the bulk of meniscal tissue which acts as a tie to resist the longitudinal splitting of circumferential collagen fibers ***(Figure 8)***

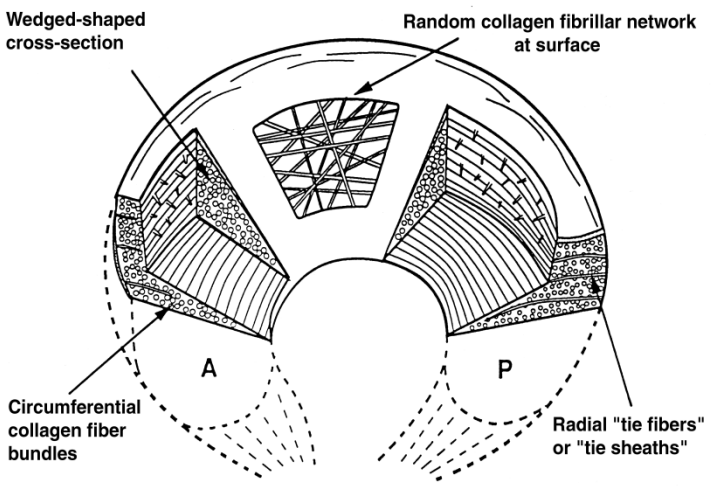

Figure 8: Arrangement of Collagen fibers in the menisci

Developmental Anatomy of Menisci:

The complete meniscal architecture is obtained between the gestational ages 8th and 10th week. Menisci develop from the intermediate layer of mesenchyme.

The development sequence of menisci is as follows:

At first, the appendicular skeletons appear continuous, without any joint cavities.

6thweek – Cartilaginous anlages of femur and tibia starts separating owing to the formation of Interzone.

7th week – A layer of decreased cell density initiates the formation of 3 layered interzones.

8th week – Cells of menisci attains a circular shape and it is randomly arranged.

9th week- Superficial meniscal cells becomes flatter and are oriented parallel to the joint surface and process of joint cavitation begins.

10th week – Menisci can be differentiated as a densely cellular tissue and its periphery consists of blood vessels and nucleus to the collagen ratio starts decreasing.

12th to 17th week – Cavitation process is complete. Collagen fibers are arranged parallel to the joint surface. Peripheral compact fibroblast layer forms 5-6 layered synovial membrane.

18th week – Sprouts of Blood vessels reaches the tips of the menisci.

Postnatally,

3 – 8 months – The morphology of the menisci commensurate with the anatomy of the femorotibial contact. Medial meniscus is more fixed than lateral meniscus. Microscopically, the cells appear more matured no evidence of cartilage matrix and blood vessel covers the entire substance of meniscus.

9th month – Steady increase in the amount of collagen can be noted and the internal zone appears avascular and occasionally blood vessels could be identified.

3 -9 years – Steady decline in the vascularity is noted. Collagen fibers appear highly organized, of which majority is arranged in circumferential manner along the long axis of meniscus.

Radial fibers could be located on the innermost layer of menisci which is more on tibial side in comparison with that femoral side and few are found to be running along the vertical pane of the body of menisci.

11 years – Menisci attains the maturity of adult menisci.

Clinical Anatomy:

Meniscal tears are the most common among knee injuries. Previous studies reported an annual incidence of 61 per 100,000 people (Baker et al, 1985). Meniscal tears are generally caused by a combination of axial loading and rotational forces that result in shear load on the meniscus (Browner et al., 2003). Meniscal lesions are closely associated with the development of knee OA, and their relationship is complex (D. J. Hunter, Y. Q. Zhang, J. B. Niu et al.,2006) Meniscal tears are characterized by the following symptoms :

- Pain in the knee
- Swelling
- A popping sensation during the injury
- Difficulty during flexion and extension of knee joint.
- Locking of knee.

Discoid meniscus:

The incidence of discoid lateral meniscus is estimated to be 0.4% to 17%.The discoid meniscus was first observed in a cadaveric specimen by **Young** (**1889)** ***(Figure 9)***.It is considered as the result of failure of absorption of central part of menisci.It is characterised by its biconcave disc shaped structure with a rolled medial edge covering the entire tibial plateau and its poor attachment owes to the classic “clunking knee” as it gets caught between the femoral

condyle and tibial plateau**(Grays's anatomy 40th edition).** Hence, it is said to be the predisposing factor for **snapping knee syndrome (Kroiss et al 1910 , Middleton DS et al 1936 , Dickhaut et al 1982)**and **Meniscal tear** in **(Ashwini et al 2012)** children and young adults because of its abnormal arrangement of collagen fibrils and abnormal vascularity. Saucerization is the technique that is used to treat discoid menisci where only the rim of the menisci is left behind.

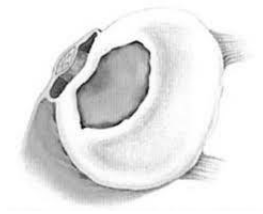

Figure 9: Discoid Menisci

Tenacious pain of meniscal tears is frequently treated with procedures such as partial or complete meniscectomy .

Total meniscectomy increases the peak contact stresses between the articular components, accounting for nearly 4% cartilage loss per annum and it is more on the lateral side **Kaplan EB et al (1957),** which resulted in 14 fold increase in radiographically documented osteoarthritis and debilitating knee pain.

The long term complications of meniscus removal are cartilaginous degeneration and bone remodeling. Presently a meniscal tear is repaired rather than removed provided the other meniscal tissue is of good quality; this paves

way for arthroscopic meniscal repair by using meniscal allograft, meniscal scaffolds.

Advancements in the investigation and treatment modalities of Meniscal tears:

Thomas Annandale sutured the medial meniscus in the year 1883.He was considered the first to do it. After that , there was a lot of development in the repair of menisci**(Mortiz Katzenstein ,1908).**Researchers performed animal experiments to prove the importance of menisci in promoting healthy knee joint**(King,1936).**There were studies conducted to show the evidences of degenerative changes of articular cartilage after meniscectomy **(Sir Thoms Fairbank,1948)** ,they insisted the importance of leaving behind the rim of meniscal tissue inorder to prevent such after effects **(Edward Tapper,1969).** Masaki Watanbe was believed to have performed the first arthroscopic meniscectomy in the year of 1962 .Meniscal allografts were introduced in painful postmeniscectomized patients**(Milachowski et al,1989)** and 75 – 90% of the patients experienced fair to excellent functional result **(Verdonk et al,2013).** Later, importance of size matched meniscal implant with size tolerance of 5% was told my many authors **(Brophy et al,2012).**

At present**,**scientists have built a meniscal scaffold using Polycaprolactone (PCL) via 3D printing technology which was loaded with connective tissue growth factor (CTGF) and transforming growth factor- (TGF-)β3. It was

shown to induce internal stem cell migration and differentiation to regenerate a new meniscus. It was found to be successful in sheep (***Figure 10)***

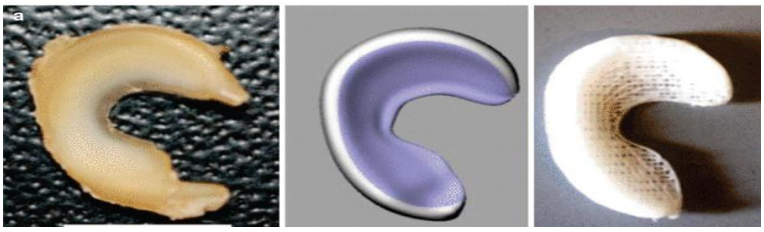

Figure 10 : Meniscal Scaffold

Meniscal Transplantation :

Meniscal transplantation in the recent years has been the most concentrated earmark in the field of orthopedics and Biomedical engineering. The slants of meniscal transplantation are by using allograft, auto grafts, biodegradable collagenous scaffolds, and permanent prosthesis. A successful meniscal replacement depends on the pertinent medium, apposite size and anatomically correct position of meniscus replacement.

Cartilage contact mechanics has been shown to be influenced by meniscal geometry **(Vrancken et al 2014)**. Partial removal of the meniscus results in an increase of the contact pressures on the articular cartilage **(Lee et al 2006; Bedi et al 2010; Seitz et al 2012)**. In addition, several studies have reported that discrepancies in the size between the native meniscus and a meniscal allograft increase the contact pressures as well **(Paletta et al 1997; Alhalki et al 2000).**

A mismatch in the size of more than 10% disturbs the contact mechanics and also increase the internal meniscus loads **(Dienst et al. 2007)**. A finite element analysis reported that the articular cartilage is more sensitive to geometric changes in the medial meniscus than the lateral meniscus due to its greater contact area **(Donahue et al, 2004).**

This study is targeted to enrich the anatomical knowledge on the incidence of morphological variations and morphometric data of menisci in dissected cadaveric fetal and adult specimens and MRI Images in this current geographic locale – Tamilnadu, India which will provide a greater insight in designing size matched meniscal scaffolds.

AIMS AND OBJECTIVES

AIM:

To study the incidence of morphological variations and to characterize and present midrange values and variability of knee menisci in dissected adult cadaveric specimens, dissected fetal cadaveric specimens and Magnetic Resonance Imaging.

OBJECTIVES:

- To determine the incidence of discoid and non discoid menisci in adult and fetal cadaveric specimens and MRI.
- To compare the incidence of variations of non discoid menisci in fetal and adult menisci.
- To observe the morphometry of medial and lateral menisci.
- To acquire knowledge on the developmental anatomy and congenital anomaly of fetal menisci.
- To measure the morphometry of menisci in living population using MRI.
- To compare meniscal thickness and width as measured by different techniques (anthropometric and Magnetic Resonance Imaging) to establish which of these 2 methods is more reliable and cost-effective for determining the meniscal size for grafting.

REVIEW OF LITERATURE

There are numerous corroborations relevant to the applied aspects of menisci and why the knowledge about menisci anatomy is crucial and ineluctable. Some of the documentations are enunciated below.

Literatures on Variations of shape of menisci:

Watson et al (1930) reported a case of 34 yrs male with clinical presentation of clicking sound on his medial side of knee joint associated with bucket handle tear and discoid medial menisci. He postulated that the tear could have lead to hypertrophy of meniscal tissue resulting in discoid shape of the menisci.

Smillie (1948) reported 29 cases of discoid lateral menisci among 1300 meniscectomies performed over a period of 7 years (1941-48) belonging to British population. Heconcluded that the discoid menisci was simple reflection of persistence of normal fetal state and divided the discoid meniscus into 3 types – Primitive, Intermediate and Infantile.

Kaplan (1957) however was unable to find a cartilaginous disc representing the meniscus at any stage of human embryological development or in any of his comparative anatomical dissections. He contended that the discoid lateral meniscus started as a normally shaped meniscus that has no attachment to the tibial plateau posteriorly. The lateral meniscus has only one attachment to the

tibial plateau posteriorly, the lateral meniscofemoral ligament, or the ligament of Wrisberg.

He also stated discoid menisci as a pathological entity which was influenced by various mechanical factors.

Ritchie et al(1965) had done a total of 39 menisectomies in children belonging to Australian population and found that discoid menisci was rare in children and concluded that the lateral menisci as the prime site for the occurrence of pathology in children.

Watanabe et al (1969) classified discoid menisci into 3 types based on arthroscopic appearance – complete, incomplete and Wrisberg variant (Based on atlas of arthroscopy, Tokyo).

Ikeuchi et al (1982) reported that among 45 patients belonging to North American population, the incidence of discoid lateral menisci accounted to 16.6% .

Dickason et al (1982) reviewed studies and found that out of 14,731 menisci which consisted of 8040 medial menisci and 6691 lateral menisci, the incidence of discoid menisci was 0.12% and 1.5% respectively.

Zaman and Leonard (1981) concluded after performing a series meniscectomies among 59 children, that arthroscopy of knee was needed before arthrotomy**.**

Bellier et al (1989) proved the relation between the snapping knee syndrome and discoid meniscus in French population by treating lateral discoid menisci with partial meniscectomies . It resulted in disappearance of snapping knee in 18 out of 19 knees

Vandermeer et al (1989) observed that among 22 patients with discoid meniscus belonging to Dallas population, 92% had incomplete discoid menisci and 8% had complete discoid menisci.

Verstraete,et al (1997) reported that radial displacement of menisci after meniscal transplantation was more common.

Kim et al (1998) found that out of 14 knee joints belonging to Korean population 14.2% had anatomical variations among which the incidence of discoid menisci was 10.9%.

Rao et al (2001) found that the incidence discoid menisci accounted to 5.8% among 100 knee menisci belong to East Goadavari region.

Rohren et al (2001) reviewed 1250 menisci retrospectively found 49 patients (45%) with lateral discoid menisci out of which 71 % patients with lateral discoid meniscus was associated with meniscal tears.

Fukuta et al (2002) reported an incidence of 13% of lateral discoid menisci out of 115 knee menisci using MRI in Japanese population.

Greis et al (2002) reported an incidence of 0.4% - 17 % discoid lateral menisci among Utah population.

Davidson et al (2003) did a study on bilateral discoid knee menisci in 34 children (32 had unilateral discoid menisci and 2 had bilateral discoid menisci) belonging to Ottawa, who were treated with partial/complete meniscectomy either arthroscopically or by open arthrotomy. Out of 36 knees, 16 of the children had excellent outcome, 10 good, 6 fair and 4 poor outcomes out of which two of them showed radiologically evident degenerative changes. He also added that out of 36 knees, 35 lateral menisci were affected.

Erbagci et al (2004) encountered three cases (1.7%) of discoid lateral meniscus in MRI among 174 subjects belonging to Turkish population.

Weiner (1974) , Engber (1981) , Nathan (1969),Ha (2009)reported that discoid lateral menisci was associated with anomalies like high fibular head, hypoplasia of lateral femoral condyle and fibular muscles, dipped tibial plateau, hypoplasia of lateral tibial spine.

Kale et al (2006) found that among 22 neonatal cadaveric knee joints belonging to Turkish population, 77.27% (17 LM) of the LMs were discoid. 54.54% of the LMs were incomplete discoid (thick horse shoe shaped), and 22.72% of the LMs were complete discoid. It was found that 22.72% of the LMs were undiscoid of which 13.63% of the LMs had a crescentic shape, and 9.09% of the LM (2 LM) were C shaped.

Papadopoulous et al(2009) reported an incidence of discoid lateral menisci 0.4% - 5% arthroscopically among Greek population.

Murlimanju et al (2010) had concluded based on their study among 108 adult menisci belonging to Manglorean population that 50% of the medial menisci were crescent- shaped, 38.9% were sided V-shaped and 11.1% were sided U-shaped. The incidence of morphological variants of lateral menisci was 61.1% were C-shaped and 38.9% were crescent-shaped. The Discoid meniscus was not found in their study population.

Murlimanju et al (2010) on observing the morphological variants among 106 fetal menisci belonging to Manglorean population reported that 82.1 % of the LMs were found to be nondiscoid, out of which 62.3% were C-shaped, 19.8% were crescentic and the remaining 17.9% was discoid menisci. Among the discoid menisci, 14.1 % were incomplete discoid and3.8% were completely discoid. The common shape of Medial menisci was crescentic (46.2%), whereas the lateral menisci was C shaped (62.3%)

Lachaniette et al (2011) reported 4 cases of symptomatic discoid medial meniscus using MRI which were not found in plain x-rays in French population.

Bae et al(2012)reported 52 patients belonging to Asian population with discoid menisci arthroscopically, among which 31 were complete discoid menisci and 21 were incomplete discoid menisci.

Patel et al (2012) reported that among Philadelphian population, out of 76 discoid menisci, 60 were unilateral(lateral) discoid menisci and 16 were bilateral discoid menisci(lateral) using MRI and plain X-ray.

Kini et al (2015) reported a case of 38-year-old female belonging to London population with symptomatic complete discoid medial meniscus in one knee and incomplete discoid menisci on the other knee using MRI.A horizontal tear in both knees were noted during arthroscopy and was proceeded with partial meniscectomies of both menisci.

Glisic et al (2015) among 1357 knee reported an incidence of 1.03% discoid lateral menisci among Serbian population.

Itagi et al (2015) reported that out of 120 menisci specimens, 96.66% of medial menisci were cresentric in shape, 1.66% showed sided V shaped and 1.66% showed sickle shape and among the lateral menisci 88.33% were C shaped, 6.66% sided U shaped and 5% showed incomplete discoid belonging to North Karnataka population.

Rashmi et al (2016) studied the shapes of 50 adult cadavers and concluded that the incidence of discoid medial and lateral meniscus were 0%

Koyuncu et al (2017) on studying 210 fetal knee specimens**,** reported the incidence of most common shape of the medial meniscus as crescentic in 50%

of specimens, and C-shaped in 61 % of the lateral menisci specimens among Turkish population.

Chakravarthy et al(2018) reported that among 116 cadaveric menisci belonging to Chennai population , 4.6% of medial menisci were crescent shaped ,34.6% were V shaped ,10.8% were U-shaped and no discoid medial menisci were observed and Out of 58 lateral menisci studied, 56.4% were C-shaped, 41.6% were crescent shaped and 2% were discoid .

Shashidhar et al (2019) studied the variations in the shapes of the menisci among 50 adult cadaveric menisci and the variations of medial menisci were found to be, 50% crescent- shaped,37% were sided V-shaped and the remaining 13% were sided U-shaped. 72% of the Lateral Menisci were found to be C-shaped and 26% were crescent-shaped. One partial discoid lateral meniscus (2%) was observed.

Literatures on Morphometrics of Menisci:

Cailliet (1976) reported that the lateral meniscus showed an average width of 12-13mm, while the medial meniscus had an average width of 10mm.

Testut and Latarjet (1975) mentioned in a more generalized description of the morphometric study of menisci that the average thickness of outer circumference was 8mm for the lateral meniscus and 6mm for the medial meniscus and that the average width of menisci was 10-12mm.

Hayashi et al (1988) described that the normal menisci showed thickness of 6-8mm and and width of 12-13mm.

Araki et al (1994) established apt criteria for Magnetic resonance imaging in diagnosing discoid menisci by correctly identifying 38 lateral discoid menisci among 33 knees providing an accuracy of 93% using parameters such as thickness and width of lateral menisci.

Erbagci et al (2004)observed the measurements of menisci among 174 healthy MRI Images and found that for the medial meniscus; the thickness of anterior third, middle third and posterior third were 5.32mm,5.03mm,5.53mm and width of anterior third, middle third and posterior third were 7.78mm,7.37mm and 11.71mm respectively. Regarding the lateral menisci the thickness of anterior third, middle third and posterior third were 4.33mm,4.94mm,5.36mm respectively and width of lateral menisci of anterior third, middle third and posterior third were 8.88mm,8.37mm,9.70mm respectively and the incidence of discoid lateral meniscus was 1.7%.

Almeida et al (2004) reported that among 44 cadaveric menisci belonging to Brazilian population, thickness of medial menisci anterior third ,middle third and posterior third were 5.92 ± 1.37 mm, 5.31 ± 1.06 mm 5.91 ± 1.13 mm respectively and thickness of lateral menisci anterior third, middle third and posterior third were 3.71 ± 1.15 mm ,6.10 ± 1.04 mm ,5.29 ± 0.78mm respectively .The width of medial menisci were anterior third, middle third

and posterior third were 9.02 ± 1.59 mm , 12.16 ± 2.58 mm , 17.37 ± 2.22 mm respectively and the width of lateral menisci at the anterior third, middle third and posterior third were 11.86 ± 1.81mm, 11.97 ± 2.56mm and 11.44 ± 1.07mm respectively.

Braz et al (2010)conducted study on 92 knee joints and found that the thickness of anterior third, middle third and posterior third of medial menisci were third was 6.17±1.68mm,6.31±1.73mm and 5.18±1.55mm respectively and the width of medial menisci at anterior third, middle third and posterior third were 7.68±1.36mm, 9.32±2.24mm and 14.46±2.26mm respectively. The thickness of anterior third, middle third and posterior third of lateral menisci were 4.40±0.83mm, 6.52±1.81mm and 5.46±1.19mm respectively and the width of lateral menisci at anterior third, middle third and posterior third were 11.32±1.46mm,11.16±1.64mm and 11.67±1.54mm respectively.

Panigrahi et al (2013) after studying 38 menisci among chennai population,concluded that the width of medial meniscus to be anterior third as 2.67 ± 0.33 mm, mid body as 3.16 ± 0.6 mm and posterior horn as 4.85 ± 0.74 mm and the lateral meniscus as anterior third 3.62 ± 0.95mm , middle third as 4.61 ± 0.97 mm and posterior third as 4.43 ± 0.67 mm .The mean thickness of medial menisci was found to be 2.34 ± 0.17 mm and lateral menisci as 1.59 ± 0.34mm.

Vineet et al (2013) after studying 54 knee joints from 27 formalin fixed fetuses belonging to Indore population ,they concluded that the mean thickness of medial menisci at the anterior one third as 2.04 ± 0.47 mm, middle one third as 2.19 ± 0.49mm and posterior one third as 2.05 ± 0.56mm and thickness of lateral menisci anterior one third as 1.80 ± 0.42 mm ,middle one third as 2.00 ± 0.45 mm and posterior one third as 1.76 ± 0.41 mm .The mean width of medial menisci was 3.06 ± 0.61 mm in its anterior one third,2.94 ± 0.53 mm in its middle third and 3.51 ± 0.74 mm in its posterior one third and of lateral menisci the anterior one third as 3.22 ± 0.50 mm ,middle one third as 3.49 ± 0.70 mm and posterior one third as 3.63 ± 0.63 mm .

Pawar et al (2014) studied 100 adult cadaveric specimens among Indian population and observed that the thickness of medial menisci at anterior third, middle third and posterior third were 5.88+1.27mm, 5.35 ± 0.67mm and 5.91 ±.83mm respectively and lateral menisci at anterior third, middle third and posterior third were 5.30 ± 0.59 mm, 5.30 ± 0.61, 5.60 ±.80mm and 5.60 ±.80mm respectively. The width of medial menisci at anterior third, middle third and posterior third were 6.10 ±.096mm, 6.30 ± 1.30mm and 8.50 ± 1.68mm respectively.

Chintan et al (2014) conducted study on 50 knee menisci belonging to surat population and observed the mean thickness of medial menisci at anterior third as 5.82±1.44 mm , middle third as 5.64±1.26 mm and posterior third as

5.86±1.06 mm and thickness of lateral menisci at anterior third as 3.7±1.52 mm , middle third as 5.78±1.22 mm and posterior third as 5.20±0.98 mm . The mean width of medial menisci at anterior third was 8.78±2.12 mm, middle third was 12.08±2.52 mm and posterior third was 16.46±2.18 mm and that of lateral menisci at anterior third was 11.3±1.30 mm, middle third was 11.66±1.48 mm and posterior third was 11.50±1.34 mm .

Narayan et al (2014) reported after studying 100 adult cadaveric knee joints belonging to East Goadavaric region that in the medial meniscus, the posterior third was the widest part (15.80 ± 2.35 mm) followed by middle third (10.50±1.20 mm) and the anterior third (8.30±1.06 mm). Comparing the width of the medial and lateral menisci, a statistically significant difference ($p<0.05$) in three points was found. The middle third of the medial meniscus was thickest (5.60±0.60 mm) followed by anterior and posterior thirds (5.40±0.5mm) showing an average of 5.47 mm. Similarly, in the lateral meniscus, the middle third was the thickest (5.90±0.33 mm) followed by the posterior (5.70±0.40 mm) and anterior (5.00 ± 0.56 mm) thirds, and their average value was 5.53 mm.

Dhananjaya et al (2014) on studying 40 knee joints reported that the mean thickness of medial meniscus at the anterior horn, mid body, and posterior horn were 6.3 ± 1.1 mm, 5.2 ± 1.3 mm, and 6.9 ± 1.1 mm, respectively and the lateral meniscus were 4.8 ± 0.7 mm, 6.4 ± 1.1 mm, and 7.0 ± 0.9 mm. The

mean width of medial meniscus at the anterior horn, mid body, and posterior horn were 10.5 ± 1.2 mm, 7.8 ± 1 mm and 13.9 ± 0.9 mm, respectively. The widths of lateral meniscus at the same regions were 11.8 ± 1.4 mm, 8.6 ± 1.2 mm, and 12.0 ± 0.9 mm, respectively.

Itagi et al (2015)reported that among 120 medial menisci belonging to North Karnataka population, the mean thickness of anterior third, middle third and posterior third were 4 ± 0.69mm, 4.2 ± 1.08mm, 4.4 ± 0.73mm respectively and the mean width of anterior third, middle third and posterior third were 6.9 ± 1.24mm, 7.2 ± 1.53mm and 12.1 ± 2.20mm respectively.

Goyal et al (2016) studied the width of 100 cadaveric lateral menisci belonging to Patiala population and the width at anterior third was 1.05mm, middle third was 1.05 and posterior third was 1.13mm.

Rashmi et al (2016) conducted study among 50 menisci among Karnataka population andfound the mean width of medial menisci at anterior horn as 8.88±0.19mm, mid body as 12.09±0.22mm and the posterior horn as 16.68±0.60 mm The mean width of lateral menisci at anterior horn was 11.52±0.23 mm, midbody was 11.87±0.29 mm and posterior horn was 11.46±0.12 mm.

Rohila et al (2016)studied 200 cadaveric menisci belonging to North Indian population and found that the width of the lateral meniscus, showed a significant difference between the three parts of menisci ,where the middle

third 11.21±2.91 mm was thicker than the anterior third 9.93±1.71 mm, and posterior third 11.03±1.40 mm. However, in the medial meniscus, the posterior third was the widest part 14.34±2.37 mm followed by the middle third 10.82±1.69 mm and anterior third 7.37±1.06 mm.

Shital et al (2018)observed that among 60 cadaveric menisci belonging to the population of Gujarat and concluded that thickness of medial menisci and recorded anterior third as 6.21±0.6 mm, middle third as 6.18±0.55 mm and posterior third as 6.30±0.42 mm and the width of medial menisci anterior third as 9.05±0.70 mm ,middle third as 11.10±0.45 mm and posterior third as 15.39±0.8 mm .

Chakravarthy et al (2018) revealed after conducting study on 58 cadaveric adult menisci belonging to the south Indian population that the width the lateral meniscus is more than that of the medial meniscus and the medial meniscus is thicker when compared to the lateral meniscus in both the left and right side knee.

Kaur et al (2019) after studying the medial menisci in 30 adult cadaveric knees found the mean width of anterior segment of medial menisci as 0.95±0.25 cm, middle segment as 1.02±0.25 cm and posterior segment as 1.46+0.26 cm.

Sivasakthi et al (2019) reviewed the range of thickness of medial meniscus at anterior third as 5.40 ± 0.5 to 6.40 ± 1.3 mm ,middle third as 5.2 ± 1.3 to 6.43

± 1.15 mm and posterior third as 5.18 to 6.72 ± 1.12 and the width of medial menisci ranges as anterior third 7.37 ± 1.06 to 10.02 ± 1.59 mm ,middle third 7.8 ± 1 to 12.16 ± 2.58 mm and posterior third 13.9 ± 0.8 to 17.37 ± 2.22 mm .The range of thickness of lateral menisci at anterior third was 3.71 ± 1.15 to 5.90 ± 0.33 mm ,middle third was 5.00 ± 0.56 to 6.75 ± 1.13 mm and posterior third was 5.29 ± 0.78 to 7.0 ± 0.60 mm and the range of width of lateral menisci at anterior third was 7.37 ± 1.0 to 11.86 ± 1.81 mm ,middle third was 8.6 ± 1.2 to 12.53 ± 0.72 mm and posterior third was 9.80 ± 1.16 to 12.03 ± 0.8 mm .

Literatures on Meniscal Allograft Sizing and Methods used :

Lexer et al (1931) used Hoffa's fat pad (infrapatellar fat) as a replacement of meniscal tissue in one of his animal experiments and observed the transformation of the fat tissue into meniscal tissue.

Kohn et al (1992) conducted meniscal autograft study on 20 female merino sheep using Achilles tendon and patellar tendon as autografts and found that the remodeling took about 12 months and it was not able to withstand the tensile force as that of the normal menisci and it was found to decrease the severity of osteoarthritis which follows meniscectomies.

Stone K R et al(1992) replaced the menisci with CMI® which is a scaffold derived from bovine Achilles tendon which was found to be rich in glycosaminoglycans and the clinical trial revealed that there was no adverse

effects in the human knee and after 36 months of implantations it showed a positive clinical outcome

Kohn et al (1993)did a study on 35 female meniscectomised sheeps. The sheeps were divided into 3 groups, 1st group with hoffa's fat pad as autograft, 2nd group with tendon as the autograft and the 3rd group consisted of sheeps without any graft replacement. They observed that group 1 showed 3 cases with meniscal remodeling considering the shape and size of the graft they were called "complete fat meniscus", In 9 sheeps, the size of the menisci were smaller when compared with that of the native menisci but the shape ,were similar. In group 2, 6 had complete tendon menisci, 8 had incomplete tendon menisci and one of the sheep showed regenerated menisci.

When tested for the tensile strength of the complete menisci with the outer hyaline cartilage as the parameter, they were not able to withstand the given pressure as compared to the normal meniscal tissue and they showed degenerative changes in long term.

Van Arkel et al (1995) studied the failure rate in meniscal transplant and found that 13% of the failure was due to misalignment secondary to impaired revascularization of the graft.

Milachowski K.A et al(1990),kohn et al (1993),Walsh C.J et al (1999),Cisa J et al (1995) had reported satisfactory results on using autograft as fat pad, tendon, periosteum, synovial flap and perichondrium .

Noyes et al (2004) evaluated the outcomes of meniscal allograft transplantation in 76% of the patients returned to low impact sports like swimming and bicycling.63% of the same patient population showed positive outcome .The study also revealed that about 40% of the population group in the age group 15 years showed negative outcome which later required additional surgery.

Rodkey et al (2005) after a clinical follow up of 6 years of 8 patients with tissue engineered collagen implant had a good prognosis and the menisci like tissue maintained its tissue integrity and function even after 5 years of follow up.

Dienst M et al (2007) reported after studying 4 right and two left intact knee joints concluded that over sized meniscal allografts led to excessive force over the articular cartilages and on the contrary undersized meniscal allografts caused greater force on the menisci thus leading to the subsequent development of degenerative changes. The mismatch up to 10% of the actual size of menisci is acceptable. This study reinforced the importance of preoperative radiographic sizing of the menisci.

Balint et al (2009) designed a fiber based scaffold consisting of quasi-circumferentially wrapped collagen-polymeric fibers with the ability to convert applied compressive loads into tensile hoop stresses as that of the native

menisci but it failed because of lack of tissue integrity when the load was applied.

Elsner JJ et al (2010) used polyethylene reinforced polycarbonate urethane (PCU) meniscus implant NUsurface® which is found to have restored the joint space and also maintained cartilage signal intensity even after 12 months of implant.

Gonzalez-Lucena G et al (2010) reported that the meniscal transplantation provided mitigation from knee pain and it also delayed the onset of Osteoarthritis and the failure rate ranged between 0% to 33.3%.

Morguchi Y et al (2013) experimented on porcine model and suggested that feasibility of meniscal repair when mesenchymal stem cell (MSC)-based therapies were used.

Liu C et al (2013) concluded after reviewing studies on post meniscectomized patient follow ups with meniscal grafts that graft size matching, appropriate preservation techniques, and surgical transplantation technique are important issues for the success of such transplantation procedures.

El-Amin et al (2011) and Holloway et al (2014)checked the compatibility of fiber-embedded hydrogel composite which consisted of ultra high molecular weight polyethylene (UHMWPE) fibers embedded in a polyvinyl-alcohol

(PVA) matrix and found that it gave the similar effect on the post mensicectomised knee joint .

Kaleka et al (2016)after studying the MRI Images and Plain radiographs of 22 patients belonging to Brazilian population they concluded that MRI was considered to the most suitable method in measuring the morphometry of menisci .They insisted the importance of measuring the thickness and width of menisci using MRI for preoperative sizing of grafts. One of the limitations they have mentioned in their study was that they could have compared the MRI parameters with the measurements from cadaveric samples.

MATERIALS AND METHODOLOGY

Our study was carried out among specimens from knee joint of adult cadaver and fetal specimens and also from MRI images at PSG Institute of Medical Sciences and Research. The Institutional Ethics committee approval was acquired before initiating the study.

Study Design: Observational Descriptive Study

Study Duration: 3 years

Sample Size:

The sample size of 250 which included 100 formalin preserved fetal knee menisci,50 formalin preserved adult knee menisci and 100 MRI Images of knee menisci of Tamil Nadu Population were taken.

- 100 formalin preserved fetal knee menisci of unknown age and sex and 50 formalin preserved adult menisci were collected from Department of Anatomy, PSG Institute of Medical Sciences and Research.

- 100 MRI Images of Adult Knee Joints were collected from Department of Radio-Diagnosis, PSG Institute of Medical Sciences and Research.

Formalin Preserved Cadaveric Menisci :

Inclusion criteria:

1. Normal MRIs without meniscal tears
2. Adult Cadavers of either sex which were embalmed were included in this study
3. Fetal cadavers of either sex above the gestational age of 9 weeks which were embalmed were included in this study

Exclusion criteria :

1. Fractured/Dislocated Knees
2. Arthritic Knee
3. Exostosis, which can change the dimensions of menisci are excluded from the study

The Adult and fetal knee joint knee satisfying the above criteria were included in our study and they were numbered and dissected methodologically to expose the knee menisci and the morphometric measurements were taken using digital vernier caliper with an accurate resolution of up to 0.01mm.The morphology of the menisci were noted macroscopically. The collected data was recorded and subjected to statistical analysis.

Dissection Procedure:

The Dissection was carried out using standardized dissection instruments such as Surgical Scalpel with a BP Handle, Blunt Knife, Retractor, Scissors(blunt & sharp), Allis Tissue Forceps ,Dissecting Forceps(plain & toothed) .

Following the dissection of the skin, fascia and the muscles, the joint capsule was incised and the patellar ligament and the collateral ligaments were cut transversely and the menisci was exposed (***Figure 11,Figure 12,Figure 13,Figure 14.)***The menisci were then studied for their shape. The morphometrics of menisci were noted using digital vernier caliper and this was done without disturbing the tibial attachment of the menisci.

1. **The Morphology of Adult Knee menisci:**

The menisci were morphologically classified as Discoid and Non Discoid variants. The non-discoid menisci variants were sub grouped as sickle shaped , sided U shaped ,sided V shaped, Crescentic (semi lunar) shaped ,C shaped and Ring shaped***(Figure 15).***

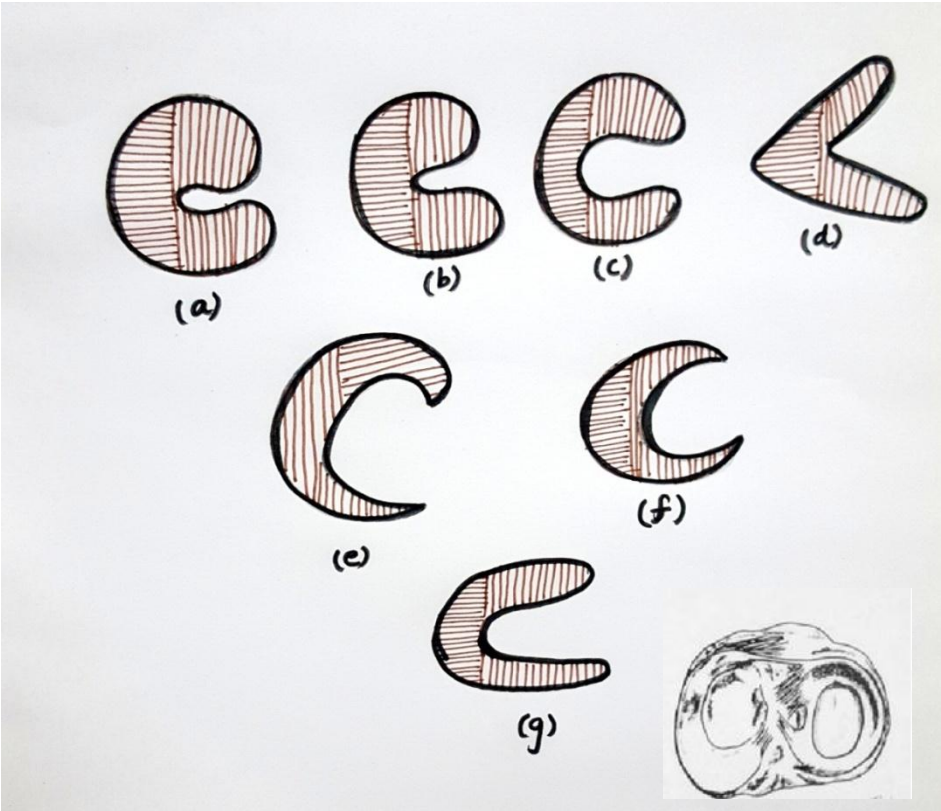

Figure15 : a)Complete Discoid b)Incomplete Discoid c)C shape d)V Shape e)Crescent shape f)Sickle shape g)U shape h)Ring shaped.

The incidence of each morphological variants were observed and entered in data sheet.

2. Morphometry of Adult and Fetal Cadaveric knee menisci :

For the parameters to be measured, the menisci was divided into 3 equal parts,the anterior horn ,mid body and posterior horn ***(Figure 24, 25 and 26,27,28,29,30,31,32)***.The thickness and width of the menisci was measured using digital vernier caliper.

PARAMETERS:

A. **Inter meniscal horn distance** – Distance between the anterior horn and posterior horn of medial meniscus and lateral meniscus

B. **Width of anterior third of menisci** – Distance between inner and outer rim at the midpoint of anterior horn

C. **Width of middle third of menisci** – Distance between inner and outer rim at the mid point of mid body of menisci.

D. **Width of Posterior third of menisci** – Distance between inner and outer rim at the mid point of posterior horn

E. **Thickness of anterior third of menisci** – Distance between superior and inferior surface at the midpoint of anterior horn of menisci

F. **Thickness of middle third of menisci** – Distance between superior and inferior surface at the midpoint of mid body of menisci

G. **Thickness of posterior third of menisci** – Distance between superior and inferior surface at the midpoint of posterior horn of menisci.

Radiomorphometrics:

MRI images were collected from the department of Radio diagnosis, PSG Institute of Medical Sciences and Research. The data was collected retrospectively .The images were taken for different clinical conditions.

The study included images of knee joint in the age group ranging from 20 to 80 years. Images with meniscal tear, bony anomalies were excluded from the study.

The images were retrieved from PACS (Picture Archiving communication system) Software and the measurements were undertaken using special tool bars for linear measurements ***(Figure 34,35,36,37 and 38)***. The section of the images in which all the bony structures were clearly visible was included for the study.

The following parameters were measured and documented :

A. **Width of anterior third of menisci** – Distance between inner and outer rim at the midpoint of anterior horn

B. **Width of middle third of menisci** – Distance between inner and outer rim at the mid point of mid body of menisci.

C. **Width of Posterior third of menisci** – Distance between inner and outer rim at the mid point of posterior horn

D. **Thickness of anterior third of menisci**–Distance between superior and inferior surface at the midpoint of anterior horn of menisci

E. **Thickness of middle third of menisci** – Distance between superior and inferior surface at the midpoint of mid body of menisci

F. **Thickness of posterior third of menisci** – Distance between superior and inferior surface at the midpoint of posterior horn of menisci.

All the recordered data were subjected to statistical analysis such as mean,standard deviation, standard deviation error and student's t test using SPSS Software.

OBSERVATIONS AND RESULTS:

The morphological features and morphometric measurements of adult and foetal cadaveric menisci were macroscopically noted, measured and tabulated.

Adult cadaveric menisci:

The incidence of the following morphological variants among 50 adult cadaveric menisci were recorded in a data sheet and analysed.

a) Complete Discoid
b) Incomplete Discoid
c) C shape
d) V Shape
e) Crescent shape
f) Sickle shape
g) U shape

MORPHOLOGY OF ADULT CADAVERIC LATERAL MENISCI :

MORPHOLOGICAL VARIANTS	N	NUMBERS
CRESCENT SHAPED	50	7
DISCOID SHAPED	50	3
INCOMPLETE DISCOID	50	1
C SHAPED	50	29
U SHAPED	50	10

Table 1: Number of morphological variants among Adult cadaveric lateral menisci

MORPHOLOGICAL VARIANTS	INCIDENCE
CRESCENT SHAPED	14%
DISCOID SHAPED	6%
INCOMPLETE DISCOID	2%
C SHAPED	58%
U SHAPED	20%

Table 2: Incidence of Morphological Variants among adult cadaveric lateral menisci

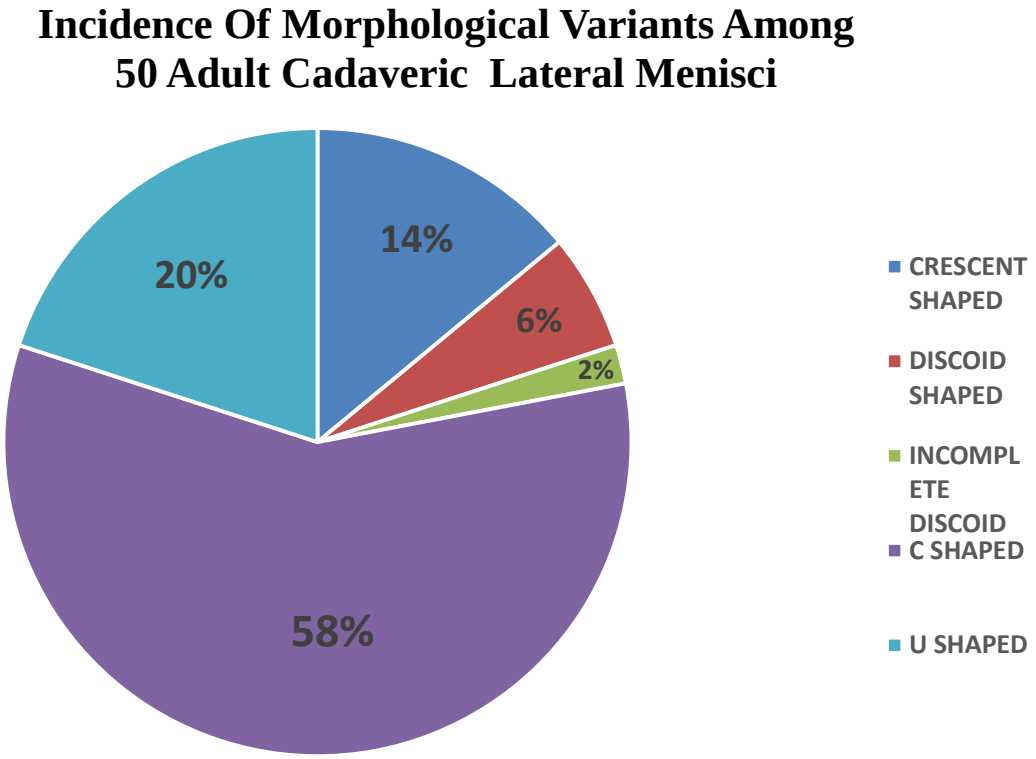

Chart 1 : Incidence of Morphological variants among adult cadaveric lateral menisci

Discoid and Incomplete discoid menisci are considered to be rare variants and in our study,there were 3 discoid and 1 incomplete discoid menisci, followed by 7 Crescent shaped menisci,10 U shaped menisci and 29 C shaped menisci (**Table 1**).

They were subjected to data analysis using SPSS Software and the incidence of Incomplete discoid,Complete discoid,Crescent shaped menisci,U shaped menisci and C shaped menisci were found to be 2%,6%,14%,20% and 58% respectively(**Table 2).**

Among the variants of lateral menisci, the incidence of C shaped menisci 58% was found to be the highest and the incomplete discoid menisci 2% to be the lowest(**Chart 1)**.

MORPHOLOGY OF MEDIAL ADULT CADAVERIC MENISCI :

MORPHOLOGICAL VARIANTS	N	NUMBERS
CRESCENT SHAPED	50	37
SICKLE SHAPED	50	6
C SHAPED	50	2
V SHAPED	50	5

Table 3: Number of morphological variants among adult cadaveric medial menisci

MORPHOLOGICAL VARIANTS	*INCIDENCE*
CRESCENT SHAPED	*74%*
SICKLE SHAPED	*12%*
V SHAPED	*10%*
C SHAPED	*4%*

Table 4: Incidence of Morphological Variants among adult cadaveric Medial Menisci

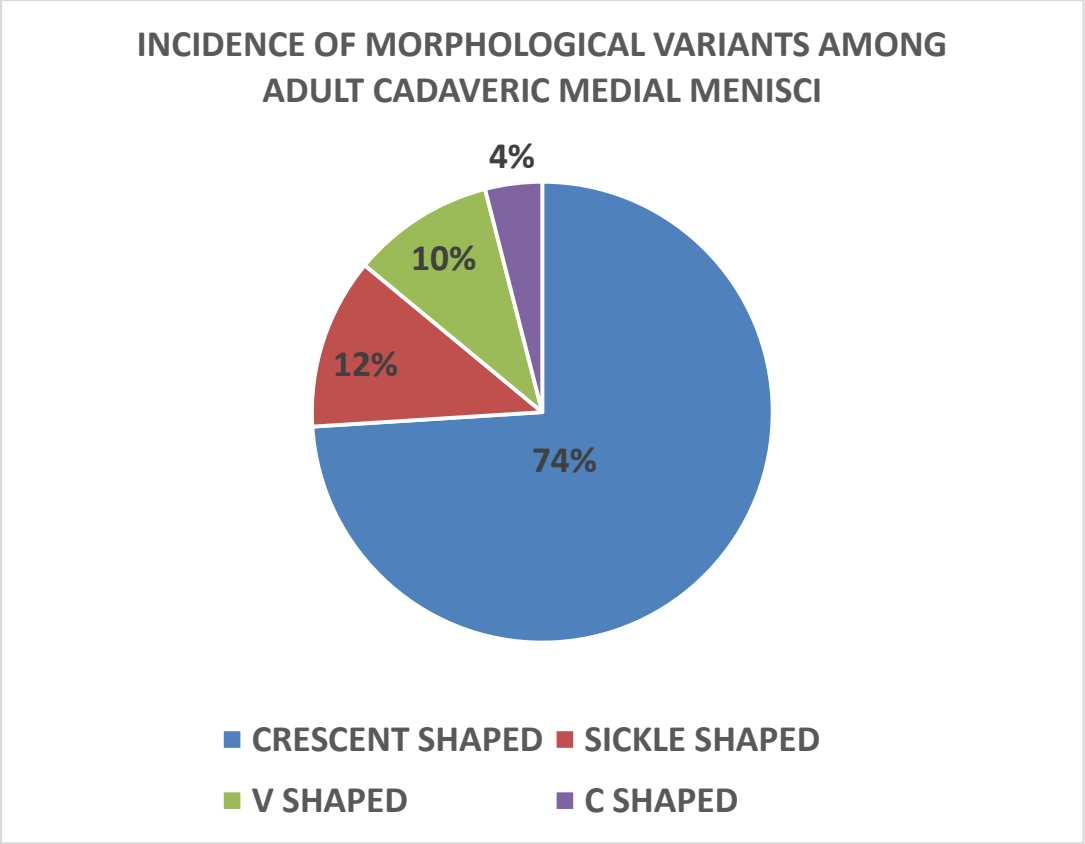

Chart 2: Incidence of morphological variants among adult cadaveric medial menisci

The number of the morphological variant among 50 adult cadaveric medial menisci were 37 Crescent shaped menisci,5 U shaped menisci,2 C shaped menisci and 6 Sickle shaped(**Table 3)**.

They were subjected to data analysis using SPSS Software and the incidence of Crescent shaped menisci,Sickle shaped menisci,V shaped menisci and C shaped menisci were found to be 74%,12%,10% and 4% respectively **(Table 4)**.

Among these the incidence of Crescent shaped menisci 74% was found to be the highest and the C shaped menisci 4 % to be the lowest (**Chart 2)**.

On comparing the incidence of morphological variants among 50 medial and lateral adult cadaveric menisci,the Crescent shaped menisci and the C shaped menisci were more common among medial and lateral menisci

INCIDENCE OF MORPHOLOGICAL VARIANTS	TOTAL
DISCOID MENISCI	3%
INCOMPLETE DISCOID MENISCI	1%
CRESCENT SHAPED MENISCI	44%
SICKLE SHAPED MENISCI	6%
C SHAPED MENISCI	31%
U SHAPED MENISCI	10%
V SHAPED MENISCI	5%

Table 5: Incidence of morphological variants among the adult cadaveric knee menisci

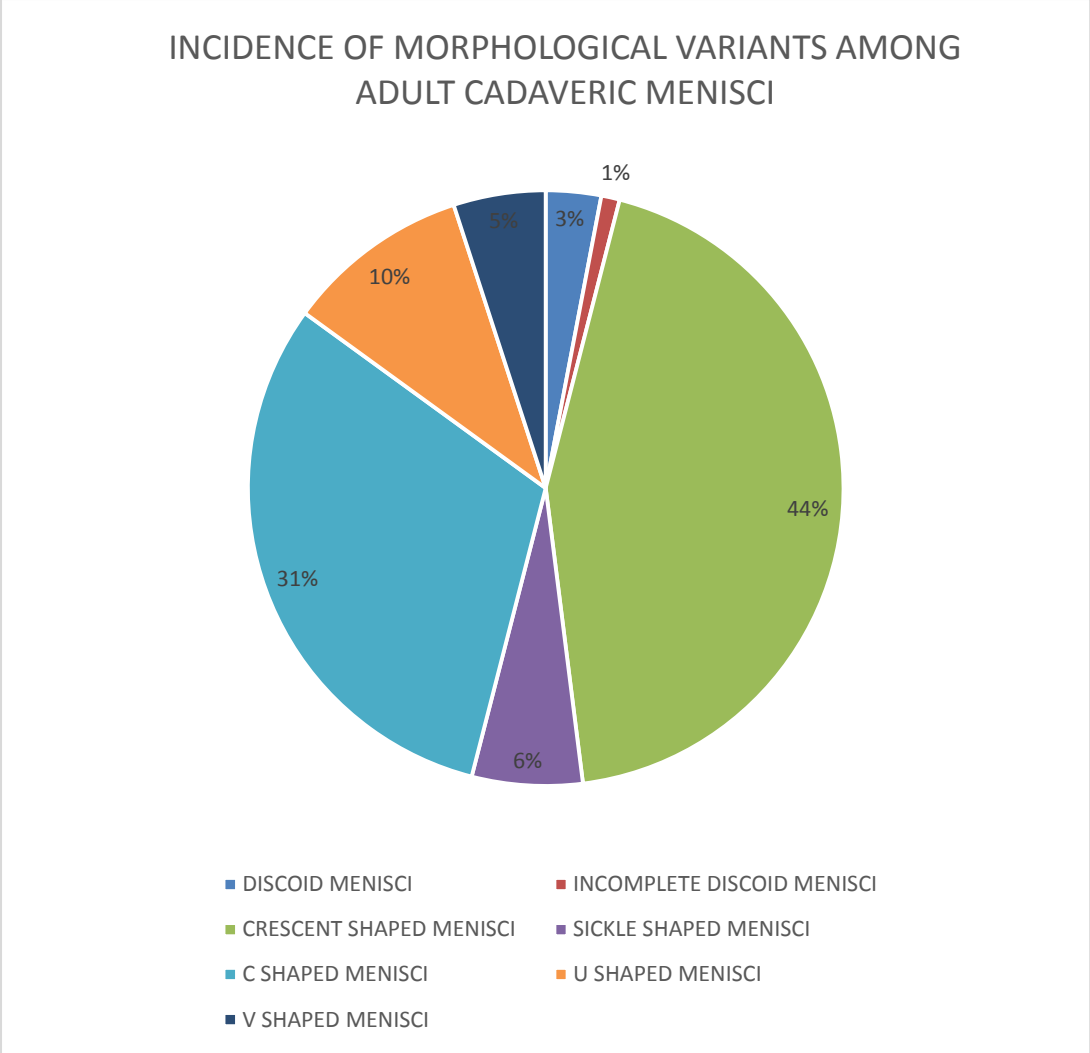

Chart 3: Incidence of morphological variants among the adult cadaveric knee menisci

MORPHOLOGY OF CADAVERIC FOETAL MENISCI:

The incidence of following morphological variants among 100 cadaveric foetal menisci were recorded in a data sheet and analysed.

a) Complete Discoid

b) Incomplete Discoid

c) Ring shaped menisci

d) C shape

e) V Shape

f) Crescent shape

g) Sickle shape

h) U shape

MORPHOLOGY OF LATERAL FOETAL CADAVERIC MENISCI :

MORPHOLOGICAL VARIANTS	N	NUMBERS
C SHAPED	100	66
INCOMPLETE DISCOID SHAPED	100	3
RING SHAPED	100	1
CRESCENT SHAPED	100	26
U SHAPED	100	4

Table 6: *Number of morphological variants among foetal cadaveric lateral menisci*

MORPHOLOGICAL VARIANTS	INCIDENCE
C SHAPED	66%
INCOMPLETE DISCOID SHAPED	3%
RING SHAPED	1%
CRESCENT SHAPED	26%
U SHAPED	4%

Table 7: Incidence of morphological variants among foetal cadaveric lateral menisci

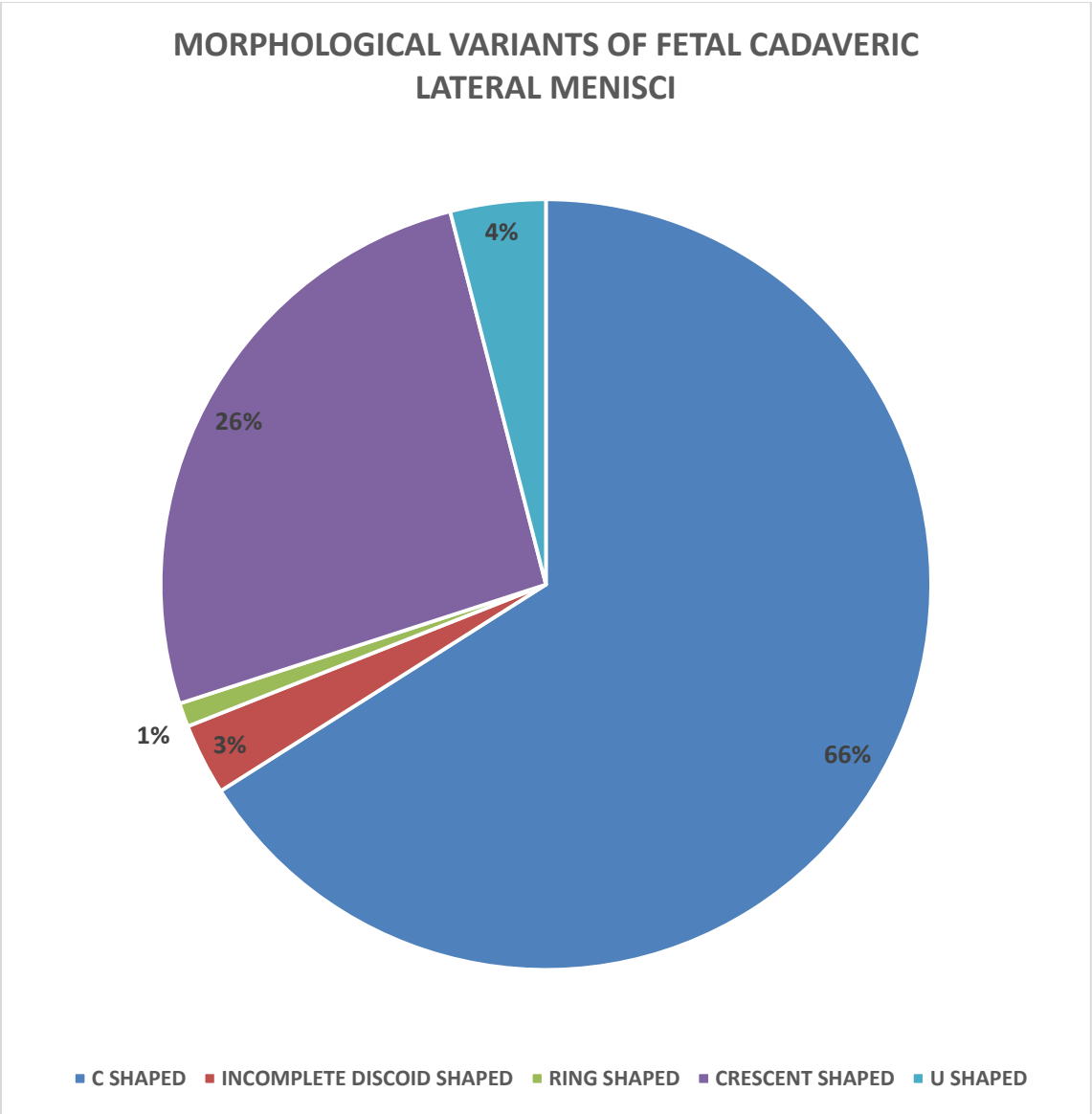

Chart 4 : Incidence of morphological variants among foetal cadaveric lateral menisci

Amongst 100 foetal cadaveric lateral menisci specimen,following morphological variants were found, 66 C Shaped menisci followed by 26 Crescent shaped menisci ,4 U shaped menisci,3 incomplete discoid shaped menisci and 1 ring shaped menisci**(Table 6)**.

They were subjected to data analysis using SPSS Software and the incidence of C shaped menisci,crescent shaped menisci,U shaped menisci,Incomplete discoid shaped menisci and **ring shaped menisci** were found to be 66%,26%,4%,3% and **1%** respectively(**Table 7)**.

Among these the incidence of C shaped menisci 66% was found to be the highest and ring shaped menisci which is referred to be the extremely rarest variant of menisci with incidence of 1% to be the lowest**(Chart 4)**.

MORPHOLOGY OF FOETAL CADAVERIC MEDIAL MENISCI :

MORPHOLOGICAL VARIANTS	N	NUMBERS
CRESCENT SHAPED	100	52
SICKLE SHAPED	100	2
C SHAPED	100	14
V SHAPED	100	28
U SHAPED	100	4

Table 8: Number of morphological variants among foetal cadaveric medial menisci

MORPHOLOGICAL VARIANTS	INCIDENCE
CRESCENT SHAPED	52%
SICKLE SHAPED	2%
C SHAPED	14%
V SHAPED	28%
U SHAPED	4%

Table 9: Incidence of Morphological variants among foetal cadaveric medial menisci

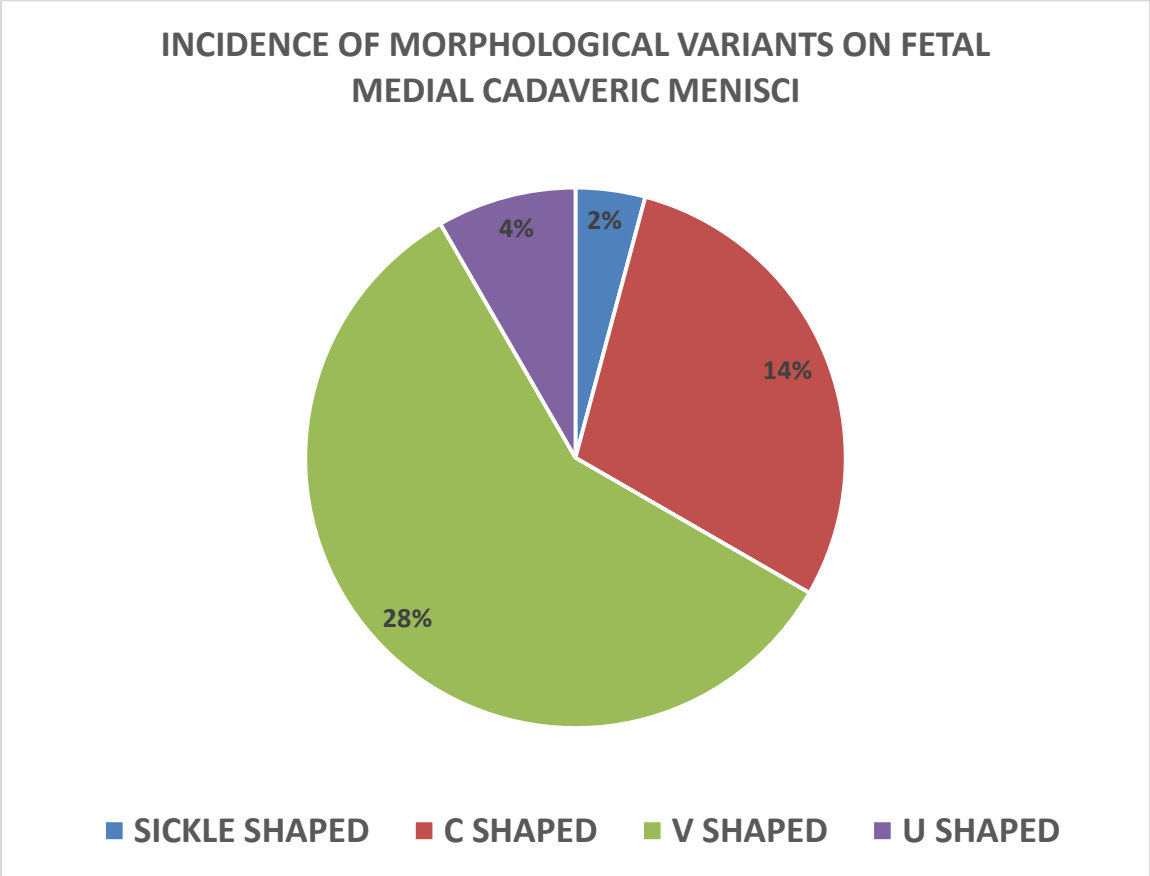

Chart 5 : Incidence Of Morphological Variants Among Foetal cadaveric Medial Menisci

The Discoid menisci was found to be absent in the medial foetal menisci and other morphological variants were found to be 52 Crescentic Shaped menisci,14 C shaped menisci,2 Sickle shaped menisci, 4 U shaped menisci and 28 V shaped medial menisci**(Table 8)**.

They were subjected to data analysis using SPSS Software and the incidence of Crescent shaped menisci,V shaped menisci,C shaped menisci,U shaped and Sickle shaped menisci were found to be 52%,28%,14%,4% and 2% respectively(**Table 9)**.

In the incidence of morphological variants among foetal cadaveric medial menisci, crescent shaped (52%) was found to be the highest and the Sickle shaped (2%) to be the lowest**(Chart 5)**.

On comparing the medial and the lateral foetal cadaveric menisci,the discoid menisci was more common among the lateral menisci than the medial menisci and the most common variant among both groups being the C shaped and Crescent shaped menisci.

MORPHOMETRICS OF ADULT CADAVERIC MENISCI :

The following parameters were considered for the morphometrics of menisci:

TACL 1 – Thickness of anterior one third of adult cadaveric lateral menisci.

TACL 2 – Thickness of middle one third of adult cadaveric lateral menisci

TACL 3 – Thickness of posterior one third of adult cadaveric lateral menisci

TACM 1 –Thickness of anterior one third of adult cadaveric medial menisci

TACM 2 -- Thickness of middle one third of adult cadaveric medial menisci

TACM 3 -- Thickness of posterior one third of adult cadaveric medial menisci

TFCL 1 -Thickness of anterior one third of foetal cadaveric lateral menisci.

TFCL 2 – Thickness of middle one thirds of foetal cadaveric lateral menisci

TFCL 3 – Thickness of posterior one third of foetal cadaveric lateral menisci

TFCM 1 –Thickness of anterior one third of foetal cadaveric medial menisci

TFCM 2 -- Thickness of middle one third of foetal cadaveric medial menisci

TFCM 3 -- Thickness of posterior one third of foetal cadaveric medial menisci

WACL 1 –Width of anterior one third of adult cadaveric lateral menisci.

WACL 2 – Width of middle one third of adult cadaveric lateral menisci

WACL 3 – Width of posterior one third of adult cadaveric lateral menisci

WACM 1 –Width of anterior one third of adult cadaveric medial menisci

WACM 2 – Width of middle one third of adult cadaveric medial menisci

WACM 3 – Width of posterior one third of adult cadaveric medial menisci

WFCL 1 –Width of anterior one third of foetal cadaveric lateral menisci.

WFCL 2 – Width of middle one thirds of foetal cadaveric lateral menisci

WFCL 3 – Width of posterior one third of foetal cadaveric lateral menisci

WFCM 1 –Width of anterior one third of foetal cadaveric medial menisci

WFCM 2 – Width of middle one third of foetal cadaveric medial menisci

WFCM 3 – Width of posterior one third of foetal cadaveric medial menisci

TAML 1 – Thickness of anterior one third of adult MRI lateral menisci.

TAML 2 – Thickness of middle one third of adult MRI lateral menisci

TAML 3 – Thickness of posterior one third of adult MRI lateral menisci

TAMM 1 –Thickness of anterior one third of adult MRI medial menisci

TAMM 2 -- Thickness of middle one third of adult MRI medial menisci

TAMM 3 -- Thickness of posterior one third of adult MRI medial menisci

WAML 1 –Width of anterior one third of MRI cadaveric lateral menisci.

WAML 2 – Width of middle one third of MRI cadaveric lateral menisci

WAML 3 – Width of posterior one third of MRI cadaveric lateral menisci

WAMM 1 –Width of anterior one third of adult cadaveric medial menisci

WAMM 2 – Width of middle one third of adult cadaveric medial menisci

WAMM 3 – Width of posterior one third of adult cadaveric medial menisci

S.No	Parameters	Mean mm	Standard Diviation
1	THICKNESS OF ANTERIOR ONE THIRD	1.09	0.53
2	THICKNESS OF MIDDLE ONE THIRD	1.37	0.40
3	THICKNESS OF POSTERIOR ONE THIRD	1.17	0.55
4	WIDTH OF ANTERIOR ONE THIRD	8.59	2.76
5	WIDTH OF MIDDLE ONE THIRD	9.29	2.38
6	WIDTH OF POSTERIOR ONE THIRD	8.73	2.66

Table 10 : Morphometrics of adult cadaveric lateral menisci:

S.No	Parameters	Mean mm	Standard Diviation
1	THICKNESS OF ANTERIOR ONE THIRD	1.34	0.51
2	THICKNESS OF MIDDLE ONE THIRD	1.02	0.61
3	THICKNESS OF POSTER ONE THIRD	1.091	0.71
4	WIDTH OF ANTERIOR ONE THIRD	6.46	0.66
5	WIDTH OF MIDDLE ONE THIRD	7.23	1.40
6	WIDTH OF POSTERIOR ONE THIRD	**10.84**	**0.73**

Table 11 : Morphometrics of adult cadaveric medial menisci

S.No	Parameters	Mean mm	Standard Diviation
1	THICKNESS OF ANTERIOR ONE THIRD	0.91	0.38
2	THICKNESS OF MIDDLE ONE THIRD	0.23	0.33
3	THICKNESS OF POSTER ONE THIRD	0.44	0.34
4	WIDTH OF ANTERIOR ONE THIRD	1.06	0.71
5	WIDTH OF MIDDLE ONE THIRD	1.54	0.69
6	WIDTH OF POSTERIOR ONE THIRD	1.65	0.74

Table 12: Morphometrics of cadaveric foetal lateral menisci

S.No	Parameters	Mean mm	Standard Diviation
1	THICKNESS OF ANTERIOR ONE THIRD	**0.71**	**0.34**
2	THICKNESS OF MIDDLE ONE THIRD	**0.77**	**0.58**
3	THICKNESS OF POSTER ONE THIRD	**0.58**	**0.66**
4	WIDTH OF ANTERIOR ONE THIRD	**1.72**	**0.79**
5	WIDTH OF MIDDLE ONE THIRD	**1.59**	**1.28**
6	WIDTH OF POSTERIOR ONE THIRD	**1.48**	**0.79**

Table 13: Morphometrics of cadaveric foetal medial menisci

S.No	Parameters	Mean mm	Standard Diviation
1	THICKNESS OF ANTERIOR ONE THIRD	4.8	0.7
2	THICKNESS OF MIDDLE ONE THIRD	5.9	1.2
3	THICKNESS OF POSTERIOR ONE THIRD	6.8	1.0
4	WIDTH OF ANTERIOR ONE THIRD	11.25	0.95
5	WIDTH OF MIDDLE ONE THIRD	7.95	1.1
6	WIDTH OF POSTERIOR ONE THIRD	11.8	0.8

Table 14: Morphometrics of adult lateral menisci in MRI

S.No	Parameters	Mean mm	Standard Diviation
1	THICKNESS OF ANTERIOR ONE THIRD	5.95	1.1
2	THICKNESS OF MIDDLE ONE THIRD	5.35	1.3
3	THICKNESS OF POSTER ONE THIRD	6.5	1.1
4	WIDTH OF ANTERIOR ONE THIRD	10.3	1.5
5	WIDTH OF MIDDLE ONE THIRD	7.75	0.9

Table 15 : Morphometrics of adult medial menisci in MRI

Comparison of morphometrics of cadaveric menisci and MRI is essential to find if there is any statistically significant difference in the measurements. The cadaveric morphometry has been regarded as the baseline measure of menisci in treating meniscal injuries and also has been employed in designing meniscal scaffolds and pre operative graft sizing. The comparison of the means were done using independent t test by SPSS Software and the results were documented .

TABLE 16 : COMPARISON OF THICKNESS OF ANTERIOR ONE THIRD OF ADULT LATERAL MENISCI :

Group Statistics					
	VAR00002	N	Mean	Std. Deviation	Std. Error Mean
VAR00001	ADULT CADAVERIC LATERAL MENISCI	50	1.03	.504	.071
	ADULT MRI LATERAL MENISCI	100	4.79	.372	.037

Independent Samples Test										
		Levene's Test for Equality of Variances		t-test for Equality of Means						
		F	Sig.	t	df	Sig. (2-tailed)	Mean Difference	Std. Error Difference	95% Confidence Interval of the Difference	
									Lower	Upper
VAR00001	Equal variances assumed	10.720	.001	-51.492	147	.000	-3.758	.073	-3.902	-3.614
	Equal variances not assumed			-46.713	76.864	.000	-3.758	.080	-3.918	-3.598

On comparing the mean thickness of anterior one third of lateral menisci measured using adult cadaveric menisci samples (1.03±0.50mm) and MRI Images (4.79±0.37mm),thep value was found to be p=o.ooo.

TABLE 17 :COMPARISON OF THICKNESS OF MIDDLE ONE THIRD OF ADULT LATERAL MENISCI

Group Statistics					
	VAR00002	N	Mean	Std. Deviation	Std. Error Mean
VAR00004	ADULT CADAVERIC LATERAL MENISCI	50	1.37	.379	.054
	MRI OF LATERAL MENISCI	100	6.13	.596	.060

Independent Samples Test										
		Levene's Test for Equality of Variances		t-test for Equality of Means						
		F	Sig.	t	df	Sig. (2-tailed)	Mean Difference	Std. Error Difference	95% Confidence Interval of the Difference	
									Lower	Upper
VAR00004	Equal variances assumed	8.214	.005	-51.416	148	.000	-4.758	.093	-4.941	-4.575
	Equal variances not assumed			-59.318	139.467	.000	-4.758	.080	-4.917	-4.599

On comparing the mean thickness of middle third of lateral menisci measured using adult cadaveric menisci samples (1.37±0.379mm)and MRI Images(6.13 ±0.59 mm),the p value was found to be p=o.ooo.

TABLE 18 : COMPARISON OF THICKNESS OF POSTERIOR ONE THIRD OF ADULT LATERAL MENISCI

Group Statistics					
	VAR00002	N	Mean	Std. Deviation	Std. Error Mean
VAR00006	ADULT CADAVERIC LATERAL MENISCI	50	1.18	.526	.074
	MRI OF LATERAL MENISCI	100	6.89	.328	.033

Independent Samples Test										
		Levene's Test for Equality of Variances		t-test for Equality of Means						
		F	Sig.	t	df	Sig. (2-tailed)	Mean Difference	Std. Error Difference	95% Confidence Interval of the Difference	
									Lower	Upper
VAR00006	Equal variances assumed	11.789	.001	-81.658	148	.000	-5.715	.070	-5.853	-5.576
	Equal variances not assumed			-70.359	68.618	.000	-5.715	.081	-5.877	-5.552

On comparing the mean thickness of posterior third of lateral menisci measured using adult cadaveric menisci samples(1.18mm±0.52) and MRI Images (6.89mm ±0.328),the p value was found to be p=o.ooo.

TABLE 19 : COMPARISON OF WIDTH OF ANTERIOR THIRD OF LATERAL MENISCI

Group Statistics					
	VAR00002	N	Mean	Std. Deviation	Std. Error Mean
VAR00007	ADULT CADAVERIC LATERAL MENISCI	50	8.5964	2.61972	.37048
	MRI OF LATERAL MENISCI	100	11.2502	.64565	.06456

Independent Samples Test										
		Levene's Test for Equality of Variances		t-test for Equality of Means						
		F	Sig.	t	df	Sig. (2-tailed)	Mean Difference	Std. Error Difference	95% Confidence Interval of the Difference	
									Lower	Upper
VAR00007	Equal variances assumed	70.551	.000	-9.593	148	.000	-2.65380	.27664	-3.20048	-2.10712
	Equal variances not assumed			-7.057	51.998	.000	-2.65380	.37607	-3.40844	-1.89916

On comparing the mean width of anterior third of lateral menisci measured using adult cadaveric menisci samples (8.49mm± 2.619) and MRI Images(11.25mm ±0.645), the p value was found to be p=o.ooo.

TABLE 20 : COMPARISON OF WIDTH OF MIDDLE THIRD OF LATERAL MENISCI

Group Statistics					
	VAR00002	N	Mean	Std. Deviation	Std. Error Mean
VAR00009	ADULT CADAVERIC LATERAL MENISCI	50	7.3524	1.19765	.16937
	MRI OF LATERAL MENISCI	100	7.7376	.24559	.02456

Independent Samples Test										
		Levene's Test for Equality of Variances		t-test for Equality of Means						
		F	Sig.	t	df	Sig. (2-tailed)	Mean Difference	Std. Error Difference	95% Confidence Interval of the Difference	
									Lower	Upper
VAR00009	Equal variances assumed	100.345	.000	-3.098	148	.002	-.38520	.12433	-.63089	-.13951
	Equal variances not assumed			-2.251	51.071	.029	-.38520	.17114	-.72878	-.04162

On comparing the mean width of middle third of lateral menisci measured using adult cadaveric menisci samples (7.35mm± 1.19) and MRI Images(7.73mm±0.24),the p value was found to be p=o.oo2

TABLE 21 : COMPARISON OF WIDTH OF POSTERIOR THIRD OF LATERAL MENISCI

Group Statistics					
	VAR00002	N	Mean	Std. Deviation	Std. Error Mean
VAR00010	ADULT CADAVERIC LATERAL MENSICI	50	9.6932	3.84402	.54363
	MRI OF LATERAL MENISCI	100	11.5929	.30915	.03091

Independent Samples Test										
		Levene's Test for Equality of Variances		t-test for Equality of Means						
		F	Sig.	t	df	Sig. (2-tailed)	Mean Difference	Std. Error Difference	95% Confidence Interval of the Difference	
									Lower	Upper
VAR00010	Equal variances assumed	101.398	.000	-4.927	148	.000	-1.89970	.38560	-2.66169	-1.13771
	Equal variances not assumed			-3.489	49.317	.001	-1.89970	.54451	-2.99375	-.80565

On comparing the mean width of posterior third of lateral menisci measured using adult cadaveric menisci samples (9.69mm ±3.84) and MRI Images(11.59mm± 0.309) the p value was found to be p=o.oo0

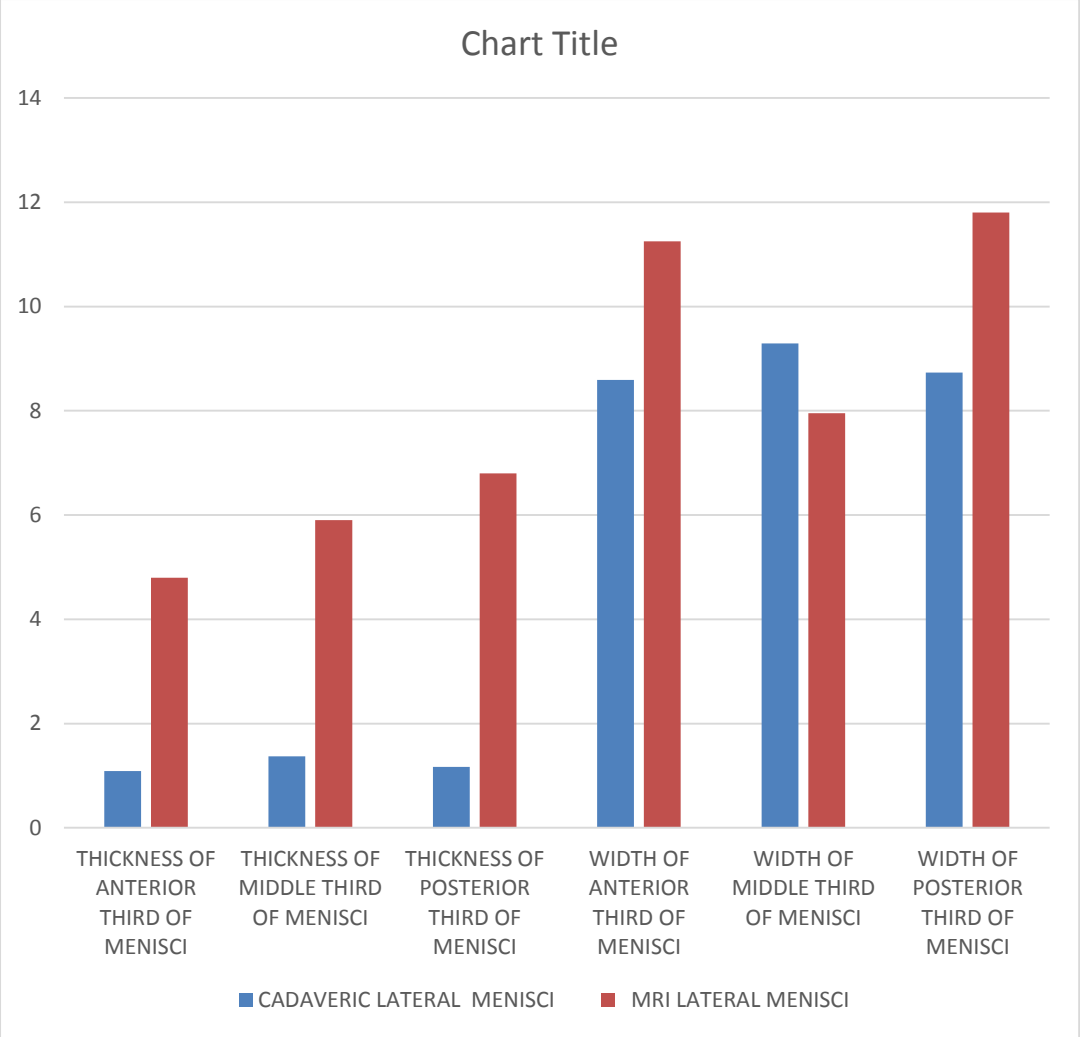

Chart 6 : ***Comparison of data between adult cadaveric lateral menisci and MRI lateral menisci***

TABLE 22 : COMPARISON OF THICKNESS OF ANTERIOR THIRD OF MEDIAL MENISCI

Group Statistics					
	VAR00002	N	Mean	Std. Deviation	Std. Error Mean
VAR00011	ADULT CADAVERIC MEDIAL MENISCI	50	1.3468	.48485	.06857
	MRI MEDIAL MENISCI	100	5.2672	.82331	.08233

Independent Samples Test										
		Levene's Test for Equality of Variances		t-test for Equality of Means						
		F	Sig.	t	df	Sig. (2-tailed)	Mean Difference	Std. Error Difference	95% Confidence Interval of the Difference	
									Lower	Upper
VAR00011	Equal variances assumed	14.423	.000	-31.054	148	.000	-3.92040	.12624	-4.16987	-3.67093
	Equal variances not assumed			-36.590	143.996	.000	-3.92040	.10714	-4.13218	-3.70862

On comparing the mean thickness of anterior one third of medial menisci measured using adult cadaveric menisci samples(1.34mm ±0.48) and MRI Images (5.26mm± 0.82) thep value was found to be p=0.000

TABLE 23 : COMPARISON OF THICKNESS OF MIDDLE THIRD OF MEDIAL MENISICI

Group Statistics					
	VAR00002	N	Mean	Std. Deviation	Std. Error Mean
VAR00012	ADULT CADAVERIC MEDIAL MENISCI	50	1.0388	.59388	.08399
	MRI MEDIAL MENISCI	100	5.3737	.38612	.03861

Independent Samples Test										
		Levene's Test for Equality of Variances		t-test for Equality of Means						
		F	Sig.	t	df	Sig. (2-tailed)	Mean Difference	Std. Error Difference	95% Confidence Interval of the Difference	
									Lower	Upper
VAR00012	Equal variances assumed	13.111	.000	-53.788	148	.000	-4.33490	.08059	-4.49416	-4.17564
	Equal variances not assumed			-46.895	70.347	.000	-4.33490	.09244	-4.51925	-4.15055

On comparing the mean thickness of middle one third of medial menisci measured using adult cadaveric menisci samples (1.03mm ±0.59) and MRI Images(5.37mm± 0.38) the p value was found to be p=o.ooo.

TABLE 24 : COMPARISON OF THICKNESS OF POSTERIOR THIRD OF MEDIAL MENISCI

Group Statistics					
	VAR00002	N	Mean	Std. Deviation	Std. Error Mean
VAR00013	ADULT CADAVERIC MEDIAL MENISCI	50	1.1080	.68957	.09752
	MRI MEDIAL MENISCI	100	6.6035	.52393	.05239

Independent Samples Test										
		Levene's Test for Equality of Variances		t-test for Equality of Means						
		F	Sig.	t	df	Sig. (2-tailed)	Mean Difference	Std. Error Difference	95% Confidence Interval of the Difference	
									Lower	Upper
VAR00013	Equal variances assumed	4.046	.046	-54.330	148	.000	-5.49550	.10115	-5.69539	-5.29561
	Equal variances not assumed			-49.642	78.146	.000	-5.49550	.11070	-5.71589	-5.27511

On comparing the mean thickness of posterior one third of medial menisci measured using adult cadaveric menisci samples(1.10mm ±0.68) and MRI Images (6.60mm± 0.52) the p value was found to be p=o.ooo.

TABLE 25 : COMPA2RISON OF WIDTH OF ANTERIOR THIRD OF MEDIAL MENISCI

Group Statistics					
	VAR00002	N	Mean	Std. Deviation	Std. Error Mean
VAR00014	ADULT CADAVERIC MEDIAL MENSIC	50	6.3910	2.53782	.35890
	MRI MEDIAL MENISCI	100	10.5641	.92908	.09291

Independent Samples Test										
		Levene's Test for Equality of Variances		t-test for Equality of Means						
		F	Sig.	t	df	Sig. (2-tailed)	Mean Difference	Std. Error Difference	95% Confidence Interval of the Difference	
									Lower	Upper
VAR00014	Equal variances assumed	18.890	.000	-14.636	148	.000	-4.17310	.28512	-4.73653	-3.60967
	Equal variances not assumed			-11.256	55.664	.000	-4.17310	.37073	-4.91587	-3.43033

On comparing the mean width of anterior one third of medial menisci measured using adult cadaveric menisci samples (6.39mm ±2.53) and MRI Images (10.56mm± 0.92) the p value was found to be p=o.ooo.

TABLE 26 : COMPARISON OF WIDTH OF MIDDLE THIRD OF MEDIAL MENISCI

Group Statistics					
	VAR00002	N	Mean	Std. Deviation	Std. Error Mean
VAR00015	ADULT CADAVERIC MEDIAL MENISCI	50	7.0506	2.04710	.28950
	MRI MEDIAL MENISCI	100	7.7376	.24559	.02456

Independent Samples Test										
		Levene's Test for Equality of Variances		t-test for Equality of Means						
		F	Sig.	t	df	Sig. (2-tailed)	Mean Difference	Std. Error Difference	95% Confidence Interval of the Difference	
									Lower	Upper
VAR00015	Equal variances assumed	64.936	.000	-3.319	148	.001	-.68700	.20696	-1.09598	-.27802
	Equal variances not assumed			-2.365	49.707	.022	-.68700	.29054	-1.27066	-.10334

On comparing the mean width of middle one third of medial menisci measured using adult cadaveric menisci samples (7.05mm ±2.04) and MRI Images (7.73mm± 0.24) the p value was found to be p=o.oo1.

TABLE 27 : COMPARISON OF WIDTH OF POSTERIOR THIRD OF MEDIAL MENISCI

Group Statistics					
	VAR00002	N	Mean	Std. Deviation	Std. Error Mean
VAR00016	ADULT CADAVERIC MEDIAL MENISCI	50	11.0570	3.67428	.51962
	MRI MEDIAL MENISCI	100	12.1380	.81941	.08194

Independent Samples Test										
		Levene's Test for Equality of Variances		t-test for Equality of Means						
		F	Sig.	t	df	Sig. (2-tailed)	Mean Difference	Std. Error Difference	95% Confidence Interval of the Difference	
									Lower	Upper
VAR00016	Equal variances assumed	101.505	.000	-2.814	148	.006	-1.08100	.38414	-1.84011	-.32189
	Equal variances not assumed			-2.055	51.452	.045	-1.08100	.52604	-2.13685	-.02515

On comparing the mean width of posterior one third of medial menisci measured using adult cadaveric menisci samples (11.05mm ±3.67) and MRI Images (12.13mm± 0.81) the p value was found to be p=o.ooo.

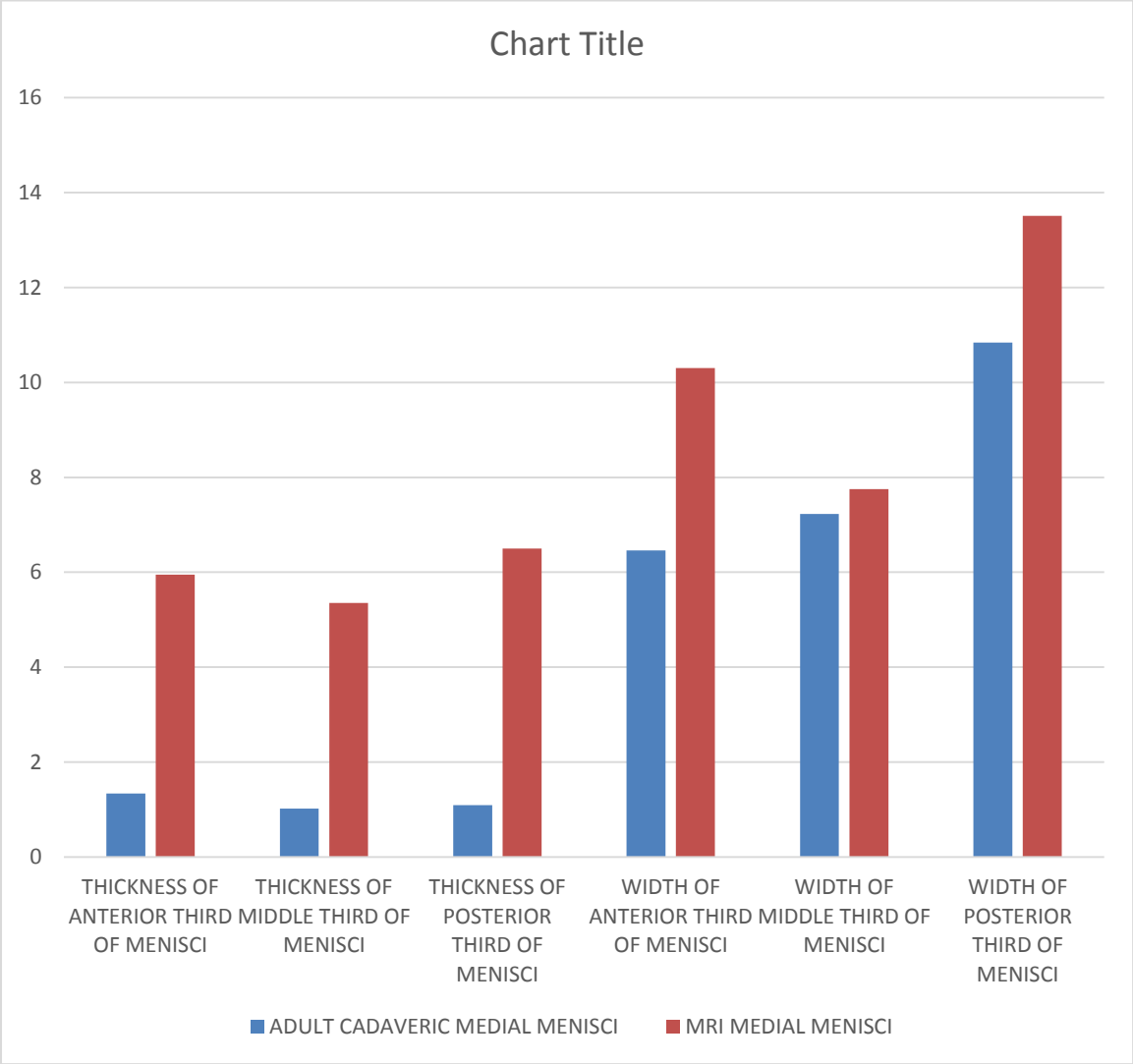

Table 28: Comparison of data between adult cadaveric medial menisci and MRI medial menisci

DISCUSSION

Menisci morphology and morphometrics is gaining its importance as ever, not only in the field of orthopaedics but also in the commercial platform as designing meniscal scaffolds. Keeping these in focus, in our study the mean values and standard deviation of morphometric parameters were correlated.The results obtained were compared with the data obtained from the other studies on morphology and morphometry of menisci and the discussion is documented as follows.

MORPHOLOGY OF CADAVERIC ADULT MENISCI:

Menisci are most often referred as crescent shaped structures until the discovery of morphological variants of menisci by Watanabe et al (1979) such as discoid, incomplete discoid and Wrisberg variants. Following that Monllau et al (1998) proposed in his study the idea of adding yet another morphological variants which is the ring shaped menisci and it is contemplated to be the rarest variant of all. Later Kale et al (2006) grouped the non discoid menisci variants into sickle shaped , sided U shaped ,sided V shaped , crescentic (semi lunar) shaped and C shaped.

Discoid menisci has an incidence of 5% of the population, the incidence is higher 13% among Asian population.

MORPHOLOGY OF ADULT CADAVERIC LATERAL MENISCI:

In our study, the variant with highest incidence among 50 adult cadaveric menisci was C shaped (58%). The second common type was U shaped meniscus which accounted for 20% and it was followed by crescent shaped (14%), discoid shaped (6%), incomplete discoid menisci (2%).

According to the study conducted by Muralimanju et al among 108 adult knee lateral menisci belonging to south Indian population, the most common meniscus was C shaped (61.1%), which correlates with our present study. The second common type was Crescent shaped menisci with a incidence of 38.9% .The incidence of discoid menisci was 0% among their study population which on the contrary is present in our study with the incidence of 8%.

When considering the study by Itagi et al amongst 120 adult cadaveric lateral menisci belonging to North Karnataka population, the C shaped menisci was found to be more common 88.3% which again correlates with our study. It was followed by U shaped menisci 6.66% which is found to be less than our study. They had reported the frequency of incomplete discoid menisci as 5% which is comparatively higher than the incidence of incomplete discoid menisci (2%) among our study population. There was no discoid meniscus reported.

According to the study conducted by Chakravarthy et al among 58 adult cadaveric lateral knee menisci belonging to South Indian population, 56.4% were C shaped being the highest frequency similar to our present study followed by 41.6% being crescent shaped which is quite similar with the study by Muralimanju et al and is higher when compared with our present study where it is only 14%.The incidence of discoid menisci was found to be 2% and there was no incidence of incomplete discoid meniscus.

According to recent study by Shashidar et al conducted among 50 adult lateral knee menisci belonging to Karnataka population the C shaped menisci had a higher frequency rate of 35% - 70% which is in accordance with the above mentioned studies it was followed by crescent shaped menisci 14-28% which coincides with the present study and the Discoid menisci was found to be 1-2%.

STUDY	INCIDENCE OF VARIOUS MORPHOLOGICALVARIANTS							
	complete discoid	incomplete discoid	crescent	sickle	C shape	V shape	U shape	ring shaped
Murlimanju et al(2010)	-	2%	26%	-	72%	-	-	-
Chakravarthy et al (2018)	2%	-	41.6%	-	56.4%	-	-	-
Shashidar et al(2019)	1-2%	-	14-28%		35 - 70%	-	-	-
Present Study	6%	2%	14%	-	58%	-	20%	-

Table 29 : Comparison of the results of lateral adult morphological variants of our study with the other authors

Cadaveric adult medial menisci:

In our present study, Crescent shaped menisci (74%) had the highest incidence among 50 cadaveric adult medial menisci. The second most commonly occurring variant was found to be sickle shaped menisci (12%) and it was followed by V shaped 10% and C shaped 4%.There was no incidence of discoid variants.

Incidence of medial discoid menisci is extremely rare (Grey's Anatomy,40th edition).

According to Muralimanju et al among 108 adult medial menisci belonging to south Indian population, the frequency of crescent shaped menisci (50%) was highest which correlates with our study,followed by V shaped menisci (38.9%) which is higher than the frequency of V shaped menisci (10%) in our study and U shaped menisci (11.1 %) which is absent in our study.

Among 120 medial menisci of Karnataka population , Itagi et al reported the incidence of crescent shaped menisci(96.66%) to be the highest which is similar to our study, followed by V shaped menisci 1.66% and sickle shaped menisci 1.66% which is less when compared with our study.

According to Sashidhar et al among 50 adult lateral knee menisci belonging to Karnataka population, the frequency of crescent shaped 24-48% was highest which is similar to our study followed by U shaped 7-14%,sided V shape 19-38% and C shape 7%, whereas in our study there is no incidence of U shaped menisci.

STUDY	INCIDENCE OF VARIOUS MORPHOLOGICAL VARIANTS							
	complete discoid	incomplete discoid	crescent	sickle	C shape	V shape	U shape	ring shaped
Murlimanju et al(2010)	-	-	50%	-	-	37%	13%	-
Chakravarthy et al(2018)	2%	-	41.6%	-	56.4%	-	-	-
Shashidar et al (2019)	2%	-	28%	-	70%	-	-	-
Present Study	-	-	74%	12%	4%	10%	-	-

Table 30 : Comparison of the results of medial adult morphological variants of our study with the other authors

Cadaveric adult menisci:

On compiling the data on morphological variant of adult cadaveric medial and lateral menisci, the frequency of morphological variants were found to be Incomplete discoid menisci 1%,Complete discoid menisci 3%,V shaped menisci 5%,Sickle shaped menisci 6%,U shaped menisci 10%,C shaped menisci 31% and Crescent shaped 44%.

The morphological variant with highest frequency among adult cadaveric menisci was crescent shape 44% and the variant with minimum frequency was found to be incomplete discoid menisci.

MORPHOLOGY OF FETAL CADAVERIC MENISCI :

The knowledge on morphological variants among foetus is essential to know about the origin of congenitaly occurring morphological variants.

The morphological variants among foetal population can be classified as

- Discoid menisci
- Incomplete discoid menisci
- Ring shaped menisci
- V shaped menisci
- C shaped menisci
- U shaped menisci
- Sickle shaped menisci

Ring shaped menisci is considered as the extremely rare morphological variant of menisci. Noble et al (1975) were first to report a case of ring shaped menisci during an autopsy procedure. It was found to occupy the medial compartment of the lateral tibial plateau. Thus ring shaped menisci can be mistaken for displaced meniscal fragement (Esteves et al 2015).It has an incidence of 0.9-2.4% among Asian population. Few cases of symptomatic

ring shaped menisci has been reported which was mistaken for bucket handle tear**(Arnold et al 2000,Atay et al 2002,Pandey et al 2009)**and in a study a 16 yr old girl was diagnosed with ring shaped menisci using arthroscopy (**koukoulias et al 2011**).

MORPHOLOGY OF FOETAL CADAVERIC LATERAL MENISCI:

In our present study**,** the morphological variant with highest incidence among 100 lateral fetal cadaveric menisci was found to be of C shaped meniscus (66%) it was followed by crescent shaped menisci 26%,U shaped menisci 4%,Incomplete discoid shaped menisci 3% and **ring shaped menisci 1%.**

Reports of ring shaped lateral menisci among fetal population has not yet been reported in the literature.Our study reports 1% incidence of ring shaped menisci among fetal cadaveric samples.

According to Kale et al among 22 fetal knee joints belonging to turkish population, the incidence of Incomplete discoid menisci (54.54%) was found to be the highest.The second commonly occuring morphological variant was found to be discoid menisci (22.72%) . 13.63% of lateral fetal menisci were found to be crescentic and 9.09% was C shaped. The results of this study highly deviates from our study as the least occuring C shaped menisci was the variant with highest incidence in our studies and the variant with the lowest

incidence in our study was found to be higest among the study population of Kale et al.

Murlimanju et al reported that 62.3% of lateral menisci among the 212 fetal menisci belonging to south indian population were found to be C shaped which is similar to our study and the variant with least frequency was complete discoid menisci 3.8% on the contrary no discoid menisci was observed in our study .

STUDY	INCIDENCE OF VARIOUS MORPHOLOGICAL VARIANTS							
	complete discoid	**incomplete discoid**	**crescent**	**sickle**	**C shape**	**V shape**	**U shape**	**ring shaped**
Kale et al(2006)	22.72%	54.54%	13.63%	-	9.02%	-	-	-
Murlimanju et al(2010)	3.8%	14.1%	19.8%	-	62.3%	-	-	-
Koyuncu et al(2017)	1.4%	18.6%	19%	-	61%	-	-	-
Present Study	-	3%	26%	-	66%	-	4%	1%

Table 31 : Comparison of the results of fetal lateral menisci morphological variants of our study with the other authors

According to Koyuncu et al among 210 lateral knee menisci belonging to turkish population,the C shaped menisi accounted for 61% , crescent shaped

19% similar to our study.Followed by incomplete discoid 18.6% and discoid menisci 1.4% which is quite contrary to the study by Kale et al on same study population .

MORPHOLOGY OF CADAVERIC FETAL MEDIAL MENISCI:

In our present study the morphological variant with highest incidence among fetal cadaveric medial menisci was found to be crescent shaped menisci (52%).The second commonly occuring variant was found to be V shaped (28%) followed by C shaped menisci (14%) ,U shaped menisci (4%) and Sickle Shaped menisci (2%) was found to be the least.

Kale et al among 22 fetal medial menisci belonging to tukish popuation reported that the incidence of sickle shaped menisci (36.36%)to be highest which in our study is the least of all variants and the least being U shaped menisci (9.09%).This differences in the incidence of morphological variants could be owed to the diffrences in the geographic locale.

According to Muralimanju et al among 212 fetal menisci 46.2% of the medial menisci were crescent shaped and thus being the highest ,similar to our study and C shaped menisci 7.5% was found to be the variant with lowest incidence which on the contrary it is of 14% in our study.

Koyuncu et al reports coincides with the results of our study where the incidence of crescent shaped (50%)was found being the highest among 210

medial fetal menisci and the lowest being C shaped (6.7%),on the contrary the variant with lowest incidence was sickle shaped (2%).

STUDY	INCIDENCE OF VARIOUS MORPHOLOGICALVARIANTS							
	complete discoid	incomplete discoid	crescent	sickle	C shape	V shape	U shape	ring shaped
Kale et al(2006)	-	-	18.18%	36.36%	13.63%	22.72%	9.09%	-
Murlimanju et al(2010)	-	-	46.2%	9.4%	7.5%	23.6%	13.2%	-
Koyuncu et al (2017)	-	-	50%	22.9%	6.7%	10.9%	9.5%	-

Table 32 : Comparison of the results of medial fetal morphological variants of our study with the other authors

MORPHOMETRICS OF FETAL CADAVERIC MENISCI :

Thickness of fetal cadaveric menisci :

Studies on morphometry of fetal cadaveric menisci are very much limited. Muralimanju et al concluded after studying 106 south Indian fetal menisci that the thickness of anterior third of lateral menisci 1.57 ± 0.41mm,thickness of middle third of lateral menisci 1.52 ± 0.39,thickness of posterior third of lateral menisci 1.49 ± 0.34 and the thickness of anterior third of medial menisci 1.61 ± 0.39mm,middle third of medial menisci 1.47 ±

0.35mm and posterior third of medial menisci 1.48 ± 0.36mm and added that the anterior third was the thickest part of the medial menisci and that the lateral meniscus was widest at the middle third.

Vineet et al after studying 54 knee joints from 27 formalin fixed fetuses concluded that the thickness of medial menisci anterior one third of (2.04 ± 0.47 mm),middle one third (2.19 ± 0.49mm), posterior one third(2.05 ± 0.56mm) and thickness of lateral menisci anterior one third (1.80 ± 0.42 mm) ,middle one third (2.00 ± 0.45 mm) and posterior one third (1.76 ± 0.41 mm).

In our present study, the thickness of anterior third of lateral menisci of fetus was found to be 0.91±0.38 mm, thickness of middle third 0.23 ±0.33mm, thickness of posterior third 0.44 ±0.34mm.The thickness of anterior third of medial menisci of fetus was found to be 0.71 ±0.348 mm, thickness of middle third of medial menisci 0.77 ± 0.58mm,thickness of posterior third of medial menisci 0.58 ± 0.66 mm.

On contrary to the previous study by Muralimanju et al, the middle third of medial menisci is found to be thicker than the anterior and posterior thirds of medial menisci and the results coincides with the study by Vineet et al. Regarding the lateral menisci,the anterior third of lateral menisci is found to be thickest than the middle and posterior thirds of lateral fetal menisci which correlates with the study of vineet et al and contradicts the results of Muralimanju et al.

Name of the study	Year	Side of Menisci	No. of Menisci	Thickness of anterior third	Thickness of middle third	Thickness of posterior third
Muralimanju et al	2010	Lateral	106	1.54±0.41mm	1.52±0.39mm	1.49±0.34mm
		Medial	106	1.61±0.39mm	1.47±0.35mm	1.48±0.36mm
Vineet et al	2014	Lateral	54	1.80±0.42mm	2±0.45mm	1.76±0.41mm
		Medial	54	2.04±0.47mm	2.19±0.49mm	2.05±0.56mm
Present study	2019	Lateral	100	0.91±0.38mm	0.23±0.33mm	0.44±0.34mm
		Medial	100	0.71±0.34mm	0.77±0.58mm	0.58±0.66mm

Width of fetal cadaveric menisci :

Muralimanju et al reported in their study the width of lateral menisci as width of anterior third of lateral menisci 3.26 ± 0.60mm,width of middle third of lateral menisci 3.53 ± 0.75mm,width of posterior third of lateral menisci 3.44 ± 0.63mm and the width of medial menisci are, width of anterior third of medial menisci2.94 ± 0.61mm ,width of middle third of medial menisci 2.88 ± 0.61mm and width of posterior third of medial menisci 3.28 ± 0.62mm .Vineet et al from their studies reported that the width of medial menisci anterior one third (3.06 ± 0.61 mm) ,middle one third (2.94 ± 0.53 mm) ,posterior one third (3.51 ± 0.74 mm) and lateral menisci anterior one third (3.22 ± 0.50 mm) ,middle one third (3.49 ± 0.70 mm) ,posterior one third (3.63 ± 0.63 mm) .

In our study, the posterior third 1.65± 0.74 mm of lateral menisci is found to be wider than the anterior and middle third of lateral menisci which

correlates with the results of Muralimanju et al and contradicts from the study by Vineeth et al where posterior third of lateral menisci is found to be wider and in the medial menisci the anterior third 1.72 ±0.79 mm is found to be wider than the middle and posterior thirds of medial menisci and is consistent with the results of above two authors.

Name of the study	**Year**	**Side of Menisci**	**No. of Menisci**	**Width of anterior third**	**Width of middle third**	**Width of posterior third**
Muralimanju et al	2010	Lateral	106	3.26±0.60mm	3.53±0.75mm	3.44±0.63mm
		Medial	106	2.94±0.61mm	2.88±0.61mm	3.28±0.62mm
Vineet et al	2014	Lateral	54	3.22±0.50mm	3.49±0.70mm	3.63±0.63mm
		Medial	54	3.06±0.61mm	2.94±0.53mm	3.51±0.74mm
Present study	2019	Lateral	100	1.06±0.11mm	1.54±0.69mm	1.65±0.24mm
		Medial	100	0.72±0.79mm	1.59±1.28mm	1.48±0.79mm

Table 33 : Comparison of width of fetal cadaveric menisci with the data from other authors

MORPHOMETRY OF ADULT CADAVERIC MENISCI :

Thickness of adult cadaveric menisci :

Almeida et al reported that anterior third of medial menisci is thicker 5.92 ± 1.37mm when comparing with the middle third 5.31 ± 1.06 mm , posterior third 5.91 ± 1.13 mm and that the middle third 6.10 ± 1.04 mm is thicker than the anterior third 3.71 ± 1.15 mm and posterior third 5.29 ± 0.78mm of lateral menisci. Braz and Silva conducted a morphometric study of 40 menisci of 20 knees and found that the middle third 6.31mm of medial menisci is thicker than the anterior third 6.17mm, and posterior third 5.18mm of medial menisci and for the lateral menisci the middle third is found to be thicker 6.52mm than anterior third 4.40mm, and posterior third 5.46mm.Panigrahi et al (2013) among 38 cadaveric menisci observed that the mean thickness of medial menisci 1.4mm and lateral menisci as 2.3mm and concluded that lateral menisci is thicker than medial menisici. Chintan et al (2014) observed that among 50 cadaveric menisci belonging north Indian poplation, the posterior third (5.86±1.06 mm) was thicker than anterior third (5.82±1.44 mm) , middle third (5.64±1.26 mm) of medial menisci , and thickness of middle third (5.78±1.22mm) of lateral menisci is higher than the anterior third (3.7±1.52 mm) and posterior third (5.20±0.98 mm) of lateral menisci similar to the study conducted by Mondal et al(2017) among 50 adult lateral knee menisci among north Indian population and found the middle third

of lateral meniscus 4.54 mm to be thicker than anterior third 2.59mm and posterior third 4.53 mm.

In our present study , the thickness of middle third 1.37±0.40 mm of lateral menisci is found to be thicker than anterior 1.09±0.53mm and posterior third1.17±0.55mm of the lateral menisci, this correlates with the previous studies and in accordance with the medial menisci, the anterior third 1.34±0.51mm is found to be thicker than the middle third 1.02±0.61mm and posterior third 1.091±0.71mm similar to Almedia et al and it differs from the results of other authors who reported posterior third to be thicker .Though the morphometric values has a lesser numerical value than other studies, it is comparable with the studies conducted by Panigrahi et al and Chakravarthy et al and this could be because of the similarity in the study location – Tamil nadu .On comparing the thickness of medial and lateral menisci, the lateral menisci is found to be thicker than the medial menisci.

Name of the study	Year	Side of Menisci	Width of anterior third	Width of middle third	Width of posterior third
Almedia et al	2004	Lateral	3.71 ± 1.15 mm	6.10 ± 1.04 mm	5.29 ± 0.78mm
		Medial	5.92 ± 1.37mm	5.31 ± 1.06 mm	5.91 ± 1.13
Chintan et al	2014	Lateral	3.7±1.52 mm	5.78±1.22mm	5.20±0.98 mm
		Medial	5.82±1.44 mm	5.64±1.26 mm	5.86±1.06 mm
Present study	2019	Lateral	1.09±0.53mm	1.37±0.40 mm	1.17±0.55mm
		Medial	1.34±0.51mm	1.02±0.61mm	1.091±0.71mm

Table 34 : Comparison of thickness of adult cadaveric menisci with the data from other authors

Width of adult cadaveric menisci:

Panigrahi et al (2013) observed the posterior third of medial menisci (4.85 ± 0.74 mm) to be wider than anterior third (2.67 ±0.33 mm) and middle third (3.16 ± 0.6 mm) , and in case of lateral menisci the middle third (4.61 ± 0.97 mm) to be wider than as anterior third (3.62 ± 0.95mm) and posterior third (4.43 ± 0.67 mm). Chintan et al (2014)reported the width of posterior third (16.46±2.18 mm) of medial menisci to be higher than anterior third(8.78±2.12 mm) , middle third (12.08±2.52 mm) and the width of lateral menisci was found to be higher in its middle third (11.66±1.48mm)than

anterior third (11.3±1.30 mm) and posterior third (11.50±1.34 mm)..Braz and silva reported that the width of the posterior third 14.96mm of medial menisci to be greater on comparing with anterior and posterior third of medial menisci 7.68mm, 9.32mm respectively and for the lateral menisci posterior third 11.67mm was found to wider than anterior 11.32mm and middle third 11.16mm .

Almedia et al revealed that the width of the middle third of the lateral menisci was more when compared to posterior third of the lateral menisci.

Similar to the results of the previous authors, in our study the posterior third 10.84 ±0.73mm of medial menisci was found to be thicker than the anterior 6.46 ± 0.66mm and middle third 7.23± 1.40mm of the menisci. The width of posterior third 11.8±0.8mm of lateral menisci was greater when comparing with the width of anterior third 11.25 ±0.95mm and middle third 7.95± 1.1mm of lateral menisci and our result agrees with the study done by Braz and Silva et al where the posterior third were wider than anterior and middle thirds of the lateral menisci and contradicts the results of other studies.
The lateral menisci are more prone for discrepancies in the width because of its increased incidence of morphological variants.The knowledge of differences in the width of menisci are essential to determine the site of possible of injury.

Name of the study	Year	Side of Menisci	Width of anterior third	Width of middle third	Width of posterior third
Braz and silva	2010	Lateral	11.32mm	11.16mm	11.67mm
		Medial	7.68mm	9.32mm	14.96mm
Panigrahi et al	2013	Lateral	3.62 ± 0.95mm	4.61 ± 0.97 mm	4.43 ±0.67 mm
		Medial	2.67 ±0.33 mm	3.16 ± 0.6 mm	4.85 ± 0.74mm
Present study	2019	Lateral	11.25 ±0.95mm	7.95 ± 1.1mm	11.8±0.8mm
		Medial	6.46 ± 0.66mm	7.23± 1.40mm	10.84 ±0.73mm

Table 35 : Comparison of width of adult cadaveric menisci with the data from other authors

MORPHOMETRY OF MRI ADULT CADAVERIC MENISCI :

Erbagci et al (2004) observed the measurements of menisci in MRI and found the the thickness of the posterior horn were 5.53 mm was greater than thickness of anterior horn of medial menisci 5.32 mm ,Thickness of the middle third 5.03 mm and regarding the lateral meniscus, posterior horn were 5.36 mm was found to be thicker than the anterior horn 4.33 mm and middle third 4.94 mm. Dhanajaya et al(2014) on analysing mri images of 80 menisci reported that the mean thickness of medial meniscus at the anterior horn, mid body, and posterior horn were 6.3 ± 1.1 mm, 5.2 ± 1.3 mm, and 6.9 ± 1.1 mm, respectively. The respective values for the lateral meniscus were 4.8 ± 0.7 mm, 6.4 ± 1.1 mm, and 7.0 ± 0.9 mm found that the lateral meniscus was

statistically significantly wider than medial at the anterior horn and mid body . In contrast, the posterior horn of medial meniscus was significantly wider than lateral meniscus. Both menisci were significantly wider at their posterior horn..

In our study, the thickness of posterior third of the lateral menisci is more (6.89mm±0.32) when comparing with that of the thickness of anterior third(5.26mm±0.82) and the middle third (6.13mm±0.596)of the lateral menisci which correlates with the results of the other two authors and in accordance with the medial menisci, similar results were observed where the posterior third of medial menisci(6.60mm±0.52) was more thicker than the anterior third (5.26mm ±0.82) and middle third (5.37mm ± 0.38)and regarding the width of lateral menisci, the width of posterior third(11.59±0.309) was greater on comparing with the anterior third 11.25mm ±0.64 and middle third 7.73mm±0.24 and the medial menisci was also wider in its posterior third 12.13mm±0.81 than the anterior third 10.56mm±0.92 and middle third 7.73mm±0.24.

The lateral menisci is found to be more thicker than the medial menisci and the width of the posterior third of medial menisci is greater than the posterior third of lateral menisci.

Comparison of mean values of parameters of adult MRI menisci with cadaveric adult menisci:

The thickness of anterior third of lateral menisci measured using MRI (4.79mm± 0.312) is statistically significantly higher when compared to that measured using adult cadaveric meniscal specimens (1.03mm ±0.504). t(148)=51.492; **p=0.000(Table 16)**

The thickness of middle third of lateral menisci measured using MRI(6.13mm ±0.596is statistically significantly higher when compared to that measured using adult cadaveric meniscal specimens(1.37mm± 0.379).t(148)=51.416; **p=0.000(Table 17)**

The thickness of posterior third of lateral menisci measured using MRI (6.89mm ±0.328) is statistically significantly higher when compared to that measured using adult cadaveric meniscal specimens (1.18mm± 0.526). t(148)=81.658; **p=0.000(Table 18)**

The width of anterior third of lateral menisci measured using MRI (11.25mm ±0.645)is statistically significantly higher when compared to that measured using adult cadaveric meniscal specimens(8.49mm± 2.619). t(148)=9.593; **p=0.000(Table 19)**

The width of middle third of lateral menisci measured using MRI (7.73mm±0.24)is statistically significantly higher when compared to that

measured using adult cadaveric meniscal specimens(7.35mm± 1.19).t(148)=3.098; **p=0.002(Table20)**

The width of posterior third of lateral menisci measured using MRI (11.59mm± 0.309)is statistically significantly higher when compared to that measured using adult cadaveric meniscal specimens(9.69mm ±3.84). t(148)=4.927; **p=0.000(Table 21)**

The thickness of anterior third of medial menisci measured using MRI (5.26mm± 0.82)is statistically significantly higher when compared to that measured using adult cadaveric meniscal specimens(1.34mm ±0.48). t(148)=31.05; **p=0.000(Table 22)**

The thickness of middle third of medial menisci measured using MRI (5.37mm± 0.38)is statistically significantly higher when compared to that measured using adult cadaveric meniscal specimens(1.03mm ±0.59). t(148)=53.78; **p=0.000(Table 23)**

The thickness of posterior third of medial menisci measured using MRI(6.60mm± 0.52)is statistically significantly higher when compared to that measured using adult cadaveric meniscal specimens(1.10mm ±0.68). t (148)=54.33; **p=0.000(Table 24)**

The width of anterior third of medial menisci measured using MRI (10.56mm± 0.92) is statistically significantly higher when compared to that

measured using adult cadaveric meniscal specimens (6.39mm ±2.53). t (148)=14.63; **p=0.000(Table 25)**

The width of middle third of medial menisci measured using MRI (7.73mm± 0.24)is statistically significantly higher when compared to that measured using adult cadaveric meniscal specimens(7.05mm ±2.04). t (148)=3.31; **p=0.001(Table 26)**

The width of posterior third of medial menisci measured using MRI (12.13mm± 0.81)is statistically significantly higher when compared to that measured using adult cadaveric meniscal specimens(11.05mm ±3.67). t (148)=2.81; **p=0.006(Table 27)**

CONCLUSION

The present study was done using adult cadaveric specimens, foetal samples and also MRI Images. The primary aim of the study was to understand the developmental changes in the menisci and to compare the morphometric measurements of cadaveric specimens with that of the MRI Images.

Establishing the apt morphological type of menisci during clinical imaging is vital as the rarer variants can be mistaken for a pathology. The extremely rare meniscal variant such as the ring shaped menisci can be mistaken for a displaced meniscal fragment by bucket handle tear, central tear or incomplete discoid menisci (Kim et al 2006) .Ring shaped menisci is thought to be atavistic as circular shaped menisci (Basmajian, 1952, Soren, 1985) was found in primates such as in Gorilla and it is more often associated with meniscal cyst (Arnold et al, 2000).

Morphometrics of cadaveric menisci is essential for proper sizing of meniscal scaffolds. The importance of width of menisci is that, narrower menisci lessens the chances for tears that being reason for the discoid menisci to be more prone for tear. Studies on meniscal morphometrics are very scarce thus our study adds to the knowledge on fetal and adult morphometrics and in particular there were no study on the morphology and morphometrics of fetal population in current geographic locale.

The various dimensions of medial and lateral menisci measured using formaldehyde preserved cadaveric specimens are significantly smaller when compared to those measured using MRI that denotes actual living values. This difference could be attributed to the shrinkage caused by formaldehyde during preservation. Thus during construction of the menisci scaffolds, the MRI values attests to be a more reliable source rather than the cadaveric meniscal dimensions. It is a very valuable fact as meniscal scaffolds of incorrect dimensions could lead to further complications in the knee joint (Shaffer et al, 2000). On contrary, majority of the recent studies have relied on the cadaveric values which do not represent the actual living values.

The limitation of our study is that statistical significance between males and females could not be studied in the cadaveric specimen. Further, with knowledge about accurate age of the cadaveric specimens we could have compared the various dimensions in different age groups between cadaveric and MRI samples. Also, alternative preservation techniques can be experimented to measure the various dimensions in the cadaver.

ILLUSTRATIVE CASES

Figure 11 : Skin,Fascia,Muscles and Joint Capsule dissected

Figure 12 : Knee Menisci exposed in Fetus

Figure 13 : Dissecting the knee joint cavity

Fig 14 :Knee Adult cadaveric Menisci exposed from joint cavity

PARAMETERS FOR MEASURING ADULT CADAVERIC MENISCI :

Figure 16 : U shaped lateral menisci and Crescent shaped Medial menisci

Figure 17 : Crescent shaped medial menisci and sickle shaped lateral menisci

Figure 18: C shape lateral menisci and V shaped medial menisci

Figure 19: Discoid lateral Menisci

MORPHOLOGY OF CADAVERIC FETAL KNEE MENISCI:

Figure 20 : Sickle shaped lateral menisci

Figure 21 : Ring shaped lateral menisci

Figure 22: Incomplete discoid lateral menisci and Crescent shaped medial menisci

Figure 23: U shaped lateral menisci and C shaped medial menisci

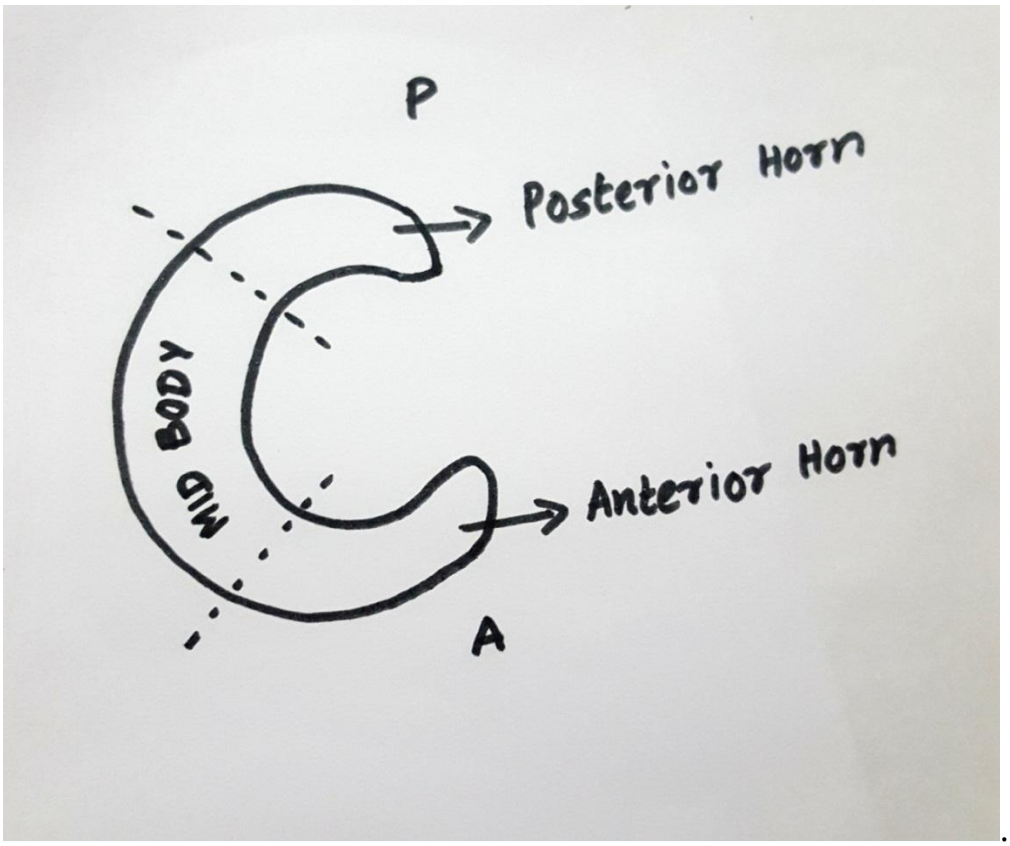

Figure 24 : Menisci divided into 3 equal parts

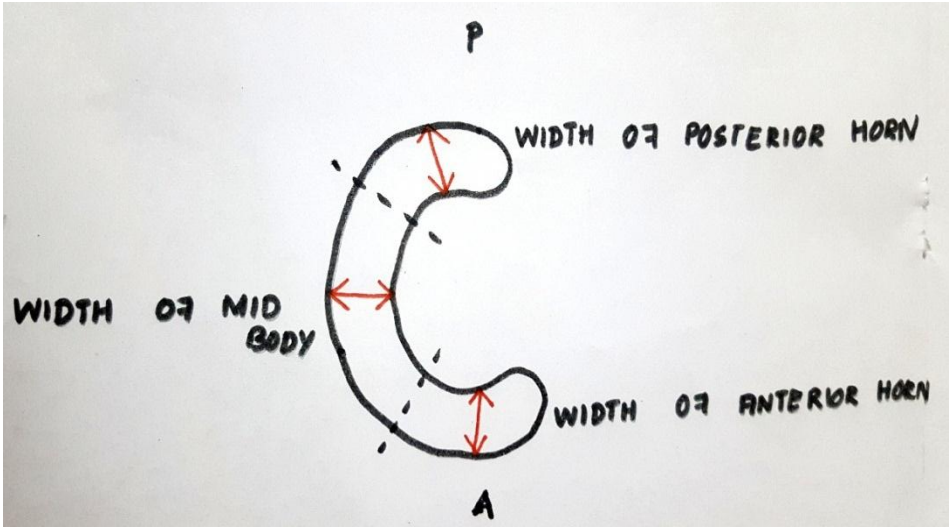

Figure 25: Measuring the width of the menisci

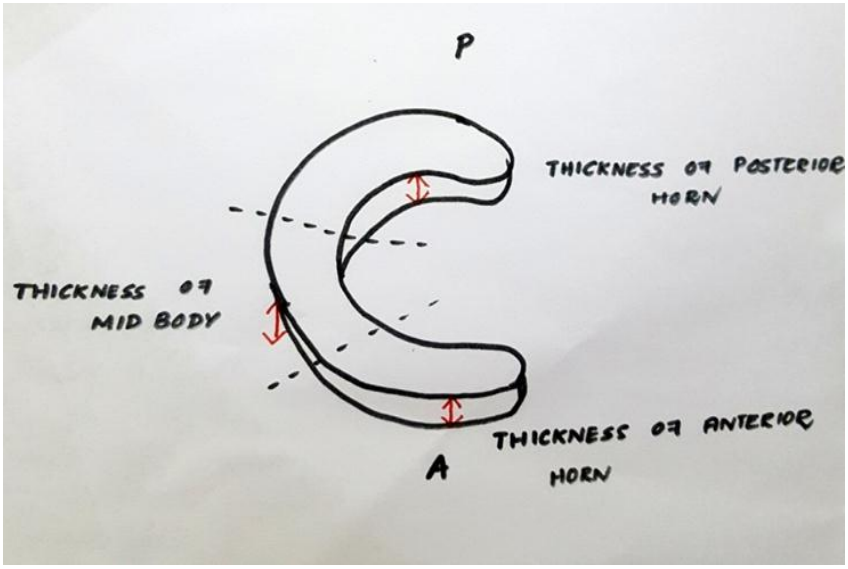

Figure 26: Measuring the thickness of the menisci

MEASURING THE PARAMETERS OF ADULT KNEE MENISCI:

Figure 27: Measuring the width of anterior horn of menisci

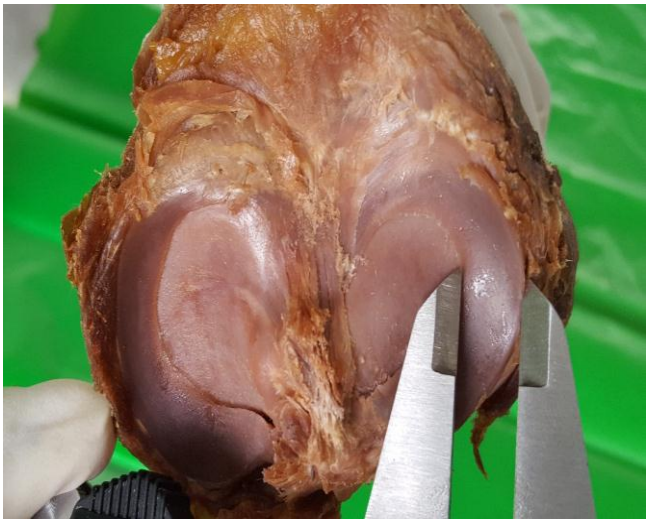

Figure 28 : Measuring the width of midbody of menisci

Figure 29 : Measuring the width of posterior horn of menisci

Figure 30 : Measuring the thickness of menisci

MEASURING THE PARAMETERS OF FETAL KNEE MENISCI :

Figure 31: Measuring the width of fetal menisci

***Figure 32*: Measuring the thickness of fetal menisci**

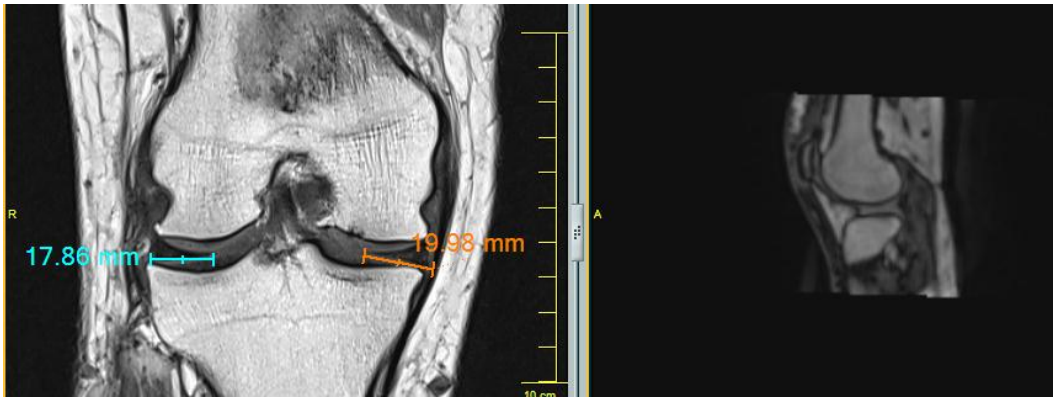

Figure 33 : Width of anterior horn of medial and lateral menisci

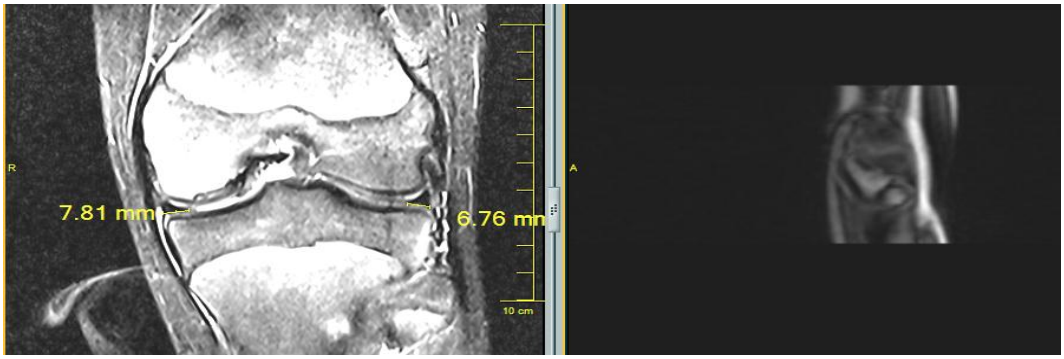

Figure 34: Width of posterior horn of medial and lateral menisci

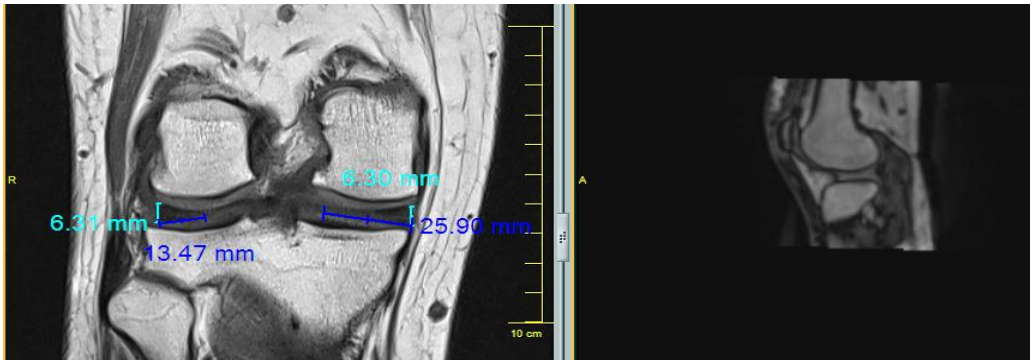

Figure 35: Width And Thickness Of Midbody Of Medial And Lateral Menisci

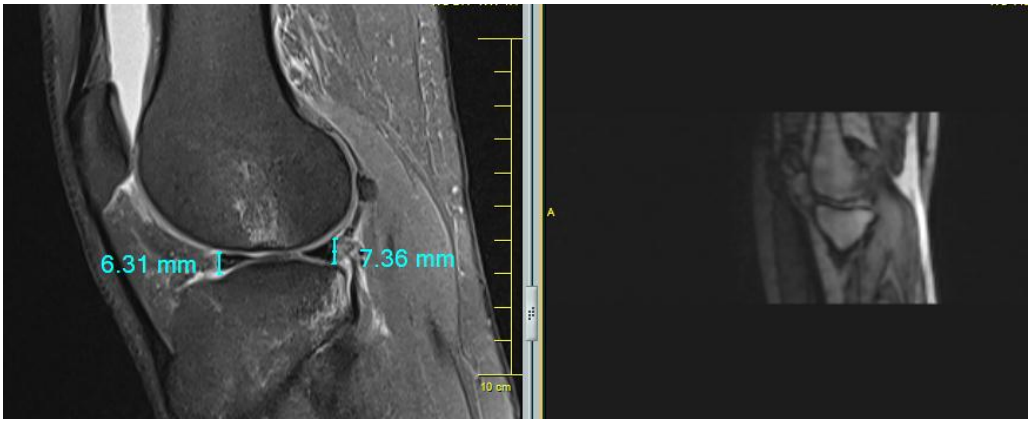

Figure 36: Thickness of anterior and posterior horn of medial menisci

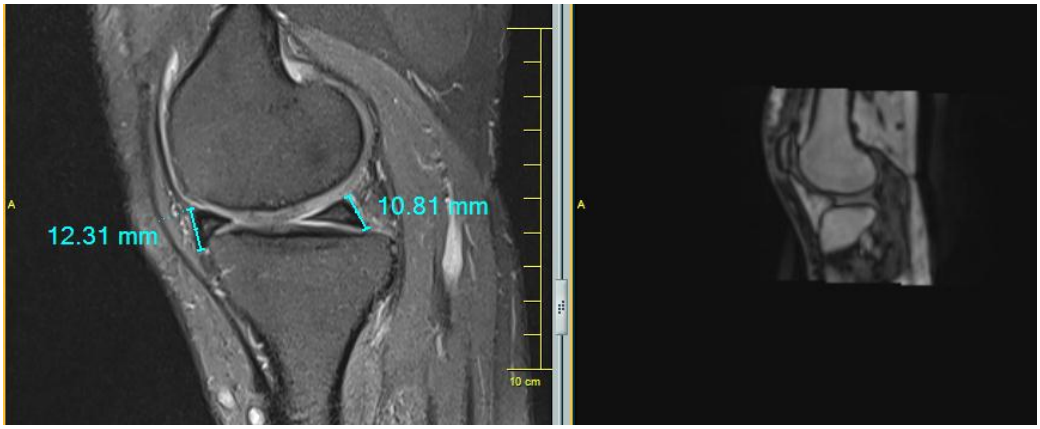

Figure 37: Thickness of anterior and posterior horn of lateral menisci

BIBLIOGRAPHY

1. Kale, A., Kopuz, C., Edýzer, M., Aydin, M.E., Demýr, M. and Ýnce, Y., 2006. Anatomic variations of the shape of the menisci: a neonatal cadaver study. *Knee Surgery, Sports Traumatology, Arthroscopy*, *14*(10), pp.975-981.

2. Aagaard, H. and Verdonk, R., 1999. Function of the normal meniscus and consequences of meniscal resection. *Scandinavian journal of medicine & science in sports*, *9*(3), pp.134-140.

3. Alhalki, M.M., Hull, M.L. and Howell, S.M., 2000. Contact mechanics of the medial tibial plateau after implantation of a medial meniscal allograft: a human cadaveric study. *The American journal of sports medicine*, *28*(3), pp.370-376.

4. da Silva Almeida, K.S., Arruda de Moraes, S.R., Tashiro, T., Da Silveira Neves, E., Toscano, A.E. and Rocha de Abreu, R.M., 2004. Morphometric study of menisc of the knee joint. *Int j Morphol*, *22*(3), pp.181-4.

5. Woo, S.Y., 1994. Anatomy, biology, and biomechanics of tendon, ligament, and meniscus. *Orthopaedic basic science*, pp.45-88.

6. Anderson, A.F., Irrgang, J.J., Dunn, W., Beaufils, P., Cohen, M., Cole, B.J., Coolican, M., Ferretti, M., Glenn Jr, R.E., Johnson, R. and Neyret, P., 2011. Interobserver reliability of the International Society of Arthroscopy, Knee Surgery and Orthopaedic Sports Medicine

(ISAKOS) classification of meniscal tears. *The American journal of sports medicine*, *39*(5), pp.926-932.

7. Andreas Martin Seitz et al., 2012. Effect of partial meniscectomy at the medial posterior horn on tibiofemoral contact mechanics and meniscal hoop strains in human knees.*Journal of orthropaedic surgery*. Volume30, Issue6:Pages 934-942

8. Araki, Y., Yamamoto, H., Nakamura, H. and Tsukaguchi, I., 1994. MR diagnosis of discoid lateral menisci of the knee. *European journal of radiology*, *18*(2), pp.92-95.

9. Arnoczky, S.P. and Milachowski, K.A., 1990. Meniscal allografts: where do we stand. *Articular cartilage and knee joint function: basic science and arthroscopy. Raven, New York*, pp.129-136.

10. Arnoczky, S.P., Warren, R.F. and Spivak, J.M., 1988. Meniscal repair using an exogenous fibrin clot. An experimental study in dogs. *The Journal of bone and joint surgery. American volume*, *70*(8), pp.1209-1217.

11. Arnoczky, S.P. and Warren, R.F., 1982. Microvasculature of the human meniscus. *The American journal of sports medicine*, *10*(2), pp.90-95.

12. Arnoczky, S.P., 1992. Gross and vascular anatomy of the meniscus and its role in meniscal healing, regeneration, and remodeling. *Knee meniscus: basic and clinical foundations*, pp.1-14.

13. Ashwini, C., Nanjaiah, C.M. and Saraswathi, G.S., 2013. Morphometrical study of menisci of human knee joint. *International Journal of Current Research and Review*, *5*(8), p.118.

14. Bae, J.H., Lim, H.C., Hwang, D.H., Song, J.K., Byun, J.S. and Nha, K.W., 2012. Incidence of bilateral discoid lateral meniscus in an Asian population: an arthroscopic assessment of contralateral knees. *Arthroscopy: The Journal of Arthroscopic & Related Surgery*, *28*(7), pp.936-941.

15. Baker, B.E., Peckham, A.C., Pupparo, F. and Sanborn, J.C., 1985. Review of meniscal injury and associated sports. *The American journal of sports medicine*, *13*(1), pp.1-4.

16. Balint, E., Gatt Jr, C.J. and Dunn, M.G., 2012. Design and mechanical evaluation of a novel fiber-reinforced scaffold for meniscus replacement. *Journal of Biomedical Materials Research Part A*, *100*(1), pp.195-202.

17. Bass, H., 1731. *Henrici Bassii... Observationes anatomico-chirurgico-medicae in quattuor decades digestae, variis observatis rarioribus exornatae et solidis medicae scientiae principiis superstructae cum figuris aenei*. in Officina Rengeriana.

18. Bedi, A., Kelly, N.H., Baad, M., Fox, A.J., Brophy, R.H., Warren, R.F. and Maher, S.A., 2010. Dynamic contact mechanics of the medial meniscus as a function of radial tear, repair, and partial meniscectomy. *JBJS*, *92*(6), pp.1398-1408.

19. Bellier G, Dupont JY, Larrain M, Caudron C, Carlioz H.,1989. Lateral discoid meniscus in children. *Journal of Arthroscopy.5*, pp .52–56.

20. Belzer, J.P. and Cannon, W.D., 1993. Meniscus tears: treatment in the stable and unstable knee. *JAAOS-Journal of the American Academy of Orthopaedic Surgeons*, *1*(1), pp.41-47.

21. Bhatt CR, Prajapati B, Suthar K, Mehta CD., 2014.Morphometric study of menisci of knee joint in the west region.Int *J Basic App Med Sci.s4(1):95-9*. pp: 2277-2103.

22. Braz, P.R.P. and Silva, W.G., 2011. Meniscus morphometric study in humans. *Braz. j. morphol. sci*, *27*(2), pp.62-66.

23. Brophy, R.H. and Matava, M.J., 2012. Surgical options for meniscal replacement. *JAAOS-Journal of the American Academy of Orthopaedic Surgeons*, *20*(5), pp.265-272.

24. Jupiter, J.B., Levine, A.M., Trafton, P.G. and Browner, B.D., 2003. *Skeletal trauma: basic science, management, and reconstruction*. WB Saunders.

25. Bullough, P.G., Munuera, L., Murphy, J. and Weinstein, A.M., 1970. The strength of the menisci of the knee as it relates to their fine structure. *The Journal of bone and joint surgery. British volume*, *52*(3), pp.564-570.

26. Vrancken, A.C.T., Crijns, S.P.M., Ploegmakers, M.J.M., O'kane, C., van Tienen, T.G., Janssen, D., Buma, P. and Verdonschot, N., 2014. 3D

geometry analysis of the medial meniscus–a statistical shape modeling approach. *Journal of anatomy*, *225*(4), pp.395-402.

27. C.H. Flouzat-Lachaniette, N. Pujol, P. Boisrenoult, P.2011.BeaufilsMénisquediscoïdemédial :unesérie de quatrecas et revue de la littératureRevue de ChirurgieOrthopédique et Traumatologique, Volume 97, Issue 8: Pages 809-815

28. RMD, C., 1976. Sindromes Dolorosas. Joelho: dor e incapacidade.

29. Caldani L.1813.Icones anatomicae.CalcographiaIosephiPicotti, VenetiisCan Chir.2003. 46: 350-8.

30. Casscells, S.W., 1978. The torn or degenerated meniscus and its relationship to degeneration of the weight-bearing areas of the femur and tibia. *Clinical orthopaedics and related research*, (132), pp.196-200.

31. Chakravarthy, D.J.P. and Khanday, D.S., 2018. Research, 10,(07), 71921-71934. *Key words*, *31629*.

32. Chandler SB.1949.The semilunar cartilages of the knee joint. Anat. Rec.103:531.

33. Chintan R. Bhatt, BhadreshPrajapati, KuldeepSuthar, C. D. Mehta.2014. Morphometric study of menisci of knee joint in the west region; *International journal of basic and applied medical sciences* .4(1)pp:95-99.

34. Cooper et al, 1973, ‘ Surgeon to the King Treatise on Dislocations and on Fractures of the Joints: Fractures of the Neck of the Thigh-bone’ .*Clinical Orthopaedics and Related Research*: *Volume 92* - *Issue* - p 3-5

35. Dandy, D.J. and Jackson, R.W., 1975. The diagnosis of problems after meniscectomy. *The Journal of bone and joint surgery. British volume*, *57*(3), pp.349-352.

36. Davidson, D., Letts, M. and Glasgow, R., 2003. Discoid meniscus in children: treatment and outcome. *Canadian journal of surgery*, *46*(5), p.350.

37. DeHaven, K.E. and Arnoczky, S.P., 1994. Meniscus repair: basic science, indications for repair, and open repair. *Instructional course lectures*, *43*, pp.65-76.

38. DeHaven, K.E. and Sebastianelli, W.J., 1990. Open meniscus repair. Indications, technique, and results. *Clinics in sports medicine*, *9*(3), pp.577-587.

39. Dhananjaya, K.V.N., Murlimanju, B., Poornima, V., Ullal, S., Mitra, P., Dinesh, K.V.N., Saralaya, V., Prabhu, L. and Prashanth, K., 2014. In vivo morphometry of menisci of the knee in South Indians: A preliminary study. *Biomedical journal*, *37*(1), p.14.

40. Di Matteo, B., Tarabella, V., Filardo, G., Viganò, A., Tomba, P. and Marcacci, M., 2013. Thomas Annandale: the first meniscus repair. *Knee Surgery, Sports Traumatology, Arthroscopy*, *21*(9), pp.1963-1966.

41. Dickason, J.M., Del, W.P., Blazina, M.E., Fox, J.M., Friedman, M.J. and Snyder, S.J., 1982. A series of ten discoid medial menisci. *Clinical orthopaedics and related research*, (168), pp.75-79.

42. Dickhaut SC., DeLee JC., 1982.The discoid lateral-meniscus syndrome. *J Bone Joint Surg Am*.64:1068–73.

43. Didio LJA.,2002., *Tratadode Anatomia Aplicada*. *2nd ed*. São Paulo. Atheneu.

44. Dienst, M., Greis, P.E., Ellis, B.J., Bachus, K.N. and Burks, R.T., 2007. Effect of lateral meniscal allograft sizing on contact mechanics of the lateral tibial plateau: an experimental study in human cadaveric knee joints. *The American journal of sports medicine*, *35*(1), pp.34-42.

45. Donahue, T.L.H., Hull, M.L., Rashid, M.M. and Jacobs, C.R., 2004. The sensitivity of tibiofemoral contact pressure to the size and shape of the lateral and medial menisci. *Journal of Orthopaedic Research*, *22*(4), pp.807-814.

46. Dye, S.F., 1996. The knee as a biologic transmission with an envelope of function: a theory. *Clinical Orthopaedics and Related Research (1976-2007)*, *325*, pp.10-18.

47. El-Amin S, Kelly N, Pallotta N, Hammoud S, Lipman J, Ma Y, et al.2014. Design and Evaluation of a Synthetic Fiber-Reinforced Hydrogel Meniscal Replacement. *ORS Annual Meet*. 417

48. Engber, W.D. and Mickelson, M.R., 1981. Cupping of the lateral tibial plateau associated with a discoid meniscus. *Orthopedics*, *4*(8), pp.904-906.

49. Erbagci, H., Gumusburun, E., Bayram, M., Karakurum, G. and Sirikci, A., 2004. The normal menisci: in vivo MRI measurements. *Surgical and Radiologic Anatomy*, *26*(1), pp.28-32.

50. Koyuncu, E., Özgüner, G., Öztürk, K., Bilkay, C., Dursun, A. and Sulak, O., 2017. The morphological anatomy of the menisci of the knee joint in human fetuses. *Balkan medical journal*, *34*(6), pp.559-566.

51. Esteves, C., Castro, R., Cadilha, R., Raposo, F. and Melão, L., 2015. Ring-shaped lateral meniscus with hypoplasic anterior cruciate ligament. *Skeletal radiology*, *44*(12), pp.1813-1818.

52. Fairbank, T.J., 1948. Knee joint changes after meniscectomy. *The Journal of bone and joint surgery. British volume*, *30*(4), pp.664-670.

53. Fithian, D.C., Kelly, M.A. and Mow, V.C., 1990. Material properties and structure-function relationships in the menisci. *Clinical orthopaedics and related research*, (252), pp.19-31.

54. Fukuta, S., Masaki, K. and Korai, F., 2002. Prevalence of abnormal findings in magnetic resonance images of asymptomatic knees. *Journal of orthopaedic science*, *7*(3), pp.287-291.

55. Ghadially, F.N., Lalonde, J.M. and Wedge, J.H., 1983. Ultrastructure of normal and torn menisci of the human knee joint. *Journal of anatomy*, *136*(Pt 4), p.773.

56. Giambattista Morgagni,1706,Book of Adversariaanatomica prima,48 pages

57. Glisic, M., Blagojevic, Z., Ristic, B., Stevanovic, V., Matic, A. and Jovanovic, Z., 2015. Discoid lateral meniscus incidence during knee arthroscopy. *Serbian Journal of Experimental and Clinical Research*, *16*(2), pp.129-134.

58. Gohiya, V. and Pandey, R., 2014. Morphometric study of the menisci of knee joints of human foetuses. *International Journal of Medical Science and Public Health*, *3*(1), pp.38-42.

59. González-Lucena, G., Gelber, P.E., Pelfort, X., Tey, M. and Monllau, J.C., 2010. Meniscal allograft transplantation without bone blocks: a 5- to 8-year follow-up of 33 patients. *Arthroscopy: The Journal of Arthroscopic & Related Surgery*, *26*(12), pp.1633-1640.

60. Greis PE, Bardana DD, Holmstrom MC, et al., 2002. Meniscal injury: I. Basic science and evaluation. *The Journal of the American Academy of Orthopaedic Surgeons.10*:168-176.5

61. De Groot, J.H., De Vrijer, R., Pennings, A.J., Klompmaker, J., Veth, R.P.H. and Jansen, H.W.B., 1996. Use of porous polyurethanes for meniscal reconstruction and meniscal prostheses. *Biomaterials*, *17*(2), pp.163-173.

62. Ha, C.W., Lee, Y.S. and Park, J.C., 2009. The condylar cutoff sign: quantifying lateral femoral condylar hypoplasia in a complete discoid

meniscus. *Clinical orthopaedics and related research*, *467*(5), pp.1365-1369.

63. Hayashi, L.K., Yamaga, H., Ida, K. and Miura, T., 1988. Arthroscopic meniscectomy for discoid lateral meniscus in children. *JBJS*, *70*(10), pp.1495-1500.

64. Herwig J, Egner E, Buddecke E.,1984. Chemical changes of the human knee joint menisci in various stages of degeneration. *Annals of the Rheumatic Diseases*. 43:635-640

65. Hey, W., 1814. Practical Observations in Surgery, London, T. *Cadell and W. Davies*.

66. Holloway, J.L., Lowman, A.M., VanLandingham, M.R. and Palmese, G.R., 2014. Interfacial optimization of fiber-reinforced hydrogel composites for soft fibrous tissue applications. *Acta biomaterialia*, *10*(8), pp.3581-3589.

67. Hunter, D.J., Zhang, Y.Q., Niu, J.B., Tu, X., Amin, S., Clancy, M., Guermazi, A., Grigorian, M., Gale, D. and Felson, D.T., 2006. The association of meniscal pathologic changes with cartilage loss in symptomatic knee osteoarthritis. *Arthritis & Rheumatism*, *54*(3), pp.795-801.

68. Ikeuchi, H., 1982. Arthroscopic treatment of the discoid lateral meniscus. Technique and long-term results. *Clinical orthopaedics and related research*, (167), pp.19-28.

69. Ingman, A.M., Ghosh, P. and Taylor, T.K.F., 1974. Variation of collagenous and non-collagenous proteins of human knee joint menisci with age and degeneration. *Gerontology*, *20*(4), pp.212-223.

70. Jackson RW.,2010.A history of arthroscopy. *Arthroscopy 26*:91–103

71. Kale, A., Kopuz, C., Edýzer, M., Aydin, M.E., Demýr, M. and Ýnce, Y., 2006. Anatomic variations of the shape of the menisci: a neonatal cadaver study. *Knee Surgery, Sports Traumatology, Arthroscopy*, *14*(10), pp.975-981.

72. Koch, T., 2013. The Hippocratic thorn in bioethics' hides: Cults, sects, and strangeness. *Journal of Medicine and Philosophy*, *39*(1), pp.75-88.

73. Patel, N.M., Cody, S.R. and Ganley, T.J., 2012. Symptomatic bilateral discoid menisci in children: a comparison with unilaterally symptomatic patients. *Journal of Pediatric Orthopaedics*, *32*(1), pp.5-8.

74. Kaplan, E.B., 1957. Discoid lateral meniscus of the knee joint. *J Bone Joint Surg*, *39*, pp.77-87.

75. Lee, S.J., Aadalen, K.J., Malaviya, P., Lorenz, E.P., Hayden, J.K., Farr, J., Kang, R.W. and Cole, B.J., 2006. Tibiofemoral contact mechanics after serial medial meniscectomies in the human cadaveric knee. *The American journal of sports medicine*, *34*(8), pp.1334-1344.

76. Kaur, A. and Sodhi, S., 2013. Morphometric study of the medial meniscus of the knee joint in thirty adult male cadavers. *J Acad Ind Res*, *2*(4), pp.226-9.

77. Desai, V.V. and Ackroyd, C.E., 2000. Resection of degenerate menisci—is it useful?. *The Knee*, *7*(3), pp.179-182.

78. Testut L, Latarjet A., 1975. *Tratado de Anatomía Humana.* 10th ed. Barcelona.

79. Kepler J.1611.Dioptrice. Kettelkamp DB, Jacobs AW.1972.Tibiofemoral contact area–determination and implications. *J Bone Joint Surg Am 54*:349–356

80. Kim et al.1995.A ring shaped lateral meniscus. *The Journal of arthroscopic and related surgery*. volume 11,issue 6:pages 738-739

81. Kim, S.J., Lee, Y.T. and Kim, D.W., 1998. Intraarticular anatomic variants associated with discoid meniscus in Koreans. *Clinical Orthopaedics and Related Research®*, *356*, pp.202-207.

82. King D.,1948.The healing of semilunar cartilages. J Bone Joint Surg [Am]1936;18:333–42

83. Fairbank, T.J., 1948. Knee joint changes after meniscectomy. *The Journal of bone and joint surgery. British volume*, *30*(4), pp.664-670.

84. Kohn D.1992.,Autograft meniscus replacement: experimental and clinical results.*J Bone Joint Surg Br.74*(6):910-7.

85. Koukouliaset al.2011. Symptomatic ring shaped lateral meniscus.*MRI Findings BMJ Case Rep 2011*.

86. Krause, W.R., Pope, M.H., Johnson, R.J. and Wilder, D.G., 1976. Mechanical changes in the knee after meniscectomy. *The Journal of bone and joint surgery. American volume*, *58*(5), pp.599-604.

87. Kroiss F.1910. Die Verletzungen der Kniegelenkoszwischenknorpel und ihrerVerbindungen. BeitrKlin Chir.66:598–801.

88. Lee, S.J., Aadalen, K.J., Malaviya, P., Lorenz, E.P., Hayden, J.K., Farr, J., Kang, R.W. and Cole, B.J., 2006. Tibiofemoral contact mechanics after serial medial meniscectomies in the human cadaveric knee. *The American journal of sports medicine*, *34*(8), pp.1334-1344.

89. Lemaire, R., 1977. Osteoarthrosis of the knee joint, a predictable consequence of meniscectomy in patients with angular deformity of the knee (author's transl). *Acta chirurgica Belgica*, *76*(3), pp.355-360.

90. Leopoldo marco antonio caldani (1725-1813) and floriano caldani (1772-1836). Iconesanatomicae., 1801-1813

91. Linder-Ganz, E., Elsner, J.J., Danino, A., Guilak, F. and Shterling, A., 2010. A novel quantitative approach for evaluating contact mechanics of meniscal replacements. *Journal of biomechanical engineering*, *132*(2), p.024501.

92. Liu, C., Toma, I.C., Mastrogiacomo, M., Krettek, C., von Lewinski, G. and Jagodzinski, M., 2013. Meniscus reconstruction: today's achievements and premises for the future. *Archives of orthopaedic and trauma surgery*, *133*(1), pp.95-109.

93. Lubowitz, J.H., Verdonk, P.C., Reid, J.B. and Verdonk, R., 2007. Meniscus allograft transplantation: a current concepts review. *Knee Surgery, Sports Traumatology, Arthroscopy*, *15*(5), pp.476-492.

94. Marcacci, M., Di Matteo, B., Filardo, G. and Tarabella, V., 2013. Rediscovering the history of orthopedics.

95. Mascarenhas, R., Yanke, A.B., Frank, R.M., Butty, D.C. and Cole, B.J., 2014. Meniscal allograft transplantation: preoperative assessment, surgical considerations, and clinical outcomes. *The journal of knee surgery*, *27*(06), pp.443-458.

96. McDevitt, C.A. and Webber, R.J., 1990. The ultrastructure and biochemistry of meniscal cartilage. *Clinical orthopaedics and related research*, (252), pp.8-18.

97. Kohn, D., Wirth, C.J., Reiss, G., Plitz, W., Maschek, H., Erhardt, W. and Wulker, N., 1992. Medial meniscus replacement by a tendon autograft. Experiments in sheep. *The Journal of bone and joint surgery. British volume*, *74*(6), pp.910-917.

98. McGinity, J.B., Geuss, L.F. and Marvin, R.A., 1977. Partial or total meniscectomy: a comparative analysis. *JBJS*, *59*(6), pp.763-766.

99. Middleton, D.S., 1936. Congenital disc-shaped lateral meniscus with snapping knee. *British Journal of Surgery*, *24*(94), pp.246-255.

100. Milachowski, K.A., Weismeier, K. and Wirth, C.J., 1989. Homologous meniscus transplantation. *International orthopaedics*, *13*(1), pp.1-11.

101. Mitsuoka, T., Shino, K., Hamada, M. and Horibe, S., 1999. Osteochondritis dissecans of the lateral femoral condyle of the knee joint. *Arthroscopy: The Journal of Arthroscopic & Related Surgery*, *15*(1), pp.20-26.

102. Morgagni JB.1719.Adversariaanatomicaomnia. Excudebat Josephus Cominus, Patavii

103. Moriguchi, Y., Tateishi, K., Ando, W., Shimomura, K., Yonetani, Y., Tanaka, Y., Kita, K., Hart, D.A., Gobbi, A., Shino, K. and Yoshikawa, H., 2013. Repair of meniscal lesions using a scaffold-free tissue-engineered construct derived from allogenic synovial MSCs in a miniature swine model. *Biomaterials*, *34*(9), pp.2185-2193.

. Motta Filho, L.A.J., Motta, L.A.J. and Motta Filho, G.R., 1999. Menisco lateral discóide: correlação anátomo-clínica. *Rev. bras. ortop*, *34*(8), pp.457-460.

104. Murlimanju, B.V., Nair, N., Pai, S., Pai, M. and Gupta, C., 2010. MORPHOLOGICAL STUDY OF THE MENISCI OF THE KNEE JOINT IN ADULT CADAVERS OF THE SOUTH INDIAN POPULATION. *Marmara Medical Journal*, *23*(2).

105. Murlimanju, B.V., Nair, N., Kumar, B., Krishnamurthy, A., Gupta, C. and Chethan, P., 2012. Clinically oriented morphometric study of medial and lateral menisci of the knee joint in adult cadavers. *La Clinica terapeutica*, *163*(2), pp.105-108.

106. Rao, N., Gupta, A.D. and Raju, A.V., 2014. Morphometric analysis of the menisci of the knee joint in population of East Godavari region of Andhra Pradesh. *Journal of Evolution of Medical and Dental Sciences*, *3*(34), pp.8972-8980.

107. Nathan, P.A. and Cole, S.C., 1969. 12 Discoid Meniscus: A Clinical and Pathologic Study. *Clinical Orthopaedics and Related Research (1976-2007)*, *64*, pp.107-113.

108. Nimje PB, Bhuiyan PS.2014. A Morphometric Study of Menisci of Knee Joint in Human Cadavers.*Int J 6) Biol Med Res.5* (1): 3807-3809.

109. NishaGoyal, NavitaAggarwal, SubhashKaushal, G.S. Kalyan, Ramandeep Kaur.2016. Morphometry Of Lateral Meniscus: A Cadaveric Study. Int J Anat Res;4(4):3179-3184.

110. Paessler, H.H., Franke, K. and Gladstone, J., 2003. Moritz Katzenstein: the father of meniscus repair surgery. *Arthroscopy: The Journal of Arthroscopic & Related Surgery*, *19*(5), pp.1-2.

111. Paletta Jr, G.A., Manning, T., Snell, E., Parker, R. and Bergfeld, J., 1997. The effect of allograft meniscal replacement on intraarticular contact area and pressures in the human knee: a biomechanical study. *The American journal of sports medicine*, *25*(5), pp.692-698.

112. Panigrahi, M. and Kumar, S.S., 2013. Morphometric Analysis of Adult Menisci–A Cadaveric Study. *IOSR Journal of Dental and Medical Sciences (IOSR-JDMS)*, *11*(1), pp.40-43.

113. Papadopoulos, A., Karathanasis, A., Kirkos, J.M. and Kapetanos, G.A., 2009. Epidemiologic, clinical and arthroscopic study of the discoid meniscus variant in Greek population. *Knee Surgery, Sports Traumatology, Arthroscopy*, *17*(6), pp.600-606.

114. Papalia, R., Franceschi, F., Diaz Balzani, L., D'Adamio, S., Maffulli, N. and Denaro, V., 2013. Scaffolds for partial meniscal replacement: an updated systematic review. *British medical bulletin*, *107*(1), pp.19-40.

115. Pereira, H., Frias, A.M., Oliveira, J.M., Espregueira-Mendes, J. and Reis, R.L., 2011. Tissue engineering and regenerative medicine strategies in meniscus lesions. *Arthroscopy: The journal of arthroscopic & related surgery*, *27*(12), pp.1706-1719.

116. Pernin, J., Verdonk, P., Si Selmi, T.A., Massin, P. and Neyret, P., 2010. Long-term follow-up of 24.5 years after intra-articular anterior cruciate ligament reconstruction with lateral extra-articular augmentation. *The American journal of sports medicine*, *38*(6), pp.1094-1102.

117. Peters, T.J. and Smillie, E.S., 1972. Studies on the chemical composition of the menisci of the knee joint with special reference to the horizontal cleavage lesion. *Clinical Orthopaedics and Related Research (1976-2007)*, *86*, pp.245-252.

118. R.Verdonka,P.Volpib,P.Verdonka,H.VanderBrachta,M.VanLaera,K.F.AlmqvistaS,VanderEeckenaE.ProsperobA.Quagliab.2013.Volume44,Supplement 1January, Pages S21-S27

119. Rao, P.S., Rao, S.K. and Paul, R., 2001. Clinical, radiologic, and arthroscopic assessment of discoid lateral meniscus. *Arthroscopy: The Journal of Arthroscopic & Related Surgery*, *17*(3), pp.275-277.

120. Rashmi B.N, Dakshayani K.R, Vadiraja N.2016. Morphometric Study Of Menisci Of Knee Joints In Adult Cadavers. *Int J Anat Res*; 4(4):2973-2978.

121. Vahvanen, V. and Aalto, K., 1979. Meniscectomy in children. *Acta Orthopaedica Scandinavica*, *50*(6), pp.791-795.

122. Rohila J, Rathee SK, Dhattarwal SK, Kundu ZS.2017.Morphometric analysis of menisci of adult human knee joint in North Indian population. *Int J Res Med Sci5*:569-73.

123. Rohren EM, Kosarek FJ, Helms CA .2001.Discoid lateral meniscus and the frequency of meniscal tears. *Skeletal Radiol 30(6*): 316–320

124. Pawar, R.M. and Natarajan, M., 2014. Magnetic resonance imaging study of normal menisci. *Journal of Evolution of Medical and Dental Sciences*, *3*(19), pp.5344-5352.

125. Di Matteo, B., Moran, C.J., Tarabella, V., Vigano, A., Tomba, P., Marcacci, M. and Verdonk, R., 2016. A history of meniscal surgery: from ancient times to the twenty-first century. *Knee Surgery, Sports Traumatology, Arthroscopy*, *24*(5), pp.1510-1518.

126. Scott, G.A., Jolly, B.L. and Henning, C.E., 1986. Combined posterior incision and arthroscopic intra-articular repair of the meniscus. An examination of factors affecting healing. *JBJS*, *68*(6), pp.847-861.

127. Sivasakthi M., Yogesh Ashok Sontakke., Aravindhan Morphometry of knee menisci.*Journal of Advance Research in Medical & Health Science* ISSN: 2208-2425

128. Smillie, I.S., 1948. The congenital discoid meniscus. *The Journal of bone and joint surgery. British volume*, *30*(4), pp.671-682.

129. Smillie, I.S., 1968. Internal Derangement of the Knee [Abridged] The Current Pattern of the Pathology of Meniscusc Tears.

130. Stärke, C., Kopf, S., Petersen, W. and Becker, R., 2009. Meniscal repair. *Arthroscopy: The Journal of Arthroscopic & Related Surgery*, *25*(9), pp.1033-1044.

131. Steadman, J.R. and Rodkey, W.G., 2005. Tissue-engineered collagen meniscus implants: 5-to 6-year feasibility study results. *Arthroscopy: The Journal of Arthroscopic & Related Surgery*, *21*(5), pp.515-525.

132. Stone, K.R., Steadman, J.R., Rodkey, W.G. and Li, S.T., 1997. Regeneration of meniscal cartilage with use of a collagen scaffold. Analysis of preliminary data. *JBJS*, *79*(12), p.1770.

133. Stone, K.R., Rodkey, W.G., Webber, R., McKinney, L. and Steadman, J.R., 1992. Meniscal regeneration with copolymeric collagen scaffolds: In vitro and in vivo studies evaluated clinically, histologically, and biochemically. *The American journal of sports medicine*, *20*(2), pp.104-111.

134. Sun Y, Jiang Q.2011.Review of discoid meniscus. Orthopaedic Surgery.3:219-223

135. Kini, S.G., Walker, P. and Bruce, W., 2015. Bilateral symptomatic discoid medial meniscus of the knee: a case report and review of literature. *Archives of trauma research*, *4*(1).

136. Tapper EM, Hoover NW.,1969.Late results after meniscectomy. *J Bone Joint Surg Am 51*:517–526

137. Testut L and Latarej A .1975.Tratado de Anatomia Humana.10th edition (Barcelona, Salvat).

138. Van Arkel, E.R. and de Boer, H.H., 1995. Human meniscal transplantation. Preliminary results at 2 to 5-year follow-up. *The Journal of bone and joint surgery. British volume*, *77*(4), pp.589-595.

139. Vandermeer, R.D. and Cunningham, F.K., 1989. Arthroscopic treatment of the discoid lateral meniscus: results of long-term follow-up. *Arthroscopy: The Journal of Arthroscopic & Related Surgery*, *5*(2), pp.101-109.

140. VeijoVahvanen&KariAalto.1979.MeniscectomyinChildren,*ActaOrthopaedicaScandinavica,50*:6, 791-795.

141. Verdonk R.2011.The meniscus: past, present and future. Knee Surg Sports TraumatolArthrosc 19:145–146

142. Verdonk P, Beaufils P, Bellemans J, Djian P, Heinrichs EL, Huysse W, Laprell H, Siebold R, Verdonk R .2012.Actifit study group. Successful treatment of painful irreparable partial meniscal defects with a polyurethane scaffold: two-year safety and clinical outcomes. *Am J Sports Med* 40:844–853

143. Verdonk R, Volpi P, Verdonk P, Van der Bracht H, Van Laer M, Almqvist KF, Vander Eecken S, Prospero E, Quaglia A.2013.Indications and limits of meniscal allografts. 44:21–27

144. Verstraete KL, et al. 1997.,Alternative treatments for meniscal injuries Eur J Radiol. . Dec;26(1):16–22

145. Vesalius, Andreas, 1514-1564. *De Humani Corporis Fabrica* : Basel, 1543. Palo Alto, CA: Octavo, 1998.

146. Voloshin AS, Wosk J.1983.Shock absorption of meniscectomized and painful knees. A comparative in vivo study. *J Biomed Eng 5*:157–161.

147. Walsh, C.J., Goodman, D., Caplan, A.I. and Goldberg, V.M., 1999. Meniscus regeneration in a rabbit partial meniscectomy model. *Tissue engineering*, *5*(4), pp.327-337.

148. Watanabe M, Takeda S.1979.Ikeuchi H. *Atlas of arthroscopy*. *3rd ed*. Tokyo, Igaku-Shoin: pp. 75–130.

149. Watson-Jones R.1930.Specimen of internal semilunar cartilage as a complete disc. *Proc R Soc Med*.;23:588

150. Weiner B, Rosenberg N., 1974. Discoid medial meniscus: Association with bone changes in the tibia. A case report.*The Journal of Bone and Joint Surgery*. *American volume*.56:171-173

151. Wirth, C.J., Milachowski, K.A. and Weismeier, K., 1986. Meniscus transplantation in animal experiments and initial clinical

results. *Zeitschrift fur Orthopadie und ihre Grenzgebiete*, *124*(4), pp.508-512.

152. Wirth CR.1981.Meniscus repair. *ClinOrthopRelat Res 157*:153–160

153. Xavier, S.R.H., Júnior, A.G.P. and Filho, T.E.P.B., 1998. Lesões Menisco-Ligamentares do Joelho. *Ortopedia e Trumatologia: Princípios e Prática*.

154. Young, R.B., 1889. The external semilunar cartilage as a complete disc. *Memoirs and memoranda in anatomy*.

155. Zaman M, Leonard MA.1981.Meniscectomy in children: results in 59 knees. Injury.12:425–428.