

**VALIDITY OF SIRIRAJ STROKE SCORE IN
DIFFERENTIATING CEREBRAL INFARCT AND
HAEMORRHAGE IN SOUTH INDIANS**

DISSERTATION SUBMITTED FOR THE

AWARD OF THE DEGREE OF

M.D. GENERAL MEDICINE

(BRANCH – I)

APRIL – 2017



DEPARMENT OF GENERAL MEDICINE

MADURAI MEDICAL COLLEGE

MADURAI 625020

THE TAMILNADU

DR.M.G.R. MEDICAL UNIVERSITY,

CHENNAI

CERTIFICATE FROM THE DEAN

*This is to certify that this dissertation entitled **VALIDITY OF SIRIRAJ STROKE SCORE IN DIFFERENTIATING CEREBRAL INFARCT AND HAEMORRHAGE IN SOUTH INDIANS** is the bonafide work of **Dr. HIBU JULI** in partial fulfillment of the university regulations of the Tamil Nadu Dr. M.G.R. Medical University, Chennai, for M.D General Medicine Branch I examination to be held in **April 2017**.*

Dr. M.R.VAIRAMUTHU RAJU MD.

The Dean,

Government Rajaji Hospital,

Madurai Medical College,

Madurai

CERTIFICATE FROM THE HEAD OF THE DEPARTMENT

*This is to certify that this dissertation entitled “**VALIDITY OF SIRIRAJ STROKE SCORE IN DIFFERENTIATING CEREBRAL INFARCT AND HAEMORRHAGE IN SOUTH INDIANS**” is the bonafide work of **Dr. HIBU JULI** in partial fulfillment of the university regulations of the Tamil Nadu Dr. M.G.R. Medical University, Chennai, for **M.D General Medicine Branch I** examination to be held in **April 2017**.*

DR.V.T.PREM KUMAR,M.D.,
Professor and HOD,
Department Of General Medicine,
Government Rajaji Hospital,
Madurai Medical College,
Madurai.

CERTIFICATE FROM THE GUIDE

*This is to certify that this dissertation entitled “**VALIDITY OF SIRIRAJ STROKE SCORE IN DIFFERENTIATING CEREBRAL INFARCT AND HAEMORRHAGE IN SOUTH INDIANS**” is the bonafide work of **Dr. HIBU JULI** in partial fulfillment of the university regulations of the Tamil Nadu Dr. M.G.R. Medical University, Chennai, for **M.D General Medicine Branch I** examination to be held in **April 2017**.*

Dr.J.SANGUMANI M.D, d.diab.

Professor of Medicine,

Department Of General Medicine,

Government Rajaji Hospital,

Madurai Medical College,

Madurai

DECLARATION

*I Dr. HIBU JULI declare that, I carried out this work on “**VALIDITY OF SIRIRAJ STROKE SCORE IN DIFFERENTIATING CEREBRAL INFARCT AND HAEMORRHAGE IN SOUTH INDIANS** ” at the Department of Medicine, Govt. Rajaji Hospital during the period **MARCH 2016 TO AUGUST 2016**. I also declare that this bonafide work or a part of this work was not submitted by me or any others for any award, degree or diploma to any other University, Board either in India or abroad.*

*This dissertation is submitted to The Tamil Nadu Dr. M.G.R. Medical University, Chennai in partial fulfillment of the rules and regulations for the award of **M.D Degree General Medicine Branch- I**; examination to be held in **April 2017**.*

Place:Madurai

Date :

DR. HIBU JULI

ACKNOWLEDGEMENTS

At the outset, I wish to thank our Dean Dr. M.R. VAIRAMUTHURAJU M.D., for permitting me to use the facilities of Madurai Medical College and Government Rajaji Hospital to conduct this study.

I would like to express my deep sense of gratitude and thanks to my beloved teacher and Head of the Department of Medicine Prof. Dr. V.T.PREMKUMAR M.D. He has always guided me, by example and valuable words of advice and has encouraged innovative thinking and original research work done by post graduates.

I shall remain eternally grateful to my beloved teacher, my guide Dr.J.SANGUMANI M.D, d.diab who has given me his moral support and encouragement through the conduct of the study and also during my entire postgraduate course.

I also sincerely express my thanks to our Professors Dr.R.Balajinathan.M.D., Dr.M.Natarajan.M.D., Dr.G.Bagialakshmi, M.D., Dr.C.Dharmaraj.M.D., Dr.Ravindran M.D., Dr.Prabhakaran M.D., Dr.Peer Mohammed for their par excellence in clinical teaching and constant support.

*I am extremely grateful to Prof. Dr. SUMATHI, MD; Head of the department of **RADIODIAGNOSIS** for her constant support, guidance, cooperation and encouragement to complete this study.*

I offer my heartfelt thanks to my Assistant Professors , Dr. R. SUNDARAM M.D. and Dr. K.S RAGHAVAN M.D, d.diab for their constant encouragement, timely help and critical suggestions throughout the study and also for making my stay in the unit both informative and pleasurable.

*I express my thanks to Dr. PRAKASH, post graduate **RADIODIAGNOSIS** for his help and support in my dissertation work.*

***My patients**, who form the most integral part of the work, were always kind and cooperative. I pray to God to give them courage and strength to endure their illness, hope all of them go into complete remission.*

I thank my friends and family who have stood by me during my times of need. Their help and support have always been invaluable to me. And last but not the least I would like to thank the Lord Almighty for His grace and blessings without which nothing would have been possible.

CONTENTS

SNO	TITLE	PAGE NO
1	INTRODUCTION	1 - 9
2	AIM AND OBJECTIVES	10
3	REVIEW OF LITERATURE	11 – 78
4	MATERIALS AND METHODS	79-88
5	ANTICIPATED OUTCOME	89 – 95
6	DISCUSSION	96 – 97
7	CONCLUSION	98
8	ANNEXURES	
	Bibliography	99 – 100
	Proforma	101 – 102
	Master Chart	103 – 104
	Ethical Clearance letter	105
	Anti Plagiarism Certificates	106 – 107

INTRODUCTION

Stroke is the second leading cause of death worldwide, causing 6.2 million deaths in 2011. Stroke is a major health issue not only because it is a major cause of death but also because it leaves patients with several residual disabilities like physical dependence, dementia and depression.

Computed tomography (CT) scan is an accurate, safe, non-invasive procedure routinely used as an investigative tool for stroke to distinguish between infarction and haemorrhage.

Computed tomography scanning of brain is expensive in both the initial investment and maintenance. In developing countries like India, cost and availability constraints prohibit its widespread use especially in rural areas.

Clinical stroke scores were developed to overcome these limitations. Differential diagnosis between infarction and haemorrhage can be made on clinical grounds with aid of Siriraj Scoring System. CT scan is not readily available in semi-urban and rural areas and the scoring systems will then come into play in differentiating the stroke subtype. This study is being done to determine the sensitivity, specificity of Siriraj score

AIMS AND OBJECTIVES

1. To differentiate between cerebral infarct and intra cerebral hemorrhage on the basis of Siriraj Stroke Score.
2. To find out the sensitivity, specificity and overall accuracy of the scoring system by comparing it with the CT scan findings.

REVIEW OF LITERATURE

Among all the neurologic diseases of adult life, the cerebrovascular ones clearly rank first in frequency and importance. At least 50 percent of the neurologic disorders in a general hospital are of this type.

Stroke is focal neurological deficit due to cerebral vascular cause which lasts more than 24 hours.

The term cerebrovascular disease designates any abnormality of the brain resulting from a pathologic process of the blood vessels. Pathologic process is given an inclusive meaning namely, occlusion of the lumen by embolus or thrombus, rupture of a vessel, an altered permeability of the vessel wall, or increased viscosity or other change in the quality of the blood flowing through the cerebral vessels. The vascular pathologic process may be considered not only in its grosser aspects of embolism, thrombosis, dissection, or rupture of a vessel but also in terms of the more basic or primary disorder, i.e., atherosclerosis, hypertensive arteriosclerotic change, arteritis, aneurysmal dilation, and developmental malformation. Equal importance attaches to the secondary parenchymal changes in the brain resulting from the vascular lesion. These are of two main types, ischemia, with or without infarction, and hemorrhage and unless one or the other occurs, the vascular lesion usually remains silent. The only exceptions to this statement are the local pressure effects of an aneurysm,

vascular headache (migraine, hypertension, temporal arteritis), multiple small vessel disease with progressive encephalopathy (as in malignant hypertension or cerebral arteritis), and increased intracranial pressure (as occurs in hypertensive encephalopathy and venous sinus thrombosis). Also, persistent acute hypotension may cause ischemic necrosis in regions of brain between the vascular territories of cortical vessels, even without vascular occlusion.

Causes of cerebral abnormalities from alterations of arteries and veins

1. Atherosclerotic thrombosis
2. Transient ischemic attacks
3. Embolism
4. Hypertensive haemorrhage
5. Ruptured or unruptured saccular aneurysm or AVM
6. Arteritis
 - a. Meningovascular syphilis, arteritis secondary to pyogenic and tuberculous meningitis, rare infective types (typhus, schistosomiasis, malaria, mucormycosis, etc.)
 - b. Connective tissue diseases (polyarteritis nodosa, lupus erythematosus), necrotizing arteritis. Wegener arteritis, temporal arteritis, Takayasu disease, granulomatous or giant-cell arteritis of the aorta, and giant-cell granulomatous angiitis of cerebral arteries
7. Cerebral thrombophlebitis: secondary to infection of ear, paranasal sinus, face, etc.; with meningitis and subdural empyema; debilitating states, postpartum, postoperative, cardiac failure, hematologic disease (polycythemia, sickle cell

- disease), and of undetermined cause
8. Hematologic disorders: anticoagulants and thrombolytics, clotting factor disorders, polycythemia, sickle cell disease, thrombotic thrombocytopenic purpura, thrombocytosis, intravascular lymphoma, etc.
 9. Trauma and dissection of carotid and basilar arteries
 10. Amyloid angiopathy
 11. Dissecting aortic aneurysm
 12. Complications of arteriography
 13. Neurologic migraine with persistent deficit
 14. With tentorial, foramen magnum, and subfalcial herniations
 15. Miscellaneous types: fibromuscular dysplasia, with local dissection of carotid, middle cerebral, or vertebrobasilar artery, x-irradiation, unexplained middle cerebral infarction in closed head injury, pressure of unruptured saccular aneurysm, complication of oral contraceptives
 16. Undetermined cause in children and young adults: moyamoya disease and others

Pathophysiology of Cerebral Ischemia and Ischemic Infarction

Cerebral infarction basically comprises two pathophysiologic processes, one, a loss in the supply of oxygen and glucose secondary to vascular occlusion, and the other, an array of changes in cellular metabolism consequent to the collapse of energy-producing processes, ultimately with disintegration of cell membranes. Of potential therapeutic importance are the observations that some of the cellular processes leading to neuronal death are not irrevocable and may be reversed by early intervention, either through restoration of blood flow, by prevention of the influx of calcium into cells, or by interdicting intermediary processes involved in cell death

Vascular Factors

At the centre of an ischemic stroke is a zone of infarction. The necrotic tissue swells rapidly, mainly because of excessive intracellular and intercellular water content. Since anoxia also causes necrosis and swelling of cerebral tissue (although in a different distribution), oxygen lack must be a factor common to both infarction and anoxic encephalopathy. The effects of ischemia, whether functional and reversible or structural and irreversible, depend on its degree and duration. The margins of the infarct are hyperemic, being nourished by meningeal collaterals, and here there is only minimal or no parenchymal damage.

If the brain is observed at the time of arterial occlusion, the venous blood is first seen to darken, owing to an increase in reduced hemoglobin. The viscosity of the blood and resistance to flow both increase, and there is sludging of formed

elements within vessels. The tissue becomes pale. Arteries and arterioles become narrowed, especially in the pale areas. Upon re-establishing flow in the occluded artery, the sequence is reversed and there may be a slight hyperaemia. If the ischemia is prolonged, sludging and endothelial damage prevent normal reflow.

These flow factors have been studied in experimental animals by Heiss and by Siesjo and others and are reviewed in detail by Hossman. These investigators have determined the critical threshold of cerebral blood flow (CBF), measured by xenon clearance, below which functional impairment occurs. In several animal species, including macaque monkeys and gerbils, the critical level was 23 mL/100 g/min (normal is 55 mL); if, after short periods of time, CBF is restored to higher levels the impairment of function can be reversed. Reduction of CBF below 10 to 12 mL/100 g/min causes infarction, almost regardless of its duration. The critical level of hypoperfusion that abolishes function and leads to tissue damage is therefore a CBF between 12 and 23 mL/100 g/min. At these levels of blood flow the EEG is slowed, and below this level it becomes isoelectric. In the region of marginal perfusion (ischemic penumbra), the K level increases (efflux from injured depolarized cells) and ATP and creatine phosphate are depleted. These biochemical abnormalities are reversible if the circulation is restored to normal. Disturbance of calcium ion homeostasis and accumulation of free fatty acids interfere with full recovery. A CBF of 6 to 8 mL/100 g/min causes marked ATP depletion, increase in extracellular K, increase in intracellular Ca, and cellular acidosis, leading invariably to histologic signs of necrosis. These changes do not become apparent for several hours. Free fatty acids (appearing as phospholipases) are activated and destroy the phospholipids

of neuronal membranes. Prostaglandins, leukotrienes, and free radicals accumulate, and intracellular proteins and enzymes are denatured. Cells then swell, a process called cellular, or cytotoxic, edema. Similar abnormalities affect mitochondria, even before other cellular changes are evident.

Implicit in all discussions of ischemic stroke and its treatment is the existence of a penumbra zone that is marginally perfused and contains viable neurons. Presumably this zone exists at the margins of an infarction, which at its core has irrevocably damaged tissue that is destined to become necrotic. Using various methods, such a penumbra can be demonstrated in association with some infarctions but not all, and the degree of reversible tissue damage is difficult to determine. The neurons in the penumbra are considered to be stunned by moderate ischemia and subject to salvage if blood flow is restored in a certain period of time. As with all infarction, the duration of ischemia plays a role. Olsen and colleagues have been able to demonstrate hypoperfused penumbral zones but, interestingly, found that regions just adjacent to them are hyperperfused. Furthermore, these investigators and others have shown that elevating the systemic blood pressure or improving the rheologic flow properties of blood in small vessels by hemodilution improves flow in the penumbra; however, attempts to use these techniques in clinical work have met with mixed success.

The phenomenon of cerebrovascular autoregulation is appropriately introduced here. Over a range of mean blood pressures of approximately 50 to 150 mm Hg, the small pial vessels are able to dilate and to constrict in order to maintain CBF in a relatively narrow range. This accommodation eventually fails at the

extremes of blood pressure, after which CBF follows systemic pressure passively, either falling precipitously or rising to levels that damage small vessel walls. The conditions in which the limits of autoregulation are exceeded are at the extremes of hypertensive encephalopathy at one end and circulatory failure at the other.

Metabolic Factors

Interest has focused on the role of excitatory neurotransmitters, particularly glutamate and aspartate, which are formed from glycolytic intermediates of the Krebs cycle. It has been found that these neurotransmitters, released by ischemic cells, excite neurons and produce an intracellular influx of Na and Ca. These changes are said to be responsible for irreversible cell injury. This is presently a subject of active biochemical and clinical research. Some current attempts at therapy, for example, are directed at limiting the extent of infarction by blocking the glutamate receptor, particularly the NMDA (N-methyl-D-aspartate) channelone of several calcium channels that open under conditions of ischemia and set in motion a cascade of cellular events, eventuating in neuronal death. However, even complete blockade of the NMDA channels has so far not prevented cellular death, presumably because dysfunction of several other types of calcium channels continues. Novel strategies have been suggested to prevent calcium influx, but the drugs that block the various calcium channels seem to work only if given before the stroke, making this approach impractical in most situations. Additional biochemical events must be induced by ischemia, including the production of free radicals, which leads to peroxidation and disruption of the outer cell membrane. Clearly, the cascade of intracellular events that lead to neuronal death is likely to be more complex than is currently envisioned.

However, the extent of neural tissue dysfunction is not dictated solely by the activation of these mechanisms in neurons. It is now clear that highly toxic influences are exerted on oligodendroglial cells in white matter during ischemia. Moreover, the injury to both neurons and oligodendroglial cells is augmented in brain tissues by an inflammatory response to the initial injury, activating endothelial cells to express cell adhesion molecules that can attract additional inflammatory cells and upregulating levels of inflammatory proteases (e.g., metalloproteases) and cytokines (e.g. interleukins and chemokines). These events are summarized in the review by Lo and coworkers.

It is evident that these events are highly complex, invoking multiple parallel molecular phenomena. The salient feature of these molecular pathways is that they provide points for potential therapeutic interventions. As one example, it is clear that as ATP production fails and energy gradients are depleted, there is significant accumulation of lactic acid in cerebral tissue, and all the biochemical changes consequent to the cellular acidosis occur. These may also be of importance in determining the extent of cell damage (see reviews of Raichle and of Plum). Myers and Yamaguchi showed that monkeys infused with glucose before the induction of cardiac arrest suffered more brain damage than did either fasted or saline-infused animals. They suggested that the high cerebral glucose level under anaerobic conditions led to increased glycolysis during the ischemic episode and that the accumulated lactate was neurotoxic. On the basis of such observations, Plum has suggested that scrupulous control of the blood glucose might reduce the risk of cerebral infarction in diabetic and other stroke-prone patients and during conditions

of potential hyperglycemia. Clinical implementation of this idea is difficult and its advantages remain to be established.

Regarding anoxic damage of the brain, Ames and Nesbett have studied the rabbit retina in an immersion chamber in which O₂ and various substrates could be altered directly rather than through the vasculature. They found that cells could withstand complete absence of O₂ for 20 min. After 30 min of anoxia, there was irreversible damage, reflected by an inability of the tissue to utilize glucose and to synthesize protein. Hypoglycemia further reduced the tolerance to hypoxia, whereas the tolerance could be prolonged by reducing the energy requirements of cells (increasing magnesium in the medium). Ames postulated that the long period of tolerance of retinal neurons to complete anoxia in vitro, in comparison to that in vivo, is related to what he called the no-reflow phenomenon (swelling of capillary endothelial cells, which prevents the restoration of circulation), as mentioned earlier. Body temperature is yet another important factor in determining the extent of infarction. A reduction of even 2 to 3°C (3.6 to 5.4°F) reduces the metabolic requirements of neurons and increases their tolerance to hypoxia by 25 to 30 percent. These biochemical, cellular, and CBF findings enable one to conceptualize maneuvers for restoring blood flow within the marginally hypoperfused zone and salvaging brain tissue, particularly since under conditions of partial ischemia, cerebral tissue may survive for periods of 5 to 6 h or even longer.

THE MAJOR TYPES OF CEREBROVASCULAR DISEASE

In classifying the cerebrovascular diseases, it is most practical, from the clinical viewpoint, to preserve the classic division into thrombosis, embolism, and hemorrhage. The causes of each of the big three, along with the criteria for diagnosis and the confirmatory laboratory tests for each, are considered here in separate sections. This classification has the disadvantage of not providing for disorders such as reversible ischemia, hypertensive encephalopathy, and venous thrombosis.

The frequency of the different types of cerebrovascular disease has been difficult to ascertain. Obviously clinical diagnosis is not always correct, and clinical services are heavily weighted with acute strokes and nonfatal cases of uncertain type. An autopsy series inevitably includes many old vascular lesions, particularly infarcts, whose exact nature cannot always be determined, and there is a bias also toward large fatal lesions (usually hemorrhages). As per Harvard Cooperative Stroke Registry, tabulated in 1978 and comprising 756 successive patients, each of whom was examined by a physician knowledgeable about strokes and subjected when necessary to appropriate ancillary examinations (four-vessel arteriography, CT scan, lumbar puncture, but before the days of MRI). For comparison, we have included an autopsy series of 740 cases, examined during the year 1949 by Fisher and Adams; of these, 179 (nearly 25 percent) had some form of cerebrovascular disease. Interestingly, in both series the ratio of infarcts to hemorrhages was 4:1 and Embolism accounted for approximately one-third of all strokes. The above studies correspond reasonably well with more recent data collated in the Stroke Data Bank

of the National Institute of Neurological and Communicative Disorders and Stroke (NINCDS) (Sacco et al, 1989) and other modern series which have had the advantage of MRI.

Atherothrombotic Infarction

Most cerebrovascular disease can be attributed to atherosclerosis and chronic hypertension; until ways are found to prevent or control them, vascular disease of the brain will continue to be a major cause of morbidity. Hypertension and atherosclerosis interact in a variety of ways. Atherosclerosis, by reducing the resilience of large arteries, induces systolic hypertension. In turn, sustained hypertension worsens atherosclerosis, seemingly driving it into the walls of small branch arteries (0.5 mm or less). All the coats of the vessel become impregnated with a hyaline-lipid material, a process that Fisher has called lipohyalinosis. The segment so affected may also weaken and allow the formation of a small dissecting aneurysm (Charcot-Bouchard aneurysm), which most neuropathologists hold responsible for the hypertensive brain hemorrhage.

The atheromatous process in brain arteries is identical to that in the aorta, coronary, and other large arteries. In general the process in the cerebral arteries runs parallel to but is somewhat less severe than that in the aorta, coronary, and lower limb vessels. There are many exceptions to this rule, however, and not infrequently a brain artery becomes occluded when there is no clinical evidence of coronary or peripheral vascular disease. Although atheromatosis is known to have its onset in childhood and adolescence, only in the middle and late years of life is it likely to have clinical effects. Hypertension, hyperlipidemia, and diabetes greatly aggravate

the process. As with coronary and peripheral atherosclerosis, individuals with low blood levels of high-density-lipoprotein (HDL) cholesterol and high levels of low-density-lipoprotein (LDL) cholesterol are particularly disposed to cerebral atherosclerosis (Nubiola et al). Long-duration cigarette smoking, an important factor in the genesis of atherosclerosis, decreases both HDL cholesterol and CBF (Ingall et al). Added to these well-established risk factors is a theorized role of an excess of homocystine and an even more speculative role for chronic inflammation or and intracellular infection of uncertain origin within plaques (*Chlamydia pneumoniae* has been implicated in some studies). Clinical experience indicates that there are families with a predilection for the development of cerebral atherosclerosis, independent of these well-defined risk factors. Obesity is also a risk factor, in part because of its correlation with diabetes.

There is a tendency for atheromatous plaques to form at branchings and curves of the cerebral arteries. The most frequent sites are in the internal carotid artery, at its origin from the common carotid; in the cervical part of the vertebral arteries and at their junction to form the basilar artery; in the stem or at the main bifurcation of the middle cerebral arteries; in the posterior cerebral arteries as they wind around the midbrain; and in the anterior cerebral arteries as they pass anteriorly and curve over the corpus callosum. It is rare for the cerebral arteries to develop plaques beyond their first major branching. Also, it is unusual for the cerebellar and ophthalmic arteries to show atheromatous involvement except in conjunction with hypertension. The common carotid and vertebral arteries at their origins from the aorta are frequent sites of atheromatous deposits, but because of abundant collateral

arterial pathways, occlusions at these sites are not commonly associated with cerebral ischemia.

The atheromatous lesions develop and grow silently for 20, 30, or more years; only in the event of a thrombotic complication do they become symptomatic. Although atheromatous plaques may narrow the lumen of an artery, causing stenosis, complete occlusion is nearly always the consequence of superimposed thrombosis (atherothrombosis). In general, the more severe the atheromatosis, the more likely the thrombotic complication, but the two processes do not always run in parallel. One patient with only scattered atheromatous plaques may thrombose a vessel, whereas another with marked atherosclerosis may have only a few thrombosed vessels or none at all. Atheromatous lesions may regress to some extent under the influence of diet and certain drugs. Hennerici and colleagues followed a series of patients with carotid stenoses for a period of 18 months and observed spontaneous regression in nearly 20 percent of the lesions. In the large majority of cases, however, atherosclerosis is a progressive disease.

Degeneration of the wall of a sclerotic vessel or hemorrhage into the wall (from rupture of the vasa vasorum) may damage the endothelium. This is known to occur particularly in the walls of the internal carotid arteries (and the coronary arteries, where it is a main cause of vessel occlusion). The lesion in the atheromatous plaque apparently excites an inflammatory reaction. Platelets and fibrin then adhere to the damaged part of the wall and form delicate, friable clots, or a subintimal atheromatous deposit may slough, spewing crystalline cholesterol Emboli into the lumen with resulting occlusion of small distal vessels. In contrast to an Embolus, a

thrombus generally does not occlude the lumen completely from the first moment of its formation; total blockage may occur only after several hours. Once the lumen of the artery has been completely occluded, the thrombus may propagate distally and proximally to the next branching points and block an anastomotic channel.

These several dynamic events in the atherosclerotic-thrombotic process probably account for the prodromal ischemic attacks described below intermittent blockage of the circulation and variable impairment of function in the vascular territory, before proceeding to permanent ischemia. Not infrequently, several arteries are affected by stenosis and thrombosis over a period of months or years. Then it becomes difficult to decipher the interplay of factors that have led to either transitory or persistent symptoms. Some of the possibilities have been outlined by Adams and colleagues (1961). The evolution of the thrombotic process may be sufficiently prolonged to explain the clinical state known as stroke in evolution; when the hemodynamic disturbance stabilizes, the stage of completed stroke is reached. These different stages acquire significance in relation to therapy and prognosis.

Treatment of Atherothrombotic Infarction and Transient Ischemic Attacks

The main objective in these forms of cerebrovascular disease is the prevention of stroke. Ideally this should be accomplished by finding patients in the asymptomatic stage of atherosclerosis. However, the medical profession has no efficient means of screening large populations at risk of developing stroke and only limited methods for altering the progression of the atherosclerotic process, even if discovered in its early stages. The widespread use of cholesterol-lowering statin medications has been shown to reduce the incidence of stroke and will probably be more widely prescribed to normal older adults. For all practical purposes, treatment is directed to patients who have already begun to have symptoms, either TIAs or ischemic lesions that are reversible to some extent.

The current treatment of atherothrombotic disease may be divided into four parts: (1) management in the acute phase, (2) measures to restore the circulation and arrest the pathologic process, (3) physical therapy and rehabilitation, and (4) measures to prevent further strokes and progression of vascular disease.

Management in the Acute Phase

The relative advantages of placing the seriously ill acute stroke patient in a neurologic special care or stroke unit have been the subject of many articles. It is our impression that the outcome in terms of morbidity and mortality in the seriously ill stroke patients improved, though admittedly this is difficult to document (for details, see Ropper and also Brott and Reed). Like the well-organized coronary care unit, stroke units have the capability of expediting the evaluation and early rehabilitation of these patients. As already emphasized, the prevention of aspiration and of

pneumonia are paramount, and probably avoidable. Also deserving attention are the prevention of venous thrombosis in the legs, pulmonary embolism, and coronary syndromes. Patients with impaired consciousness require special care of skin, eyes, mouth, bladder, and bowel. These measures are best provided in a unit with trained clinical staff and the technology to monitor blood pressure, pulmonary function, blood gases, and, when appropriate, intracranial pressure .

Measures to Restore the Circulation and Arrest the Pathologic Process

Once a thrombotic stroke has developed fully (i.e., the completed stroke), none of the therapeutic measures so far devised has proved to be consistently effective in restoring the damaged cerebral tissue to a functional state. The influence of anticoagulants and thrombolysis at an early stage of stroke are discussed below. One's efforts must be directed to making a diagnosis of thrombosis at the earliest possible stage and circumventing the full catastrophe by all means available without risking the safety of the patient. Even when the symptoms and signs have become persistent, it is conceivable that some of the affected tissue, particularly at the edges of the infarct, has not been irreversibly damaged and will survive if perfusion can be re-established. On the assumption that cerebral perfusion might be diminished by assuming the upright position, it is probably advisable for patients with a major stroke to remain nearly horizontal in bed for the first day. When sitting and walking begin, special attention should be given to maintenance of normal blood pressure (patients should avoid standing quietly or sitting with the feet down for prolonged periods, etc.).

Several studies have confirmed the prevalence of new or exaggerated hypertension following an ischemic stroke and its tendency to decline within days even without medications. The treatment of previously unappreciated hypertension is preferably deferred until the neurologic deficit has stabilized. We agree with Britton and colleagues that it is prudent to avoid antihypertensive drugs in the first few days unless there is active myocardial ischemia or the blood pressure is high enough to pose a risk to other organs, particularly the kidneys, or there is a special risk of cerebral hemorrhage as a result of the use of thrombolytic drugs.

Thrombolytic Agents

Tissue plasminogen activators (recombinant t-PA and streptokinase), when administered intravenously, convert plasminogen to plasmin, the latter being a proteolytic enzyme capable of hydrolyzing fibrin, fibrinogen, and other clotting proteins. These drugs are effective in the treatment of coronary artery occlusion (but are associated with a 1 percent risk of cerebral hemorrhage), and they also have now been shown to have a role in the treatment of stroke.

The multicenter study organized by the National Institute of Neurological and Communicative Disorders and Stroke (see the NINCDS and Stroke rt-PA Stroke Study Group in the References) has provided evidence of benefit from intravenous t-PA. Treatment within 3 h of the onset of symptoms led to a 30 percent increase in the number of patients who remained with little or no neurologic deficit when re-examined 3 months after the stroke and when assessed 1 year later in the study by Kwiatkowski et al. It is not easy to comprehend why the benefits apparently extended to all types of ischemic stroke, including those due to occlusion of small

vessels (lacunes), and why improvement was not at all apparent in the days immediately following treatment, only much later. The t-PA was administered in a dose of 0.9 mg/kg, 10 percent of which was given as an initial bolus, followed by an infusion of the remainder over 1 h. A dose of 90 mg was not exceeded, this being lower than the dose used for myocardial infarction. The relative improvement in neurologic state came at the expense of a 6 percent risk of symptomatic cerebral hemorrhage, i.e., a far lower rate than in most previous studies (some of the hemorrhages were into the area of infarction without causing symptomatic worsening). Patients with massive infarcts (ones that encompassed more than two-thirds of the territory of the middle cerebral artery) or with high scores on a clinical stroke scale devised for the National Institutes of Health (NIH) study or with uncontrolled hypertension or who were more than 80 years of age or who had recently received anticoagulants (except aspirin) were excluded from this study. Further analysis of the NINCDS trial has revealed that patients who were treated earlier within the 3-h time frame had more benefit than those treated later; indeed, the administration of t-PA in the time period between 2.5 and 3 h after the stroke was of little value.

Comparable data from the randomized European Cooperative Acute Stroke Study (ECASS; see Hacke et al), which included 620 patients, identified two situations in which t-PA administered intravenously within 6 h, at a slightly higher dose than in the above trial (1.1 mg/kg, to a maximum of 100 mg), led to an improved neurologic outcome, but the overall results of this trial were considered

to be unfavorable largely because of a high rate of cerebral hemorrhage. In a second trial (ECASS II) in 800 patients, using the same dose as in the NINCDS-sponsored trial but giving the thrombolytic drug up to 6 h after the stroke, no benefit could be confirmed and the rate of symptomatic hemorrhage was 8.8 percent (compared with 3.4 percent in untreated patients). Yet a subgroup of patients with carotid middle cerebral artery strokes of moderate severity specifically those with moderate-sized infarcts from occlusion of vessels distal to the carotid artery and adequate collateral circulation through surface vessels did appear to benefit. In some patients with basilar artery occlusion with coma of only brief duration and those without extensive thrombosis, prompt t-PA treatment also resulted in an overall improvement in neurologic function, but there were numerous exceptions.

In all these trials, patients with large cerebral infarctions had poor outcomes and suffered a high incidence of cerebral hemorrhage. It has been concluded, therefore, that the presence of blood in the first CT scan and evidence of extensive infarction, occupying most of the MCA territory, precludes this mode of therapy. In two similar trials conducted by the European MAST-I groups (see the Multicentre Acute Stroke Trial in References), using streptokinase within 6 h of stroke, there was actually an adverse outcome in the treated group having an excess of early deaths; this trial had a 21 percent incidence of symptomatic cerebral hemorrhage and an 18 percent incidence of hemorrhagic infarctions.

At the present time the use of intravenous t-PA therapy can be advocated only in patients who arrive in the Emergency department and can be fully evaluated within 3 h of the onset of a stroke, preferably even earlier (thus excluding those who

awaken from a night's sleep with the symptoms) and have no hemorrhage on the CT scan. Generally also excluded are those in whom the deficit is either very small (e.g., hand affected only, dysarthria alone, minor aphasia) or, more importantly, so large as to implicate the entire territory of the middle cerebral artery. Although seemingly a promising approach to acute stroke, the use of acute thrombolytic therapy depends on the very early identification of a restricted group of patients; therefore this therapy is applicable to only a limited proportion of stroke patients who present to the Emergency department (approximately 5 percent) or those who have strokes while under observation in the hospital. It is noteworthy that attempts to reproduce the beneficial effects of t-PA in a community setting have been disappointing largely because of deviations from treatment guidelines and an excess number of hemorrhages (Katzan et al). Nonetheless, acute intravenous thrombolysis that is managed closely by experienced individuals using validated protocols is a compelling treatment at the moment for acute ischemic stroke. Public health education should increase the numbers of stroke patients who seek early attention and thus raise the proportion who are eligible for t-PA treatment.

Thrombolytics injected intra-arterially can in some instances dissolve occlusions of the middle cerebral and basilar arteries and, if administered within hours, reduce the neurologic deficit. However, the routine intra-arterial injection of thrombolytics into infarcted tissue has produced a high incidence of cerebral hemorrhage, approaching 20 percent in some studies and leaving the overall morbidity about the same in treated and untreated patients. There is also a high incidence of reocclusion of the treated vessel. The exception, in our limited experience, has been basilar artery

thrombosis without cerebellar infarctions, where large neurologic deficits are at times reversed with fewer complications. Treatment even several hours after the first symptoms may stop progression, but the lack of a systematic study of this approach makes it difficult to endorse without reservation. Mechanical lysis of an intra-arterial clot may be as effective.

Causes of cerebral Embolism

1. Cardiac origin

- a.* Atrial fibrillation and other arrhythmias (with rheumatic, atherosclerotic, hypertensive, congenital, or syphilitic heart disease)
- b.* Myocardial infarction with mural thrombus
- c.* Acute and subacute bacterial endocarditis
- d.* Heart disease without arrhythmia or mural thrombus (mitral stenosis, myocarditis, etc.)
- e.* Complications of cardiac surgery
- f.* Valve prostheses
- g.* Nonbacterial thrombotic (marantic) endocardial vegetations
- h.* Prolapsed mitral valve
- i.* Paradoxical Embolism with congenital heart disease (e.g., patent foramen ovale)
- j.* Myxoma

2. Noncardiac origin

- a.* Atherosclerosis of aorta and carotid arteries (mural thrombus, atheromatous material)
- b.* From sites of dissection and/or fibromuscular dysplasia of carotid and

vertebrobasilar arteries

c. Thrombus in pulmonary veins

d. Fat, tumor, or air

e. Complications of neck and thoracic surgery

f. Pelvic and lower extremity venous thrombosis in presence of right-to-left cardiac shunt

3. Undetermined origin

Another source of Embolism is the carotid or vertebral artery, where clot forming on an ulcerated atheromatous plaque may be detached and carried to an intracranial branch (artery-to-artery Embolism). A similar phenomenon may occur with arterial dissections and sometimes with fibromuscular disease of the carotid or vertebral arteries.

Atheromatous plaques in the ascending aorta have been recognized in the last decades to be a more frequent source of Embolism than had been appreciated. Amarengo and colleagues reported that as many as 38 percent of a group of patients with no discernible cause for embolic stroke had echogenic atherosclerotic plaques in the aortic arch that were greater than 4 mm in thickness, a size thought to be associated on a statistical basis with strokes. Disseminated cholesterol emboli are known to occur in the cerebral circulation and may be dispersed in other organs as well; rarely, this is sufficiently severe to cause an encephalopathy and pleocytosis in the spinal fluid.

Paradoxical embolism can occur when an abnormal communication exists between the right and left sides of the heart (particularly a patent foramen ovale, or PFO) or when

both ventricles communicate with the aorta; thus embolic material arising in the veins of the lower extremities or pelvis or elsewhere in the systemic venous circulation can bypass the pulmonary circulation and reach the cerebral vessels. Pulmonary hypertension (often from previous pulmonary embolism) favours the occurrence of paradoxical embolism, but this may occur with a PFO even in the absence of pulmonary hypertension. Of 30 patients in whom a PFO could be demonstrated, 17 had evidence of a right-to-left shunt; brain infarction was associated with positive phlebography of the legs and abnormal pulmonary scintigraphy (Itoh et al). Several studies indicated that the presence of a small atrial septal aneurysm adjacent to the patent foramen increases the likelihood of stroke. In the series of Mas and colleagues, patients ages 18 to 55 who had a stroke were followed for 4 years; the risk of second stroke was 2 percent in those with a PFO alone and 15 percent among those with both a PFO and an atrial septal aneurysm (curiously, the risk among those with neither congenital abnormality was 4 percent higher than for PFO). This mechanism comes into play mainly in considering the causes of stroke in the younger patient. Subendocardial fibroelastosis, idiopathic myocardial hypertrophy, cardiac myxomas, and cardiac lesions of trichinosis are rare causes of Embolism.

The vegetations of acute and subacute bacterial endocarditis give rise to several different lesions in the brain (page 606). Mycotic aneurysm is a rare complication of septic Embolism and may be a source of intracerebral or subarachnoid hemorrhage. Marantic or nonbacterial thrombotic endocarditis is a frequently overlooked cause of cerebral Embolism; at times it produces a baffling clinical picture, especially when

associated, as it often is, with carcinomatosis, cachexia from any cause, or lupus erythematosus.

Mitral valve prolapse may be a source of emboli, especially in young patients, but its importance has probably been overestimated. The initial impetus for considering this abnormality as a source of embolus came from the study of Barnett and colleagues of a group of 60 patients who had TIAs or partial strokes and were under 45 years of age; prolapse was detected (by echocardiography and a characteristic midsystolic click) in 24 patients but in only 5 of 60 age-matched controls. However, in several subsequent large studies (Sandok and Giuliani and Jones et al), only a very small proportion of strokes in young patients could be attributed to prolapse; even then, the connection was only inferred by the exclusion of other causes of stroke. Indeed, in a recent study using stringent criteria for the echocardiographic diagnosis of prolapse, Gilon and colleagues could not establish any relation to stroke. Rice and colleagues have described a family with premature stroke in association with valve prolapse and a similar relationship has been reported in twins; the same may occur in Ehlers-Danlos disease.

The pulmonary veins are a potential if infrequent source of cerebral emboli, as indicated by the occurrence of cerebral abscesses in association with pulmonary suppurative disease and by the high incidence of cerebral deposits secondary to pulmonary carcinoma. In Osler-Weber-Rendu disease, pulmonary shunts serve as a conduit for emboli. As remarked above, surgery of the neck and thorax can be complicated by cerebral embolism. A rare type is that which follows thyroidectomy, where thrombosis in the stump of the superior thyroid artery extends proximally until

a section of the clot, protruding into the lumen of the carotid, is carried into the cerebral arteries.

During cerebral arteriography, emboli may arise from the tip of the catheter, or manipulation of the catheter may dislodge atheromatous material from the aorta or carotid or vertebral arteries and account for some of the accidents during this procedure. Transcranial Doppler has suggested that small emboli frequently arise during these procedures; a study by Bendszus and colleagues found that 23 of 100 consecutive patients had new cortical lesions shown on diffusion-weighted MRI just after cerebral arteriography. However, none of these were symptomatic and with good technique, emboli from vascular catheters are infrequent.

Cerebral Embolism must always have occurred when secondary tumour is deposited in the brain, and cerebral embolism regularly accompanies septicaemia, but a mass of tumour cells or bacteria is seldom large enough to occlude a cerebral artery and produce the picture of stroke. Nevertheless, tumour embolism with stroke has been reported from cardiac myxomas and occasionally with other tumours. It must be distinguished from embolism due to marantic endocarditis that complicates malignant neoplasms (nonbacterial thrombotic endocarditis, discussed further on). Cerebral fat embolism is related to severe bone trauma. As a rule, the Emboli are minute and widely dispersed, giving rise first to pulmonary symptoms and then to multiple dermal (anterior axillary fold and elsewhere) and cerebral petechial hemorrhages. Accordingly, the clinical picture is more of an encephalopathy and not strictly focal, as it is in a stroke, although in some instances it may have focal features. Cerebral air embolism is a rare complication of abortion, scuba diving, or

cranial, cervical, or thoracic operations involving large venous sinuses; it was formerly encountered as a complication of pneumothorax therapy. Clinically, this condition may be difficult to separate from the deficits following hypotension or hypoxia, which frequently coexist. Hyperbaric treatment may be effective if instituted early.

Despite the large number of established sources of emboli, the point of origin cannot be determined in about 30 percent of presumed embolic infarctions. In such cases, emboli may have originated from thrombi in the cardiac chambers but have left behind no residual clot and may be undetectable by even sophisticated methods such as trans-esophageal echocardiography and newer MR techniques. Others may be due to atheromatous material arising from the aorta. If extensive evaluation fails to disclose the origin, the odds still favour a source in the left heart. Not infrequently the diagnosis of cerebral embolism is made at autopsy without finding a source. The search for a thrombotic nidus may not have been sufficiently thorough in these cases, and small thrombi in the atrial appendage, endocardium (between the papillary muscles of the heart), the aorta and its branches, or pulmonary veins may have been overlooked. Nevertheless, in some cases, even when studied carefully postmortem, no source of embolic material can be discovered.

LESS COMMON CAUSES OF OCCLUSIVE CEREBROVASCULAR DISEASE

Fibromuscular Dysplasia

This is a segmental, nonatheromatous, noninflammatory arterial disease of unknown etiology. It is uncommon (0.5 percent of 61,000 arteriograms in the series of So et al), but it is being reported with increasing frequency because of improved

arteriographic techniques. In our experience, it has often been an incidental finding in asymptomatic individuals undergoing aortic angiography.

First described in the renal artery by Leadbetter and Burkland in 1938, fibromuscular dysplasia is now known to affect other vessels, including cervicocerebral ones. The internal carotid artery is involved most frequently, followed by the vertebral and cerebral arteries. The radiologic picture consists of a series of transverse constrictions, giving the appearance of an irregular string of beads or a tubular narrowing; it is observed bilaterally in 75 percent of cases. Usually only the extracranial part of the artery is involved. In the series of Houser and colleagues, 42 of 44 patients were women, and 75 percent were over 50 years of age. All of the patients reported by So and coworkers were women, ranging in age from 41 to 70 years. Cerebral ischemia may be associated with the process but the rate of this complication has not been established. Our impression is that it is low. Among 79 untreated asymptomatic patients followed for an average of 5 years, 3 had a cerebral infarct 4 to 18 years after the initial diagnosis in the study by Corrin et al. Also, between 7 and 20 percent of affected individuals are found to have intracranial saccular aneurysms (rarely a giant aneurysm), which may be a source of subarachnoid hemorrhage, and 12 percent develop arterial dissections, as described below.

The pathology of this disease has been summarized by Schievink and colleagues. The narrowed arterial segments show degeneration of elastic tissue and irregular arrays of fibrous and smooth muscle tissue in a mucous ground substance. Dilatations are due to atrophy of the coat of the vessel wall. There is atherosclerosis

in some and arterial dissection in others. Usually vascular occlusion is not present, though there may be marked stenosis. In some instances the mechanism of the cerebral ischemic lesion is unexplained. Possibly thrombi form in the pouches or in relation to intraluminal septa.

So and colleagues have recommended excision of the affected segments of the carotid artery if the neurologic symptoms are related to them and conservative therapy if the fibromuscular dysplasia is an incidental arteriographic finding in an asymptomatic patient. It is now possible to dilate the affected vessel by means of endovascular techniques, and several case reports have suggested that benefit is achieved at lower risk in this way than with surgical excision. Associated intracranial saccular aneurysms should be sought by arteriography or magnetic resonance angiography and surgically obliterated if their size warrants it (page 722). It is not known if anticoagulation or antiplatelet therapy confer protection from stroke.

Dissection of the Cervical and Intracranial Vessels

Internal Carotid Artery Dissection

It has long been appreciated that the process formerly known as Erdheim's medionecrosis aortica cystica, the main cause of aortic dissection, may extend into the common carotid arteries, occluding them and causing massive infarction of the cerebral hemispheres. Examples of such an occurrence were cited by Weisman and Adams in 1944 in their study of the neurology of dissecting aneurysms of the aorta. In more recent years, attention has been drawn to the occurrence of spontaneous dissection of the internal carotid artery and the fact that it is an important cause of

hemiplegia in young adults. Several large series of such cases have been reported in separate studies by Ojemann, Mokri, and Bogousslavsky and their colleagues.

Traumatic or apparently spontaneous carotid dissection is a not uncommon cause of stroke, particularly in younger individuals. Bogousslavsky and colleagues found 30 instances (comprising both genders) in 1200 consecutive patients with a first stroke (2.5 percent). It should be suspected in young adult women (typically in their late thirties or early forties), who seem especially susceptible to the condition, either as a spontaneous event or in relation to a whiplash injury, bouts of violent coughing, or direct trauma to the head or neck, which need not be severe e.g., being struck in the neck by a golf or tennis ball. We have also encountered cases that occurred during pregnancy and immediately after delivery. Indeed, it is questionable if many cervical arterial dissections are truly spontaneous, since most can be connected to some strenuous event. Three of our patients over the years had a carotid dissection that was manifest as a hemiplegia days after blunt head injury. A small number of patients have fibromuscular disease, as discussed above; the Ehlers-Danlos and Marfan syndromes, osteogenesis imperfecta, and alpha-1-antitrypsin deficiency are also associated with an increased risk of vascular dissection. One of these conditions should be suspected if multiple extracranial vessels are involved in spontaneous dissections (neck and thoracic trauma are more common causes of this configuration).

It is of interest that a few patients with carotid dissection have had warning attacks of unilateral cranial or facial pain, followed, within minutes to days, by signs of ischemia in the territory of the internal carotid artery. The pain is nonthrobbing

and centered most often in and around the eye; less often, it is in the frontal or temporal regions, angle of the mandible, or high anterior neck over the carotid artery. Rapid and marked relief of the pain after the administration of corticosteroids is virtually a diagnostic feature (see below). The ischemic manifestations consist of transient attacks in the territory of the internal carotid, followed frequently by the signs of hemispherical stroke, which may evolve smoothly over a period of a few minutes to hours or over several days in a fluctuating or stepwise fashion. A unilateral Horner syndrome is often present. Cervical bruits sometimes audible to the patient, amaurosis fugax, faintness and syncope, and facial numbness are less common symptoms. Most of the patients described by Mokri and coworkers presented with one of two distinct syndromes: (1) unilateral headache associated with an ipsilateral Horner syndrome or (2) unilateral headache and delayed focal cerebral ischemic symptoms. Some patients have evidence of involvement of the vagus, spinal accessory, or hypoglossal nerve; these nerves lie in close proximity to the carotid artery and are nourished by small branches from it.

In most cases, dissection of the internal carotid artery can be detected by ultrasound and confirmed by MRI, which shows a double lumen, and by MRA. These procedures may obviate the need for arteriography. The latter procedure reveals an elongated, irregular, narrow column of dye, usually beginning 1.5 to 3 cm above the carotid bifurcation and extending to the base of the skull, a picture that Fisher has called the string sign. There may be a tapered occlusion or an outpouching at the upper end of the string. Less often the dissection is confined to the midcervical

region, and occasionally it extends into the middle cerebral artery or involves the opposite carotid artery or the vertebral and basilar arteries.

The extensive study by Mokri and colleagues showed that a complete or excellent recovery occurred in 85 percent of patients with the angiographic signs of dissection; mainly, these were patients without stroke. The outcome in cases complicated by stroke is far less benign. About one-quarter of such patients succumb and one-half of the survivors remain seriously impaired (Bogousslavsky et al). In the remainder, early recanalization of the occluded artery can be observed (as determined by ultrasonography), with good functional recovery. Pseudoaneurysms form in a small proportion of patients and generally do not require surgical repair; they also do not preclude cautious anticoagulation.

The pathogenesis of spontaneous carotid dissection is at present uncertain. In most of the recently reported cases, cystic medial necrosis has not been found on microscopic examination of the involved artery. In some, there was a disorganization of the media and internal elastic lamina, but the specificity of these changes is in doubt, since Ojemann and colleagues noted similar changes in some of their control cases. In a small proportion of cases there are the changes of fibromuscular dysplasia, as noted earlier. A more thorough study of these vessels in routine autopsy material is needed.

Treatment

The treatment has usually been immediate anticoagulation to prevent embolism using first heparin, then warfarin but it must be acknowledged that this approach has not been demonstrated to be more successful than careful observation. Once a stroke has

occurred, even though Ebolic in most cases, prompt reopening of the artery can at times prove beneficial; this is currently performed by endovascular techniques. Despite numerous publications demonstrating the ability of skilled operators to reopen a dissection by endovascular methods, acute intervention has not been studied in a way that allows a judgment regarding its value. Whether stent placement is additionally beneficial has also not been determined. Interesting, and of both therapeutic and diagnostic value, is the relief of pain afforded by corticosteroids in cervical and intracranial dissections, as mentioned above. Most neurologists take the approach that warfarin, if used, may be discontinued after several months or a year, when angiography or MRA shows the lumen of the carotid artery to be patent, or at least reduced to no more than 50 percent of the normal diameter, and smooth-walled.

Familial Subcortical Infarction (CADASIL)

A process similar to Binswanger leukoencephalopathy, but without hypertension, has been identified as an autosomal dominant familial trait linked in several families to a mutation on chromosome 19. It had been described previously under a number of names, including hereditary multi-infarct dementia. The acronym CADASIL (cerebral autosomal dominant arteriopathy with subcortical infarcts and leukoencephalopathy) is now applied. In these patients, recurrent small strokes, often beginning in early adulthood, culminate in a subcortical dementia. Migraine headaches, often with neurologic accompaniments, may precede the strokes by several years, as may numerous and varied TIAs that are attributed, probably incorrectly, to the migraine. Some individuals display few clinical changes; others are demented or have strokes that simulate lacunes. We are unable to comment on

the encephalopathy and coma, in some cases accompanied by fever, described by Schon and colleagues. It seems to represent another very rare condition.

The familial nature of the process may not be appreciated because genetic penetrance is not complete until after 60 years of age. On MRI scans, clinically unaffected family members may show substantial changes in the white matter well before strokes or dementia arises. In some cases, particularly in Japan, early alopecia and lumbar spondylosis have been associated with CADASIL.

The MRI and CT appearance of multiple confluent white matter lesions of various sizes, many quite small and concentrated around the basal ganglia and periventricular areas, is similar to that in Binswanger disease. When these are asymmetrical and periventricular, they are difficult to distinguish from the lesions of multiple sclerosis. In the autopsy cases studied by Jung and colleagues, numerous partially cavitated infarctions were found in the white matter and basal ganglia. In the regions of these infarctions were small vessels, 100 to 200 μ m diameter, in which the media contained basophilic granular deposits with degeneration of the smooth muscle fibers. Attribution of the white matter degeneration to these vascular changes presents the same problems as in Binswanger disease, particularly in view of patency of most of the many small vessels in the material. Again, the relation of the vascular changes to lesions in the brain has not been studied in serial sections. Nevertheless, CADASIL is probably the main cause of sporadic instances of what otherwise passes for Binswanger disease but without the obligate hypertension of the latter. Also, migraine headaches are not a component of Binswanger disease.

The responsible mutation on chromosome 19 of the Notch 3 gene, in the same locus as the gene for familial hemiplegic migraine, has been characterized by Joutel and colleagues; this provides a diagnostic test that can be performed on the blood or skin. However, the mechanism by which this leads to the vasculopathy or white matter changes is not clear. The diagnosis can also be confirmed by finding eosinophilic inclusions in the arterioles of a skin biopsy (osmophilic with electron microscopy). Awareness of this apparently vascular form of white matter degeneration adds to the list of inherited leukoencephalopathies, the others being inherited metabolic disturbances.

Amyloid Angiopathy

This process is discussed further on in relation to lobar cerebral hemorrhages in the elderly. The angiopathy consists of the deposition of amyloid in the media and adventitia of small vessels, predominantly in the meninges, cortex, and cortical penetrating vessels. The incidence at autopsy of vascular amyloid deposition in the brain is related to the age of the population studied; rates of 12 percent are cited in patients above 85 years of age (the same changes are present in over 25 percent of individuals with Alzheimer disease, but the nature of the amyloid is different in the two conditions). Over the last few years, however, our colleague Greenberg has emphasized certain clinical features associated solely with cerebrovascular amyloidosis. Of interest here are multiple TIAs, some with migrainous features such as spreading sensory symptoms, and fairly rapid progression to dementia. Telltale signs of small hemorrhages that are more characteristic of diffuse cerebrovascular amyloid are often present in these cases. These old hemorrhages are seen to

advantage with gradient echo sequences on the MRI. The frequency of this interesting condition in the elderly is unclear. There is a separate familial amyloidotic condition of diffuse white matter degeneration with dementia, associated in some families with calcification in the occipital lobes.

Strokes in Children and Young Adults

it is probable that ischemic necrosis of cerebral tissue can occur in utero. The resulting stroke is usually referred to as congenital hemiplegia. However, very little is known about the underlying vascular lesions, so that nothing further can be said about them here.

The occurrence of acute hemiplegia in infants and children is a well-recognized phenomenon. In a series of 555 consecutive postmortem examinations at the Children's Medical Centre in Boston, there were 48 cases (8.7 percent) of occlusive vascular disease of the brain (Banker). The occlusions were both embolic (mainly associated with congenital heart disease) and thrombotic, and the latter were actually more common in veins than in arteries. Similarly, stroke is not an uncommon event in young adults (15 to 45 years). This group accounts for an estimated 3 percent of cerebral infarctions. In terms of causation, this group is remarkably heterogeneous. In a series of 144 such patients, more than 40 possible etiologies were identified (H. P. Adams et al). Nevertheless, 78 percent of the group could be accounted for by three categories, more or less equal in size: atherosclerotic thrombotic infarction (usually with a recognized risk factor); cardiogenic Embolism (particularly in association with rheumatic heart disease, bacterial and verrucous endocarditis, paradoxical Embolism through patent foramen ovale, and prosthetic valves); and

nonatherosclerotic vasculopathies (arterial trauma, dissection of the carotid artery, moyamoya, lupus erythematosus, drug-induced, vasculitis). Hematologically related disorders, use of oral contraceptives, the postpartum state, and hypercoagulable states were the probable causes in 15 percent of the 144 patients. The presence of antiphospholipid or anticardiolipin antibodies (lupus anticoagulant) appears to explain some of these cases and is discussed further under Stroke as a Complication of Haematologic Disease; the majority of these patients are women in their thirties without manifesting systemic lupus erythematosus.

Despite the attention they have received as a cause of strokes in the juvenile period, the frequency of thrombophilic disorders due to inherited deficiencies of naturally occurring anticoagulant factors is low. They predispose primarily to cerebral venous clotting. Most arise from partial protein deficiencies due to heterozygous mutations in the genes encoding proteins that are important factors in the clotting cascade (antithrombin III, proteins S and C) and those due to disturbances of clotting balance (resistance to activated protein C, or factor V Leiden mutation, and prothrombin mutations as well as excess factor VIII) (see discussion by Brown and Bevan). However, when they are homozygous, these mutations may be associated with devastating neonatal hemorrhagic conditions. In some series that report cases of strokes in youth, such that of Becker and colleagues, up to half of the cases had one of these disorders, the commonest being the factor V Leiden mutation, but others have found this mutation to be much less frequent, and that is consonant with our experience. Nevertheless, in children with unexplained stroke, particularly venous and especially if there has been a previous thrombosis or if the strokes are recurrent,

it is advisable to carry out an extensive hematologic investigation, especially including testing for antiphospholipid antibody (an acquired defect), as described on page 735. Establishing a diagnosis of a prothrombotic clotting gene variant has therapeutic significance, since strokes are prone to occur in the setting of such additional risks as the use of oral contraceptives or smoking. In adults, the evaluation for inherited clotting defects is far less fruitful. Furthermore, it should be kept in mind that the levels of proteins C and S and of antithrombin are temporarily depressed after stroke, so that any detected abnormalities must be confirmed months later.

Stroke associated with genetic disorders

	GENE	INHERITANCE	STRUCTURES AFFECTED	GENERAL POPULATION (%)	WITH CEREBRAL THROMBOSIS (%)
Causes of arterial or venous infarction					
Activated protein C resistance	Leiden factor V mutation	AR	v	2-15	5-20
Prothrombin 20210	Prothrombin	AR	v	0.1	1-5
Protein C deficiency	Protein C gene	AR	v	0.2-0.4	3-6
Protein S deficiency	Protein S gene	AR	v	0.03-0.13	1-5
Increased Factor VIII	von Willebrand factor deficiency	AR	v	10	25
Antithrombin III deficiency	Antithrombin III	AR	v	Rare	3-8
Plasminogen deficiency	Plasminogen activator-1	AR	v		
Lipoprotein (a)	Apolipoprotein (a)	AR	v		
Marfan syndrome	Fibrillin 1		v,h,ao	0.03	
Fabry disease	Alpha-galactosidase	AR	v		
Sickle cell syndrome	Globin genes		v,a		
Heparin cofactor II	Heparin cofactor II	AR	v	Rare	? 5
Platelet collagen receptor	Platelet collagen receptor	AR	v		
Factor XII	Factor XII	AR	v		

Phosphodiesterase 4D	Phosphodiesterase 4D	Complex	a		
CADASIL	Notch 3	AD	a		
Hyperhomocysteinemia	Methylene tetrahydrofolate reductase	AR	a	Rare	20 in young
Homocysteinemia	Cystathione beta-synthase	AR	a		
Homocysteinemia	Homocysteine methyl transferase	AR	a		
Ehlers Danlos disease			a		
MELAS (mitochondrial):	mtDNA	Maternal			
Causes of cerebral hemorrhage associated with congenital diseases					
von Hippel-Lindau (Chap. 31)	pVHL	AD	hemorrhage		
Cavernous malformations	Cerebral cavernous malformations (CCM1)	AD			
Cerebral amyloidosis	Apolipoprotein E4	Complex			
Cerebral hemorrhage with amyloidosis					
Dutch type	Amyloid precursor protein	AD			
Icelandic type	Cystatin C	AD			
Hereditary hemorrhagic telangiectasia	Endoglin	AD			
Hereditary hemorrhagic telangiectasia	Activin receptor-like kinase (ALK-1)	AD			
Polycystic kidney disease	Polycystin 1, 2	AD			
Key: AD, autosomal dominant; AR, autosomal recessive; v, venous; a, arterial; ao, aorta; h, heart.					

Persistent cerebral ischemia and infarction may occasionally complicate migraine in young persons. The combination of migraine and the Pill is particularly hazardous, as detailed below. Similarly, despite the common occurrence of mitral valve prolapse in young adults, it is probably only rarely a cause of stroke. Stroke due to either arterial or venous occlusion occurs occasionally in association with ulcerative colitis and to a lesser extent with regional enteritis. Evidence points to a

hypercoagulable state during exacerbations of inflammatory bowel disease, but a precise defect in coagulation has not been identified. Meningovascular syphilis and fungal and tuberculous meningitis and other forms of chronic basal meningitis are considerations in this age group; the strokes are usually of the cavitory lacunar type, resulting from infectious-inflammatory occlusion of small basal vessels.

INTRACRANIAL HEMORRHAGE

This is the third most frequent cause of stroke. Although more than a dozen causes of non traumatic intracranial haemorrhage, primary or hypertensive spontaneous intracerebral hemorrhage, ruptured saccular aneurysm and vascular malformation, and hemorrhage associated with the use of anticoagulants or thrombolytic agents account for the majority. Cerebrovascular amyloidosis and bleeding disorders account for a small number. The small brainstem hemorrhages secondary to temporal lobe herniation and brainstem compression (Duret hemorrhages), hypertensive encephalopathy, and brain purpura might be included in this group, but they do not simulate a stroke.

Causes of intracranial hemorrhage (including intracerebral, subarachnoid, ventricular, and subdural)

1. Primary (hypertensive) intracerebral haemorrhage
2. Ruptured saccular aneurysm
3. Ruptured AVM; less often, venous and dural vascular malformations
4. Cavernous angioma
5. Trauma including posttraumatic delayed apoplexy
6. Haemorrhagic disorders: leukaemia, aplastic anemia, thrombocytopenic purpura,

liver disease, complication of anticoagulant or thrombolytic therapy, hypofibrinogenemia, hemophilia, Christmas disease, etc.

7. Haemorrhage into primary and secondary brain tumors
8. Septic Embolism, mycotic aneurysm
9. With hemorrhagic infarction, arterial or venous
10. With inflammatory and infectious disease of the arteries and veins
11. With arterial amyloidosis
12. Miscellaneous rare types: vasopressor drugs, cocaine, moyo moyo, herpes simplex encephalitis, vertebral artery dissection, acute necrotizing hemorrhagic encephalitis (Hurst disease), tularemia, anthrax, etc.

Primary (Hypertensive) Intracerebral Haemorrhage

This is the mundane spontaneous brain hemorrhage. It is due predominantly to chronic hypertension and degenerative changes in cerebral arteries. In recent decades, with increased awareness of the need to control blood pressure, the proportion of hemorrhages attributable to causes other than hypertension has greatly increased; more than half such hemorrhages on our services now occur in normotensive individuals, and the hemorrhages more often than previously arise in locations that are not typical for hypertension. Nevertheless, the hypertensive cerebral hemorrhage serves as a paradigm for understanding and managing the cerebral hemorrhage.

In order of frequency, the most common sites of a cerebral hemorrhage are (1) the putamen and adjacent internal capsule (50 percent); (2) the central white matter of the temporal, parietal, or frontal lobes (lobar hemorrhages, not strictly associated with hypertension); (3) the thalamus; (4) a cerebellar hemisphere; and (5) the pons (see Weisberg et al). The vessel involved is usually a penetrating artery that originates from a larger trunk vessel. About 2 percent of primary hemorrhages are multiple. Rarely the bleeding is solely intraventricular, possibly from the choroid plexus. The problem is one of bleeding that occurs within brain tissue; rupture of arteries lying in the subarachnoid space is practically unknown apart from aneurysms and some vascular malformations.

The extravasation of blood forms a roughly circular or oval mass that disrupts the tissue and grows in volume as the bleeding continues (Fig. 34-20). Adjacent brain tissue is distorted and compressed. If the hemorrhage is large, midline structures are displaced to the opposite side and reticular activating and respiratory centers can be compromised, leading to coma and death in the manner described in Chap. 17. Both the size and the location of the clot determine the degree of upper brainstem compression (Andrew et al). Rupture or seepage into the ventricular system may occur, and the CSF becomes bloody in these cases. However, a hemorrhage of this type almost never ruptures through the cerebral cortex. When the hemorrhage is small and located at a distance from the ventricles, the CSF may remain clear even on repeated examinations.

In the first hours and days following the hemorrhage, a limited amount of edema accumulates around the clot and adds to the mass effect. Hydrocephalus may

occur as a result of bleeding into the ventricular system or from compression of the third ventricle.

Extravasated blood undergoes a predictable series of changes. At first fluid, it clots within hours. Before the clot forms, red cells may settle in the dependent part of the hematoma and form a meniscus with the plasma above; this is particularly prone to occur in cases of anticoagulant-induced hemorrhage. A fluid-fluid level is then observed on scans (hematocrit effect). Only masses of red blood cells (RBCs) and proteins are found within the hematoma; rarely one sees a few remnants of destroyed brain tissue. The hematoma is surrounded by petechial hemorrhages from torn arterioles and venules. Within a few days, hemoglobin products, mainly hemosiderin and hematin, begin to appear. The hemosiderin forms within histiocytes that have phagocytized RBCs and takes the form of ferritin granules, which stain positively for iron. As oxyhemoglobin is liberated from the RBCs and becomes deoxygenated, methemoglobin is formed. This begins within a few days and imparts a brownish hue to the periphery of the clot. Phagocytosis of RBCs begins within 24 h, and hemosiderin is first observed around the margins of the clot in 5 to 6 days. The clot changes color gradually, over a few weeks, from dark red to pale red, and the border of golden-brown hemosiderin widens. The edema disappears over many days or weeks. In 2 to 3 months, larger clots are filled with a chrome-colored mush, which is slowly absorbed, leaving a smooth-walled cavity (slit hemorrhage) or a yellow-brown scar. The iron pigment (hematin) becomes dispersed and studs adjacent astrocytes and neurons. It may persist well beyond the border of the hemorrhage for years.

In CT scans, fresh blood is visualized as a white mass as soon as it is shed. The mass effect and the surrounding extruded serum and edema are hypodense. After 2 to 3 weeks, the surrounding edema begins to recede and the density of the hematoma decreases, first at the periphery. Gradually the clot becomes isodense with brain. There may be a ring of enhancement from the hemosiderin-filled macrophages and the reacting cells forming the capsule of the hemorrhage. By MRI, either in conventional T1- or T2-weighted images, the hemorrhage is not easily visible in the 2 or 3 days after bleeding, since oxyhemoglobin is diamagnetic or, at most, is slightly hypointense, so that only the mass effect is evident. After several days the surrounding edema is hyperintense in T2-weighted images. As deoxyhemoglobin and methemoglobin form, the hematoma signal becomes bright on T1-weighted images and dark on T2. As the hematoma becomes subacute, the dark images gradually brighten. When methemoglobin disappears and only hemosiderin remains, the entire remaining mass is hypodense on T2-weighted images, as are the surrounding deposits of iron. MR images that display areas of magnetic susceptibility will show hemorrhages earlier and detect remnants of deposited hemosiderin even years afterwards.

Hemorrhages may be described as massive, moderate, small, slit, and petechial. Massive refers to hemorrhages several centimeters in diameter; small applies to those 1 to 2 cm in diameter and less than 20 mL in volume; a moderate-sized hemorrhage, of course, falls between these two, both in diameter and in volume. Slit refers to an old collapsed hypertensive or traumatic hemorrhage that lies just beneath the cortex.

Pathogenesis

The hypertensive vascular lesion that leads to arterial rupture in some cases appears to arise from an arterial wall altered by the effects of hypertension, i.e., the change referred to in a preceding section as segmental lipohyalinosis and the false aneurysm (microaneurysm) of Charcot-Bouchard. Ross Russell has affirmed the relationship of these microaneurysms to hypertension and hypertensive hemorrhage and their frequent localization on penetrating small arteries and arterioles of the basal ganglia, thalamus, pons, and subcortical white matter. However, in the few hemorrhages examined in serial sections by our colleague C. M. Fisher, the bleeding could not be traced to Charcot-Bouchard aneurysms. Takebayashi and coworkers, in an electron microscopic study, found breaks in the elastic lamina at multiple sites, almost always at bifurcations of the small vessels. Possibly these represent sites of secondary rupture from tearing of small vessels by the expanding hematoma.

Putaminal Haemorrhage

The most common syndrome is the one due to putaminal hemorrhage, with extension to the adjacent internal capsule (Fig. 34-20). The neurologic symptoms and signs vary slightly with the precise site and size of the extravasation, but hemiplegia from interruption of the capsule is a consistent feature of medium-sized and large clots. Vomiting occurs in about half the patients. Headache is frequent but not invariable. With large hemorrhages, patients lapse almost immediately into a stupor with hemiplegia, and their condition visibly deteriorates as the hours pass. More often, however, the patient complains of headache or of some other abnormal cephalic sensation. Within a few minutes the face sags on one side, speech becomes slurred or

aphasic, the arm and leg gradually weaken, and the eyes tend to deviate away from the side of the paretic limbs. These events, occurring gradually over a period of a few minutes to a half hour, are strongly suggestive of intracerebral bleeding. The paralysis may worsen; a Babinski sign appears, at first unilaterally and then bilaterally; the affected limbs become flaccid; painful stimuli are not appreciated; speaking becomes impossible; and confusion gives way to stupor. The most advanced stages are characterized by signs of upper brainstem compression (coma); bilateral Babinski signs; deep, irregular, or intermittent respiration; dilated, fixed pupils, first on the side of the clot; and occasionally by decerebrate rigidity.

The widespread use of CT scanning has disclosed the frequent occurrence of smaller putaminal hemorrhages, which in former times would have been misdiagnosed as embolic or thrombotic ischemic strokes (especially if the CSF was clear). With hemorrhages confined to the anterior segment of the putamen, the hemiplegia and hyperreflexia tend to be less severe and to clear more rapidly (Caplan). There is also prominent abulia, motor impersistence, temporary unilateral neglect, and with left-sided lesions, nonfluent aphasia and dysgraphia. With posterior lesions, weakness is also less and is attended by sensory loss, hemianopia, impaired visual pursuit to the opposite side, Wernicke-type aphasia (left-sided lesions), and anosognosia (right-sided).

Caplan has also analyzed the effects of relatively pure caudate hematoma. Those extending laterally and posteriorly into the internal capsule behave much like large putaminal hemorrhages. Those extending medially into the lateral ventricle give rise

to drowsiness, stupor, and either confusion and underactivity or restlessness and agitation.

Thalamic Haemorrhage

The central feature here is severe sensory loss on the entire contralateral body. If large or moderate in size, thalamic hemorrhage also produces a hemiplegia or hemiparesis by compression or destruction of the adjacent internal capsule (Fig. 34-21). The sensory deficit is usually severe and involves all of the opposite side, including the trunk, and may exceed the motor weakness. A fluent aphasia may be present with lesions of the dominant side, and amorphosynthesis and contralateral neglect with lesions of the nondominant side. A homonymous field defect, if present, usually clears in a few days.

Thalamic hemorrhage, by virtue of its extension into the subthalamus and high midbrain, may cause a series of ocular disturbances pseudo-abducens palsies with one or both eyes turned asymmetrically inward and slightly downward, palsies of vertical and lateral gaze, forced deviation of the eyes downward, inequality of pupils with absence of light reaction, skew deviation with the eye ipsilateral to the hemorrhage assuming a higher position than the contralateral eye, ipsilateral ptosis and miosis (Horner syndrome), absence of convergence, retraction nystagmus, and tucking in (retraction) of the upper eyelids. Extension of the neck may be observed. Compression of the adjacent third ventricle leads to enlargement of the lateral ventricles, and this requires temporary drainage of the ventricles in a small proportion of patients. Small and moderate-sized hemorrhages that rupture into the

third ventricle are seemingly associated with fewer neurologic deficits and better outcomes, but early hydrocephalus is almost invariable.

Pontine Haemorrhage

Here deep coma usually ensues in a few minutes, and the clinical picture is dominated by total paralysis, decerebrate rigidity, and small (1-mm) pupils that react to light. Lateral eye movements, evoked by head turning or caloric testing, are impaired or absent. Death usually occurs within a few hours, but there are rare exceptions in which consciousness is retained and the clinical manifestations indicate a smaller lesion in the tegmentum of the pons (disturbances of lateral ocular movements, crossed sensory or motor disturbances, small pupils, and cranial nerve palsies) in addition to signs of bilateral corticospinal tract involvement. A small number of our patients with small tegmental hemorrhages and blood in the CSF have survived, with good functional recovery. In a series of 60 patients with pontine hemorrhage reviewed by Nakajima, 19 survived (8 of these had remained alert). Similarly, Wijdicks and St. Louis reported that 21 percent made a good recovery, mostly those who were alert on admission.

Cerebellar Haemorrhage

This usually develops over a period of one to several hours, and loss of consciousness at the onset is unusual. Repeated vomiting is a prominent feature, along with occipital headache, vertigo, and inability to sit, stand, or walk. Often these are the only abnormalities, making it imperative to have the patient attempt to stand and walk; otherwise the examination may be falsely normal. In the early phase of the illness, other clinical signs of cerebellar disease may be minimal or lacking;

only a minority of cases show nystagmus or cerebellar ataxia of the limbs, although these signs must always be sought. A mild ipsilateral facial weakness and a diminished corneal reflex are common. Dysarthria and dysphagia may be prominent in some cases but usually are absent. Contralateral hemiplegia and ipsilateral facial weakness do not occur unless there is displacement and compression of the medulla against the clivus. There is often paresis of conjugate lateral gaze to the side of the hemorrhage, forced deviation of the eyes to the opposite side, or an ipsilateral sixth nerve weakness. Vertical eye movements are retained. Other ocular signs include blepharospasm, involuntary closure of one eye, skew deviation, œcular bobbing, and small, often unequal pupils that continue to react until very late in the illness.

Occasionally, at the onset, there is a spastic paraparesis or a quadriparesis with preservation of consciousness. The plantar reflexes are flexor in the early stages but extensor later. When these signs occur, hydrocephalus is present and may require drainage. In the series of St. Louis et al, those with vermian clots and hydrocephalus were at the highest risk for deterioration. As the hours pass, and occasionally with unanticipated suddenness, the patient becomes stuporous and then comatose or suddenly apneic as a result of brainstem compression, at which point reversal of the syndrome, even by surgical therapy, is seldom successful.

Lobar Haemorrhage

Bleeding in areas other than those listed above, specifically in the subcortical white matter of one of the lobes of hemisphere, is not associated strictly with hypertension; it is presented here for ease of exposition. Any number of other causes are usually responsible, the main ones being anticoagulation or thrombolytic therapy,

arteriovenous malformation (discussed further on), trauma, and, in the elderly, amyloidosis of the cerebral vessels.

Laboratory Findings

Among laboratory methods for the diagnosis of intracerebral hemorrhage, the CT scan occupies the foremost position. This procedure has proved totally reliable in the detection of hemorrhages that are 1.0 cm or more in diameter. Smaller pontine hemorrhages are visualized with less certainty. At the same time, coexisting hydrocephalus, tumor, cerebral swelling, and displacement of the intracranial contents are readily appreciated. MRI is particularly useful for demonstrating brainstem hemorrhages and residual hemorrhages, which remain visible long after they can no longer be seen by the CT scan (after 4 to 5 weeks). Haemosiderin and iron pigment have their own characteristic appearances, as described earlier.

In general, lumbar puncture is ill advised, for it may precipitate or aggravate an impending shift of central structures and herniation. The white cell count in the peripheral blood may rise transiently to 15,000/mm³, a higher figure than in thrombosis. The sedimentation rate is mildly elevated in some patients.

Course and Prognosis

The immediate prognosis for large and medium-sized cerebral clots is grave; some 30 to 35 percent of patients die in 1 to 30 days. Either the hemorrhage extends into the ventricular system or intracranial pressure is elevated to levels that preclude normal perfusion of the brain. Sometimes the hemorrhage itself seeps into vital centers such as the hypothalamus or midbrain. A formula that predicts outcome of hemorrhage based on clot size has been devised by Broderick and coworkers; it is

mainly applicable to putaminal and thalamic hemorrhages. They found a close correlation with outcome. A volume of 30 mL or less, calculated from the CT scan, predicted a generally favorable outcome; only 1 of their 71 patients with clots larger than 30 mL had regained independent function by 1 month. By contrast, in patients with clots of 60 mL or larger and an initial Glasgow Coma Scale score of 8 or less, the mortality was 90 percent (this scale is detailed on page 754). As remarked earlier, it is the location of the hematoma, not simply its size, that determines the clinical effects. A clot 60 mL in volume is almost uniformly fatal if situated in the basal ganglia but may be more benign if located in the frontal or occipital lobe. From the studies of Diringier and colleagues, it appears that hydrocephalus is also an important predictor of poor outcome, and this accords with our experience.

In patients who survived., in those with smaller hemorrhages, there can be a surprising degree of restoration of function, since, in contrast to infarction, the hemorrhage has to some extent pushed brain tissue aside rather than destroyed it. Function may return very slowly, however, because extravasated blood takes time to be removed from the tissues. Also, since rebleeding from the same site is unlikely, the patient may live for many years. In some instances of medium-sized cerebral and cerebellar hemorrhages, papilledema appears after several days of increased intracranial pressure. This does not mean that the hemorrhage is increasing in size or swelling only that papilledema is slow to develop. Healed scars impinging on the cortex are liable to be epileptogenic; the frequency of seizures after each type of hemorrhage has not been established, but it is lower than for ischemic strokes. There

is probably no need to administer anticonvulsive medication unless a seizure has occurred.

The poor prognosis of all but the smallest pontine hemorrhages has already been mentioned. Cerebellar hemorrhages present special problems that are discussed below.

Associated Systemic Changes

Acute subarachnoid hemorrhage is associated with several characteristic responses in the systemic circulation, water balance, and cardiac function. The ECG changes include symmetrically large peaked T waves and other alterations suggesting subendocardial or myocardial ischemia. Also there is a tendency to develop hyponatremia; this abnormality and its relationship to intravascular volume depletion plays a key role in treatment, as discussed further on. Albuminuria and glycosuria may be present for a few days. Rarely, diabetes insipidus occurs in the acute stages, but water retention or a natriuresis is more frequent. There may be a leukocytosis of 15,000 to 18,000 cells per cubic millimeter, but the sedimentation rate is usually normal.

Course and Prognosis

The outstanding characteristic of this condition, mentioned earlier, is the tendency for the hemorrhage to recur from the same site. This threat colors all prognostications and dominates modern treatment strategies. Unfortunately there appears to be no way of determining reliably which patients will bleed again. The cause of recurrent bleeding is not understood but may be related to naturally

occurring mechanisms of clot formation and lysis at the site of initial rupture, usually at the dome of the aneurysm.

Patients with the typical clinical picture of spontaneous subarachnoid hemorrhage in whom an aneurysm or arteriovenous malformation cannot be demonstrated angiographically have a distinctly better prognosis than those in whom the lesion is visualized (Nishioka et al). In a series of 323 angiographically negative cases followed for an average of 10 years, there was rebleeding in only 12 (Hawkins et al). After 22 years, 69 percent of these patients had survived. It is customary in most centers to repeat the arteriogram in several weeks, because it has been observed that vascular spasm may have earlier obscured the aneurysm. It is advantageous to obtain x-rays from several different angles in order to expose those views that were obscured by adjacent overlying vessels. If the first study involves all cerebral vessels and utilizes several views of the basal circulation, it has been our experience that the second arteriogram is infrequently more revealing but our practice is to repeat it nonetheless.

Another clinical circumstance with a favorable outcome is limited perimesencephalic hemorrhage, described by van Gijn and colleagues. The cisterns surrounding the midbrain and upper pons are symmetrically filled with blood, the headache is mild, and signs of vasospasm do not develop. No aneurysm is found at the expected site for blood in this region, i.e., at the top of the basilar artery. The patient usually does well and a second arteriogram is probably not required. It has been speculated that the bleeding has a venous rather than an aneurysmal source.

As regards prognosis of aneurysmal hemorrhage, McKissock and colleagues decades ago found that the patient's state of consciousness at the time of arteriography was the single best index of outcome, and this remains true today. Their data, representative of the status of aneurysm management in the 1950s and consonant with the natural history before the advent of modern surgical and intensive care techniques, indicated that of every 100 patients reaching a hospital and coming to arteriography, 17 were stuporous or comatose and 83 appeared to be recovering from the ictus. At the end of the following 6 months, 8 of every 100 patients had died of the original hemorrhage and 59 had had a recurrence (with 40 deaths), making a total of 48 deaths and 52 survivors. In regard to recurrence of bleeding, it was found that of 50 patients seen on the first day of the illness, 5 rebled in the first week (all fatal), 8 in the second week (5 fatal), 6 in the third and fourth weeks (4 fatal), and 2 in the next 4 weeks (2 fatal), making a total of 21 recurrences (16 fatal) in 8 weeks.

The most comprehensive long-term analysis of the natural history of the disease is contained in the report of the Cooperative Study of Intracranial Aneurysms and Subarachnoid Haemorrhage (Sahs et al). This study was based on long-term observations of 568 patients who sustained an aneurysmal bleed between 1958 and 1965 and were managed only by a conservative medical program. A follow-up search in 1981 and 1982 disclosed that 378, or two-thirds of the patients, had died; 40 percent of the deaths had occurred within 6 months of the original hemorrhage. For the patients who survived the original hemorrhage for 6 months, the chances of survival during the next two decades were significantly worse than those of a matched normal population. Rebleeding occurred at a rate of 2.2 percent per year

during the first decade and 0.86 percent per year during the second. Rebleeding episodes were fatal in 78 percent of cases. These statistics, however, also reflect the outcome prior to the modern era of microsurgery and neurologic intensive care management.

One would expect these figures to have improved in recent years, but the change has not been striking. In a prospective clinical trial conducted by the International Cooperative Study in 1990 and based on observations of 3521 patients (surgery performed in 83 percent), it was found, at the 6-month evaluation, that 26 percent of the patients had died and 58 percent had made a good recovery (Kassell et al). Vasospasm and rebleeding were the leading causes of morbidity and mortality in those who survived the initial bleed.

In respect to rebleeding, all series indicate that the risk is greatest in the first day but extends for weeks. The observations of Aoyagi and Hayakawa are similar to those of other series; they found that rebleeding occurred within 2 weeks in 20 percent of patients, with a peak incidence in the 24 h after the initial episode.

Treatment

This is influenced by the neurologic and general medical state of the patient as well as by the location and morphology of the aneurysm. Ideally, all patients should have the aneurysmal sac obliterated, but the mortality is high if the patient is stuporous or comatose (grade IV or V, see below). Before deciding on a course of action, it has been useful to assess the patient with reference to the widely Employed scale introduced by Botterell and refined by Hunt and Hess, as follows:

Grade I. Asymptomatic or with slight headache and stiff neck

Grade II. Moderate to severe headache and nuchal rigidity but no focal or lateralizing neurologic signs

Grade III. Drowsiness, confusion, and mild focal deficit

Grade IV. Persistent stupor or semicoma, early decerebrate rigidity and vegetative disturbances

Grade V. Deep coma and decerebrate rigidity

The general medical management in the acute stage includes the following, all or in part: bed rest, fluid administration to maintain above-normal circulating blood volume and central venous pressure, use of elastic stockings and stool softeners; administration of beta blockers, calcium channel blockers, intravenous nitroprusside, or other medication to reduce greatly elevated blood pressure and then maintain systolic blood pressure at 150 mmHg or less; and pain-relieving medication for headache (this alone will often reduce the hypertension). The prevention of systemic venous thrombosis is critical, usually accomplished by the use of cyclically inflated whole-leg compression boots. The use of anticonvulsants is controversial; many neurosurgeons administer them early, with a view of preventing a seizure-induced risk of rebleeding. We have generally avoided them unless a seizure has occurred.

Calcium channel blockers are being used extensively to reduce the incidence of stroke from vasospasm. Nimodipine 60 mg, administered orally every 4 h, is currently favored. Although calcium channel blockers do not alter the incidence of angiographically demonstrated vasospasm, they have reduced the number of strokes in each of five randomized studies, beginning with the one conducted by Allen and colleagues. Several groups have been using angioplasty techniques to dilate

vasospastic vessels and reporting symptomatic improvement, but there are as yet insufficient controlled data to judge the merits and safety of this procedure.

The most notable advances have been in the techniques for the obliteration of aneurysms, particularly the operating microscope and endovascular approaches, and in the management of circulatory volume. In the majority of patients intravascular volume is depleted in the days after subarachnoid hemorrhage. This, in turn, greatly increases the chances of ischemic infarction from vasospasm, though it does not alter its incidence or severity. In part, this volume contraction can be attributed to bed rest, but sodium loss, probably resulting from the release of atrial natriuretic factor (ANF), a potent oligopeptide stimulator of sodium loss in renal tubules, may also be a factor. Hyponatremia develops in the first week after hemorrhage, but it is unclear whether this also results from the natriuretic effects of ANF or is an effect of antidiuretic hormone, causing water retention. The work of Diringier and co-workers suggests that both mechanisms are operative, but we would emphasize that it is the volume depletion, not hyponatremia per se, that is of the greatest clinical consequence.

Both the risk of re-rupture of the aneurysm and some of the secondary problems that arise because of the massive amount of blood in the subarachnoid space can be obviated by early obliteration of the aneurysm. Because of the changes in water balance and the risk of delayed stroke from vasospasm, there has been an emphasis on early volume expansion and sodium repletion by the intravenous infusion of crystalloids. As Solomon and Fink have pointed out, this can be accomplished with relative safety and without fear of aneurysmal rupture if blood

pressure is allowed to rise only minimally. And, of course, fluid replacement and a modest elevation of blood pressure become completely safe if the aneurysm has been surgically occluded. Thus the current approach is to operate early, within 36 h if possible, on all patients in grades I and II and then to increase intravascular volume and maintain normal or above-normal blood pressures. This eliminates the risk of re-bleeding, with its high mortality, and helps prevent the second cause of morbidity, stroke from vasospasm. The timing of surgery or endovascular treatment for grade III patients is still controversial, but if their medical condition allows, they too probably benefit from the same early and aggressive approach. In grade IV patients, the outcome is generally dismal, no matter what course is taken, but we have usually counselled against early operation; some neurosurgeons disagree. The insertion of ventricular drains into both frontal horns has occasionally raised a patient with severe hydrocephalus to a better grade and facilitated early operation. In the hands of experienced anesthesiologists and cerebrovascular surgeons, the operative mortality, even in grade III and IV patients, has now been reduced to 2 to 3 percent. For a detailed account of the operative approach to each of the major classes of saccular aneurysm, the reader is referred to the monograph by Ojemann and colleagues.

Several alternative therapeutic measures are still being studied. Among these, endovascular obliteration of the lumen of the aneurysm holds the most promise. This has become the preferred approach for aneurysms that are surgically inaccessible for example, those in the cavernous sinus or for patients whose medical state precludes an operation. Among several trials that have compared surgery with endovascular

placement of coils in the aneurysm, several have shown a slight superiority of the latter. For example, the International Subarachnoid Aneurysm Trial Group randomly assigned over 2000 patients to surgery or platinum coil placement; the overall rate of death or dependence at 1 year was 24 percent in the endovascular group and 31 percent in the operated group. Doubtless, further studies will continue to clarify the relative benefits of the treatment. We would comment that the skill of the surgeon and the quality of postoperative care are major determinants of outcome; perhaps the simplicity of endovascular treatment and the improvements in the training of interventional specialists will prove its advantage over time.

Because of the current approach of ablating the aneurysm early, the previously popular use of antifibrinolytic agents as a means of impeding lysis of the clot at the site of aneurysmal rupture has been generally abandoned. Repeated drainage of the CSF by lumbar puncture is also no longer practiced as a routine. One lumbar puncture is generally carried out for diagnostic purposes if the CT scan is inconclusive; thereafter spinal fluid drainage is performed only for the relief of intractable headache or to detect recurrence of bleeding. As mentioned earlier, patients with stupor or coma who have massive hydrocephalus often benefit from decompression of the ventricular system. This is accomplished initially by external drainage and may require permanent shunting if the hydrocephalus returns. The risk of infection of the external shunt tubing is high if it is left in place for much more than 3 days. Replacement with a new tube, preferably at another site, reduces this risk.

Unruptured Intracranial Aneurysms

Not infrequently, cerebral angiography, MRI, MRA, or CT scanning performed for an unrelated reason, discloses the presence of an unruptured saccular aneurysm. Or, a second or third aneurysm is found during the angiogram to assess a ruptured one. There is now a reasonable body of information about the natural history of these lesions. Wiebers and colleagues observed 65 patients with one or more unruptured aneurysms for at least 5 years after their detection. The only clinical feature of significance relative to rupture was aneurysmal size. None of 44 aneurysms smaller than 10 mm in diameter had ruptured, whereas 8 of 29 aneurysms 1 cm or larger eventually did so, with a fatal outcome in 7 cases. Two large studies have attempted to refine these statistical data. In the older Cooperative Study of Intracranial Aneurysms, none of the aneurysms less than 7 mm diameter had further trouble. A more recent and quite sizable cooperative study that included 4060 patients and gathered data prospectively for 5 years, conducted by the International Study of Unruptured Intracranial Aneurysms Investigators, found an extremely low rate of rupture, about 0.1 percent yearly, for aneurysms smaller than 7 mm in diameter, an annual risk of 0.5 percent was found for aneurysms between 7 and 10 mm, and a risk ranging from 0.6 to 3.5 percent for lesions between 13 and 24 mm (depending on location). The risk ranged up to 10 percent for aneurysms greater than 25 mm diameter. The yearly rates for rupture were higher in all categories if there had been prior bleeding from another site. The location of the lesion also had great bearing on the risk of rupture, as did increasing age; notably, vertebrobasilar and posterior cerebral aneurysms bled at a rate many times higher than the others. The importance

of such data is underscored by the comparison to the risk of surgery and endovascular treatment, which begin to exceed the risk of bleeding within 5 years in the smaller aneurysms located in the carotid circulation.

Giant Aneurysms

As has been stated, these are believed to be congenital anomalies even when there is considerable atherosclerosis in their walls. They may become enormous in size, by definition greater than 2.5 cm in diameter, but sometimes twice or more as large. Most are located on a carotid, basilar, anterior, or middle cerebral artery. They grow slowly by accretion of blood clot within their lumens or by the organization of surface blood clots from small leaks. At a certain point they may compress adjacent structures, e.g., those in the cavernous sinus, optic nerve, or lower cranial nerves. The giant fusiform aneurysm of the midbasilar artery, with signs of brainstem ischemia and lower cranial nerve palsies, is a relatively common form. Clotting within the aneurysm may cause ischemic infarction in its territory of supply. Giant aneurysms may rupture and cause subarachnoid hemorrhage, but not nearly as often as saccular aneurysms. This clinical observation has been confirmed by the International Study, referred to above.

Treatment is surgical if the lesion is symptomatic and it is accessible; treatment is with endovascular techniques if the lesion is in the vertebral or midbasilar artery. Obliteration of the lumen, coupled with vascular bypass procedures, has been successful in the hands of a few cerebrovascular neurosurgeons, but the morbidity is high. Some aneurysms can be ligated at their necks, others by trapping or by the use of an intravascular detachable balloon. Drake has summarized his experience in the

treatment of 174 such cases. Ojemann and colleagues have also had singular success in treating these lesions by a combination of surgical techniques; in more than 40 cases, half of them trapped and half obliterated, there was not a single fatality. Some have been wrapped in muslin or similar material with mixed results. We have followed one such patient operated by T. Sundt over 25 years ago. Recent attempts at stabilizing the expansion of the aneurysm by stenting are under study.

Arteriovenous Malformations of the Brain

An arteriovenous malformation (AVM) consists of a tangle of dilated vessels that form an abnormal communication between the arterial and venous systems, really an arteriovenous fistula. It is a developmental abnormality representing persistence of an embryonic pattern of blood vessels and is not a neoplasm, but the constituent vessels may proliferate and enlarge with the passage of time. Arteriovenous malformations have been designated by a number of other terms, such as angioma and arteriovenous aneurysm, but these are less appropriate; angioma suggests a tumor, and the term aneurysm is generally reserved for the lesions described in the preceding section. Venous malformations, consisting purely of distended veins deep in the white matter, are a separate entity; they may be the cause of seizures and headaches but seldom of hemorrhage. When a small hemorrhage occurs in relation to venous malformation, it is usually due to an associated cavernous malformation.

Vascular malformations vary in size from a small blemish a few millimeters in diameter lying in the cortex or white matter to a huge mass of tortuous channels constituting an AV shunt of sufficient magnitude, in rare instances, to raise cardiac output. Hypertrophic dilated arterial feeders can be seen approaching the main lesion

and to break up into a network of thin-walled blood vessels that connect directly with draining veins. The latter often form greatly dilated, pulsating channels, carrying away arterial blood. The tangled blood vessels interposed between arteries and veins are abnormally thin and do not have the structure of normal arteries or veins. Arteriovenous malformations occur in all parts of the cerebrum, brainstem, and cerebellum (and spinal cord), but the larger ones are more frequently found in the central part of a cerebral hemisphere, commonly forming a wedge-shaped lesion extending from the cortex to the ventricle. Some lie on the dural surface of the brain or spinal cord, but these most often turn out to be direct arteriovenous fistulas, as discussed further on.

When hemorrhage occurs, blood may enter the subarachnoid space, producing a picture almost identical to that of ruptured saccular aneurysm, but generally less severe; since most AVMs lie within cerebral tissue, bleeding is more than likely to be intracerebral as well, causing a hemiparesis, hemiplegia, and so forth, or even death.

Arteriovenous malformations are about one-tenth as common as saccular aneurysms and about equally frequent in males and females. The two lesions AVM and saccular aneurysm (on the main feeding artery of the AVM) are associated in about 5 percent of cases; the conjunction increases with the size of the AVM and the age of the patient (Miyasaka et al). Rarely, AVMs occur in more than one member of a family in the same generation or successive ones.

For a review of the Embryologic theories of formation of AVMs, the reader is directed to the article by Fleetwood and Steinberg.

Clinical Features

Bleeding or seizures are the main modes of presentation. Most AVMs are clinically silent for a long time, but sooner or later they bleed. The first hemorrhage may be fatal, but in more than 90 percent of cases the bleeding stops and the patient survives. The rate of hemorrhage in untreated patients is established to be 2 to 4 percent per year, far lower than for aneurysms. The mortality rate in two major series (Crawford et al, Ondra et al) has been 1 to 2 percent per year but as high as 6 to 9 percent in the immediate year following a first hemorrhage. The matter of an increased risk of AVM rupture during pregnancy has been disputed. The weight of evidence suggests that the risk is not raised by pregnancy alone, but as with saccular aneurysm that parturition and Valsalva activity is always a source of concern. Before rupture, chronic, recurrent headache may be a complaint; usually the headache is of a nondescript type, but a classic migraine with or without neurologic accompaniment occurs in about 10 percent of patients probably with greater frequency than it does in the general population. Most of the lesions associated with migraine-like headaches lie in the parieto-occipital region of one cerebral hemisphere, and about two-thirds of such patients have a family history of migraine.

Huge AVMs may produce a slowly progressive neurologic deficit because of compression of neighbouring structures by the enlarging mass of vessels and by shunting of blood through greatly dilated vascular channels (intracerebral steal), resulting in hypoperfusion of the surrounding brain (Homan et al). When the vein of Galen is enlarged as a result of drainage from an adjacent AVM, hydrocephalus may result. Not infrequently one or both carotid arteries pulsate unusually forcefully in

the neck. A systolic bruit heard over the carotid in the neck or over the mastoid process or the eyeballs in a young adult is almost pathognomonic of an AVM. However, such bruits have been heard in fewer than 25 percent of our patients. Exercise that increases the pulse pressure may bring out a bruit if none is present at rest.

The blood pressure may be elevated or normal; it is axiomatic that the occurrence of intracranial bleeding with a previously normal blood pressure should raise the suspicion of an AVM, but also of ruptured saccular aneurysm, bleeding diathesis, cerebral vessel amyloidosis, or hemorrhage into a tumor. Rarely, inspection of the eye grounds discloses a retinal vascular malformation that is coextensive with a similar lesion of the optic nerve and basal portions of the brain. Cutaneous, orbital, and nasopharyngeal AVMs may occasionally be found. Rarely, skull films show crescentic linear calcifications in the larger malformations.

The natural history of AVMs has been studied by Ondra and colleagues, who have presented data on a large and comprehensive series of untreated malformations in Finland over a 30-year period, and another similar series has been reported by Crawford and co-workers in Great Britain. In the latter study, comprising 343 patients, 217 were managed without surgery and observed for many years (mean, 10.4 years). Haemorrhage occurred in 42 percent and seizures in 18 percent. By 20 years after diagnosis, 29 percent had died and 27 percent of the survivors had a neurologic handicap. Although the lesion is present from birth, onset of symptoms is most common between 10 and 30 years of age; occasionally it is delayed to age 50 or even beyond. In almost half of patients, the first clinical manifestation is a cerebral

subarachnoid hemorrhage; in 30 percent, a seizure is the first and only manifestation; and in 20 percent, the only symptom is headache. Progressive hemiparesis or other focal neurologic deficit is present in about 10 percent of patients. In a series of 1000 patients referred mainly for proton beam radiation of an AVM and studied by our colleague R. D. Adams, 464 had a hemorrhage as the first manifestation and 218 had a seizure (mainly with frontal and frontoparietal lesions). In 139, the lesion came to attention as a result of a progressive neurologic deficit; most of these were situated in the posterior fossa or axially in the cerebrum. Headaches were an early symptom in 212, but only 59 of these patients had a subsequent hemorrhage. The combination of a prolonged history of headaches, seizures, and a progressive deficit almost always indicated a large malformation.

Fully 95 percent of AVMs are disclosed by CT scans if enhanced and an even larger number by MRI (Fig. 34-25). Magnetic susceptibility MRI shows small areas of previous bleeding around AVMs. Arteriography is usually necessary to establish the diagnosis with certainty and will demonstrate AVMs larger than 5 mm in diameter (Fig. 34-26); MRI may fail to reveal smaller lesions. Small ones may be obscured by hemorrhage; even at autopsy, a careful search under the dissecting microscope may be necessary to find them.

Treatment

The preferred approach in most centers is surgical excision. Some 20 to 40 percent of AVMs are amenable to block dissection, with an operative mortality rate of 2 to 5 percent and a morbidity of 5 to 25 percent (see Fleetwood and Steinberg for a

summary of reported surgical results up to 2002). In the others, which are inaccessible, attempts have been made to obliterate the malformed vessels by ligation of feeding arteries or by the use of endovascular embolization with liquid adhesives or particular material that are injected via a balloon catheter that has been navigated into a feeding vessel. Complete obliteration of large AVMs is usually not possible by these methods but, they are highly effective in reducing the size of the **AVM prior to surgery.**

Kjellberg and Chapman pioneered the treatment of AVMs at the Massachusetts General Hospital using a single dose of subnecrotizing stereotactically directed proton radiation. The technique of radiosurgery has been adopted by others using photon radiation sources, such as a linear accelerator, gamma knife, and other modes of focused x-ray radiation, as an accepted alternative to operative treatment of lesions situated in deep regions, including the brainstem, or in eloquent areas of the cortex. Generally, malformations smaller than 3 cm diameter are treatable in this way. Radiosurgical obliteration of AVMs occurs in a delayed manner, usually with a latency of at least 18 to 24 months after treatment. During this early period the patient is unprotected from rebleeding.

The likelihood of successful treatment and the nature of the risks depend on the location and size of the AVM and the radiation dose delivered. After 2 years, 75 to 80 percent of AVMs smaller than 2.5 cm in diameter have been obliterated. Even for those AVMs that have not been totally eliminated, the radiation effect appears to confer some long-term protection from bleeding. Of the larger ones, a majority are shrunken or appear less dense. The rest have shown no change at this low dose level,

but even in this group, the morbidity and mortality are lower than in the untreated group. However, a proportion of larger AVMs that are obliterated will recanalize, and many of these will subsequently bleed. Among more than 250 patients whose AVMs disappeared following proton beam therapy, there has been no recurrence of hemorrhage for up to 10 years; in larger AVMs (approximately the last 1000 cases) treated in this way, the frequency and severity of hemorrhage have been significantly reduced. The results of treatment with focused gamma radiation have been about the same. In one study, the risk of hemorrhage was reduced by 54 percent between the time of radiation and obliteration of the malformation and by 88 percent thereafter (Maruyama et al).

Two types of complications of radiation occur at a combined rate of approximately 2 to 4 percent. The first is delayed radiation necrosis, which is predictable based on the radiation dose, and the second is a venous congestion that occurs several weeks or months after treatment. The latter is indicative of the desired effect of thrombosis of the malformation. Both cause local symptoms for weeks or months. Radiation necrosis may be reduced by the administration of corticosteroids but the vascular problem generally is not helped.

The treatment of AVMs by endovascular techniques is increasingly popular but has not been fully evaluated. Nearly every AVM has several feeding arteries, some not reachable by catheter, and some part of the AVM remains after treatment. In most series, 25 percent or more of AVMs, mostly of small and medium size, could be completely obliterated, with a mortality rate below 3 percent and morbidity of 5 to 7 percent, which compares favorably with surgical outcomes. These techniques

are also particularly well adapted to lesions of a combined AVM and an aneurysm on the feeding vessel.

Most recently, combined therapy that begins with endovascular reduction of the lesion and is followed by either surgery or radiation has been viewed most favorably. In series of patients using this approach, over 90 percent of lesions could be obliterated with a very low rebleeding rate over several years. What is clear is that the plan for each patient must be individualized based on the size, location, nature of feeding vessels, the presence of other vascular lesions (aneurysm or additional AVM), and the age of the patient. Even then, there will be differences of opinion based on local resources and experience.

Finally, if the primary problem is recurrent seizure, successful treatment with reduction or cessation of seizures is achieved in a very high proportion of cases. The results are comparable to those from surgery and radiation, even if the AVM is not entirely obliterated.

MATERIALS AND METHODS:

STUDY POPULATION:

This study is to be conducted among 60 patients who are admitted with an acute onset of neurological deficit in the Department of Medicine in Government Rajaji Hospital, Madurai.

Inclusion criteria:

- Patients whose deficit lasted for more than 24 hours
- CT scan showed cerebral infarction or intra-cerebral hemorrhage
- Patients of both sex
- Patients age > 18 years

Exclusion criteria:

- Age <18 years
- Duration of stroke > 14 days because of the possibility of missing an ICH
- Causes of focal neurological deficit other than stroke (tuberculosis, tumor or trauma , transient ischemic attack)
- Patients on anti-coagulation therapy
- Patients in whom CT scan could not be done
- Patients admitted 72 hours after the onset of neurological deficit
- Patients with sub-arachnoid hemorrhage
- Repeat or recurrent stroke

ANTICIPATED OUTCOME:

Based on clinical variables such as level of consciousness , blood pressure, atheroma markers and the presence of headache, vomiting, Siriraj Stroke Score, a clinical scoring is to be used for the bedside diagnosis of the nature of the lesion in stroke patients where CT scan is not available.

DATA COLLECTION:

On admission, detailed history and thorough clinical examination including neurological assessment will be carried out. Patient's level of consciousness will be assessed by Glasgow Coma Scale (GCS).

RADIOLOGICAL INVESTIGATION:

Computed Tomography (CT) Brain

STUDY PROTOCOL:

On admission detailed history and thorough clinical examination including neurological assessment will be carried out. Patients will be assumed to be fully conscious if they had a score of >13 on the Glasgow Coma Scale (GCS), drowsy if they had a GCS score of 8–13 and unconscious if they scored <7 . Siriraj Stroke Score will be calculated and compared with the CT findings done on admission. A radiologist from the hospital, blind to the clinical features, will classify the CT brain scans as either infarction or haemorrhage.

Siriraj Stroke Score (SSS) will be calculated using the formula = (2.5×level of consciousness) + (2×vomiting) + (2×headache) + (0.1×diastolic blood pressure) - (3×atheroma markers) -12.

This will be computed for each patient. Scores will be calculated by obtaining details of each clinical variable. If any variable is not available e.g. if patient is unconscious, information will be obtained from patient's relatives. If the relatives were unaware of a particular variable, then the variable score will be adjusted as zero. A score above 1 indicates intracranial haemorrhage, while a score below -1 indicates infarction. The score between 1 and -1 represents an equivocal result.

DESIGN OF STUDY: Cross Sectional Study

PERIOD OF STUDY: MARCH 2016 TO AUGUST 2016

COLLABORATING DEPARTMENTS:

Department of General Medicine

Department of Radiology

ETHICAL CLEARANCE: Obtained

CONSENT: Individual written and informed consent.

ANALYSIS: Statistical analysis

CONFLICT OF INTEREST : Nil

FINANCIAL SUPPORT: Nil

PARTICIPANTS: Patients admitted with an acute onset of neurological deficit at Department of Medicine, Government Rajaji Hospital, Madurai will be enrolled and who satisfy the inclusion and exclusion criteria.

Siriraj Stroke Score

Variable	Clinical features	Score
·Consciousness	Alert	+0X 2.5
	Stupor, DrowsySemicoma,	+1X 2.5
	Coma	+2X 2.5
·Vomiting	No	+0 X 2
	Yes	+1X 2
·Headache within two hours	No	+0X 2
	Yes	+1X 2
·Diastolic blood pressure	---mm Hg	+Diastolic B.P.(x0.1)
·Atheromamarkers	None	-0 X3
[Diabetes, Angina, Intermittent Claudication]	One or more	-1X3
·Constant		-12

>1 = hemorrhage; < -1 =Infarction; -1 to +1 =equivocal.

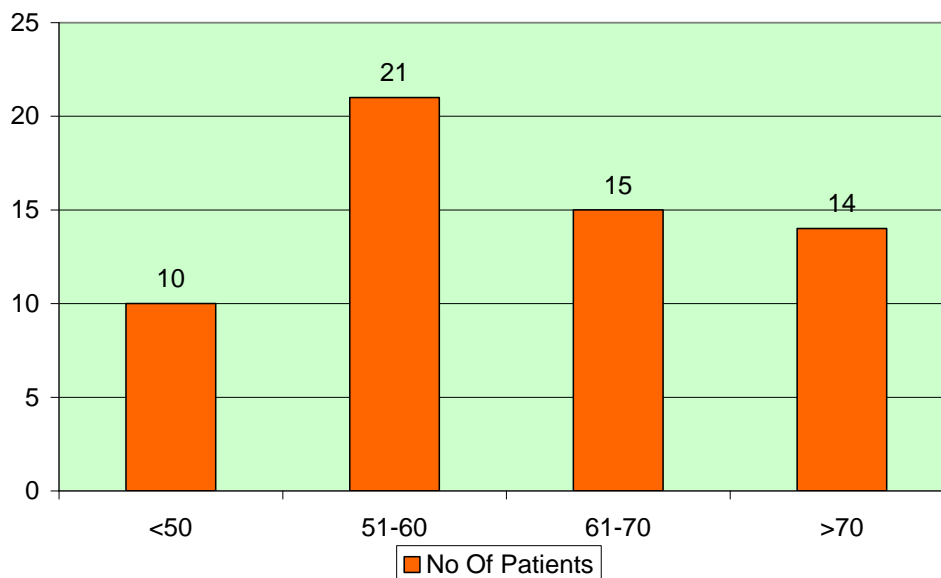
RESULTS AND INTERPRETATIONS

Table - 1

Age distribution

Age	No of Patients	%
<50	10	16.67
51-60	21	35.00
61-70	15	25.00
>70	14	23.33
Total	60	100.00
Mean	60.03	
SD	10.63	

AGE DISTRIBUTION

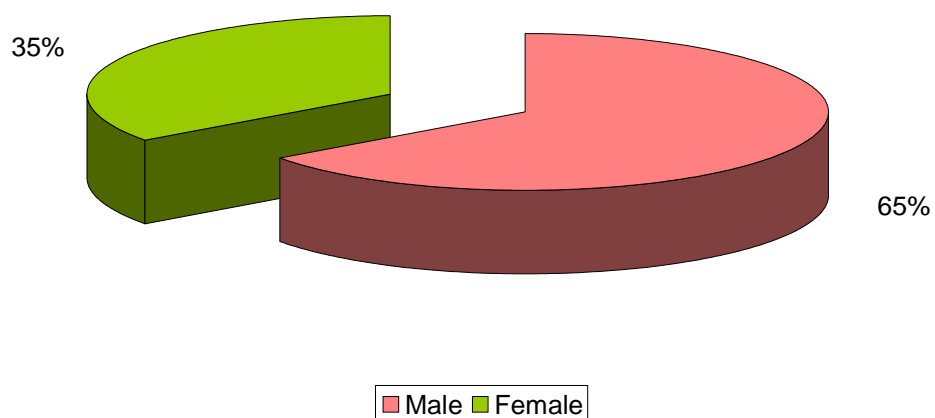


Most of the patients were in the age between 50 to 60 years though it ranged from 40 to 80 years old. Out of 60 patients, 21 of them were in the age group of 50 to 60 years.

Table – 2

Sex	No of Patients	%
Male	39	65.00
Female	21	35.00
Total	60	100.00

SEX DISTRIBUTION

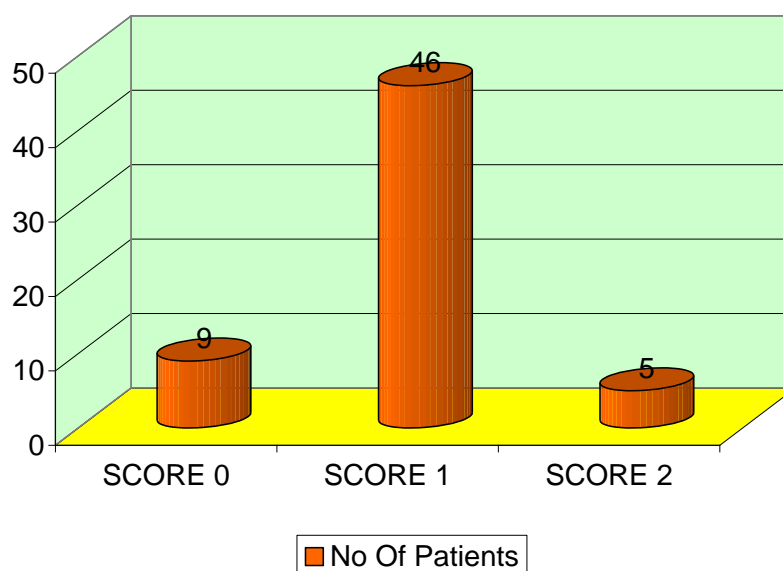


Of the total patients, 65 % were male

TABLE - 3

Level of Consciousness	No of Patients	%
SCORE 0	9	15.00
SCORE 1	46	76.67
SCORE 2	5	8.33
Total	60	100.00

CONSCIOUSNESS

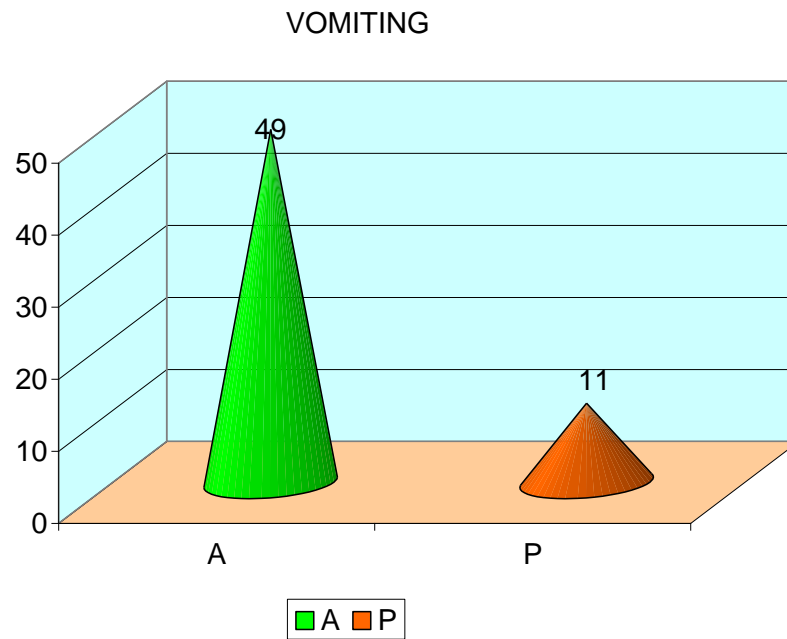


Score 0 denotes unconscious, score 1 denotes drowsy, score 2 denotes conscious. Level of consciousness was assessed by Glasgow coma scale (GCS). 46 out of the total 60 were admitted in drowsy state.

Table – 4

Vomiting

Vomiting	No Of Patients	%
Present (P)	11	18.33
Absent (A)	49	81.67
Total	60	100

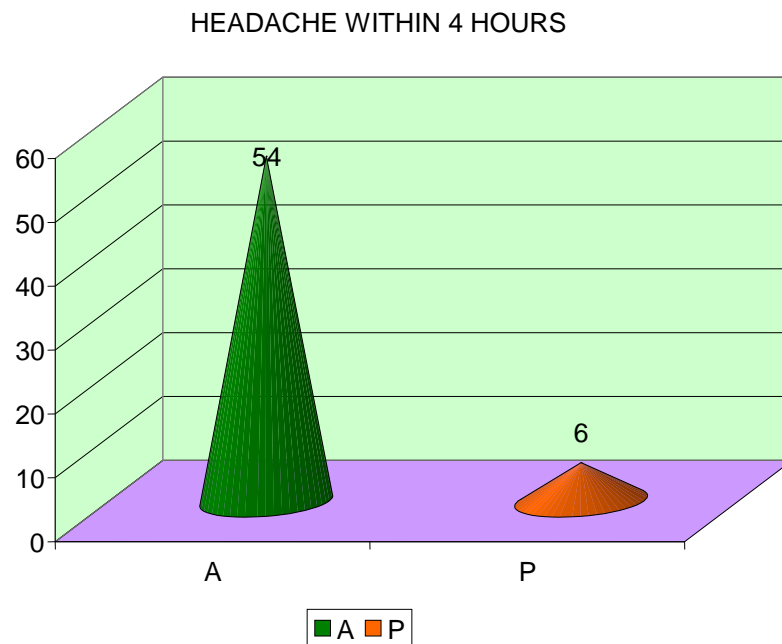


Out of total 60 patients only 11 patients had vomiting within 24 hours

Table – 5

Headache within 4 hours

Headache within 2 hrs	No Of Patients	%
Absent(A)	54	90.00
Present(B)	6	10.00
Total	60	100.00




Headache was present in 6 patients out of total 60 cases within 4 hours

Table – 5

Diastolic BP

Diastolic BP(mm Hg)	No Of Patients	%
<150	15	25.00
>150	45	75.00
Total	60	100.00

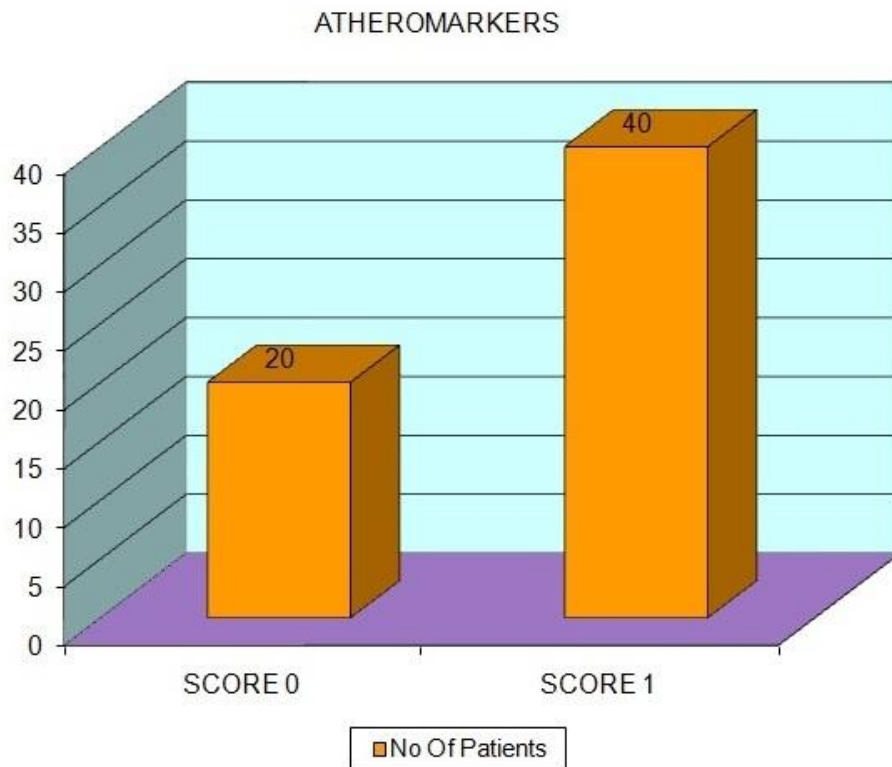
DIASTOLIC BP



45 patients out of total 60 had diastolic BP >150 mm Hg

Table - 6

Atheroma markers	No Of Patients	%
SCORE 0	20	33.33
SCORE 1	40	66.66
Total	60	100.00

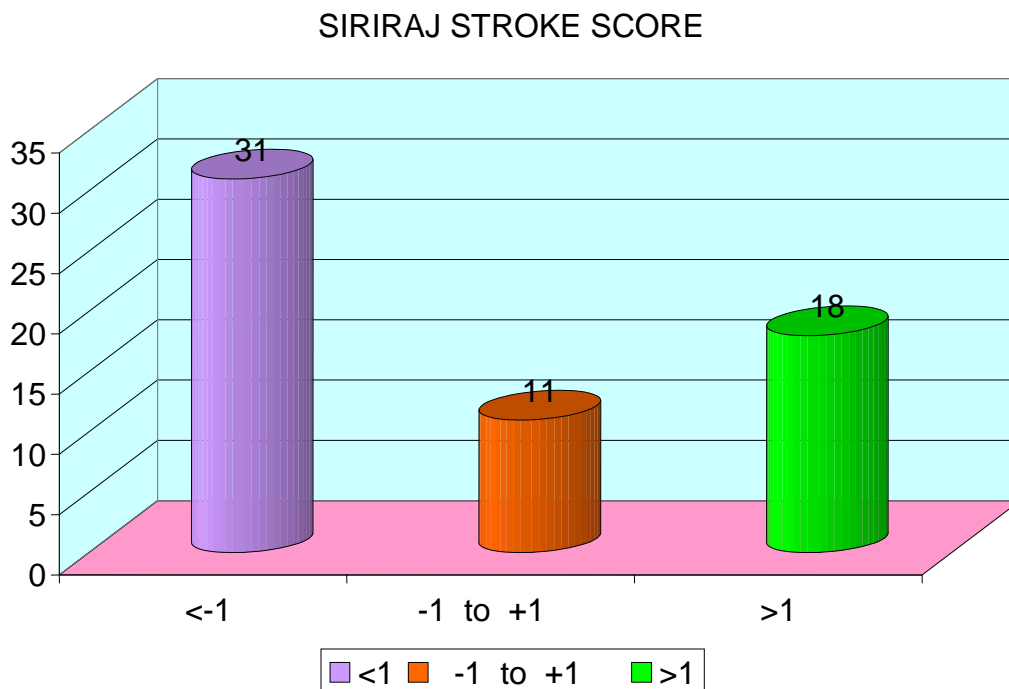


Atheroma markers (diabetes, angina, intermittent claudication) were present in 40 out of total 60 patients.

Table - 7

Siriraj stroke score	NO.OF CASES	%
<-1	31	51.67
-1 to +1	11	18.33
>+1	18	30.00
Total	60	100.00

P value - 0.015 Significant



< - 1 denotes infraction, > +1 denotes hemorrhage, -1 to +1 denotes equivocal

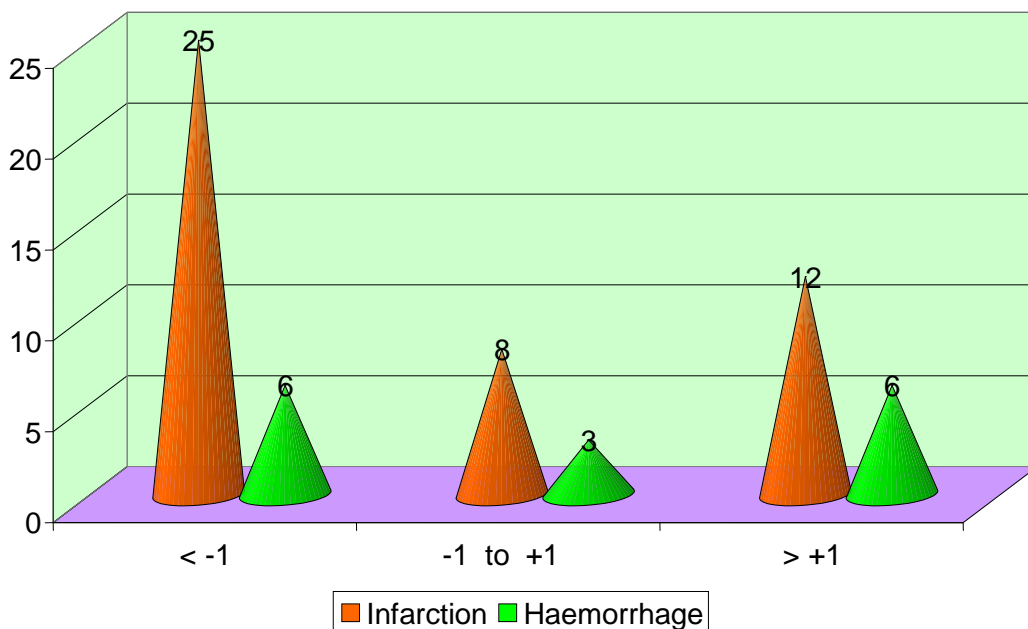
By Siriraj score 31 out of the 60 patients had infarction and only 18 patients had hemorrhage, 11 patients showed equivocal score.

Table – 8

Siriraj Stroke Score and CT comparison

Siriraj stroke score	Infarction	Hemorrhage	Total
< -1	25	6	31
-1 to +1	8	3	11
> +1	12	6	18
Total	45	15	60

SIRIRAJ STROKE SCORE VS CT COMPARISON



Comparing CT scan, 25 out of the 45 patients had infarction and 6 out of 18 patients had hemorrhage. Out of 11 equivocal score 8 patients had infarction and three patients had hemorrhage

Table – 9

Comparison of Siriraj Stroke Score (SSS) with CT Brain Scan

Diagnosis of Ischemic Stroke

Siriraj stroke score	Infarction	Non – infarction	Total
<-1	25	6	31
>+1 and -1 to +1	20	9	29
total	45	15	60

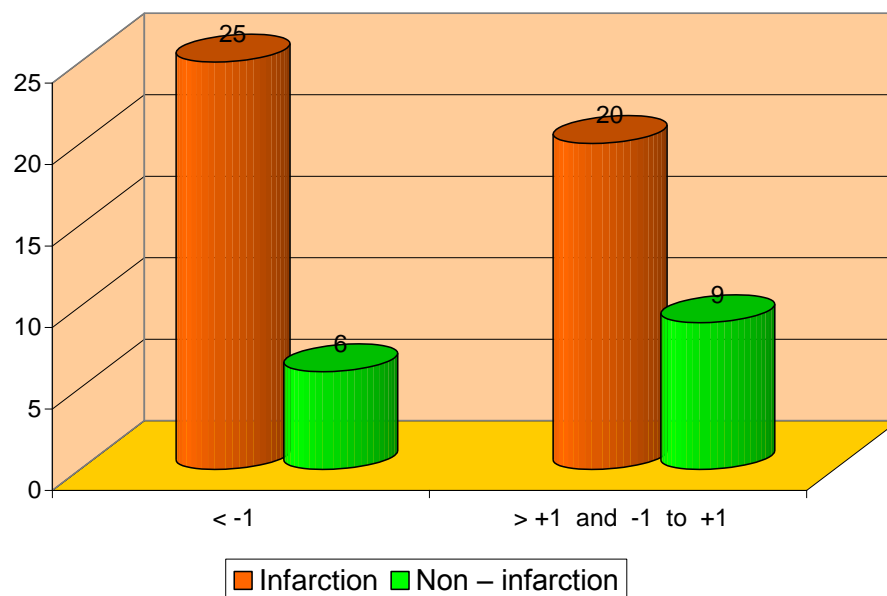
Sensitivity - 55.55%

Specificity - 60%

Positive predict value - 80.64 %

Negative predict value – 31.03 %

Sirraj Stroke Score with CT Brain scan Diagnosis of Ischemic stroke



By score 25 patients showed infarction out of the total 31 cases

Table - 10

Comparison of Siriraj Stroke Score (SSS) with CT Brain Scan

Diagnosis of Hemorrhagic Stroke

Siriraj stroke score	Hemorrhage	Non Hemorrhage	Total
> +1	6	12	18
< -1 and -1 to +1	9	33	42
Total	15	45	60

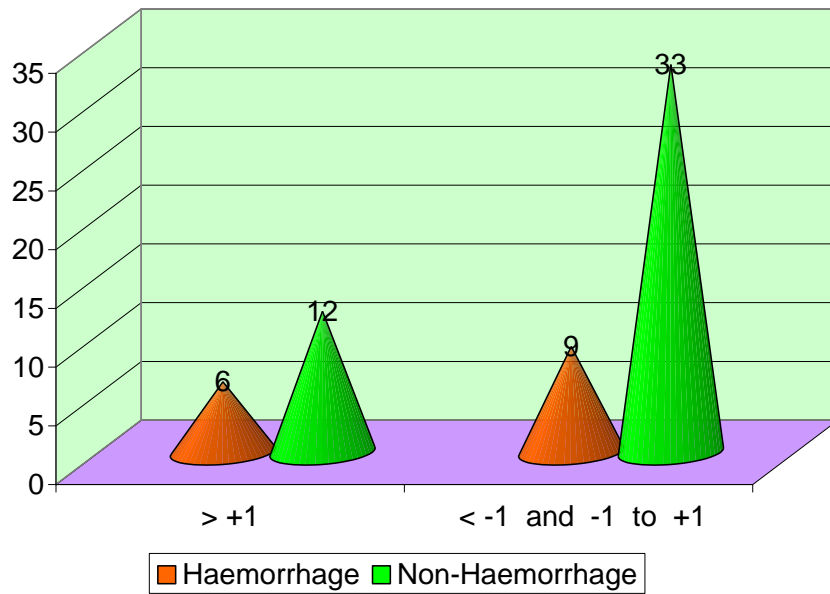
Sensitivity - 40%

Specificity - 73%

Positive predict value- 33.33 %

Negative predict value - 78.57 %

Siriraj Score with CT Brain scan Diagnosis of Haemorrhagic stroke



Out of total 18 patients, 6 cases had hemorrhage by score

DISCUSSION

We evaluated 60 patients after 24 hours of onset of stroke. On admission, detailed history and thorough clinical examination including neurological assessment were carried out. Patient's level of consciousness was assessed by Glasgow Coma Scale (GCS). It was assigned fully conscious if they had a score of >13 on the Glasgow Coma Scale, drowsy if they had a GCS score of 8–13 and unconscious if they scored <7 and we came out with various distributions of parameters as follows

It ranged from 40 to 80 years of age with mean at 60.2 years.

Males exceeded females in all the age group.

Most of the patients had access to reach the hospital within 24 hours though most of them could not make it within 3-4 hours of the onset.

The demography coincides with most of other geographical areas and to that found in literatures.

Level of consciousness as per GCS score was low in the first 24 hours more so in haemorrhagic stroke.

Atheroma markers namely diabetes, angina and intermittent claudication were found to be more as age increased and in those who had ischemic stroke.

Vomiting was seen more in haemorrhagic stroke though only few cases of ischemic exhibited vomiting, indicating likelihood of vomiting more in haemorrhagic stroke.

Blood pressure was found to be elevated more in haemorrhagic stroke being more in diastolic blood pressure when compared to ischemic stroke as many of ischemic stroke also were found to be associated with hypertension but did not exceed the 150 mm HG especially for diastolic blood pressure. So, it indicates more the blood pressure, haemorrhagic stroke is more likely.

Headache though a common complaint was found more in cases of haemorrhage and ischemic cases exhibited less of it, thus headache is more likely to be associated with haemorrhage.

In this study, Siriraj score showed positive predictive value of 80.64% for ischemic stroke and negative predictive value of 78.57% for hemorrhagic stroke and the P value is 0.015 (significant).

CONCLUSION

Based on clinical variables such as level of consciousness, blood pressure, atheroma markers and the presence of headache and vomiting, Siriraj Stroke Score, a clinical scoring can be used for the bedside diagnosis of the nature of the lesion in stroke patients where CT scan is not available immediately.

BIBLIOGRAPHY

1. Celani MG, Righetti E, Migliacci R, Zampolini M, Antoniutti L, Grandi CF et al. Comparability and validity of two clinical scores in the early differential diagnosis of acute stroke. *BMJ* 1994; 308: 1674 – 1676.
2. Hung LY, Wang PY, Wang Y, Chia LG. Clinical distinction between acute haemorrhagic and acute ischemic stroke by Siriraj stroke score. *Zhohghuayixuezazhi* 1995; 55:248-252.
3. Pongavarin N, Viriyavejakul A, Komontri C. Siriraj Stroke Score and validation study to distinguish Supratentorial Intracerebral Haemorrhage from Infarction. *BMJ* 1991; 302: 1565 – 1567.
4. Akpononu BE, Mutgi AB, Lee L, Khuder S, Federman DJ, Roberts C. Can a clinical score aid in early diagnosis and treatment of various stroke syndromes? *Am J Med Sci* 1998; 315:194-8.
5. Comparison of Siriraj Stroke Score with computerized tomography in ascertaining stroke type among South Indians. Pavan MR , Madi MD , Achappa B , Unnikrishnan B. *Int J Biol Med Res.* 2012; 3(3): 1930-1933
Journal homepage: www.biomedscidirect.com
6. Comparability and Validity of Clinical Scorings in Differentiating Cerebral Infarct and Hemorrhage Dr. S. Sreevani M.D*, Dr. M. Bhargavi Devi*, M.D, Dr. P. Shakunthala M.D*, Dr. R. Siddeswari, M.D**, Dr. N. Srinivasa Rao, M.D* *International Journal of Scientific and Research Publications*, Volume 5, Issue 2, February 2015 1 ISSN 2250-3153

7. Validation study of the Siriraj Stroke Score in African Nigerians and Evaluation of the Discriminant Values of its Parameters. A Preliminary Prospective CT Scan Study. Kehinde o.KolapoMMCP, FWACP; Shamsideen A.Ogun, Cert. Neurol. (Lond), FWACP; Mustapha A. Danesi, MRCP, FWACP, FMCP; Bamidele Sanya Osalusi, FMCP; Kayode A.Odusote. Stroke 2006 published by American Heart Association.
8. Kochar DK, Joshi A, Agarwal N, Aseri S, Sharma BV, Agarwal TD. Poor diagnostic accuracy and applicability of Siriraj stroke score, Allen score and their combination in differentiating acute haemorrhagic and thrombotic stroke. J Assoc Physicians India 2000; 48: 584 – 588.
9. Wadhawani J, Hussain R, Raman PG. Nature of lesion of Cerebro Vascular Stroke patients, clinical stroke score and computed tomography scan brain correlation. J Assoc Physicians India 2002; 50: 777-781.
10. J Stroke. Sep 2013; 15(3): 128–134
11. Priya Badam, Vaishali Solao, Madhukar Pai, S.P.Kalanthri. The national medical journal of India. Vol. 16, No. 1, 2003.
12. Efstathiou SP, Tsioulos DI, Zacharos ID. A new classification tool for clinical differentiation between haemorrhagic and ischaemic stroke. J Intern Med 2002; 252:121.
13. Salawu F, Umar I, Danburam A. Comparison of hospital stroke scores with computerized Tomography in ascertaining stroke type among Nigerians. Ann Afr Med. 2009; 8:14-8.
14. Connor MD, Modi G, Warlow CP. Accuracy of the Siriraj and Guy's Hospital Stroke Scores in Urban South Africans. Stroke. 2007; 38:62-8. Epub 2006 Nov 30.

PROFORMA

Name :

IP No. :

Sex :

Department :

General Examinations :

Yes

No

Vomiting

Consciousness

Head ache

Blood pressure

Atheromarkers

Score

CT Report

Siriraj Stroke Score

Variable	Clinical features	Score
·Consciousness	Alert	+0X 2.5
	Stupor, DrowsySemicoma,	+1X 2.5
	Coma	+2X 2.5
·Vomiting	No	+0 X 2
	Yes	+1X 2
·Headache within two hours	No	+0X 2
	Yes	+1X 2
·Diastolic blood pressure	---mm Hg	+Diastolic B.P.(x0.1)
·Atheromamarkers [Diabetes, Angina, Intermittent Claudication]	None	-0 X3
	One or more	-1X3
·Constant		-12

>1 = hemorrhage; < -1 =Infarction; -1 to +1 =equivocal.

S.No:	Name	Age	Sex	Consciousness	Vomiting	Headache within 2 hrs	Diastolic BP	Atheroma markers		CT Brain H-Haemorrhage I - Infarction E - Equivocal
1	ANNATHAI	56	M	0	0	0	160	1	1.5	H
2	RATHINA PAUL	57	M	1	0	0	163	2	1.8	H
3	RASOOL BEEVI	53	M	1	0	0	150	2	-0.5	I
4	MUNIAPPAN	54	M	2	0	0	153	2	2.3	H
5	PANDI	58	F	1	0	0	161	2	1.6	H
6	EUACHI	51	M	1	0	0	149	2	-0.6	I
7	KASIPANDI	61	F	1	0	0	159	2	-0.1	I
8	SUNDAR	57	M	1	0	0	156	2	-0.1	I
9	LAKSHMI	45	M	1	0	0	163	2	-0.8	I
10	JEEMNA	75	F	1	0	0	163	2	-0.8	I
11	SIVAGURUNATHAN	53	M	0	1	1	154	2	1.4	H
12	EASWARAN	52	M	1	0	0	147	2	-0.8	I
13	SUNDARAJAN	61	F	1	0	0	162	2	-0.7	I
14	SURESH	67	F	1	0	0	157	2	-0.2	I
15	AYYADURAI	58	M	1	0	0	148	2	-0.7	I
16	SEKAR	51	M	1	0	0	150	2	-0.5	I
17	PATTU	53	F	1	0	0	162	2	-0.7	I
18	THANGARAJ	64	M	1	0	0	158	2	-0.3	I
19	GURUNATHAN	68	M	1	0	0	161	0	4.4	H
20	SINGARAJ	76	F	1	0	0	160	2	2.8	I
21	RAVI	80	F	1	0	0	158	2	6.7	I
22	ARUNACHALAM	43	F	0	1	1	154	1	-0.4	H
23	LAKSHMIAMMAL	71	F	0	0	0	148	0	-0.2	H
24	SHAHUL HAMEED	58	M	1	0	0	162	0	-0.4	H
25	YOGAMMAL	74	M	1	0	0	159	2	-0.2	I
26	SELVI	73	M	1	0	0	157	2	-0.2	I
27	KANAGARAJ	61	F	1	0	0	159	2	-0.4	I
28	MARIAPPAN	52	M	0	0	0	150	0	3	H
29	PERIYASAMY	43	F	1	1	1	145	1	6	H
30	PETCHIMUTHU	72	M	1	0	0	163	2	-0.8	I
31	ANANDHARAJ	64	M	1	0	0	159	2	-0.4	I
32	JEYARANI	77	F	0	1	0	160	0	6	H
33	KALIMUTHU	45	M	1	0	0	164	2	-0.9	I
34	SANKAR	69	M	1	1	1	155	2	0.7	H
35	MANDIRAN	55	F	1	0	0	162	2	4.1	I
36	AMMAPONNU	56	M	1	1	1	156	2	5.3	H

37	PARAMASIVAM	73	M	2	0	0	153	1	0	H
38	KANNAN	70	M	0	1	0	160	2	-0.2	E
39	MARIAPPAN	43	F	1	0	0	157	2	3	I
40	MUTHUPETCHI	49	M	0	1	1	140	1	2.2	H
41	CHANDRAN	52	M	2	0	0	152	2	-0.8	H
42	RAJAKUMARI	42	M	1	0	0	147	2	1.9	I
43	KANDAN	72	F	1	1	0	154	2	1	H
44	MURUGAN	66	M	1	0	0	165	2	0.8	E
45	CHELLAPPA	54	M	1	0	0	163	2	-0.3	E
46	PADMAVATHI	65	F	1	0	0	152	2	-0.2	I
47	MURUGAN	63	M	1	0	0	157	2	1.7	I
48	NAGESHWARI	53	M	2	1	0	127	2	-0.4	E
49	MARIAPPAN	68	F	1	0	0	151	2	0.8	E
50	SIVAKUMAR	47	M	1	0	0	163	2	-0.6	I
51	MURUGAN	51	M	1	0	0	149	2	0.7	E
52	PALANIRAJ	46	F	1	0	0	162	2	-2.5	I
53	VIJAYASHREE	76	M	0	0	0	155	2	0.5	I
54	CHELLAMMAL	62	M	1	0	0	160	2	2	E
55	ESWARAN	74	M	2	0	0	150	2	-0.7	E
56	PATTAMMAL	61	F	1	0	0	162	2	-0.9	I
57	SENTHIL	44	M	1	0	0	146	2	1.4	I
58	KANAGAMANI	73	M	1	1	0	149	2	0.3	E
59	MANIKANDAN	57	M	1	0	0	158	2	0.4	E
60	SARASWATHI	78	F	1	0	0	159	2	0.4	E



MADURAI MEDICAL COLLEGE
MADURAI, TAMILNADU, INDIA -625 020

(Affiliated to The Tamilnadu Dr.MGR Medical University,
 Chennai, Tamil Nadu)



Prof Dr V Nagaraajan MD MNAMS
 DM (Neuro) DSc.(Neurosciences)
 DSc (Hons)
 Professor Emeritus in Neurosciences,
 Tamil Nadu Govt Dr MGR Medical
 University
 Chairman, IEC

Dr.R.Parameswari, MD., Member
 Secretary,
 Director & Professor of
 Pharmacology, Madurai Medical
 College, Madurai.

Members

1. Dr.K.Meenakshisundaram, MD
 (Physiology)Vice Principal,
 Madurai Medical College
2. Dr.G.Veerasekar, MS., (Plastic
 Surgery)Medical Superintendent,
 Govt. Rajaji Hospital, Madurai
- 3.Dr.R.Balajinathan,MD(General
 Medicine) i/c Professor of Medicine,
 Madurai Medical College, Madurai.
- 4.Dr.A.Sankaramahalingam,
 MS.,Professor & H.O.D. Surgery,
 Madurai Medical College & Govt.
 Rajaji Hospital, Madurai.
- 5.Dr.G.Meenakumari,
 MD.(Pathology) Professor & H.O.D of
 Pathology, Madurai Medical
 College, Madurai
- 6.Mrs.Mercy Immaculate Rubalatha,
 M.A., B.Ed., Social worker, Gandhi
 Nagar, Madurai
- 7.Thiru.Pala.Ramasamy, B.A.,B.L.,
 Advocate, Palam Station Road,
 Sellur.
- 8.Thiru.P.K.M.Chelliah, B.A.,
 Businessman,21, Jawahar Street,
 Gandhi Nagar, Madurai.


**ETHICS COMMITTEE
 CERTIFICATE**

Name of the Candidate : Dr.HIBU JULI
 Course : PG in MD, GENERAL MEDICINE
 Period of Study : 2014-2017
 College : MADURAI MEDICAL COLLEGE
 Research Topic : VALIDITY OF SIRIRAJI RISK
 SCORE IN DIFFERENTIATING
 CEREBRAL INFARCT AND
 HAEMORRHAGEIN, SOUTH
 INDIANS
 Ethical Committee as on : 08.02.2016

The Ethics Committee, Madurai Medical College has decided to
 inform that your Research proposal is accepted.


 Member Secretary


 Chairman


 Dean / Convenor
DEAN
 Madurai Medical College
 Madurai-20





Digital Receipt

This receipt acknowledges that Turnitin received your paper. Below you will find the receipt information regarding your submission.

The first page of your submissions is displayed below.

Submission author: 201411105 Md Genmed Hibu Juli
Assignment title: 2015-2015 plagiarism
Submission title: VALIDITY OF SIRIRAJ STROKE SC...
File name: Dr_Hibu_Juli_-_General_Medicine_..
File size: 424.5K
Page count: 85
Word count: 16,979
Character count: 94,259
Submission date: 22-Sep-2016 04:45PM
Submission ID: 708592174

VALIDITY OF SIRIRAJ STROKE SCORE IN
DIFFERENTIATING CEREBRAL INFARCT AND
HAEMORRHAGE IN SOUTH INDIANS

DISSERTATION SUBMITTED FOR THE
AWARD OF THE DEGREE OF

M.B. GENERAL MEDICINE
(BRANCH - I)
APRIL - 2017



DEPARTMENT OF GENERAL SURGERY
MADURAI MEDICAL COLLEGE
MADURAI-625028
THE TAMILNADU
DR.M.G.R. MEDICAL UNIVERSITY,
CHENNAI

201411105 Md Genmed Hibu Juli User Info Messages Student English Help Logout

turnitin

Class Portfolio Peer Review My Grades Discussion Calendar

NOW VIEWING: HOME > THE TAMIL NADU DR.M.G.R.MEDICAL UTY 2015-16 EXAMINATIONS

Class Homepage

This is your class homepage. To submit to an assignment click on the "Submit" button to the right of the assignment name. If the Submit button is grayed out, no submissions can be made to the assignment. If resubmissions are allowed the submit button will read "Resubmit" after you make your first submission to the assignment. To view the paper you have submitted, click the "View" button. Once the assignment's post date has passed, you will also be able to view the feedback left on your paper by clicking the "View" button.

Assignment Inbox: The Tamil Nadu Dr.M.G.R.Medical Uty 2015-16 Examinations

Info	Dates	Similarity
2015-2015 plagiarism	Start 23-Nov-2015 2:27PM Due 07-Nov-2016 11:59PM Post 01-Dec-2015 12:00AM	19% ■

Resubmit View Download

Copyright © 1998 – 2016 Turnitin, LLC. All rights reserved.
Usage Policy Privacy Pledge Helpdesk Research Resources

preferences

turnitin Processed on: 22-Sep-2016 17:48 IST
ID: 708592174
Originality Report Word Count: 16979
Submitted: 2

VALIDITY OF SIRIRAJ STROKE SCORE IN DIFFERENT...
By 201411105 Md Genmed Hibu Juli

Document Viewer

Similarity Index	Similarity by Source
19%	Internet Sources: 18% Publications: 3% Student Papers: 1%

include quoted include bibliography excluding matches < 12 words mode: show highest matches together

VALIDITY OF

SIRIRAJ STROKE SCORE IN DIFFERENTIATING CEREBRAL INFARCT AND HAEMORRHAGE IN 12

SOUTH INDIANS DISSERTATION SUBMITTED FOR THE AWARD OF THE DEGREE OF M.D. GENERAL MEDICINE (BRANCH - I) APRIL - 2017 DEPARTMENT OF GENERAL SURGERY MADURAI MEDICAL COLLEGE MADURAI 625020 THE TAMILNADU DR.M.G.R. MEDICAL UNIVERSITY, CHENNAI INTRODUCTION

Stroke is the second leading cause of death worldwide, causing 6.2 million deaths in 2011. 16

Stroke is a major health issue not only because it is a major cause of death but also because it leaves patients with several residual disabilities like physical dependence, dementia and depression. 2

"Computed tomography (CT) scan is an accurate, safe, non-invasive procedure routinely used as an investigative tool for stroke to distinguish between infarction and haemorrhage. Computed tomography scanning of brain is expensive in both the initial investment and maintenance. In developing countries like India, cost and availability constraints prohibit its widespread use especially in rural areas. Clinical stroke scores were developed to overcome these limitations. Differential diagnosis between infarction and haemorrhage can be made on clinical grounds with aid of Siriraj Scoring System. CT scan is not readily available in semi-urban and rural areas and the scoring systems will then come into play in differentiating the stroke subtype. This study is being done to determine the sensitivity, specificity of Siriraj score." AIMS AND OBJECTIVES 1.

To differentiate between cerebral infarct and intra cerebral hemorrhage on the basis of Siriraj Stroke Score. 2. To 2

- 14% match (Internet from 21-Apr-2016)
<http://www.federaljack.com>
- 1% match (Internet from 28-Sep-2012)
<http://www.biomedscidirect.com>
- 1% match (Internet from 22-May-2011)
<http://neurosm.tripod.com>
- 1% match (Internet from 04-Sep-2016)
<https://fr.scribd.com/document/259262754/Care-ICU-Fluids-Electrolytes-and-Nutrition-epub>
- 1% match (student papers from 05-Nov-2013)
[Submitted to Higher Education Commission Pakistan](#)
- 1% match (Internet from 27-Jul-2008)
<http://www.accessmedicine.com>
- < 1% match (publications)
[R. D. Adams, "Recent Developments in Cerebrovascular Diseases", BMJ, 04/05/1958](#)