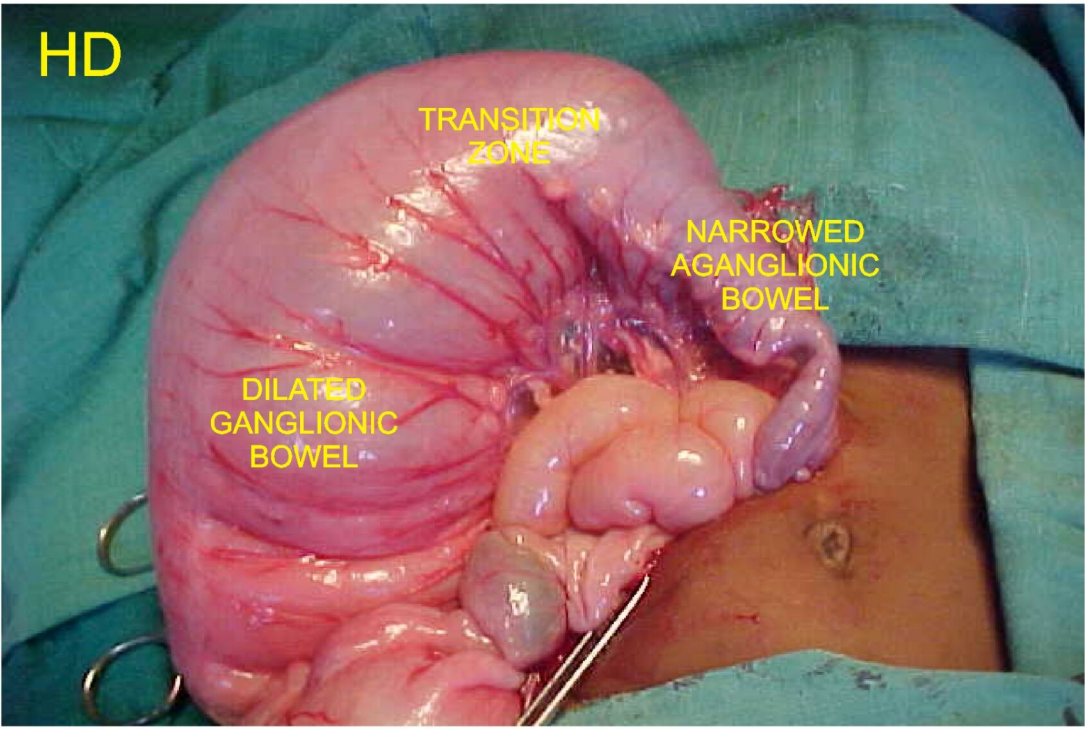
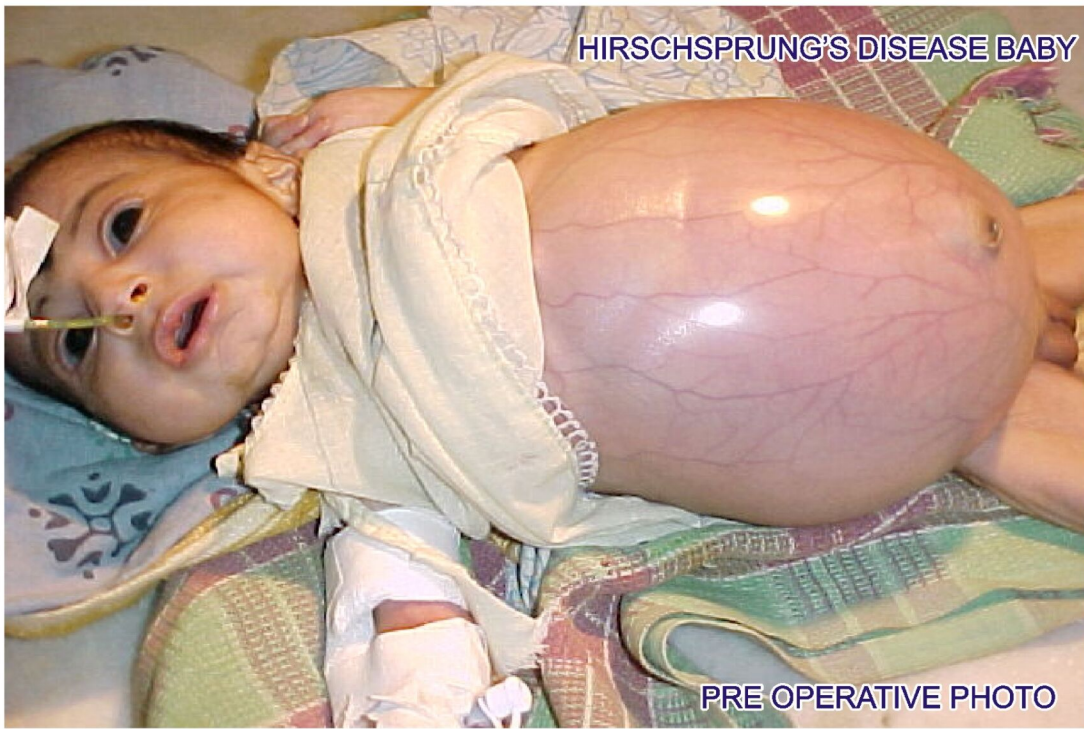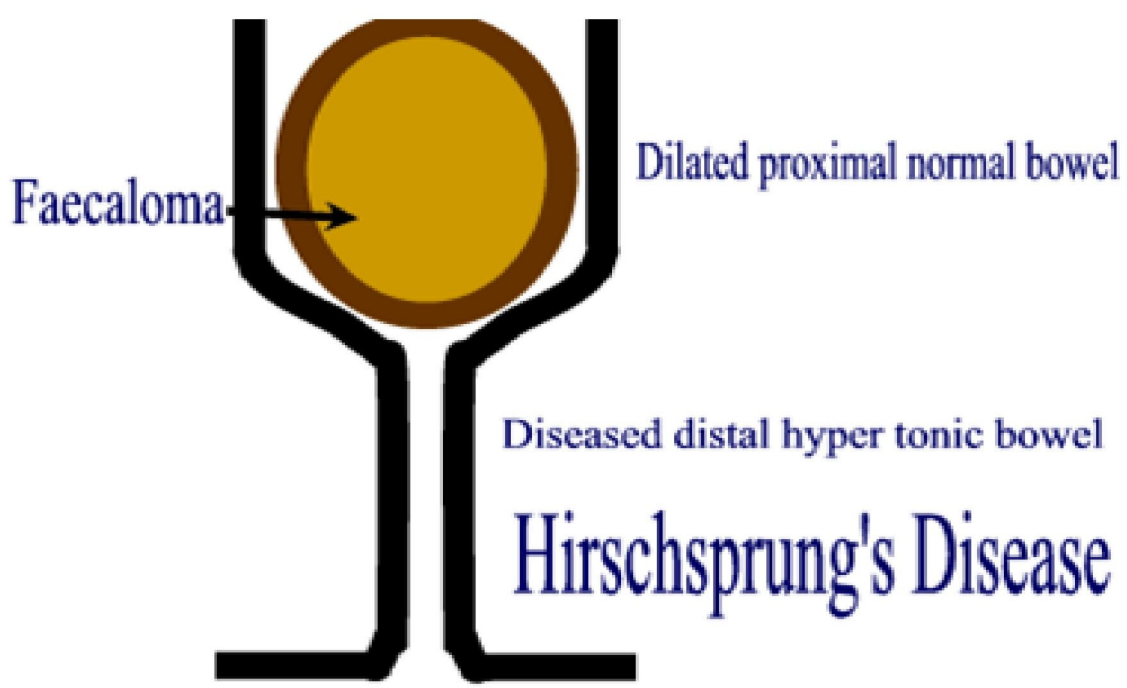
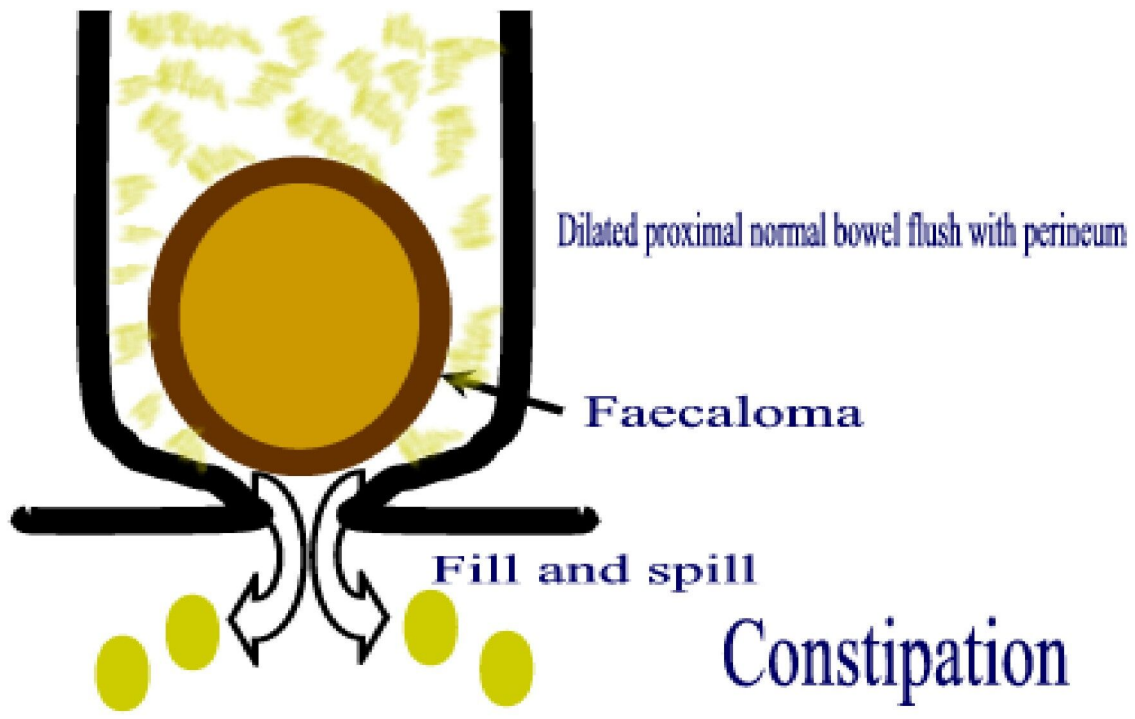
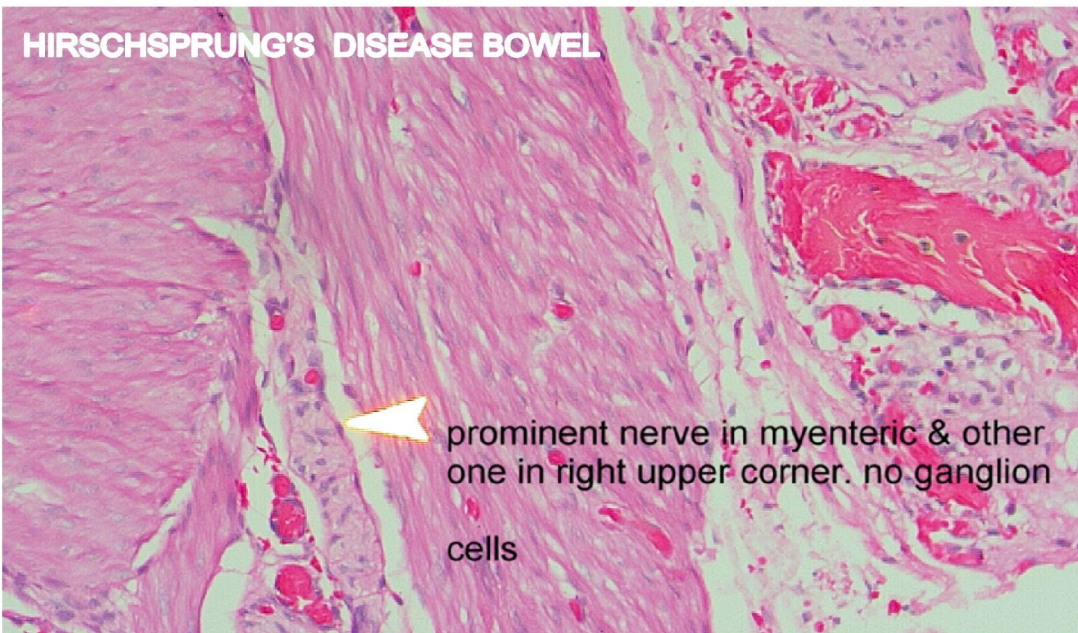
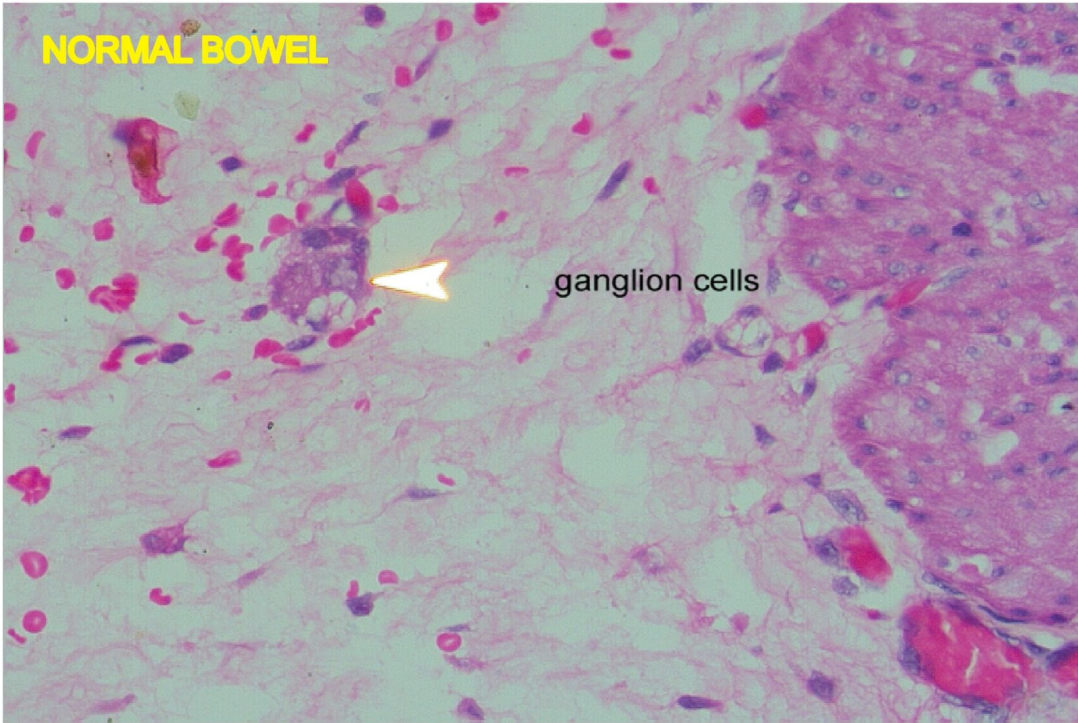


HD

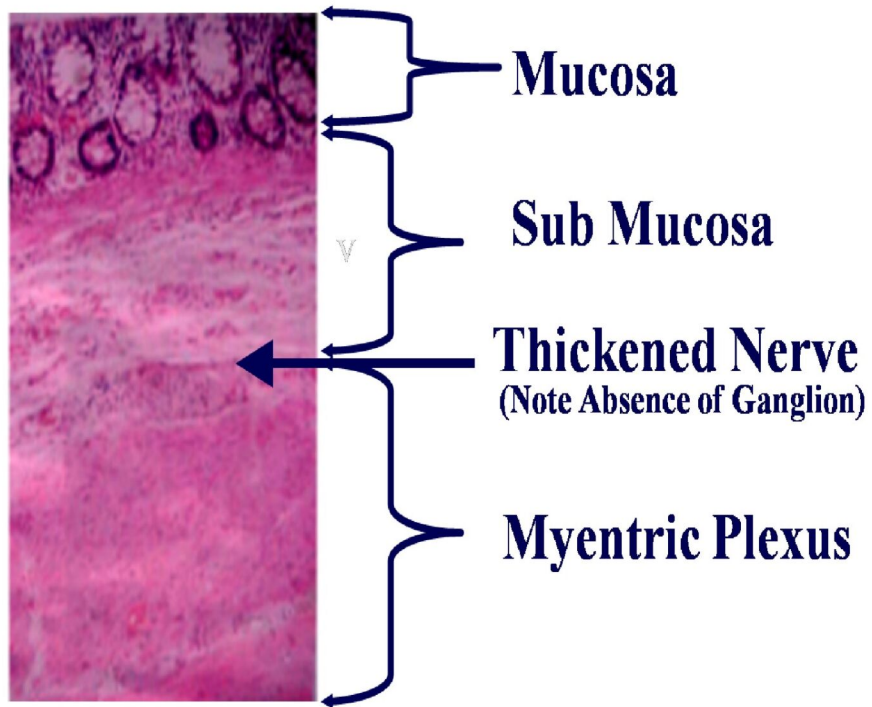


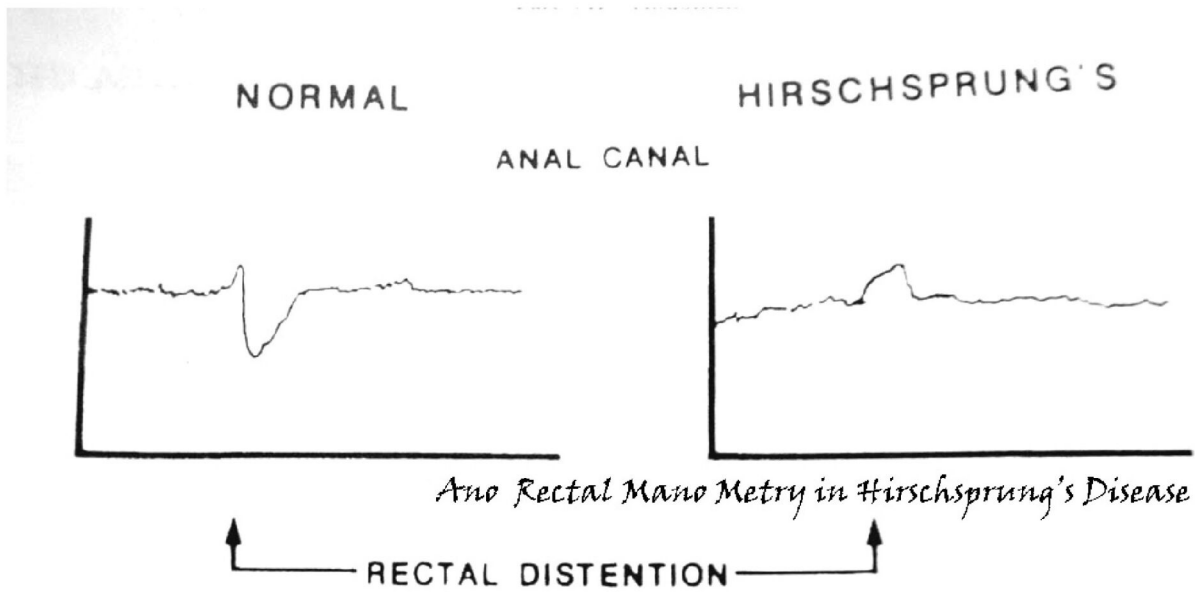






HISTOLOGICAL PICTURE OF HIRSCHSPRUNG'S DISEASE BOWEL





NORMAL

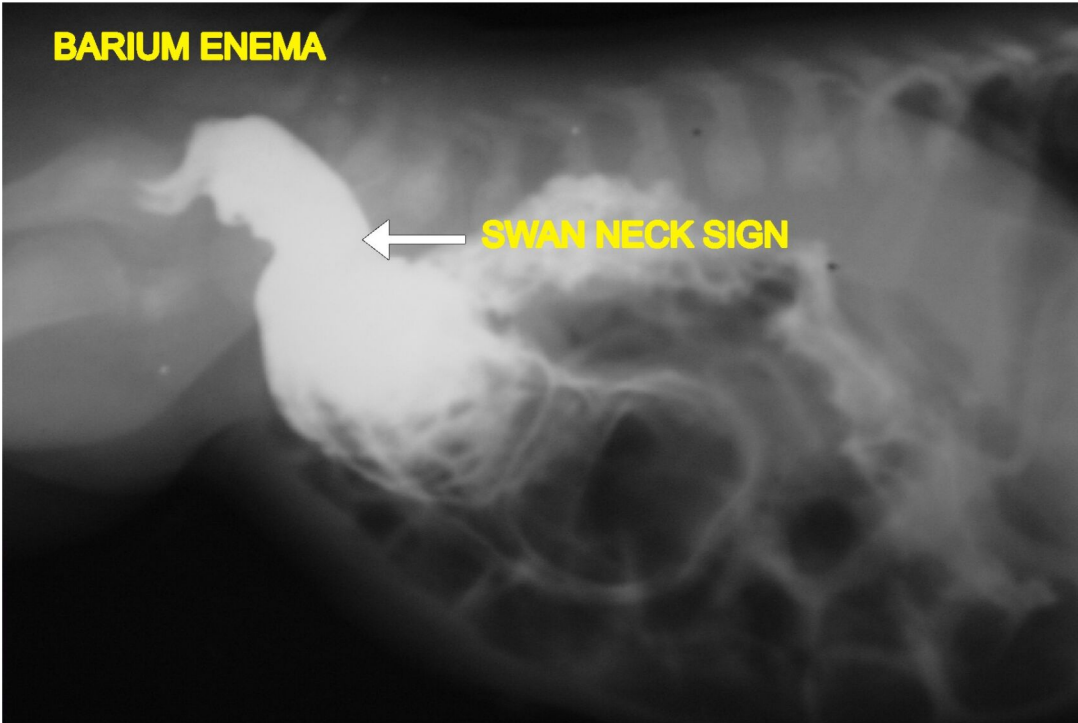
HIRSCHSPRUNG'S

ANAL CANAL

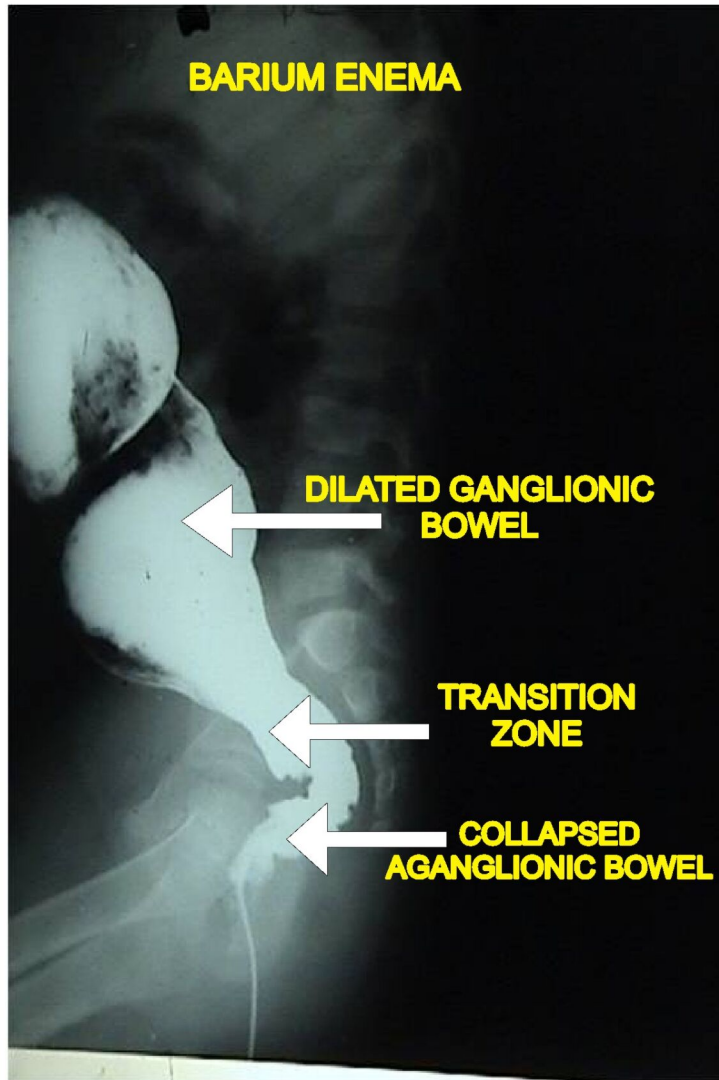
Ano Rectal Mano Metry in Hirschsprung's Disease

RECTAL DISTENTION

BARIUM ENEMA

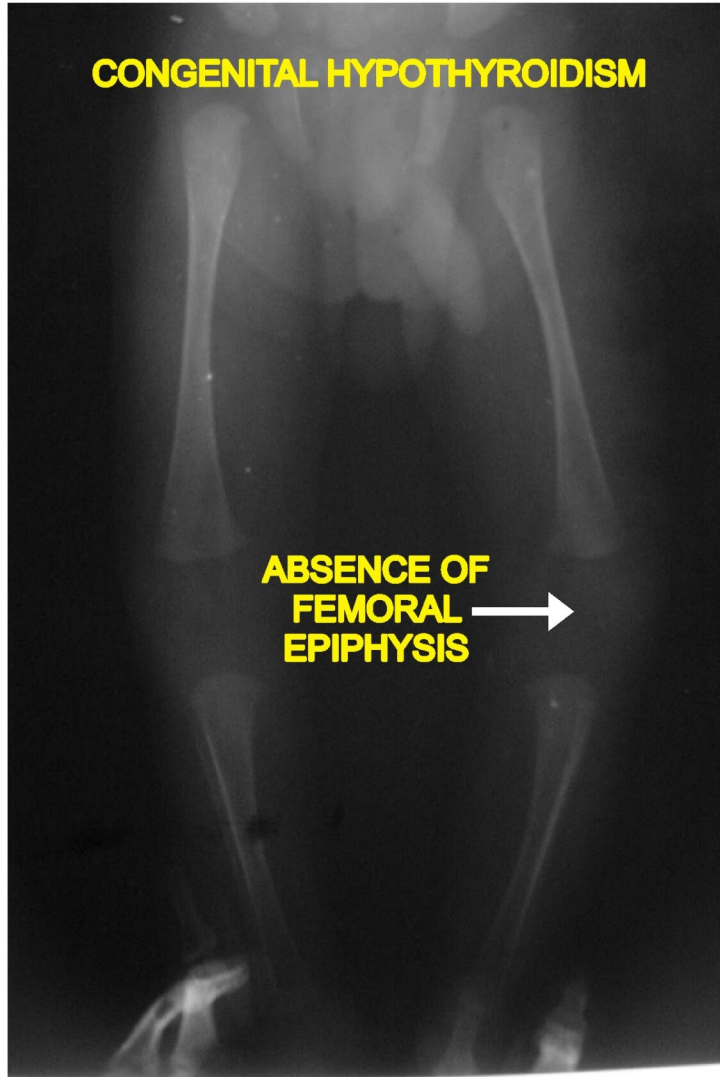


BARIUM ENEMA

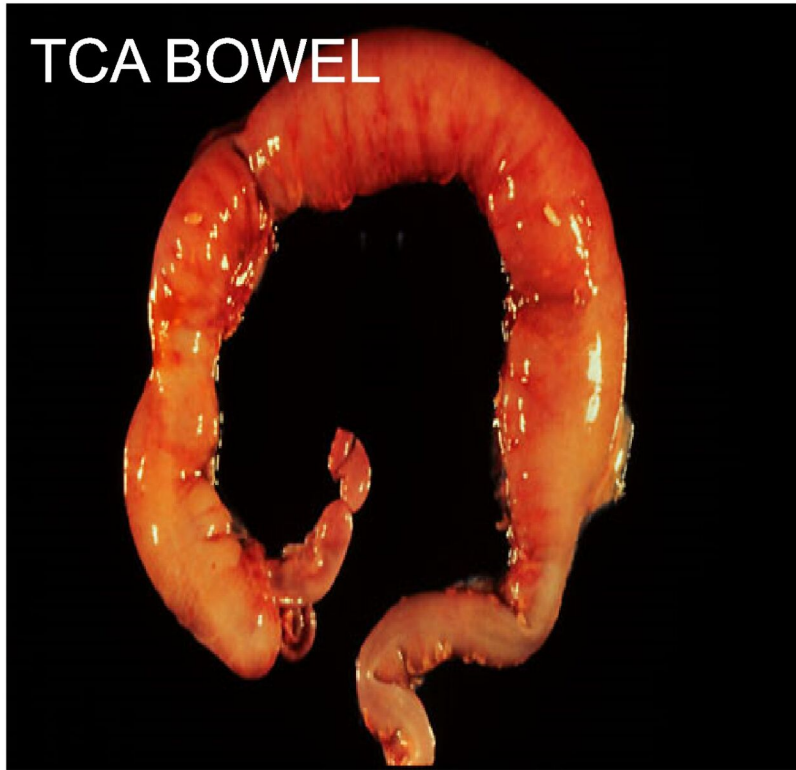

CONGENITAL HYPOTHYROIDISM

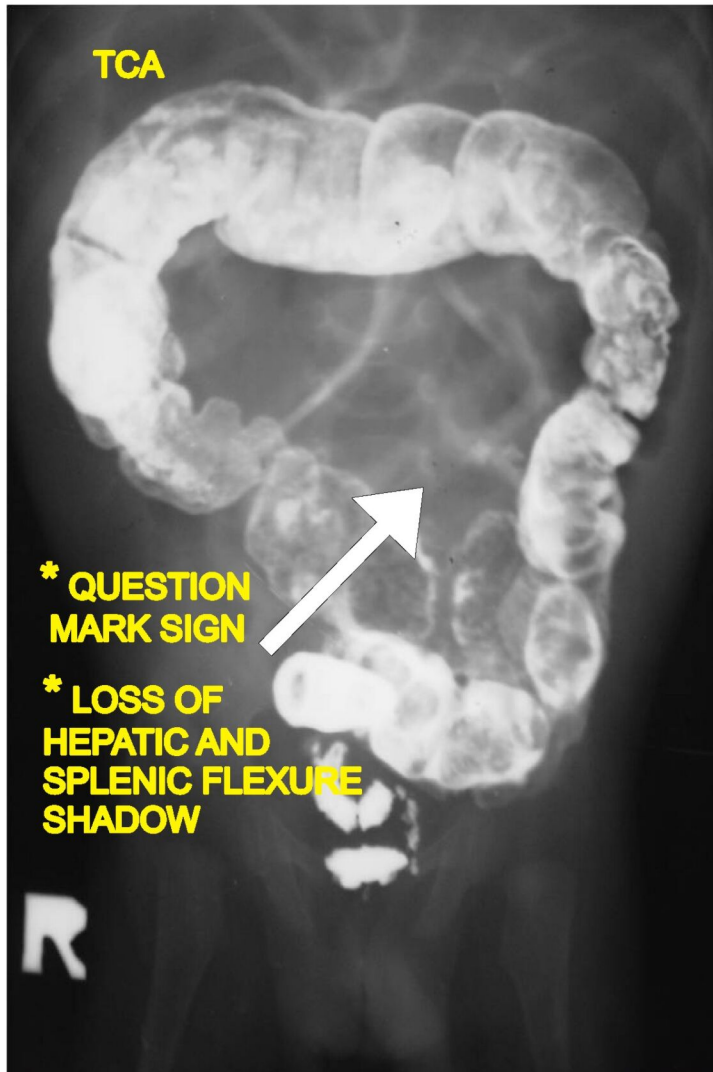**ABSENCE OF
FEMORAL
EPIPHYSIS** →



TCA BOWEL

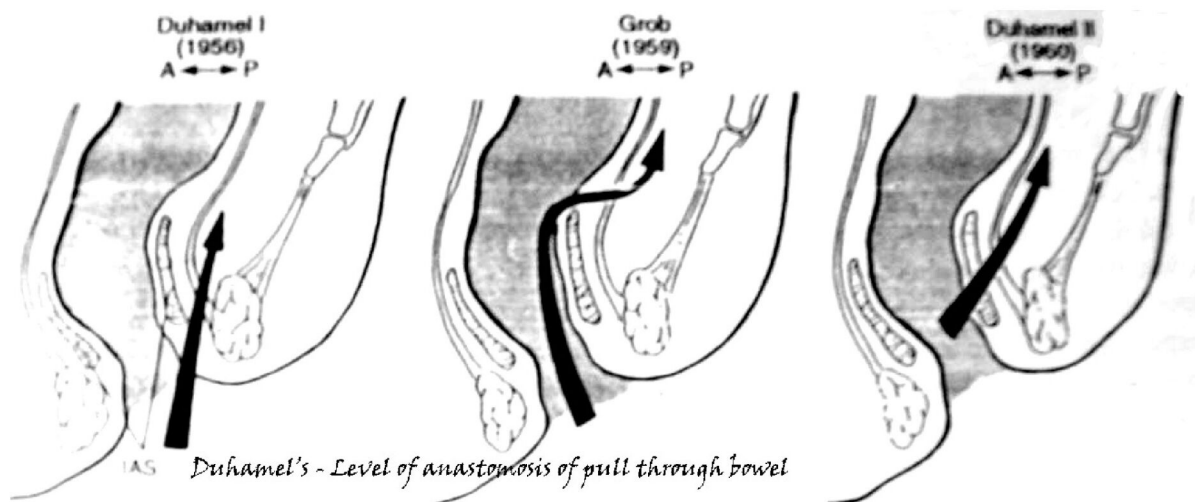


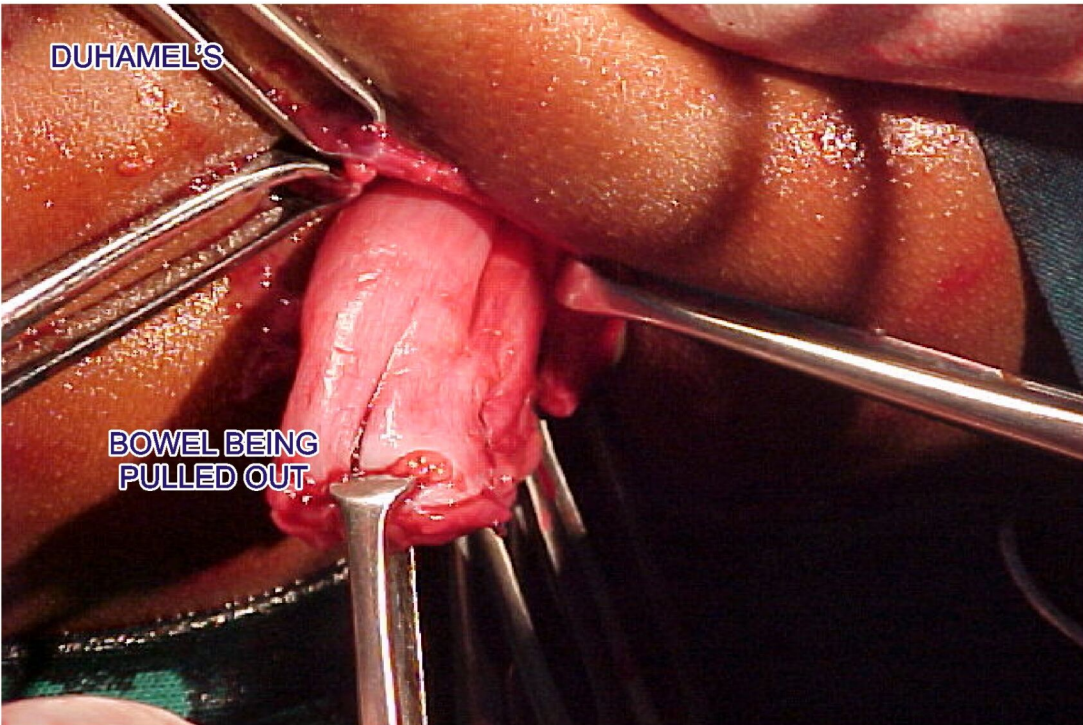
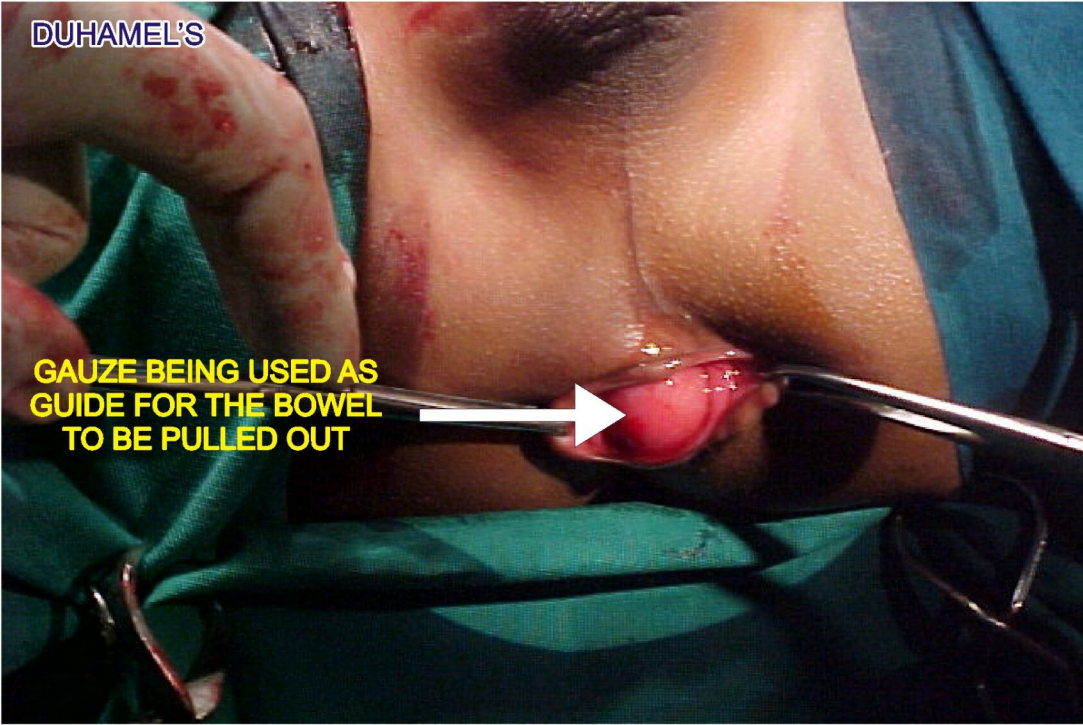
TCA

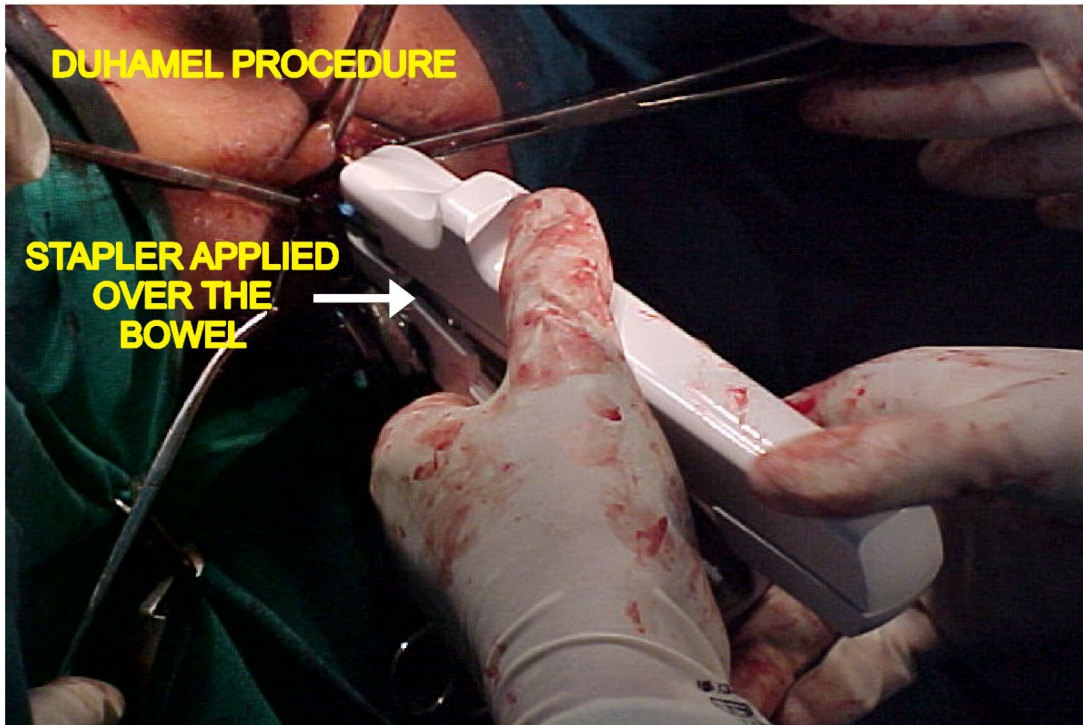
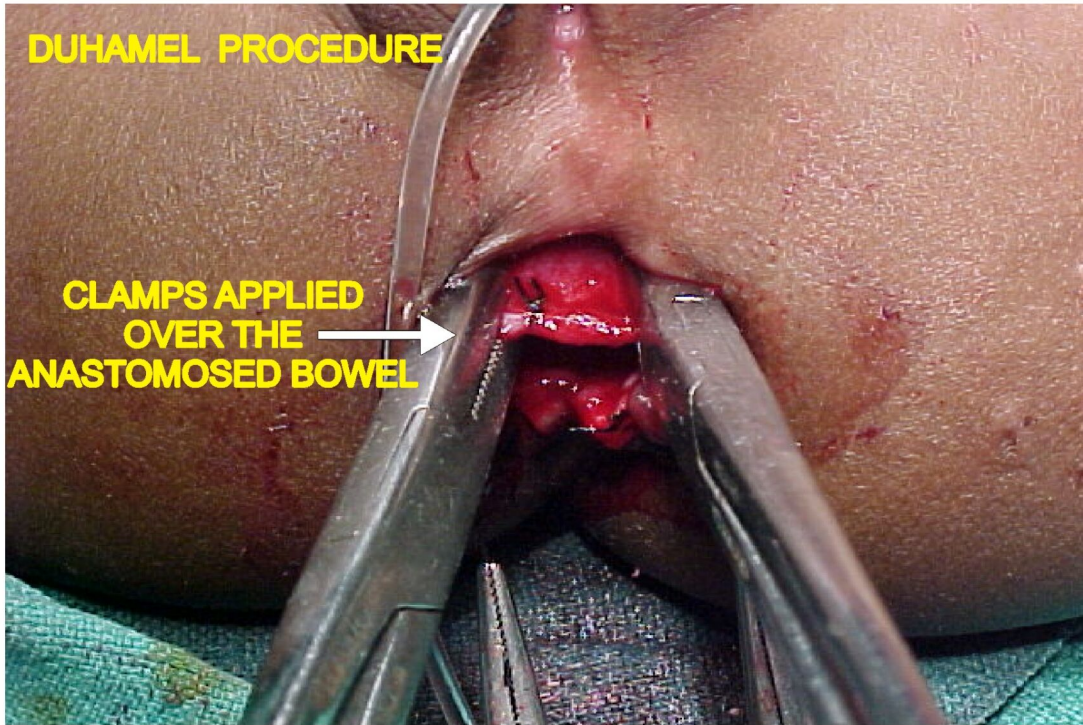


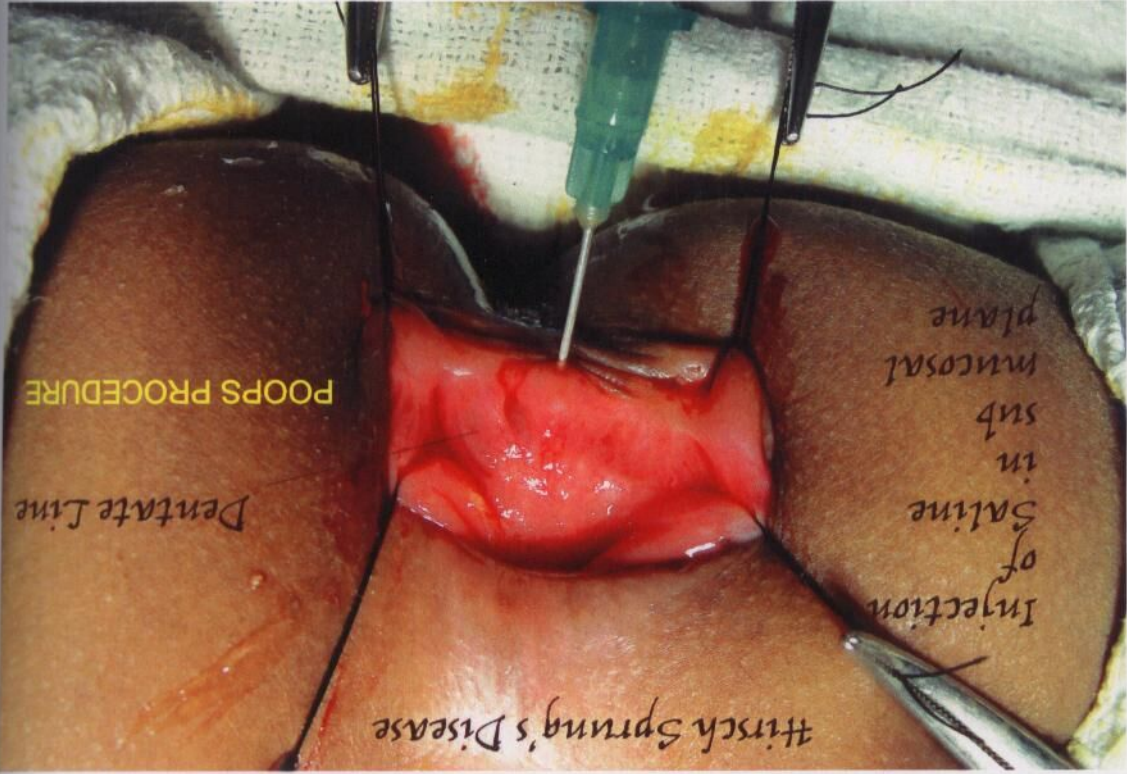
* QUESTION
MARK SIGN

* LOSS OF
HEPATIC AND
SPLENIC FLEXURE
SHADOW

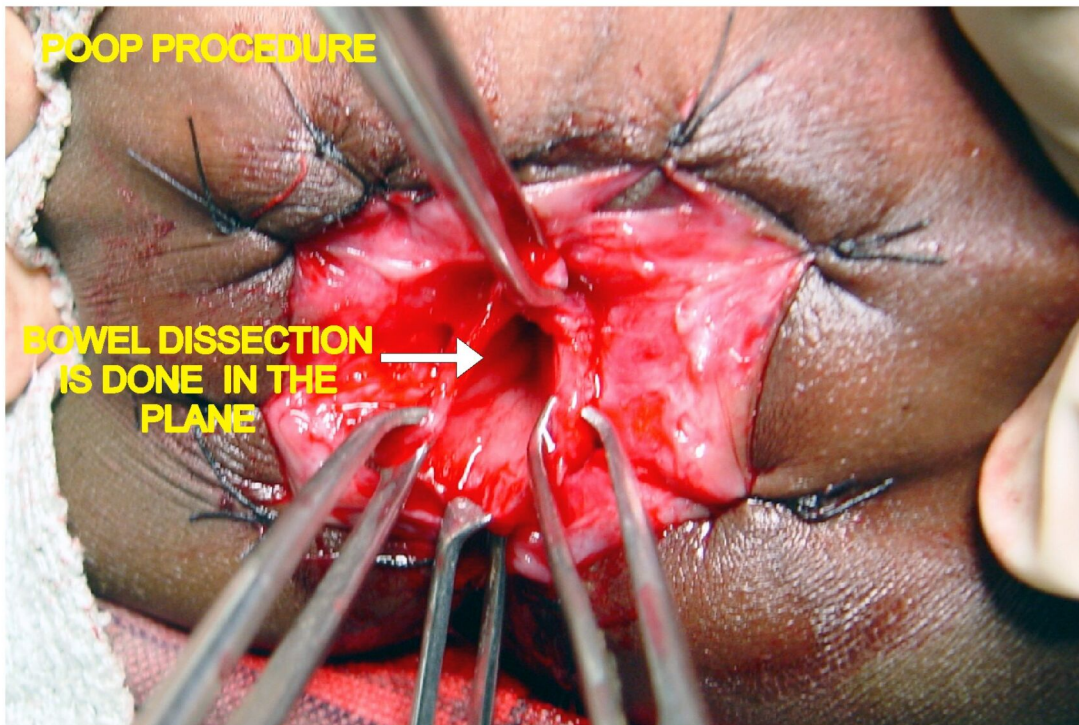
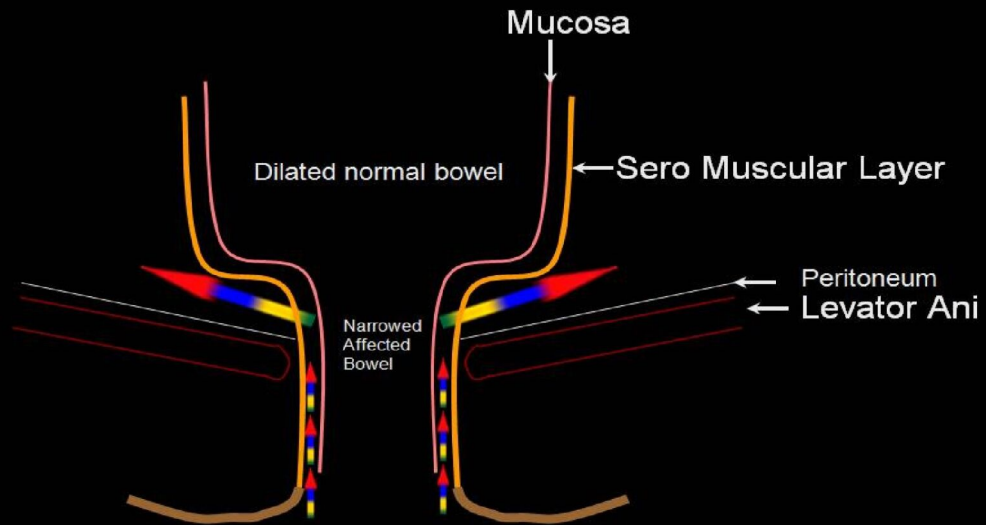


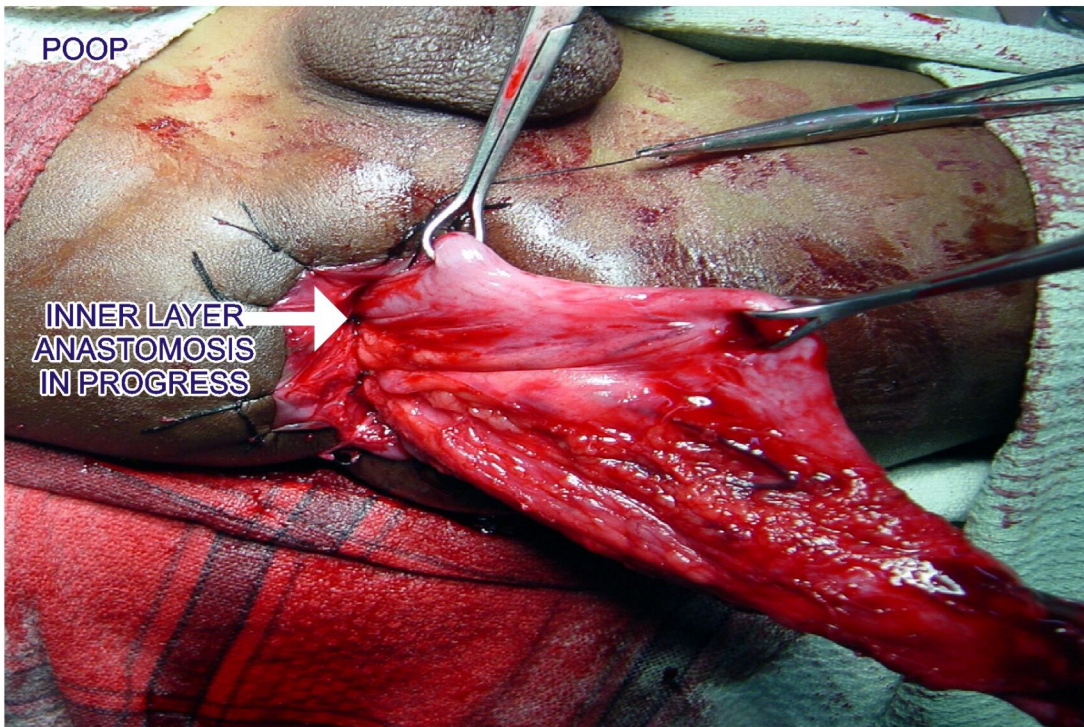
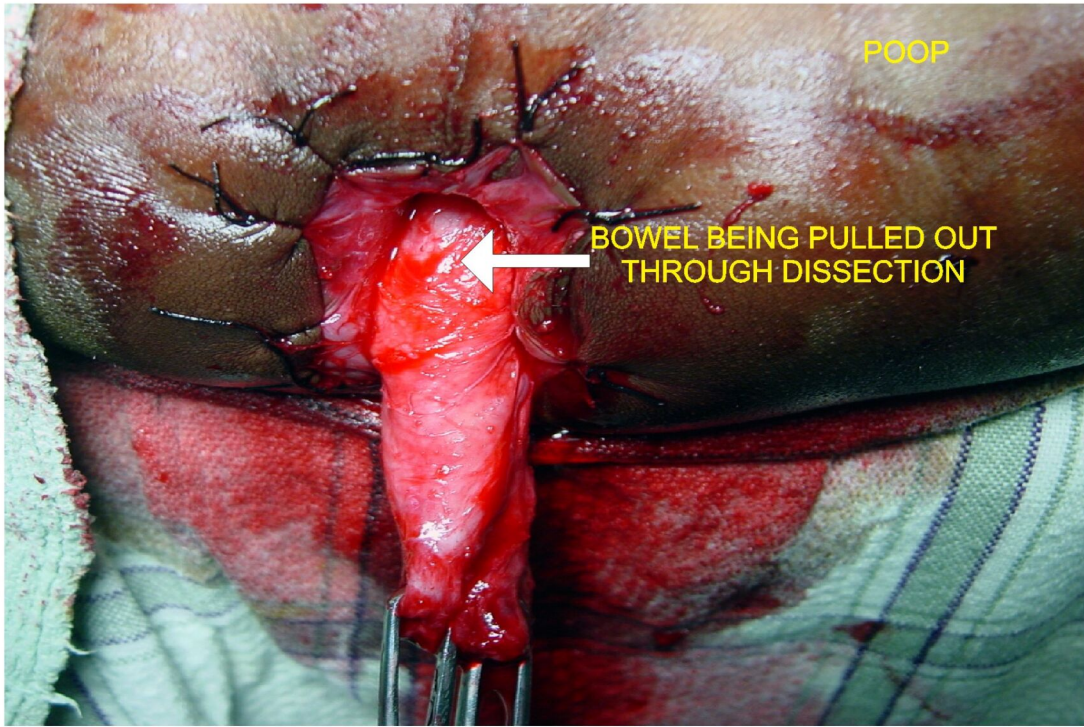


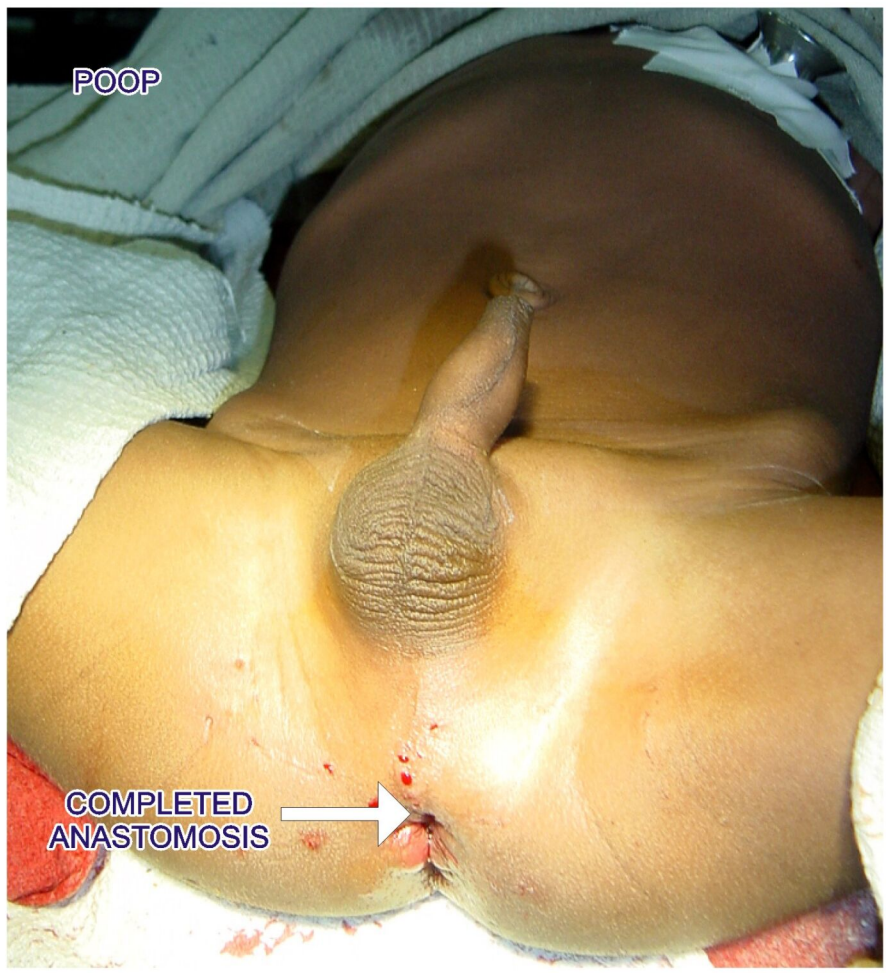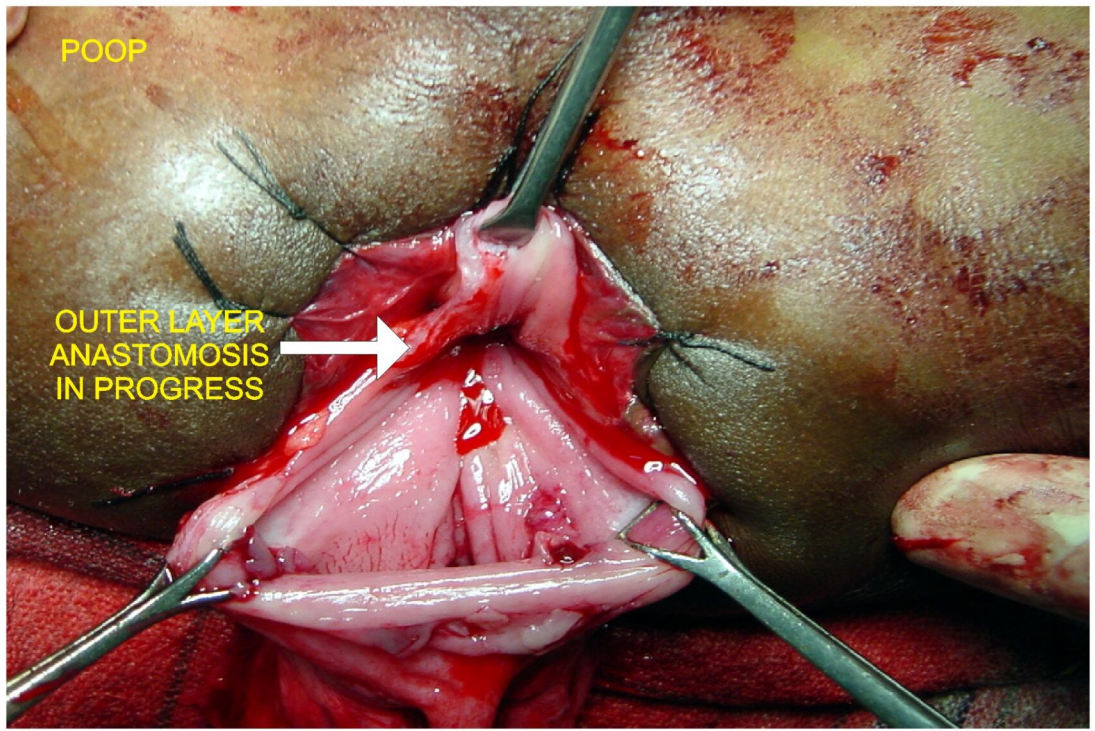


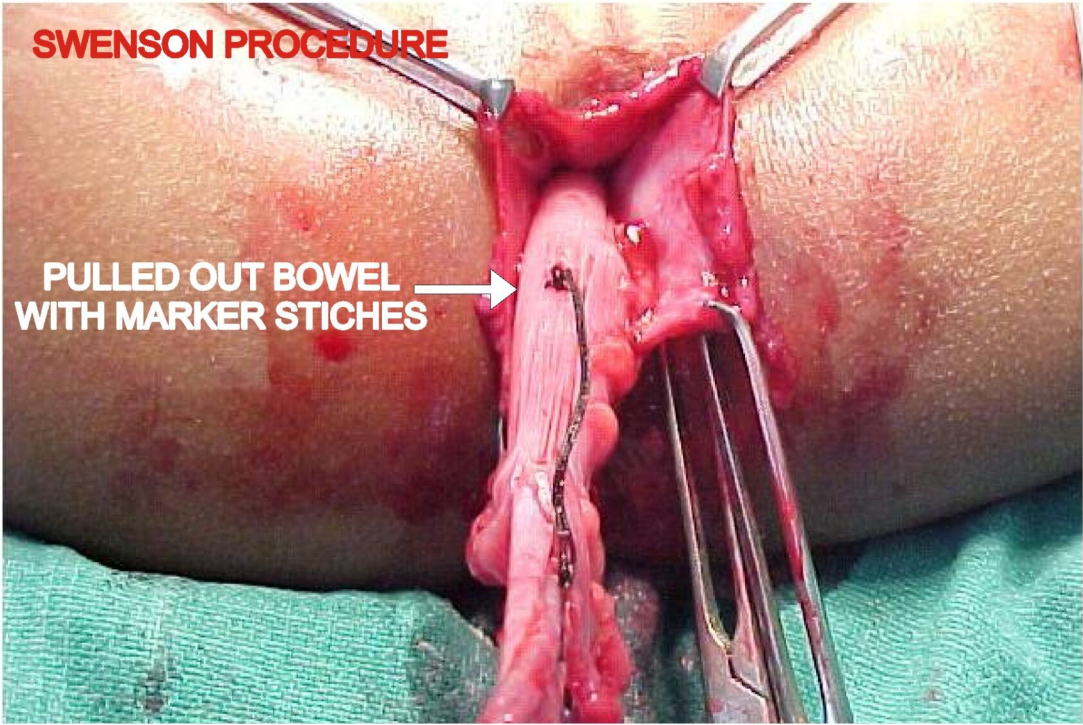
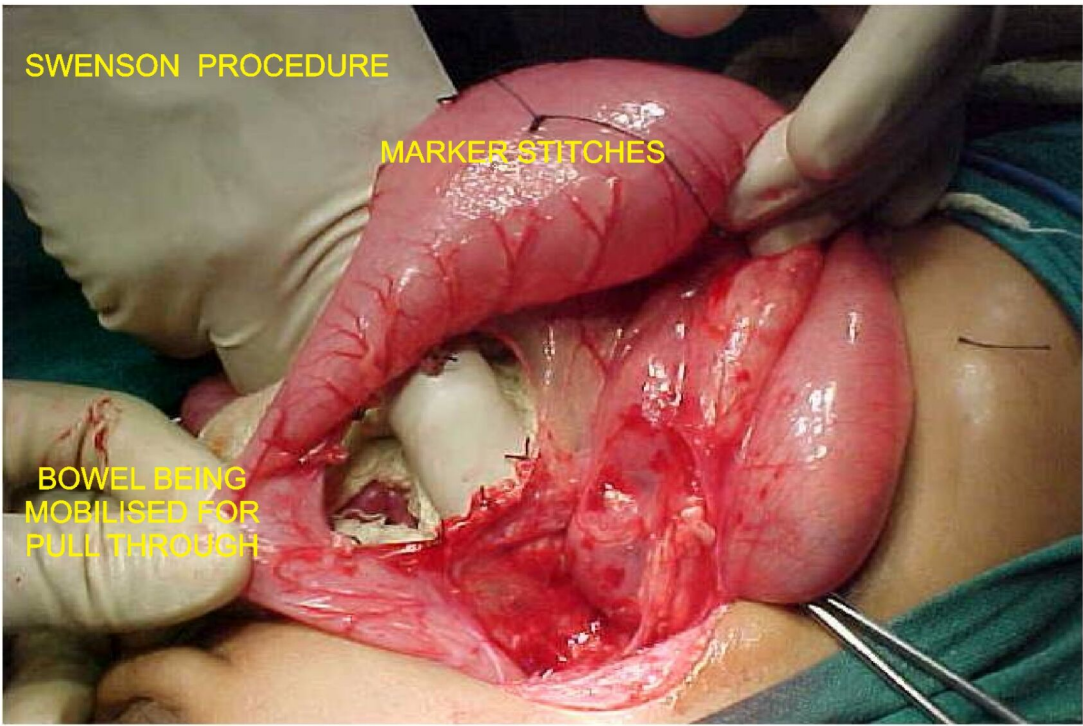


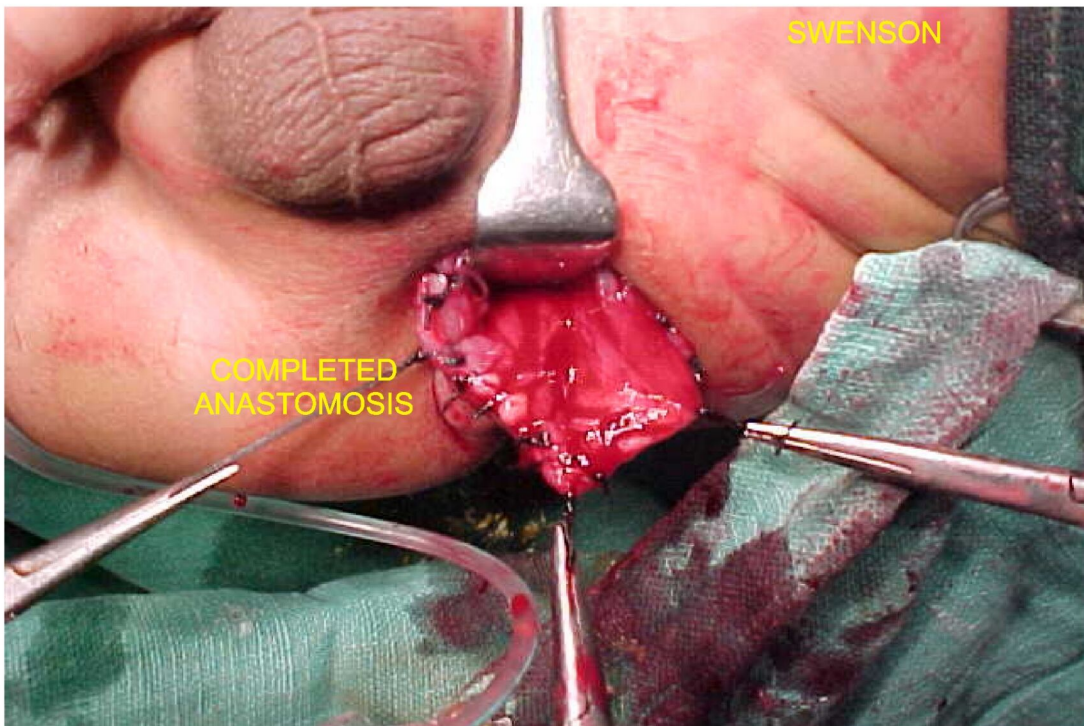
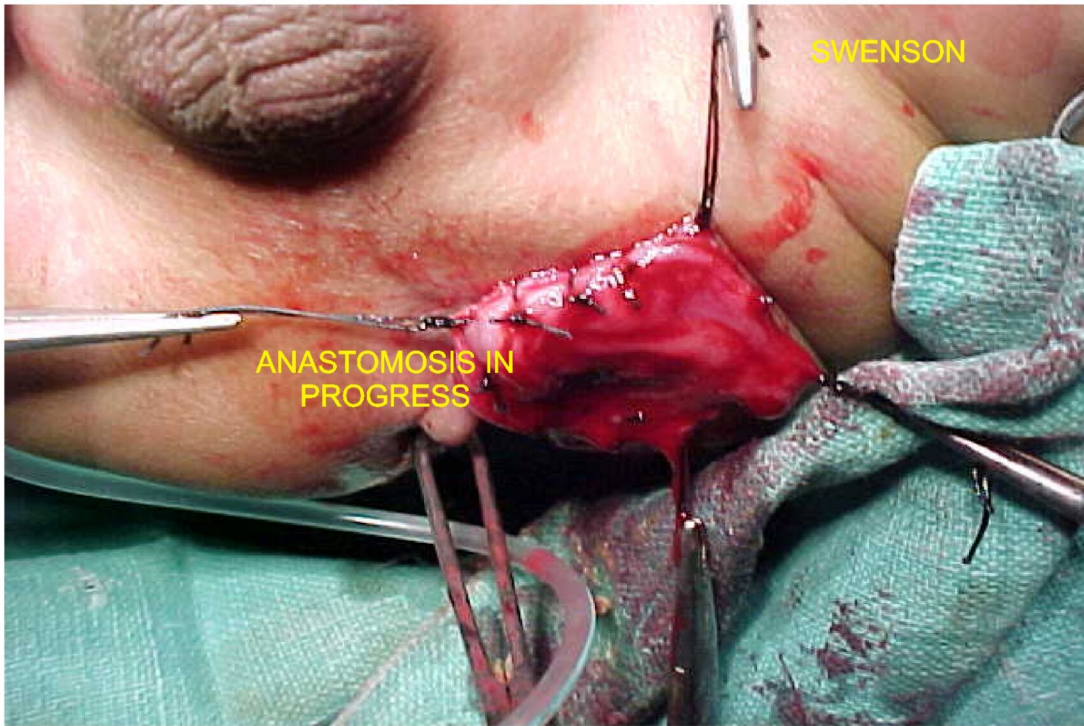
Plane of dissection in POOP

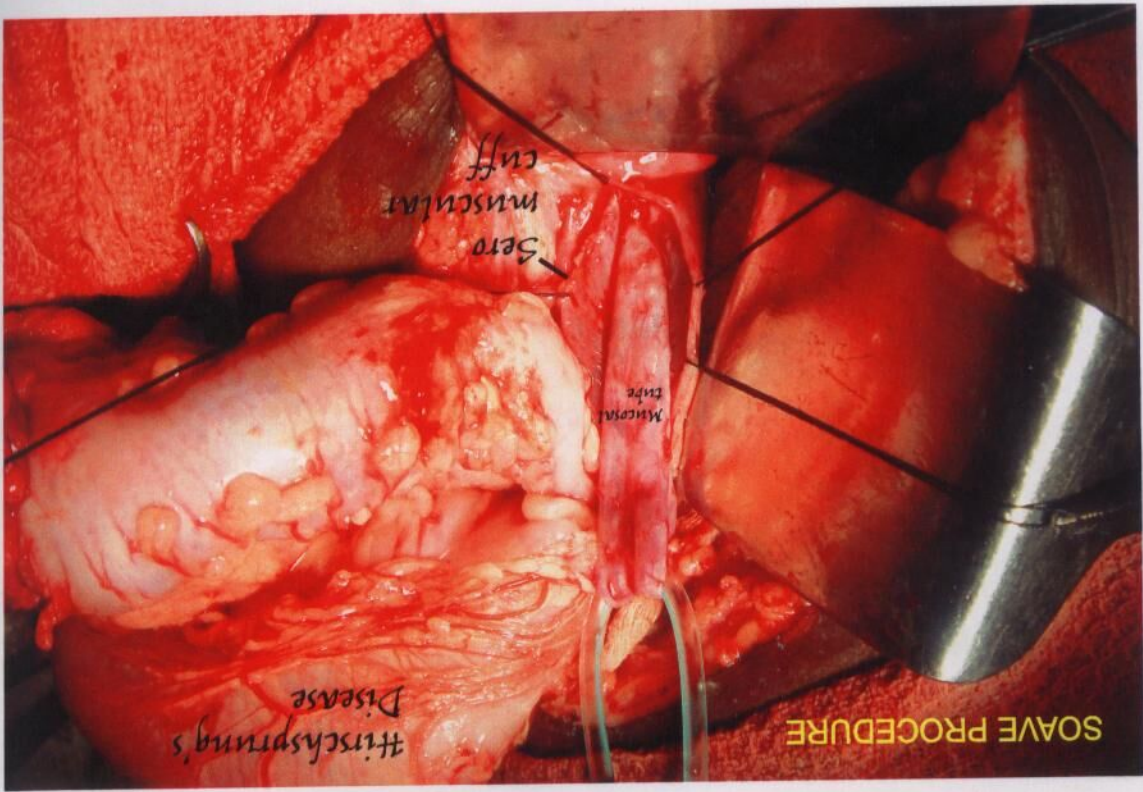
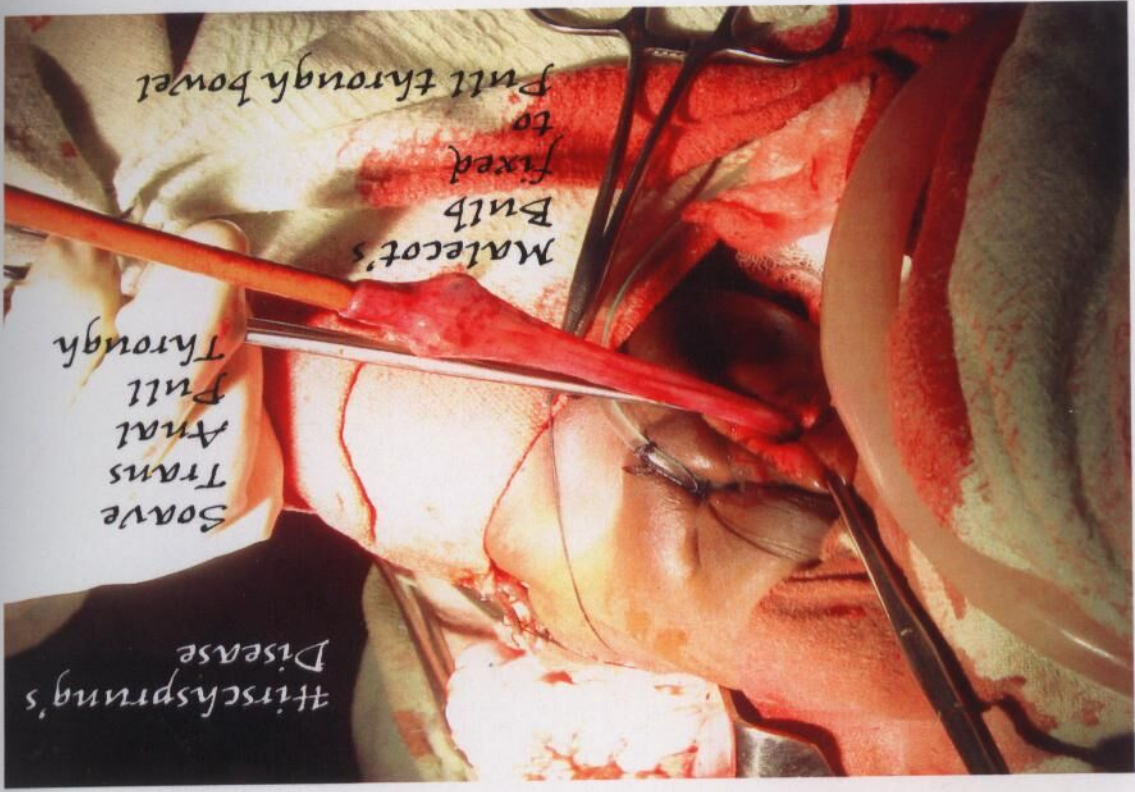


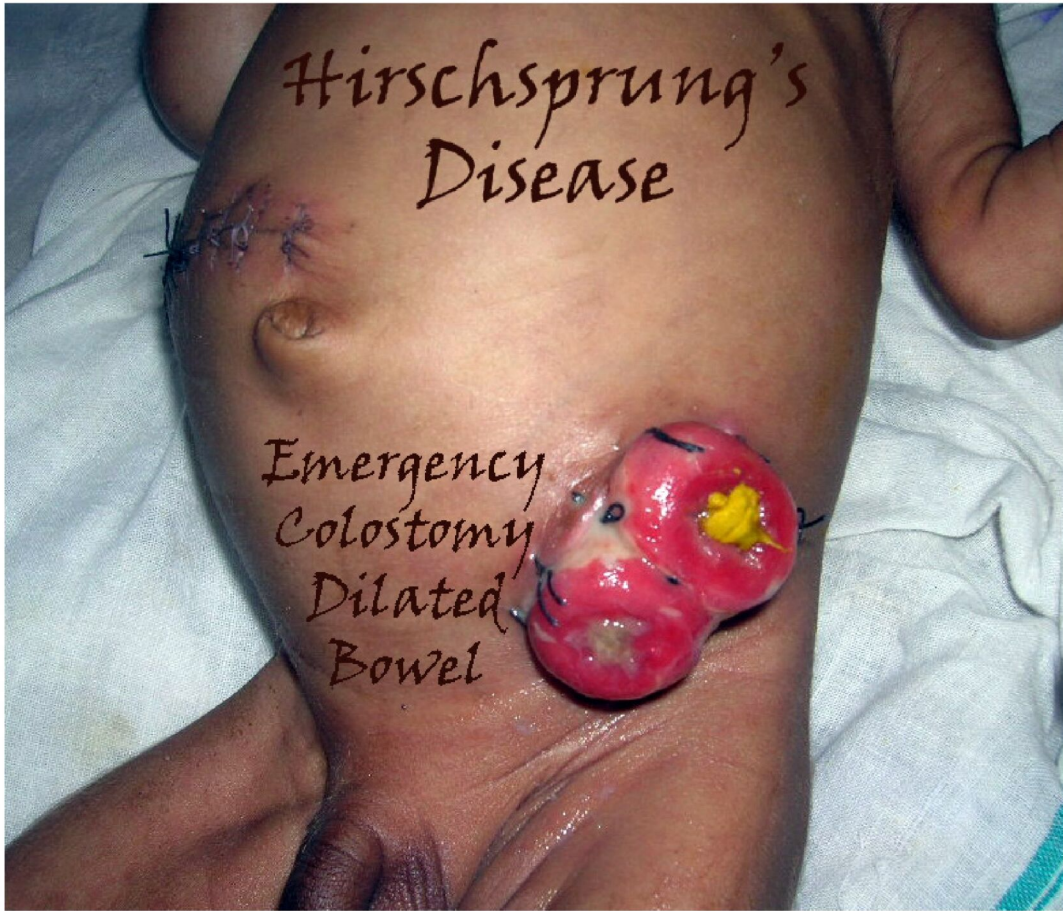


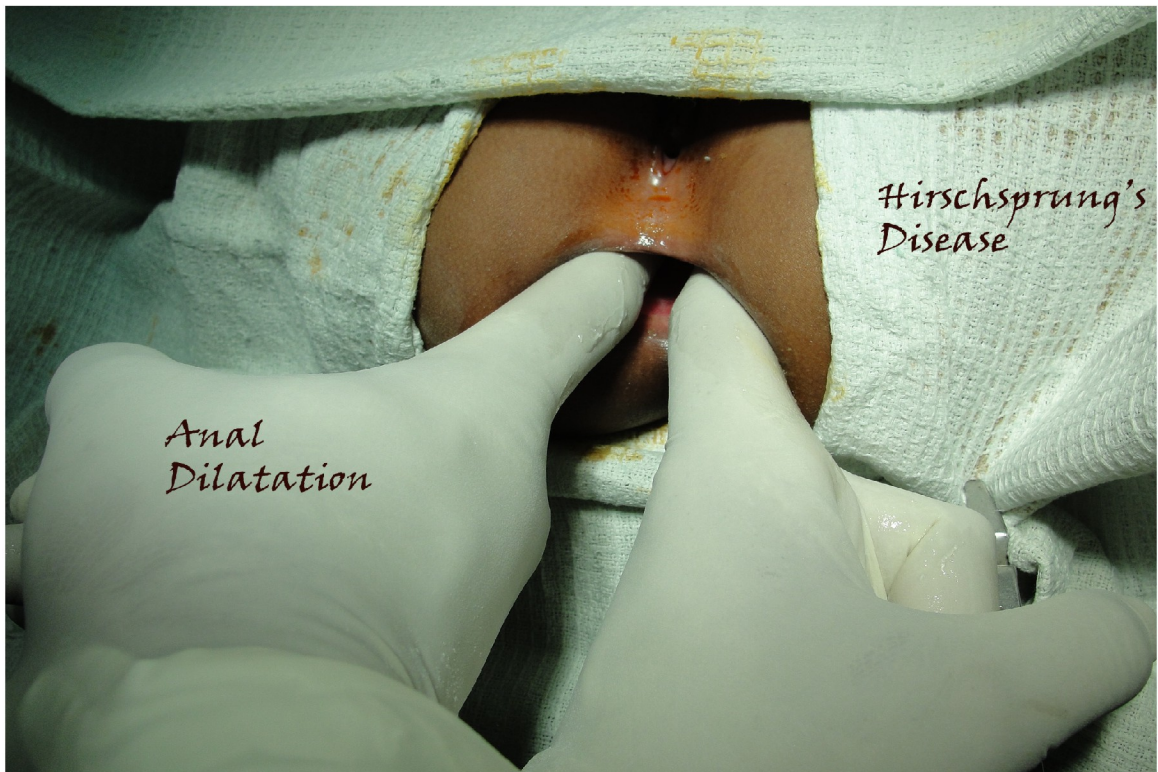










Hirschsprung's
Disease

Anal
Dilatation