STUDY OF LUMBAR PLEXUS IN 25 CADAVERS

Dissertation submitted in partial fulfillment of the requirement for the award of

M.S. DEGREE EXAMINATION
(ANATOMY)

BRANCH V

MARCH – 2010

Institute of Anatomy
Madurai Medical College
Madurai - 625 020

THE TAMILNADU Dr. M.G.R. MEDICAL UNIVERSITY
CHENNAI- 600 032
TAMILNADU

CERTIFICATE

This is to certify that the dissertation entitled **"STUDY OF LUMBAR PLEXUS IN 25 CADAVERS"** submitted by **Dr.J.Jayarani,** postgraduate in Anatomy to the faculty of Anatomy, **The Tamilnadu Dr. M.G.R Medical University, Chennai** in partial fulfillment of the requirement for the award of M.S. Degree in Anatomy, is a bonafide work carried out by her under my direct supervision and guidance.

Place: Madurai

Date:

Dr**. V. Rajaram D.L.O., M.S.,**
Director & Professor I/C
Institute of Anatomy
Madurai Medical College
Madurai.

DECLARATION

I, **Dr.J.JAYARANI** solemnly declare that the dissertation entitled "**STUDY OF LUMBAR PLEXUS IN 25 CADAVERS"** has been prepared by me under the guidance and supervision of **Dr.V.RAJARAM D.L.O., M.S.**, Director & Professor I/C, Institute of Anatomy, Madurai Medical college, Madurai in partial fulfillment of the requirement for the award of **M.S. (Anatomy)** Degree Examination of **The Tamilnadu Dr. M.G.R Medical University, Chennai** to be held in March 2010. This work has not formed the basis for the award of any other degree to me from any other university.

Place: **Madurai** **Dr. J.JAYARANI**
Date:

ACKNOWLEDGEMENT

I express my profound gratitude to the **DEAN,** Madurai Medical College, Madurai for permitting me to use the college and Department facilities for my study.

I sincerely thank **Dr.V.RAJARAM, D.L.O., M.S.,** Director (Incharge), Institute of Anatomy, Madurai Medical College, Madurai for his constant guidance, encouragement and untiring technical help rendered throughout the period of this study.

I also thank Dr.T.Jeeva M.S., Dr.S.Sundari.,M.S., Dr.Parthiban DCH., M.S., Dr.Ananthi DGO.,M.S.,Dr.Shobana DGO.,M.S., and other faculty & non faculty members in the Institute of Anatomy for their valuable help in the execution of the work.

CONTENTS

INTRODUCTION

The study of lumbar plexus is interesting and useful because of

- Various approaches to Lumbar plexus block
- Injury to femoral nerve in Psoas abscess, Inguinal block dissection in carcinoma penis, Dislocation of Hip joint, Fracture Pelvis due to Road traffic accidents can be avoided with above knowledge.
- In case of Disc prolapse and Lumbar spondylosis – easily diagnosed by the study of dermatomal distribution of lumbar nerves.
- In case of Iliac crest bone graft.
- In procedures like Bladder tumour resection, Werthims operation, total hip replacement.
- In Routine Herniorrhaphy injury to ilioinguinal Nerve can be avoided.

AIM

To study Lumbar plexus in relation to its site, formation, branching pattern and variations

MATERIALS AND METHODS

Dissection of Lumbar plexus was conducted in 19 male and 6 female cadavers bilaterally.

In this study cadavers, received at the Institute of Anatomy, Madurai Medical College – Madurai, were utilized.

The cadavers were embalmed and stored in the tanks, filled with vat solutions.

After detailed dissection of the lumbar plexus the collected data was tabulated under different headings and the important features of normal and its variations, were noted down.

Instruments used

- Stainless steel scalpel.
- Stainless steel 14” blade with handle.
- Stainless steel long and short scissors curved and straight.
- Stainless steel short forceps toothed and non toothed.
- Cotton
- Cream sheets used as markers.

Methods

Lumbar plexus was explored by Transperitoneal approach

Abdomen was opened as per cunningham's volume II (115) peritoneum was incised. Visceral organs like stomach, liver, spleen, pancreas, kidney, jejunum, ilieum, ascending, transverse, descending and sigmoid colon removed alongwith mesentry. Aorta and its branches like coeliac, superior and inferior mesenteric vessels excised and removed. By exposing the ilio psoas fascia branches like femoral, lateral cutaneous nerve of thigh, iliohypogastric, ilioinguinal nerves were identified on the lateral border of psoas major muscle. Obturator nerve was seen medial to psoas major. Genitofemoral nerve was seen on the surface of psoas major muscle. Psoas fascia and muscle removed in piece meal to study the formation and site of lumbar plexus. Branches of the Lumbar Plexus were traced upto iliac crest laterally and inguinal ligament anteriorly.

Lumbar Plexus

Site

Lumbar plexus is situated within the substance of the psoas major muscle in front of the transverse processes of corresponding lumbar vertebrae.

Formation of plexus

The upper three lumbar ventral rami and greater part of the fourth take part in the formation of the lumbar plexus.

Above, the plexus is narrow and is usually connected with the twelfth thoracic nerve by a small offset from that nerve named thoraco lumbar nerve, below it is wider and is joined to the sacral plexus by means of a branch passing from fourth lumbar nerve (furcal nerve) to the fifth lumbar which forms Lumbo Sacral Trunk.

Lumbar plexus formation give appearance as series of loop due to several nerve arise by two (or) more roots from corresponding number of spinal nerves which is differ from interlacement formation of Brachial Plexus.

Formation of Branches

The first lumbar nerve have been joined by the branch from twelfth thoracic nerve gives off the ilio hypogastric and ilio inguinal nerves and sends downward a communicating branch to the second nerve. The fibres of thoraco lumbar nerve enters chiefly the iliohypogastric nerve but some may also pass to ilioinguinal nerve. The descending branch of the first

lumbar nerve contributes to the genitofemoral nerve, often to the femoral nerve and occasionally to the obturator nerve.

The second lumbar nerve contributes to greater part of the genitofemoral and lateral cutaneous nerves and gives a connecting branch to the third lumbar nerve from which some of the fibres of the femoral and obturator nerves are derived.

From the third nerve three branches proceed. The largest part enters the femoral nerve, a small branch joins the lateral cutaneous of thigh and the third arising to the obturator nerve.

The fourth nerve also gives three branches of which the anterior and posterior serve to complete the obturator and femoral nerves respectively, while the third branch placed below the others descends to join the fifth lumbar nerve thus forming the lumbosacral trunk which enters into the sacral plexus.

In normal condition the upper three lumbar nerves enter wholly into the lumbar plexus and the fifth nerve into the sacral plexus. While the fourth - the nervus furcalis of V.Jhering is divided between the two plexuses.

Muscular branches to Quadratus lumborum and psoas major are given off directly from the plexus.

Classification Of Branches

The branches were classified in relation to key muscle – psoas major as lateral, anterior and medial.

Lateral Branches

- *The ilio hypogastric nerve:* It emerges from upper lateral border of psoas major.
- *The ilioinguinal nerve:* It emerges from lateral border of psoas major along with or caudal to iliohypogastric nerve.
- *Lateral cutaneous nerve of thigh:* It emerges on the lateral side of psoas major below inguinal nerve.
- *Femoral nerve:* This is the largest branch of lumbar plexus arises from dorsal branches of second, third and fourth lumbar ventral rami. It emerges low on its lateral border of psoas major muscle.

Anterior Branches

Genito femoral nerve. It emerges on anterior surface of psoas major.

Medial Branches

Obturator Nerve

This nerve arises from the ventral branches of 2nd, 3rd, 4th lumbar ventral rami, the third being largest, second very small. It emerges from the medial border of psoas major near the pelvic brim.

Lumbo sacral trunk

This trunk formed by part of fourth and whole fifth lumbar ventral rami on the medial margin of psoas major

Accessory obturator nerve

It Occasionally present, is small and arises from the ventral branches of third, fourth lumbar ventral rami. It descends along the medial border of psoas major.

Course and Distributions :

Ilio hypogastric Nerve:

It emerges from upper lateral border of psoas major, runs behind the lower renal pole in front of quadratus lumborum and then enters the anterolateral abdominal wall.

Ilioinguinal Nerve:

This nerve descends from lateral border of psoas major, pierces transverse abdominis near anterior end of iliac crest and pierces the internal oblique to supply it.In inguinal canal it traverses below the spermatic cord emerging with it in the superficial inguinal ring to supply proximo medial skin of thigh and also the skin around root of penis and scrotum in male and skin of monspubis and labium major in female.

Lateral cutaneous nerve of thigh:

This lateral cutaneous nerve comes out from lateral side of psoas major and crosses iliacus muscle obliquely towards anterior superior iliac spine. On the right side nerve passes posterolateral to caecum. On the left side nerve passes behind the descending colon. On both sides pass behind or through the inguinal ligament medial to anterior superior iliac spine at a variable distance of 10 to 15 mm and divide into anterior and posterior branches and thereby enters the front of thigh.

Femoral Nerve:

This nerve descends from the lateral border of psoas major and passes between psoas and iliacus deep to iliac fascia passing behind the inguinal ligament to the thigh lateral to the femoral sheath. The nerve supplies small branches to iliacus in the abdomen and pectineus and vascular branches to femoral artery near the inguinal ligament.

Genito femoral nerve:

It emerges from the anterior surfaces of psoas major crosses obliquely behind the ureter and divides above the inguinal ligament into genital and femoral branches. Genital branch supplies cremastric muscle. Femoral branch supplies the skin of front of thigh.

Obturator nerve:

This nerve comes out from the medial border of the psoas major and descend forwards along the lateral wall of lesser pelvis on the obturator internus muscle antero superior to obturator vessels towards the obturator foramen for supplying the medial side of thigh.

Lumbosacral trunk:

This trunk emerges from the medial margin of psoas major and descends near the pelvic brim anterior to sacroiliac joint to join the sacral plexus.

Accessory obturator nerve:

It descends along the medial border of psoas major, crosses the superior pubic ramus behind the pectineus and divides into branches, one entering the deep surface of pectinens to supply the hip joint and one connecting with the obturator nerve's anterior branch.

With the above criteria, the site, formation, branching pattern of lumbar plexus was studied.

REVIEW OF LITERATURE

Lumbar plexus had been dissected out and analysed thoroughly for more than 100 years by many Anatomists and Anesthetists.

Site and Formation of Plexus

At the earliest Eisler in 1891 had analysed Lumbar Plexus and had stated that in the normal condition the first three Lumbar nerves enter wholly into the lumbar plexus, fifth lumbar nerve into the sacral plexus while the fourth the nervus furcalis of (V. Jhering who had found out that it is divided between the two plexuses (Lumbar and Sacral) – Quain's anatomy, XI edition 1909).

C.S. Sherrington (1893) in experiments on cat and monkey in journal of physiology XIII639 gives the name prefixed and post fixed. Langley gives high and low (the anterior and posterior) forms on experiments done in lumbar plexus of cat.

A.M. Paterson (1893-94) in "the Origin and distribution of nerves to the Lower Limb" – Journal of Anatomy and physiology XXVIII states that in the low form of plexus (furcal nerve formed by L4 and L5 or L5), that the iliohypogastric and ilioinguinal nerves receive an additional root from 12th thoracic nerve.

Bardeen C.R.A.W. Elting (1901) in a statistical study of the variations in the formation and position of the lumbo sacral plexus in man Anat. Anz. 19:124 – 128, 209-232 has reported about the variation in formation of Lumbar Plexus in the following tabular column. Normal lumbar plexus, high form, Low form by Bardeen is given below in the tabular column.

Nerve	**High form**	**Normal**	**Low form**
Lat. Femoral Cutaneous	L1 – L2	L2 – L3	L3 – L4
Femoral	T12 – L4	L2 – L4	L3 – L5
Obturator	L1 – L4	L2 – L3	L3 – L5
Furcal Nerve	L3 – L4	L4	L4 – L5

According to J. Symington and E.A. Schafer (199) of Quains Elements of Anatomy. The lumbar plexus is formed by the ventral primary divisions of the upper four lumbar nerves. It is placed in the substance of the psoas muscle, in front of the transverse processes of the corresponding vertebrae. Above, the plexus is narrow, and is usually connected with the last thoracic nerve by a small offset from that nerve, named thoraco – lumbar, below, it is wider, and is joined to the sacral

plexus by means of a branch passing from the fourth lumbar nerve to the fifth.

According to Gray's Anatomy 37 Edition 1989, Lumbar Plexus is in the posterior part of substance of psoas major muscle anterior to lumbar transeverse processes. The paravertebral part of psoas major has a posterior mass of muscle attached to the transverse processes and an anterior mass attached to the lips of the vertebral bodies, interventebral discs and tendinous arches. The lumbar plexus is between these masses and hence in line with the intervertebral formina and formed by the first three and most of the fourth nerves. The smaller moiety of the fourth joins the fifty as a Lumbosacral trunk, which joins the sacral plexus. The fourth is often termed the nervus furcalis, being divided between the two plexuses; but the third is occasionally the nervus furcalis; or both third and fourth may be furcal nerves and the plexus is termed prefixed (High). More frequently the fifth nerve is furcal, the plexus then being termed postixed (Low).

Farny J, Drolet P, Girard M. 1994 in Can J Anaesth 41 (12): 1238 – 9 Anatomy of posterior approach to the lumbar plexus nerve says that four cadavers were dissected and 22 computed tomography files of the

lumbosacral region were studied. Cadaver dissections demonstrated and he reported that the lumbar plexus, at the level of L5, is within the substance of the psoas major muscle rather than between this muscle and the quadratus lumborum.

Erbil Km Ondenoqlus, Basar R, Okajimas Folia Anat Jpn 1999 may; 76(1) 55 – 9 – unusual branching in lumbar plexus – states complex bilateral variation – left side:- it is post fixed & posterior to psoas muscle.

i) Lateral cutaneous nerve of thigh – formed by anterior rami of L1, L2. Femoral nerve: L1, L2, L3, L5. Obturator Nerve : L1, L2, L3

Right Side: - prefixed and within the substance of psoas muscle.

Moso T, Kikuchi, Konno S, Yaginuma H – 2003, Mar 1; 28(5) : 423 -8, discussion 427 – 8 – Anatomic study of Lumbar plexus with respect to retro peritoneal endoscopic surgery.

According to Gray's Anatomy 40 Edition 2008 – Lumbar plexus lies within the substance of the posterior part of psoas muscle, anterior to transverse process of lumbar vertebrae, formed by first three and most of fourth lumbar ventral rami. The first lumbar ramus receive a branch from last thoracic nerve. Paravertebral part of psoas major consists of posterior

and anterior masses which arise from different attachment. Lumbar plexus lies between these masses hence is in line with the intervertebral foramina.

Articles in Chinese Zhonghuawai ke za zhi et al 2008 may 46 (9) : 647-9. Clinical anatomy of lumbar plexus in lumbar. Antero laterally approach – minimally invasive surgery states.

Anterior view: Lumbar plexus arranged in lateral to medial from L2-L5.

Lateral view : arrangement ventral to dorsal L2 – L5, angle degree between lumbar nerve and lumbar vertebrae increases from L1- L5 and close contact with transverse. By sectional anatomy – Lumbar plexus location in dorsal third of psoas major, so safety zone of psoas major is ventral two third.

Formation of Branches

J. Symington and E.A. Schafer (1909) of Quains Elements of Anatomy, states that the usual arrangement of lumbar plexus as such. The first lumbar nerve, having been joined by the branch from the last thoracic, gives off the ilio-hypogastric and ilio-inguinal nerves, and sends downwards a communicating branch to the second lumbar nerve. The

fibres of the thoraco lumbar cord enter chiefly the ilio-hypogastric nerve, but some may pass also to the ilio-inguinal. The descending branch of the first nerve contributes to the genitor-femoral, often to the femoral, and occasionally to the obturator nerve.

The second lumbar nerve furnishes the greater part of the genitor-femoral and lateral cutaneous nerves, and gives a connecting branch to the third, from which some of the fibres of the femoral and obturator nerves are derived. From the third nerve three branches proceed: the largest part enters the femoral nerve; a small branch, dorsally placed, joins the lateral cutaneous nerve of thigh; and the third arising from the ventral aspect of the trunk, passes to obturator nerve. The fourth nerve also gives three branches, of which the anterior and posterior serve to complete the obturator and femoral nerves respectively, while the third, placed below the others, descends to join the fifth lumbar nerve, thus forming the lumbosacral cord, which enters into the sacral plexus.

W.Henry Hollinshed (1976) recorded in Lumbar Plexus formation and branching pattern that the first lumbar may or may not receive fibres from twelfth thoracic nerve. It gives a major stem which divides into iliohypogastric and ilioinguinal nerve while a small branch descends to

unite with a small branch of second lumbar and forms genitofemoral nerve. The second lumbar give a root to genitofemoral nerve and gives origin to parts of both lateral femoral cutaneous nerve and femoral nerve from its posterior branch and from its anterior branch to a part of obturator nerve.

The third lumbar contributes to lateral femoral cutaneous nerve, femoral nerve and obturator nerve.

The fourth lumbar divides before it enters the lumbar plexus, sends its major division to the lumbar plexus. The posterior branch of this division contributes to femoral nerve and anterior branch contributes to obturator nerve.

The other part of the fourth lumbar nerve goes down to join or parallel to corresponding branch of fifth lumbar nerve as lumbo sacral trunk.

According to the Gray's Anatomy (1989) Lumbar plexus varies, in its usual arrangement the first lumbar nerve is joined by a branch from twelfth thoracic nerve and bifurcates. The upper and larger part divides into iliohypogastric into and ilioinguinal nerves. The lower part units with the second lumbar branch to form the genitofemoral nerve. The remainder

of the second, third and part of the fourth nerves joining the plexus divide into ventral and dorsal branches. Ventral branches of second, third and fourth nerves unites each divides into smaller and larger parts. The two smaller of parts unite to form lateral femoral cutaneous nerve of the thigh. The two larger parts join with the dorsal branch of the fourth to form femoral nerve. Accessory obturator nerve when it is present arises from third and fourth ventral branches.

Jack Joseph (1990) in “Aids anatomy describes lumbar plexus as in Gray’s anatomy.

Erbil Km Ondesoglus, Basar R, Okajimas Folia Anat Jpn 1999 may; 76(1) 55 - 9 - censual branching in lumbar plexus - states complex bilateral variation - left side:- it is post fixed & posterior to proas muscle.

Lateral cutaneous nerve of thigh – formed by anterior rami of L1, L2. Femoral nerve: L1, L2, L3, L5. Obturator Nerve: L1, L2, L3. Right Side:- prefixed with in substance of psoas muscle.

According to Gray’s Anatomy 39 Edition 2005 - Lumbar plexus lies within the substance of the posterior part of psoas muscle, anterior to transverse process of lumbar vertebrae, formed by first three and most of fourth lumbar ventral rami. The first lumbar ramus receive a branch from

last thoracic nerve. Paravertebral part of psoas major consists of posterior and anterior masses which arise from different attachment lumbar plexus lies between these masses hence is in line with the intervertebral form a.

Branches of lumbar plexus	**Root value**
Iliohypogastric nerve	L1
Ilio inguinal	L1
Genito femoral	L1 & L2 dorsal division
Lateral femoral cutaneous nerve	L2 & L3
Femoral nerve	L2, L3 & L4
Obturator nerve	L2, L3 & L4
Accessory obturator nerve	L3 & L4
Muscular branches	T12, T1, L2, L4

Davies F (1935) states in “A note on the first Lumbar nerve Journal of Anat. 70;177-178” that ilioinguinal nerve may be regarded as collateral branch of the first lumbar nerve, ilio hypogastric as the main trunk, in the variation of Lumabr Plexus.

W.Henry Hollinshed III edition 1976 found that the first Lumbar Nerve may or may not receive fibers from sub costal nerve. But gives a

major stem that divides into ilio hypogastric and ilioinguinal Nerve and a small branch which descends down to join small branch of 2nd Lumbar Nerve.

Ronald A.Bergman, Ph.D Adel K.Afifi, MD., MS., Ryosuke Miyauchi, MD., (1988) in Illustrated Encyclopedia of Human Anatomic Variation: Opus III Nervous System 2000 Plexuses reported that asymmetry of the Lumbar Plexus between the right and left side of the body is due to variable connection of sub costal nerve and second Lumbar nerves to the First Lumbar Nerve.

Jack Joseph (1990) in "Aids anatomy describes lumbar plexus as in Gray's anatomy.

In 1998 in Folia Morphol (Warsz) 1998; 57 (4) : 377-81 Mine Erbil K, Onderoglu S, Basar R, Hacettepe University, Department of Anatomy, Ankara, noted that in one cadaver unusual branching in Lumbar Plexus has been dissected – the Lumbar Plexus on the left side was post fixed and located posterior to the psoas major muscle. Femoral nerve was formed by ventral rami L2, L3, L4 and L5 spinal nerves. On the right side Lumbar Plexus was prefixed femoral nerve was formed by ventral rami L1, L2, L3

and L5 spinal nerves. The right Lumbar Plexus was located in substance of the psoas major muscle.

Erbil Km Ondesoglus, Basar R, Okajimas Folia Anat Jpn 1999 may; 76(1) 55 - 9 - censual branching in lumbar plexus - states complex bilateral variation - left side:- it is post fixed & posterior to proas muscle. Lateral cutaneous nerve of thigh – formed by anterior eami of L1, L2. Femoral nerve: L1, L2, L3, L5. Obturator Nerve: L1, L2, L3. Right Side: - prefixed with in substance of psoas muscle.

Branches

Ilio hypogastric nerve

Normally Ilio Hypogastric nerve is derived mainly from the first lumbar nerve and may also receive fibres from 12th Thoracic nerve. It passes forwards anterior to the quadratus lumborum of the abdomen. After furnishing a lateral cutaneous nerve to the skin of the hip becomes subcutaneous anteriorly and ends in the suprapubic skin of the lower part of abdomen above the superficial inguinal ring.

In Eisler 1891 states that 12th thoracic nerve gives a branch to first Lumbar nerve which in turn gives Iliohypogastric and Ilioinguinal nerves.

Bardeen C.R, 1906 – 07 in (Development and variation of the nerves and the musculature of the trunk in man. Am.J. Anat, 6:259-390, states that IlioHypogastric nerve occasionally is derived from last thoracic nerve and it may even receive fibres from 11th thoracic nerve. The ilioHypogastric nerve divides into Iliac and hypogastric branches. The iliac nerve varies in size with the lateral cutaneous branch of 11th Thoracic nerve or may be absent. The hypogastric branch is joined with last thoracic nerve.

W.Henry Hollinshed 1976, gives the following variations for ilio hypogastric nerve that it may arise from 11th, 12th thoracic nerve or from 12th thoracic nerve alone or from first Lumbar nerve alone.

Ronald A. Bergman Phd., in Compendium of Human Anatomic variation – Urban & Schwarzenberg, Munich and Baltimore 1988 states that the iliac branch of the iliohypogastric nerve may be absent, replaced by the lateral cutaneous branch of the twelfth thoracic nerve.

In Gray's Anatomy (1989) it is mentioned that Ilio hypogastric nerve arises from the first Lumbar Nerve and connects Ilio inguinal and subcostal nerves.

Jack joseph (1990) in Aids to Anatomy states that both Ilio inguinal and Ilio hypogastric nerves are derived from first Lumbar nerve.

R.J. Lasts Anatomy (1994) 9th edition arise states ilio hypogastric nerve from anterior remus of along with ilio hypogastric nerve & then divides from a common stem.

According to Gray's anatomy edition 2005. The ilio hypogastric nerve originates from the L1 ventral ramus, emerges from the upper lateral border of psoas major. This nerve connects with the subcostal and ilio inguinal nerves – descends medial to anterior, superior iliac spine, supply skin and postero lateral skin of gluteal region.

Ilio Inguinal Nerve

Eisler (1891) the Ilio Inguinal nerve along with Ilio hypogastric nerve arises by a common trunk from first Lumbar nerve. It may also be derived from 12th Thoracic nerve. It may arise from a loop between first and second Lumbar nerve or even from Second Lumbar nerve.

According to E.A. Schafer and J. Symington (1909) in Quain's Elements of Anatomy ilioinguinal nerve is derived from first Lumbar nerve and sometimes receive fibres from 12th Thoracic nerve. It appears beneath the outer border of psoas muscle below the Ilio hypogastric nerve

and is directed obliquely downwards and outward over the Quadratus Lumborum and Iliacus to the anterior end of Iliac crest. After piercing the transverse abdominis it descends along the inguinal canal to emerge out of the superficial inguinal ring. Then it becomes subcutaneous to supply monspubis and proximal part of thigh etc.,

Acceding to Griffin M (1909) in Quain's Anatomy 11th Edition the Ilio Inguinal nerve may be absent. Its place usually will be taken by genital branch, rarely by the femoral branch of Genitofemoral nerve or very rarely by Lateral Cutaneous nerve of thigh.

According to Davies (1935) the ilio-inguinal nerve may be regarded as the collateral branch of the first Lumbar nerve.

According to W. Henry Hollinshed 1976 the following variations for ilio inguinal nerve can occur - arises from Twelfth thoracic nerve alone or from Twelfth Thoracic nerve and First Lumbar nerve.

According to Ronald Bergman (1988) of Virtual Hospital 2000 University of Iowa – out of 200 cadavers dissected IlioInguinal nerve arise from the common trunk with Ilio hypogastric nerve in Twenty five percent of cases. It was absent in 2.5% Ilioinguinal nerve was formed from one root in 92.5% and from two roots in about 5% of cases. In 86%,

the Ilio inguinal carried fibres from one spinal nerve (Primarily from L1) and in 11%, from two spinal nerves (T12, L1, L2; or L2, L3).

According to Gray's Anatomy (1989) that the Ilio inguinal nerve, smaller than the iliohypogastric, arises with it from the first Lumbar ventral ramus, emerges from the lateral border of the psoas major.

According to R.J.Last's Anatomy (1994) 9th edition the ilio inguinal nerve represents the collateral branch of ilio hypogastric nerve.

In Gray's anatomy (2005) - 39th edition states the ilio inguinal nerve originates from the L1 ventral ramus, it is smaller than the ilio hypogastric nerve and arises with it from the first lumbar ventral ramus, emerge from the lateral border or psoas major, with or just inferior to the ilio hypogastric nerve. This nerve sometimes connects with the ilio hypogastric nerve near the anterior end of the iliac crest. The ilio inguinal and iliohypogastric nerves are reciprocal in size. The ilioinguinal is occasionally very small and ends by joining the ilio hypogastric a branch of which than takes its place. Occasionally the ilio inguinal nerve is completely absent when the ilio hypogastric nerve supplies its territory.

Genitofemoral Nerve

According to Eisler of (1891) this is the most variable branch of the Lumbar plexus. The two divisions of Genitofemoral nerve often arise independently from the Lumbar plexus - Quain's Anatomy.

E.A. Schafer and J.Symington in Quain's Elements of Anatomy Genitofemoral nerve originates chiefly from second lumbar nerve but receive few fibres from the connecting branch of first and second Lumbar nerve. It descends obliquely through the substance of Psoas major muscle, emerges and lie on the anterior surface of that muscle, divides in to Genital and Femoral branches.

It often bifurcates close to its origin from the plexus in which case its two branches perforate the psoas muscle in different places.

According to Ronald A. Bergman, Ph.D, in compendium of human anatomic variation (1988) has stated that in a study of 200 bodies, the genitofemoral nerve was a single trunk in 80%, and two separate branches, Genital and femoral, in 20%.

The single trunk may arise from L1, L2, or L2, L3.

The double trunk may arise from L1, L2 or L1, L2 and L3.

W. Henry Hollinshed 1976, 3rd Edition gives the following variations for Genitofemoral nerve L1, or L2, L1-L3; L2, L3.

According to Gray's Anatomy (1989) 37th Edition – genitofemoral nerve often divides close to its origin. Its branches namely genital and femoral emerge separately from the psoas major muscle to supply cremaster muscle and skin of front of thigh.

In Lasts Anatomy 1994 Genito femoral nerve is formed in the substance of psoas major by union of branches from L1 and L2.

In grays anatomy 2005 – the geni to femoral nerve originator from the L1 and L2 ventral rami. It is formed within the substance psoas major descends through the muscle on its anterior. Surface near the medial border opposite the third or fourth lumbar vertebrae. It often divides dose to its origin. Passes behind the inguinal ligament and supplies the skin to upper part femoral triangle.

Lateral Cutaneous Nerve of Thigh

According to Schafer and Symington of Quain's Anatomy (1909) normally lateral cutaneous nerve of thigh arises from second and third Lumbar nerves. From the outer border of the Psoas major muscle it crosses the Iliacus lying beneath the Iliac fascia, passes under the inguinal

ligament to enter the thigh and there divides into anterior and posterior branches.

According to Griffin.M in Quain's Anatomy 11th, Edition (1909) in the normal form lateral cutaneous nerve is derived mainly from second lumbar nerve and it also receives small root from the third lumbar nerve. In high form of lumbar plexus it arises from second Lumbar nerve or from first and second lumbar nerve. In the low form of Lumbar plexus it arises from the third lumbar nerve.

According to R.J.Last's Anatomy (1994) – 9th Edition Lateral femoral cutaneous nerve is formed by union of fibres from the posterior divisions of the anterior rami of L2 and L3.

Anomalous Course

The lateral cutaneous nerve often accompanies, or is united with, the femoral nerve below the inguinal ligament.

W.Henry Hollinshed 1976, 3rd Edition gives the following variations for Lateral Cutaneous nerve of thigh. In the high form it arises from – T12 – L2; L1 – L2, in the low form from L3 – L4.

Ronald A. Bergman Ph.D., 1988 in Compendium of Human Anatomic variation – Urban & Schwarzenberg, Munich and Baltimore

reports that this nerve may arise from the femoral nerve or as independent branch of the lumbar plexus (L2, L3). Several variations in the formation, course and branches of this nerve have been reported. The nerve may be absent on one side and may be replaced by a branch of the anterior femoral cutaneous nerve or by the ilioinguinal nerve or by a branch of genitofemoral nerve. The posterior branch of the lateral cutaneous nerve may be replaced by a branch of the genitofemoral nerve.

According to Gray's Anatomy (1989) Lateral cutaneous nerve of thigh arise from dorsal branches of second and third Lumbar ventral rami. Right side it descends below the caceum and left side behind the descending Colon and at variable distance from anterior superior iliac spine it passes through or behind inguinal legment to enter the thigh.

In R.J.Lasts's Anatomy (1994) – the lateral femoral cutaneous nerve may arise as a branch from the femoral nerve.

In J.Orthop Trauma 1999 Jan; 13: 17-9 Anatomic study of the lateral femoral cutaneous nerve Hospodar PP, Ashman ES, Traub JA, New York states that the course of the lateral femoral cutaneous nerve is highly variable; the nerve was most commonly found at ten to fifteen millimeters from the anterior superior iliac spine and as far medially as

forty-six millimeters. When using the ilioinguinal surgical approach, if the lateral femoral cutaneous nerve is not encountered immediately adjacent to the anterior superior iliac spine, dissection upto five centimeters medial to the anterior superior iliac spine may be necessary to locate the nerve.

According Resenberger R.J.Loeweneck H, Meyer G. Surg. Endosc 2000 Aug; 14 (8): 731 – 5. The course of the genitofemoral nerve, lateral femoral cutaneous nerve, and ilioinguinal nerve within the operation site – laparoscopic hernioplasty, investigated in 53 adult dissecting-room bodies. Their relationship to the deep inguinal nerve iliopubic tract, and anteriog superior iliac spine was also examained. Results: The lateral femoral cutaneous nerve and the ilioinguinal nerve may run immediately lateral to the anterior superior iliac spine.

Anat Sir Int 2002 Dec 77 (4) : 247-9. Variations of Lateral femoral cutaneous Erbil Km, et al. Department of Anatomy Hacettepe University, Turkey. Erbil Km, et al. Department of Anatomy Hacettepe University, Turkey-

Dissected 28 cadavers. Variations seen in 2 on the right ventral rami of 1st & 2nd lumbar spinal nerves were united and then his nerve was divided into four branches, from medial to lateral these were obturator,

Femoral, medially located Lateral femoral cutaneous nerve, and the laterally located lateral femoral cutaneous nerve.

On the Left side there were three lateral femoral cutaneous nerve all these pierced the psoas major muscle anterolaterally.

Two of these nerves, which pierced the psoas major muscle more proximally than third. United with each other by communicating branch anterior to the iliacus muscle.

This type of variations are very important to prevent injury and occurrence of meralgia parasthetica.

In Grays anatomy (2005) 9th edition the lateral femoral cutaneous nerve arises from the second and third lumbar vertral rami. Right side the nerve passes posterolateral to the caccum, left side passes behind the lower part of the descending colon. Variably medial to anterior superior iliac spine pass behind or through inguinal ligament anterior to or through sartorius, and enter into the thigh.

Femoral Nerve

According to Eisler (1891) it is the largest nerve arising from Lumbar Plexus. It arises from third and fourth Lumbar nerves usually but

in high forms from second and first Lumbar nerves and the low forms from fourth and fifth lumbar nerve.

Bardeen C.R. and A.W. Elting (1901) in a statistical study of the variations in the formation and position of the lumbo-sacral plexus in man. Anat. Anz., 19:124-128, 209-232 states that femoral nerve in normal form arises from second Lumbar to fourth Lumbar nerves. In high form it arises from Twelfth thoracic to fourth Lumbar nerves and in low form it arises from third lumbar to fifth Lumbar nerves.

W. Hentry Hollinshed 1976, gives the following variations – Femoral nerve arises from the dorsal divisions of first lumbar to fourth lumbar or from first lumbar to fifth lumbar nerves or second lumbar to fifth lumbar nerves.

It is the largest nerve arising from dorsal branches of second, third and fourth lumbar ventral rami. It emerges on the lateral border of psoas major muscle, passes between it and the Iliacus muscle deep to iliac fascia. Then it passes behind the inguinal ligament to reach the thigh behind the inguinal ligament it is separated from the femoral artery by part of the psoas major. In the abdomen the nerve supplies small branches to the iliacus and pectineus and a branch to the proximal part of the

femoral artery; the latter branch may arise in the thigh. The nerve to the pectineus branches from the medial side of the femoral nerve at the inguinal ligament level. – Gray's Anatomy.

R.J. Last's (1994) in ninth Edition states that femoral nerve arises from posterior divisions of second, third and fourth lumbar vetral rami – posterior divisions. It issues from the lateral border of psoas major muscle and crosses the iliac fossa in the gutter between psoas and Iliacus, deep to the Iliac fascia. It supplies iliacus here, and then passes beneath the inguinal ligament lateral to the femoral sheath.

In Gray's anatomy (2008) 40th edition the femoral nerve, the largest branch of lumbar plexus, arises from the dorsal branches of the second, third, and fourth lumbar ventral rami. It emerging low on lateral border of psoas muscle passing behind the inguinal ligament where it separate from the femoral artery by psoas muscle, enter into the thigh and supplies iliacus and pectineus.

Obturator Nerve

Eisler (1981) noted that the obturator nerve sometimes has an additional root from the first lumbar nerve in the high form or fifth lumbar nerves in low form of plexus. The root from second is always present.

M.Henry Hollinshed 1976 gives the following variations for Obturator nerve – IN the high form of plexus it arises from first to fourth lumbar nerves and in the low form of plexus it arises from third lumbar nerve to fifth lumbar nerves.

According to Gray's Anatomy 37th Edition usually it arises from anterior divisions of second, third and fourth lumbar ventral rami. Third division being the largest, the one from the second is very is small. It descends in the Psoas major emerging from its medial border at the pelvic brim to pass behind the common iliac artery and descend forwards along the lateral pelvic wall on the obturator internus to wards the obturator foramen.

According to R.J. Last's anatomy (1994) ninth edition the obturator nerve, formed from the anterior divisions of second, third, fourth ventral room of lumbar nerves piercing the medial border of psoas passing side wall of the pelvis to the obturator foramen.

According to Gray's Anatomy (2008) 40th edition the obturator nerve arises from the ventral branches of the second to fourth lumbar ventral rami second ventral branch is smallest, third ventral branch is largest emerging from medial border of psoas muscle at pelvic brion to

pass behind common iliac vessels and lateral to the internal iliac vessels, discends on obturator internus, antero superior to the obturator vessels to the obturator foramen.

Lumbo Sacral Trunk

Bardeen, C.R, (1901) A statistical study of the variations in the formation and position of the Lumbo-sacral plexus in man. Anat. Rec. 19:124-128, 209-232 states that contribution to lumbo sacral trunk may come from third lumbar or fifth Lumbar nerve. Sometimes the branch from fourth lumbar nerve to the lumbosacral plexus is absent. In such cases, the fifth lumbar nerve supplies branches to both the lumbar and sacral plexuses. Thus, contributions to both plexuses may come from the fourth lumbar nerve, the third and fourth, the fourth and fifth or the fifth lumbar nerve alone.

W. Henry Hollinshed 1976, states that the Lumbo sacral trunk is formed from the part of ventral branch of fourth lumbar nerve, the other part forms part of obturator nerve. It descends downwards to join or runs parallel to the corresponding branch of fifth lumbar nerve and with that form the lumbosacral trunk, which joins the sacral plexus.

Gray's Anatomy 37 Edition (1989). The lumbosacral trunk comprises part of the fourth and all the fifth Lumbar ventral rami; it appears at the medial margin of the psoas major, descending over the pelvic brim anterior to the sacro-iliac joint to join the first sacral ramus.

It is formed by the union of fifth Lumbar nerve with part of the fourth Lumbar nerve.

R.J. Last (1994) states that lumbo sacral trunk is formed from fourth and fifth Lumbar nerves which forms part of sacral plexus.

Gray's anatomy (2005) 39th edition states the smaller of fourth lumbar nerve joins the fifth lumbar nerve forms the lumbar-sacral trunk which joins the sacral plexus.

Accessory Obturator Nerve

Eisler in 1891 in his discussion on Lumbo Sacral plexus of man reported finding it in 8 of 32 cases – frequency of 25% The Anatomical Record 136, 367.

Bardeen in 1906 found the accessory obturator nerve to be present in 21 of 250 specimen. A frequency of 8.4%.

De Sousa (1942) reported a 19% occurrence of accessory obturator nerve.

Kaiser (1949) found it in two of 24 sides, an 8.3% frequency. The anatomical Record 136, 367-369.

According to Russell T.Woodburne (1956) - The Anatomical Record - 136, 367-368 found that the small accessory obturator nerve arising from the lumbar plexus by roots from the third and fourth lumbar nerves which emerge between the roots of the obturator and femoral nerves. It parallels the obturator nerve along the medial side of the psoas muscle but runs somewhat more ventrally. Characteristically, the accessory obturator nerve passes deep to the expansion of the psoas minor tendon to cross the superior ramus of the pubis directly on the bone.

W.Henry Hollinshed 1976, says that accessory obturator nerve may arise from L1-L3; L2; L3;L4. He had not mentioned his remarks regarding the incidence.

According to Gray's Anatomy (1989) 37th Edition Accessory obturator nerve is small and occasionally present. It arises from the ventral branches of the third and fourth Lumbar ventral rami. It descends along the medial border of the psoas major, crosses the superior pubic ramus behind the pectineus and divides into three branches – one entering

the deep surface of the pectineus, another supplying the hip joint and third connecting with the obturator nerve's anterior branch.

According to R.J.Last's (1994) the accessory obturator nerve is incorrectly named. Its only characteristic in common with the obturator nerve is that it leaves the medial border of the psoas muscle. Its more important bony relation is shared with the femoral nerve. Like the femoral nerve it passes over, not under, the pubic ramus and like the femoral nerve, it is derived from posterior and not anterior divisions of the nerves of the lumbar plexus. It should have been named the "accessory femoral" nerve instead of accessory obturator nerve. It is formed in the substance of the psoas from the posterior (not anterior) divisions of the third and fourth Lumbar nerves and it supplies the pectineus muscle. It is present in thirty percent of individuals.

OBSERVATIONS

Lumbar plexus

Site

Psoas major muscle

According to Gray's anatomy (2008) the lumbar plexus is present in the posterior part of the substance of the psoas major muscle, anterior to transverse process of lumbar vertebrae.

In the present study the lumbar plexus was seen in the substance of psoas major in all 50 specimens. This coincides with Gray's anatomy.

Psoas minor

As per Gray's anatomy (2008) the incidence of psoas minor muscle is 12% where the lumbar plexus, within the substance of muscle.

In the present study the incidence of psoas minor was 8%. (Fig. 1)

Psoas minor

Muscle	Frequency
Present	4
Absent	46
Total	50

Formation of Lumbar Plexus

The upper three lumbar ventral rami and upper part of the fourth unite to form lumbar plexus. The lower part descends to unite with the fifth lumbar nerve to form a thick nerve called lumbosacral trunk. So the fourth lumbar nerve is called nervus furcalis. This normal pattern was observed in 48 specimens (Fig.2).

In one specimen third lumbar nerve gives a furcal branch to fourth lumbar nerve (Fig. 3).

In one specimen fifth lumbar nerve gives a furcal branch (Fig. 4).

Nervus furcalis

Lumbar nerve	**Frequency**
Third nerve	1
Fifth nerve	1
Fourth nerve	48
Total	**50**

Branching pattern of lumbar plexus

Iliohypogastric nerve

In 49 specimans the iliohypogastric nerve arises from first lumbar nerve.

In one specimen the iliohypogastric nerve receives a branch from subcostal nerve (Fig 5).

Iliohypogastric nerve

Formation	Frequency
A branch from T12	1
From L1	49
Total	**50**

Ilioinguinal nerve

(i) In 46 cadaveric specimens, the ilioinguinal nerve arises from first lumbar nerve. (Diagram 1)

In one specimen the ilioinguinal nerve arises from second lumbar nerve (Fig.6).

One specimen the ilioinguinal nerve arises from loop formed between first and second lumbar nerve (Fig.7).

One specimen the ilioinguinal nerve arises from third lumbar nerve (Fig.8). and in one specimen the ilioinguinal nerve was absent (Fig.9).

Ilioinguinal nerve

Formation	**Frequency**
L1	46
L2	1
L1-L2 loop	1
L3	1
Absent	1
Total	**50**

Genitofemoral nerve

In 50 cadaveric specimens the genitofemoral nerve lies in the anterior substance of the psoas major muscle (Fig.10).

In 4 cadaveric specimens the genitofemoral nerve divides as genital and femoral branch at origin level (Fig.11).

Lateral femoral cutaneous nerve of thigh

In 40 cadaveric specimens the lateral femoral cutaneous nerve of thigh arises from dorsal division of second and third lumbar nerve. (Diagram 2)

In two cadaveric specimens the lateral femoral cutaneous nerve arises from first and second lumbar nerve (Fig.12).

The lateral femoral cutaneous nerve arises from second lumbar nerve - high form in two cadaveric specimens (Fig.13).

From third lumbar nerve - low form in three cadaveric specimens (Fig.14).

In one cadaveric specimen the lateral femoral cutaneous nerve arises as two branch from, second lumbar nerve (Fig.15). and in two specimen as a branch of femoral nerve (Fig.16).

Lateral Femoral Cutaneous Nerve Formation

Formation	**Frequency**
L1L2 (High form)	2
L2 (High form)	2
L3 (Low form)	3
L2-two branch	1
From femoral nerve	2
From L2-L3 (Normal)	40
Total	**50**

Formation of femoral nerve

In 49 specimens femoral nerve arises from dorsal division of third, fourth lumbar nerve and in one cadaveric specimen. Fifth lumbar nerve gives a branch to femoral nerve (Fig 17).

Femoral nerve

Formation	Frequency
Dorsal division L2-L4 (Normal)	49
Dorsal division L3-L5 (Low form)	1
Total	**50**

Obturator nerve

In out of 49 specimens where obturator nerve arises from ventral division of second, third, fourth lumbar nerves.

In one specimen fifth lumbar nerve gives a branch to obturator nerve (Fig.18).

Formation	Frequency
Ventral division L2-L4 (Normal)	49
Ventral division L3-L5 (Low form)	1
Total	**50**

Accessory Obturator Nerve

In out of 50 specimens the accessory obturator never seen in 4 specimens and arises from third and fourth lumbar nerves (Fig 19).

Accessory obturator never

Formation	Frequency
Present	4
Absent	46
Total	**50**

Lumbosacral trunk

Lower division of fourth lumbar nerve and fifth lumbar nerve unites to form lumbosacral trunk. This normal pattern was observed in 49 cadaveric specimens.

In one specimen fifth lumbar nerve gives branch to lumbosacral trunk (Fig 20).

Nervus furcalis

Formation	Frequency
L4 furcal nerve *(Normal)*	49
L5 furcal nerve *(Low form)*	1
Total	**50**

Inference

In the observation of branching pattern of lumbar plexus , the variations for lateral femoral cutaneous nerve was observed in ten specimens out of fifty specimens (diagram 3) Which was high compared to other branches. .

Observation of Branching Pattern of Lumbar Plexus (Normal / Variations)

Branches	Normal	Variations
Iliohypogastric nerve	49	1
Ilio inguinal nerve	46	4
Genito Femoral nerve	46	4
Lateral Femoral cutaneous nerve	40	10
Femoral Nerve	49	1
Obturator Nerve	49	1
Accessory Obturator Nerve	46	4

DISCUSSION

The word plexus is misleading, plexuses are not interlacements of the spinal nerves but a temporary union of the fibres of adjacent spinal nerves and this is probably due to multiple origins of nerves of distribution so that most of the branches of the plexus contain fibres from two or more segmental nerves.

According to Furbinger (1909) in Quain's anatomy on Morphology of lumbar plexus the multiple origins is intimately related to the fusion of the myotomes from which the muscles of the limbs are derived and in association with this is the multiple innervation of individual muscles.

Lumbar Plexus

1. Site

According to the study of onderoglu and his colleagues the lumbar plexus was seen in the posterior part of the substance of psoas major muscle.

According to Gray's anatomy 37th (1989) & 40th edition (2008) the lumbar plexus is in the posterior part of substance of psoas major muscle anterior to lumbar transverse process.

According to articles in Chinese. Zhonghuawai Ke Zazhi et al 2008 may 46 (9):647-9 clinical anatomy of lumbar plexus states the location of lumbar plexus in dorsal third of psoas major. So safety of zone psoas major is ventral two third.

The study of, site of lumbar plexus helps in surgeries like , lumbotomy and laproscopic herniorrhaphy, and also in clinical diagnosis like disc prolapse and lumbar spondylosis. In the present study, the lumbar plexus was located in the posterior part of substance of psoas major muscle in all fifty specimens. This coincides with observation of Farny J, Drolet P.Girard M. who have done 4 cadaver dissections and demonstrated that the lumbar plexus is within the posterior part of substance of the psoas major muscle rather than between this muscle and the quadrants lumborum.

Psoas minor muscle

According to Gray's anatomy 40th edition (2008) psoas minor muscle present in 12%, the relation of lumbar plexus with minor muscle is gave as major muscle.

In the present study psoas minor was observed in 8% which was coincides with Gray's Anatomy (2008) and maintained the relation to lumbar plexus same as major muscle.

Formation of lumbar plexus

At the earliest Eisler in 1891 has analysed lumbar plexus and has stated that in the normal condition the first three lumbar nerves enter wholly into the lumbar plexus, fifth lumbar nerve into the sacral plexus while the fourth the nervus furcalis of (V.Jherng who as found out that it is divided between the two plexuses - Quain's Anatomy, XI edition 1909).

In 1893 C.S.Sherrington in experiments on cat and monkey in journal of physiology XIII 639 gives the name prefixed and post fixed. Langley gives high and low (the anterior and posterior) forms on experiments done in lumbar plexus of cat. Bardeen C.R.A.W. Elting (1901) a statistical study of the variations in the formation and position of the lumbo sacral plexus in man Anat. Anz. 19:124-128, 209-232. has reported about the variation in formation of lumbar plexus in the following tabular column. Normal lumbar plexus, high form, low form by Bardeen is given below in the tabular column.

Nerve	High form	Normal	Low form
Lat. Femoral cutaneous	L1-L2	L2-L3	L3-L4
Femoral	T12-L4	L2-L4	L3-L5
Obturator	L1-L4	L2-L3	L3-L5
Fureal nerve	L3-L4	L4	L4-L5

The above mentioned reference coincides with the present study in 48 specimens.

According to Gray's Anatomy 37 edition 1989, lumbar plexus is in the posterior part of substance of psoas major muscle anterior to lumbar transverse processes and formed by the first three and most of the fourth lumbar nerve. The smaller moiety of the fourth joins the fifth as a lumbosacral trunk, which joins the sacral plexus. The fourth is often termed the nervus furcalis, being divided between the two plexuses. In the present study this pattern is seen in 48 specimens.

According to Gray's anatomy the third lumbar nerve is occasionally the nervus furcalis; or both third and fourth may be furcal nerves, when the plexus in termed prefixed (High). More frequently the fifth nerve is furcal, the plexus then being termed post fixed (Low).

In 1998 in Folia Morphol (Warsz) 1998;57(4): 377-81 Mine Erbil K, OnderogluS, Basar R, Hacettepe University, Department of Anatomy, Ankara, states that in one cadaver unusual branching in lumbar plexus has been dissected that is the lumbar plexus on the left side was post fixed and located posterior to the psoas major muscle. Femoral nerve was formed by ventral rami of second, third, fourth and fifth lumbar spinal nerves. On the right side lumbar plexus was prefixed femoral nerve was formed by ventral rami of first, second, third, and fifth spinal nerves. The right lumbar plexus was located in substance of the psoas major muscle.

In the present study a branch from the third nerve unites with the lower division of fourth never (furcal nerve) in one specimen out of 50 specimens. Hence the plexuses can be termed as prefixed and high form. in one specimen fifth lumbar nerve gives the furcal branch. Hence the plexus can be termed as post fixed and low form. Both of which coincides with Bardeen's observation and the observation of onderolglu and his colleagues. Normal formation of lumbar plexus was observed in 48 specimens.

In present study the lumbar ventral rami increases in size from above downwards. This coincides with the observation of J.Symington of Quain's Elements of Anatomy 1909.

Branching pattern of lumbar plexus

Iliohypogastric nerve

J.Symington states that 12th thoracic nerve gives a branch to first lumbar nerve which in turn gives ilio hypogastric and ilio inguinal nerves Quain's Anatomy 11 edition 1909.

In 1906-07 Bardeen C.R, in Development and variation of the nerves and the musculature of the inferior extremity and of the neighboring regions of the trunk in man. Am.J.Anat, 6:259-390, states that Ilio hypogastric nerve is occasionally derived from last thoracic nerve and it may even receive fibres from 11th thoracic nerve.

In Gray's Anatomy it is mentioned that ilio hypogastric arises from the first lumbar nerve and connects with ilio inguinal and subcostal nerves.

Jack Joseph (1990) in Aids to Anatomy states that both ilio inguinal and ilio hypogastric nerves are derived from first lumbar nerve.

W.Henry Hollinshed 1976, 3rd Edition 673 gives the following variations for ilio hpogastric nerve that it may arise from eleventh twelveth thoracic nerve or from twelveth thoracic nerve alone or from first lumbar nerve alone.

In the present study ilio hypogastric nerve receives a branch from the twelfth thoracic nerve in one specimen and in 49 specimens the ilio hypogastric nerve arises from first lumbar nerve. This coincides with Bardeen C.R.1906-07 observation and also coincides with W.Henry Hollinshed 1976 observation, that iliohypogastric nerve may arises from eleventh, twelveth thoracic nerve or from 12th thoracic nerve alone or from first lumbar nerve alone.

Coincides with Eisler's (1891) of lumbar plexus , Gray's Anatomy statement and Jack Joseph (1990) in Aids to Anatomy that both ilio inguinal and ilio hypogastric nerves are derived from first lumbar nerve.

Ilioinguinal nerve

According to E.A.Schafer and J.Symington in Quain's Elements of Anatomy ilio inguinal nerve is derived from first lumbar nerve and sometimes receives fibres from twelfth thoracic nerve.It may arise from

a loop between first and second lumbar nerve or even from second lumbar nerve.

According to Davies the ilioinguinal nerve may be regarded as the first collateral branch of the first lumbar nerve.

Henry Hollinshed also confirm the ilioinguinal nerve commonly arise from first lumbar nerve.

According to Ronald Bergman (1988) of virtual hospital 2000 University of Iowa out of 200 cadavers dissected ilioinguinal nerve arise from the common trunk with iliohypogastric nerve in twenty five percent of cases. It was absent in 2.5% ilioinguinal nerve was formed from one root in 92.5% and from two roots in about 5% of cases. In 86% the ilioinguinal carried fibres from one spinal nerve (primarily from L1) and in 11%, from two spinal nerves (T12, L1, L1 L2; or L2 L3).

The study of lumbar plexus branching pattern is very useful. Particularly to avoid injury to the ilioinguinal nerve in surgery like routine and laproscopic herniorrhaphy.

In the present study ilioinguinal nerve derived from L1 in 48 specimens. Coincides with observation of J.Symingten Quain's Anatomy and Henry Hollinshed.

In one specimen ilioinguinal nerve arises from second lumbar nerve which coincides with J.Symington observations.

According to J.Symington Quain's Anatomy and Henry Hollinshed the ilioinguinal nerve arises from loop formed between first and second lumbar nerve, this variation was seen in one specimen. In present work the ilioinguinal nerve arises form third lumbar nerve in one specimen and was absent in one specimen , which coincides with Ronald Bergman observation and Gray's anatomy (2008)

According to W.Henry Hollinshed 1976 the following variations for ilioinguinal nerve arises from twelfth thoracic nerve alone or from twelfth thoracic nerve and first lumbar nerve. In the present study this variations was not observed in any specimens.

Genitofemoral nerve

EA Schafer and J.Symington in Quain's elements of Anatomy states, the Genito femoral nerve originates chiefly from second lumbar nerve but receives few fibres from the connecting branch of first and second lumbar nerve. It descends obliquely through the substance of

psoas major muscle; emerges on the anterior surface of that muscle, divides into genital and femoral branches.

In Gray's anatomy, genitofemoral nerve often divides close to its origin. Its branches namely genital and femoral emerge separately from the psoas major muscle to supply cremaster muscle and skin of front of the thigh.

The anatomical study of genitofemoral nerve is useful to avoid injury to it while herniorrhaphy, vasectomy and varicocoelectomy. In the present study genitofemoral nerve originates from first and second lumbar nerve in all 50 specimens. In four specimens the genitofemoral nerve divides close to its origin as genital and femoral branch. This observation coincides with Gray's Anatomy.

According to Eisler of and Ronald (1891) A. Bergman, two divisions of genitofemoral nerve genital and femoral branches often arises independently from lumbar plexus Quain's anatomy. This observation was not seen in the present study.

Lateral femoral cutaneous nerve of thigh

According to schefer and Symington normally lateral femoral cutaneous nerve arises from second and third lumbar nerves, descends

from the outer border of the psoas major muscle, it crosses the iliacus lying beneath the iliac fascia, passes under the inguinal ligament to enter the thigh and there divides into anterior and posterior branches.

According to Griffin.M Quain's anatomy 11th edition in the normal form it is derived mainly from second lumbar nerve and it also receives small root from the third lumbar nerve.

According to Ronald A. Bergman 1988 in compendium of Human Anatomic variation urban and Schwarzeborg Munich and Baltimore states that this nerve may arise from the femoral nerve, several variations in the formation, course and branches of this nerve have been reported. .

According to J.Symington of Quain's Anatomy, the lateral femoral cutanoeus nerve often accompanies or is united with femoral nerve below the inguinal ligament.

W.Henry Hollinshed 1976, gives the following variations for lateral cutaneous nerve of thigh. In the high form it arises from T12-L2; L1-L2. In the low form it arises from L3-L4.

Knowledge about lateral femoral cutaneous nerve helps to avoid injury to this nerve causing meralgia parasthetica while taking iliac crest bone graft.

Anat Sci Int 2002 Dec 77(4); 247-9 Variations of LFCN Erbill KM et al, Department of Anatomy Hacettepe University Turkey. Dissected 28 cadavers variations seen in two. one on right, ventral rami of First and Second lumbar spinal nerves were united and then this nerve was divided into four branches from medial to lateral these were obturator, femoral, medially located lateral femoral cutaneous nerve and laterally located lateral femoral cutaneous nerve. On the left side there were three lateral cutaneous nerve, all these pierced the psoas major muscle anterolaterally.

Two of these nerves, which pierces the psoas major muscle more proximally than third, united with each other by communicating branch anterior to the iliacus muscle. This type of variations are very important to prevent injury and occurrence of meralgia paraesthetica.

In the present study the lateral femoral cutaneous nerve of thigh arises from second and third lumbar nerve in 40 specimens. It coincides with J.Syminton's observation.

In two specimens the lateral cutaneous nerve arises from the first and second lumbar nerve and in two specimens from second nerve, high form.

In three specimens the lateral cutaneous nerve of thigh arises from third lumbar nerve low form, this observation was coincide with Hollinshed and Griffins statement.

In two specimens the lateral cutaneous nerve arises from the femoral nerve this observation coincides with Ronald A.Bergman 1988.

In one specimen the lateral cutaneous nerve was divided into two branches. This observation was coincides with, Erbil KM et al, Anat. Sci (2002).

In present study on branching pattern of lumbar plexus, the most variations was found with formation of lateral femoral cutaneous nerve of thigh, which coincides with Gray's anatomy (2008) and Henry Hollinshed.

Femoral nerve

The study of femoral nerve helps to avoid Injury to it, in psoas abscess, inguinal block dissection and in pelvis fracture.

According to Gray's Anatomy, femoral nerve is the largest nerve arising from dorsal branches of second, third and fourth lumbar ventral rami. It emerges on the lateral border of psoas major muscle, passes

between it and the iliacus muscle deep to iliac fascia. Then it passes behind the inguinal ligament to reach front of thigh 1989.

This observation coincides with the present study in the 49 specimens.

According to Eisler it is the largest nerve arising from lumbar plexus. It arises from third and fourth lumbar nerves usually but in high forms arises from first and second lumbar nerve.

This variation was not observed in the present study.

Bardeen C.R. and A.W.Elting (1901) in a statistical study of the variations in the formation and position of the lumbo-sacral plexus in man. Anat. Anz., 19:124-128, 209-232 states that femoral nerve in normal form arises from second lumbar to fourth lumbar nerves. In high form it arises from Twelfth thoracic to fourth lumbar nerves and in low form it arises from third lumbar to fifth lumbar nerves.

In the present study, femoral nerve arises from second, third and fourth lumbar nerves in 49 specimens which coincides with Bardeen's observation that femoral nerve in normal form arises from second lumbar to fourth lumbar nerves,

In the present study femoral nerve arises from second, third, fourth and fifth lumbar nerves in one specimen. This coincides with Henry Hollinsheds - variations of femoral nerve.

This is also observed by Onderoglu and his colleagues (1998) Folia Morphol (Warsz)

Obturator Nerve

The study of obturator nerve helps in clinical diagnosis like referred pain due to disease of hip joint, and inflammatory disease of ovary and also in treatment plan like obturator neurectomy to relieve adductor spasm.

According to Gray's Anatomy 37th edition usually obturator nerve arises from anterior divisions of second, third and fourth lumbar ventral rami. Third division being the largest, the one from the second is very is small.

The obturator nerve sometimes has an additional root from the first in the high form or fifth lumbar nerves in low form of plexus. The root from second is always present Eisler 1891 on lumbar plexus - Quains anatomy.

W.Henry Hollinshed (1976) gives the following variations for obturator nerve. In the high form of plexus it arises from first to fourth lumbar nerves and in the low form of plexus it arises from third lumbar nerve to fifth lumbar nerves.

In the present study obturator nerve arises from second, third and fourth lumbar ventral rami in 49 specimens and in one specimen arises from ventral rami of third, fourth and fifth lumbar nerves. This coincides with Eisler study and variations given by Henry Hollinshed.

Accessory Obturator Nerve

Knowledge about the accessory obturator never helps to diagnose the referred pain in hip join disease where articular twig to hip joint arises from accessory obturator nerve when it present.

According to Gray's Anatomy thirty seventh edition accessory obturator nerve is small and occasionally present. It arises from the ventral branches of the third and fourth lumbar ventral rami. It descends along the medial border of the psoas major, crosses the superior pubic ramus behind the pectineus and divides into three branches, one entering the deep surface of the pectineus, another supplying the hip joint and third connecting with the obturator nerve's anterior branch.

According to Russell T.Woodburne (1956) The Anatomical Record 136, 367-368. The small accessory obturator nerve arises form the lumbar plexus by roots from the third and fourth lumbar nerves which emerge between the roots of origin of the obturator and femoral nerves. It parallels the obturator nerve along the medial side of the psoas muscle but runs somewhat more ventrally. Characteristically, the accessory obturator nerve passes deep to the expansion of the psoas minor tendon to cross the superior ramus of the pubis directly on the bone.

Eisler in 1891 in his discussion on lumbo sacral plexus of man reported finding accessory obturator nerve in 8 of 32 cases frequency of 25%. The Anatomical Record 136, 367. In the present study it is observed in four out of fifty specimens which is about 8%. So it does not coincide with Eisler's study.

Bardeen in 1906 found the accessory obturator nerve to be present in 21 of 250 specimen. A frequency of 8.4%. So the present study almost coincides with Bardeen study.

De sousa (1942) reported a 19% occurrence, in his study which does not coincide with the present study.

Kaiser (1949) found it in two of 24 sides, an 8.3% frequency.

Lumbosacral Trunk

According to Gray's Anatomy 37 edition. The lumbosacral trunk comprises of part of the fourth and whole of the fifth lumbar ventral rami; it appears at the medial margin of the psoas major, descending over the pelvic brim anterior to the sacro-iliac joint to join the first sacral ramus.

Bardeen, C.R. (1901) a statistical study of the variations in the formation and position of the lumbo-sacral plexus in man. Anat. Rec. 19:124-128, 209-232 states that contribution of lumbo sacral trunk may come from third lumbar. Sometimes the branch from fourth lumbar nerve to the lumbosacral plexus is absent. In such cases, the fifth lumbar nerve supplies branches to both the lumbar and sacral plexuses. Thus, contributions to both plexuses may come from the fourth lumbar nerve, the third and fourth, the fourth and fifth or the fifth lumbar nerve alone.

W.Henry Hollinshed 1976, 3rd Edition states that the lumbo sacral trunk is formed from the part of ventral branch of fourth lumbar nerve, the other part forms part of obturator nerve. It descends downward to join or parallel the corresponding branch of fifth and with that form the lumbosacral trunk, which joins the sacral plexus.

R.J.Last in ninth edition 1994 states that lumbo sacral trunk is formed from fourth and fifth lumbar nerves which forms part of sacral plexus.

In the present study out of 50 specimens lumbo sacral trunk is formed by part of the fourth and the whole of the fifth lumbar ventral rami in 49 specimens where it appears at the medial margin of the psoas major, descending over the pelvic brim anterior to the sacro-iliac joint to join the first sacral ramus. This observation coincides with the Gray's Anatomy thirty seventh edition W.Henry Hollinshed and R.J.Last.

In one specimen fifth lumbar nerve gives a furcal branch, that forms post fixed type of lumbar plexus.

CONCLUSION

The present work was carried out to study the site, formation and branching pattern of lumbar plexus in 50 specimens.

The site of lumbar plexus was noticed in the posterior part of substance of psoas major muscle in 50 specimens and in four specimens the lumbar plexus was located in the substance of psoas minor muscle also.

Of all the specimens (50), one showed the pre fixed type and one showed the post fixed type of lumbar plexus.

Variations for iliohypogastric, obturator and femoral nerve was observed in one specimen and for ilioinguinal, genitofemoral, and accessory obturator nerve was observed in four specimens.

Variations in the formation of lateral femoral cutaneous nerve was observed in ten specimens, of which five were low form and five were high form.

Thus the knowledge of anatomy of lumbar plexus in relation to its site, formation, branching pattern and variations are useful to surgeons, not only in surgical procedures, but also in diagnosing various clinical conditions associated with it, like referred pain, psoas abscess and hip joint diseases.

BIBLIOGRAPY

1. Anson, B.J., Ed. (1966) Morris' Human Anatontm 12th ed., The Blakiston Division, McGraw-Hill Book Company, New York.
2. Bardeen, C.R. (1906-07) Development and variation of the nerves and the musculature of the inferior extremity and of the neighboring regious of the trunk in man. Am. J. Anat. 6:259-390.
3. Bardeen, C.R. and A.W. Elting. (1901) A statistical study of the variations in the formation and position of the lumbo-sacral plexus in man. Anat. Anz. 19: 124-128, 209-232.
4. Bergman, R.A., Thompson, S.A., Afifi, A.K. and F.A. Saadeh. (1988) Compendium of Human Anatomic Variation., Urban & Schwarzenberg, Munich and Baltimore.
5. Eisler (1891) discussion of the lumbosacral plexus of man Anat. Anz., 6:274-281.
6. Erbil Km et al. Anat Sci Int 2002 Dec 77(4): 247-9. Department of Anatomy Hacettepe University Turkey. Variations of Lateral Femoral cutaneous nerve.

7. Erbil Km Onderoqlu. S, Basar R, Okajimas Folia Anat Jpn 1999 May; 76(1) 55-9 unusual branching in lumbar plexus.
8. Fann AV. Anatomy and evaluation of the lumbosacral plexus. In Physical Medicine & Rehabilitation Clinics of North America. 9(4) : 815-29.
9. Farny J, Drolet P, Girard M. France. Anatomy of the posterior approach to the lumbar plexus block. Can J Anaesth, 1994 Dec; 41(2) : 1238-9.
10. Gault D.T. FRCS, P.J.Smilt MB FRCS Feripheral nerves in New Airds' companion in Surgical studies Ii Edition.
11. Grays Anatomy 2008 (40th) Edition. Articles in Chinese. Zhonghuawai Kezazhi et al 2008 May 46(9): 647-9. Clinical anatomy of lumbar plexus in lumbar – anterolaterally.
12. Hanna MH, Peat SJ, D'Costa F. Anaesthesia 1993 Aug; 48(8):675-8 Lumbar Plexus block : an anatomical study.
13. Hentry Hollinshed W.Text Book of Anatomy 1976 3rd Edition.
14. Hospodar PP, Ashman ES, Traub JA. Anatomic study of the lateral femoral cutaneous nerve with respect to the ilioinguinal surgical dissection. J Ortho Trauma 1999 Jan: 13 (1): 17-9.

15. Ibid., 28: 169-191.1894 The origin and distribution of nerves to the lower limb.
16. Jamieson, E.B. (1903) Some anomalies in nerves arising from the lumbosacral plexus, and a bilaminar musles pectineus in a foetus; and on variations in the nerve supply in man and in some other mammals. J. Anat.Physiol. 37:266 – 286.
17. Kaiser, R.A. 1949 Obturator and accessory obturator nerves. J. Bone Jt. Surg., 31A : 815-819.
18. Katritsis, E., Anagnostopoulou, S. and N. Papadopoulos. (1980) Anatomical observations on the accessory obturator nerve (Based on 1000 speciments). Anat. Anz. 148:440-445.
19. Mine Erbil K, Onderoglu S, Basar R. Unusual branching in lumbar plexus. Folia Morphol (Warsz) 1998:57 (4) : 377-81.
20. Minerva Anestesiol 2005 sep: 71(9): 549-54. Anatomy and imaging of lumbar plexus.
21. Moro T, Kikuchi, Konno S, YaqinumaH-2003 Mar 1; 28(5): 423-8, discussion 427-8. Anatomic study on lumbar plexus with respect to retroperitoneal endoscopic surgery.

22. Oelrich, T.M. and D.A. Moosman. (1977) The aberrant course of the cutaneious component of the ilioinguinal nerve. Anat. Rec. 189-23, 3-236.
23. Papadopoulos, N.J. and E.D. Katritsis. (1981) Some observations on the course and relations of the iliohypogastric and ilioinguinal nerves (based on 348 specimens). Anat. Anzeiger 149:357 -364.
24. Paterson, A.M. (1894) The origin and distribution of the nerves to the lower limb. J. Anat. Physiol. 28: 84-95, 169-193.
25. Piasecka Kacperska & Gladyskowsha-Rzeczycka (1972) have reviewed the variations in primates, including mankind (Gray's Anat) Folio Morphol 312:21-33.
26. R.J. Last Surgical Anatomy 8th Edition 1990.
27. Rosenberger RJ, Loeweneck H, Meyer G. Munich, Germany. The cutaneious nerves encountered during laparoscopic repair of inguinal hernia: new anatomical findings for the surgeon. Surg. Endosc 2000 Aug; 14 (8) : 731-5.
28. Schaefer, E.A. Symington, J. and T.H. Bryce, Eds. (1915) Quain's Anatomy, Longmans, Green and Co., London.

29. Urbanowicz, Z. (1981) Connections between the lumbar and the sacral plexus in man. Folia Morphol. (Warsaw) 40:271-279.

30. Urbanowicz, Z. and S. Zaluska (1969) Formation of the lumbar plexus in man and macaca. Folia Morphol. (Warsaw) 28: 256-271.

31. Webber, R.H. (1961) Some variations in the lumbar plexus of nerves in man. Acta. Anat. 44:336-345.

32. Woodburne, R.T. (1956) The accessory obturator nerve and the innervation of the pectineus muscle. Anat. Rec. 136:367-369.

33. Zaluska, S. (1971) The obturator nerve in man and macaca. Folia Morphol. (Warsaw) 30:89-96.

34. Zaluska, S. (1975) External structure of the ilioinguinal nerve in postnatal life in man. Folia Morphol. (Warsaw), 34:419-424.

LUMBAR PLEXUS

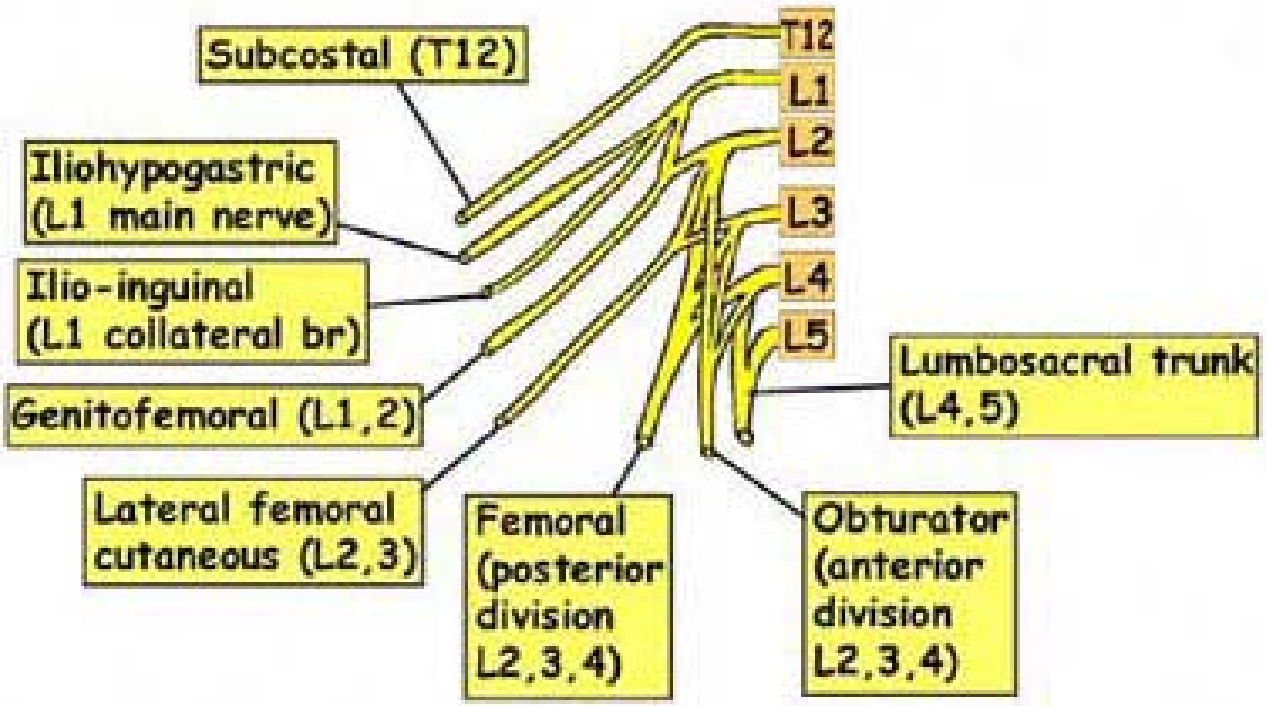

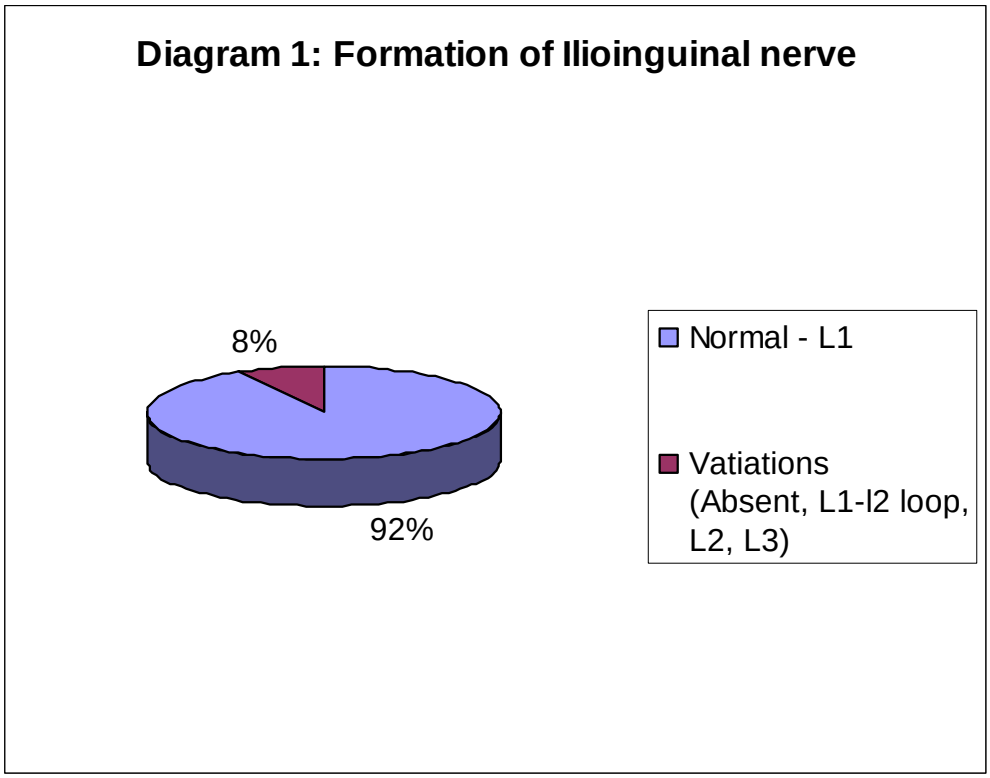
Diagram 1: Formation of Ilioinguinal nerve
8%
92%
Normal - L1
Vatiations (Absent, L1-l2 loop, L2, L3)

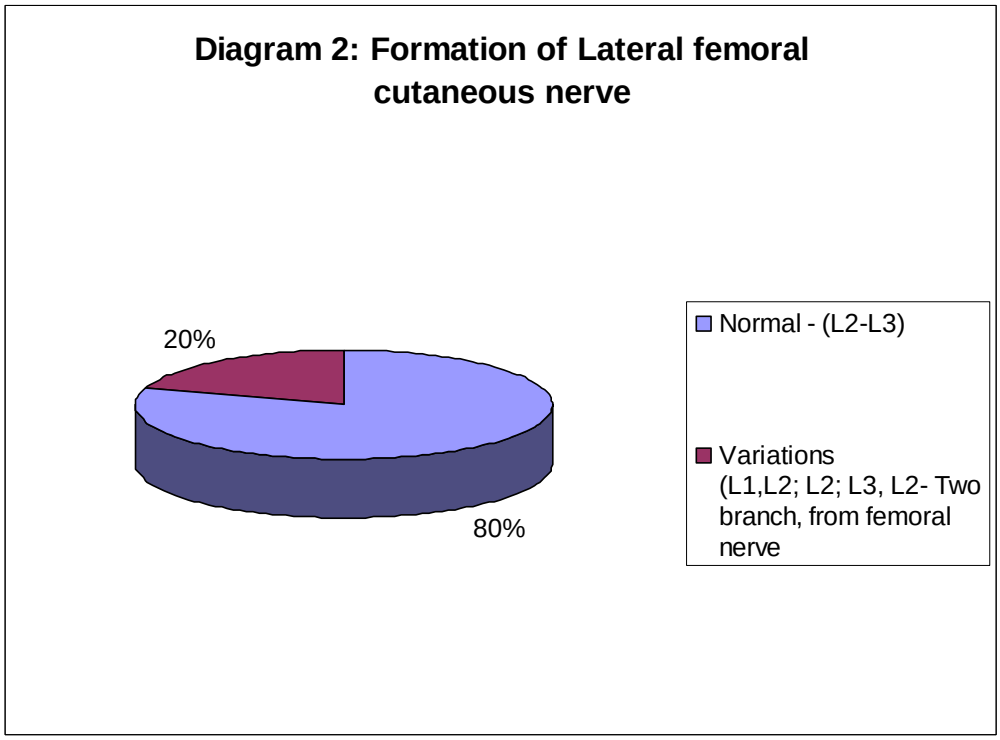
Diagram 2: Formation of Lateral femoral cutaneous nerve
20%
80%
Normal - (L2-L3)
Variations (L1,L2; L2; L3, L2- Two branch, from femoral nerve

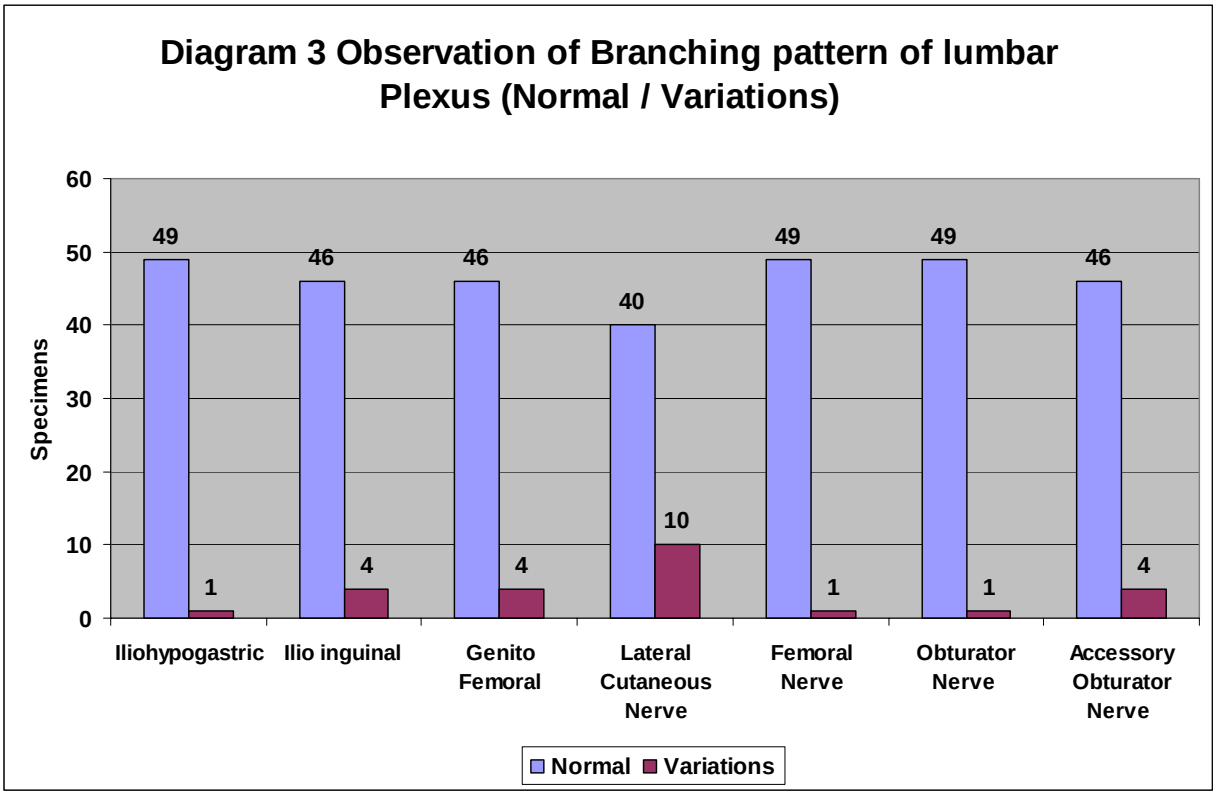
Diagram 3 Observation of Branching pattern of lumbar Plexus (Normal / Variations)
Specimens
60
50
40
30
20
10
0
49
1
46
4
46
4
40
10
49
1
49
1
46
4
Iliohypogastric
Ilio inguinal
Genito Femoral
Lateral Cutaneous Nerve
Femoral Nerve
Obturator Nerve
Accessory Obturator Nerve
Normal
Variations

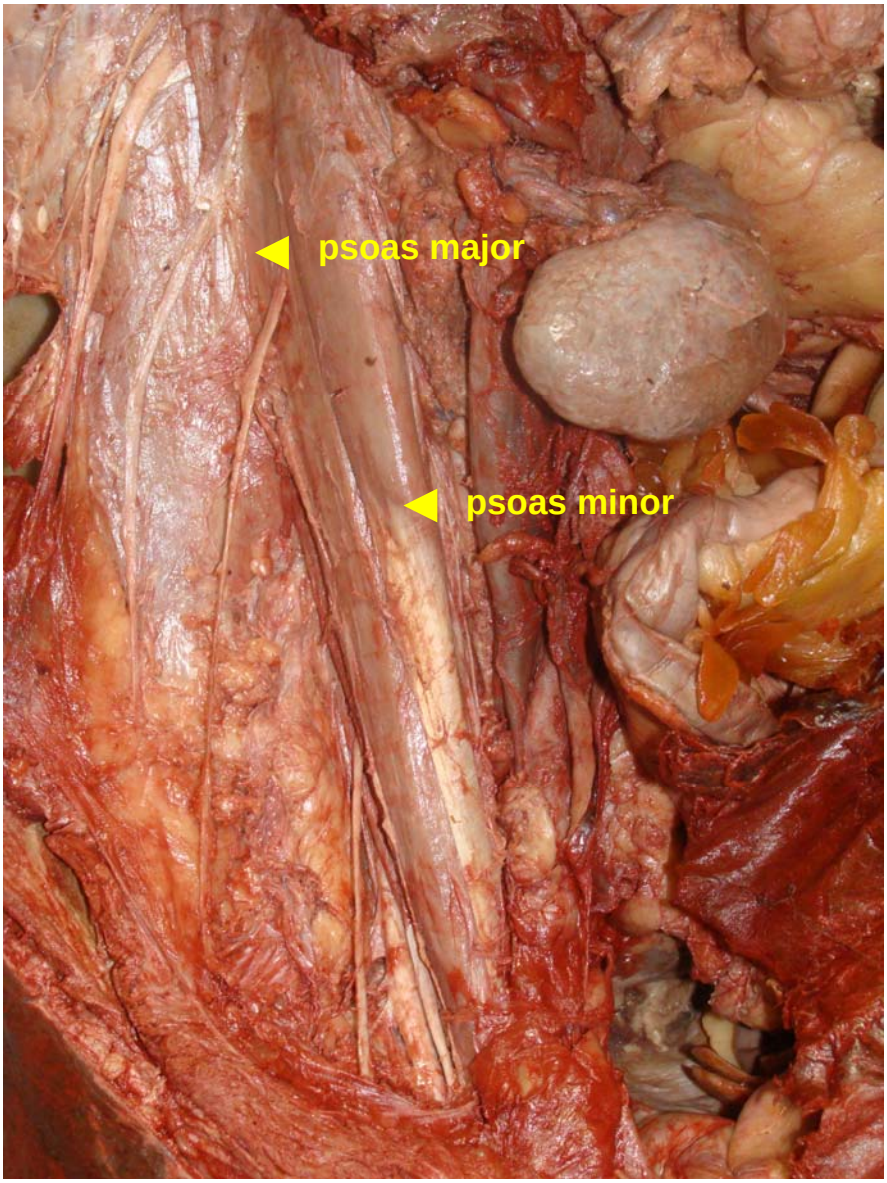

Fig.1 Lumbar plexus within the substance of psoas major and psoas minor muscle

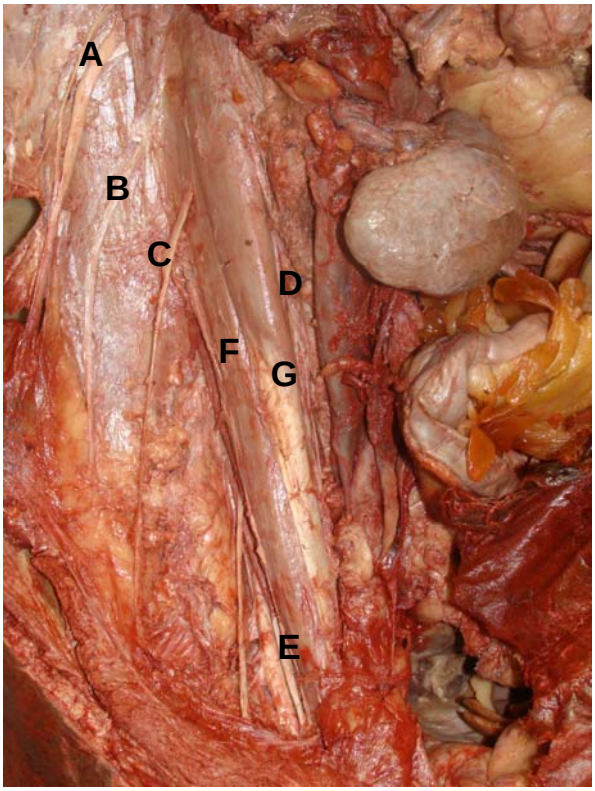

A. Iliohypogastric nerve
B. Ilioinguinal nerve
C. Lateral cutaneous nerve
D. Genitofemoral nerve
E. Femoral nerve
F. Psoas major
G. Psoas minor

Figure 2 Normal branching pattern of lumbar plexus

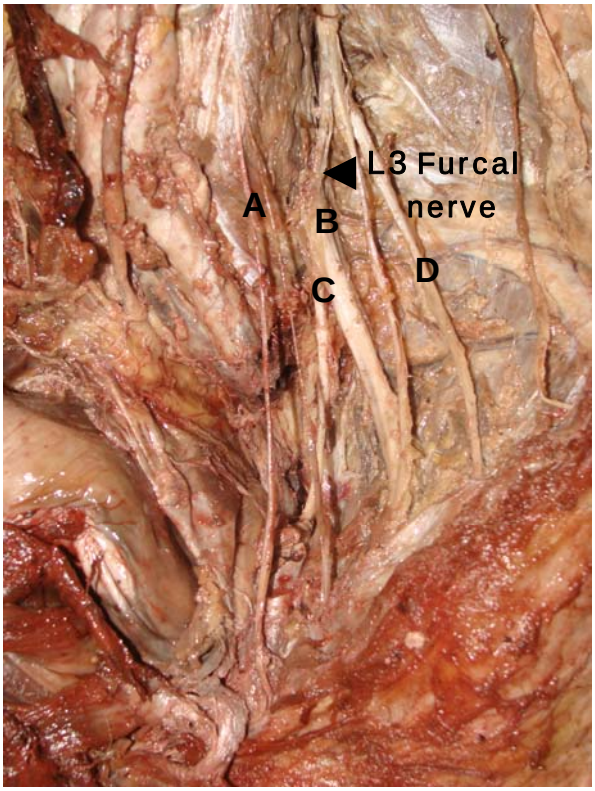

A. Genitofemoral nerve
B. Femoral nerve
C. Obturator nerve
D. Lateral cutaneous nerve

Figure 3 Third lumbar nerve gives a furcal branch to fourth nerve

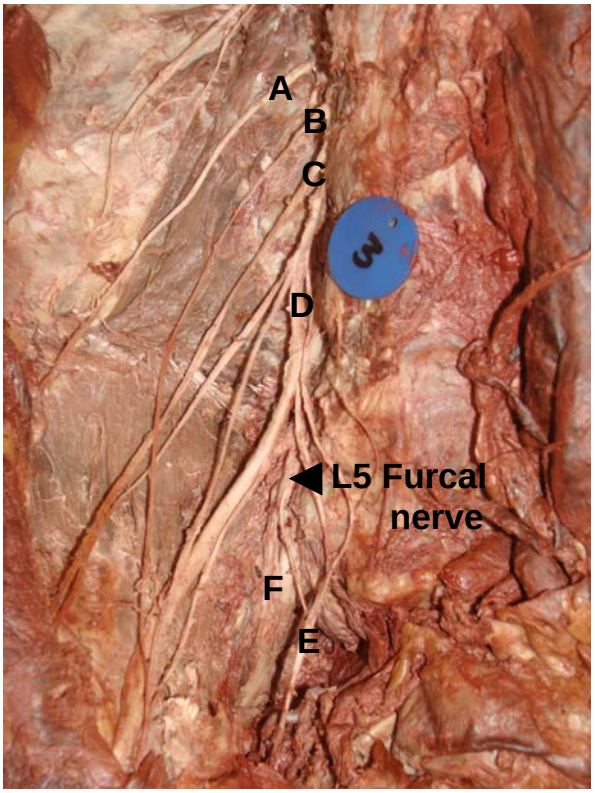

A Iliohypogastric nerve
B. Ilioinguinal nerve
C. Lateral cutaneous nerve
D. Femoral nerve
E. Obturator nerve
F. Lumbo sacral trunk

Figure 4 Fifth lumbar nerve gives a furcal branch

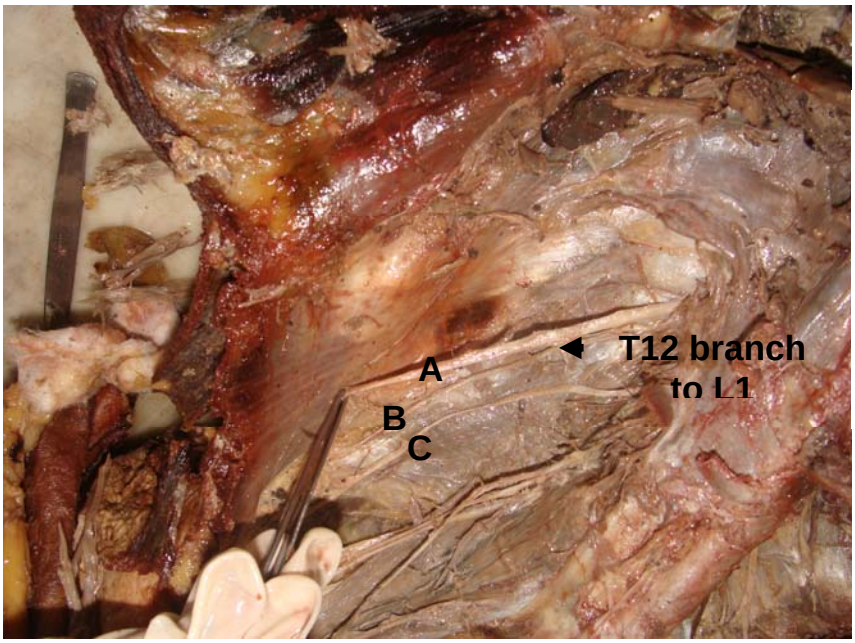

A Sub costal nerve
B. Iliohypogastric nerve
C. Ilioinguinal nerve

Figure 5 Iliohypogastric receives a branch from subcostal nerve

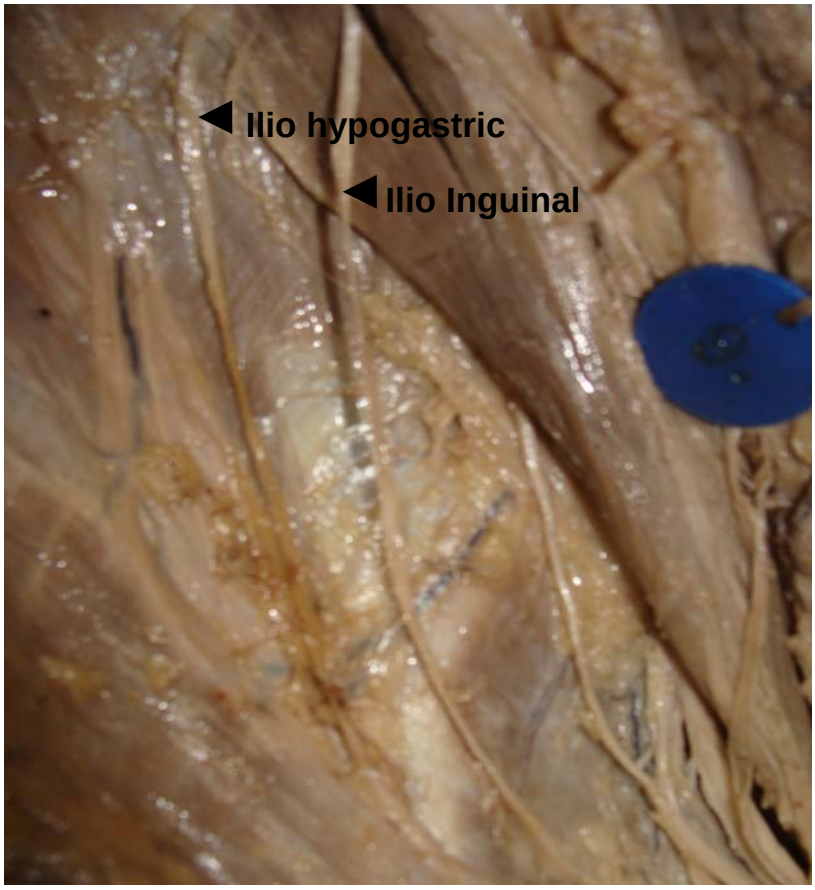

Figure 6 Ilioinguinal nerve from L2

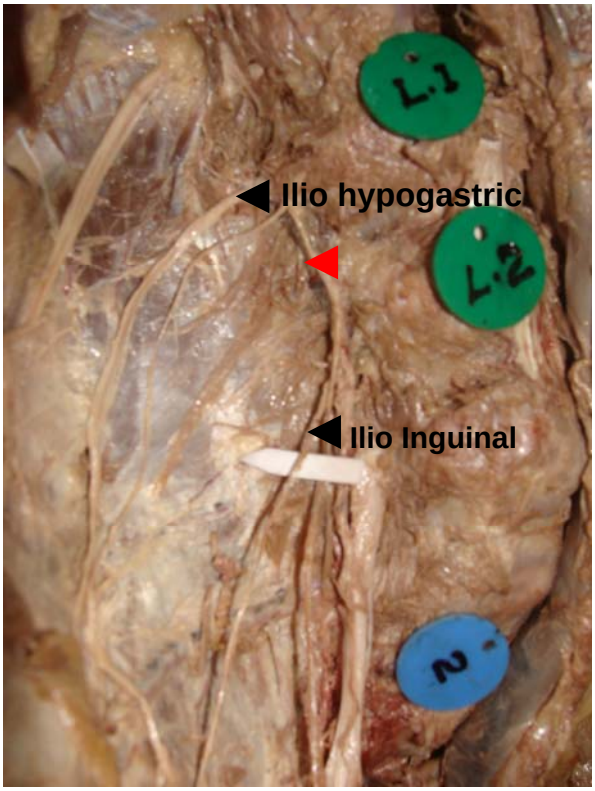

Figure 7 Ilioinguinal nerve from L1-L2 loop

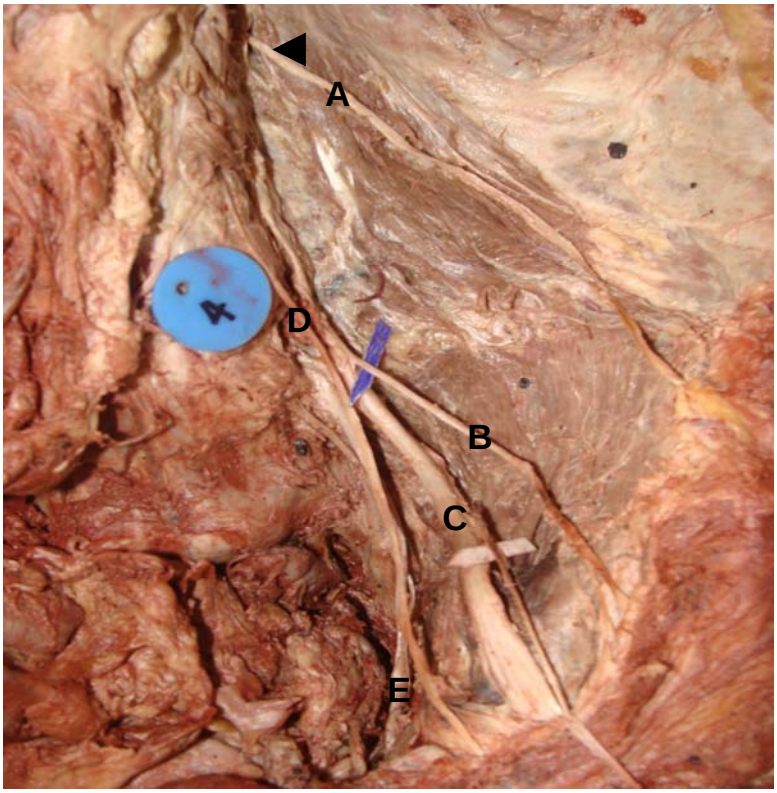

A. Ilioinguinal nerve
B. Lateral cutaneous nerve
C. Femoral nerve
D. Genitofemoral nerve
E. Obturator nerve

Figure 8 Ilioinguinal nerve from third lumbar nerve - L3

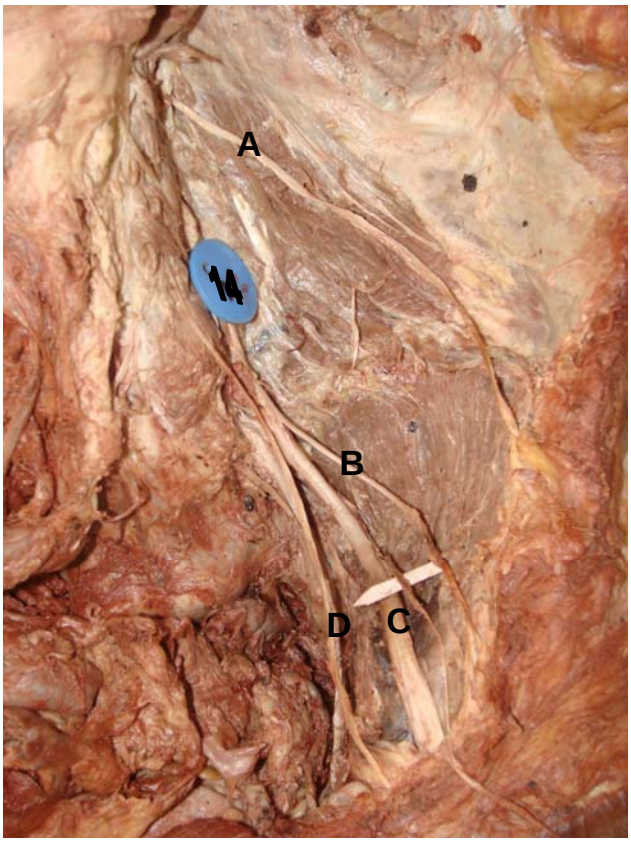

A. Iliohypogastric nerve
B. Lateral cutaneous nerve
C. Femoral nerve
D. Obturator nerve

Figure 9 Iioinguinal nerve absent

A. Genitofemoral nerve
A_1. Genital branch
A_2. Femoral branch
B. Psoas major

Figure 10 Genitofemoral nerve in the anterior substance of psoas muscle

A. Genitofemoral nerve
A_1.Genital branch
A_2.Femoral branch
B. Psoas major
C. Ilioinguinal nerve

Figure11 Higher division of Genitofemoral nerve as genital and femoral branch

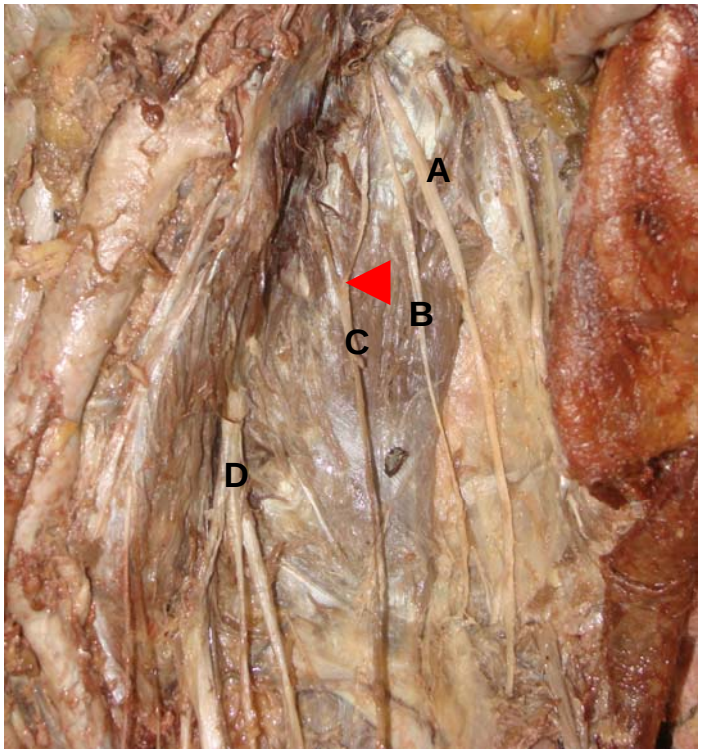

A. Iliohypogastric nerve
B. Ilioinguinal nerve
C. Lateral cutaneous nerve
D. Femoral nerve

Figure12 Lateral femoral cutaneous nerve from L1, L2. High form

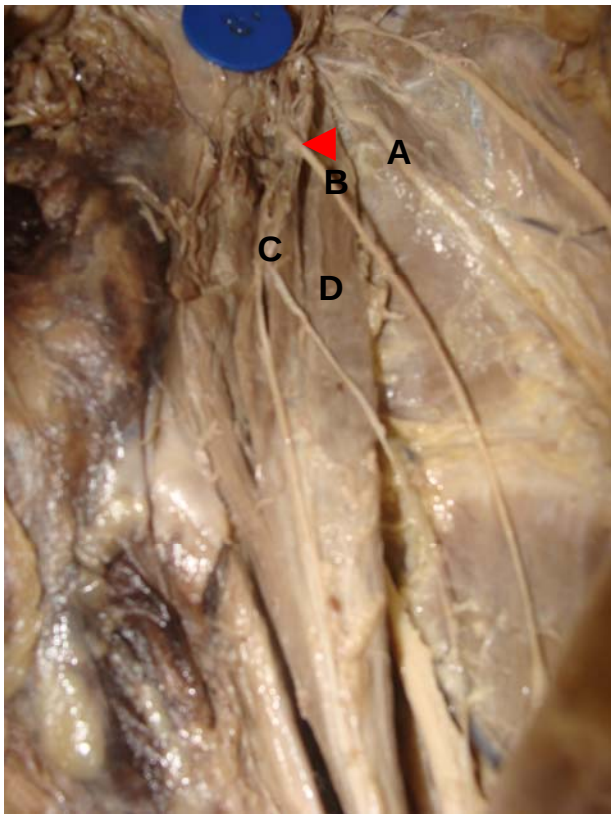

A. Ilioinguinal nerve
B. Lateral cutaneous nerve
C. Genito femoral nerve
D. Psoas major

Figure 13 Lateral femoral cutaneous nerve from L2 – High form

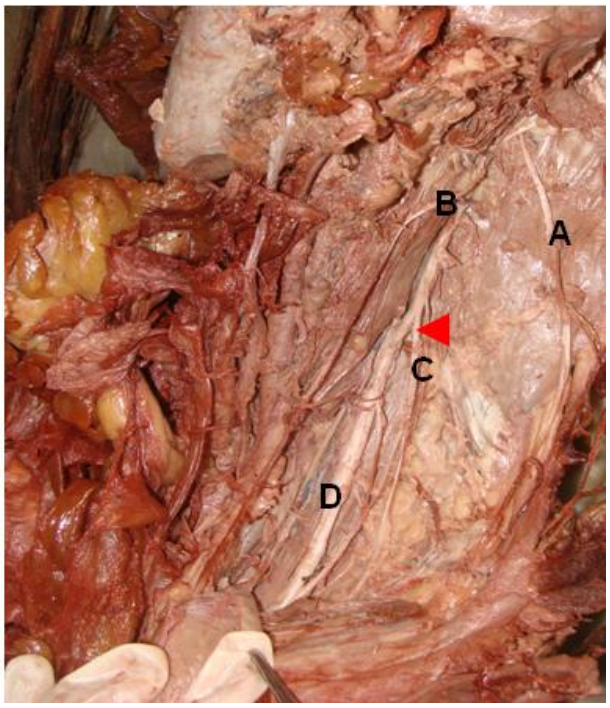

A. Iliohypogastric nerve
B. Genito femoral nerve
C. Lateral cutaneous nerve
D. Femoral nerve

Figure 14 Lateral femoral cutaneous nerve from L3 – Low form

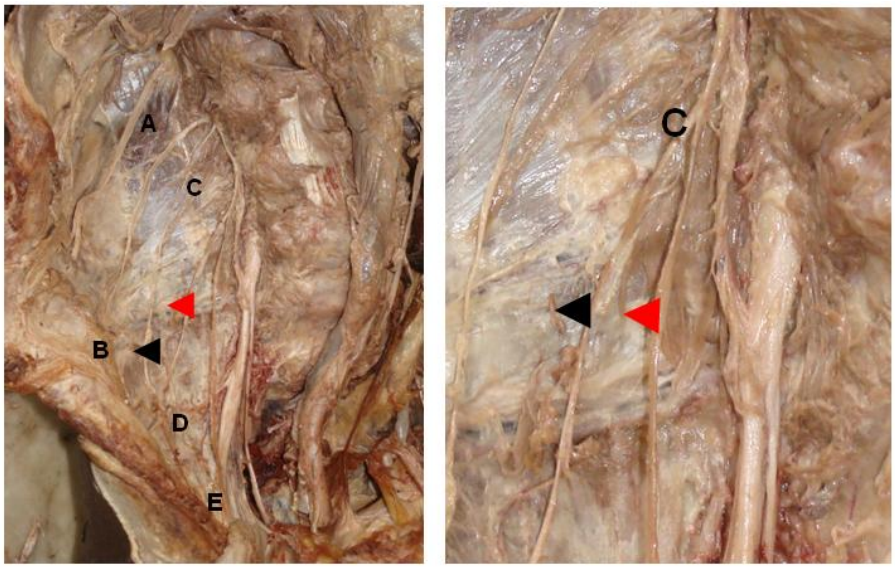

Figure 15 Lateral femoral cutaneous nerve as two branch

A. Iliohypogastric nerve **B. Ilioinguinal nerve** **C. Lateral cutaneous nerve**
D. Femoral nerve **E. Obturator nerve**

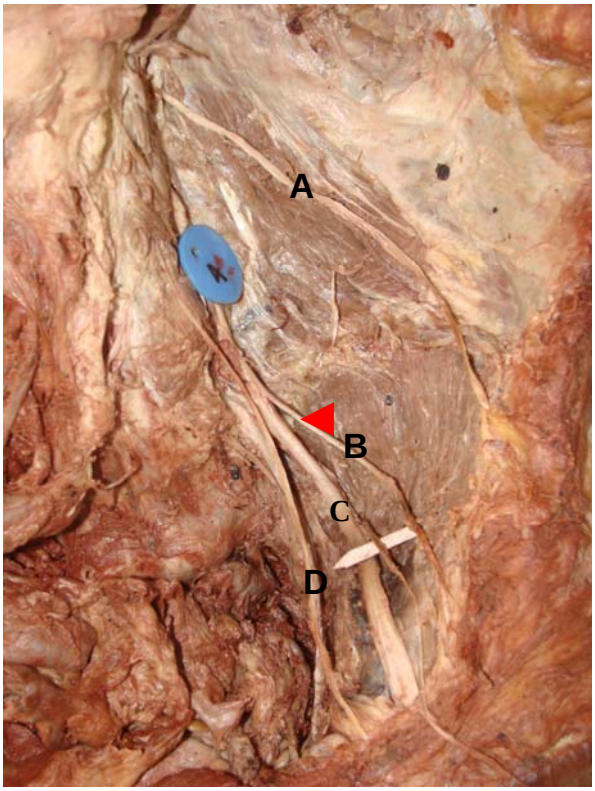

A. Ilioinguinal nerve
B. Lateral cutaneous nerve
C. Femoral nerve
D. Obturator nerve

Figure 16 Lateral femoral cutaneous never as branch of femoral nerve

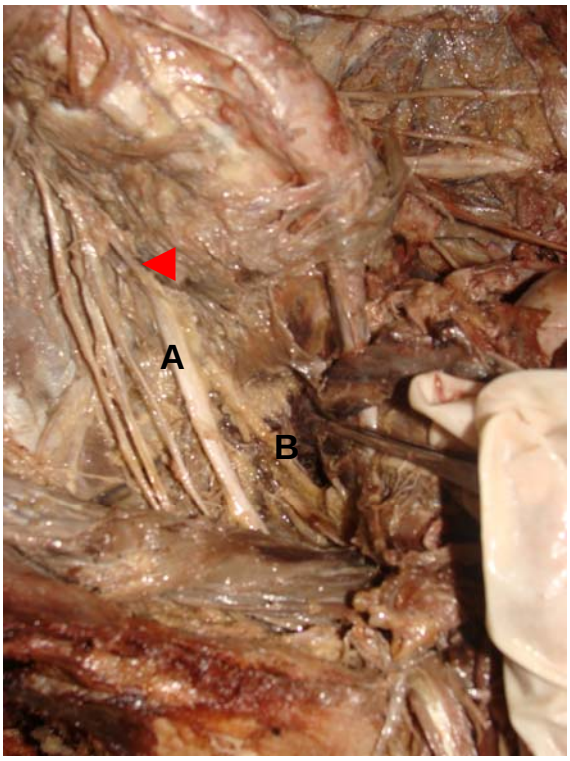

A. Femoral nerve
B. Obturator nerve

Figure 17 Fifth lumbar nerve gives branch to femoral nerve – low form

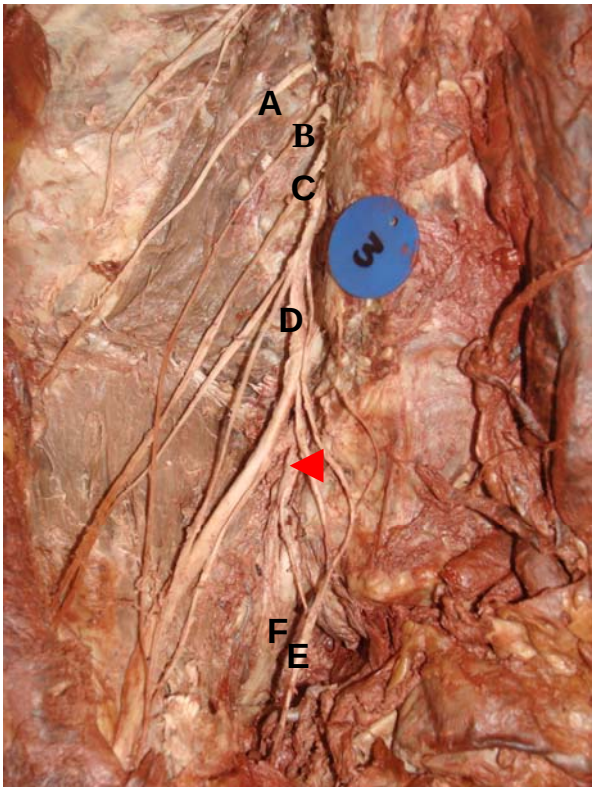

A Iliohypogastric nerve
B. Ilioinguinal nerve
C. Lateral cutaneous nerve
D. Femoral nerve
E. Obturator nerve
F. Lumbo sacral trunk

Figure 18 Fifth lumbar nerve gives branch to obturator nerve – low form

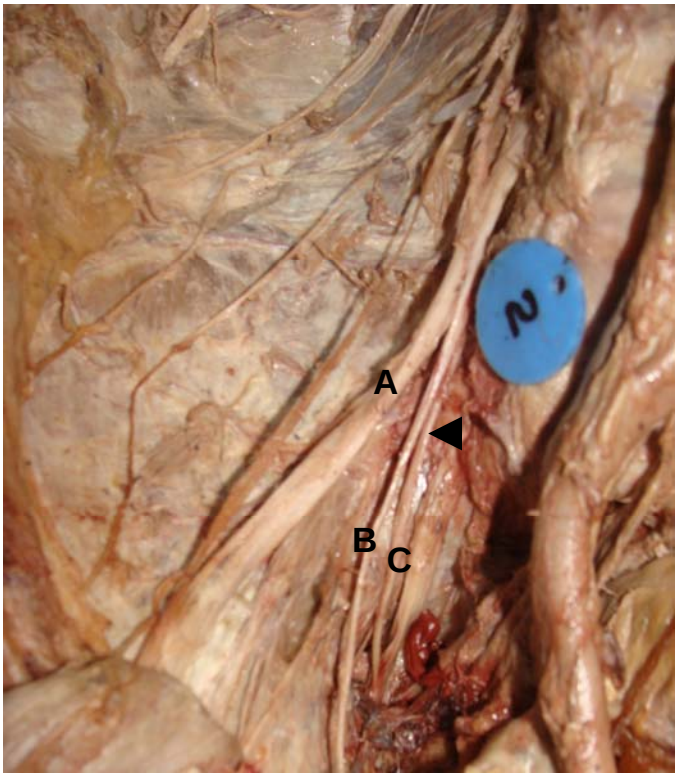

A. Femoral nerve
B. Obturator nerve
C. Accessory obturator nerve

Figure 19 Accessory obturator nerve formed by third, fourth lumbar nerves

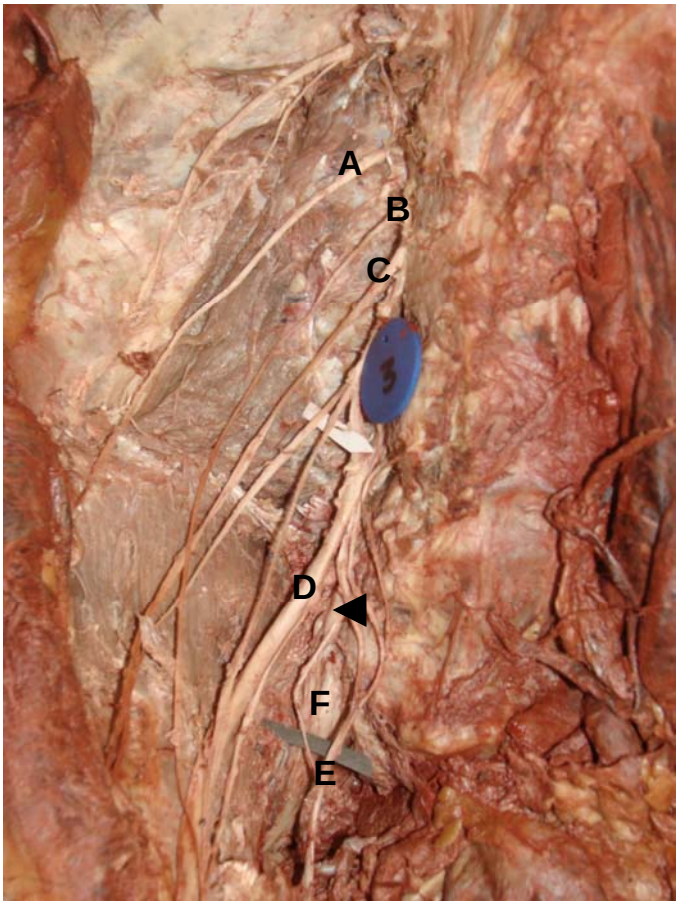

A Iliohypogastric nerve
B. Ilioinguinal nerve
C. Lateral cutaneous nerve
D. Femoral nerve
E. Obturator nerve
F. Lumbo sacral trunk

Figure 20 Fifth lumbar nerve gives branch to lumbosacral trunk