THE TAMILNADU DR.M.G.R. MEDICAL UNIVERSITY

CHENNAI – TAMILNADU

DISSERTATION

ON

A STUDY ON THE BRANCHING PATTERN OF MIDDLE CEREBRAL ARTERY

Submitted for M.S.Degree Examination
Branch V
(Anatomy)
Examination in September 2006

MADURAI MEDICAL COLLEGE
MADURAI

CERTIFICATE

Certified that this is a bonafied record of the work entitled **"DISSERTATION ON A STUDY ON THE BRANCHING PATTERN OF MIDDLE CEREBRAL ARTERY"** done by for the submission in partial fulfillment of requirement for the award of M.S. Department for September 2006 of the Tamilnadu Dr. M.G.R. Medical University, Chennai carried out her under my direct supervision and guidance.

Director and Professor
Institute of Anatomy
Madurai Medical College,
Madurai

ACKNOWLEDGEMENT

I hereby convey my profound gratefulness to Professor **Dr.T.HARIHARAN, M.S.,** Director and Head of the Institute of Anatomy, Madurai Medical College, Madurai for his able guidance innumerable suggestions and helped me a lot in completing this study. True to my heart, without his help and guidance, this compilation of specimen completion of study would not have been possible.

I am extremely grateful to Professor. **Dr.Meiyalagan, M.D.,** Head of the Department of Forensic Medicine and his staff for the help rendered by them for collection of specimens.

I am extremely grateful to Assistant Professor **Dr.V.Rajaram, M.S.,** for his help in my study.

I am grateful to the non teaching staff of the Department of Anatomy, Madurai Medical College.

I am really thankful to **Dr.Kalavathi Ponniraivan** and **Dr.Saraswathi M.S.,** Dean, Madurai Medical College for her kind permission to conduct and to complete the study.

INTRODUCTION & AIM OF STUDY

INTRODUCTION AND AIM OF STUDY

It is brought to the light of medical world that the lesion of the middle cerebral artery is the commonest catastrophes among the lesions of arteries of the brain, both internal carotid and vertebro basilar system.

In day to day life, due to urbanization of the even rural places, the change in the diet habits, the stress and strain which the people undergo, the tensions and emotions to which the people are subjected to compete with the modernization of the computer world, the sequence of occurrence of middle cerebral artery lesion is still more increased.

Usually the lesions are acute in onset, the patient should not have experienced even the earlier symptoms of any pathology in cerebral arteries. Due to poor knowledge of regular clinical checkup among the illiterate people, it is more commonly the illiterate who are subjected to this lesions when compared to the metropolitans. The cerebro vascular

catastrophe has become so common that in everyday clinical life we come across so many cases with varying manifestations and varying presentations of cerebral arterial lesions.

The lesion may be an isolated lesion, involving either the initial segment of artery or the divisions of artery or the branches of the divisions of the artery or it may be associated with lesions of other cerebral arteries.

Depending upon the clinical manifestations and based on the investigations we may have to modify the treatment. It may be either a Haemorrhage or Atheroma or a Thrombus or an Embolus which require different methods in therapy. The therapy varies depending upon the functional areas involved and the duration between the onset of the symptoms and the time the patient get admitted in the hospital and upon the percentage of the ischaemia developed in the functional areas.

As per update upto Nov. 18, 2003 the presentation of middle cerebral artery stroke syndrome include the following varied presentation.

Author: Daniel I Slater, MD, Staff Physician, Department of Physical medicine and rehabilitation, Medical college of Virginia.

Coauthor(s): Jeffery S Johns, MD, Director of Rehabilitation Consultation services, Department of physical medicine and rehabilitation, Charlotte Institute of Rehabilitation.

Daniel I Slater, MD, is a member of the following medical sciences: American Academy of Physical Medicine and Rehabilitation.

Editor(s): Partrick J Potter, MD, Director of Spinal Cord Injury Program, Associate Professor, Department of Physical Medicine and Rehabilitation, Parkwood Hospital Lawson Health Research Institute, Francisco Talavera, PharmD, PhD, Senior Pharmacy Editor, eMedicine; Richard Salcido, MD, Chairman, Erdman Professor of Rehabilitation, Department of Physical Medicine and Rehabilitation, University of Pennsylvania School of Medicine; Kelly L Allen, MD, Consulting Staff, Department of

Physical Medicine and Rehabilitation, Lourdes Regional Rehabilitation Center, Our Lady of Lourdes Medical center, and Denise I campagnolo, MD, MS, Director of Clinical Trials Research, Barrow Neurological Institute, St.Joseph's Hospital.

- Main trunk occlusion of either side yields contralateral hemiplegia, eye deviation towards the size of the middle cerebral artery infarct, contralateral hemianopsia, and contralateral hemianesthesia. Eye and head deviation towards the side of the lesion is probably due to damage to the lateral gaze center (Brodmann area 8), or it can represent classic neglect, particularly when the right Middle Cerebral Artery is involved.

- Trunk occlusion involving the dominant hemisphere causes global aphasia, whereas involvement of the nondominant hemisphere causes impaired perception of deficits (anosognosia) resulting from the stroke, as well as more qualitative deficits of speech, as discussed later in this article.

- Superior division infarcts lead to contralateral deficits with significant involvement of the upper extremity and face and partial sparing of contralateral leg and foot.

- Inferior division infarcts of the dominant hemisphere lead to Wernick's aphasia. Such infarcts on either side yield a superior quadrantanopsia or homonymous hemianopsia, depending on the extent of infarction. Right inferior branch infarcts also may lead to a left visual neglect. Finally, resultant temporal lobe damage can lead to an agitated and confused state.

- Loss of consciousness initially is rare after Middle Cerebral Artery stroke but occurs slightly more often than in vertebrobasilar strokes (8.4% vs 5.7%)

- Surprisingly, assigning clear-cut syndromes of weakness to specific territories of Middle cerebral artery infarct has posed a significant challenge. The prognosis of such motor deficit also has not completely been elucidated,

with case reports of remarkable recovery from dense limb involvement.

- Partial hemiparesis patterns have been mapped more readily to certain Middle cerebral artery territory infarts. The National Institute of Neurological and Communicative Disorders and stroke (NINCDS) data bank project gathered pilot data from 488 patients with unilateral hemisphere strokes.

- Hemianopsia has long been known to accompany the syndrome following a large Middle cerebral artery infarct.

- Autonomic disturbance after Middle Cerebral artery stroke often can be evidenced by contralateral edema of the hand and foot arising within hours of the infarct and lasting upto 2 weeks.

- Excessive sweating contralateral to the territory of an Middle Cerebral artery stroke can be indicative of a larger lesion, affecting deep and superficial branches.

- The left cerebral hemisphere is dominant for speech and language in more than 95% of right-handed individuals.

- Wernicke's aphasia, also termed receptive or sensory aphasia, is caused more often by occlusion of the lower division of the Middle Cerebral Artery bifurcation or one of its branches.

- Conductive aphasia classically is thought to be caused by a disruption of neural pathways or the arcuate fasciculus connecting the motor and sensory areas concerned with speech.

So the study of the middle cerebral artery, which has a wider distribution than anterior and posterior cerebral arteries, has been selected as my study.

REVIEW OF LITERATURE

REVIEW OF LITERATURE

Charcot 1868 reported a lateral lenticulostriate branch from the Middle cerebral artery when it his in the lateral surface of the Putamen.

Windle 1888 first described an anterior middle cerebral artery, in 4.5% of his cases.

Blackburn 1907 found the presence of Anterior Middle Cerebral artery in 42 of his 400 specimens.

Beevor C.E. (1909) found the lenticulostriate arteries destined to supply Basal Ganglia and Thalamus.

Shellshear J.L. 1920 has reported one artery to lenticulostriate was larger than others and he fount it passing around the lateral border of lenticular nucleus, when the named as the artery of internal Haemorrhage or the artery of charcot.

Horey H, and Shellshear J.L. 1925 found Middle cerebral artery supplying the lateral border of lentiform nucleus, 1925.

Shellshear 1925 Horey fixend middle cerebral artery supplying the lateral border of lentiform nucleus. 1920.

Folx C and Hillemand, Hyde J.B. 1925 found that the lateral striate arteries were about 0.5mm in diamter.

Frix and levy 1927 made a clinico pathological study of superior and inferior middle cerebral artery division occlusion, 1927.

Adachi and Hascbe 1929 reported the presence of anterior Middle Cerebral artery in 136 out of 1420 specimens studied.

Walser 1942 reported the posterior temporal branch from Middle cerebral artery.

Vander and Adams 1953 found that the middle cerebral artery ended in small arterioles which has anastamosis's with posterior cerebral arteries.

Schdesigner 1953 described 4 to 5 descending branches of Middle Cerebral artery are in lateral angiogram, which were arranged in two rows, each connected by loops and lower to sylvian fissure was parallele to the superior insularsulcus presenting a triangular appearance called Sylvian triangle.

Ferner and Kautzky 1959 found that entire arterial spread formed a fan of 270 degrees although with many radii whose length and strength varied considerably.

Vander Fecken 1959 found the orbito frontal and anterior temporal branches, the temporal polar branch arising near the anterior temporal artery.

Varder fecken 1959 found that the orbito frontal and anterior temporal branches has their origin from a common trunk, the temporal polar branch arising near the anterior temporal artery in 22 out of 40 cases.

West berg 1963 found the artery of Heubner as a single trunk in 32 of his 34 specimens. It was absent in one case which was associated with the absence of anterior cerebral truck and in another instance it was double. He also described that the medial lenticulo striate arteries seen in angiograms were usually branches of the artery of Heubner (107, 108).

Jain 1964 found out that the artery of Huebnur was the most constant of all the branches of the brain and was present bilaterally in all cases. 300 cases which he studied he found that Middle Cerebral artery has a course 5-30mm in sylvian fissure with the lumen having size of 6mm.

Jain 1964 found accessory middle cerebral artery in 9 out of 300 brains of which it was unilateral in 8 specimens and bilateral in one specimen. He also found that the origin was from the anterior middle cerebral artery in 8 cases from internal carotid artery in one case.

Barrett RE, Fraser RA, Stein BM. 1971 made a study of the fluorescence histochemical survey of monoaminergic innervation of cerebral blood vessels in primate and humans.

Fraser RA, Stein BM, Pool JL. 1971 studied Adrenergic blockade of hypocapnic cerebral arterial constriction.

Jeffrey L.Salver and Jose biller 1972 found the trifurcation of Middle cerebral artery.

Jeffrey and Josefiller 1972 reported a bifurcated Middle cerebral artery with the superior division giving rise to orbitofrontal, Prefrontal, Prerolandic and Rolandic branches. They have also reported a case of trifurcation of Middle cerebral artery.

Garrido E, Stein BM 1976 has given a case report on Middle cerebral artery embolectomy. Case report. Journal of Neurosurgery 1976; 44:517-521.

Stein BM, Wolpert SM 1980 studied Arteriovenous malformations of the brain I: Archives of Neurology 1980; 37: 1-5.

Gibet all 1987 has described four segments M_1, M_2, M_3, M_4 of the Middle cerebral artery. Bosousslavsky 1988 reported a total occlusion of middle cerebral artery.

Barr WB, Jaffe J, Wasserstein J, Michelson WJ, Stein BM. 1989 studied Regional distribution of cerebral arteriovenous malformations. Interactions with sex and handedness. Archives of Neurology 1989; 46:410-412.

Venkatasubramanian Prohoumja I Hurlet A Mohr JP Priondhi's 1994 studied the velocity changes in Middle cerebral artery during transfusion in sickle cell anaemia.

Daniel Islater, Jeffery S Johns has updated the Middle cerebral artery study upto 2003.

MATERIALS AND METHODS

MATERIALS AND METHODS

Specimens are collected from the post mortem bodies in the Department of Forensic Medicine, Madurai Medical College during the period of this study from October 2004 to September 2006.

The cadavers utilised for this study were unclaimed dead bodies received from the Government Rajaji hospital, Madurai. The cadavers were kept in the mortuary cooler for 10days. After fulfillment of the routine administrative formalities, they were received by the Institute of Anatomy, Madurai Medical College, Madurai. The dead bodies were embalmed with the following preservative fluids.

Formalin (37-40%)	– 500ml
Glycerin	- 2 litre
Common salt	- 1 kgm
Thymol	- Few crystals
Water	- q.s. 6 lts.

The embalmed cadavers were stored in tanks filled with dilute (10%) formalin.

Instruments:

1. Stainless steel student's
2. Stainless steel scissors
3. Stainless steel forceps long and toothed.
4. Stainless steel forceps long and non-toothed.
5. Stainless steel forceps short, non-toothed.

A skin incision was made along coronal plane connecting the tip of the two auricle. A sagital incision connecting the external occipital protruberance was made. The four flaps were dissected to the sides. The vault of the skull was sawed with Axablade through the above landmarks. The vault was removed as single piece.

The cranial nerves attachments were cut on both sides and a deep cut on tentorium cereblli over the petrous part of temporal bone was made on either side and a transverse cut as low down as possible over the medulla oblongata was made. The brain was removed from cranial cavity and

preserved in 5% formalin solution and numbered serially from 1-50 for study. In the duramater on either side of the superior sagital sinus a sagital incision was made from the External Occipital protruberance upto the crista galli. Then the anterior end of the falx cerebri was divided from the cristagalli and the falx cerebri was pulled towards its posterior attachment.

The tentorium cerebelli was divided along with attached borders to the posterior clinoid process and the superior border of the petrus temporal.

The nerves emerging from the base of the brain were divided, the arteries of the base divided and the brain removed en mass from the cavity.

The internal carotid was identified when it is ventral to the anterior perforated substance. Now the middle cerebral artery was traced from the internal carotid. The middle cerebral artery was followed in the stem of the lateral sulcus.

ANATOMY OF MIDDLE CEREBRAL ARTERY:

Middle cerebral artery is the largest of the terminal branches of the internal carolid artery. It lies cistern of the stem of Lateral sulcus (sylvian fissure) accompanied by superficial middle cerebral vein in the inferior surface of cerebrum. Then it comes to the lateral end of stem of lateral sulcus and it divides into a superior and an inferior division which come to lie in the posterior ramus of the lateral sulcus in the superolateral surface of the cerebrum.

M_1 SEGMENT:

The proximal middle cerebral artery (M_1 segment) give rise to penetrating branches (termed lenticulo striate arteries) that supplies the putamen outer globus pallidum, posterior limb of the internal capsule above the plane of upper border of globus pallidus, the adjacent corona radiata, and the body upper and lateral head of caudate nucleus in the sylvian fissure. The middle cerebral artery in most patients divides into superior and inferior divisions. (M_2 branch). Branches of the inferior division supply the inferior parietal and temporal cortex and those from the superior division supply the inferior

parietal and temporal cortex. There is considerable variability in the parietal lobe supply between the two divisions which about two third of individuals having an inferior division that supplies region above the angular gyrus.

It gives rise to the cortical branches from superior and inferior divisions, Branch and distribution areas:

M_2 SEGMENT:

Superior Division:

It gives rise to lateral orbito frontal which supplies the pars orbitalis and the pre frontal cortex; a pre Rolandic branch which supplies the middle and posterior parts of the Superior Middle and inferior frontal gyri. Frontal eye field area and Broca's area. A Rolandic branch which supplies pre central and post central gyrus except the leg area and Broca's area. An anterior parietal which distributes to the parietal association cortex and also to supramarginal gyrus.

Interior division:

It gives rise to Tempropolar branch supplying the temporal pole an anterior temporal branch, which supplies the superior temporal gyrus the auditary receptive cortex.

A posterior temporal which supplies the auditary receptive cortex and also the angular gyrus (Wernick's area).

Posterior parietal which distributes to the supra marginal and angular gyrus that is, Wernick's area which are the auditary visual association cortex.

EFFECT OF LESION IN SUPERIOR DIVISION:

1) Motor aphasia due to lesion in Brocas area.
2) Loss of conjugate movement of eyeball due to lesion in frontal eye field.
3) Contra lateral hemiplegia due to lesion in motor area.
4) Except the leg area in sensory cortex.
5) Asterognesis due to Lesion in sensory association cortex.

EFFECT OF LESION IN INFERIOR DIVISION:

1) Auditary loss (partial) and auditary receptive and associative cortex due to lesion of anterior temporal and posterior temporal branch.
2) Wernick's aphasia (auditary and visual aphasia is due to lesion of posterior parietal branch.

Cortical supply of middle cerebral artery is in the major part of Supero Lateral surface except a finger breath area along the superior border extending from frontal pole to the sulcus parieto occipitals., except an area on the occipital lobe behind parieto occipital sulcus. Inferior temporal gyrus inferior surface lateral half of the orbital part is supplied by middle cerebral artery. In Medial surface supplies only the uncus.

Two approaches are used to describe middle cerebral artery anatomy. The functional branching approach follows the Middle Cerebral Artery trunk from the source to the end branches.

The other approach known as segmental approach, analyses branches of the middle cerebral artery in relationship to brain landmark dividing the artery into 4 main segments. In the segmental approach, M_1 is the portion most proximal to the origin of the vessel and M_4 includes the terminal Middle Cerebral Artery branches at the brain surface.

The segmental approach is most often for angiographic purposes and relates segments of middle cerebral artery to specific cerebral landmarks. The first of 4 segments M_1 describes the artery from its origin to the Limen insulae. Most of which is the portion from which the lenticulostriate arteries arises.

The second portion of M_1 describes the 3 branches that result from the bifurcation of middle cerebral artery and enter the sylvian sulcus M_2 is the segment that runs along the Insula. M_3 follows the operculum superior to the Insula.

Finally M_4 describes the branches of the middle cerebral artery that passes nearly all the convex surface of the cerebral

hemisphere aside from the frontal pole and posterior rim. Using the functional branching approach to Anatomy, the middle cerebral artery generally arises as a single trunk of 14-16mm length and a diameter of approximately 3mm-6mm.

First branch consists of 5-7 small lenticulo striate arteries that supply the putamen, pallidum, lentiform nucleus, Internal capsule and caudate nucleus of basal ganglia.

Occasionally a few of the smaller lenticulostriate arteries arise from the internal carotid arteries. After giving lenticulostriate branch middle cerebral artery bifurcates into superior and inferior divisions. The superior branch supplies the prefrontal and orbitofrontal cortex inferior branch supplies the anterior middle and polar temporal regions.

METHOD OF STUDY

The branching pattern of middle cerebral artery was studied in 50 brains as follows.

M_1 SEGMENT:

1) Length of M1 segment
2) Size of M1 segment
3) Branches, number Gyrus supplied by it, any other artery to the same gyrus. If so size of lumen of both.
4) Angle of origin.
5) Termination of M_1 segment.
6) Lumen size comparison between origin and termination of M1 segment.
    a) Artery supply to the Broca's area.
    b) Artery supply to the frontal eye field.
    c) Artery to motor and sensory area.
    d) Artery supply to the sensory cortex, Wernick's area and auditary cortex.
    e) Central branches or the lenticulo striate branches.

1. SOURCE OF ORIGIN

Source of origin of Middle cerebral artery is noted source of other arteries if any is noted.

2. SITE AND LEVEL OF ORIGIN

Site and level of origin of middle cerebral artery is noted.

3. OTHER TERMINAL BRANCHES OF INTERNAL CAROTID ARTERY

Internal carotid artery's other terminal branches are noted.

4. SIZE OF LUMEN AND ITS COMPARISON WITH OTHER TERMINAL BRANCHES FOR ALL FUNCTIONAL AREAS

Size of Lumen of middle cerebral artery is noted and its lumen is compared with other terminal branches for all the functional areas.

M_1 SEGMENT:

1. LENGTH OF M_1 SEGMENT

From the origin of the middle cerebral artery from the internal carotid artery the length of M_1 was measured. Variation in the mode of course and termination of M_1 were also looked.

2. SIZE OF LUMEN OF M_1:

Size of lumen of M_1 was also measured.

3. BRANCHES, NUMBER, GYRUS TO WHICH ENTER ANY OTHER ARTERY TO THE SAME GYRUS IF SO SIZE OF LUMEN OF BOTH:

Branches from the M_1 segment number of branches, any other artery to the gyrus are noted and the size of lumen of both are noted.

4. ANGLE OF ORIGIN

Angle of origin of each division are noted.

5. TERMINATION OF M1 SEGMENT AND NUMBER OF DIVISION:

Termination of M1 segment and number of division are noted.

6. LUMEN SIZE AND COMPARISON BETWEEN ORIGIN AND TERMINATION OF M_1 SEGMENT:

Lumen size and the origin and termination of M1 segment are noted as

1. Artery to the Brocas area
2. Supply to the frontal eyefield
3. Rolandic branch to motor sensory area
4. Parietal supply to association cortex.
5. Supply to the auditary receptive cortex.
6. To the Wernick's area.

OBSERVATION

OBSERVATION

The study of the branching pattern of middle cerebral artery in 50 brains revealed the following features.

1. SOURCE OF ORIGIN:

Middle cerebral artery arises as one of the terminal branch of internal carotid artery in 50 brains. (100%) 50 brains are noted. No abnormal source of origin.

Source of origin middle cerebral artery	Normal	Variation
	Internal carotid artery	From other arteries
Number of specimens	50	Nil
Percentage	100%	Nil

1) Crampton (1962) described accessory middle cerebral artery incidence of 3%
2) Jain (1964) reported an accessory middle cerebral artery. But no such accessory middle cerebral artery has been reported.

2. SITE OF LEVEL OF ORIGIN:

Arises lateral to the anterior perforated substance in 50 brains. No other abnormal level of origin has been noted in the present study.

Source of origin middle cerebral artery	Normal	Variation
	Lateral to the anterior perforated substance	Nil
Number of specimens	50	Nil
Percentage	100%	Nil

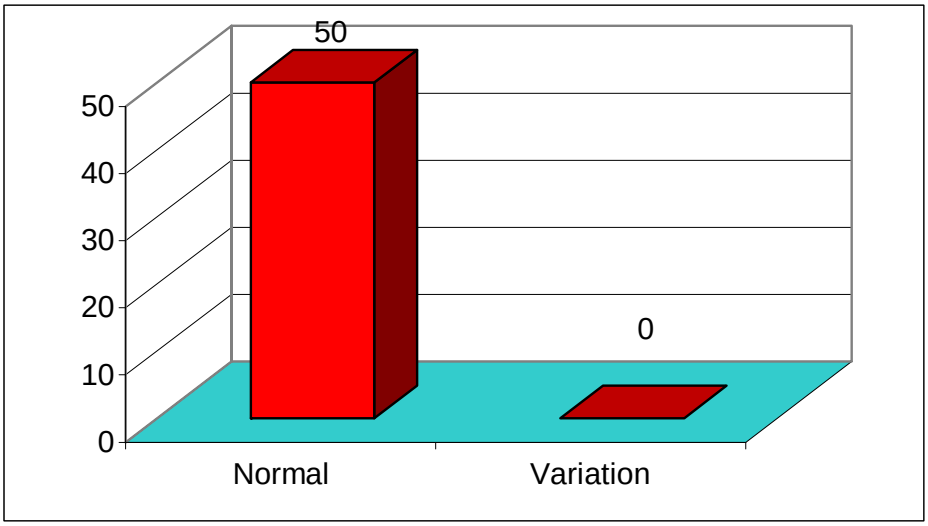

3. OTHER TERMINAL BRANCHES OF INTERNAL CAROTID ARTERY:

In addition to the middle cerebral artery, the anterior cerebral artery is one of the terminal branch is noted in 50 brains. No other abnormal terminal branches are noted in the present work.

Other terminal branches of internal carotid artery	Normal	Variation
	Anterior cerebral artery	Nil
Number of specimens	50	Nil
Percentage	100%	Nil

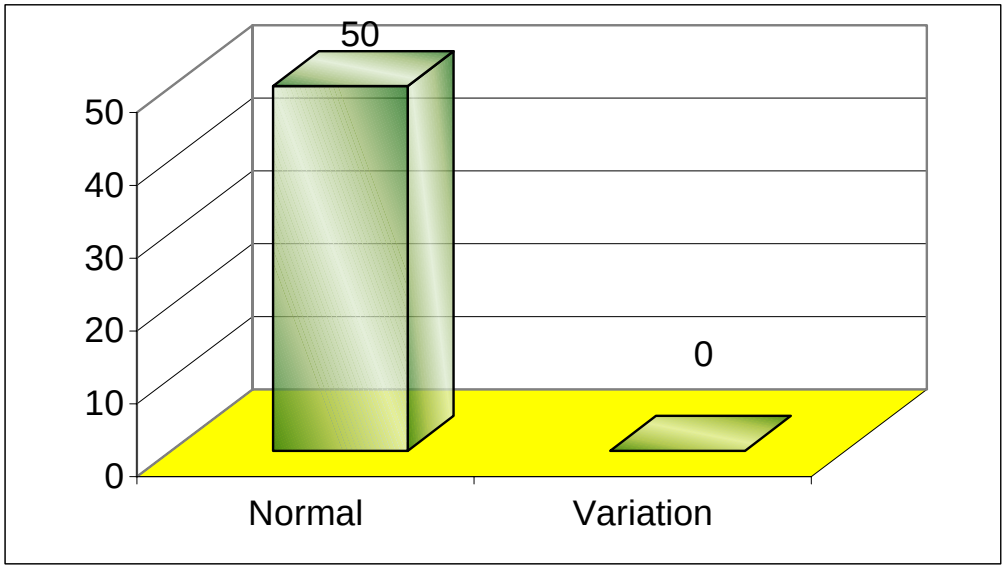

4. SIZE OF LUMEN:

Size of lumen of middle cerebral artery at its origin was between 3mm to 6mm with the standard size of the lumen reported by Jain (1964).

In the present study the Size of lumen of middle cerebral artery was 3mm in 46 specimens. 6mm in 4 specimens on both sides. In the 46 specimens where the size was 3mm, the size of the lumen of the Anterior cerebral artery was 3mm.

In the four specimens middle cerebral artery lumen is 6mm. Anterior cerebral artery lumen was 2mm in size.

Size of Middle cerebral artery	Normal	Variation
Number of specimens	46	4
Percentage	92%	8%

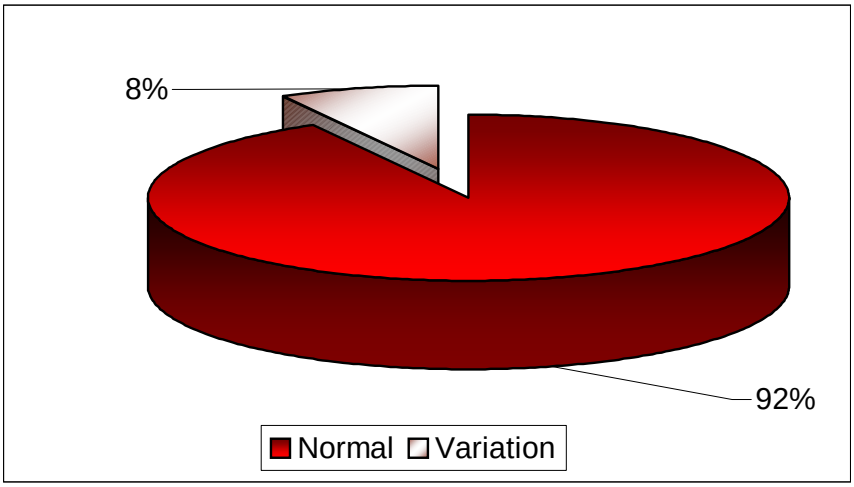

M1 segment is the distance between the origin of middle cerebral artery lateral to anterior perforated substance before its divisions.

Normal length of M_1 was 14-16m in 46 specimens

Length of M_1 segment was 10mm → in specimen 2(left), 3(left) two specimens.

It was 21m.m. → in specimen Number 5(left)

30m.m in 7 Left 7 right

Length of M_1 segment	Normal	Variation		
	14-16mm	10mm	21mm	30mm
Number of specimens	46	2	1	1
Percentage	92%	4%	2%	2%

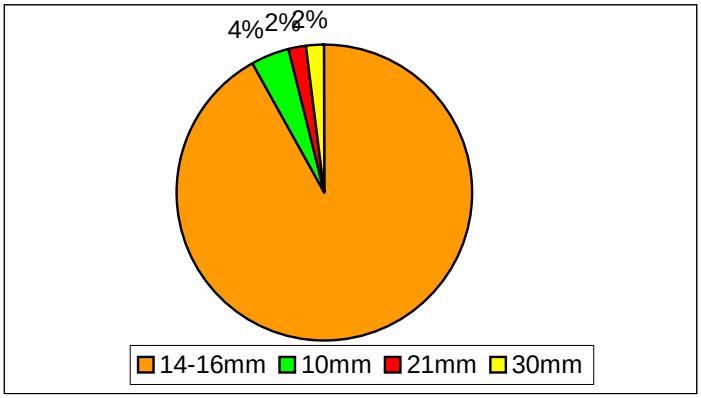

2. SIZE OF LUMEN OF M_1 SEGMENT AT ITS TERMINATION:

Size of lumen of its termination was M1 segment is 3mm in 40 specimens and 4mm in 1 specimen, 5mm specimen in one specimen (No.8) and 6mm in 8 specimens.

Size of M_1 segment	Normal	Variation		
	3mm	4mm	5mm	6mm
Number of specimens	40	1	1	8
Percentage	80%	2%	2%	16%

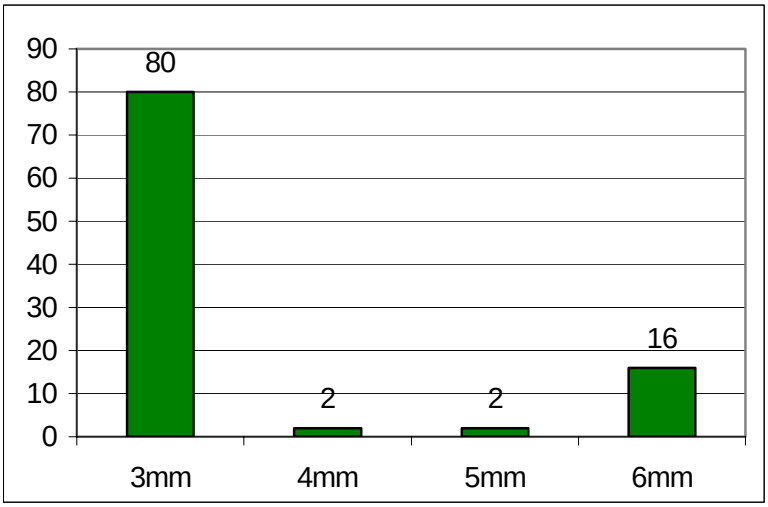

3. BRANCHES, NUMBER, GYRUS TO WHICH SUPPLY BY OTHER ARTERY TO THE SAME GYRUS IF SO SIZE OF LUMEN OF BOTH:

In the specimen No.1 on the left side orbito frontal takes origin from the M_1 segment and connected with Fronto polar which comes superior division and supply Broca's area.

1) In the present study, the pars traingularis is supplied by the M_1 segment and also by its superior division.

a) Eye field area is supplied by prerolandic branch, Motor area is supplied by rolandic branch and Sensory area is supplied by anterior parietal branch. In this the length of M1 segment is 10mm. Angular artery supplies angular gyrus. Anterior and posterior temporal supplies auditary receptive and auditary associative cortex.

b) In the picture orbitofrontal arises from the stem of the branch lumen is 3m.m. Middle cerebral artery lumen is 6m.m

3) In the picture 7. Motor speech area is supplied by 3 branches. Orbito frontal, Fronto polar and pre Roladic arises from stem before the division of middle cerebral artery.

4) a) In the picture 8 prorolandic and rolandic branches are interconnected. Prerolandic supplies premotor. Rolandic supplies motor area by interconnections these area has more blood supplies. Lumen for these middle cerebral artery is 6mm.

b) In the picture 8 Angular artery is connected with posterior temporal artery. So sensory area wernicks area is connected with auditary association area. In this specimen the M1 segment is 25m.m and middle cerebral artery has 3 divisions with lumen of 6m.m. Angular and posterior temporal artery lumens are of 6m.m.

In the specimen 2 left where the middle cerebral artery divides in to three divisions, the superior division gives rise to pre Rolandic, Rolandic and Anterior parietal branches the inferior division giving rise to anterior and posterior temporal arteries. The middle division giving rise to angular and supramarginal branches.

5. In this picture 53, orbito frontal arises from the stem and divides into two branches. Each of these two branches again divides into two branches. In this specimen M_1 diameter is 30mm and has 3 divisions of middle cerebral

artery. Lumen is 3mm and middle cerebral artery is 6mm.

6. In the picture 10, orbito frontal is connected with prerolandic branch. In this specimen the central branches are two in number. M_1 Segment of the middle cerebral artery lumen is 6mm.

7. In this picture 66 M_1 segment was 10mm. Prerolandic branch supplies the motor speech area and also frontal eye field area. Prerolandic, Rolandic and Anterior parietal branches are interconnected.

8. In this picture 56, the Fronto polar artery is connected with orbitofrontal, prerolandic and Rolandic branches are interconnected. In this specimen the lumen of the Rolandic and prerolandic branches were 3mm.

9. In the picture 51, M_1 segment is 21cms. The size of the lumen is Orbitofrontal and frontopolar diameter are

3mm. In addition to its supply to orbital gyrus also supplies motor speech area.

10. In the picture 5 there is more communications between the pre Rolandic, Rolandic and Anterior parietal branches. In this M_1 segment 21mm. More than normal. Lumen for middle cerebral artery is 6mm and the lumen of the pre rolandic, rolandic and anterior parietal were also 6mm in diameter.

11. In this picture 52 again there is more communication pre rolandic, rolandic and anterior parietal branches. In the same specimen angular artery is connected with posterior temporal artery.

12. In this specimen 6 right, length of M_1 is 30mm. There is no communication between the branches.

13. In the picture 57 where length of middle cerebral artery is 10mm. Angular artery is connected with prerolandic artery.

14. In the picture 68 prerolandic prefrontal artery supplies orbital part of Inferior surface and communicated with orbito frontal branch.

15. In the picture 52 inferior division gives rise to three branches at varying angle diameter is 6mm. Each having diameter of 6mm.

16. In the picture 54 Inferior division gives 6 branches rise to six branches that ramify in the temporal lobe and then continues as angular artery.

In specimen, #2, M_1 segment terminates by dividing into superior, middle and inferior divisions. In other specimens M_1 segment divides only into with superior and inferior divisions.

Termination of M_1 Segment	Normal	Variation
	2 Divisions	3 Divisions
Number of specimens	49	Specimen #2
Percentage	98%	2%

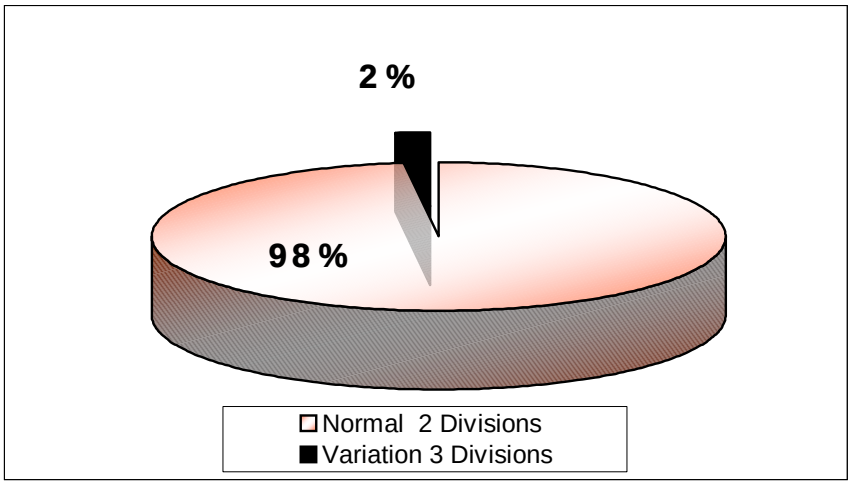

6. LUMEN SIZE OF M_1 BETWEEN ORIGIN AND TERMINATION:

In 50 specimens the lumen size of M_1 between origin and termination are noted. In the specimen #2, 5,6,8 on both sides was 6mm. Lumen size was same at origin and termination. In other specimens the lumen sizes were 3mm at origin and termination.

Lumen size of M_1 between origin and termination	Normal	Variation
	3mm	6mm
Number of specimens	46	#2, 5, 6, 8 (Left) #R2, R5, R6, R8
Percentage	92	8%

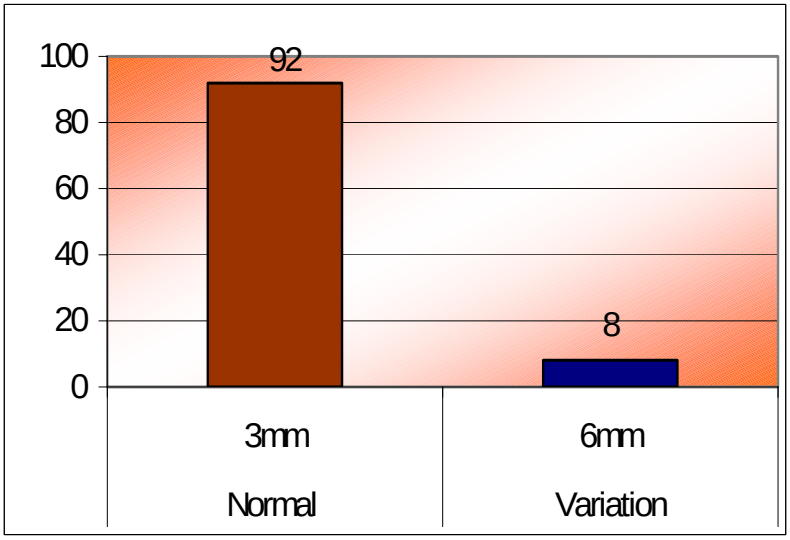

LENTICULO STRIATE BRANCH:

Lenticulo striate branch appears from the M_1 segment. Usually 4 to 6 in number.

In 43 (specimen) 4 branches are seen. In 4 specimens 6 branches #2L, #3L, #5L, #6L, 3 (specimens) #1L, #4L, #9L and in one specimens there were two branches.

In picture 61- Lenticulo striate branches are six in number.

Lenticulo striate branches	Lenticulo striate Branches	
	Four	Six
Number of specimens	4	46
Percentage	8%	92%

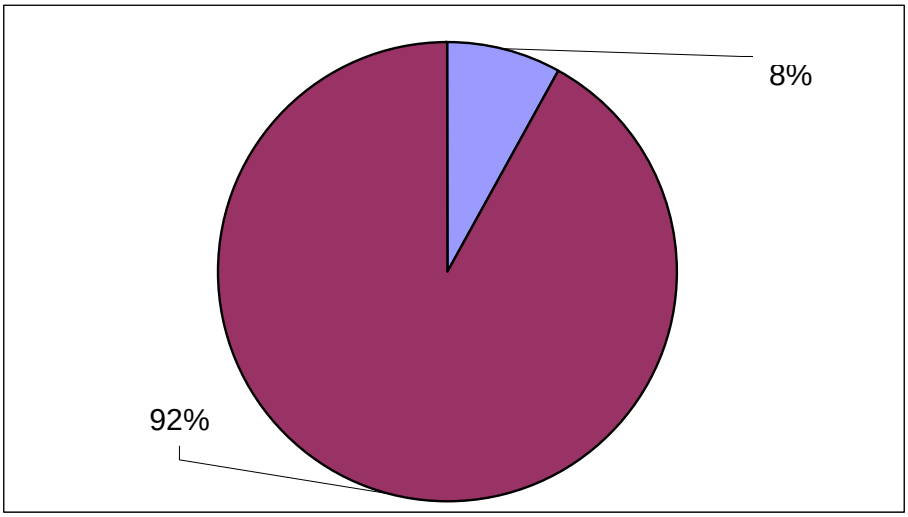

4. ANGLE OF ORIGIN:

Angle of origin in the orbito frontal is 110°.

Fronto polar –120°

Pre frontal -130°

Each branch varies 10° in difference.

Middle cerebral artery length is 15mm.

Lumen is 6mm.

This is same in 47 specimen.

In specimen #L6, R6 angle of variation is 20° is that

frontopolar-110°,

Prefrontal 130°,

Orbito Frontal –150°.

It has M_1-30mm, diameter 6mm, L#3, #R3 specimen L1

& 1R, Angle of origin,

Fronto polar-110°,

Prefrontal –130°,

Orbito frontal-150°,

M_1 segment length-30mm,

Lumen size 6mm

In specimen L#2, & R2, the same angle of origin. M_1 segment is 30mm. Lumen size 6mm.

Angle of origin	Normal				
	Fronto polar	prefrontal	Orbito	Frontal	Percentage
Number of specimens (47)	110°	120°	130°		94%
Variation (3)	110°	130°	150°		6%

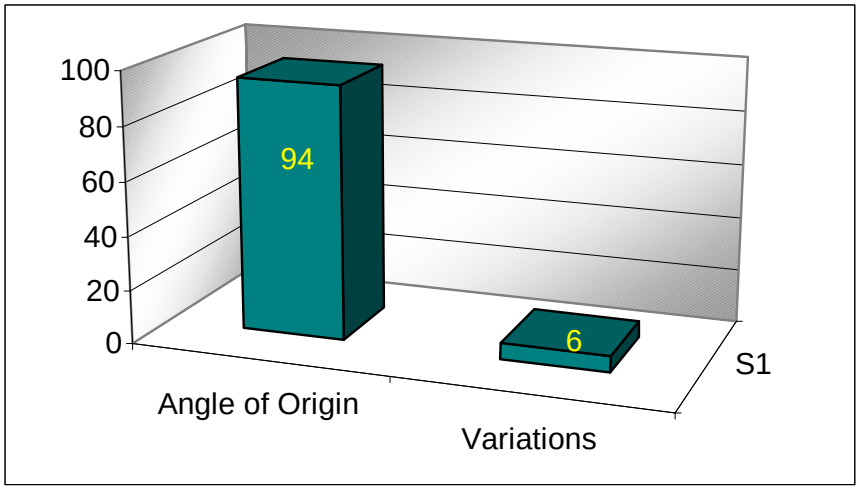

Angle of origin of post Rolandic, rolandic and prerolandic artery angle of origin is noted. Angle of origin of post rolandic is 110°. Rolandic 120, Anterior parietals 130° connections are more is the diameter 10mm in specimen and 20mm in specimen. Normal diameter is 14-16mm

Percentage	Connections		Branch	Angle of origin
90%	More than 2	45	Pre rolandic	110°
10%	More than 4	5	Rolandic	120°
			Anterior parietal	130°

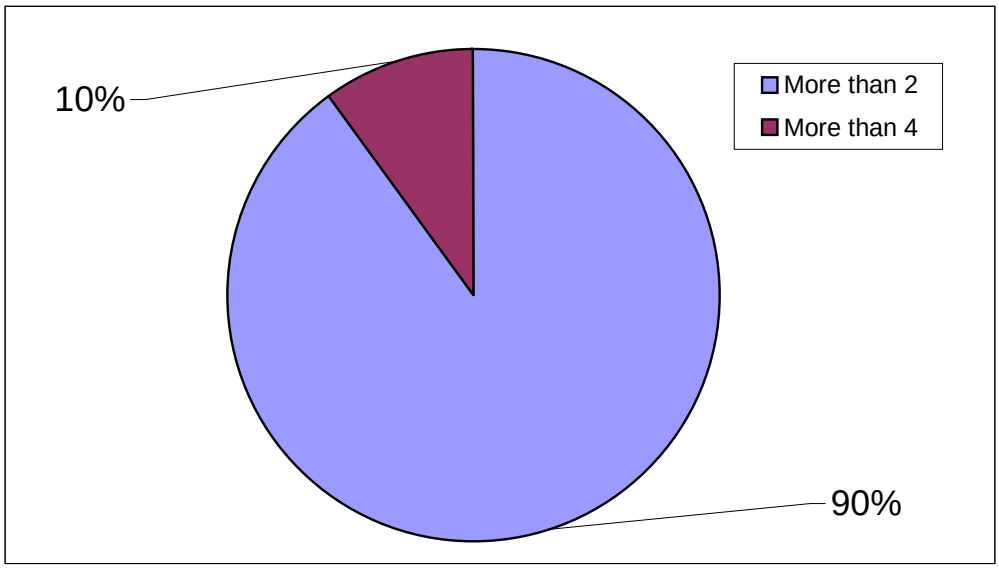

ANGLE OF ORIGIN

Angular artery	120°
Anterior temporal	130°
Posterior temporal artery	140°

It is 10° variation in it is 120° 140° 160° more than 20o variation in 10 specimens. It has M_1 segment is more than 25mm and also has three divisions.

Branch	Angle of origin	Variations
Angular artery	120° 130° 140°	120° 140° 160°
Specimens	45	5
Percentage	90%	10%

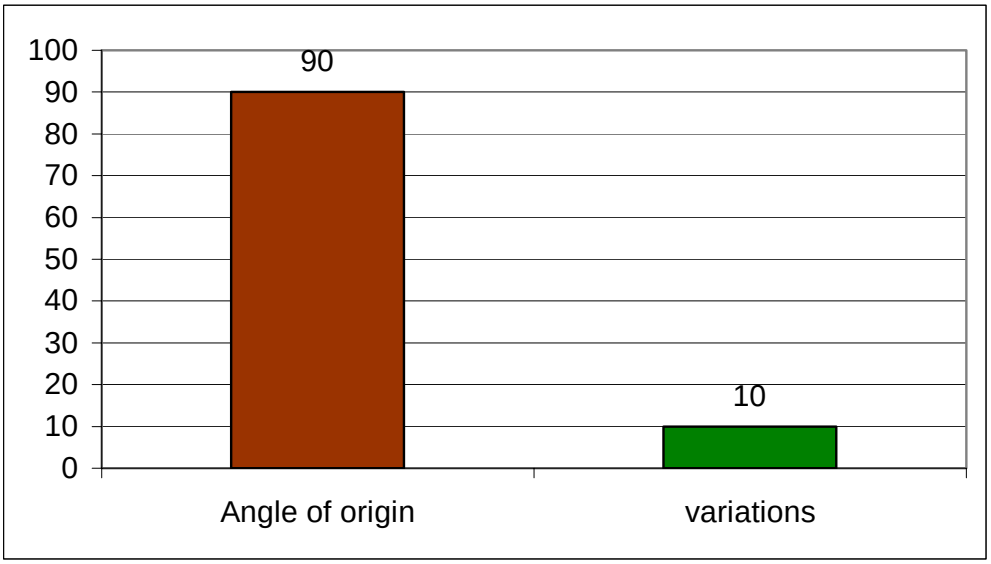

More 20% in the specimen of having 3 divisions and M_1 length is 30mm. Specimens are $^L2$, $^R2$, $^L3$, $^R3$, $^L4$, $^R4$, $^L5$, $^R5$, $^L6$, $^R6$.

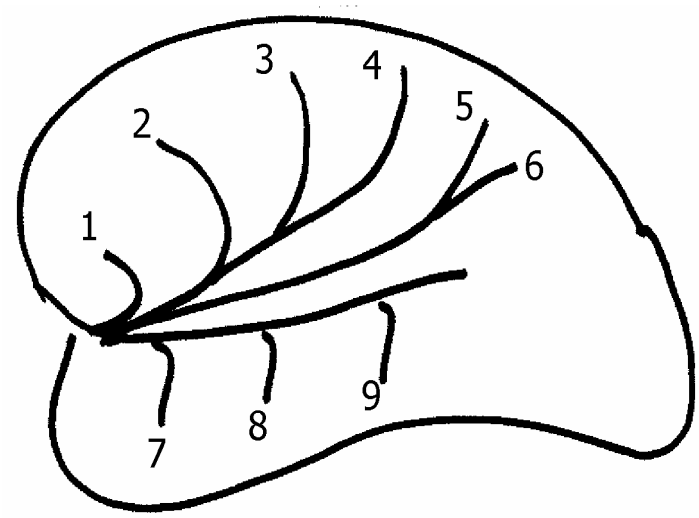

1 – FRONT POLAR

2 – PRE ROLANDIC

3 – ROLANDIC

4 – ANTERIOR PARIETAL

5 – POSTERIOR PARIETAL

6 – ANGULAR

7 – TEMPOROPOLAR

8 – ANTERIOR TEMPORAL ARTERY

9 – POSTERIOR TEMPORAL

THREE DIVISIONS OF MIDDLE CEREBRAL ARTERY

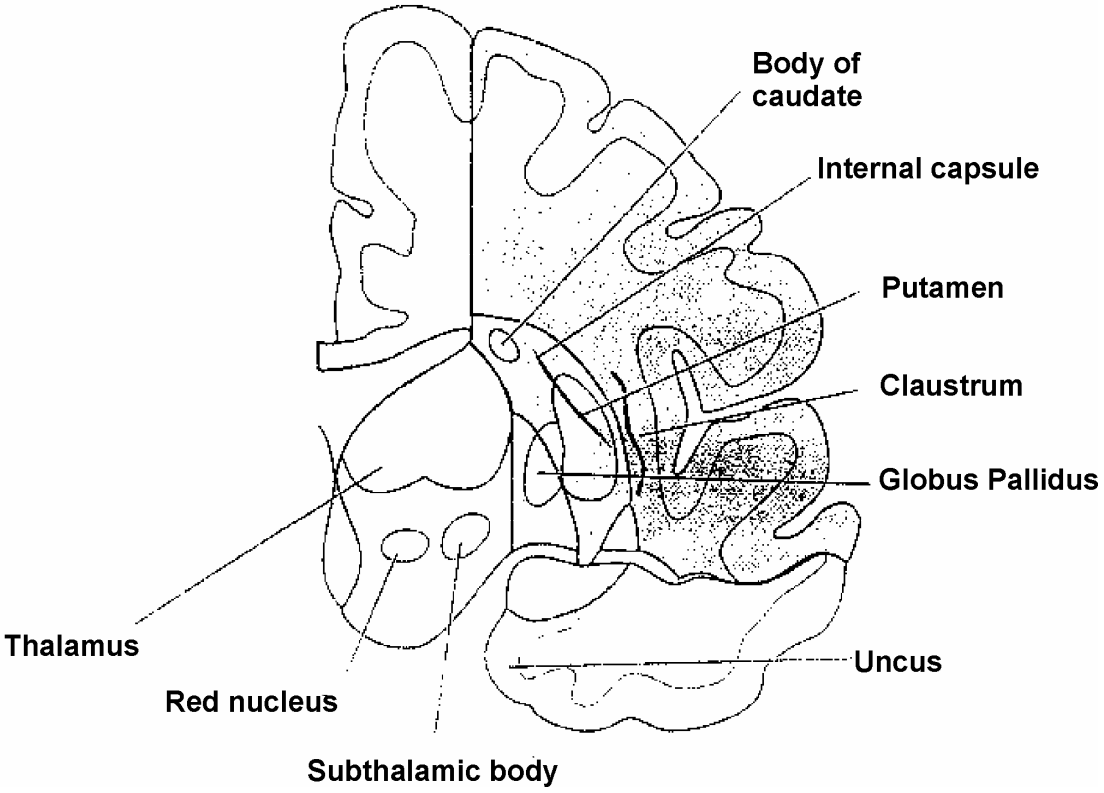
Body of
caudate
Internal capsule
Putamen
Claustrum
Globus Pallidus
Thalamus
Uncus
Red nucleus
Subthalamic body

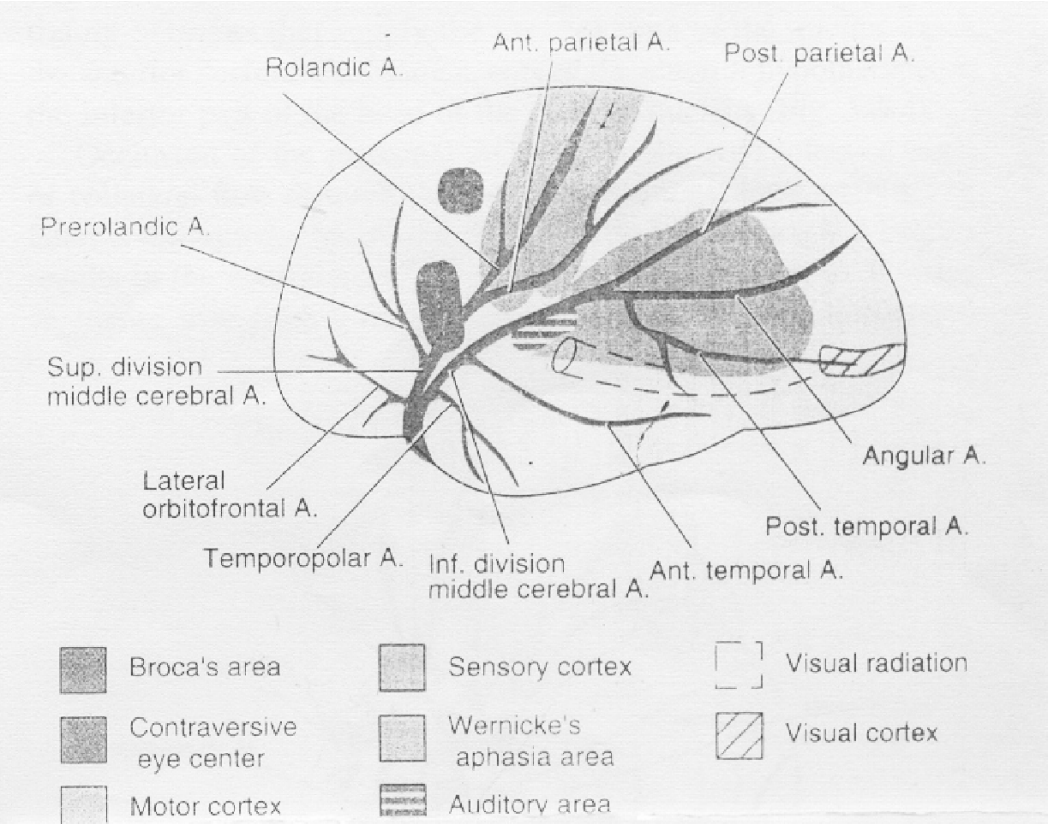
Ant. parietal A.
Post. parietal A.
Rolandic A.
Prerolandic A.
Sup. division
middle cerebral A.
Angular A.
Lateral
orbitofrontal A.
Post. temporal A.
Temporopolar A.
Inf. division
middle cerebral A.
Ant. temporal A.
Broca's area
Sensory cortex
Visual radiation
Contraversive
eye center
Wernicke's
aphasia area
Visual cortex
Motor cortex
Auditory area

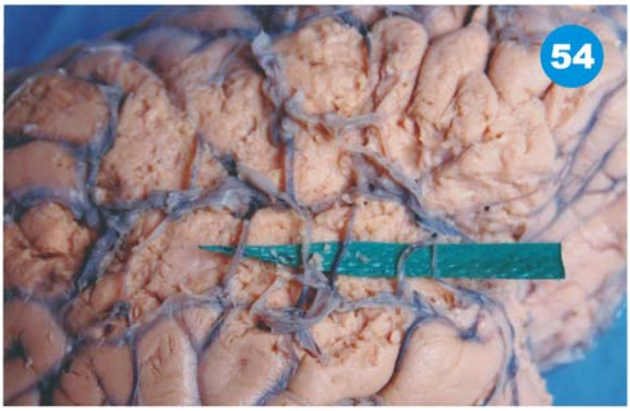

Angular Artery has six branches

Angular Artery to prerolandic region

Orbitofrontal connected with prefrontal
Two branches to metathalamus

Orbitofrontal gives prefrontal and
then supplies Broca's area.

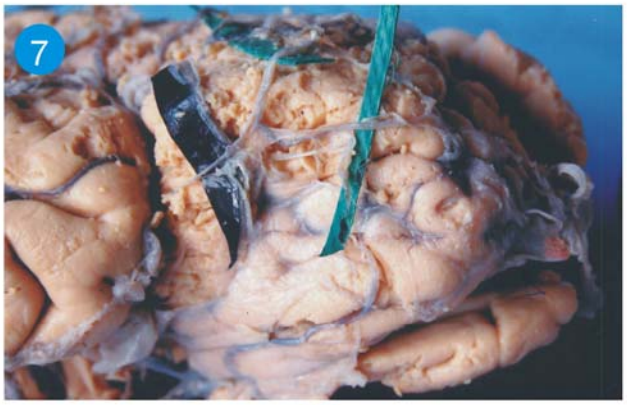

Orbitofrontal connected with prefrontal branch

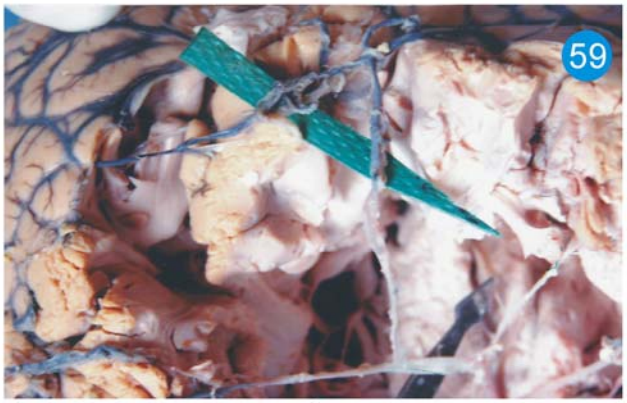

Orbitofrontal gives prefrontal and supplies Broca's area

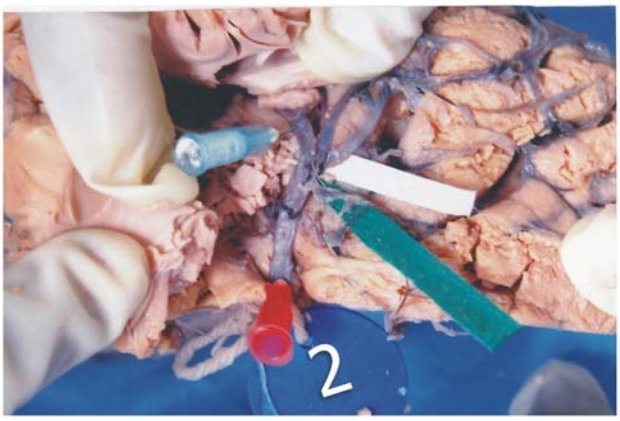

Middle cerebral artery has 3 divisions

Orbitofrontal arises from stem and connected with frontopolar

Orbitofrontal gives prefrontal a
supplies Broca's area

Frontopolar connected
with orbitofrontal

Prerolandic and Rolandic branches are interconnected.

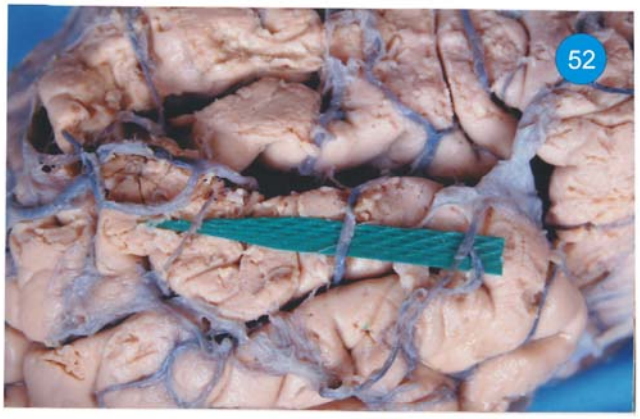

Inferior Division gives three branches at varying angulations to superio temporal gyrus. Angular artery is connected with posterior temporal arte

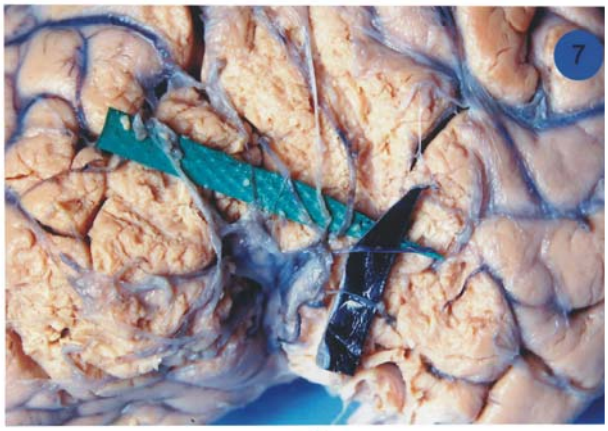

Motor switch area is supplied by Orbitofrontal, Frontopolar and Prerolandic branches

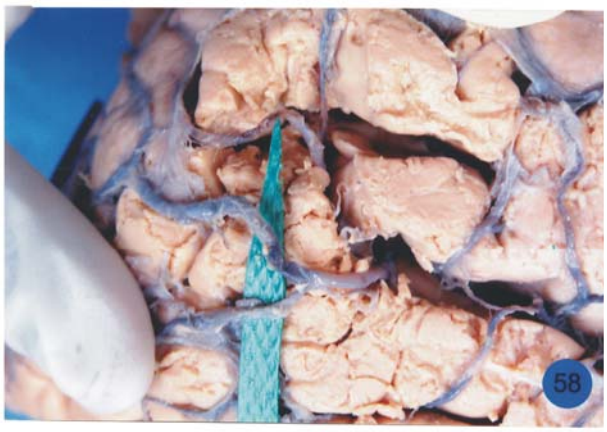

Angular artery and posterior parietal supplying auditary and visual association cortex

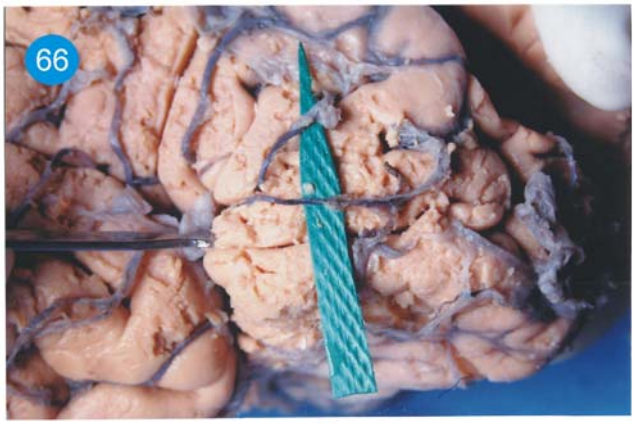

Prerolandic supplies motor speech area and also frontal eye field are

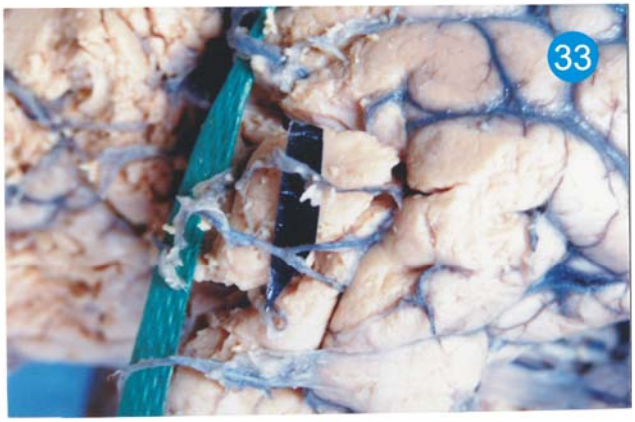

Branches from angular artery to temporal gyrus.

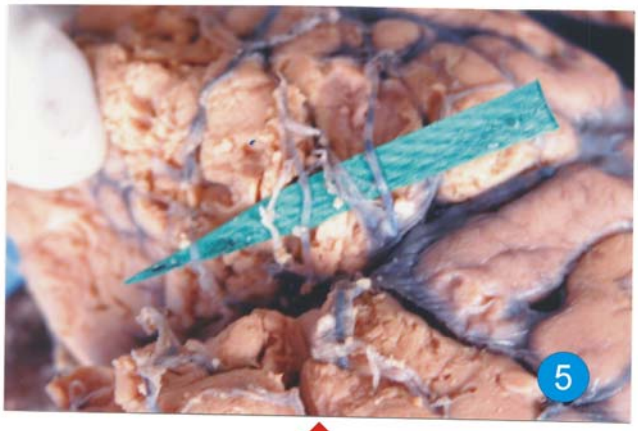

Interconnections are more in Prerolandic, Rolandic and anterior parietal branches

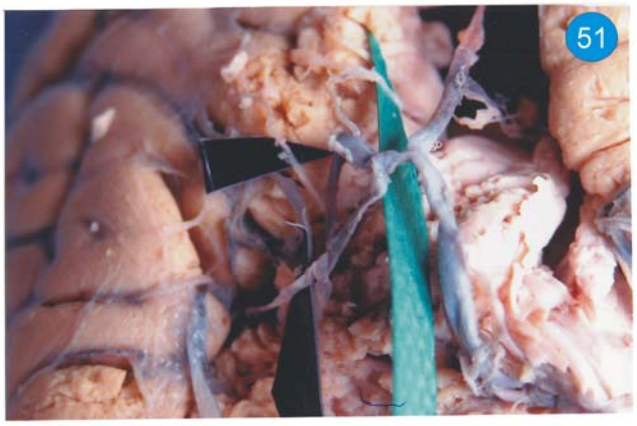

Frontopolar in addition to supply to orbital gyrus and also supplies motor speech area

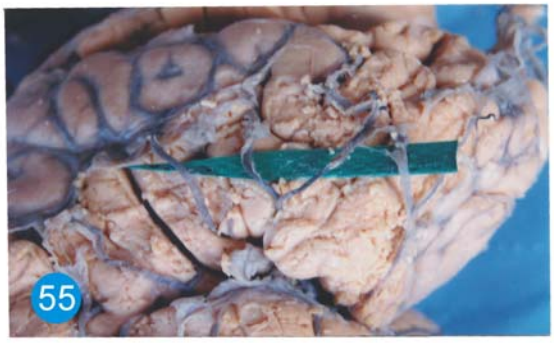

Interconnections between the arteries supplying various gyrus.

Orbitofrontal arises from the sten
and divides into two branches

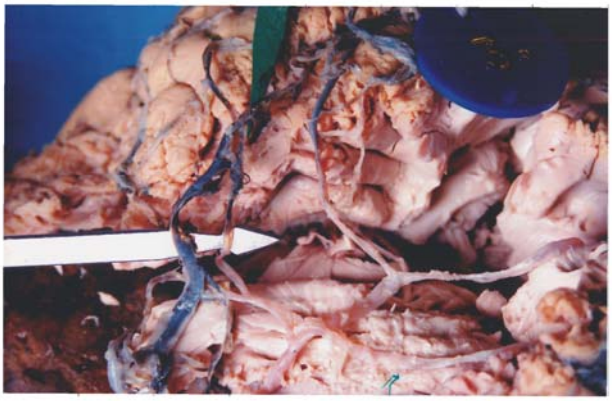

M1 Segment length is 30mm.

DISCUSSION

DISCUSSION

ORIGIN OF MIDDLE CEREBRAL ARTERY:

As per the description in the standard textbooks Gray and kasper the middle cerebral artery is the largest of the terminal branches of the internal carotid artery. In the present study in all the specimens the origin was also from the internal carotid artery it was the largest terminal branches.

Jain (1964) Reported an accessory middle cerebral artery in addition to the usual middle cerebral artery. In the present work no such accessory middle cerebral artery has been noted.

The size of lumen of middle cerebral artery was from 3mm to 6mm. It has been observed that in the four specimens where the size of the lumen was 6mm in middle cerebral artery, the size of the lumen of the Anterior cerebral artery was only 2mm.

THE MIDDLE CEREBRAL ARTERY I SEGMENT:

COURSE:

As per standard description it lies in the cistern of the stem of the lateral sulcus accompanied by the superficial middle cerebral vein in the sylvian fissure. In the present study all the middle cerebral artery have the same course as per the standard description.

LENGTH:

It was noted that the length was 14 to 16mm, which coincides with the standard length reported by Jain (1964) found that the middle cerebral artery causes in sylvian fissure and internal luman with an average length of 16mm. He studied in 300 brains and found the artery of Huebnur was the most constant of all the branches of the brain and was present bilaterally in all cases.

In the present study the length was 10mm in two specimens, 21mm in one specimen, 30mm in one specimen.

BRANCHING:

The size of lumens at the termination of the M_1 segment was noted to be 6mm in 40 specimen, 4mm in one, 5mm in one, 6mm in eight specimens. It is noted that the size of the human deviates from its origin to its termination as division.

In the present study the number Lenteculo striate branches were six branches in 28 specimens and 4 in 22 specimen. As per shellshear J.L. (1920) there was 6 to 7 lenteculostriate branch.

Lenticulostriate Branches	**Six branches**	**Four branches**
Arises from stem of middle cerebral artery	28	22
Percentage	56%	44%

In one specimen No.2 comes to the superolateral surface to supply the inferior frontal gyrus.

In specimen No.2 (left) side it gives rise to two branches, which enters the Broca's area.

DIVISIONS OF M_1:

As per standard description the Rolandic branch supplies both motor and sensory areas. But in the present study it has been noted that the anterior parietal supplies the sensory cortex and the Rolandic branch supplying only motor cortex.

Usually there are two divisions of superior and inferior. In the present study the middle cerebral artery divides into three division in one specimen 2. percentage of middle cerebral artery is 2%

In picture 7 motor speech area is supplied by three branches. Orbitofrontal, Fronto polar and pre Rolandic and it is observed that there is a liberal supply to motor speech area.

M_1 Segment	2 Divisions	**3 Divisions**
Specimens	49	1
Percentage	98%	2%

SUPERIOR DIVISION:

COURSE:

It is observed that prerolandic and Rolandic branches are inter connected and so it is observed through the anastamosis there is a liberal supply to motor and sensory cortex.

It is observed that in picture 8 the angular artery which supplies the visual association cortex is connected with posterior temporal branch and so it is noted that the visual part of the Wernick's area receives more blood supply.

In picture 53 (left) of the division of the orbito frontal shows a dichotomous pattern which has not been observed in any specimen, and this division has not been reported previously.

In picture No.10 (left) there were only two central branches (Lenticulostriate branches) which has not been reported previously. Since there is a free communication between the branches of the superior division, it may be taken

that if there is a occlusion to one branch the collateral may take over the area and the risk of ischaemia may be reduced.

In picture No.56 (left) the lumen of the Rolandic and prerolandic which supply respectively the hypermotor and sensory cortex and the frontal eyefield is equal to that of the lumen of the parent trunk and there could be a liberal supply the above mentioned functional areas.

In 51, (left) the orbitofrontal supplies, in addition to its routine distribution, the motor speech area and so there is a more blood suplly to Broca's area from both orbitofrontal and frontopolar.

In picture 5 (left) there is a free communication the branches superior division angular artery which supplied visual association cortex connects with posterior parietal which supplies sensory association cortex.

In the picture 57, (left) Angular artery connected to Prerolandic artery.

In the picture 52, (left) gives rise to its branches at varying degrees which is a predisposing factor for hemorrhage and thrombus formation.

In the picture 54 (left) there are six branches to inferior division which ensures a liberal supply to be auditary receptive cortex.

Six Branches:

The size of the lumen of M_1 between the origin and its termination coincides with the previous reports by other authors.

The Lenticulostriate branches are usually four to six in number which arise with the report by the previous workers. In the present study it is observed that there is only two branches in one specimen.

ANGLE OF ORIGIN:

There is a wide variation in the angle of origin of the branches from the M1 segment and its divisions, which agree with the report by the previous workers.

CONCLUSION

CONCLUSION

It has been observed in all specimens the middle cerebral artery was the largest of the terminal branches of the internal carotid artery arising that lateral the anterior perforated substance.

An accessory middle cerebral artery has been reported by Jain 1964, such artery has not been found in the present study.

In the present study the size of the lumen of anterior cerebral artery is between 3 to 6mm. The largest diameter of 6mm has been observed in four specimens of which is two specimens the lumen of the Anterior cerebral artery was only 2mm. So it may be concluded that these two cases are more prone for anterior cerebral artery area ischaemia.

Length of the artery which is between 14 to 16mm in majority of the specimens agree with the previous works. In

this work, the length of Middle cerebral artery in two specimens were only 10mm. In these cases the force of flow will be more and so prone for damage to the tunics of the arteries. In one specimen it was 21mm and in another 30mm and so there is a possibility for sluggish flow which is a predisposing factor for the formation of thrombus.

It is observed that there is a uniform reduction in the caliber of the middle cerebral artery from origin to its termination. But in two specimens the lumen and the termination is same as in its origin, which ensues that there is liberal supply to the functional areas only in these two specimens which reduce the risk of cerebrovascular catastrophes.

It has been reported in the present study that the Rolandic branch supplies only motor cortex and anterior parietal supplying the sensory cortex in addition to its supply to the parietal association cortex. So It may be concluded that the occlusion of Rolandic giving rise to only motor loss and the

occlusion of anterior parietal branch giving rise to hemiparesis and astereognsis. This serves an example of varying clinical manifestation in occlusion of either the division of the branches of the division.

It has been observed that the motor speech area supplied by orbitofrontal branch from M_1 segment. Frontopolar and Prerolandic branches from superior division. So it may be concluded that this case if there is occlusion to M_1 Segments there is motor aphasia. But when the occlusion is in the superior division, this case may escape from Motor Aphasia, since there is a supplying from M_1. In the same if the occlusion is prerolandic which usually supplies motor speech area, again it escapes ischaemia.

There had been only two lenticulostriate branches and so the Basal Ganglia and the related structures may suffer from deficient blood supply. Since the lumen of Prerolandic and Rolandic branches are equal to the lumen of middle cerebral

artery there could be more blood supply to frontal eye field area and the motor and sensory cortex.

Since there is a free communication between the angular artery a branch of inferior division and anterior parietal branch, a branch of superior division which supplies the sensory association cortex, in occlusion of superior division astereognosis may not be present.

Since the inferior division gives rise to varying degrees of its branches, this variation may be a predisposing factor either for hemorrhage or thrombus formation.

It has been observed that there are six branches from inferior division to the auditary receptive cortex and so it one branch it blocked it may be compensated by the other branches.

In general it has been observed that there is a few difference with branching pattern of the middle cerebral artery

the pattern of one specimen does not correspond to pattern in the other brain.

There is a free communications between the branches of the division especially on the left side and the branches of the left side appear to be larger.

There is in general less branches and smaller branches on the right side without free communications.

On the right side it has been noted that the lenticulostriate branches were less.

BIBLIOGRAPHY

BIBLIOGRAPHY

Bogousslavsky 1988 found first infacts involve in middle cerebral artery. He found the complete involvement of middle cerebral artery,.

Cunha e Sa MJ, Stein BM, Solomon RA, McCormick PC. 1992 The treatment of associated intracranial aneurysms and arteriovenous malformations. Journal of Neurosurgery; 77:853-859.

DeMeritt JS, Pile-Spellman J, Mast H, Moohan N, Lu DC, Young WL, Hacein-Bey L, Mohr JP, Stein BM. 1995 Outcome analysis of preoperative embolization with N-butyl cyanoacrylate in the treatment of cerebral arteriovenous malformations. American Journal of Neuroradiology; in press.

Di Tullio M, Sacco RL, Gopal A, Mohr JP, Homma S. 1992 Patent foreman ovale as a risk factor for cryptogenic stroke (see comments). Annals of Internal Medicine; 117:461-465.

Di Tullio M, Sacco RL, Massaro A, Venkatasubramanian N, Sherman D, Hoffmann M, Mohr JP, Homma S. 1993 Transcranial Doppler with contrast injection for the detection of patent foramen ovale in stroke patients. International Journal of Cardiac Imaging; 9:1-5.

Di Tullio M, Sacco RL, Venkatasubramanian N, Sherman D, Mohr JP, Homma S. 1993 Comparison of diagnostic techniques for the detection of a patent foramen ovale in stroke patients. Stroke; 24:1020-1024.

Fleischer LH, Young WL, Pile-Spellman J, terpenning B, Kader A, Stein BM, Mohr JP. 1993 Relationship of transcranial Doppler flow velocities and arteriovenous malformation feeding artery pressures (see comments) Stroke; 24:1897-1902.

Fleischer LH, Young WL, Pile-Spellman J, terpenning B, Kader A, Stein BM, Mohr JP. 1993 Relationship of transcranial Doppler flow velocities and arteriovenous malformation feeding artery pressures (see comments). Stroke; 24:1897-1902.

Foulkes MA, Sacco, RL, Mohr JP, Hier DB, Price TR, Wolf PA. Parametric modeling stroke recurrence. Neuroepidemiology, 13:19-27.

Fraser RA, Stein BM, Barrett RE, Pool JL. 1970 Noradrenergic mediation of experimental cerebrovascular spasm. Transactions of the American Neurological association; 95:21-26.

Frix and levy, 1927, The studied of the clinical manifestation of clinico pathological study of superior and inferior middle cerebral artery division occlusion.

Garrido E, Stein BM: 1976 Middle cerebral artery embolectomy. Case report. Journal of Neurosurgery; 44:517-521.

Gibo et al, 1987 found the four divisions of Middle cerebral artery as M_1, M_2, M_3 and M_4 segments,.

Hier DB, Yoon WB, Mohr JP, Price TR, Wolf PA. 1994 Gender and aphasia in the stroke Data Bank. Brain & Language; 47:155-167

Hoffman M, Sacco RL, Mohr JP, Buda J. 1993 Cerebroappendicular embolism: simultaneous cerebral infarction and brachial plexopathy. Neurology; 43:620-621.

Hoffman M, Sacco RL, Mohr JP, Buda J. 1993 Cerebroappendicular embolism: simultaneous cerebral infarction and brachial plexopathy. Neurology; 43:620-621.

Homma S, Di Tullio MR, Sacco RL, Mihalatos D, Li Mandri G, Mohr JP. 1994. Characteristics of patent foremen ovale associated with cryptogenic stroke. A biplane transesophageal echocardiographic study. Stroke;25:582-586.

Jain 1964, found that average diameter of middle cerebral artery of 16mm,

Jeffrey and Jose Biller 1972, Bifurcation of middle cerebral artery, superior division gives orbitofrontal, prefrontal, prerolandic and rolandic inferior division given.

Jeffrey L.Salver and Jose biller 1972 found the trifurcation of Middle cerebral artery.

Kader A, Young WL, Pile-Spellman J, Mast H, Sciacca RR, Mohr JP, Stein BM. The influence of hemodynamic and anatomic factors on hemorrhage from cerebral.

Kittner SJ, Sharkness CM, Sloan MA Price TR, Dambrosia JM, Tuhrim S, Wolf PA, Mohr JP, Hier DB, Caplan LR. 1992 Infarcts with a cardiac source of embolism in the NINDS Stroke Data bank: neurologic examination. Neurology; 42: 299-302

Kittner SJ, Sharkness CM, Sloan MA, Price TR, Dambrosia JM, Tuhrim S, Wolf PA, Mohr JP, Hier DB. 1992 Features on initial computed tomography scan of infarcts with a cardiac source of embolism in the NINDS stroke Data Bank. Stroke; 23:1748-1751.

Kugler S, Anderson B, Cross D, Sharif Z, Sano M, Haggerty R, Prohovnik I, Hurlet-Jensen A, Hilal S, Mohr JP, 1993 et. al. Abnormal cranial magnetic resonance imaging scans in sickle-cell disease. Neurological correlates and clinical implications. Archives of Neurology; 50:629-635.

Libman RB, Sacco RL, Shi T, Correll JW, Mohr JP. 1994. Outcome after carotid endaterectomy for asymptomatic carotid stenosis. Surgical Neurology; 41:443-449.

Lustgarten JH, Solomon RA, Quest DO, Khanjdi AG, Mohr JP. 1994 Carotid endarterectomy after noninvasive evaluation by duplex ultrasonography and magnetic resonance angiography. Neurosurgery;34:612-618; discussion 618-619.

Marshall RS, Lazar RM, Binder JR, Desmond DW, Drucker PM, Mohr JP. 1994 Intrahemispheric localization of drawing dysfunction. Neuropsychologia; 32:493-501.

Marshall RS, Lazar RM, Binder JR, Desmond DW, Drucker PM, Mohr JP. 1994 Intrahemispheric localization of drawing dysfunction. Neuropsychologia; 32:493-501.

Mayer SA, Sacco RL, Shi T, Mohr JP. 1994 Neurologic deterioration in noncomatose patients with supratentorial intracerebral hemorrhage. Neurology; 44:1379-1384.

Mayer SA, Tatemichi TK, Hair LS, Goldman JE, Camac A, Mohr JP. 1993 Hemineglect and seizures in Binswanger's disease: clinical-pathological report. Journal of Neurology, Neurosurgery & Psychiatry; 56:816-819.

Mohr JP, Foulkes MA, Polis AT, Hier DB, Kase CS, Price TR, Tatemichi TK, Wolf PA. 1993 Infarct topography and hemiparesis profiles with cerebral convexity infarctioin: the stroke data bank. Journal of neurology, Neurosurgery & Psychiatry; 56:344-351.

Mohr JP. 1993 Classification and mechanisms of cerebrovascular disease. Annals of Epidemiology; 3:454-457.

Monrum, 1942, Walsh found the posterior temporal branch, 1937.

Omal 1992, found that cardiac embolus liges in the internal carotid artery and migrates to the middle cerebral artery.

Shellshear 1920, found that one artery of lenticulostriate is larger and passes around the lateral border lenticular nucleus which causes the internal cerebral haemorrhage as the artery of charcot.

Shellshear, 1925 Horey fixend that middle cerebral artery supplying the lateral border of lentiform nucleus. 1920.

Shepherd JT, Bergan JJ, Cohen RA, Hawiger JJ, Hillis LD, Katzen BT, Mohr JP. 1994 Report of the task force on vascular medicine. Circulation; 89-532-535.

Sonntag VK, Yuan RH, Stein BM. 1977 Giant intracranial aneurysms: a review of 13 cases. Surgical Neurology; 8:81-84.

Stein BM, Mohr JP. 1988 Vascular malformations of the brain (editorial). New England Journal of Medicine; 319:368-370.

Stein BM, Sisti MB, Mohr JP, Pile-Spellman 1994 J.Radiosurgery and venous malformations (letter, comment). Journal of Neurosurgery; 80:175; discussion 175-177.

Stein BM, Wolpert SM. 1977 Surgical and embolic treatment of cerebral arteriovenous malformations. Surgical Neurology; 7:359-369.

Stein BM. 1979 Surgical lesions of the intracranial optic nerves and optic chaism. Ophthalmology; 86:308-312.

Tatemichi TK, Desmond DW, Paik M, Figueroa M, Gropen TI, Stern Y, Sano M, Remien R, Williams JB, Mohr JP, 1993 et.al Clinical determinants of dementia related to stroke. Annals of Neurology; 35:568-575.

Timsit SG, Sacco RL, Mohr JP, Foulkes MA, Tatemichi TK, Wolf PA, Price TR, Hier DB. 1993 Brain infarction severity differs according to cardiac or arterial embolic source. Neurology; 43:728-733.

Vander and Adams 1953, found that middle cerebral artery vessels end in small arteries and arterioles that anastomosis with interior and posterior cerebral arteries.

Vander Fecken 1959 found the orbito frontal and anterior temporal branches, the temporal polar branch arising near the anterior temporal artery.

Venketasubramanian N, Prohovnik I, Hurlet A, Mohr JP, Piomelli S. 1994 Middle cerebral artery velocity changes during transfusion in sickle cell anemia. Stroke; 25:2153-2158.

Venketasubramanian N, Sacco RL, Di Tullio M, Sherman D, Homma S, Mohr JP. 1993 Vascular distribution of paradoxical emboli by transcranial Doppler (see comments) Neurology; 43:1533-1535.

Wolpert SM, Stein BM. 1979, Factors governing the course of emboli in the therapeutic embolization of cerebral arteriovenous malformations. Radiology; 131:125-131.