STUDY OF THE VARIATION IN THE RELATIONS OF RECURRENT LARYNGEAL NERVE TO THE THYROID GLAND AND ITS VASCULAR PEDICLES

submitted to

The Tamil Nadu Dr.M.G.R.Medical University

M.S. DEGREE EXAMINATION

BRANCH – V(ANATOMY)

STANELY MEDICAL COLLEGE, CHENNAI

THE TAMIL NADU DR.M.G.R. MEDICAL UNIVERSITY

CHENNAI

MARCH 2009

DECLARATION

I solemnly declare that the dissertation titled "Study of the relations of recurrent laryngeal nerve to the thyroid gland and its vascular pedicles" was done by me in the Department of Anatomy, Govt. Stanley medical college & Hospital, Chennai-1 under the guidance and supervision of **Dr. S.Chitra, M.S**. (Anatomy), Professor, Department of Anatomy, Govt. Stanley medical college, Chennai.

This dissertation is submitted to the Tamilnadu Dr.M.G.R.Medical University towards partial fulfillment of the requirement for the award of M.S. Degree (Branch V) in Anatomy.

Place:

Date:

Dr.J.Thilagavathi

ACKNOWLEDGEMENT

I sincerely thank **Dr.J.Mohana Sundaram, M.D., Ph.D., D.N.B., Dean, Govt. Stanley Medical College**, Chennai – 600 001 for granting me permission to utilize the facilities in this institution for my study.

I would like to express my sincere and profound gratitude to **Dr.Sudha Seshayyan, M.S., (Anatomy),** Former Professor and Head of the Department of Anatomy**,** Stanley Medical College, Chennai – 600 001 for her constant support, guidance and suggestions to complete my dissertation work.

I would like to express my sincere and profound gratitude to **Dr.S.Chitra, M.S., (Anatomy)**, Professor, Department of Anatomy**,** Stanley Medical College, Chennai – 600 001 for her valuable support, guidance and suggestions to refine my dissertation work.

My special thanks go to **Dr.B.Shanthakumar, M.D.,** Professor and Head of the Department of Forensic Medicine, Govt. Stanley Medical College, Chennai – 600 001 for permitting me to collect the specimens from the Department of Forensic Medicine for this study.

My special thanks go to **Dr.P.Dileepan, M.S.,** Professor and Head of the Department of Surgery, Govt. Stanley Medical College, Chennai – 600 001 for permitting me to observe the surgeries for my study.

My heartfelt thanks go to **Dr.M.Mohanambal, M.D., D.G.O.,** Superintendent of Raja Sir Ramasamy Mudaliyar lying in hospital for permitting me to collect foetal specimens for this study.

I owe my sincere acknowledgements to **Dr.T.Vasanthakumar, M.S., (Anatomy),** Assistant Professor for his encouragement in planning and pursuing this study.

I am also thankful to **Dr.C.Karunanithi, Dr.Mohandas Joe Chandra, Dr.Syed Rafi Ahmed, Dr.N.Rajasekaran, Dr.V.K.Venkatesan** and **Dr.C.Vijayabhaskar** for their valuable guidance and support during this study.

I would also like to express my sincere thanks to my colleagues and the technicians in the department who helped me in the completion of this study.

I would like to express my special regards to my husband **Dr.K.Muthukumar** and my son **Ganapathy Narayana Arul** for their constant support and cooperation throughout this study.

My sincere appreciation and thanks to all the participants in this study and to all the well wishers who have contributed in completing this work, to whom I shall remain grateful.

CERTIFICATE

This is to certify that the dissertation titled "Study of the relations of recurrent laryngeal nerve to the thyroid gland and its vascular pedicles" is a bonafide work done by Dr.J.Thilagavathi. It is a regular systematic study done under my guidance and supervision and submitted for ensuing M.S., ANATOMY BRANCH V Examination, March 2009 of the Tamilnadu Dr M.G.R Medical University, Chennai.

Place:

Date:

Dean

Stanley Medical College
Chennai - 1

Professor & Hod
Department Of Anatomy
Stanley Medical College
Chennai - 1

.

LIST OF CONTENTS

STUDY OF THE VARIATION IN THE RELATIONS OF RECURRENT LARYNGEAL NERVE TO THE THYROID GLAND AND ITS VASCULAR PEDICLES

AIM:

A sound knowledge of the normal human anatomy and common variations in it are very important to a physician and gives a major contribution to the skill and success of a surgeon.

This is especially true for a surgeon ,operating on the neck because it is one of the most difficult areas to operate upon, there being a very little space.

The recurrent laryngeal nerve innervates the intrinsic muscles of the larynx. These muscles are important in the production and modulation of the phonation component of the voice. During the course of the recurrent laryngeal nerve in the neck, the nerve is intimately related to the inferior thyroid artery and its branches. The relation of the recurrent laryngeal nerve to the inferior thyroid artery and its branches is highly variable. This makes the recurrent laryngeal nerve, extremely vulnerable to injury during the surgical manipulation of the neck, especially in the surgeries involving the thyroid gland.

When present in variable positions, the recurrent laryngeal nerve has a greater liability to be included in a ligature, crushed by an instrument or stretched during mobilization of the thyroid gland in the standard Thyroidectomy procedure.

Morbidity due to iatrogenic injury to the recurrent laryngeal nerve is reported to be up to 20% during thyroid surgery. This is one of the important criteria for operating surgeons because of the serious functional sequelae that include voice changes with respiratory embarrassment.

The current evaluation of out-patient short stay thyroid surgery and minimally invasive video assisted, thyroid lobectomy using laparoscope to avoid scar in the neck requires a very precise knowledge of the normal and variant anatomy, which is the corner stone for the performance of a safe and effective procedure.

An extensive analyses of the recurrent laryngeal nerve was studied under the following parameters

1. Origin

2. Relation to the Tracheo oesophageal groove

3. Relation to the inferior thyroid artery and its branches

REVIEW OF LITERATURE

Rogers, 1929 pointed out that the inferior thyroid artery is formed by a fusion between the branches of primitive vascular system which gives rise to arterial trunks and therefore it is not surprising to find that the arterial pattern showing gross variations in its relation to the inferior thyroid artery and its branches ,when they are finally formed.

Berlin DD et al., 1935, reported that the recurrent laryngeal nerve was commonly found in the Para tracheal position on the right side (53%) and within the Tracheo oesophageal groove on the left side (56%).He also described three surgically important relations of the nerve with respect to the posterior suspensory ligament of the thyroid gland (Ligament of Berry) as follows;

1. The Recurrent laryngeal nerve was frequently found to lie deep to the Ligament of Berry.

2. Deep to the Ligament of Berry, lies the postero lateral extension of the thyroid lobe (Tubercle of Zuckerkandl).

3. Extra laryngeal branching of the recurrent laryngeal nerve often occurred just proximal to the Ligament of Berry.

Ruth E.M.Bowden, 1955, studied the variations in the position, branching and relations of the recurrent laryngeal nerve in 19 cadavers and 9 fresh postmortem specimens. The study observed following relations of the recurrent laryngeal nerve to the inferior thyroid artery;

Relations of the recurrent laryngeal nerve to the inferior thyroid artery;

Nerve - Anterior to the artery		Nerve - Posterior to the artery		Nerve - Intermingled with the branches of the artery	
Right	**left**	**Right**	**left**	**Right**	**left**
8	3	9	15	11	9

It was also observed that 4 recurrent laryngeal nerves on the right side and 2 on the left side passed through the ligament of berry.

In relation to the tracheo oesophageal groove, it was found that 85% recurrent laryngeal nerves on the right side and 93% on the left side were within the tracheo oesophageal groove. 4 recurrent laryngeal nerves on the right side (15%) and 2 on the left side (7%) were found anterior to the groove. There was no evidence of penetration of thyroid gland by the recurrent laryngeal nerve on either side.

Extra laryngeal branches of the recurrent laryngeal nerve to the larynx were seen in 72% of the subjects.

Roysulce, Miyanchi M.D et.al, (1956) have stated that the inferior thyroid artery may be absent or doubled. When it is absent, it may be replaced by the Arteria-thyroidea Ima.

Claude J Hunt M.D et al., (1961) have stated as the recurrent laryngeal nerve ascends in the neck, it comes in close relation to the inferior thyroid artery. It usually passes beneath the inferior thyroid artery but may be passing anterior or passing through the dividing branches of

the artery. When the recurrent laryngeal nerve is under the artery, elevation of the thyroid gland from the thyroid bed does not disturb its anatomical position and leaves it safe.

George R Stewart et.al, (1972) identified and exposed 3496 recurrent laryngeal nerves during the thyroid surgeries. Of the 1776 recurrent laryngeal nerves, visualized, 6 were found to be non-recurrent on the right side (0.0006%). No non- recurrent laryngeal nerve was found on the left side.

Norman W Thompson M.D., William K Oslen M.D 1973, observed that the recurrent laryngeal nerve had a variable relationship with the inferior thyroid artery. It may pass behind or in front of the inferior thyroid artery, in between its two major branches or among its terminal branches or in combination of the above mentioned.

Bilateral symmetry of the recurrent laryngeal nerve in relation to the inferior thyroid artery was noted only in 17%. It was also observed that the recurrent laryngeal nerve was frequently found anterior to the tracheo oesophageal groove and that the right recurrent laryngeal nerve was found to be more often in the above position than the left recurrent laryngeal nerve.

It was also noted that the extra laryngeal branching of the recurrent laryngeal nerve had occurred in 43 – 78%. This extra laryngeal branching when present just below the level of the thyroid gland makes the nerve at a high risk of injury during ligation of the thyroid gland during thyroidectomy.

Chiu- an Wang, M.D., FACS, Boston et al., (1975), conducted a study on 500 recurrent laryngeal nerves in 156 cadavers and 94 surgeries. They concluded that

1. The inferior thyroid artery though used traditionally as a guide in identifying the recurrent laryngeal nerve, it has a highly variable anatomical pattern and this limits its usefulness as a guide for per operative identification of the nerve.

2. The inferior cornu of the thyroid cartilage was found to be a reliable guide and was more effective than the inferior thyroid artery to pinpoint the recurrent laryngeal nerve.

The authors also pointed out that the recurrent laryngeal nerve may be anterior or closely intermingled with the branches of the inferior thyroid artery. Here it may be mistaken for one of the branches of the inferior thyroid artery because of the visual pulsation of the nerve transmitted from an underlying arterial trunk.

John E. Scandalaki's M.D., et.al, (1976) examined the course of the recurrent laryngeal nerve in 62 male and 42 female cadavers and presented the following data;

Relationship of the recurrent laryngeal nerve and inferior thyroid artery:

RELATION	% FREQUENCY IN 102 CADAVERS		
	RIGHT	LEFT	BOTH SIDES
A. Nerve - anterior to the artery	31.4	9.8	20.8
B. Nerve - posterior to the artery	19.6	63.7	41.8
C. Nerve – in between the branches of the artery	49	26.5	37.4

Relationship of the recurrent laryngeal nerve to the tracheo oesophageal groove:

POSITION OF THE NERVE	% FREQUENCY	
	RIGHT	LEFT
A. In the tracheo oesophageal groove	41	56
B. Posterior to the tracheo oesophageal groove (Para oesophageal)	5	6
C. Anterior to the tracheo oesophageal groove (Para tracheal)	49	35
D. In the thyroid parenchyma	5	3

Based on the observations it was noted that no one pattern of relationship of the recurrent laryngeal nerve and inferior thyroid artery could be considered normal and a surgeon must be prepared for any configuration of artery and the nerve. Injury to the recurrent laryngeal nerve where it crosses the inferior thyroid artery is usually due to tearing of a branch of the artery and a careless attempt to catch the bleeding vessel.

It was also observed that the recurrent laryngeal nerve was at a higher risk of injury when it is present in the Para tracheal position and also in cases, where the recurrent laryngeal nerve penetrates the thyroid gland.

John M Lore Jr M.D., (1983) suggested that one of the most important considerations relating to thyroid surgery is the relationship of the posterior suspensory ligament of the thyroid to the recurrent laryngeal nerve. It was observed that as the recurrent laryngeal nerve emerges from the superior thoracic inlet, it lies in a triangle bounded laterally by the carotid sheath and its contents, medially by the trachea and the oesophagus and the base is formed by the inferior pole of the thyroid gland. The apex is directed inferiorly, through which the recurrent laryngeal nerve enters the neck.

The recurrent laryngeal nerve occasionally passed through the ligament of berry. In such cases inadvertent clamping of the ligament may injure the recurrent laryngeal nerve which passes through it.

Extra laryngeal branches of the recurrent laryngeal nerve were noted in 39%.

Katz A D (1986) examined 721 recurrent laryngeal nerves from 400 patients and reported extra laryngeal division of the nerve to be present in about 58%. In 97 cases, bilateral

bifurcations and in 10 cases bilateral trifurcations were found. It was suggested that injury to anyone of the extra laryngeal branches of the recurrent laryngeal nerve can cause vocal cord paralysis. Damage to any of the branches of recurrent laryngeal nerve to the oesophagus can cause dysphagia. Therefore, all the branches of the recurrent laryngeal nerve however small must be preserved whenever possible.

Al - Salihi A R, Dabbagh, A W. et al., (1989) studied the anatomy of the recurrent laryngeal nerve in 106 postmortem cases and observed that the usual position of the recurrent laryngeal nerve was in the tracheo oesophageal groove. The recurrent laryngeal nerve was found posterior to the inferior thyroid artery on the left in most cases , while its relations to the inferior thyroid artery was very variable on the right side.

Lekcos NL, Tzardis PT., et al., (1992) studied the relationship of the recurrent laryngeal nerve to the inferior thyroid artery and the suspensory ligament of Berry in 172 patients undergoing thyroidectomy. Out of the total 191 nerves identified, 82.6% on the right side and 85.4% on the left side passed either posteriorly or between the branches of the inferior thyroid artery. Majority of the nerves were found close to the suspensory ligament of Berry.

J.S.H.Wade, M.C., Cardiff et al., (1995) studied the course and the relationship of the recurrent laryngeal nerves in a clinical series of 100 patients submitted to subtotal thyroidectomy and presented the following data;

Relationship of the recurrent laryngeal nerve and inferior thyroid artery:

NERVE AND ARTERY RELATIONSHIP	LEFT	RIGHT
A. Nerve - superficial to arterial trunk	5	16
B. Nerve - deep to arterial trunk	58	37
C. Nerve - in between the branches of arterial trunk	37	47

It was observed that the vulnerability of the recurrent laryngeal nerve to injury, during thyroidectomy was due to

1. Its position in between the branches of the inferior thyroid artery
2. Due to its close proximity to the inferior thyroid veins which were found anterior to the tracheo oesophageal groove
3. Because of its course within the ligament of berry

Henry W.Gray (Gray's Anatomy – 39th edition) states that the recurrent laryngeal nerve differs in origin and course on both the sides. On the right side, it arises from the vagus anterior to the first part of the subclavian artery. It then curves backwards below the subclavian artery and then behind the subclavian artery to ascend obliquely to the side of the trachea behind the common carotid artery.

On the left side, the nerve arises from the vagus on the left of the aortic arch, curves

below it immediately behind the attachment of the ligamentum arteriosum in the concavity of the arch and ascends on the side of the trachea.

As it ascends it lies in the tracheo oesophageal groove and it is closely related to the medial surface of the thyroid gland before passing under the lower border of the inferior constrictor to enter the larynx, supplying all the intrinsic muscles of the larynx except the cricothyroid.

On both sides, near the lower pole of the thyroid gland it is more often anterior to the tracheo oesophageal groove. As it ascends, the recurrent laryngeal nerve comes to lie most often within the groove. On the right side, the nerve is either anterior to, or posterior to or intermingled with terminal branches of the inferior thyroid artery, while on the left, the nerve usually posterior to the inferior thyroid artery.

Outside its true capsule, the thyroid gland has a distinctive covering of pretracheal fascia, which splits into two layers at the posterior border of the gland.

One layer covers the entire medial surface of the lobe at or just before the isthmus has conspicuous thickening, the lateral ligament of the thyroid gland, the Suspensory ligament of Berry which attaches the gland to the trachea and the lower part of the cricoid cartilage.

The other layer is posterior, passing behind the oesophagus and pharynx, is attached to the pre vertebral fascia. By this splitting of the fascia, a compartment is formed on each side, lateral to the trachea and oesophagus filled with fat. It is in this fat, the terminal parts of the recurrent laryngeal nerve and inferior thyroid artery lie.

The recurrent laryngeal nerve may be lateral or medial to the lateral ligament of thyroid gland or sometimes may be embedded on it.

Sasou.S, Nakamura.S (1998) et.al., examined 689 recurrent laryngeal nerves during 486 thyroid surgeries and in 25 autopsied cadavers. It was observed that recurrent laryngeal nerves were located dorso lateral to the ligament of Berry in most cases. Neither the nerve penetrated the ligament nor was present medial to it.

Giovanni Sturmiolo M.D. et.al (1999) conducted intra operative study to define the anatomical relationships between the recurrent laryngeal nerve and inferior thyroid artery in 192 patients and observed that the recurrent laryngeal nerve was lying posterior to the trunk of inferior thyroid artery in 30.5% in the right side and 36.7% in the left side. It was suggested that exposure of the recurrent laryngeal nerve during the thyroid surgery is a sound surgical practice, which reduces the incidence of the recurrent laryngeal nerve injury.

Dorathea M.I., Liebermann Meffert M.D et.al (1999) studied the course of recurrent laryngeal nerve and external laryngeal nerve in post mortem enbloc specimens from 34 human corpses. 23 specimens were studied by macroscopic dissection method and 11 by serial sectioning. In most of the specimens the recurrent laryngeal nerves were found to pass sinuously upward within the lateral peri tracheal and less frequently peri oesophageal, loose connective tissue. The left recurrent laryngeal nerve was found closer to the tracheo oesophageal groove than the right.

Richard D. Bliss M.D. et.al, (2000) studied the relations of the recurrent laryngeal nerve in 6702 patients who underwent thyroidectomies from 1970 – 1990. It was observed that nearly 30 variations in the relationship between the recurrent laryngeal nerve and inferior thyroid artery. It was found that on the left side, recurrent laryngeal nerve usually passed posterior to the inferior thyroid artery while on the right side the nerve was commonly seen anterior to the artery or in between the branches.

It was reported that an enlarged tubercle of Zuckerkandl occurred in 41 out of the 161 thyroid lobes examined. Among the 41 cases, the recurrent laryngeal nerve was found medial to the tubercle in 37 cases and lateral to the tubercle in 4 cases. It was also found that recurrent laryngeal nerve may lie anterior to the tracheo oesophageal groove. Instead of its normal position within the groove, this anterior position of the nerve made it more prone to get injured during the dissection of inferior thyroid veins.

Campus B.A. et.al. (2000) studied the anatomical relations of the recurrent laryngeal nerve to the inferior thyroid artery in 76 embalmed corpses consisting of 8 females and 68 males. The study presented as depicted in the table below;

Relationship of the recurrent laryngeal nerve and inferior thyroid artery:

RECURRENT LARYNGEAL NERVE POSITION	RIGHT SIDE		LEFT SIDE		BOTH SIDES	
	N	%	N	%	N	%
A. Anterior to the inferior thyroid artery	27	38.04	13	18.05	40	27.97
B. Posterior to the inferior thyroid artery	8	11.26	27	37.05	35	24.97
C. In between the branches of the inferior thyroid artery	36	50.7	32	44.45	68	47.56
Total	71	100	72	100	143	100

Based on the above observations, it was concluded that there was a significant difference ($p < 0.05$) in the distribution of the recurrent laryngeal nerve and three types of relationships

between the recurrent laryngeal nerve and the inferior thyroid artery on the right and left sides.

Gauger P.G, Delbridge L.W et.al., (2001) conducted a prospective study on 100 patients who underwent thyroidectomy to find out the incidence of the tubercle of Zuckerkandl. It was noted that in 63% of the patients, the tubercle was present and it was also noted that in 45% of the patients the tubercle was more than 1CM. In 93% of the patients with enlarged tubercle of Zuckerkandl, the recurrent laryngeal nerve passed medial to it and in 7%, the recurrent laryngeal nerve passed lateral to it. It was suggested that since the tubercle of Zuckerkandl is a distinctive feature of thyroid gland and can be easily identified in most of the thyroidectomies and understanding of the consistent anatomical relationship between the tubercle of Zuckerkandl and the recurrent laryngeal nerve was crucial to safe thyroidectomy.

Poyeaz, M, Cal gunner E (2001) studied a total of 52 recurrent laryngeal nerves on fixed cadavers of 4 adult women and 26 adult men and observed the incidence of the recurrent laryngeal nerve in between the branches of the inferior thyroid artery was the commonest variant.

Ashkan Monfared B.S, Daniel Kim, M.D., (2001) studied the surgical anatomy of the right and left recurrent laryngeal nerves and their variations in 21 fresh cadavers. It was found that on the right side, the recurrent laryngeal nerve had the highest probability of passing in between the branches of the inferior thyroid artery, while on the left the recurrent laryngeal nerve commonly crossed the arterial branches, posteriorly.

MATERIALS AND METHODS

The study materials are

a) 20 cadavers

b) 15 post mortem en-bloc specimens

c) 10 patients who underwent partial or total thyroidectomies

d) 5 still born fetuses

A) DISSECTION ROOM CADAVERS:

All the 20 cadavers **(12 males and 8 females)** had been embalmed with 10% formalin solution containing 4% formalin for 3 months, prior to dissection.

B) POST MORTEM EN-BLOC SPECIMENS:

15 post mortem en-bloc specimens **(13 males and 2 females)** were collected from the Institute of Forensic Medicine, Government Stanley medical college and studied by conventional dissection method.

C) CLINICAL STUDY:

Subjects included 10 patients; **all females**, who underwent partial or total thyroidectomies in the surgical operation theatre, Department of surgery, Government Stanley medical college, Chennai – 6000 01.

D) Foetal study:

5 still born fetuses **(2 males and 3 females)** were obtained from the Department of Obstetrics and Gynaecology, RSRM Hospital**,** Government Stanley medical college, Chennai – 6000 01. All were embalmed with 10% formalin solution and studied.

The study was done systematically and as per the rules advised by the ETHICAL COMMITTEE.

METHODS

1. DISSECTION METHOD
2. CLINICAL STUDY
3. FOETAL STUDY

I. DISSECTION OF CADAVERS:

The dissection was carried out according to the methodology prescribed in the Cunningham's Practical Manual.

The skin was incised by a vertical incision extending from the symphysis menti to the supra sternal notch. The incision was extended laterally along the lower border of the base of the mandible up to the angle of the mandible. Two triangular laps were reflected on both sides up to the anterior border of the Sternocleidomastoid muscle.

The superficial fascia with Platysma was incised and reflected along the line of the skin incision, after noting the position o the anterior jugular veins. The investing layer of the deep cervical fascia was then lifted up using a forceps and incised vertically. It was followed laterally up to its fusion with the Carotid sheath deep to the Sternocleidomastoid muscle on either side.

The Sternothyroid and the superior belly of the omohyoid were cleared from their fascial covering. Their nerve supply from the Ansa cervicalis, entering their lateral border was noted. They were then divided in the middle 1/3rd just distal to their nerve supply and reflected.

The Sternothyroid muscle was then exposed and carefully incised in the middle one third

and was reflected. This exposed the pretracheal fascia and the thyroid gland.

EXPOSURE OF THE RECURRENT LARYNGEAL NERVE:

Position of the middle thyroid veins which leaves the lateral lobe of the thyroid close to its middle one third was noted and it was cut. The lateral lobes of the thyroid gland were lifted from the thyroid bed. The tough lateral ligament of Berry was visualized. The position of the recurrent laryngeal nerve in relation to this ligament was noted. The tubercle of Zuckerkandl was looked for.

After gently retracting the anterior border of the Sternocleidomastoid muscle laterally, the Carotid sheath and its contents were seen. The cervical part of the Vagus was fully exposed and the origin of a non recurrent laryngeal nerve was looked for. Right and left recurrent laryngeal nerves from the vagus were noted as they looped around the first part of the subclavian artery and the ligamentum arteriosum respectively and their continuation with the already identified cervical part of the nerve was ascertained.

The distal part of the recurrent laryngeal nerve was traced upwards up to its entry in to the larynx, deep to the lower border of the inferior constrictor muscle and antero-inferior to the tip of the inferior cornu of the thyroid cartilage. Extra laryngeal branches of the recurrent laryngeal nerve to the larynx and their site of origin from the main trunk of the nerve were noted.

The inferior thyroid artery was traced from its origin from the thyrocervical trunk. The point of emergence at the distal part of the artery behind the medial border of the Carotid sheath was noted. The point of branching of the artery into its terminal glandular branches to the thyroid gland was noted and the relations of these to the recurrent laryngeal nerve and its

branches were noted.

The following observations were made on the right and left recurrent laryngeal nerves

a) Origin

b) Relation to the tracheo oesophageal groove

c) Relation to the inferior thyroid artery and its branches.

II. DISSECTION OF THE POST MORTEM EN-BLOC SPECIMENS:

After reflecting the Sternocleidomastoid muscle and the infra hyoid strap muscle, dissection and identification of the recurrent laryngeal nerve was done following the same steps as for the cadaveric specimens and the same parameters as mentioned above were studied.

III. CLINICAL STUDY:

The steps of the partial and total thyroidectomies were observed on 10 patients in the surgical theatre. The following parameters of the recurrent laryngeal nerve were noted

a). Relation to the tracheo oesophageal groove

b) Relation to the inferior thyroid artery and its branches.

IV. FOETAL STUDY:

All the still born fetuses were dissected in the anterior triangle of the neck. An attempt was made to identify the recurrent laryngeal nerves on both sides and to study them in relation to the same parameters as that mentioned for adult specimens.

OBSERVATION

The origin, course and relations of the recurrent laryngeal nerve were studied by

1. Dissection method.

2. Clinical study.

3. Foetal study.

I. **Dissection method:**

In 20 cadavers and 15 post mortem specimens – 70 recurrent laryngeal nerves, 35 on the right side and 35 on the left side were dissected.

The recurrent laryngeal nerve was studied under the following parameters

a). Origin

b). Relation to the tracheo oesophageal groove

c). Relation to the inferior thyroid artery and its branches

A) Origin:

ON THE RIGHT SIDE:

All the Right recurrent laryngeal nerves, originated from the right vagus, at the level of the root of the neck in the right side, looping around the first part of the right subclavian artery.

ON THE LEFT SIDE:

All the Left recurrent laryngeal nerves, originated from the left vagus in the superior mediastinum, by looping around the arch of Aorta, just lateral to the ligamentum arteriosum.

The very rare anomaly of the non recurrent laryngeal nerve was not found in any one of the specimens.

B) Relation to the tracheo oesophageal groove:

The position of the recurrent laryngeal nerves in relation to the tracheo oesophageal groove was studied in two different levels:

1. At 2cm level below the lower border of the cricoid cartilage, which corresponds to the inferior thyroid pole.

2. At 1cm level below the lower border of the cricoid cartilage, which corresponds to the junction between the middle and lower third of the lateral lobes of the thyroid gland.

1. At 2cm level below the lower border of the cricoid cartilage:

On the right and left sides, out of the 70 recurrent laryngeal nerves, in both the male and

females,

On BOTH SIDES:

- 41 out of 70 (58.57%) nerves were seen in the Para tracheal position
- 29 out of 70 (41.42%) were seen within the tracheo oesophageal groove
- No para oesophageal position of the recurrent laryngeal nerve was observed

WHEN THE MALES AND FEMALES ARE COMPARED:

ON THE RIGHT SIDE:

In males;

Out of 25 recurrent laryngeal nerves, 10 recurrent laryngeal nerves were in the tracheo oesophageal groove and 15 other recurrent laryngeal nerves were in paratracheal position.

In females:

Out of 10 recurrent laryngeal nerves, 2 recurrent laryngeal nerves were found in tracheo oesophageal groove and in 8, the recurrent laryngeal nerves were found in paratracheal position.

ON THE LEFT SIDE:

In males

Out of 25 recurrent laryngeal nerves, 14 recurrent laryngeal nerves were in the tracheo oesophageal groove and in 11, the recurrent laryngeal nerves were in paratracheal position.

In females:

Out of 10 recurrent laryngeal nerves, 8 recurrent laryngeal nerves were found in tracheo oesophageal groove and in 2, the recurrent laryngeal nerves were found in paratracheal position.

The results are given in the Table – 1 and Fig – 1.

TABLE 1

Relation of recurrent laryngeal nerve to the tracheo oesophageal groove at 2cm level below the lower border of the cricoid cartilage:

Side of the neck	sex	No	Within the tracheo oesophageal groove		Paratracheal		Para oesophageal
			N	%	N	%	
RIGHT	Male	25	10	40	15	60	-
	Female	10	2	20	8	80	-
LEFT	Male	25	14	56	11	44	-
	Female	10	8	80	2	20	-

Fig 1

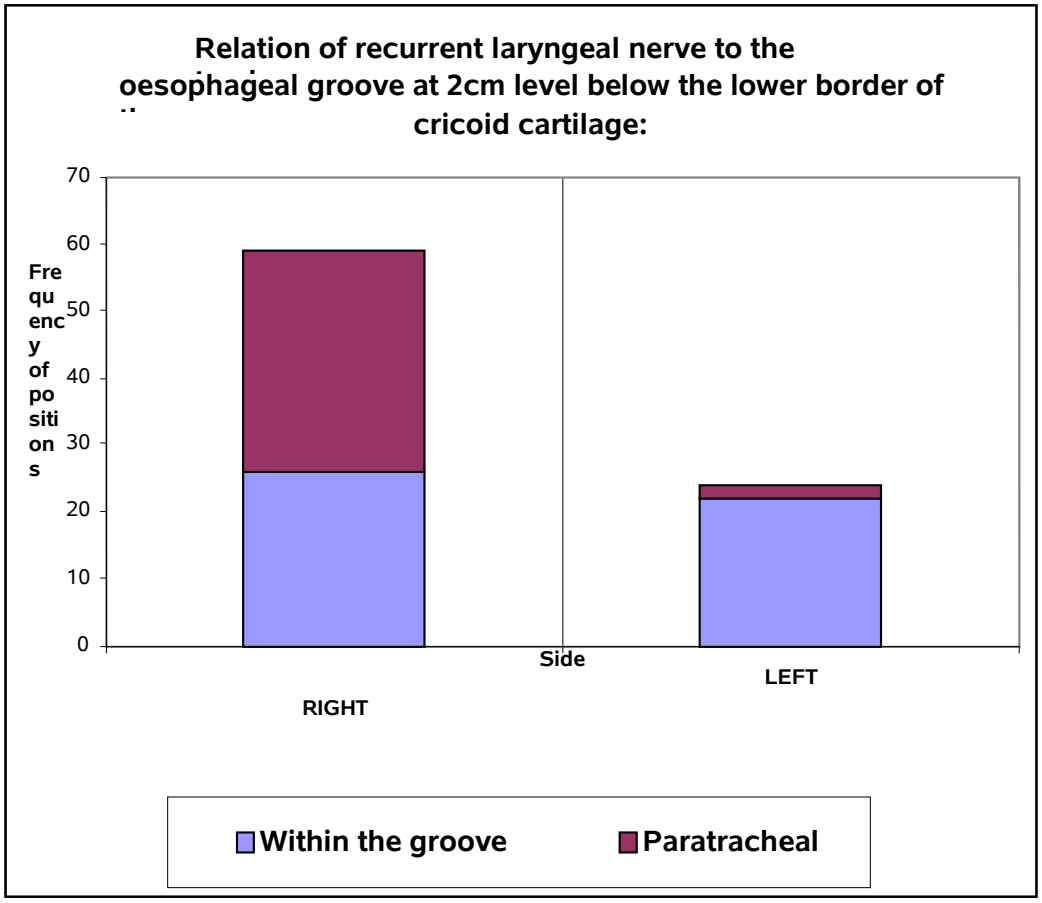
Relation of recurrent laryngeal nerve to the oesophageal groove at 2cm level below the lower border of cricoid cartilage:
Frequency of positions
70
60
50
40
30
20
10
0
Side
RIGHT
LEFT
Within the groove
Paratracheal

WHEN ONLY RIGHT AND LEFT SIDES ARE COMPARED;

ON THE RIGHT SIDE

12 out of 35 recurrent laryngeal nerves were found in the tracheo oesophageal groove.

23 out of 35 recurrent laryngeal nerves were found in the paratracheal position.

No nerves were found in the paraoesophageal position.

ON THE LEFT SIDE

22 out of 35 recurrent laryngeal nerves were found in the tracheo oesophageal groove.

13 out of 35 recurrent laryngeal nerves were found in the paratracheal position.

No nerves were found in the para oesophageal position.

STATISTICAL ANALYSIS using CHI-SQUARE TEST:

a. When the right and left sides are compared , Chi - Square value was 0.02, stating that there is statistical significance (P value < 0.05)

b. When the males and females are compared , Chi - Square value was 0.425, stating that there is **NO** statistical significance (P value > 0.05)

1. At 1CM level below the lower border of cricoid cartilage:

WHEN THE MALES AND FEMALES ARE COMPARED:

(Table-2 ; Fig – 2)

ON THE RIGHT SIDE:

In males;

Out of 25 recurrent laryngeal nerves, 18 recurrent laryngeal nerves were in the tracheo oesophageal groove and 7 other recurrent laryngeal nerves were in paratracheal position.

In females:

Out of 10 recurrent laryngeal nerves, 8 recurrent laryngeal nerves were found in tracheo oesophageal groove and in 2, the recurrent laryngeal nerves were found in paratracheal position.

ON THE LEFT SIDE:

In males:

Out of 25, in 23 cadavers the recurrent laryngeal nerves were in the tracheo oesophageal groove and in 2, the recurrent laryngeal nerves were in paratracheal position.

In females:

In all the 10 specimens, recurrent laryngeal nerves were found in the tracheo oesophageal groove. No paratracheal position of the recurrent laryngeal nerve was noted.

TABLE 2

Relation of recurrent laryngeal nerve to the tracheo oesophageal groove at 1cm level below the lower border of the cricoid cartilage:

Side of the neck	sex	No	Within the tracheo oesophageal groove		Paratracheal		Para oesophageal
			N	%	N	%	
RIGHT	Male	25	18	72	7	28	-
	Female	10	8	80	2	20	-
LEFT	Male	25	23	92	2	8	-
	Female	10	10	100	-	-	-

Fig 2

Graph showing the relation of the recurrent laryngeal nerve to the tracheo oesophageal groove at 1cm level below the lower border of the cricoid cartilage

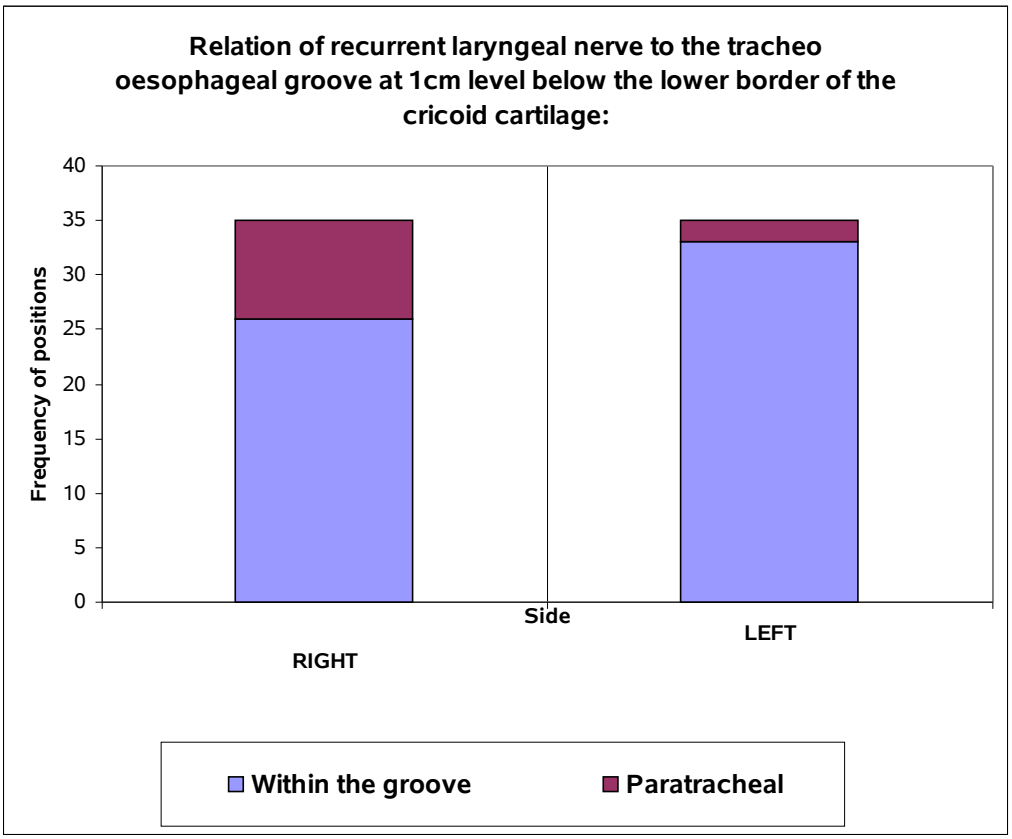

WHEN ONLY RIGHT AND LEFT SIDES ARE COMPARED:

ON THE RIGHT SIDE

Out of 35 recurrent laryngeal nerves, 26 were found in the tracheo oesophageal groove.

9 out of 35 recurrent laryngeal nerves were found in the paratracheal position.

No nerves were found in the paraoesophageal position.

ON THE LEFT SIDE

Out of 35 recurrent laryngeal nerves, 33 recurrent laryngeal nerves were found in the tracheo oesophageal groove.

2 out of 35 recurrent laryngeal nerves were found in the para tracheal position.

No nerves were found in the para oesophageal position.

STATISTICAL ANALYSIS using CHI-SQUARE TEST:

a. When the right and left sides are compared using the Chi – Square test, the 'p' value was 0.029, stating that there is statistical significance (P value < 0.05).

b. When the males and females are compared using the Chi - Square test, the 'P' value was 0.167, stating that there is **NO** statistical significance(P value > 0.05)

Thus statistically significant difference was seen in the relationship of the recurrent laryngeal nerve to the tracheo oesophageal groove between the right and left side in both levels that is, when the recurrent laryngeal nerve is 1 CM below the level of the cricoid cartilage and 2CM below the level of the cricoid cartilage.

C) RELATION OF THE RECURRENT LARYNGEAL NERVE TO THE INFERIOR THYROID ARTERY AND ITS BRANCHES:

(Table – 3, Fig- 3)

WHEN ONLY RIGHT AND LEFT SIDES ARE COMPARED:

ON THE RIGHT SIDE;

Out of 35 recurrent laryngeal nerves, 4 recurrent laryngeal nerves were found **ANTERIOR** to the branches of the inferior thyroid artery. (11%).

13 out of 35 recurrent laryngeal nerves were found **POSTERIOR** to the branches of the inferior thyroid artery. (37.05%).

Out of 35 recurrent laryngeal nerves, 18 recurrent laryngeal nerves were found in between the branches of the inferior thyroid artery. (51%)

ON THE LEFT SIDE

Out of 35 recurrent laryngeal nerves, 7 recurrent laryngeal nerves were found **ANTERIOR** to the branches of the inferior thyroid artery. (20%).

18 out of 35 recurrent laryngeal nerves were found **POSTERIOR** to the branches of the inferior thyroid artery. (51.4%).

Out of 35 recurrent laryngeal nerves, 10 recurrent laryngeal nerves were found in between the branches of the inferior thyroid artery. (28.6%).

TABLE 3

RELATION OF THE RECURRENT LARYNGEAL NERVE TO THE INFERIOR THYROID ARTERY AND ITS BRANCHES:

Side of the neck	Sex	Frequency	Anterior To The Branches Of The Inferior Thyroid Artery	Posterior To The Branches Of The Inferior Thyroid Artery	In Between The Branches Of The Inferior Thyroid Artery
RIGHT SIDE	Male	25	1	9	15
	Female	10	3	4	3
LEFT SIDE	Male	25	4	12	9
	Female	10	3	6	1

Fig 3

Graph showing the relation of the recurrent laryngeal nerve to the inferior thyroid artery and its branches:

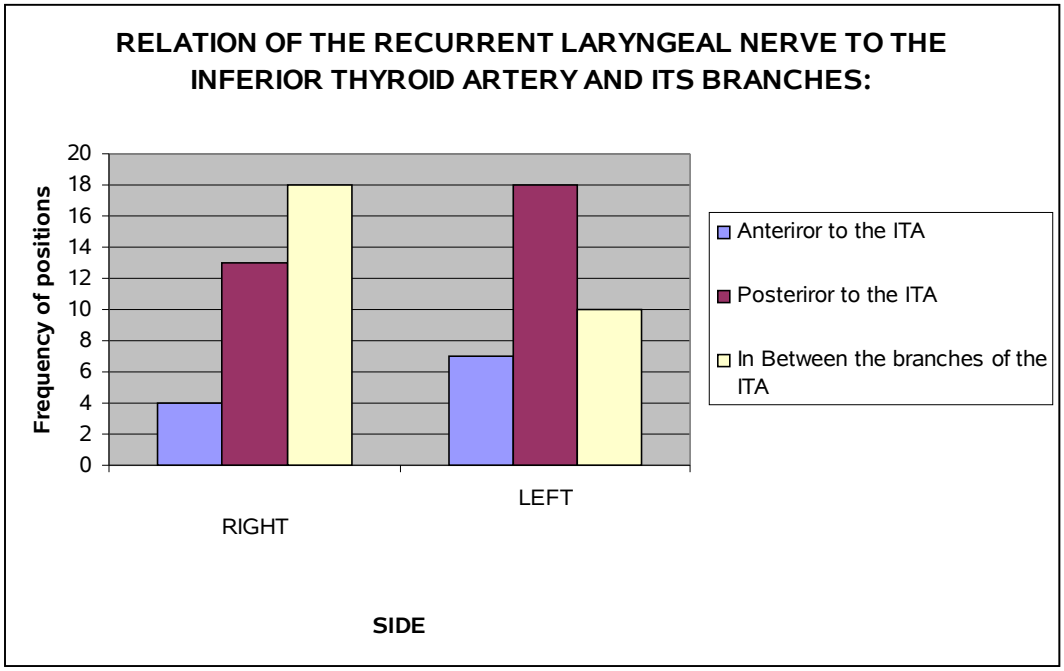

WHEN BOTH RIGHT AND LEFT SIDE ARE COMPARED

Out of 70 recurrent laryngeal nerves, 11 recurrent laryngeal nerves were found **ANTERIOR** to the branches of the inferior thyroid artery. (15.7%).

31 out of 70 recurrent laryngeal nerves were found **POSTERIOR** to the branches of the inferior thyroid artery. (44.3%).

Out of 70 recurrent laryngeal nerves, 28 recurrent laryngeal nerves were found in between the branches of the inferior thyroid artery. (40%).

STATISTICAL ANALYSIS USING CHI-SQUARE TEST:

a. When the right and left sides are compared using the Chi – Square test, the 'p' value was 0.003, stating that there is statistical significance. (P value < 0.05).

b. When the males and females are compared using the Chi - Square test, the 'P' value was 0.26, stating that there is **NO** statistical significance. (P value > 0.05).

Thus statistically significant difference was seen in the relationship of the recurrent laryngeal nerve to the Inferior thyroid artery and its branches between the right and left side: but **NOT** between males and females.

II. CLINICAL STUDY:

A total of 10 patients who underwent bilateral total thyroidectomies in the Surgical Department were studied.

The following parameters of the recurrent laryngeal nerve were observed ;(**Table - 4; Fig 4).**

a. Relation to the Tracheo oesophageal groove.

b. Relation to the Inferior thyroid artery and its branches.

A. Relation to the Tracheo oesophageal groove: .

The position of the recurrent laryngeal nerve was seen at the level of the inferior thyroid artery (approximately 1 CM below the lower border of the cricoid cartilage).

ON THE RIGHT SIDE:

Out of 10 recurrent laryngeal nerves, 6 recurrent laryngeal nerves were found in tracheo oesophageal groove (60%) and in 4, the recurrent laryngeal nerves were found in Para tracheal position (40%).

ON THE LEFT SIDE:

Out of 10 recurrent laryngeal nerves, 8 recurrent laryngeal nerves were found in tracheo oesophageal groove (80%) and in 2, the recurrent laryngeal nerves were found in Para tracheal position (20%).

TABLE 4

Relation of recurrent laryngeal nerve to the tracheo oesophageal groove

Side of the neck	sex	No	Within the tracheo oesophageal groove		Paratracheal		Para oesophageal
			N	%	N	%	
RIGHT	Female	10	6	60	4	40	-
LEFT	Female	10	8	80	2	20	-

Fig 4

Graph showing relation of recurrent laryngeal nerve to the tracheo esophageal groove:

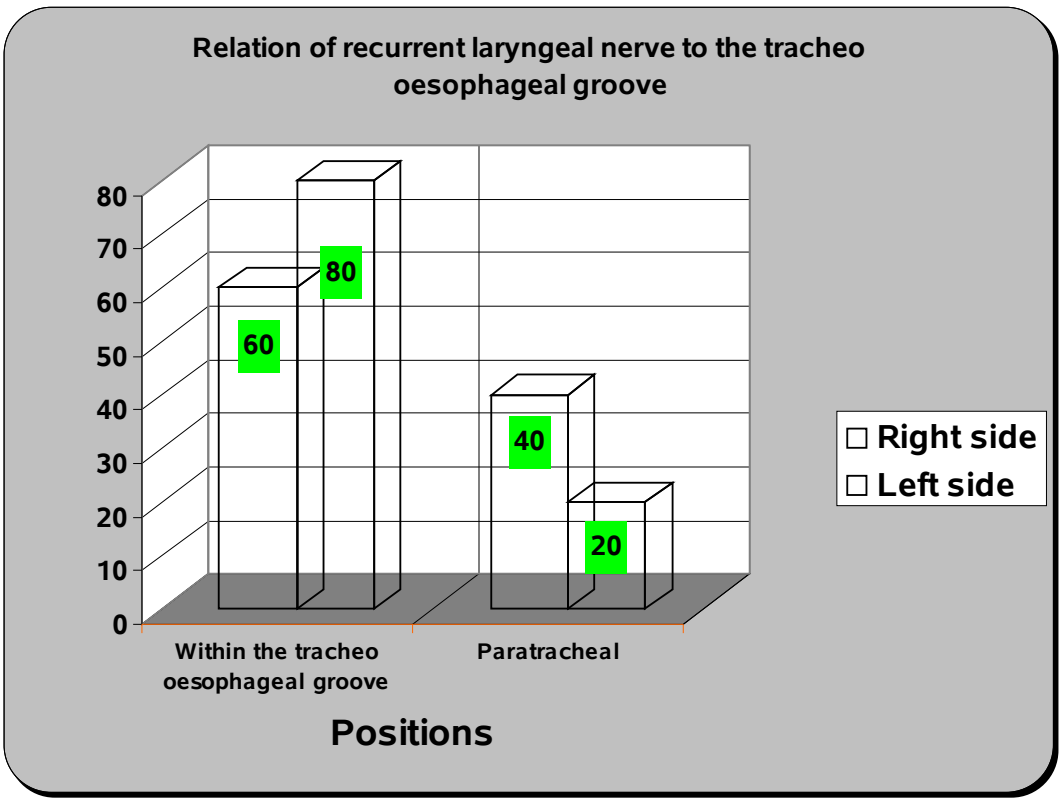

B) RELATION OF THE RECURRENT LARYNGEAL NERVE TO THE INFERIOR THYROID ARTERY AND ITS BRANCHES:

(Table -5 ; Fig -5)

ON THE RIGHT SIDE:

Out of 10 recurrent laryngeal nerves, 1 recurrent laryngeal nerve was found **ANTERIOR** to the branches of the inferior thyroid artery. (10%).

3 out of 10 recurrent laryngeal nerves were found **POSTERIOR** to the branches of the inferior thyroid artery. (30%).

6 out of 10 recurrent laryngeal nerves were found in between the branches of the inferior thyroid artery. (60%).

ON THE LEFT SIDE:

Out of 10 recurrent laryngeal nerves, 1 recurrent laryngeal nerve was found **ANTERIOR** to the branches of the inferior thyroid artery. (10%).

5 out of 10 recurrent laryngeal nerves were found **POSTERIOR** to the branches of the inferior thyroid artery. (50%).

4 out of 10 recurrent laryngeal nerves were found in between the branches of the inferior thyroid artery. (40%).

TABLE 5

RELATION OF THE RECURRENT LARYNGEAL NERVE TO THE INFERIOR THYROID ARTERY AND ITS BRANCHES:

Side of the neck	Frequency	Anterior To The Branches Of The Inferior Thyroid Artery	Posterior To The Branches Of The Inferior Thyroid Artery	In Between The Branches Of The Inferior Thyroid Artery
RIGHT SIDE	10	1	3	6
LEFT SIDE	10	1	5	4

Fig 5

Graph showing the relation of the recurrent laryngeal nerve to the inferior thyroid artery and its branches

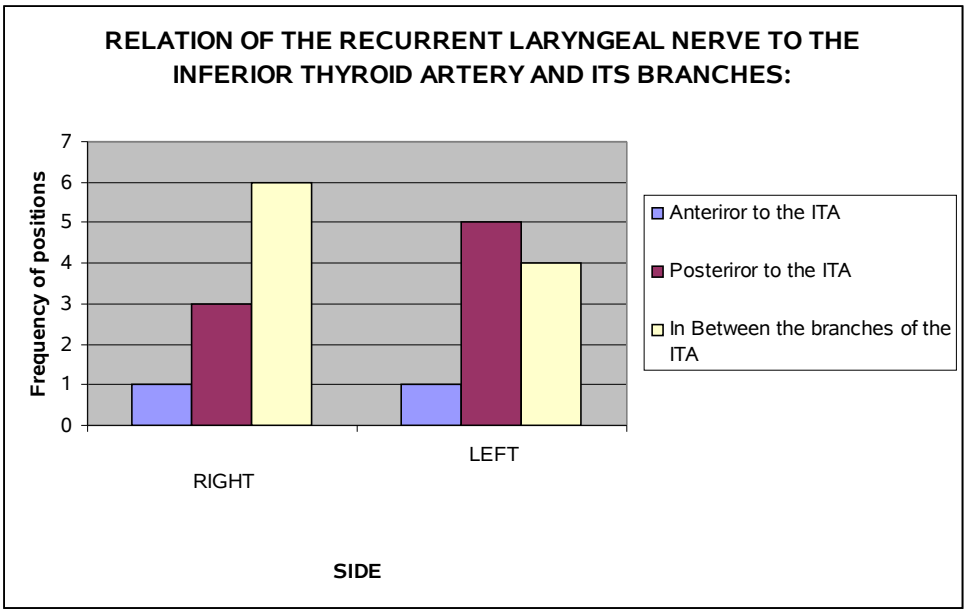

1. FOETAL STUDY

5 Still born babies (2 Males and 3 Females) were dissected in the neck region and the recurrent laryngeal nerves were identified on both the sides.

A. Relation to the Tracheo oesophageal groove: .

ON THE RIGHT SIDE:

Out of 5 recurrent laryngeal nerves, 2 recurrent laryngeal nerves were found in tracheo oesophageal groove (40%) and in 3 recurrent laryngeal nerves were found in paratracheal position (60%).

ON THE LEFT SIDE:

Out of 5 recurrent laryngeal nerves, 4 recurrent laryngeal nerves were found in tracheo oesophageal groove (80%) and in 1, the recurrent laryngeal nerve was found in Para tracheal position (20%).

B. RELATION OF THE RECURRENT LARYNGEAL NERVE TO THE INFERIOR THYROID ARTERY AND ITS BRANCHES:

ON THE RIGHT SIDE:

Out of 5 recurrent laryngeal nerves, 1 recurrent laryngeal nerve was found **ANTERIOR** to the branches of the inferior thyroid artery. (20%).

4 out of 5 recurrent laryngeal nerves were found in between the branches of the inferior thyroid artery. (80%).

No recurrent laryngeal nerves were found **POSTERIOR** to the branches of the inferior thyroid artery.

ON THE LEFT SIDE:

ALL the five recurrent laryngeal nerves were found **POSTERIOR** to the branches of the inferior thyroid artery. (100%).

NO recurrent laryngeal nerves, were found either anteriorly or in between the branches of the inferior thyroid artery.

TABLE 6

RELATION OF THE RECURRENT LARYNGEAL NERVE TO THE INFERIOR THYROID ARTERY AND ITS BRANCHES:

SIDE OF THE NECK	FREQUENCY	Anterior to the branches of the inferior thyroid artery	Posterior to the branches of the inferior thyroid artery	In between the branches of the inferior thyroid artery
RIGHT SIDE	5	1	0	4
LEFT SIDE	5	0	5	0

DISCUSSION

The variations in the origin, course and relations of the recurrent laryngeal nerve in the current study were analysed and compared with those described by previous authors.

A. ORIGIN:

The recurrent laryngeal nerves differ in their origin on the two sides of the neck.

On the right side, the nerve arises from the right vagus, anterior to the first part of the right subclavian artery, looping around right subclavian artery to ascend obliquely to the side of the trachea.

On the left side, the nerve arises from the left vagus, on the left of the aortic arch, curves below it, immediately below the attachment of the ligamentum arteriosum and ascends in or near the tracheo oesophageal groove, (Henry W. Gray 39TH edition).

George.R. Stewart (1972) reported a finding of six non recurrent laryngeal nerves on the right side out of 1776 nerves visualized (0.003%).There was no non recurrent laryngeal nerve on the left side.

The non recurrent laryngeal nerve which is a very rare anomaly was not found in any one of the cases in the present study.

B. RELATION OF THE RECURRENT LARYNGEAL NERVE TO THE TRACHEO OESOPHAGEAL GROOVE:

According to Henry W. Gray the recurrent laryngeal nerve ascends in or near the tracheo oesophageal groove and at the level of the lower pole of the thyroid gland. The recurrent

laryngeal nerves are more commonly anterior to the groove (paratracheal) on the right side than on the left side.

Berlin (1935) reported that the recurrent laryngeal nerve is more commonly in the paratracheal position on the right side (53%) and within the tracheo oesophageal groove on the left side (56%).

Bowden (1955) reported that the recurrent laryngeal nerves most frequently pass within the tracheo oesophageal groove in both the right and on the left sides. Paratracheal position was found only in 15% on the right side and 7% on the left side.

John.E.Skandalakis et al., (1976) stated that majority of the right recurrent laryngeal nerves were in the paratracheal position (49%) and the left recurrent laryngeal nerves were in the tracheo oesophageal groove (56%).

He also observed that para oesophageal position of the recurrent laryngeal nerve was found in 5% of the cases on the right side and 6% of cases on the left side. Penetration of the thyroid parenchyma by the recurrent laryngeal nerve was found in 5% of the cases on the right side and 3% of cases on the left side.

In the present study, the relation of the recurrent laryngeal nerve to the tracheo oesophageal groove was studied in two levels.

A) 2 CM below the lower border of the cricoid cartilage which corresponds to the lower pole of the thyroid gland:

In this level, the recurrent laryngeal nerves on the right side were more commonly para tracheal in position (70%), while on the left side the recurrent laryngeal nerves were found to

lie more commonly within the tracheo oesophageal groove (63%). This is comparable with the description of Henry W Gray, Berlin (1935) and John.E.Skandalakis et al., (1976) but not with the findings of the Bowden (1955).

In the current study, the chi-square test showed that the differences of the recurrent laryngeal nerves on the right and left side were statistically significant.

B). 1 CM below the lower border of the cricoid cartilage:

At this level the recurrent laryngeal nerves were found to lie most frequently within the tracheo oesophageal groove on both sides. The paratracheal position was greater on the right side, however the paratracheal position of the right recurrent laryngeal nerve was lesser in this level than that in the previous level. This is in conformity with Henry Gray's description.

Also at this level, the differences in the position of the recurrent laryngeal nerves between the right and left side were statistically significant.

The para oesophageal position of the recurrent laryngeal nerve was not seen compared to John.E.Skandalakis et al., (1976), who reported an incidence of para oesophageal position of the recurrent laryngeal nerve, 5% and 6% on the right and left sides respectively.

There was no penetration of the thyroid parenchyma as observed by the John.E.Skandalakis et al., (1976) **in the current study.**

The comparison of the relations of the recurrent laryngeal nerves to the tracheo oesophageal groove as reported by the previous authors is given in the **table 7** with the frequencies in percentage:

TABLE 7

The comparison of the relations of the recurrent laryngeal nerves to the tracheo oesophageal groove:

RIGHT SIDE:

Position	Berlin (1935)	Bowden (1955)	John.E.Skandalakis (1976)	**Current study**
Paratracheal	53	15	49	70
Tracheo oesophageal groove	47	85	41	30
Para oesophageal	-	-	5	-
Penetration of the thyroid parenchyma	-	-	5	-

TABLE 8

The comparison of the relations of the recurrent laryngeal nerves to the tracheo oesophageal groove:

LEFT SIDE:

Position	Berlin (1935)	Bowden (1955)	John.E.Skandalakis (1976)	Current study
Paratracheal	44	7	35	30
Tracheo oesophageal groove	56	93	56	70
Para oesophageal	-	-	6	-
Penetration of the thyroid parenchyma	-	-	3	-

SURGICAL IMPORTANCE:

Henry W Gray (39TH edition) pointed that the recurrent laryngeal nerve is relatively "safe" within the tracheo oesophageal groove. Richard D Bliss et.al.,(2000) have stated that when the right recurrent laryngeal nerve lie within the paratracheal position, it is **less protected** and is more vulnerable to injury during the cauterization of the inferior thyroid veins because the nerve lies closer to the inferior thyroid veins, when present in this position.

Accordingly, high risk position of recurrent laryngeal nerve in the paratracheal position was seen in statistically significant proportion on the right side compared to the left side in the present study. A surgeon must be aware of this fact, while dealing with the inferior thyroid veins during thyroidectomies.

C. RELATION OF THE RECURRENT LARYNGEAL NERVE TO THE INFERIOR THYROID ARTERY AND ITS BRANCHES:

Rogers (1929) pointed out that the relation of the recurrent laryngeal nerve to the inferior thyroid artery is embryologically determined and highly variable.

Henry W Gray (39th edition) states that the recurrent laryngeal nerve may pass anterior, posterior or in between the branches of the inferior thyroid artery.

Reed (1934), Bach Huber (1943) stated that the recurrent laryngeal nerve most frequently found posterior to the inferior thyroid artery followed by its position in between the branches of the inferior thyroid artery and that position of the recurrent laryngeal nerve anterior to the inferior thyroid artery was a rare finding.

Fowler and Hansen (1929), Berlin (1935), Simon (1943), Armstrong and Hinton (1951), Hunt (1968), Chang-chien (1980) and Costa (1997) in their independent reports had also stated that the recurrent laryngeal nerve was most frequently found in the following order;

1. Posterior to the inferior thyroid artery
2. Anterior to the inferior thyroid artery
3. In between the branches of the inferior thyroid artery

Flament et.al (1983) reported that the recurrent laryngeal nerve most frequently occurred In between the branches of the inferior thyroid artery.

In the present study, there exists a statistically significant difference in the relation of the recurrent laryngeal nerve to the branches of the inferior thyroid artery coinciding with that reported by Campos B A et.al., (2000).

On the right side, the recurrent laryngeal nerve was most frequently found in between the branches of the inferior thyroid artery (70%) while on the left side it was found posterior (42.85%).

When the both sides were considered together the recurrent laryngeal nerve was found in the following order of frequency;

1. Posterior to the inferior thyroid artery (44.3%)
2. In between the branches of the inferior thyroid artery (40%)
3. Anterior to the inferior thyroid artery (15.7%)

The above findings correlate with the following eminent authors as mentioned in the ensuing table 9.

TABLE 9

Relationship of the recurrent laryngeal nerve with the inferior thyroid artery – a comparison of the present study with eminent authors:

Author	Year	Anterior to the inferior thyroid artery	Posterior to the inferior thyroid artery	In between the branches of the inferior thyroid artery
Fowler and Hansen	1929	26%	65.5%	8.5%
Reed	1935	32.14%	53.57%	14.3%
John.E.Skandalakis et al.,	1976	20.6%	41.6%	37.3%
Present study	**2008**	**15.7%**	**44.3%**	**40%**

Fig 6

Graph showing Comparison of the present study with eminent authors:

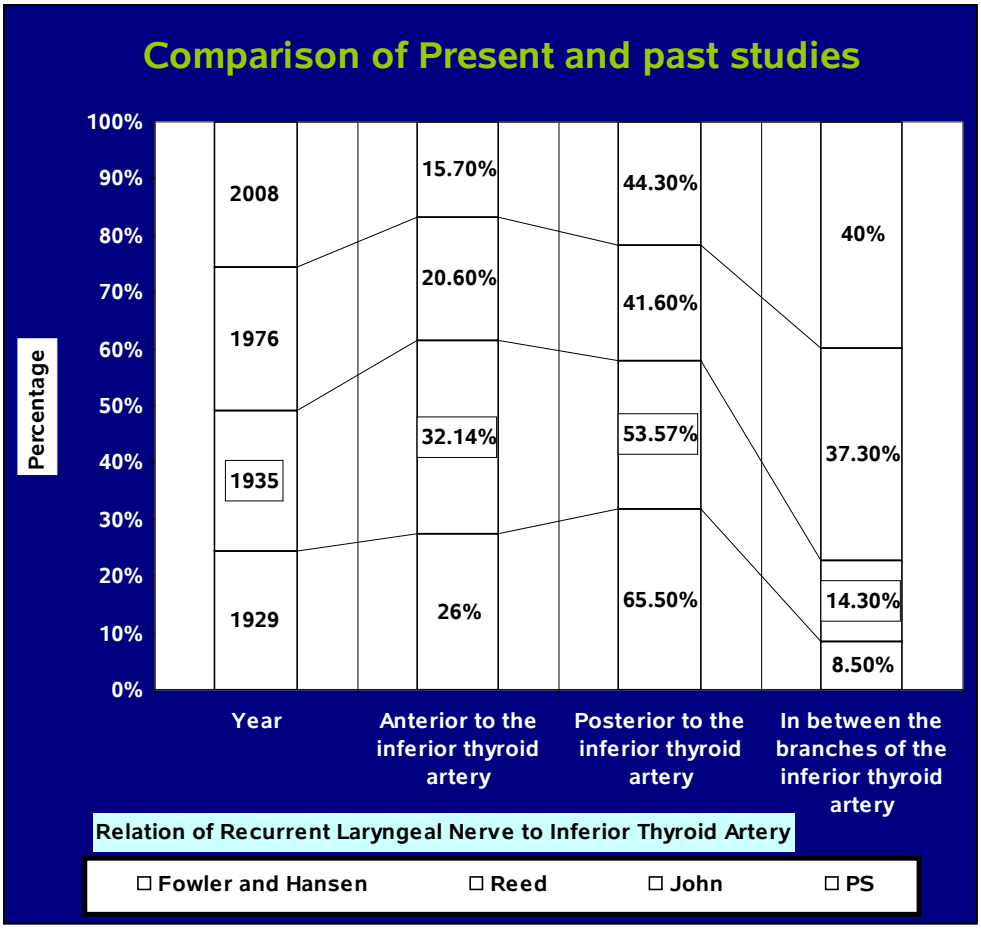

John. E.Skandalakis M D et al, (1976) stated that the injury to the recurrent laryngeal nerve where it crosses the inferior thyroid artery is usually due to the tearing of a branch of the artery and a careless attempt to catch the bleeding vessel, when the recurrent laryngeal nerve is caught and tied along with the vessel.

From the above discussion, the high risk position of the recurrent laryngeal nerve was seen in the following situations in the present study;

1. when the recurrent laryngeal nerve is present in the paratracheal position (65% on

the right side and 13% on the left side)

2. when the recurrent laryngeal nerve passes

a) Anterior to the inferior thyroid artery (15.7%)

b) In between the branches of the inferior thyroid artery (40%)

In the present study, the cadaver and post mortem dissection findings also coincide with the findings of the clinical study and foetal study.

CONCLUSION

In the present study, the anatomy of the recurrent laryngeal nerve has been analyzed under the parameters described by the eminent authors in the field of Anatomy.

Analysis of the recurrent laryngeal nerve was done separately on both sides of the neck and in both the sexes.

The recurrent laryngeal nerve has been analyzed based on its origin, course and the intimate relationship with the inferior thyroid artery and its branches.

The dissection findings of cadavers, post mortem specimens and fetuses have been supported by the clinical studies. The results of the present study have coincided with many of the previous eminent authors.

The present study has also mentioned the vulnerable and high risk positions of the recurrent laryngeal nerve and the reasons for the same in the surgical point of view.

It is sincerely hoped that the results of the present study will be a guide and will be of great help to the surgeons performing partial and total thyroidectomies.

DISSECTION STUDY
Photo 1

COMMON CAROTID
ARTERY

VAGUS
NERVE

Photo 2

CUT END OF
CLAVICLE

RIGHT
RECURRENT
LARYNGEAL
NERVE

FOETAL STUDY

Photo 3

STILL BORN DISSECTION

SKIN WITH PLATYSMA

SUPERIOR
BELLY OF
OMOHYOID

STERNOCLEIDO
MASTOID

CLINICAL STUDY

Photo 4

Photo 5

RIGHT RECURRENT
LARYNGEAL
NERVE

Photo 6

BIBLIOGRAPHY

1. Al - Salihi A R, Dabbagh, A W: Anatomy of the recurrent laryngeal nerve in normal Iraqis – Acta Anat. (Basel) 1981; Vol.135 (3); 245-247.

2. Berlin D.D: The Recurrent laryngeal nerves in total ablation of the normal thyroid gland – an anatomical and surgical study - Surg.Gynec.Obste.1935, vol.60; 19 – 26.

3. Campus B.A. et.al.,: The relations of the recurrent laryngeal nerve and the inferior thyroid artery – A study in corpses – Rev. Hosp.Clin.Fac.Med. S. Paulo 55 (6); 195-200, Nov (2000).

4. Chiu- an Wang, M.D., FACS: The use of inferior cornu of the thyroid cartilage in identifying the recurrent laryngeal nerve – Surgery, Obstetrics &Gynecology Jan (1975) Vol. 140, 91-94.

5. Claude J Hunt M.D: The recurrent laryngeal nerve as related to thyroid surgery: American journal of surgery. July (1961), vol. 27: 548 – 552.

6. Dorathea M.I., Liebermann Meffert M.D et.al: Recurrent laryngeal nerve and superior laryngeal nerves – a new look with implications for the Oesophageal surgeon – Annuals of thoracic surgery (1999), vol. 67: 217-223.

7. Gauger P.G, Delbridge L.W et.al: Incidence and importance of the Tubercle of Zuckerkandl in thyroid surgery. European Journal of Surgery (2001), Vol 167: 249 –254.

8. George R Stewart et.al: The non recurrent laryngeal nerve – British journal of surgery (1972), May vol.59 (5), 379-381.

9. Giovanni Sturmiolo M.D. et.al (1999): The recurrent laryngeal nerve related to thyroid Surgery; American journal of surgery. June (1999), vol. 177: 485 – 488.

10. Henry William Gray (Gray's Anatomy – 39th edition).

11. John E. Scandalaki's M.D., et.al: Embryological considerations in thyroid Surgery; American journal of surgery. Sep (1976), vol. 42: 621-628.

12. John E. Scandalaki's M.D., et.al: The recurrent laryngeal nerve; American journal of surgery. Sep (1976), vol. 42: 629-634.

13. John M Lore Jr M.D: Practical anatomical considerations in thyroid tumour surgery – Archives of otolaryngology; Sep (1983) vol. 109: 568 –574.

14. J.S.H.Wade,M.C, M.C., Cardiff et al: Vulnerability of the recurrent laryngeal nerve at thyroidectomy – British journal of surgery (1995) – Vol.43; 164-180.

15. Katz A D; Extra laryngeal of the laryngeal nerve- American journal of surgery. Oct (1986), vol. 152; 407 –410.

16. Lekcos NL, Tzardis PT., et al: Course of the recurrent laryngeal nerve related to the inferior thyroid artery- International journal of surgery;

Oct – Dec (1992), vol. 77(4); 287-288.

17. Norman W Thompson M.D., William K Oslen M.D: The continuing development of the technique of thyroidectomy - American journal of surgery. June (1973), vol. 73(6); 913 –927.

18. Poyeaz, M, Cal gunner E: Recurrent laryngeal nerve and the inferior thyroid artery – Okajimas Folia anatomy, Japan, August 2001; vol.78; 65 –74.

19. Rogers: Journal of anatomy, London,1929; vol.64; 50.

20. Richard D. Bliss M.D. et.al: Surgeon's approach to the thyroid gland, World journal of surgery; August (2000), vol. 24; 891 –897.

21. Ruth E.M.Bowden: Surgical anatomy of the recurrent laryngeal nerve, British journal of surgery 1955, vol. 43; 153 –163.

22. Sasou.S, Nakamura.S et.al: Suspensory ligament of Berry – its relation to the recurrent laryngeal nerve, Head & Neck, December, 1998, vol. 20; 694 -698