A Dissertation on

A STUDY ON ROLE OF ANATOMICAL OBSTRUCTION IN PATHOGENESIS OF CHRONIC SINUSITIS

Submitted to the

THE TAMILNADU DR. M.G.R. MEDICAL UNIVERSITY

In partial fulfilment of the requirements

For the award of the degree of

M.S.BRANCH IV
(OTORHINOLARYNGOLOGY)

GOVERNMENT STANLEY MEDICAL

COLLEGE & HOSPITAL

THE TAMILNADU DR. M.G.R. MEDICAL UNIVERSITY,

CHENNAI, TAMILNADU

APRIL 2014

DECLARATION

I, **DR. YAHYA ABDUL BASITH.M**, Solemnly declare that the dissertation, titled **" A STUDY ON THE ROLE OF ANATOMICAL OBSTRUCTION IN THE PATHOGENESIS OF CRONIC SINUSITIS"** is a bonafide work done by me during the period of MARCH 2012 to NOVEMBER 2013 at Government Stanley Medical College and Hospital, Chennai under the expert supervision of **PROF.DR.T.BALASUBRAMANIAN, M.S., D.L.O.,** Professor and Head, Department Of Otorhinolaryngology , Government Stanley Medical College and hospitals, Chennai.

This dissertation is submitted to The Tamil Nadu Dr. M.G.R. Medical University in partial fulfilment of the rules and regulations for the M.S. degree examinations in Otorhinolaryngology to be held in April 2014.

Chennai-1 **DR.YAHYA ABDUL BASITH.M**

Date:

CERTIFICATE

This is to certify that this dissertation on "**A STUDY ON ROLE OF ANATOMICAL OBSTRUCTION IN THE PATHOGENESIS OF CHRONIC SINUSITIS"** presented here in by DR YAHYA ABDUL BASITH M, is the original work done in Department of Otorhinolaryngology, Government Stanley Medical College and Hospitals, Chennai in partial fulfillment of the regulations of the Tamilnadu DR.M.G.R Medical University, Chennai for the award of M.S (Otorhinolaryngology), under guidance and supervision during the academic year 2011 – 2014.

PROF. DR.T.BALASUBRAMANIAN, M.S., D.L.O.,
Professor and Head,
Department of Ent & Head and Neck Surgery,
Stanley Medical College & Hospital,
Chennai.

PROF.DR.S.GEETHALAKSHMI M.D., Ph.D.,
Dean
Stanley Medical College & Hospital,
Chennai.

ACKNOWLEDGEMENT

I wish to express my sincere thanks to **Prof. Dr.GEETHALAKSHMI, M.D., Phd, DEAN**, Government Stanley Medical College and Hospital for having permitted me to utilize the facilities of the hospital for the conduct of the study.

My heartfelt gratitude to **Prof. Dr. T.BALASUBRAMANIAN, M.S., D.L.O,** Professor and Head, Department of Otorhinolaryngology, Government Stanley Medical College and Hospital for his motivation, valuable suggestions, expert supervision and for making all necessary arrangements for conducting this study.

I owe my sincere thanks to **Prof. Dr. N.SEETHALAKSHMI M.S.,D.L.O.,** Professor of Otorhinolaryngology, **Prof.Dr.RAMANIRAJ M.S, D.L.O** Professor of Otorhinolaryngology, for supporting, guiding and encouraging me in this study.

I wish to thank my Assistant professors DR. ATHIYAMN M.S, DR.KARUPPASAMY M.S., D.L.O., DR.CHANDRAMOULI M.S., DR.NANMULLAI M.S., DR.BHARANIDHARAN D.L.O. for their valuable suggestion and help.

I also thank Mrs. Radhakalaiselvan, Audiologist and speech pathologist of ENT Department, Government Stanley hospital for her expert assistance.

My sincere thanks to all those post graduates who helped me during this study period.

I thank the staff nurses and theatre personnel, Government Stanley Hospital for their cooperation and assistance.

Last but not the least, my indebtedness and gratitude to all the patients who are the cornerstone of my study, and who most willingly and selflessly subjected themselves to this study for the sake of benefit to their community.

CONTENTS

A STUDY ON ROLE OF ANATOMICAL OBSTRUCTION IN PATHOGENESIS OF CHRONIC SINUSITIS

ABSTRACT

This is a study about the role of obstructive anatomic variations in the osteomeatal complex of the nasal cavity leading to the development of chronic sinusitis, conducted in a tertiary care centre between July2011 to November2013. About 50 patients were studied for the frequency of occurrence of main anatomical variants like nasal septum deviation, pneumatised middle turbinate, paradoxically curved middle turbinate and infraorbital ethmoid air cell(haller cell), which was compared with a control group of 50 patients on the basis of nasal symptoms of sinusitis and radiological imaging by CT scan of the paranasal sinuses. All the patients were evaluated for the effectiveness of endoscopic sinus surgery by evaluating for the improvement of symptoms and patency of the sinus drainage. Nasal septum deviation followed by pneumatised middle turbinate and paradoxical middle turbinate was the commonly observed anatomical variation at the osteomeatal complex and there was significantly good improvement of the disease symptoms and quality of life following endoscopic sinus surgery.

INTRODUCTION

Sinusitis is a commonly diagnosed condition in the general population. As the inflammation nearly always involves the nasal mucosa also, it is now more aptly called as “Rhinosinusitis”. It is a Group of disorders characterised by inflammation of the mucosa of nose and paranasal sinuses of at least 12 consecutive weeks duration. Patients with chronic Rhinosinusitis may have acute flareups, in such conditions it is called acute exacerbation of chronic sinusitis.

The Rhinosinusitis Task Force of the American Academy of Otolaryngology-Head and Neck Surgery has classified the chronic rhinosinusitis based on the duration of the symptoms. They are 1) Acute (ARS) 7 days to <4 week, 2) sub acute 4 – 12 week, 3) chronic (CRS) >12 week and 4) and acute exacerbation of chronic, if there is acute worsening of chronic sinusitis with return to base line.

The etiological factors for chronic sinusitis can be broadly divided into three overlapping groups: genetic or physiologic factors, environmental factors and structural (obstructive) factors.

Here we assess the role of anatomical obstructions (structural factors) in pathogenesis of chronic sinusitis, based on symptoms and radiological findings of the patients. The occurrence of major anatomical

variations in the nose like nasal septal deviation, concha bullosa, paradoxical middle turbinate and haller cell, leading to chronic sinusitis have been analysed. Symptomatic patients with CT evidence of chronic sinusitis will be subjected to undergo functional endoscopic sinus surgery and correction of the anatomical obstruction, which is causing the disease.

AIMS AND OBJECTIVES

AIMS OF STUDY

1) To study the role of major anatomical obstructions causing chronic Sinusitis.

2) To find the prevalence of major anatomical variations in patients with Chronic sinusitis.

3) To find out the effectiveness of surgical correction of anatomical Obstruction in treatment of chronic sinusitis.

REVIEW OF LITERATURE

Chronic Rhinosinusitis (CRS) is a spectrum of diseases characterised by Inflammation of mucosa of the nose and paranasal sinuses of more than 12 consecutive weeks duration[1,2].

Lanza and kennedy reported the now well accepted classification of the Rhinosinusitis formed by the Rhinosinusitis Task force of the American academy of Otolaryngology-Head and Neck surgery in 1997.[3,4]

This classification relies on two major criteria that help to identify whether or not a patient has rhinosinusitis primarily on the basis of symptoms and then to classify rhinosinusitis types based primarily on temporal time frames from the onset of symptoms.

The symptoms of rhinosinusitis are divided into major and minor categories. Patients with two major factors or one major and two minor factors, are diagnosed to have the disease.[4,6]

Major Symptoms/Signs

Facial pain/pressure

Facial congestion/fullness

Nasal obstruction/blockage

Nasal discharge/purulence, discolored posterior drainage

Hyposmia/anosmia

Purulent discharge on nasal examination

Fever (in acute cases only)

Minor Symptoms/Signs

Headache

Fever (non acute rhinosinusitis)

Halitosis

Fatigue

Tooth pain

Cough

Ear pain/pressure/fullness

Many of the etiological factors have been postulated for the Development of rhinosinusitis, which can be broadly classified in to Genetic/physiological factors, environmental factors and structural factors.[5]

Major structural factors (anatomical variants) in the nose leading to sinus obstruction and inflammation are septal deviation, paradoxical middle turbinates, concha bullosa, and haller's cell.[7]

Anatomy of lateral wall of nose

Embryology:

The paranasal sinuses develop from the ridges formed in the lateral nasal wall called ethmoturbinals[8]. During 8th week of development a series of 5 to 6 ridges appear , but after regression and fusion only 3 to 4 ridges persist. The first ethmoturbinals regresses at the time of development and its ascending part becomes the agger nasi and the descending part form the uncinate process. The second ethmoturbinals form the middle turbinate and the third ethmoturbinal form the superior turbinate. The 4th and 5th ethmoturbinals join to form the supreme turbinate.

There are primary furrows that lie between the ethmoturbinals, that forms the various nasal meati and recesses. The first primary furrow lies between the first and second ethmoturbinals. Its descending part forms the ethmoid infundibulum, hiatus semilunaris, and middle meatus, and its ascending part contribute to the formation of frontal recess. The primordial maxillary sinus develops from the inferior aspect of ethmoid infundibulum.[9-11] The second and third primary furrows form the superior meatus and supreme meatus respectively.

The ethmoturbinals during their development from the lateral nasal wall form bony structures that attach the ethmoid complex to lamina papyracea and skull base. The furrows then develop in to numerous prerecesses and recesses and contribute to the complex pneumatisation of the ethmoid bone. As the development progresses, secondary evaginations and invaginations form from the lateral nasal wall between the maxilla and ethmoturbinals.[12,13] The frontal sinus might have developed from direct extension of frontal recess, one or more anterior ethmoid cell or from the anterior aspect of the ethmoid infundibulum.[14,15]

Bighman et al highlighted the role of a cartilaginous nasal capsule that surround the developing nasal cavity in addition to the ridges and furrows.[16] He observed that all three turbinates in the lateral nasal wall develop from this cartilaginous nasal capsule.[17] Wang et al also pointed out the role of cartilaginous capsule. In their view they postulated that all four pairs of paranasal sinuses develop from the cartilaginous capsule out

pouching of the nasal mucous membrane is only a secondary phenomenon rather than the primary force in sinonasal development.

Sphenoid sinus develop as the nasal mucosa invaginates in to the posterior portion of the cartilaginous nasal capsule during the third month of fetal development. This invagination expands to form a pouch like

cavity referred as cartilaginous cupolar recess.[18] In later months of fetal life the surrounding wall of this cartilage get ossified and forms the so called ossiculum bertini. In second and third years this ossiculum bertini becomes attached to the body of sphenoid after its intervening cartilage is resorbed.

Sinus pneumatisation is completed between 9 - 12 years in majority of human subjects.[19,20]

The ethmoid sinus is commonly called ‘the labyrinth’ because of its complexity and interpersonal variability. Many otorhinolaryngologists and surgeons have decreased the complexity of the ethmoid sinus by dividing it in to many series of lamellae on the basis of embryological development. The first is the uncinate process, second is the ethmoid bulla, third being the basal or ground lamella and fourth is that of the superior turbinate.

The basal lamella of the middle turbinate is special, that it divides the ethmoid cells in to two groups i.e anterior and posterior. The lamellae are almost constant feature between the human subjects, and so their intraoperative recognition is utmost important to help the surgeon maintaining the correct orientation.

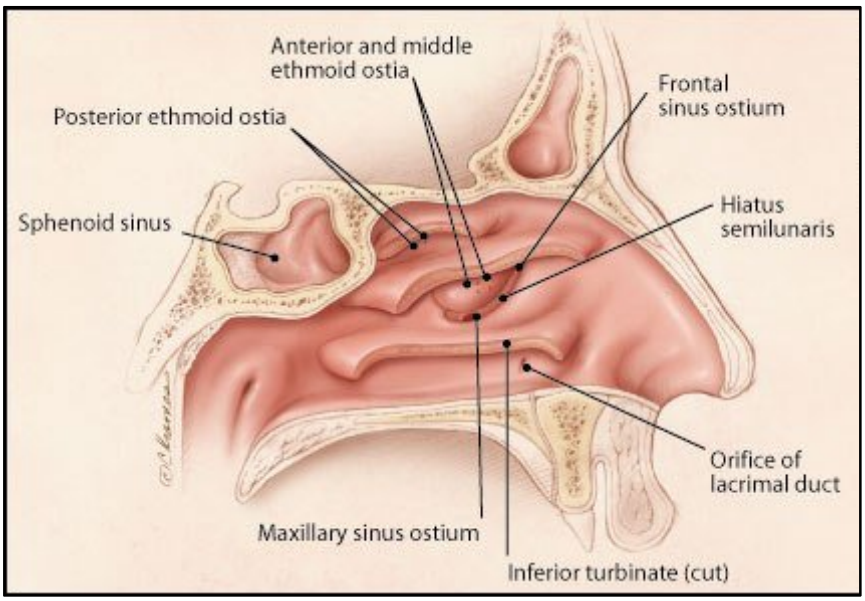

Anatomy of Lateral Wall of Nose

Anterior ethmoid

During anterior rhinoscopy a prominence can be noticed immediately anterior to the middle turbinate's attachment in to the lateral wall. This is called agger nasi. In Latin language, agger means mound or eminence, nasi means nose. This is a constant feature on nasal examination and in most but not all cases, it gets pneumatised from an anterior ethmoid cell called agger nasi cell. The agger nasi cell usually takes its origin from the superior part of the ethmoid infundibulum or from the frontal recess region.[8,15,21,22,23]The boundaries of agger nasi cell

are, anteriorly frontal process of maxilla, superiorly frontal recess, anterolaterally nasal bones, and inferomedially lacrimal bone.

The agger nasi is closely related to the lacrimal bone, causing epiphora in many patients with sinus disease. It is also important in frontal sinus disease and its management. The pneumatisation of agger nasi may extend inferomedially to pneumatise the uncinate process.[24,25]

Uncinate process

The uncinate process is sagittally oriented, almost paralleling the ethmoid bulla. It is 3-4 mm wide and 1.5-2 cm in length. Its posterior margin has no bony attachments and is free through most of its course. The hiatus semilunaris lies directly behind its posterior margin. Anteriorly and superiorly it attaches to the ethmoidal crest of the maxilla, just inferior to anterior attachment of middle turbinate on to the lateral wall of nose. Directly inferior to this it attaches with the posterior portion of the lacrimal bone.

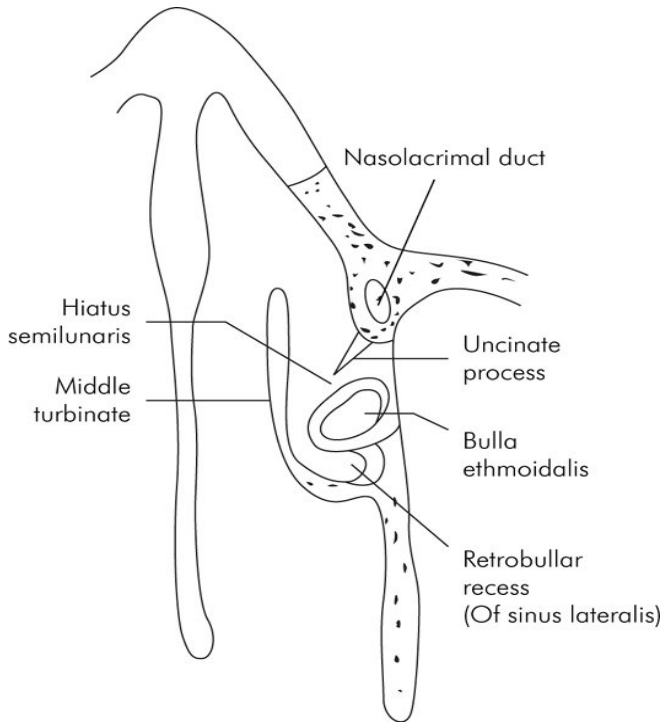

Axial view of middle turbinate and uncinate with surrounding structures.

Posteroinferiorly the uncinate process fuses to the ethmoidal process of inferior turbinate. The attachment to the inferior turbinate is thick and often it splits or widen to attach with the stout inferior turbinate bone., the uncinate gives off a small bony projection at its posterior and superior end to attach to the lamina perpendicularis of the palatine bone.[8,26]

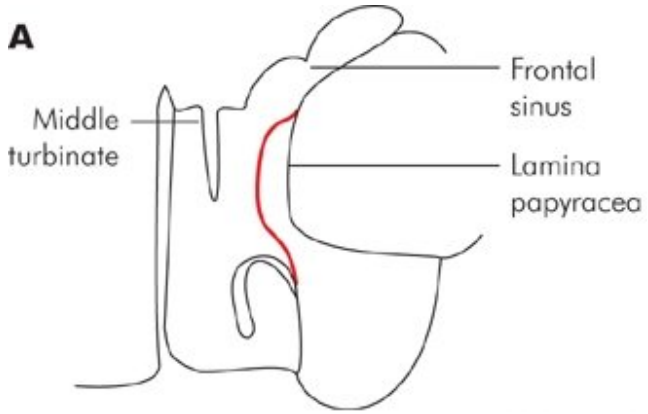

1. Uncinate attached to lamina papyracea

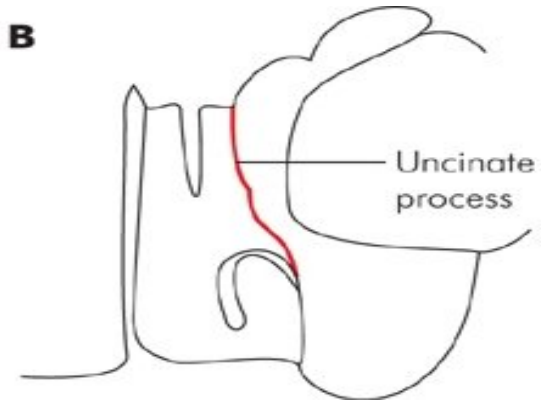

2. Uncinate attached to skull base

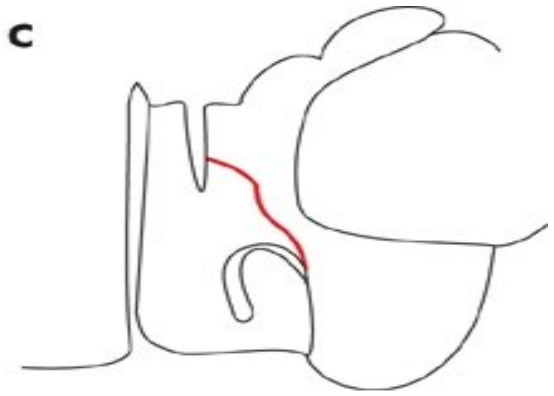

3. Unicinate attached to middle turbinate

The uncinate does not have any bony attachments anterior and posterior to its attachment to the inferior turbinate. At this site the lateral wall of nose is devoid of bone and contain only mucosa of the middle meatus, sinus mucosa and a thin connective tissue layer in between. They are referred to as anterior and posterior fontanelles.

The posterior fontanelle on the lateral nasal wall is much larger and distinct than the anterior fontanelle and also, it contains an opening in to the maxillary sinus, the called the accessory ostium of the maxillary sinus.. It can be mistaken for the natural ostium of the sinus and it is seen in 20 – 25% of the population.[27] The superior attachment of the uncinate varies in different people. Most of the time it bends laterally to get attached to the laminapapyracea of the orbit. It may also attach centrally to the skull base or in the medial aspect to the superior part of the vertical lamella of the middle turbinate.[28] The uncinate forms the anterior and medial boundary of the ethmoid infundibulum.

The uncinate may get displaced laterally against the orbit, as seen in a case of hypoplasia of maxillary sinus, or it may be displaced medially as which occur in cases of extensive polyposis within the ethmoid infundibulum.

In rare cases the uncinate is so medialised that it recurves on itself to give the appearance of a double middle turbinate. The uncinate process can be pneumatised also In a small percentage of patients.[24,25]

Ethmoid Bulla

The ethmoid bulla is the largest and most constant of the anterior ethmoid air cells. It is located within the middle meatus anterior to the basal lamella of the middle turbinate and directly posterior to the uncinate process. The cell has its base on the laminapapyracea and projects in to the middle meatus medially. The cell has the appearance of a bulla, which is a hollow, thin walled, rounded bony prominence.

The anterior wall of the ethmoid bulla can extend to the skull base and form the posterior limit of frontal recess superiorly. The bulla can blend with the ground lamella posteriorly. Anatomic variations of the ethmoid bulla may occur. The ethmoid bulla can be one of the largest ethmoid air cells and can lie in the lower aspect of the middle meatus when highly pneumatised. In certain cases, a low lying bulla may potentially narrow the infundibulum and thus, impair mucociliary transport and ventilation. The ethmoid bulla is formed by pneumatisation of, and behind, the second basal lamella or bulla lamella. When unpneumatised, a bony projection from the laminapapyracea may result

and it is referred to as the torus lateralis[8]. This is estimated to occur in approximately 8% of patients.

Hiatus Semilunaris

Hiatus semilunaris is a Latin word which can be translated as hiatus means gap, cleft or passage way and semilunaris means crescent shaped. It is the crescent shaped cleft in between the posterior free margin of the uncinate process and the anterior wall of ethmoid bulla. It is a two dimensional sagittally oriented cleft through which middle meatus communicate with the ethmoid infundibulum. This cleft is further defined as the hiatus semilunaris inferior by Grunwald to differentiate it from smaller less defined hiatus semilunaris superior.[8] Hiatus semilunaris superior is a cleft between posterior wall of the ethmoid bulla and ground lamella of the middle turbinate through which the middle meatus communicate with the lateral sinus.

Ethmoidal infundibulum

Strictly speaking, infundibulum means funnel shaped structure or passage.[29] It is a funnel - shaped passage through which the secretions from various anterior ethmoid cells, maxillary sinus, and sometimes frontal sinus, are transported to the middle meatus. Situated in the

anterior ethmoid region, the ethmoidal infundibulum is a three dimensional space, bordered in medial aspect by uncinate process, by laminapapyracea laterally, anterosuoeriorly by frontal process of maxilla and superolaterally by lacrimal bone. In a sagittal perspective, the ethmoid infundibulum is curved corresponding to the course of uncinate and anterior wall of ethmoid bulla.

The ethmoid infundibulum and middle meatus communicate each other through the hiatus semilunaris. Viewing in a coronal section immediately above the level of maxillary ostia, the maxillary ostium forms the inferior boundary, lateral boundary is the lamina papyracea and medial boundary of the ethmoid infundibulum is formed by the uncinate process.

Anterior wall of the ethmoid bulla forms the superior boundary, and the superomedial boundary is formed by hiatus semilunaris.

The importance of the superior aspect of the ethmoid infundibulum is its close relationship with the frontal recess. This relationship of the infundibulum and frontal recess is to a large extent determined by the uncinate process attachment superiorly. Most of the time the uncinate bends laterally and get attached to the laminapapyracea, thus forming the

recessus terminalis, which is the superior boundary of the ethmoidal infundibulum.

The frontal recess may drain medial to uncinate process when the uncinate attaches to the laminapapyracea laterally. The uncinate can attach alternatively to the ethmoid roof or insert in to the middle turbinate.

The frontal recess will be contiguous with the ethmoidal infundibulum in these cases.

Several variations exist in the attachment of the uncinate and relationship of the ethmoid infundibulum and frontal recess. The inferior aspect of the infundibulum is also quite important due to its relationship to the maxillary ostium. The natural ostium of the maxillary sinus is commonly located in the posteroinferior one-third of the ethmoidal infundibulum. The most inferoposterior portion of the infundibulum terminates as it drains in to the middle meatus and blends with the posterior fontanelle mucosa.

Sinus Lateralis (Suprabullar and Retrobullar Recesses)

The sinus lateralis is a variable air space, that lies behind and above the ethmoid bulla and is sometimes also referred to as the

suprabullar and retrobullar recesses. This space was first described by Grunwald and may be highly developed, and in such cases is bordered by the lamina papyracea laterally, superiorly the ethmoid roof, the basal lamella of the middle turbinate posteriorly and the ethmoid bulla roof and posterior wall inferiorly and anteriorly.

The sinus lateralis lies anterior to the middle turbinate basal lamella, and thus it is anterior ethmoid in location. However it is not considered an anterior ethmoid air cell as it does not have a single ostia for ventilation and drainage. Instead, it is considered as a recess that communicate with middle meatus via hiatus semilunaris superior.

Stammberger pointed out that if the ethmoid bulla do not extend to the base of skull to form the posterior wall of the frontal recess, the sinus lateralis can communicate with the frontal recess and the hiatus semilunaris inferior.[8,26] The ethmoid bulla often opens posteriorly, in to the sinus lateralis.

Osteomeatal complex

The term osteomeatal complex has been widely described and incorporated into our literature. It was first coined by Naumann.[30] It should be stressed that the osteomeatal complex is a functional unit

rather than an anatomic structure. It refers to the physiologic arrangement of structures into which the frontal, maxillary, and anterior ethmoid sinuses drain.

Anatomically, this corresponds to the area of the ethmoid infundibulum and its surrounding structures**.**

It refers to the physiologic arrangement of structures into which the frontal, maxillary, and anterior ethmoid sinuses drain. Anatomically, this corresponds to the area of the ethmoid infundibulum and its surrounding structures.

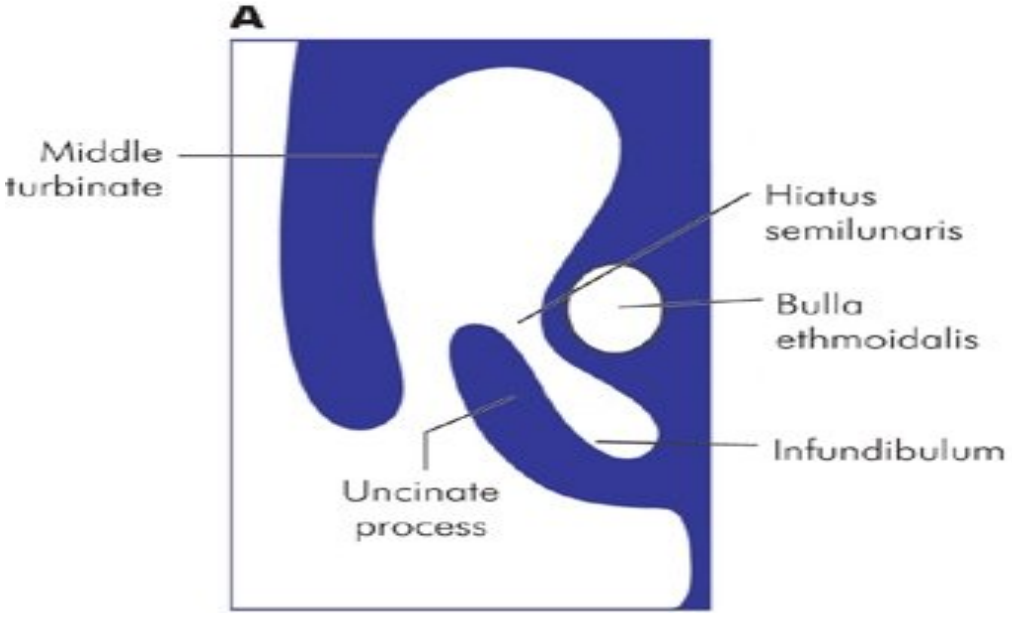

Osteomeatal Complex

It is crucial to have a good patency of the sinuses for adequate mucociliary function and thus subsequent drainage of the sinuses. The sinonasal mucosa produces about 1 L of mucus per day, which is getting cleared by the mucociliary transport. Obstruction of these ostia of sinuses can lead to fluid accumulation and stagnation, thus creating a moist and hypoxemic environment suitable for the pathogens to grow and flourish.

The Frontal Recess and Sinus

The frontal sinus drains in to the middle meatus and so to the nasal cavity through a complex passage described as a 'nasofrontal duct'.

Anatomic dissection reveals that, there is no existence of a true duct. But in an attempt to redefine the nomenclature of this area and to more accurately define the anatomy, the term frontal recess has recommended.

Being the most anterosuperior aspect of the ethmoid sinus, the frontal recess forms a connection with the frontal sinus.[26] The frontal recess boundaries are, laterally by the laminapapyracea, medially by the middle turbinate, anteriorly by the posterior and superior wall of agger nasi cell, the anterior wall of ethmoid bulla posteriorly(when present). If the anterior wall of the ethmoid bulla does not reach the skull base, the

frontal recess can communicate with the suprabullar recess and form a complete posterior wall.

The frontal recess tapers towards internal os of the frontal sinus; and above the os , as the anterior and posterior tables diverge to their respective positions it get widened to form a hourglass-like appearance, with the most narrowed portion being the frontal ostium. The complexity of the anatomy of this region can be better understood when the effect of the surrounding ethmoid cells such as the frontal cell, agger nasi cell, and supraorbital ethmoid cells are taken in to consideration. There is an intimate relationship existing between the frontal recess and agger nasi cell.

Secretions from the frontal sinus used to follow a path through the frontal recess and over the posteromedial surface of the agger nasi cell and thus reaches the nasal cavity. If the frontal recess is relatively narrowed and the agger nasi cell is extensively pneumatised, then the patient may be predisposed to frontal sinusitis.

An extensively pneumatised agger nasi may be mistaken for the frontal recess or frontal sinus during the course of the endoscopic surgery.

The residual posterosuperior wall of the agger nasi cell can be left posteriorly to the ethmoid roof, and iatrogenic stenosis of the frontonasal connection can occur, if a large agger nasi call is mistakenly opened for a frontal sinus.[31]

In addition to the agger nasi cell, there are other ethmoid cells that can have a close relationship with the frontal recess.

According to Van Alyea about 50% of cadaveric specimens studied had anterior ethmoid cells that have encroached in to the frontal sinus, and among these one-third were encroached in to the area of the ostium of frontal sinus. .[32] He called them as ‘frontal cells’.

Schaeffer stated that the anterior ethmoid air cells can pneumatise extending in to the frontal sinus and appear as the sinus has duplicated. Stammberger stated that anterior ethmoid cells can develop from the frontal recess, alongside the frontal sinus, in to the frontal bone. These are called the bulla frontalis’ by Zuckerkandl.[8]

The supraorbital ethmoid cell is another anatomic variation in the region of the frontal recess. Supraorbital ethmoid cells commonly occur from pneumatisation of the orbital plate of the frontal bone by ethmoid air cells. Kasper felt that these cells originated in the third and fourth frontal furrow regions, from which they pneumatised laterally and

superiorly over the orbit in to the orbital plate of frontal bone.[22] Pneumatisation of the orbital plate of bone can also occur from the frontal sinus proper.

Maxillary sinus

The maxillary sinus is being a single chamber, is bounded superiorly by the roof of orbit, inferiorly by the alveolus and dental portion of the maxilla and hard palate, laterally by the zygomatic process, posteriorly by a thin bony plate separating the cavity from the pterygopalatine and infratemporal fossa and medially by the uncinate process, fontanelles and inferior concha.

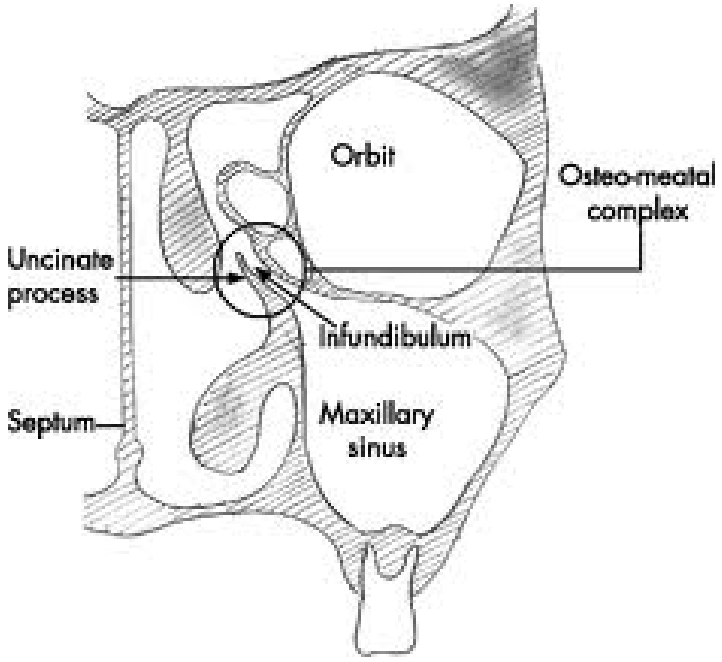

Maxillary sinus

The maxillary sinus ostium is located within the most poster inferior one-third of the infundibulum in 71.8%.[15,27] The most commonly observed anatomical variation in the maxillary sinus region is the infra orbital ethmoid cell or Haller's cell. Haller's cells are felt to arise from the anterior ethmoid in 88% and the posterior ethmoid in 12%.[33]

Another anatomical variation is hypoplasia or atelectasis of the maxillary sinus.[34,35] In which the maxillary sinus is smaller, the surrounding maxillary bone is thicker, and the uncinate process is hypoplastic and lies against the inferomedial orbit, and hence the infundibulum is atelectatic.

Uncinectomy will be more difficult in these patients due to the lateral displacement of the structure and the risk of inadvertent orbital entry due to this displacement against the orbit.

Middle Turbinate

The middle turbinate of the ethmoid bone, which develops from the second ethmoturbinal is having many important features. Anteriorly the turbinate attaches the agger nasi region at the crista ethmoidalis (ethmoidal eminence) on the lateral wall. From here it traverses superiorly and medially to attach vertically to the lateral aspect of cribriform plate. After a variable distance the insertion courses

horizontally along the skull base and inferiorly to attach to the lamina papyracea and medial wall of maxillary sinus.[8] This segment is in a coronal plane and it divides the ethmoidal labrynth in to anterior and posterior groups and is referred to as ground lamella or basal lamella. The posterior aspect of the middle turbinate is having its inferior attachment to the lateral wall at the crista ethmoidalis of the perpendicular process of palatine bone, which lies just anterior to the sphenopalatine foramen.

Posterior Ethmoid Sinus

The posterior ethmoid sinus is a group of 1 to 5 ethmoid air cells, and as they are developmentally derived from the second and third furrows, they drain in to the superior and supreme meati of the lateral nasal wall. The posterior ethmoid sinus is bounded anteriorly by the middle turbinate basal lamella, by the anterior wall of the sphenoid sinus posteriorly, laterally by the laminapapyracea , by the vertical parts of the superior and supreme turbinates and their corresponding meati medially, and superiorly by the roof of ethmoid.

The posterior ethmoid cells, due to their proximity to the skull base and optic nerve have special surgical significance. Anatomic variation in the posterior ethmoid is therefore especially important for surgeons be aware of.

Onodi performed detailed investigations of the variability in posterior ethmoid anatomy, and he specifically highlighted the relationship that most posterior ethmoid cell could have with the optic nerve.[36] Onodi described 38 variations in the relationship of the most posterior ethmoids to the optic nerve, arranging them in to 12 major groups. He stressed that when the most posterior ethmoid cell was highly pneumatised, it could stretch posteriorly along the lamina papyracea in to the anterior wall of sphenoid sinus. When this occurred , the optic nerve which usually considered to border the lateral and superior aspects of the sphenoid sinus, would actually be adjacent to the posterior ethmoid cell. if this anatomic variation is not appreciated , dissection in the posterior ethmoid can result in trauma to the optic nerve and blindness.

Modern endoscopic sinus surgeons began to refer this anatomic variation as Onodi cell.[26] If the sphenoethmoidal cell is large, the carotid canal can bulge in to the posterior ethmoid sinus as well. Onodi cautioned the surgeons not to assume that, to reach the sphenoid sinus, one simply extend the dissection through the limits of the posterior ethmoid. Surgical dissection within the posterior ethmoid should always be oriented in an inferior and medial direction, rather than a superolateral direction, to avoid fatal orbital or cranial injury.

Sphenoid Sinus

The sphenoid sinus is found embedded in to the clivus and is limited posterosuperiorly by the sella turcica. Horizontally situated septations are actually bony septations between the posterior ethmoid sinus and sphenoid sinus and they do not represent septations in the sphenoid sinus. The sphenoid sinus shows great variability in shape and size.

It is of three types:

type 1: Conchal sinus

It is the most primitive and with an incidence of 2-3%. Hence, the sella turcica is totally surrounded by bone and remains totally unexposed to the aerated sinus.

Type 2: Pre sellar pneumatisation

In this type, the posterior half of the sella turcica is surrounded by bone, while the anterior part is pneumatised and has an incidence of approximately 10-24%.

Type 3: Sellar pneumatisation.

It is the commonest type with an incidence of 86%

Physiology Of Mucociliary Clearance

The movement of the mucous blanket is referred to as mucociliary clearance. Inflammatory sinus disease results primarily from the interference of mucociliary clearance caused by the compromise of the osteomeatal channels of the individual sinus cavities. The mucosa of the paranasal sinuses and nasal fossae are lined by ciliated cuboidal epithelium that secretes mucus. The cilia are in a constant motion and act in concert to propel the mucus in each sinus toward the nasopharynx. There are specific pattern of flow for each sinus and they persists even if alternative openings are surgically created in the sinus.[25]

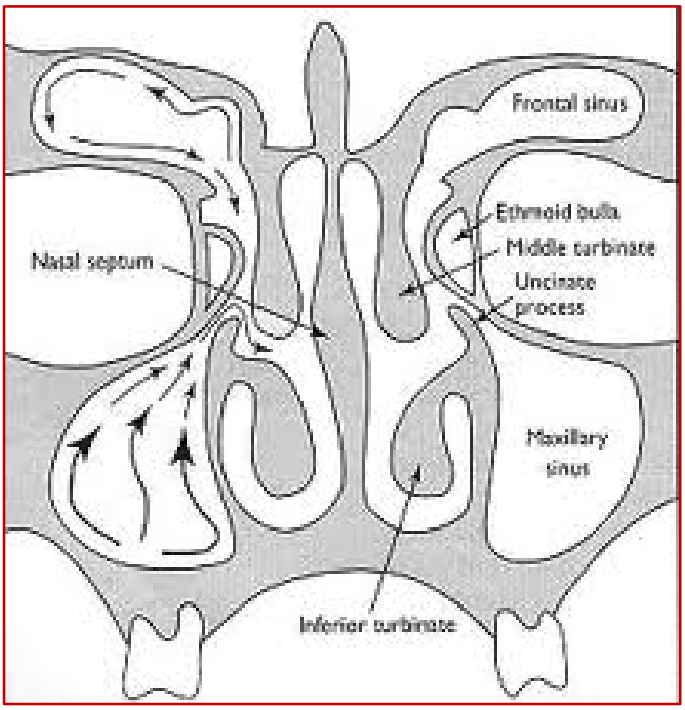

Mucociliary Flow in Maxillary and Frontal sinus

In the maxillary sinus, mucus flow is created centripetally toward the primary ostium. Then the mucus is transported to the hiatus semilunaris through the infundibulum, from where it passes in to the middle meatus and then finally in to the nasopharynx. In the frontal sinus, the mucus flows in to the primary ostium down through the frontal recess and then in to the middle meatus, where it joins the flow from the ipsilateral maxillary sinus.[25]

The sphenoid sinuses and posterior ethmoids clear their mucus in to the spheno-ethmoidal recess. The mucus flow then enters the superior meatus and then to nasopharynx.

CT Scan of Paranasal Sinuses

CT is currently the modality of choice in the evaluation of the paranasal sinuses and adjacent structures. Its ability to optimally display the bone, soft tissue and air provides an accurate picture of both the anatomy and the extend of disease in and around the paranasal sinuses. In contrast to standard radiographs, CT clearly shows the fine bony anatomy of the osteomeatal channels.

Performing the initial ct scan after an adequate course of medical therapy and pre-treatment with sympathomimetic nasal spray 15 minutes prior to scanning in order to eliminate or diminish reversible mucosal inflammation and reduce nasal congestion (mucosal edema), improve the display of fine bony architecture and any irreversible mucosal disease.

Since the osteomeatal unit is best represented in the coronal plane, it is the primary imaging orientation for evaluation of the sinonasal tract. This can be achieved by direct coronal scanning or by reformatting data acquired in the axial plane in to coronal plane images. Coronal study is optimally performed with the patient in the prone position so that any remaining sinus secretions do not obscure the osteomeatal unit. In patients who cannot tolerate prone positioning (children, patients with advanced age,etc.), the hanging head technique can sometimes be

utilized. In this technique, the patient is placed in the supine position and the neck is maximally extended. A pillow is placed under the patient's shoulders to facilitate positioning. The CT gantry is then angled to be perpendicular to the hard palate. However it is not always possible to obtain true direct coronal images with this technique. When direct coronal study becomes difficult due to patient's positioning, spiral scanning or thin section, contiguous axial CT images with coronal reconstructions are performed. Axial images complement the coronal study, particularly when there is severe disease (opacification) of any of the paranasal sinuses and surgical treatment is contemplated. The axial studies are needed, as the posterior walls of the various sinuses are not well seen, if at all, in the coronal plane. Axial images are particularly important in visualizing the frontoethmoid junction and sphenoethmoid recess. For axial scans which are 5mm thick, the orbitomeatal line is taken as reference. The introduction of spiral CT and multidetector CT scanners allowed even more refined reconstruction in planes other than the primary scan plane.

Opacification of osteomeatal unit has been found to predispose patients to the development of sinusitis. Opacification of osteomeatal unit without frontal, maxillary or anterior ethmoid sinus disease is very rare.

Diagnostic nasal endoscopy

The advent of nasal endoscopes has facilitated more accurate diagnosis and proper treatment of sinonasal diseases. Diagnostic nasal endoscopy has become a routine tool in evaluation of sinonasal diseases nowadays.

For conducting a proper diagnostic nasal endoscopy, the nasal mucosa is prepared by using mixture of local anesthetic and decongestant to facilitate surface anesthesia and decongestion within a few minutes. Ideally the nasal endoscopy is done using a 4mm, 30 degree endoscope, and also using 2.7 mm scope in narrow passages. This angulation helps in direct visualization of the nasal cavity and introduction along the axis, hence inadvertent injury to the nasal mucosa is averted. It also helps in adequate visualization of the nasal meatus and the entire nasopharynx.

The procedure is done in three steps as follows;

First pass: visualization of the nasal vestibule, nasopharynx, and inferior meatus by passing the endoscope along the floor of the nasal cavity.

Second pass: evaluation of the sphenoethmoid recess and superior meatus.

Third pass: Examination of the osteomeatal unit.

ANATOMIC VARIATIONS

Deviation of Nasal Septum:

Nasal septum deviation is one of the main causes of anatomical obstruction at the level of middle turbinate in the osteomeatal complex.

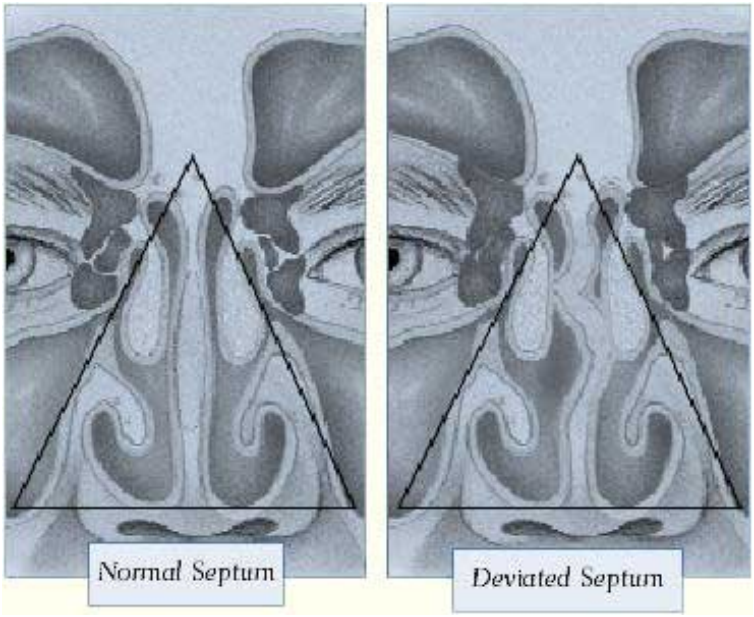

Cottle classified nasal septal deviation in to three types.

1) Simple deviation: It is the most common type. Here there is only a mild deviation with no obstruction.

2) Obstructive type: The deviated nasal septum touches the lateral nasal wall or, but on decongestion with vasoconstrictors the obstruction is relieved due to shrinking of the turbinate.

3) Impaction: There will be a septal spur with gross angulation of the septum leading to severe obstruction, even after decongestion.

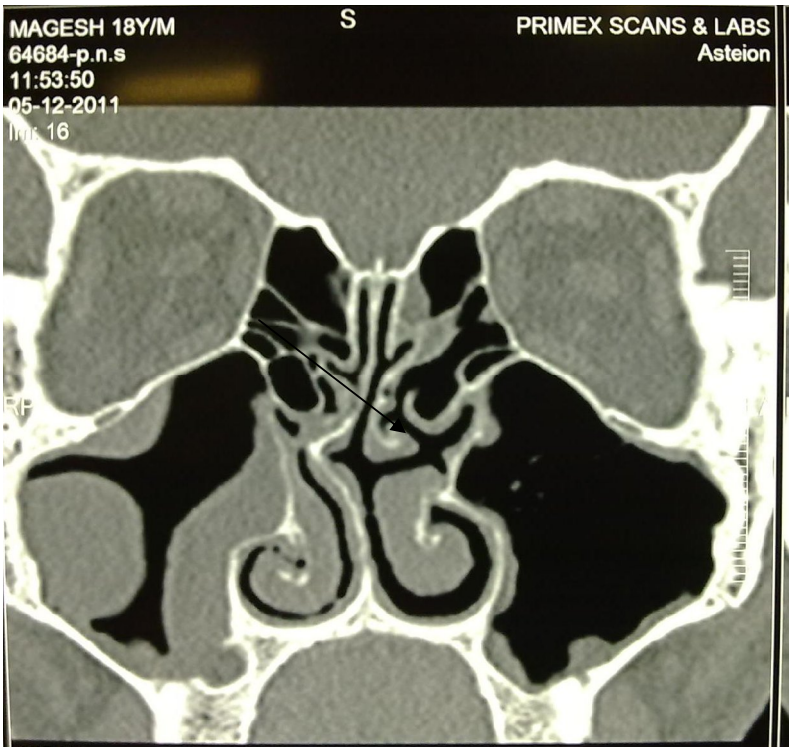

CT scan of a patient shows deviated nasal septum with spur

Concha bullosa:

Concha bullosa is nothing but pneumatisation of the turbinate, usually the middle turbinate and is said to be one of the most common anatomical variations in the nose. Based on the location, Bolger et al[50] classified pneumatisation of the turbinate as lamellar concha bullosa (pneumatisation of the vertical lamella of the turbinate only), bulbous concha bullosa (pneumatisation of the bulbous part only), and extensive

concha bullosa (pneumatisation of the whole part). There are many studies in the literature suggesting the role of concha bullosa in the etiology of sinus disease. If there is significant expansion of the concha, it leads to compression of the uncinate process on to the lateral wall of nose leading to obstruction of the osteo-meatal complex and ethmoid infundibulum.

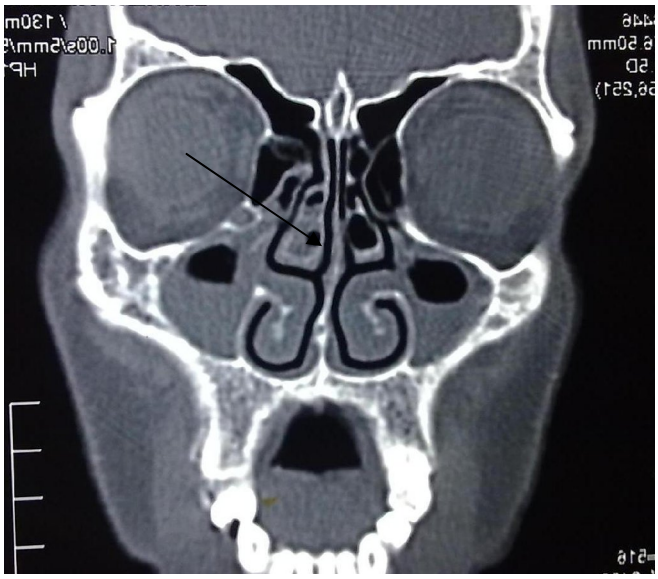

Coronal CT scan shows concha bullosa leading to maxillary sinusitis

There is disagreement in the literature regarding the origin of middle turbinate pneumatisation. The proposed areas from which the middle turbinate can get pneumatised are, anterior ethmoid, posterior ethmoid, and frontal recess.[37,38,39] Additionally, pneumatisation from the

superior meatus is said to be responsible for the pneumatisation of the vertical lamellar of the middle turbinate.

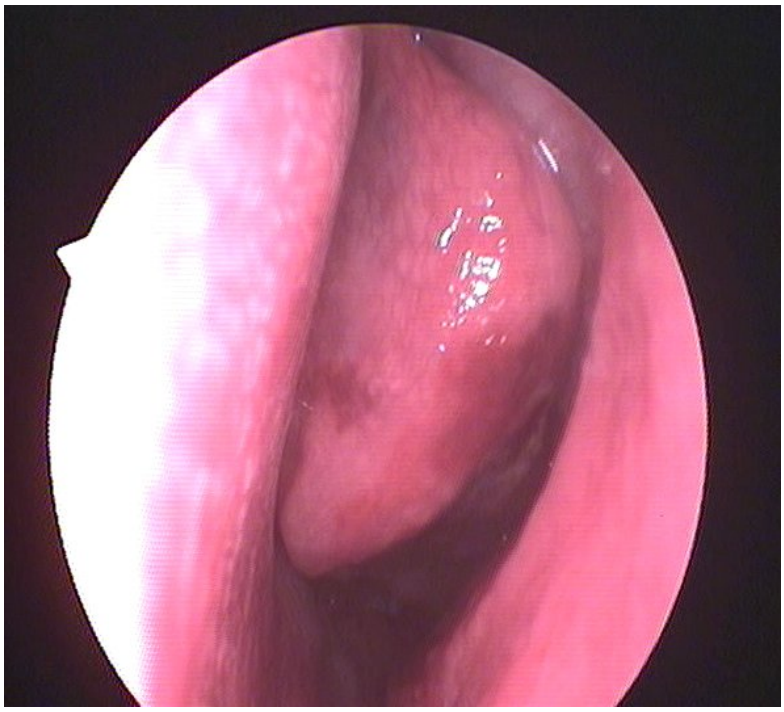

Endoscopic picture of Concha bullosa

Paradoxical middle turbinate:

Paradoxical turbinate is another anatomical variation of the nasal cavity leading to obstruction and chronic sinusitis. Middle turbinate is said to be paradoxical, if it is concave medially rather than laterally. Usually paradoxical turbinate occurs where the mucosa is hyperplastic. This mucosal overgrowth causes the mucosa to buckle and fold inwards,

with the resultant curvature pointing to the septum. An excessively curved paradoxical turbinate can compresses the uncinate process leading to obstruction of the osteo-meatal complex.

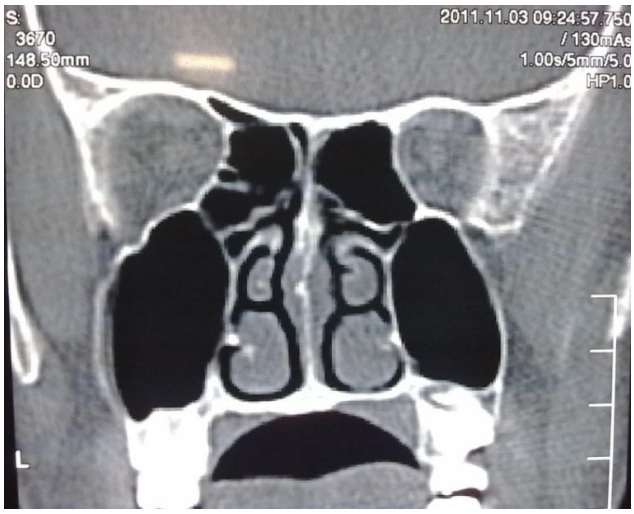

Coronal CT scan showing paradoxical middle turbinates.

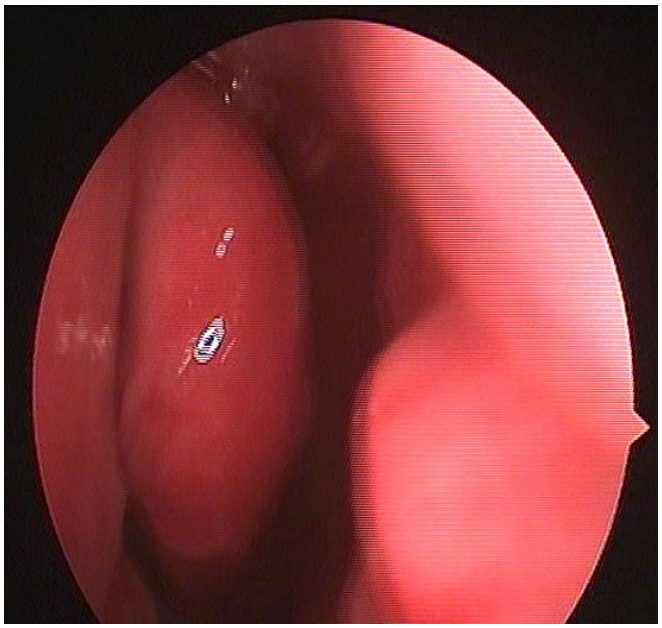

Endoscopic picture of paradoxical middle turbinates

Haller's cell:

Haller was an anatomist who described the "ethmoidal cell which Excavates the os planum and os maxillare, outwardly continuing from the ethmoid labyrinth capsule".[40] The cell is actually an ethmoid air cell that pneumatises in to the floor of the orbit or roof of the maxillary sinus, inferior and lateral to the ethmoidal bulla, closely related to the ethmoid infundibulum and maxillary sinus ostium.

Haller's cells are thought to originate from the anterior ethmoid in 88% and posterior ethmoid in 12%. A variety of terms have been used to Refer to Haller's cell, including the maxilla-orbital cells, the maxilla-ethmoidal Cell, and orbito-ethmoidal cells.[41, 42] Haller's cells can obstruct osteomeatal complex by their close proximity to the uncinate process.

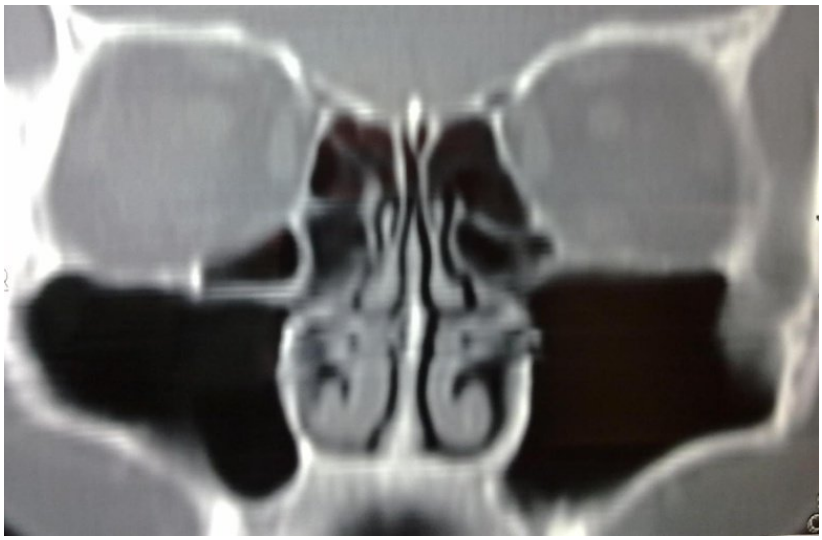

CT scan showing right infra orbital ethmoid cell (Haller's cell)

Clark *et al,* 1989

He studied the incidence of concha bullosa in patients with chronic Sinusitis and found that, 33% of patients with sinusitis had a concha bullosa and 11% in the control group($p<0.001$), in their radiological study.

Bolger *et al,* 1991

He studied the sinus scans of the patients which was taken for inus and non-sinus complaints, and he found no statistical difference in the incidence of true concha bullosa and concha bullosa that involves the vertical part only. But he noticed bulbous concha bullosa in 35.3% of the scans of patients with rhinitis or sinusitis as compared to 13.9% in the control group.

Yousem *et al,* 1991

He studied sinus scans of the patients with sinus and non- sinus complaints and found that there was no higher risk of having sinusitis in the presence of a concha bullosa. So he concluded that most of the concha bullosa were small and did not cause significant narrowing and obstruction at the osteomeatal complex leading to sinusitis.

Scribano *et al*, 1993

He observed in his study of CT scans that, maxillary sinusitis was more in patients with a concha bullosa obstructing the osteomeatal complex than in those, whose concha bullosa does not cause obstruction at the osteomeatal complex.

Liu *et al*, 1998

Liu *et al*, in 1998 have demonstrated that when the size of the anatomical variant is greater at the osteomeatal area, the higher the frequency of association with alteration of the sinus mucosa and sinusitis.

Kennedy *et al*, 1998

kennedy *et al* reported the incidence of infra orbital ethmoid cell (Haller's cell) as 10% after studying the coronal CT scan of the patients with or without sinus problems.

Ameri *et al*, 2001

He carried out a case control study on 148 patients with chronic sinusitis due to anatomical variations in the nose. Deviated nasal septum

and concha bullosa were the two anatomic variants significantly associated with sinusitis in his study.

Talaiepour *et al,* 2004

He analyzed the CT scan of 143 patients presented to the hospital with a clinical diagnosis of chronic sinusitis and found out the frequency of anatomical variants among them. The frequency of major anatomic variants were : Aggar nasi cell in 56.7%, haller cell in 3.5%, nasal septum deviation 63%, and concha bullosa 35%.

M. Adeel, M. S. A. Rajput, S. Akhter*, et al*.,2011

They studied the CT scan of 87 patients presented to the hospital with sinonasal symptoms and analyzed the presence of anatomical variations among them. There were no anatomical variants in 37 scans. 16 scans showed single variation, while 18 showed two and 6 scans showed three variations in an individual patient. Nasal septum deviation was the most commonly observed variation followed by concha bullosa and paradoxical middle turbinate.

Alkire BC, Bhattacharrya N *et al*

They studied the CT scan of 37 patients with recurrent acute rhinosinusitis against 47 controls who underwent CT scan for some other

reasons. CT scans were analyzed for the presence of Haller cells, septal spur and concha bullosa. There was more anatomical variations in the study group, but was not statistically significant.

MATERIALS AND METHODS

Patients with chronic sinusitis having anatomical obstruction in their coronal CT of paranasal sinuses, in the age group of 18 to 45 were selected against a control group of population having anatomical obstruction in their scans with no sinusitis. There was 50 patients in the study group and 50 patients in the control group. Patients with CT scans taken for other reasons (eg: faciomaxillary trauma) who were having any of the anatomical variations in the nose were taken as the control group.

Patients in the study group were selected after proper history taking and clinical examination. All the patients having symptoms suggestive of chronic sinusitis were subjected to take coronal CT of the paranasal sinuses. All of them further subjected to undergo a diagnostic nasal endoscopic examination.

As septal deviation is a rule rather than an exception in the population, only Cottle's type 2 (obstruction) and type 3 (impaction) were taken in to consideration while studying its prevalence.

All the patients in the study group underwent Functional Endoscopic Sinus Surgery (FESS) and correction of the anatomical

obstruction as the definitive treatment for their complaints. They were followed up 1 week, 2 week, 1 month, 3 month and 6 months post operative period by nasal endoscopic examination for disease clearance and improvement of symptoms.

Study period

From March 2012 to November 2013 at Govt. Stanley medical college.

Inclusion criteria

1. Patients with symptoms of chronic sinusitis (major symptoms)
2. Symptoms present for more than 3 months
3. Age 18-45 years
4. Coronal CT scan of paranasal sinuses showing features of chronic sinusitis
5. Coronal CT scan of paranasal sinuses shows anatomical variation at OMC leading to obstruction and sinusitis.
6. No previous nasal surgeries in the past.
7. No evidence local sepsis from oral cavity and oropharynx.
8. No history suggestive of allergic rhinitis

Exclusion criteria

1. symptoms of chronic sinusitis for less than 3 months
2. Age <18 or >45 years
3. Symptoms of chronic sinusitis with no CT changes
4. Coronal CT scan not showing anatomical obstruction at OMC
5. History of previous nasal surgery
6. Evidence of focal sepsis from oral cavity or oropharynx
7. Patients with allergic rhinitis.

Method of study

Step 1: Patients with symptoms of chronic sinusitis were examined clinically- anterior rhinoscopy.

Step 2: All these patients will be advised to take coronal CT scan of paranasal sinuses

Step 3: Patients whose CT scan shows evidence of sinusitis and anatomical obstruction at OMC were subjected to diagnostic nasal endoscopy.

Step 4: Patients with chronic sinusitis due to anatomical obstruction at OMC were subjected to undergo Functional Endoscopic

Sinus Surgery (FESS) along with correction of the anatomical variation.

Step 5: Postoperatively all those patients were followed up at 1st week, 2nd week, 4th week, 3rd month and 6th month with nasal endoscopic examination by two criteria i.e

i. disease clearance

ii. improvement of symptoms

Surgical correction of anatomical obstruction

Patients with deviated nasal septum were corrected of their obstruction either by septoplasty or submucous resection(SMR) operation, according to the type of deviation i.e anterior or posterior. The procedure was done under general anesthesia or local anesthesia.

First infiltration is given with a pre mixed solution of 2% lignocain with adrenalin, 1: 100000 concentration on both sides of the cartilaginous and bony septum. Then Freer's hemitransfixation or Killian's incision is put according to the type of the deviation. In septoplasty mucoperichondrial flap is elevated on one side and mucoperiosteal flap elevated on both sides.

Then deviated bony septum is removed and cartilage repositioned after trimming the lower edge.

In submucous resection (SMR), mucoperichondrial and mucoperiosteal flaps elevated on both sides of the nasal septum and as much as the bony and cartilaginous septum is removed as is needed to correct the deviation. Then flaps are repositioned and sutured.

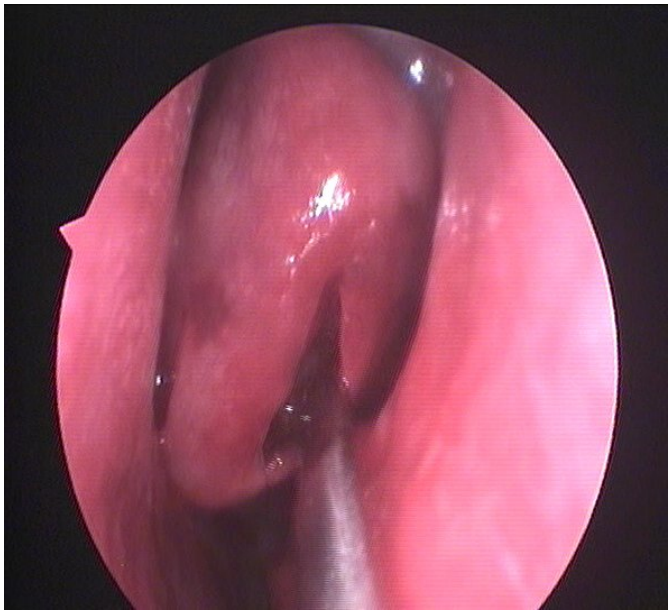

Picture showing surgical correction of concha bullosa

Patients with concha bullosa, corrected with conchoplasty. A concha bullosa is having a medial and lateral lamella. After packing the nose with topical anesthetic and decongestant medication pre operatively, infiltration with pre formed solution is given in the axilla of middle

turbinate as well as near the posterior end of the middle turbinate. Then using sickle knife concha bullosa is incised over the anterior wall and the lateral lamella is removed, after separating from the mucosa. This will relieve the obstruction at OMC.

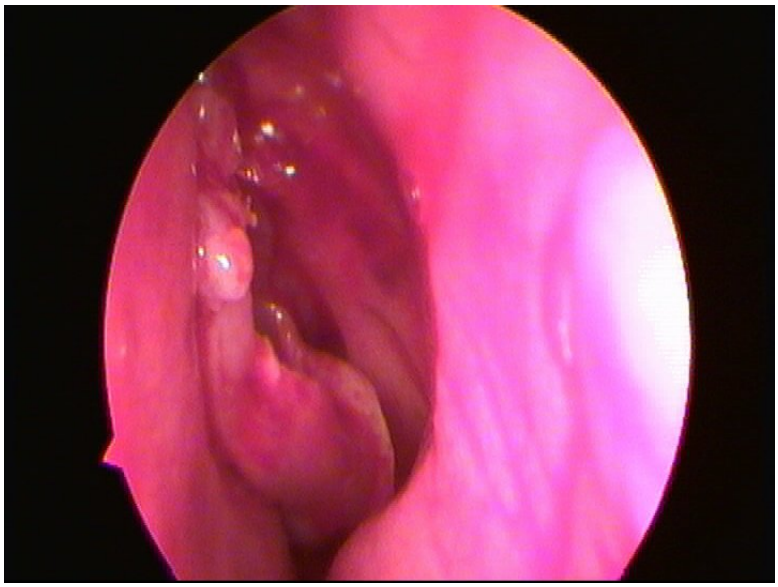

Endoscopic view of middle turbinate after correcting concha bullosa

A paradoxical middle turbinate causing severe obstruction to the drainage of the sinuses was dealt with partial middle turbinectomy. After preoperative anesthetic and decongestant packing infiltration is given with premixed anesthetic solution over the middle turbinate. Then a cut is made with turbinate scissors back for about 18mm from the anterior end and partially freed piece of turbinate fractured downwards. It is then possible to snare off appropriate amount to open up the middle meatus.

Functional Endoscopic Sinus Surgery

The initial understanding that drainage of the diseased sinuses alone by functional endoscopic sinus surgery, is sufficient for resolution of the disease, has currently modified to some extend based on the new understanding of the disease process. But the concept that surgery should extend one stage beyond the diseased mucosa, detected at the time of surgery or by CT scan, remains unchanged. So simply draining the diseased sinuses will be insufficient in chronic diseases.

Post operative close endoscopic studies has revealed that most of the time disease persists in localized areas and that it tends to recur at the same site even if the diseased mucosa is removed. But it typically resolves when the underlying diseased bone is removed. So it has been postulated that the underlying bone may be an important factor in the disease process, more so in case of chronic sinusitis. So wherever possible the underlying osteitic bony septations have to be removed completely during the surgery.

Steps of the procedure

All cases of endoscopic sinus surgery were done under general anesthesia with controlled hypotension after getting informed written consent from the patients. The nose is packed with 4% lignocain with adrenalin (1:100000) , 20 minutes prior to the surgery. The procedure was done using 4mm, zero degree endoscope and camera connecting to the monitor.

1. **Uncinectomy:**

The site of attachment of the uncinate on the lateral wall of nose is identified. Then the sickle knife is used to remove the uncinate process as close as possible to its attachment to the posterior edge of the lacrimal duct ridge. The knife is moved parallel to the lateral nasal wall with sawing action from anterosuperior to posteroinferior direction, taking care not to injure the lamina papyracea. The uncinate is then removed using a blakesley forceps. Uncinectomy can also be done using a back biting forceps.

2. **Middle meatal maxillary antrostomy**:

The natural ostium of the maxillary sinus is best identified by locating the inferior cut edge of the uncinate process and displacing it

medially. The ostium can then be palpated using a ball-tipped probe. If the ostium is patent and the disease is limited, then removal of some additional uncinate only is required.

The maxillary sinus ostium is enlarged by extending the posterior wall of the ostium to the posterior fontanelle. However tissue should not be removed circumferentially to avoid stenosis of the ostium.

Tissue is also removed anteriorly using a back biting forceps or punch, taking care not to injure the nasolacrimal duct, which lie anterior to the ostium and uncinate process.

There are many theoretical consideration regarding the size of the antrostomy to be performed. Experimental studies have demonstrated that, too much exposure of the maxillary sinus mucosa to air flow resulted in slowing of mucosal clearance. Hence ideally the ostium of maxillary sinus and its mucosa should remain protected from airflow. Hence there is a theoretical advantage to keep the surgically created ostium small, except in few cases like diffuse chronic sinusitis of long duration, or when there is evidence of osteitis in CT or during the time of surgery, in such cases it wise to do a wide middle meatal antrostomy.

3. Frontal sinusotomy:

Frontal sinus is notorious for persistent and recurrent disease after surgery. The two most common cause of disease in frontal sinus is, first displacement of the uncinate process medially due to the presence of infundibular disease, leading to obstruction of the frontal recess. Secondly displacement of the frontal sinus ostium posteriorly due to an enlarged agger nasi cell.

Frontal sinusitis caused by infundibular disease is treated by opening the frontal recess after meticulous removal of the uncinate process.

4. Ethmoidectomy:

Nasal obstruction, postnasal discharge and nasal congestion and are the most common symptoms of ethmoid sinusitis. The ethmoidal bulla is infractured in its medial aspect using a blakesley forceps and the residual bony portions are removed with a forceps or a curette. The medial orbital wall is identified from the starting itself to ensure lateral positioning during the surgery. After removal of the bulla, the retrobullar and suprabullar recesses are visualized with the basal lamella.

If the posterior ethmoid cells are to be opened, the basal lamella is perforated just above its horizontal part. Then the remaining portions are removed superiorly and laterally using a through cutting forceps. Then the intercellular bony partitions are removed carefully between the posterior ethmoid cells. The posterior most ethmoid cell is identified by its pyramidal shape with its apex pointing posteriorly, laterally and superiorly.

5. Sphenoidotomy:

The safest method of Sphenoidotomy from the ethmoid sinus is to identify the superior meatus and superior turbinate by palpating medial to the middle turbinate and superior turbinate. Then resect the most inferior part of the superior turbinate and palpate the sphenoid ostium to enter the sinus. The ostium is enlarged medially and inferiorly using kerrison’s punch.

Post operative follow up:

All the patient who underwent the surgery was discharged on the second post operative day. Post operative antibiotics were given for all the patients for one week. They were followed up on the end of 1st week, 2nd week , 4th week, 3rd month and 6th month. The outcome of the surgery was assessed by two factors i.e.

1) Improvement of the symptoms and

2) Patency of the drainage of the sinuses.

At the first post operative visit (1st week) , the nose is packed with anesthetic decongestant pack and any blood clots and adhesions are gently removed. After that all patients are instructed to irrigate the nose with normal saline two times a day for 3 – 6 weeks. Mucosa would have formed over the operative area by the end of 3rd week and by the end of 6 weeks after surgery mucociliary flow is reestablished in most of the patients. Results of the surgery are evaluated only after this.

Evaluation of the results of surgery:

Timing of evaluation: As it is always possible for sinus problems to recur, the results of the surgery represent the success rate for a certain time frame.

The mucosa is reestablished and mucociliary function starts by the end of 3rd week, we start evaluating our patients by this time onwards. Many of the patients who had no improvement by the end of 3rd week, did well after 6 weeks or 1 month follow up time.

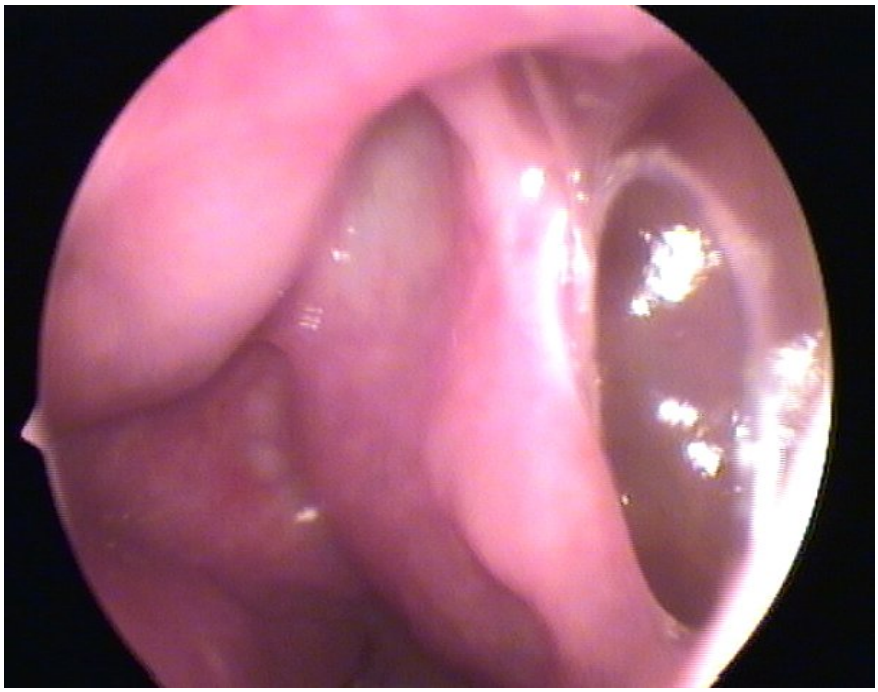

Picture showing patent middle meatal antrostomy after 6 weeks

Method of evaluation:

We considered two main criteria for reporting the success rate of surgery, that is improvement of the symptoms following the surgery and patency of the sinuses on nasal endoscopic examination in each follow up periods. There was contradiction between these two criteria during the evaluation process i.e patients who had no improvement of their symptoms, had their sinuses patent during nasal endoscopic examination.

So we considered symptomatic improvement as the main criteria to rate the success of surgery than nasal endoscopic findings.

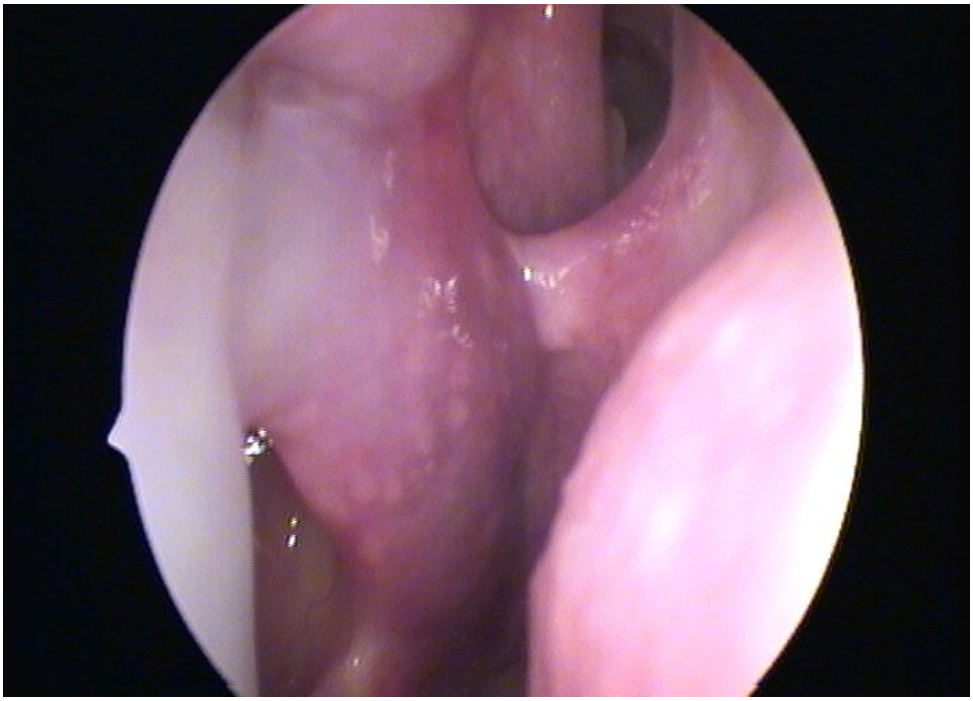

Picture showing post operative ethmoidectomy status with normal mucosa

RESULTS AND OBSERVATIONS

The number of patients involved in the study group was 50, both males and females and that in the control group was also 50. The study results among them were as follows.

Age distribution of patients with chronic sinusitis

Age group	No. of patients
18 – 25 years	18 (36%)
26 – 35 years	17 (34%)
36 – 45 years	15 (30%)

Table 1: Shows the age distribution of patients with chronic sinusitis

Among the 50 patients studied, 18 (36%) patients were of the age group 18 -25 years, 17 (34%) between 26 – 35 years and 15 (30%) between 36 – 45 years.

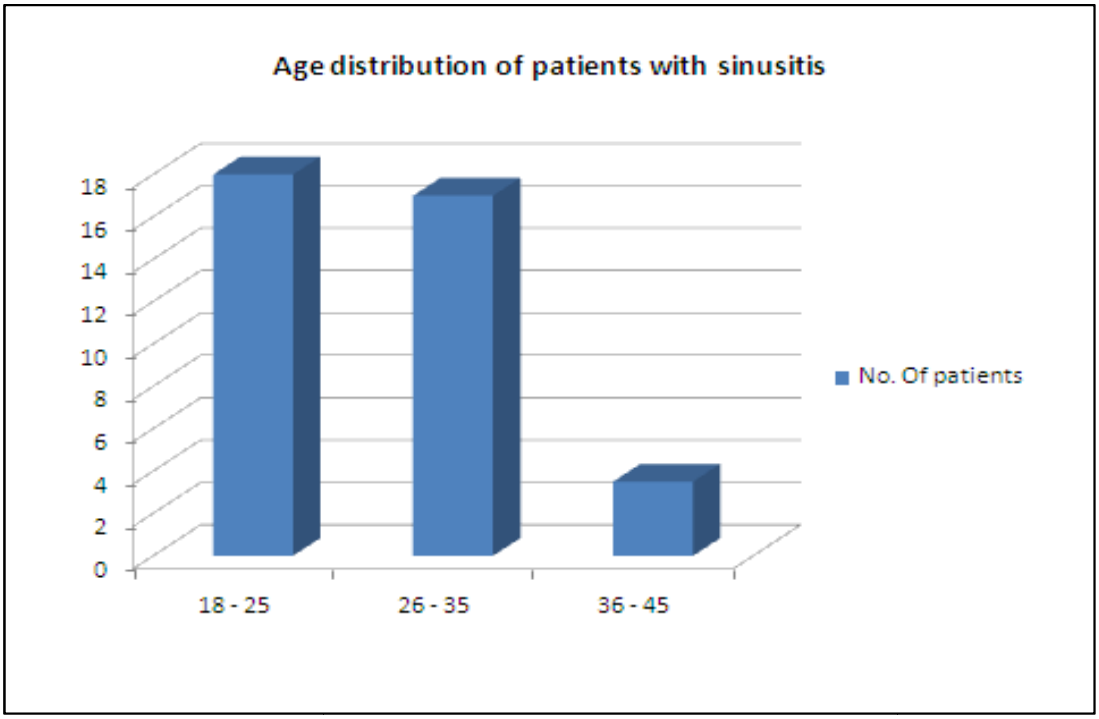

***figure 1*: shows the age distribution of cases.**

Sex distribution of patients with chronic sinusitis

Sex	No. of patients
MALE	25 (50%)
FEMALE	25 (50%)

Table 2: showing the sex distribution of cases

The incidence of chronic sinusitis was equal in both males and females in our study.

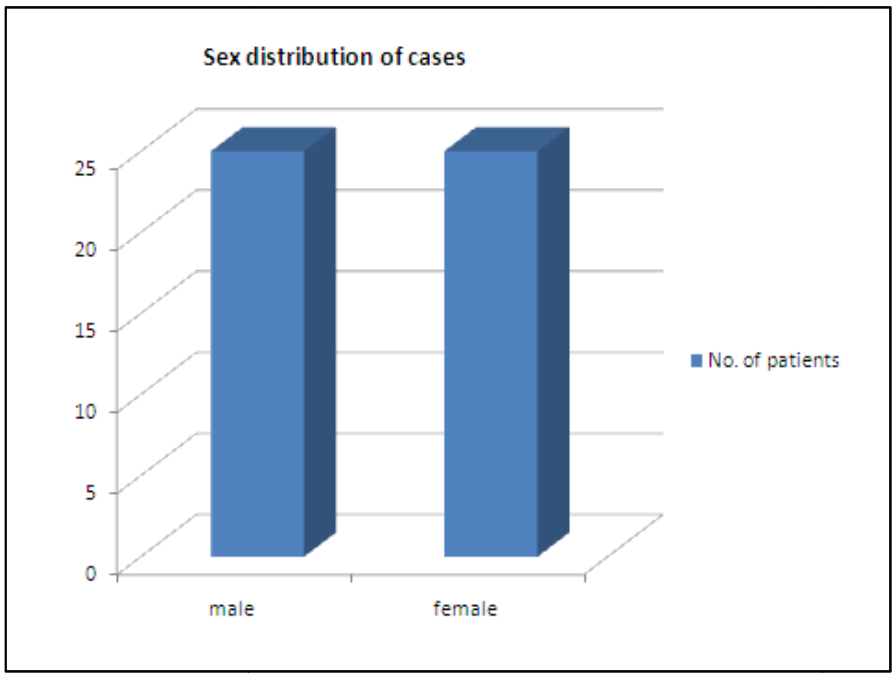

***Figure 2*: showing the sex distribution of cases**

Frequency of anatomical variations.

Anatomical variation	male	female	total
DNS	19 (38%)	18 (36%)	37 (74%)
CB	12 (24%)	10 (20%)	22 (44%)
PMT	8 (16%)	2 (4%)	10 (20%)
HALLER	2 (4%)	1 (2%)	3 (6%)
DNS + CB	3 (6%)	9 (18%)	12 (24%)
DNS + PMT	4 (8%)	1 (2%)	5 (10%)
DNS + CB + PMT	2 (4%)	0	2 (4%)

Table 3: showing frequency of different anatomical variations

DNS =deviated nasal septum, CB =concha bullosa, PMT =paradoxical middle turbinate

The frequency of occurrence of each anatomical variation was analyzed among the patients with sinusitis. Among the 50 cases, 37 (74%) had nasal septal deviation, either alone or in combination with other anatomical variation. Concha bullosa was seen in 22 (44%) cases, a paradoxical middle turbinate in 10 (20%) cases and haller cell in 3 (6%) cases.

There were patients with more than one anatomical variations i.e 12 (24%) cases had septal deviation and concha bullosa together, 5 (10%) cases had septal deviation and paradoxical middle turbinate and 2 (4%) patients had all the three occurring together.

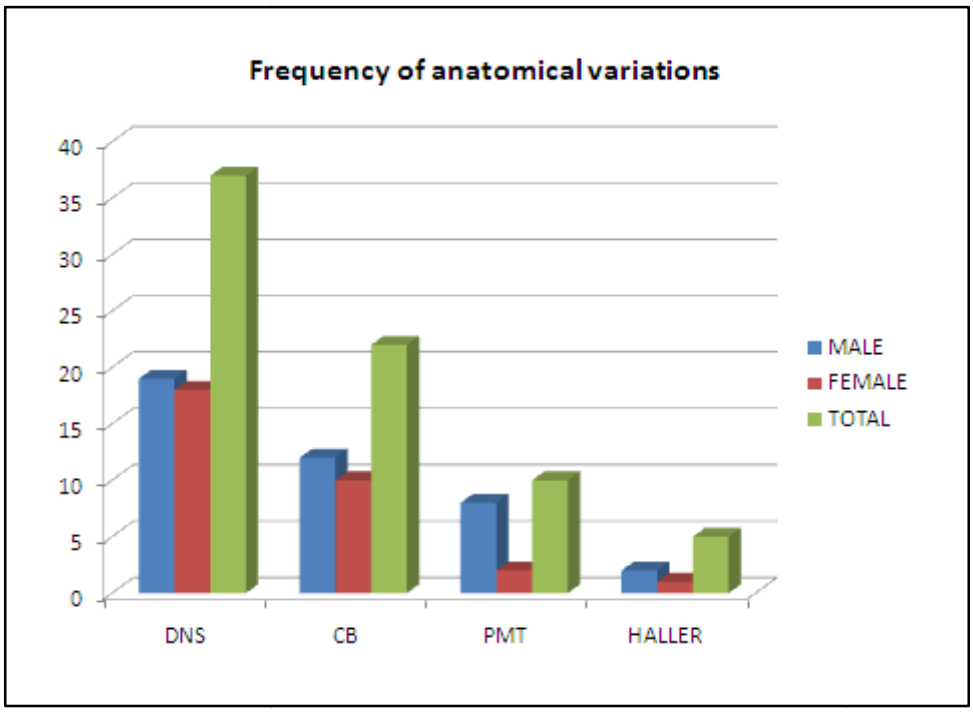

Figure 3: **showing frequency of major anatomical variations.**

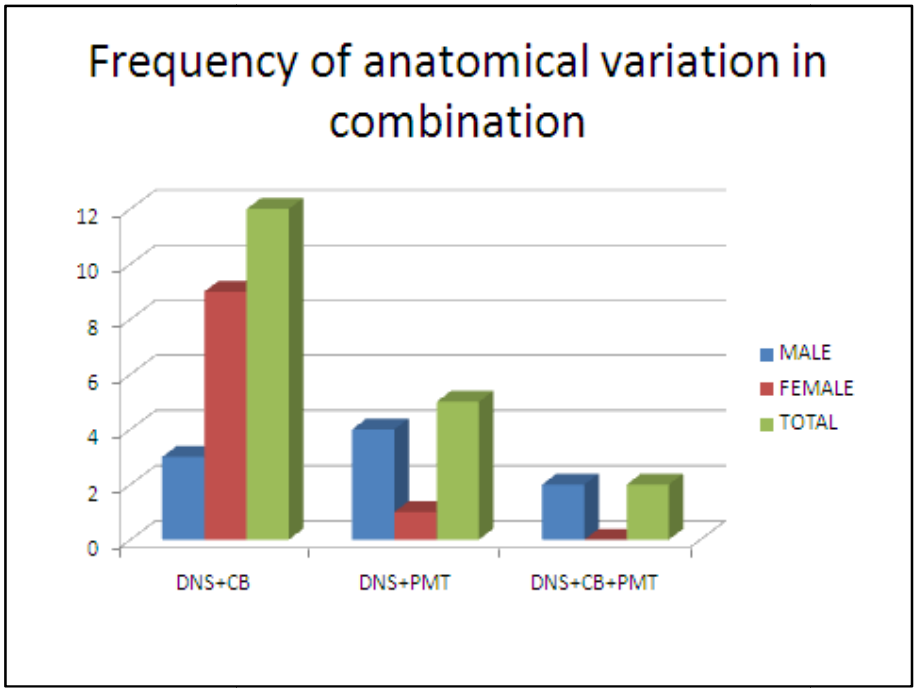

Figure 4: **shows frequency of anatomical variation occurring in combination**

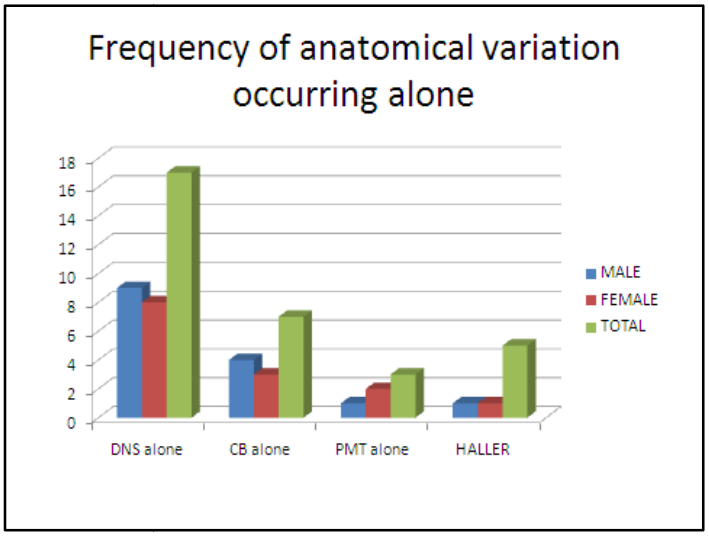

Figure 5: **frequency of anatomical variation occurring alone.**

Among the 50 cases studied, 17 (34%) had septal deviation alone as the anatomical variation, 7 (14%) cases had concha bullosa alone, 3 (6%) cases were having paradoxical middle turbinate alone and 2 (4%) cases had only haller cell. Rest of the cases had combination of anatomical variations. (figure:5 & 6).

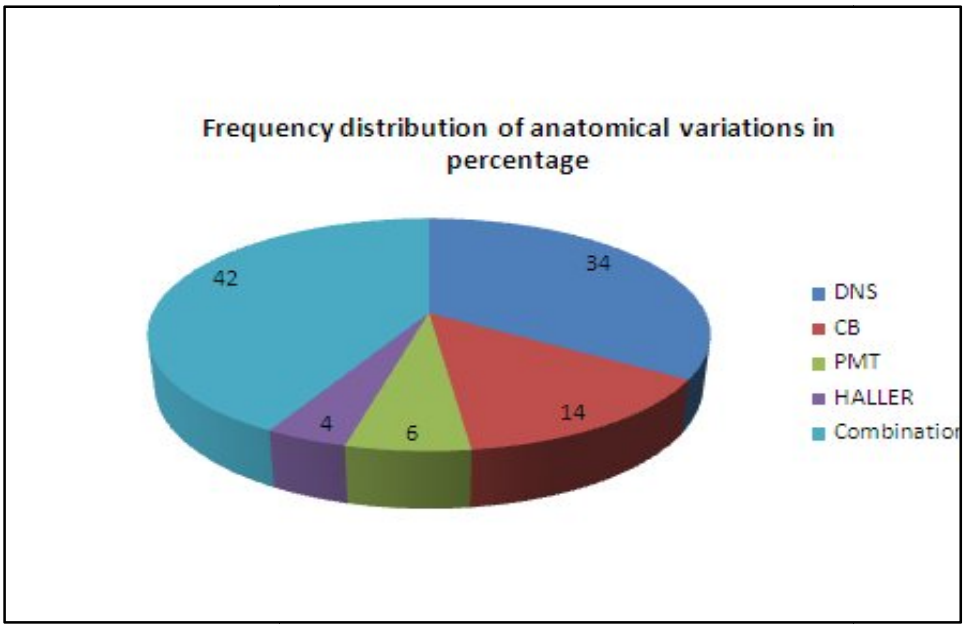

Figure 6: **A Pie chart showing the isolated frequency of each anatomical variation. DNS =deviated nasal septum, CB =concha bullosa, PMT =paradoxical middle turbinate.**

Chief complaints of the patients with sinusitis

complaints	No. of patients
Nasal obstruction	14 (28%)
Nasal discharge	6 (12%)
Headache	10 (20%)
Nasal obstruction& headache	11 (22%)
Nasal obstruction& nasal discharge	7 (14%)
Facial pain	3 (6%)
Anosmia	1 (2%)

Table 4: showing the frequency of chief complaints of the patients.

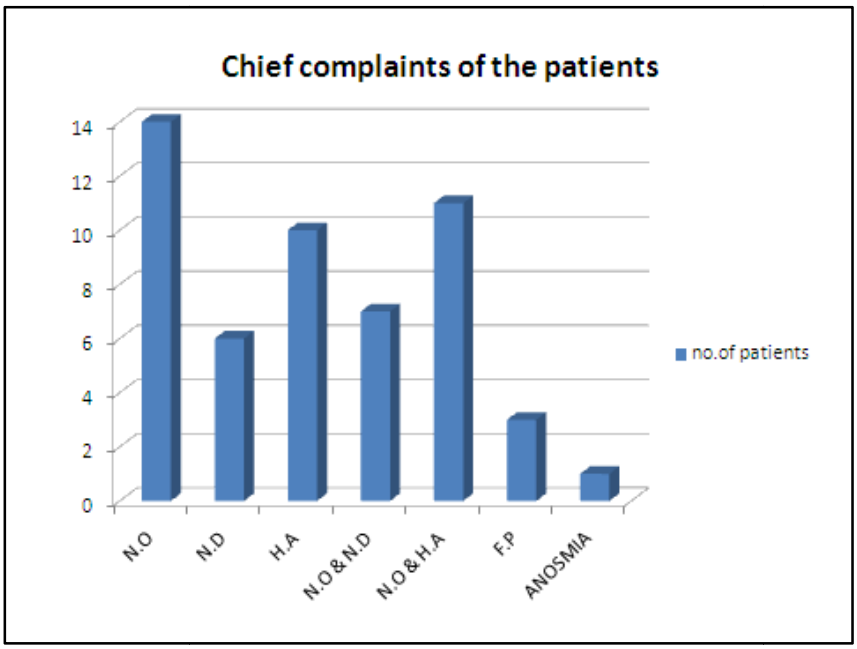

Figure 6: **showing the frequency of presentation of chief complaints**

N.O =nasal obstruction, N.D =nasal discharge, H.A =headache, F.P =facial pain

When the presenting symptom or chief complaints of the patients were analyzed, we found that 14 (28%) cases had nasal obstruction, 6 (12%) cases had nasal discharge, 10 (20%) had head ache as the main complaint. 7 (14%) cases had both nasal obstruction and nasal discharge, 11 (22%) had both nasal obstruction and headache, 3 (6%) cases had facial pain and one patient had anosmia as the chief complaint. (table:4, figure:6).

Involvement of sinuses in patients with sinusitis

Sinus involved	No. of patients
Maxillary	9 (18%)
Ethmoid	13 (26%)
Frontal	1 (2%)
Maxillary & ethmoid	21 (42%)
All sinuses	4 (8%)

Table 5: shows the sinuses affected in patients with sinusitis.

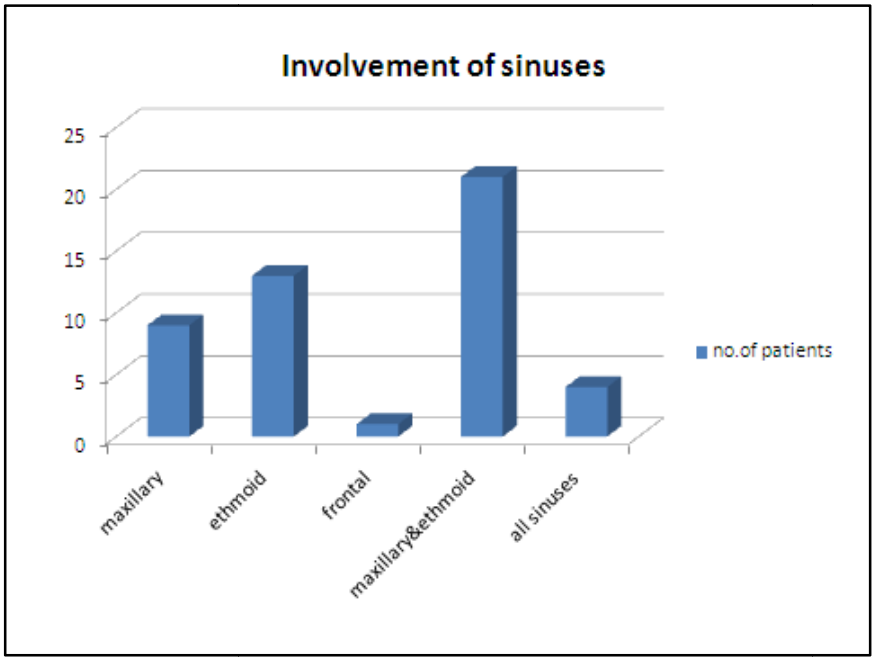

figure 7: shows the frequency of involvement of the sinuses.

The sinuses involved in patients with sinusitis were analyzed for all cases. Both maxillary sinus and ethmoid sinus were involved in 21 (42%) cases, ethmoid alone in 13 (26%) cases, maxillary sinus alone in 9 (18%) cases and one patient had only frontal sinus involved. All sinuses were affected in 4 (8%) cases. (table:5, figure:7).

Frequency of major anatomical variations in study group& control group

Anatomical variation	Study group	Control group	P- value
Deviated nasal septum	37 (74%)	18 (36%)	0.00015
Concha bullosa	22 (44%)	9 (18%)	0.005
Paradoxical middle turbinate	10 (20%)	3 (6%)	0.042
Haller cell	3 (6%)	1 (2%)	0.36

Table 6: showing frequency of major anatomical variants in study group and control group.

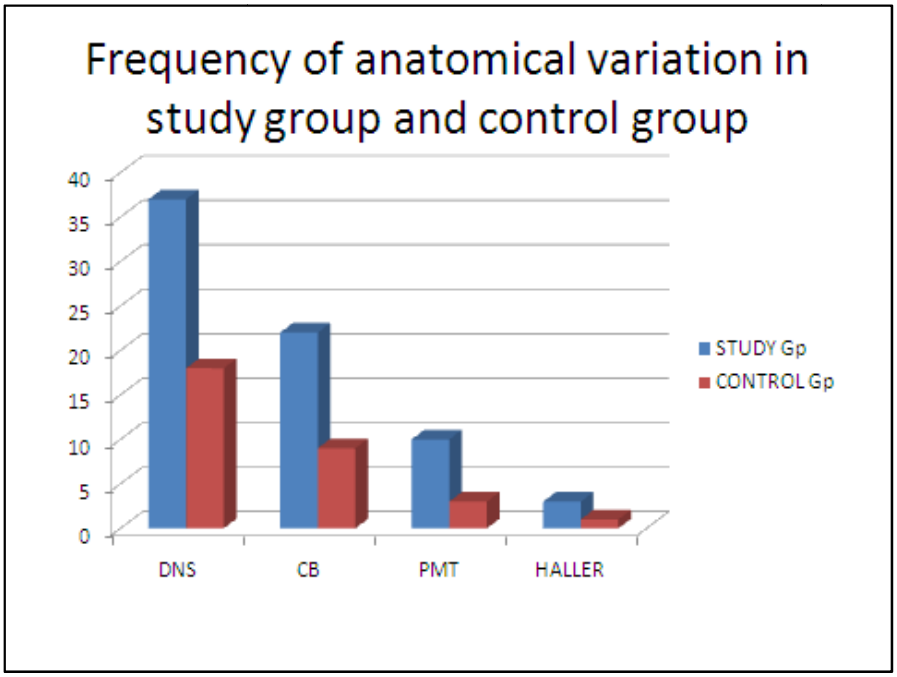

Figure 8:shows the frequency of major anatomical variants in two groups.

We compared the frequency of the major anatomical obstructive variants in the study group with that of the control group. The frequency of septal deviation was 18 (36%) in the control group and 37 (74%) in the study group with a p-value of 0.00015 (<0.05). Similarly for concha bullosa, it was 9 (18%) in the control group and 22 (44%) in the study group (p-value 0.005 i.e <0.05), for paradoxical turbinate, 3 (6%) in control group and 10 (20%) in study group (p-value 0.042, <0.05) and for haller cell it was 1 (2%) in control group and 3 (6%) in the study group(p-value 0.36).

Post operative assessment

Postoperative status	No. of patients
Symptoms improved	34 (68%)
No improvement of symptoms	12 (24%)
Patency of sinuses - good	39 (78%)
Patency of sinuses – impaired	7 (14%)
Did not come for follow up	4 (8%)

Table:7 showing the postoperative status of the patients.

Out of the 50 cases operated for chronic sinusitis due to anatomical obstruction, 34 (68%) cases had improvement of their symptoms, even though 39 (78%) cases were having a good patency of their sinuses post operatively. 12 (24%) cases had no improvement of their symptoms and 7 (14%) had impaired sinus drainage on post operative nasal endoscopic examination. Among the 50 cases, 4 cases did not turn up for follow up.(table:7).

DISCUSSION

Stammberger et al[43,44] stated that narrowing of the osteomeatal complex either due to anatomical configuration or due to hypertrophied mucosa, may cause obstruction and hence stagnation of the sinus secretions that may there by, become infected or perpetuate the infection.

Mackay and Lund[45] proposed that the osteomeatal complex acts as a drainage pathway for the maxillary, anterior ethmoid and frontal sinuses they considered the posterior osteomeatal unit to be a part of the sphenoid sinus. In various regions of the osteomeatal complex, overcrowding due to anatomical variation occurs, and thus, two mucosal layers come in to contact with each other, thus creating the likelihood of obstruction to mucociliary clearance. Secretions then may be retained at these sites, producing increased potential for infection, even without the closure of the ostium. The most likely areas of mucosal contact automatically are in the narrow mucosa lined pathways of the middle meatus and the ethmoid infundibulum.

In our study, we considered major anatomical obstructions in osteomeatal complex like septal deviation, concha bullosa, paradoxical middle turbinate and Haller cells. As a deviated nasal septum is a normal

occurrence in the population rather than an abnormal variation, we considered only gross septal deflections which may hamper the mucociliary drainage leading to infection, i.e Cottle's type 2 & type 3. There was statistically significant difference between the two groups of having a septal deviation and occurrence of sinusitis. Different studies worldwide have found different results regarding the occurrence of a deviated nasal septum in the population.

study	**Sample size**	**DNS**
Perez et al (spain)[46]	110	58.2%
H.Mamtha (india)[47]	40	65%
Dutra et al (Brazil)[48]	71	14.1%
AR Talaiepour et al (iran)[49]	143	63%
Current study	50	74%

The wide difference in the studies may be because of the difference in the selection criteria i.e the exact definition of a septal deviation to be included in the study. In our study we included patients with gross septal deviation according to the Cottle's classification.

When concha bullosa was studied, we included bulbous and extensive type of concha bullosa, according to the Bolger et al[50]

classification in our study. The frequency of concha bullosa was 44% in our study, which is higher when compared to the reported incidence of 28% by Azruddin et al[51], 24% by Llyod[52] and 42.6% by Maru et al[53] and less when compared to the study of Bolger et al[50], which is 53.6%. There was a statistically significant difference among the study group and control group (p-value <0.05) in our study.

The middle turbinate can be paradoxically curved i.e bent in the reverse direction, which may lead to the obstruction of the middle meatus and thus to sinusitis. The incidence in our study was 20%, with a p-value of <0.05 i.e there is a statistically significant association between the presence of paradoxical turbinate and sinusitis. It was 12% by Azruddin et al[51], 27% by Bolger et al[50], and 15% by Llyod[52].

Haller cells are ethmoid air cells which extend beyond the limits of the ethmoid labyrinth in to the maxillary sinus. In our study the incidence of haller cells was 3 (6%). There was no statistically significant difference among the study group and control group (p-value >0.05).

Most of the patients in our study had the chief complaint as nasal obstruction, followed by headache, nasal discharge, facial pain and one case had anosmia. The most common sinus involved was ethmoid sinus, followed by maxillary and frontal. But majority of the patients had

involvement of both maxillary and ethmoid sinus and 4 cases had involvement of all the sinuses.

By the end of 6th week after surgery, nasal mucosa and mucociliary flow would have been reestablished in most of the patients. So we started evaluating the outcome of the surgery by this time for all patients in our study. Even though 78% of the patients had a good patency of their sinus drainage post operatively, only 68% had an improvement of symptoms following the surgery. So we considered symptomatic improvement as the ultimate factor to decide the surgical intervention as a success. There was no improvement of symptoms in 24% of patients following surgery in our study. Whereas study conducted by Gliklich and Metson[54] shows symptomatic relief in about 82% of patients. Welch and Stankiewicz[55] shows symptomatic relief in 85% and Lazer and colleagues found improvement in 80% of patients.

CONCLUSION

Visualization of paranasal sinus anatomy has improved by the use of computerized tomography of the sinuses. It helps in evaluating the exact anatomy and find out the abnormal anatomical variation which will help the surgeons to avoid intra operative complications as well as to give the best results for the patients.

The most common anatomical variation leading to osteomeatal obstruction in our study was a deviated nasal septum, followed by concha bullosa and paradoxical middle turbinate. There was a statistically significant association between the presence of a septal deviation, concha bullosa and paradoxical turbinate with the occurrence of sinusitis, but not with Haller cells. Most of the patients had presence of more than one anatomical obstruction and ethmoid sinus followed by maxillary sinus were the most commonly involved sinuses. There was significant symptomatic improvement following the endoscopic nasal surgery along with correction of the anatomical obstruction, but many a time post operative medical therapy also needed to help the patient relieved of symptoms.

Anatomical obstruction at the Osteomeatal complex is one of the major etiological factor leading to the development of chronic sinusitis. Proper evaluation with computerized tomogram of paranasal sinuses along with nasal endoscopy helps to identify the problem and aid in deciding the treatment protocol. Functional endoscopic sinus surgery helps to alleviate symptoms of patients with chronic sinusitis to a large extend.

BIBLIOGRAPHY

1 . Benninger M5, Ferguson BJ, Hadley JA, Hamilos DJ, Jacobs M, Kennedy DW et 01. Adult chronic rhinosinusitis: Definitions, diagnosis. epidemiology and pathophysiology. Otolaryngology and Head and Neck Surgery. 2 003; 129:51-32.

2. Otolaryngologic Clinics of North America : chronic sinusitis; vol.38 December 2005 issue. page no. 1144-1145.

3. Report of the Rhinosinusitis Task Force Committee Meeting. Otolaryngology and Head and Neck Surgery.1997; 117: 51-68.

4. Lanza DC, Kennedy DW. Adult rhinosinusitis defined. Otolaryngology and Head and Neck Surgery. 1997; 117:51-7 .

5. Benninger MS, Ferguson BJ, Hadley JA, et al. Adult chronic rhinosinusitis: definitions, diagnosis, epidemiology, and pathophysiology. Otolaryngol Head Neck Surg 2003;129(3 Suppl):1â,32.

6. Benninger MS, Ferguson BJ, Hadley JA, et al: Adult chronic rhinosinusitis: definitions, diagnosis, epidemiology, and pathophysiology. *Otolaryngol Head Neck Surg* 2003; 129:S1-S32.

7. Khalid AN, Hunt J, Perloff JR, et al. The role of bone in chronic rhinosinusitis. Laryngoscope 2002;112(11):1951â€“1957.

8. Stammberger GE. Functional Endoscopic sinus Surgery: Messerklinger technique. Philadelphia, PA:BC Decker;1991

9. Davis WB. Nasal accessory sinus in man. Philadelphia, PA;WB Saunders;1914

10. Hall GW. Embryology and abnormal anatomy of the maxillary sinus. Northwest Med 1969;68:1010-1.

11. Schaeffer JP. The sinus maxillaries and its relations in the embryo, child and adult man. Am J Anat 1912;10:313-67.

12. Schaeffer JP. The genesis, development and adult anatomy of the nasofrontal duct region in man. Am J Anat 1916;20: 125-45.

13. Libersa C, Laude M, Libersa JC. The pneumatisation of the accessory cavities of the nasal fossae during growth. Anat Clin 1981;2:265-73.

14. Hanson NL. Embryological development of the nasal accessory sinuses. Illinois Med J1931;60: 386-9.

15. Van Alyea OE. Ethmoid labrynth: anatomic study, with consideration of the clinical significant of its structural characteristics. Arch Otolaryngol 1939;29:881-901.

16. Bingham B, Wang RG, Hawke M, Kwok P. The embryonic development of the lateral nasal wall from 8 to 24 weeks. Laryngoscope 1991;101:912-97.

17. Wang RG Jiang SC, Gu R. The cartilginuos nasal capsule and embryonic development of human paranasal sinuses. J Otolaryngol 1994;23:239-43.

18. Vidic B. The postnatal development of the sphenoidal sinus and its spread in to the dorsum sellae and posterior clinoid processes. AJR Am J Roentgenol 1968 104:177-83.

19. Szolar D, Preidler K, Ranner G, et al. Magnetic resonance assessment of age related development of the sphenoid sinus. Br J Radiol 1994:67:431-5.

20. Van Alyea OE. Sphenoid sinus: anatomic study, with consideration of the clinical significance of the structural characteristics of the sphenoid sinus. Arch Otolaryngol 1941:34:225-53.

21. Schaeffer JP. The nose, paranasal sinuses, nasolacrimal passageways and olfactory organ in man: a genetic, developmental, and anatomico-physiological consideration. Philadelphia, PA:P.Blakiston's Son; 1920.

22. Kasper KA. Nasofrontal connections: a study based on one hundred consecutive dissections. Arch Otolaryngol 1939;29: 881-901.

23. Ritter RN. The paranasal sinuses: anatomy and surgical technique, 3rd ed. St Louis, MO: CV Mosby; 1973.p. 17-33.

24. Bolger WE, Woodruff WW, Parsons DS. CT demonstration of uncinate process pneumatisation: a rare paranasal sinus anomaly. Am J Neurorad 1990;11:552.

25. Kennedy DW, Zinriech SJ.The functional endoscopic approach to inflammatory sinus disease: current perspectives and technique modifications. Am J Rhinol 1988;2:89-96.

26. Stammberger HR, Bolger WE, Clement PAR, et al. Anatomic terminology and nomenclature in sinusitis. Ann Otol Rhinol Laryngol 1995;104 (Suppl 167):7-19.

27. Van alyea OE. Ostium maxillare: anatomic study of its surgical accessibility. Arch Otolaryngol Head Neck Surg 1939;24:552-69.

28. Onishi T. Bony defects and dehiscence of the roof of the ethmoid cells. Rhinology 1981;19:195-202.

29. Stedman's medical dictionary 24th ed. Baltimor, MD: Williams and Wilkins; 1982. p. 710.

30. Naumann H. Patholische anatomic der chronischen rhinitis und sinusitis. In: proceedings VIII. International congress of Oto-rhinolarygology. Amsterdam: Excerpta Medica;1965; p.12.

31. Kuhn FA, Bolger WE, Tisdal RG. The agger nasi cell in frontal recess obstruction : an anatomic, radiologic and clinical correlation. Op Tech Otolaryngol Head Neck surg 1991;2:226-31.

32. Van Alyea OE. Frontal cells. Arch Otolaryngol 1941;34:11-23

33. Kainz J, Braun H, Genser P. Haller's cells: morphologic evaluation and clinico-surgical relevance. Laryngorhinootologie 1993;72: 599-604.

34. Bolger WE, Woodruff WW, Morehead J, Parsons DS. Maxillary sinus hypoplasia: classification and description of associated

uncinate hypoplasia. Otolayngol Head Neck Surg 1990;103: 759-65.

35. Bolger WE, Kennedy DW. Atelectasis of the maxillary sinus. J Respir Dis 1992;13 1448-50.

36. Driben MJ, Bolger WE, Robles HA, et al. The reliability of computerized tomographic detection of the Onodi (sphenoethmoid) cell. Am J Rhinol 1998;12:105-11.

37. Schaeffer JP. On the genesis of air cells in the conchae nasals. Anat Rec 1910; 4:167-80.

38. Lothrop HA. The anatomy of the inferior ethmoidal turbinate bone with particular reference to cell formation: surgical importance of such ethmoid cells. Ann Surg 1903;38:233-55.

39. Zinriech SJ, Mattox DE, Kennedy DW, et al. Concha bullosa: CT evaluation. J Comput Assst Tomogr 1988;12:778-4.

40. Von Haller A. First lines of physiology. In: Cullen w, editor 1st US ed, Edinburgh: Obabran, Penniman and Co; 1803. p. 224.

41. Kimpotic-Nemanic J, Draf W, Helms J. Surgical anatomy of the Head and Neck Berlin: Springer- Verlag;1998.

42. Skillern RH. The catarrhal and suppurative diseases of the accessory sinuses of the nose. Philadelphia, PA: JB Lippincott; 1913. p.302.

43. Stammberger H. Secretion transport. In : Functional endoscopic sinus surgery. Philadelphia: BC Decker, 1991:17-46.

44. Kopp W, Stammberger H, Fotter R. Special radiologic image of the paranasal sinuses. Eur J Radiol 1988: 8:152-156.

45. Mackay IS, Lund VJ. Surgical management of sinusitis. In: Scott-Brown's Otolaryngology, 6th ed. Oxford: Butterworth- Heinemann, 1997:4/12/1-4/12/29.

46. Perez P, Sabate J, Carmona A, Catalina-Herrera CJ, Jimenez-Castellanos J. Anatomical variations in the human paranasal sinus region studied by CT. J Anat 2000; 197: 221-7.

47. Mamatha H, Shamasundar NM, Bharathi M, Prasanna L. Variations of ostiomeatal complex and its applied anatomy: a CT scan study. Indian J Sci Technol 2010; 3: 904-7.

48. Dutra LD, Marchiori E. Helical computed tomography of the paranasal sinuses in children: evaluation of sinus inflammatory diseases. Radiologia Brasileira 2002; 35: 161-9.

49. Talaiepour AR, Sazgar AA, Bagheri A. Anatomic variations of the paranasal sinuses on CT scan images. J Dentistr Tehran Univ Med Sci 2005; 2(4).

50. Bolger WE, Butzin CA, Parsons DS. Paranasal sinus bony anatomic variations and mucosal abnormalities: CT analysis for endoscopic sinus surgery. Laryngoscope 1991; 101:56-64.

51. Azruddin, Yadav SPS, Yadav RK, Singh J. Low dose CT in chronic sinusitis. Indian Journal of Otolaryngology and Head Neck Surgery 2000; 52: 17-21.

52. Lloyd GAS, Lund VJ, Scadding GK. Computerised tomography in the preoperative of Functional endoscopic sinus surgery. Journal of Laryngology and Otology 1991;105:181-185.

53. Maru YK, Gupta V. Anatomic variations of the bone in Sinonasal CT. Indian journal of Otolaryngol and Head Neck Surgery 2001;53:123-128.

54. Gliklich RE, Metson R. Effect of sinus surgery on quality of life. Otolaryngol Head Neck Surg 1997; 117:12-7.

55. Welch KC, Stankiewicz JA. A contemporary review of endoscopic sinus surgery: techniques, tools and outcomes. Laryngoscope 2009;119:2258-68.

PROFORMA

Name: **Age:** **Sex:**

Occupation:

Address:

OP/IP no: **DOA:** **DOD:**

Chief complaints:

History presenting illness:

h/o nasal obstruction/blockage

h/o facial pain/pressure

h/o facial congestion/fullness

h/o nasal discharge/purulence/discoloured posterior drainage

h/o Hyposmia or anosmia

h/o headache/fever/halitosis/fatigue/dental pain

h/o cough

h/o excessive sneezing

h/o nasal bleeding

h/o snoring/mouth breathing

h/o ear discharge/pain/pressure

h/o vertigo/tinnitus

h/o decreased vision/difficulty in reading.

History of past illness:

h/o any medical illness

h/o any previous surgery in Ear/Nose/Throat

h/o any other surgeries

h/o of trauma

Personal history:

h/o smoking/alcohol intake

General examination:

a) general condition

b)built and nourishment

c)pallor/icterus/cyanosis/clubbing/lymph node enlargement/pedal edema

d)vital signs

Systemic examination:

a) cardiovascular system
b) respiratory system
c) central nervous system
d) gastrointestinal system

E.N.T Examination:

Examination of nose: external frame work

columella and vestibule

septum

Anterior Rhinoscopy:

	Inferior turbinate	Inferior meatus	Middle turbinate	Middle meatus	Nasal septum	Floor
Right						
Left						

Posterior Rhinoscopy:

	choana	Post.end of Middle turbinate	Post.end of Inferior turbinate	Post.end of septum	Eustachean tube orifice	Fossa of Rossenmuller
Right						
Left						

Cold spatula test

Cotton wool test

Cottle's test

Paranasal sinus tenderness

Examination of Ear:

Pinna

Preauricular area

Postauricular area

External auditory canal

Tympanic membrane

Examination of Throat:

Oral cavity

Oropharynx

Examination of Neck:

Indirect laryngoscopic examination:

Investigations:

1) CBC, RFT, Blood grouping and typing
2) urine routine examination
3) RBS
4) HIV, HBSAg
5) CT- PNS
6) Diagnostic nasal endoscopy
7) Otoendoscopy.

Surgery:

Anesthesia:

Procedure:

Approach:

Technique:

Follow up:

Nasal endoscopy after 1st week, 2nd week, 1 month, 3month & 6months.

INSTITUTIONAL ETHICAL COMMITTEE, STANLEY MEDICAL COLLEGE, CHENNAI-1

Title of the Work : Study on role of Anatomical obstruction in Pathogenesis of chromic sinusitis

Principal Investigator : Dr. Yahya Abdul Basith

Designation : PG in MS (ENT)

Department : Department of ENT
Government Stanley Medical College,
Chennai-1

The request for an approval from the Institutional Ethical Committee (IEC) was considered on the IEC meeting held on 06.03.2012 at the Council Hall, Stanley Medical College, Chennai-1 at 2PM

The members of the Committee, the secretary and the Chairman are pleased to approve the proposed work mentioned above, submitted by the principal investigator.

The Principal investigator and their team are directed to adhere to the guidelines given below:

1. You should inform the IEC in case of changes in study procedure, site investigator investigation or guide or any other changes.
2. You should not deviate from the area of the work for which you applied for ethical clearance.
3. You should inform the IEC immediately, in case of any adverse events or serious adverse reaction.
4. You should abide to the rules and regulation of the institution(s).
5. You should complete the work within the specified period and if any extension of time is required, you should apply for permission again and do the work.
6. You should submit the summary of the work to the ethical committee on completion of the work.

MEMBER SECRETARY,
IEC, SMC, CHENNAI

சுய ஒப்புதல் படிவம்

ஆராய்ச்சி நிலையம் : **காது, மூக்கு, தொண்டை பிரிவு**
ஸ்டான்லி அரசு பொது
மருத்துவமனை மருத்துவக் கல்லூரி,
சென்னை - 600 001.

பங்கு பெறுபவரின் பெயர் :

பங்கு பெறுபவரின் எண் :

மருத்துவ ஆய்வின் விவரங்கள் எனக்கு விளக்கப்பட்டது. எனது மூக்கில் பிரச்சனைகள் ஏற்பட்டுள்ளது என்பது தெரியப்படுத்தப்பட்டது. எனது மூக்கு நோய் பற்றிய சந்தேகங்களை கேட்கவும், அதற்கான தகுந்த விளக்கங்களை பெறவும் வாய்ப்பளிக்கப்பட்டது. இந்த நோய்க்கு தீர்வுக்காண FESS முறை பயன்படுத்தப்பட உள்ளது. இந்த அறுவை சிகிச்சையின் விளைவுகளை ஆய்வில் பயன்படுத்தவும் தன்னிச்சையாக சம்மதிக்கிறேன். எக்காரணத்தினாலும், எந்தக் கட்டத்திலும் எந்த சட்ட சிக்கலுக்கும் உட்படாமல் இவ்வாய்வில் இருந்து விலகிக் கொள்ளலாம் என்றும் அறிந்து கொண்டேன்.

இந்த ஆய்வின் மூலம் கிடைக்கும் தகவல்களையும், பரிசோதனை முடிவுகளையும், மருத்துவர் மேற்கொள்ளும் ஆய்வில் பயன்படுத்திக் கொள்ளவும், அதை பிரசுரிக்கவும், தேவைப்பட்டால்-என்னையும், எனக்கு நடக்கும் அறுவை சிகிச்சையையும் புகைப்படம் எடுக்கவும் நான் முழுமனதுடன் சம்மதிக்கிறேன்.

பங்கேற்பவரின் கையொப்பம் : நாள் :

கட்டை விரல் ஒப்பம் இடம் :

பங்கேற்பவரின் பெயர் மற்றும் விலாசம்:

ஆய்வாளரின் கையொப்பம் : நாள் :

ஆய்வாளரின் பெயர் : இடம் :

தகவல் படிவம்

தாங்கள் உட்படுத்தப்பட்ட பரிசோதனைகளின் மூலம் தங்கள் மூக்கில் நோய் (Chronic Sinusitis) இருப்பது தெரிய வந்துள்ளது. இதன் விளைவாக தங்களின் மூக்கில் பிரச்சனைகள் ஏற்பட்டு உள்ளது.

இந்த மூக்கின் பிரச்சனைகளுக்கு தீர்வுக்காண FEES அறுவை சிகிச்சை முறை பயன்படுத்தப்பட உள்ளது. மேலும் இந்த அறுவை சிகிச்சையின் விளைவுகளை ஒப்பிட்டு ஆய்வு மேற்கொள்ளப்படவும் உள்ளது. இது குறித்த தகவல்களையும், முடிவுகளையும் ஆய்வில் பயன்படுத்த விரும்புகிறோம்.

தாங்கள் விரும்பினால் மருத்துவ ஆய்விலிருந்து எப்பொழுது வேண்டுமானாலும் விலகிக் கொள்ளலாம். எந்த சட்ட சிக்கலுக்கும் உட்படாமல் எப்பொழுது வேண்டுமானாலும் தங்கள் ஆய்விலிருந்து விலகிக் கொள்ளலாம்.

இந்த ஆய்வின் மூலம் கிடைக்கும் தகவல்களும், பரிசோதனை முடிவுகளும் தங்களின் ஒப்புதலின்றி ஆய்வில் பயன்படுத்தப்படமாட்டாது.

ஆய்வாளரின் கையொப்பம் :

ஆய்வாளரின் பெயர் :

இடம் :

நாள் :

Turnitin Document Viewer - Mozilla Firefox

https://turnitin.com/dv?o=380470465&u=1024053256&s=&student_user=1&lang=en_us

The Tamil Nadu Dr. M.G.R. Medical ... | Medical - DUE 31-Dec-2013 | What's New

Originality | GradeMark | PeerMark

ROLE OF ANATOMICAL OBSTRUCTION IN PATHOGENESIS OF CHRONIC SINUSITIS

BY 22112154 , M.S. ENT YAHYA ABDUL BASITH M , ESMAYIL

turnitin 21% SIMILAR

Dissertation on

A STUDY ON ROLE OF ANATOMICAL OBSTRUCTION

IN PATHOGENESIS OF CHRONIC SINUSITIS

Submitted to the

THE TAMILNADU DR. M.G.R. MEDICAL UNIVERSITY

In partial fulfilment of the requirements

For the award of the degree of

M.S.BRANCH IV
(OTORHINOLARYNGOLOGY)

No Service Currently Active

PAGE 1 OF 81

KEY TO MASTER CHART

N.O = nasal obstruction

N.D = nasal discharge

H.A = headache

F.P = facial pain

DSR = deviated nasal septum to right

DSL = deviated nasal septum to left

PMT = paradoxical middle turbinate

CB = concha bullosa

CP = conchoplasty

SP = septoplasty

PMTR = partial middle turbinate resection

FESS = functional endoscopic sinus surgery

0 = symptoms improved

1 = no improvement of symptoms

2 = did not come for follow up

(+) = patency of sinus good

(-) = patency of sinus impaired

MASTER CHART

Sl No.	Name	Age/sex	OP/IP No	compla	Anterior rhinoscopy	DNE	sinus involved	CT PNS	Procedure	Post operative follow up			
										1st week	3rd week	1 month	3 months
1	sraswathy	29/F	43546	N.O	DSL	DSL,PMT	maxillary	DNS, PMT	CP+MTR+FESS	1, +	0, +	0,+	0, +
2	devi	33/F	39053	N.D	DSR, septal spur	DSR, septa; spur	maxillary,ethmoid	DNS	SP+FESS	0, -	0, +	0, +	0, +
3	KRISHNAMOORTHY	45/M	33630	N.O	boggy MT	B/L boggy MT	ethmoid	B/L CB	CP+FESS	0, -	0, +	0, +	0, +
4	shahul hameed	25/M	460073	N.O, N.D	DSR, septal spur	DSR,purulant disc	maxillary,ethmoid	DNS	SP+FESS	1, +	1, +	1, +	1, +
5	manivel	32/M	468423	N.O	DSL	DSL	max.,ethm.,sphend	DNS	SP+FESS	2	2	2	2
6	lincy	22/F	303647	H.A	DSR	DSR	maxillary,ethmoid	DNS	SP+FESS	0, -	0, +	0, +	0, +
7	melvin	18/M	302410	N.O	DSR	PMT	maxillary<ethmoid	PMT	PMTR+FESS	1, -	1, +	1, +	1, +
8	ragul	19/M	303456	N.D	DSL	DSL	max.,ethm.,sphend	DNS, PMT	SP+FESS	1, -	1, -	0, +	0, +
9	devi	30/F	500275	H.A	DSR	DSR	maxillary,ethmoid	DNS,HALLER	SP+FESS	0, -	0, +	0, +	0, +
10	musthri bani	30/F	316753	H.A	DSR,Boggy MT	DSR,Boggy MT	ethmoid	DNS,CB	CP+FESS	0, -	0, -	1, -	1, -
11	murugan	23/M	312389	H.A	DSL	DSL	maxillary,ethmoid	DNS	SP+FESS	1, -	0,+	0, +	0, +
12	karthik	22/M	316420	N.O	DSR,Boggy MT	DSR,Boggy MT	maxillary,ethmoid	DNS,CB	SP+CP+FESS	1, +	0, +	0, +	0, +
13	sumathi	26/F	259220	H.A	DSL	PMT	maxillary	PMT	PMTR+FESS	0, -	0, +	0, +	0, +
14	devi	30/F	300027	H.A	PMT	PMT	maxillary	PMT	PMTR+FESS	1, -	1, -	1, +	1, +
15	saranya	25/F	521118	N.O, N.D	DSL	DNS,Boggy MT	All sinuses	DNS,CB	SP+CP+FESS	1, -	0, -	0, -	0, -
16	elumalai	45/M	521218	N.O	DSR,Boggy MT	DNS,Boggy MT	maxillary,ethmoid	DNS,CB	CP+FESS	0, -	0,+	0, +	0, +
17	mathan	22/M	501367	N.O	DSL,Boggy MT	DNS,Boggy MT	frontal	DNS,CB,PMT	CP+FESS	0, -	0, +	0, +	0, +
18	roopa	28/F	42524	NO,H.A	DSR	DSR	All sinuses	DNS	SP+FESS	0, -	0, +	0, +	0, +
19	banumathi	39/F	42522	N.D	DSL,	DSL	ethmoid	DNS	SP+FESS	1, -	0, +	0, +	0, +
20	banu	24/F	516165	F.P	DSR,Boggy MT	DNS,Boggy MT	ethmoid	DNS,CB	SP+CP+FESS	1, -	1, +	0, +	0, +
21	sintha	45/F	334149	N.D	DSR	DNS,Boggy MT	All sinuses	DNS,CB	SP+CP+FESS	0, -	0, +	0, +	0, +
22	kumaresan	29/M	511113	N.O	DSR	DSR	maxillary	DNS	SP+FESS	0, -	0, -	1, +	1, +
23	fathima	29/F	499557	N.O,Anosmi	DSL,Boggy MT	DSL,Boggy MT	ethmoid	DNS	SP+FESS	0, -	0, +	0, +	0, +
24	vanitha	28/F	515021	N.D	boggy MT	B/L boggy MT	maxillary,ethmoid	CB	CP+FESS	0,+	1, +	0, +	0, +
25	Saravanan	15/M	440967	N.O,N.D	boggy MT	B/L boggy MT	Maxillary	CB	CP+FESS	0, +	0, +	1, -	1, -
26	Ganga	35/F	311432	H.A	DSR	DSR	ethmoid	DNS	SP+FESS	0, -	0, +	0, +	0, +
27	Nithya	24/F	530414	N.O,H.A	boggy MT	Boggy MT	maxillary,ethmoid	CB	CP+FESS	2	2	2	2
28	Ramachandran	28/M	43593	N.O,N.D,H.A	DSR	DSR	maxillary	DNS,PMT	PMTR+FESS	1, -	1, -	0, +	0, +
29	Mahesh	18/M	43856	N.O,H.A	DSR	DSR	maxillary,ethmoid	DNS	SP+FESS	0, -	0, +	0, +	0, +
30	Velankanni	45/M	554986	F.P,N.O	DSL	DSL	maxillary,ethmoid	DNS	SP+FESS	0, -	1, -	0, +	0, +
31	Mallika	38/F	333349	N.O,H.A	DSL	DSL,Boggy MT	All sinuses	DNS,CB	CP+FESS	1, -	1, -	1, +	1, -
32	Riswi	39/M	522800	N.O,H.A	DSR	DSR	maxillary,ethmoid	DNS,PMT	SP+FESS	0, -	0, +	0, +	0, +
33	Thirumalai	23/F	44768	N.O,N.D	DSR,Boggy MT	DSR,Boggy MT	Maxillary	DNS,CB,PMT	CP+SP+FESS	1, -	1, +	0, +	1, -
34	Chandramouli	39/M	334422	N.O	DSL	DSL,PMT	maxillary,ethmoid	DNS,PMT	SP+FESS	0, -	0, +	0, +	0, +
35	Ramesh	39/M	511572	N.O	boggy MT	PMT,Boggy MT	ethmoid	CB,PMT	CP+FESS	0, -	1, +	0, +	0, +
36	Sampathkumar	44/M	567750	N.O	DSL	DSL,Boggy MT	maxillary,ethmoid	DNS,CB	CP+SP+FESS	1,-	0,-	0, +	0, +
37	raju	38/M	45484	N.O	DSL	DSL	maxillary	DNS	SP+FESS	1, -	0, +	0, -	0,-
38	nagajothi	32/F	44778	N.O,N.D,H.A	DSR	DSR	maxillary,ethmoid	DNS	SP+FESS	0, -	0, +	0, +	0, +
39	Kamal	26/M	448213	N.O,H.A	DSL,Septal spur	DSL, Septal spur	maxillary	DNS	SP+FESS	0, -	0, -	1, +	0, +
40	Boolgammal	39/F	455220	H.A	DSR	DSR	maxilary,ethmoid	DNS	SP+FESS	2	2	2	2
41	Kalaivani	45/F	327360	N.O	Purulant dischrge	purulant dischrg	ethmoid	HALLER	FESS	0, +	0, +	0, +	0, +
42	Shameema	19/F	218166	N.O,H.A	boggy MT	Boggy MT	maxillary,ethmoid	CB	CP+FESS	1, -	1, -	1, +	1, +
43	Prema	45/F	175136	N.D	DSL	DSL,Boggy MT	ethmoid	DNS,CB	CP+SP+FESS	0, -	0, +	0, +	1, +
44	Bujamma	35/F	47591	N.O,H.A	DSL	DSL	ethmoid	DNS	CP+FESS	1, +	1, +	0, +	0, +
45	Nagaraj	19/M	315763	N.O,N.D	boggy MT	Boggy MT	maxillary,ethmoid	B/L CB	CP+FESS	1, -	1,-	1,-	1,-
46	Nirmal kumar	24/M	322439	N.O,H.A	boggy MT	Boggy MT	ethmoid	CB,HALLER	CP+FESS	0, -	0, +	0, +	0, +
47	Manogaran	39/M	48024	H.A	boggy MT	Boggy MT	ethmoid	CB	CP+FESS	0, -	1, -	0, +	1, +
48	Shobana	28/F	465692	N.D,H.A,F.P	DSL	DSL	maxillary,ethmoid	DNS	SP+FESS	0, -	1, -	0, +	0, +
49	Anusuya	19/F	31298	H.A	DSR,Boggy MT	DSR,Boggy MT	maxillary,ethmoid	DNS	SP+FESS	0, -	0, +	0, +	0, +
50	Karthik	21/M	35135	N.O	DSL	DSL	ethmoid	DNS	SP+FESS	2	2	2	2