A DISSERTATION ON

ANALYTICAL CROSS SECTIONAL STUDY TO ASSESS THE EFFECTIVENESS OF BOWEL ANASTOMOSIS USING DOUBLE LAYERED AND SINGLE LAYERED CLOSURE

Dissertation submitted to

THE TAMIL NADU Dr.M.G.R.MEDICAL UNIVERISTY

CHENNAI

with partial fulfilment of the regulations

for the Award of the degree

M.S. [General Surgery]

Branch – I

DEPARTMENT OF GENERAL SURGERY,

STANLEY MEDICAL COLLEGE ,

CHENNAI.

MAY – 2019

CERTIFICATE

This is to certify that the dissertation entitled "**ANALYTICAL CROSS SECTIONAL STUDY TO ASSESS THE EFFECTIVENESS OF BOWEL ANASTOMOSIS USING DOUBLE LAYERED AND SINGLE LAYERED CLOSURE**" is a bonafide original work of **Dr R. SUKUMAR,** in partial fulfilment of the requirements for M.S. Branch-I (General Surgery) examination of the Tamil Nadu Dr. M.G.R. Medical University to be held in MAY 2019 under my guidance and supervision in 2018-2019.

Prof Dr. C. BALAMURUGAN, M.S

HOD & Professor of General Surgery,
Stanley Medical College & Hospital,
Chennai - 600001

Prof DR.ROSY ADHALINE SELVI, M.S

Professor of General Surgery,
Guide & Supervisor,
Stanley Medical College & Hospital
Chennai – 600001

Dr. PONNAMBALAM NAMASIVAYAM, M.D, DNB

Dean

Stanley Medical College & Hospital, Chennai – 600001

DECLARATION

I**, Dr. R. SUKUMAR** solemnly declare that the dissertation titled is a bonafide work done by me at Govt. Stanley medical college and hospital during 2017-2018 under the guidance and supervision of my unit chief **Prof DR.ROSY ADHALINE SELVI, M.S** professor of surgery. The dissertation is submitted to Tamil Nadu Dr. M.G.R. Medical University, towards partial fulfilment of requirement for the award of M.S. Degree (Branch-I) in general surgery, examination to be held in MAY 2019.

Place : Chennai

Date :

(**Dr. R. SUKUMAR)**

SCAN COPY OF ETHICAL COMMITTEE CERTIFICATE

GOVERNMENT STANLEY MEDICAL COLLEGE & HOSPITAL,CHENNAI -01

INSTITUTIONAL ETHICS COMMITTEE

TITLE OF THE WORK : ANALYTICAL CROSS SECTIONAL STUDY TO ASSES THE EFFECTIVENESS OF BOWEL ANASTOMOSIS USING DOUBLE LAYERED AND SINGLE LAYERED CLOSURE.

PRINCIPAL INVESTIGATOR : DR. R. SUKUMAR
DESIGNATION : PG IN MS GENERAL SURGERY
DEPARTMENT : DEPARTMENT OF GENERAL SURGERY, GOVT. STANLEY MEDICAL COLLEGE.

The request for an approval from the Institutional Ethical Committee (IEC) was considered on the IEC meeting held on 30.07.2018 at the Council Hall, Stanley Medical College, Chennai-1 at 10am.

The members of the Committee, the secretary and the Chairman are pleased to approve the proposed work mentioned above, submitted by the principal investigator.

The Principal investigator and their team are directed to adhere to the guidelines given below:

1. You should inform the IEC in case of changes in study procedure, site investigator investigation or guide or any other changes.
2. You should not deviate from the area of the work for which you applied for ethical clearance.
3. You should inform the IEC immediately, in case of any adverse events or serious adverse reaction.
4. You should abide to the rules and regulation of the institution(s).
5. You should complete the work within the specified period and if any extension of time is required, you should apply for permission again and do the work.
6. You should submit the summary of the work to the ethical committee on completion of the work.

MEMBER SECRETARY,
IEC, SMC, CHENNAI

PLAGIARISM CERTIFICATE

Wed 24 Oct 71%

secure.urkund.com

URKUND

Urkund Analysis Result

Analysed Document:	suki thesis 2.docx (D42935951)
Submitted:	10/23/2018 2:38:00 PM
Submitted By:	suku89@gmail.com
Significance:	19 %

Sources included in the report:

FINAL THESIS FULL.doc (D31238494)
BMW thesis final edited.docx (D31180568)
Thesis main main.docx (D42761759)
FINAL THESIS FULL.doc (D30633361)
paper anastomosis.docx (D30907833)
DR.K.PARTHIPAN- THESIS.docx (D42672561)
https://www.slideshare.net/Unit6lnh/intestinal-anastomosis-and-staplers
https://link.springer.com/article/10.1007%252Fs11605-015-3003-0

Instances where selected sources appear:

44

CERTIFICATE

This is to certify that the dissertation work titled "**ANALYTICAL CROSS SECTIONAL STUDY TO ASSESS THE EFFECTIVENESS OF BOWEL ANASTOMOSIS USING DOUBLE LAYERED AND SINGLE LAYERED CLOSURE**" of the candidate **Dr R. SUKUMAR** with registration number **221611070** for the award of **M.S. Degree (Branch-I) in general surgery**. I personally verified the urkund.com website for the purpose of plagiarism check. I found that uploaded thesis file contains from introduction to conclusion pages and result shows **19 percentage** of plagiarism in the dissertation.

Prof DR.ROSY ADHALINE SELVI, M.

GUIDE AND SUPERVISOR

ACKNOWLEDGEMENT

I express my heartful gratitude to Prof.Dr.PONNAMBALA NAMASIVAYAM, M.D, DNB, Dean, Stanley Medical College and Hospital, Chennai-1 for permitting me to do this study and use the resources of the college.

I am profoundly indebted to Prof. Dr. C. BALAMURUGAN M.S., Professor of General Surgery, Head of the Department, Stanley Medical College and hospital, for his constant and valuable support.

I consider it a privilege to have done this study under the supervision of my beloved Prof. Dr. ROSY ADHALINE SELVI., M.S who has been a source of constant inspiration and encouragement to accomplish this work.

I express my deepest sense of thankfulness to my Assistant Professors, Dr. MALARVIZHI M.S., Dr. PALANI MAHADEVAN M.S., Stanley Medical College and Hospital for their valuable inputs and constant encouragement without which this dissertation could not have been materialized.

INTRODUCTION :

Bowel resection and anastomosis have been done for many number of cases including bowel obstruction, perforation, gangrene, malignancy etc. In conventional technique, by applying double layered sutures, it causes narrowing of the bowel lumen and causes great tissue strangulation.

The technique for single layered closure is simple, easy, takes less time, uses less suture material than the conventional method. This technique also theoretically provides better post operative condition in which bowel anatomy and physiology can return to normal earlier, causing minimal tissue trauma and less narrowing of the lumen.

Hence in this article, patients with bowel anastomosis using these two techniques are compared and to see which technique is better for patient's safety.

AIMS AND OBJECTIVES :

To compare the results obtained from these two techniques and to asses the bowel's ability to regain the continuity after anastomosis using two different methods of suturing.

MATERIALS AND METHODS :

PLACE OF STUDY Department of general surgery, government Stanley medical college and hospital, Chennai

DURATION 12 months

STUDY DESIGN Cross sectional study

INCLUSION CRITERIA All patients who underwent laparotomy with bowel anastomosis

EXCLUSION CRITERIA Patients with comorbidities like diabetes, Tuberculosis, steroid abuse.

Patients with colo rectal anastomosis where the access is very restricted

SAMPLE SIZE 50

SAMPLE SIZE CALCULATION

By using the parent study, the prevalence of bowel anastomosis was found to be 15%(1).

By using the formula,

$N = 4pq/ d^2$

Where N = sample size

p = prevalence (15%)

q = 100-p (85%)

d = absolute precision (10%)

SAMPLE SIZE = 50

METHODOLOGY

Written informed consent will be obtained from the patients undergoing the procedure.

The patients with laparotomy and bowel anastomoses using these two techniques are included in this study.

During follow up, patients are divided into a control and test group. Control group patients are those who had two layered bowel anastomosis using vicryl (polygalactic acid) where the continuous sutures have been taken extramucosally as a first layer and then reinforced by suturing seromuscular layer across the previous one using silk as a second layer intermittently.

Test group patients are those who had single layered bowel anastomosis using vicryl where extramucosal sutures have been taken continuously as a single layer without any reinforcement. And the patients are followed.

Observations are tabulated according to the predesigned proforma.

The results are analyzed using Microsoft excel for tabular transformation and graphical representation.

For comparing the parameters, chi square test or fischer's exact test are used.

SPSS software will be used for statistical analysis.

REVIEW OF LITERATURE

EMBRYOLOGY

During the fourth week of gestation, the flat embryonic endoderm folds and fuses in the midline to create the gut tube. The tube consists of the foregut, midgut, and hindgut. The midgut, which will give rise to the distal duodenum, jejunum, and ileum, is located in the middle of this tube and is open to the yolk sac. During development, the connection between the midgut and the yolk sac will close and become only a thin stalk known as the vitelline duct. The endoderm will form the epithelial lining of the digestive tract, and the splanchnic mesoderm will give rise to the muscle, connective tissue, and peritoneal components of the gut wall.

Throughout gestation, the small intestine will lengthen and rotate. By the fifth to seventh weeks, the midgut will have outgrown the capacity of the abdominal cavity, forcing it into a hairpin loop configuration and then herniating into the umbilicus. As it herniates, the loop rotates 90 degrees counterclockwise. This rotation places the ileum in the left quadrant of the abdomen. Between the tenth and twelfth weeks, the abdominal cavity has grown and is now capable of containing the small intestine. As it retracts back into the abdomen, the jejunum and ileum will rotate an additional 180 degrees. By the

end of the twelfth week, the small intestine has rotated 270 degrees counterclockwise. The rotation of the intestines is important for establishing the permanent location of the abdominal organs. The proximal jejunum is positioned on the left side of the abdomen and the remaining loops of intestine will be displaced to the right.

The location of the duodenum is also affected by stomach rotation and pancreas development. As the stomach rotates during gestation, the duodenum will move to the right of the abdomen and up against the dorsal wall, and become retroperitoneal. The fusion of the ventral and dorsal pancreatic buds displaces the duodenum creating the characteristic C-loop.

CELL DIFFERENTIATION

It is known that the gut develops along four different axes: (1) anterior-posterior, (2) dorsal-ventral, (3) leftright, and (4) radial. The molecular mechanisms responsible for development along these axes are still being investigated. The development and differentiation of different regions of the gut is dependent on reciprocal interaction between the endoderm and the splanchnic mesoderm. In the initial stages of formation, the intestinal tract is lined by simple columnar endodermal epithelium that is surrounded by splanchnopleural mesoderm.

During the sixth week, the endodermal epithelium proliferates and occludes the lumen completely. Over the next 2 weeks, vacuoles will develop and coalesce to create a hollow tube. This process is known as recanalization. After this process is complete, the mucosal layer will develop villi as aggregates of mesoderm push throughthe epithelium. The submucosal connective tissue and smooth muscle layers arise from the mesodermal coating of the gut tube.

During the creation of the villi, pit-like intestinal crypts form at the base of the villi. Epithelial stem cells reside within the crypt and undergo a high rate of mitosis, which gives rise to the epithelial cells for the entire intestine. The epithelial cells within each crypt are of monoclonal origin. The stem cell divides into daughter cells, leaving one daughter cell anchored in the crypt, whereas the other continues to divide and migrate up the side of the crypt and onto the villus. This division and migration is responsible for renewing the intestinal lining in a rapid manner. While in utero, the stem cells will differentiate into one of the four major epithelial cell types: Paneth, enteroendocrine, goblet, or enterocyte.

At 12 weeks of gestation, cell differentiation has begun but maturation will continue during the fetal period and even in the first months of life. The cells will not develop digestive function until exposed to food.

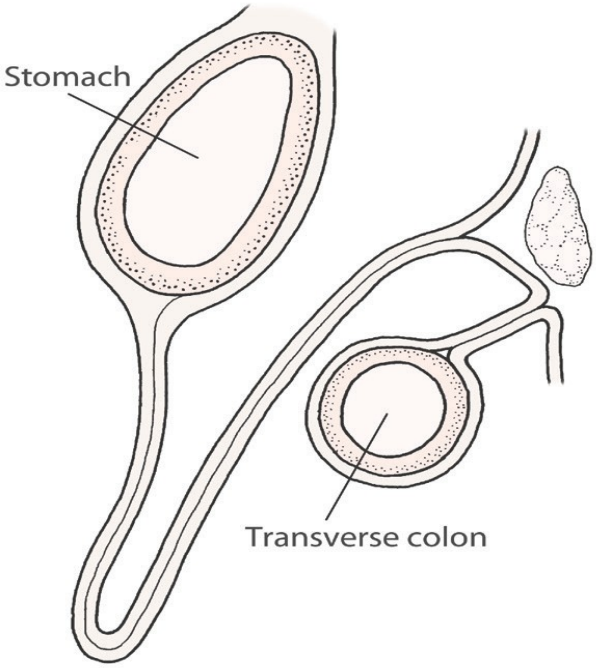

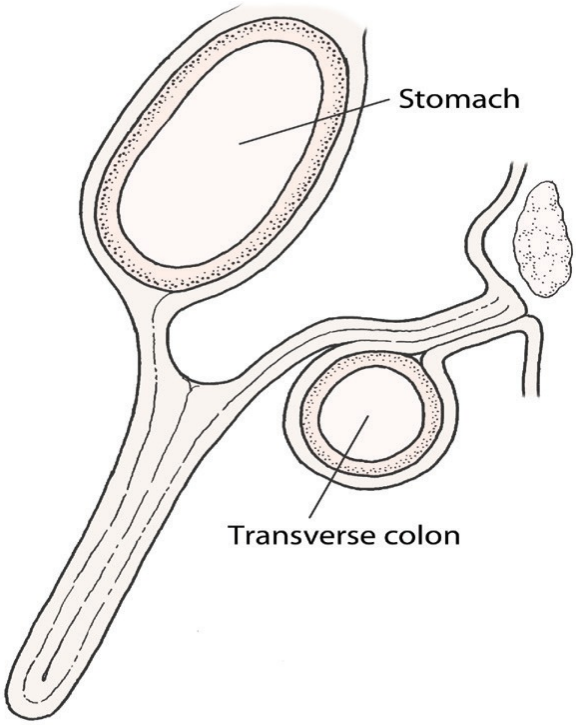

THE DEVELOPMENTAL ROTATION AND DIFFERENTIAL GROWTH OF THE GUT

ANATOMY OF BOWEL:

SMALL INTESTINE : The small intestine is the longest part of the gastrointestinal tract and extends from the pyloric orifice of the stomach to the ileocecal fold. This hollow tube, which is approximately 6 – 7 m long with a narrowing diameter from beginning to end, consists of the duodenum, the jejunum, and the ileum.

JEJUNUM

The jejunum and ileum make up the last two sections of the small intestine. The jejunum represents the proximal two-fifths. It is mostly in the left upper quadrant of the abdomen and is larger in diameter and has a thicker wall than the ileum. Additionally, the inner mucosal lining of the jejunum is characterized by numerous prominent folds that circle the lumen (plicae circulares). The less prominent arterial arcades and longer vasa recta (straight arteries) compared to those of the ileum are a unique characteristic of the jejunum.

The arterial supply to the jejunum includes jejunal arteries from the superior mesenteric artery.

ILEUM

The ileum makes up the distal three-fifth of the small intestine and is mostly in the right lower quadrant. Compared to the jejunum, the ileum has thinner walls, fewer and less prominent mucosal folds (plicae circulares),

shorter vasa recta, more mesenteric fat, and more arterial arcades.

The ileum opens into the large intestine where the cecum and ascending colon join together. Two flaps projecting into the lumen of the large intestine (the **ileocecal fold**) surround the opening. The flaps of the ileocecal fold come together at their end forming ridges. Musculature from the ileum continues into each flap, forming a sphincter. Possible functions of the ileocecal fold include preventing reflux from the cecum to the ileum, and regulating the passage of contents from the ileum to the cecum.

The arterial supply to the ileum includes:

■ ileal arteries from the superior mesenteric artery; and

■ an ileal branch from the ileocolic artery (from the superior mesenteric artery).

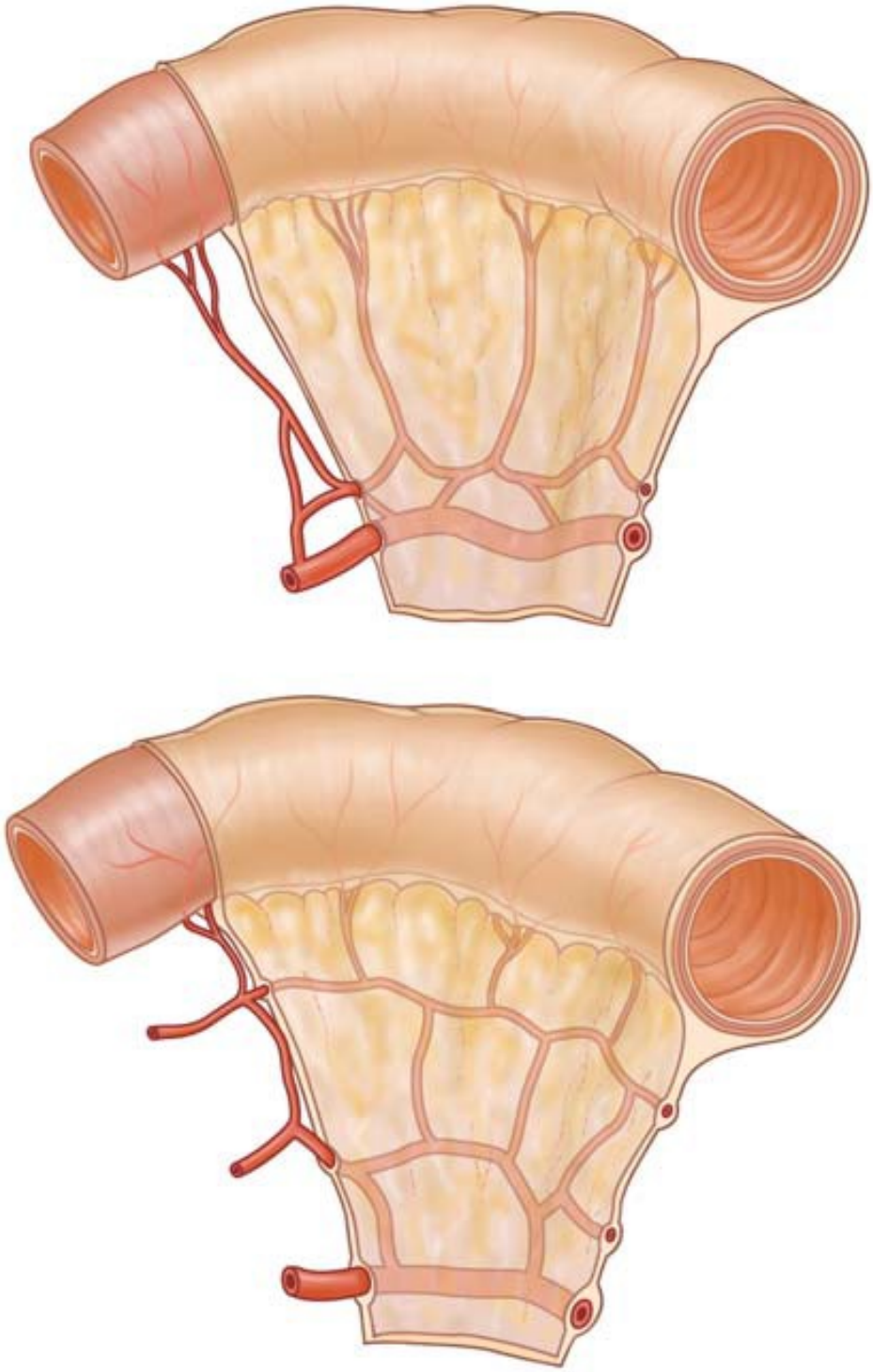

JEJUNUM AND ILEUM

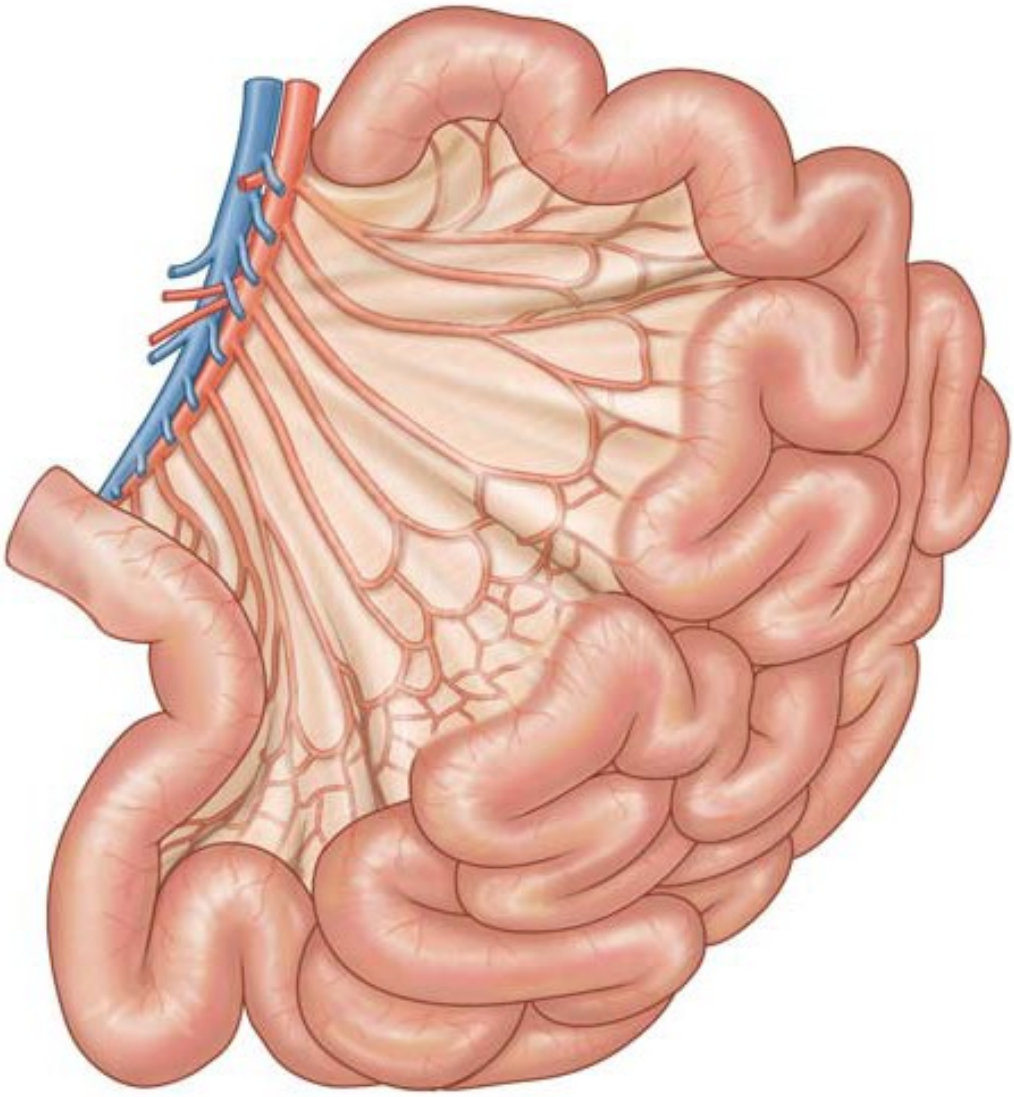

ARTERIAL SUPPLY OF SMALL BOWEL FROM SUPERIOR MESENTRIC ARTERY

LARGE INTESTINE

The large intestine extends from the distal end of the ileum to the anus, a distance of approximately 1.5 m in adults. It absorbs fluids and salts from the gut contents, thus forming feces, and consists of the cecum, appendix, colon, rectum, and anal canal. Beginning in the right groin as the cecum, with its associated appendix, the large intestine continues upward as the **ascending colon** through the right flank and into the right hypochondrium. Just below the liver, it bends to the left, forming the **right colic flexure** (**hepatic flexure**), and crosses the abdomen as the **transverse colon** to the left hypochondrium. At this position, just below the spleen, the large intestine bends downward, forming the **left colic flexure** (**splenic flexure**), and continues as the **descending colon** through the left flank and into the left groin. It enters the upper part of the pelvic cavity as the sigmoid colon, continues on the posterior wall of the pelvic cavity as the rectum, and terminates as the anal canal.

The general characteristics of most of the large intestine

■ its large internal diameter compared to that of the smallintestine;

■ peritoneal-covered accumulations of fat (the **omental appendices**) are associated with the colon;

■ the segregation of longitudinal muscle in its walls into three narrow bands (the **taeniae coli**), which are primarily observed in the cecum and colon and less visible in the rectum;

■ the sacculations of the colon (the **haustra of colon**) **Colon**

The colon extends superiorly from the cecum and consists of the ascending, transverse, descending, and sigmoid colon. Its ascending and descending segments are (secondarily) retroperitoneal and its transverse and sigmoid segments are intraperitoneal. At the junction of the ascending and transverse colon is the right colic flexure, which is just inferior to the right lobe of the liver. A similar, but more acute bend (the left colic flexure) occurs at the junction of the transverse and descending colon. This bend is just inferior to the spleen, higher and more posterior than the right colic flexure, and is attached to the diaphragm by the phrenico colic ligament.

Immediately lateral to the ascending and descending colons are the **right** and **left paracolic gutters.** These depressions are formed between the lateral margins of the ascending and descending colon and the posterolateral abdominal wall and are gutters through which material can pass from one region of the peritoneal cavity to another. Because major vessels and lymphatics are on the medial or posteromedial sides of the ascendingand descending colon, a relatively blood-free mobilization of the ascending and descending colon is possible by cutting

the peritoneum along these lateral paracolic gutters. The final segment of the colon (the sigmoid colon) begins above the pelvic inlet and extends to the level of vertebra SIII, where it is continuous with the rectum.

This S -shaped structure is quite mobile except at its beginning, where it continues from the descending colon, and at its end, where it continues as the rectum. Between these points, it is suspended by the sigmoid mesocolon.

The arterial supply to the ascending colon includes:

■ the colic branch from the ileocolic artery (from the superior mesenteric artery);

■ the anterior cecal artery from the ileocolic artery (from the superior mesenteric artery);

■ the posterior cecal artery from the ileocolic artery (from the superior mesenteric artery); and

■ the right colic artery from the superior mesenteric artery.

The arterial supply to the transverse colon includes

■ the right colic artery from the superior mesenteric artery;

■ the middle colic artery from the superior mesenteric artery; and

■ the left colic artery from the inferior mesenteric artery.

The arterial supply to the descending colon includes the left colic artery from the inferior mesenteric artery.

The arterial supply to the sigmoid colon includes sigmoidal arteries from the inferior mesenteric artery

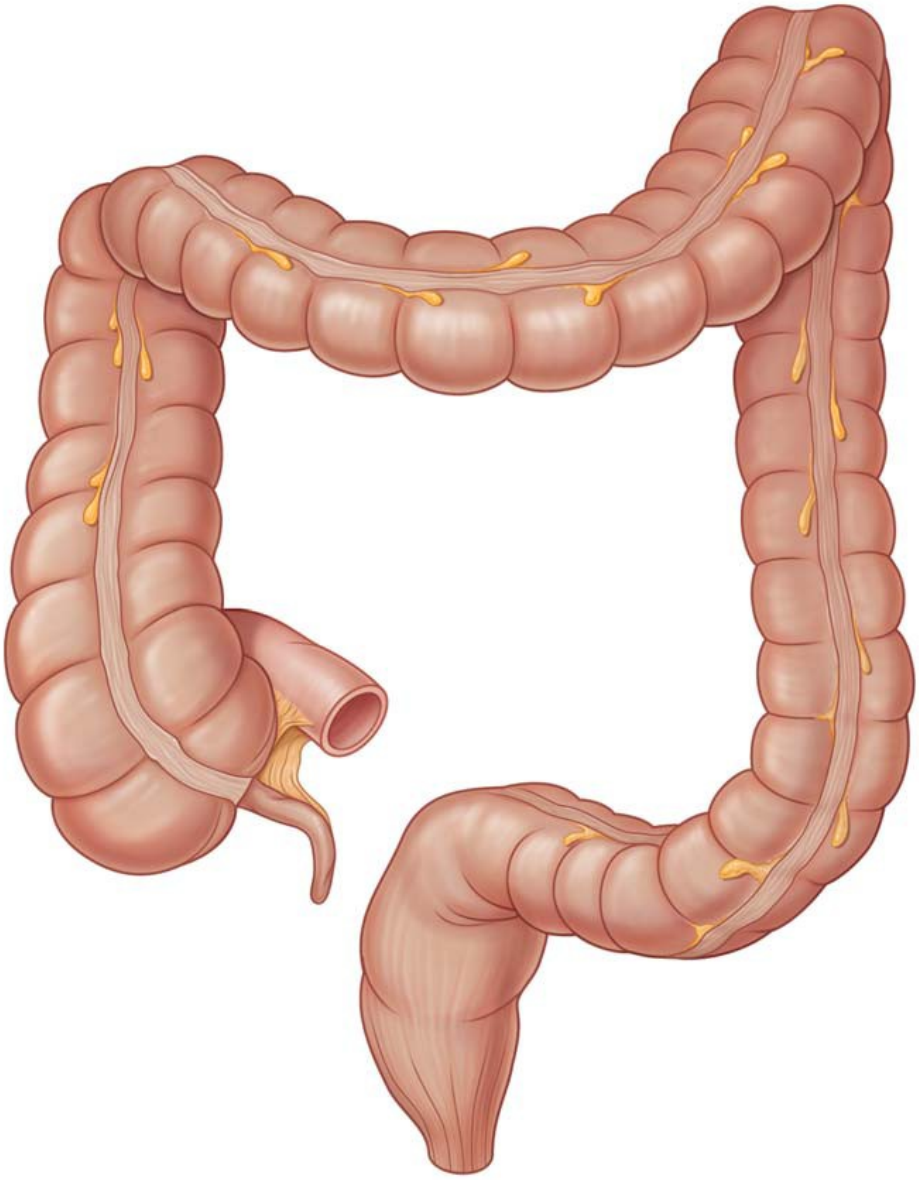

LARGEINTESTINE

VASCULATURE

ARTERIAL SUPPLY

The small intestine is derived from the embryonic gut tube regions of the foregut and midgut. The celiac artery supplies the foregut and the superior mesenteric artery(SMA) supplies the midgut. The duodenum is both a foregut and midgut structure and thus receives dual blood supply. The jejunum and ileum are midgut structures and receive arterial blood from the SMA only.

The celiac trunk gives rise to the common hepatic artery that divides into the proper hepatic artery and the gastroduodenal artery (GDA). The proper hepatic artery will supply the liver and the GDA will supply branches to the duodenum, stomach, and pancreas. The anterior superior and posterior superior pancreaticoduodenal arteries arise from the GDA and supply blood to the second and third portion of the duodenum as well as the pancreas.

The SMA branches directly off of the aorta and supplies blood to the majority of the small intestine, pancreas, and proximal large intestine. The SMA gives rise to several branches that are important surgically. The posterior inferior and anterior inferior pancreaticoduodenal arteries anastomose with the superior pancreaticoduodenal arteries from the GDA to supply blood to the duodenum and pancreas. The intestinal arteries are branches from the SMA that create a unique network of

arteries known as an arcade that supply the jejunum and ileum. Arterial branches known as vasa recta run from the arcade to the intestinal wall. These arteries then bifurcate and travel along the intestinal wall to provide adequate blood flow. The vasa recta represent another anatomic variant to help distinguish the jejunum from the ileum. The vasa recta of the jejunum are straight and long, whereas those supplying blood to the ileum are arborized and short. The ileocolic artery supplies blood to the ileum, cecum, and appendix.

VENOUS DRAINAGE

The venous drainage of the small intestine mirrors the arterial supply. The duodenum empties into the pancreaticoduodenal, the right gastroepiploic, and the portal vein. The jejunum and ileum are drained by the superior mesenteric vein, which will join with the splenic vein to drain into the portal vein.

LYMPHATICS

There are several levels of lymphatic drainage of the small intestine that follow the vasculature. The lymph drains into the nodal chain adjacent to the bowel wall and then into the nodes of the mesenteric arcade. From there the lymphatic vessels follow along the trunk of the SMA. The large lymphatic channel will course parallel to

the aorta and join with the two lumbar lymphatic trunks to drain into the cysterna chyli. The cysterna chyli is located below the level of the diaphragm at the end of the thoracic duct anterior to the lumbar spine and posterior to the aorta. Once lymph collects in this dilated sac, it will then pass through the aortic opening of the diaphragm and flow into the main thoracic duct. The thoracic duct runs parallel with the aorta and empties into the subclavian vein where it joins with the jugular vein.

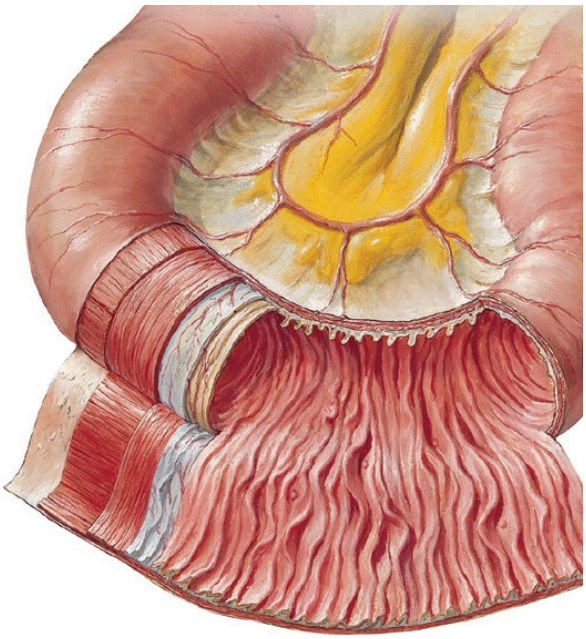

LAYERS OF JEJUNUM

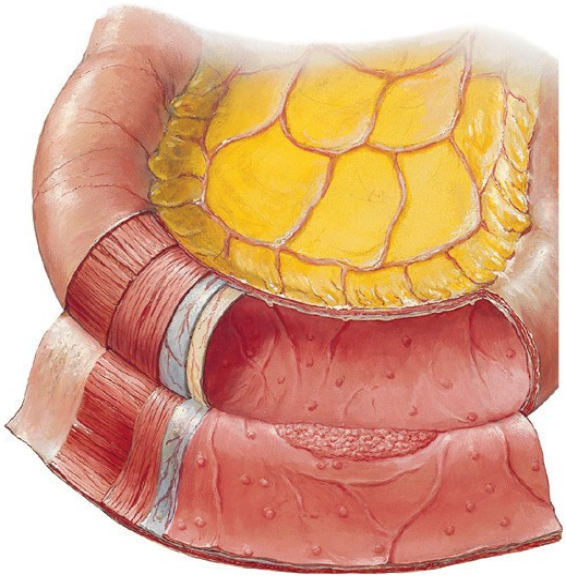

LAYERS OF ILEUM

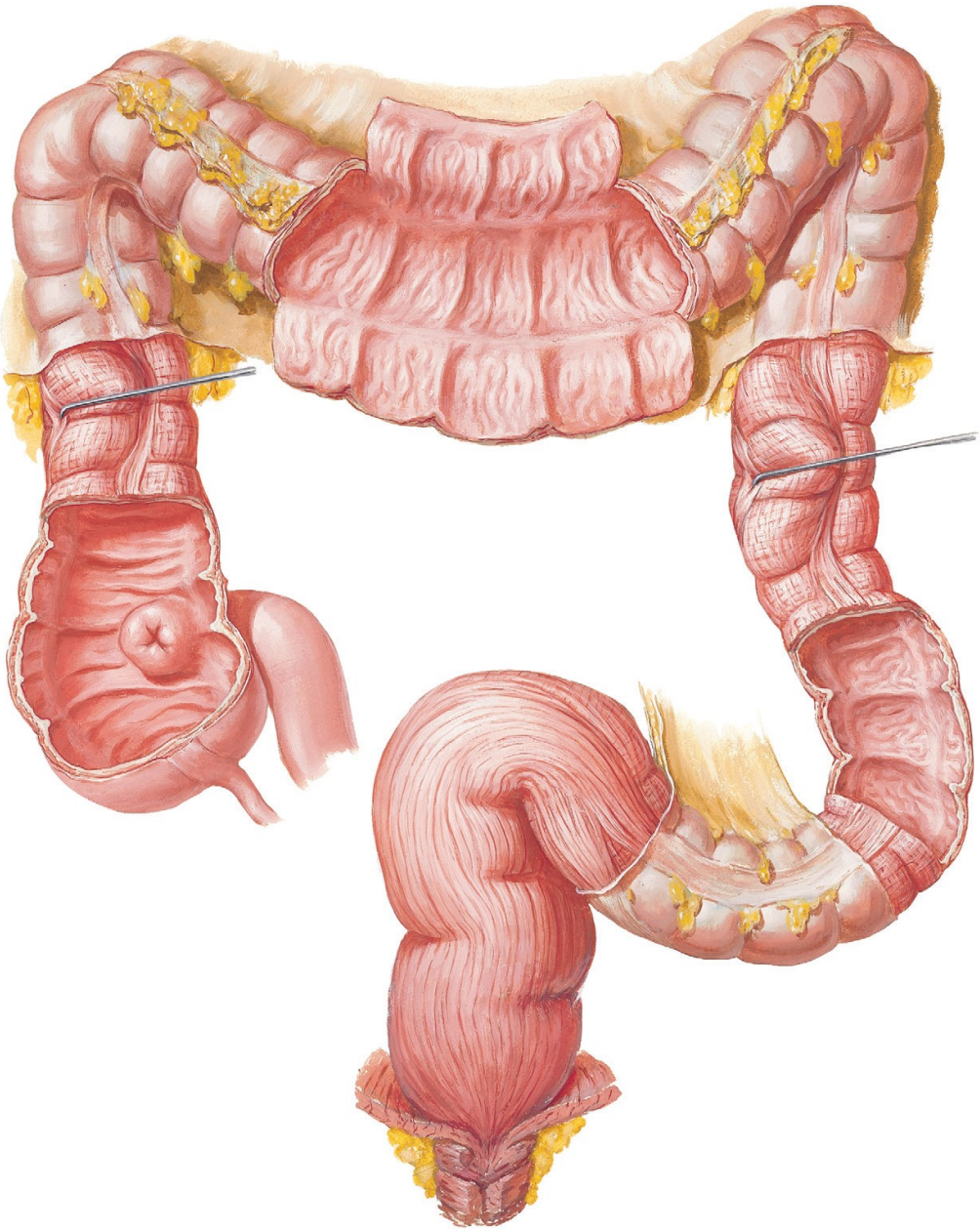

LAYERS OF COLON

PHYSIOLOGICAL ANATOMY OF THE GASTRO INTESTINAL WALL

Cross section of the intestinal wall, including the following layers from the outer surface inward: (1) the *serosa,* (2) a *longitudinal smooth muscle layer,* (3) a *circular smooth muscle layer,* (4) the *submucosa,* and (5) the *mucosa.* In addition, sparse bundles of smooth muscle fibers, the *mucosal muscle,* lie in the deeper layers of the mucosa. The motor functions of the gut are performed by the different layers of smooth muscle.

Gastrointestinal Smooth Muscle Functions as a Syncytium.

The individual smooth muscle fibers in the gastrointestinal tract are 200 to 500 micrometers in length and 2 to 10 micrometers in diameter, and they are arranged in bundles of as many as 1000 parallel fibers. In the *longitudinal muscle layer,* the bundles extend longitudinally down the intestinal tract; in the *circular muscle layer,* they extend around the gut.

Within each bundle, the muscle fibers are electrically connected with one another through large numbers of *gap junctions* that allow low-resistance movement of ions from one muscle cell to the next. Therefore, electrical signals that initiate muscle contractions can travel

readily from one fiber to the next within each bundle but more rapidly along the length of the bundle than sideways.

Each bundle of smooth muscle fibers is partly separated from the next by loose connective tissue, but the muscle bundles fuse with one another at many points, so in reality each muscle layer represents a branching latticework of smooth muscle bundles. Therefore, each muscle layer functions as a *syncytium;* that is, when an action potential is elicited anywhere within the muscle mass, it generally travels in all directions in the muscle. The distance that it travels depends on the excitability of the muscle; sometimes it stops after only a few millimeters, and at other times it travels many centimeters or even the entire length and breadth of the intestinal tract.

Also, because a few connections exist between the longitudinal and circular muscle layers, excitation of one of these layers often excites the other as well.

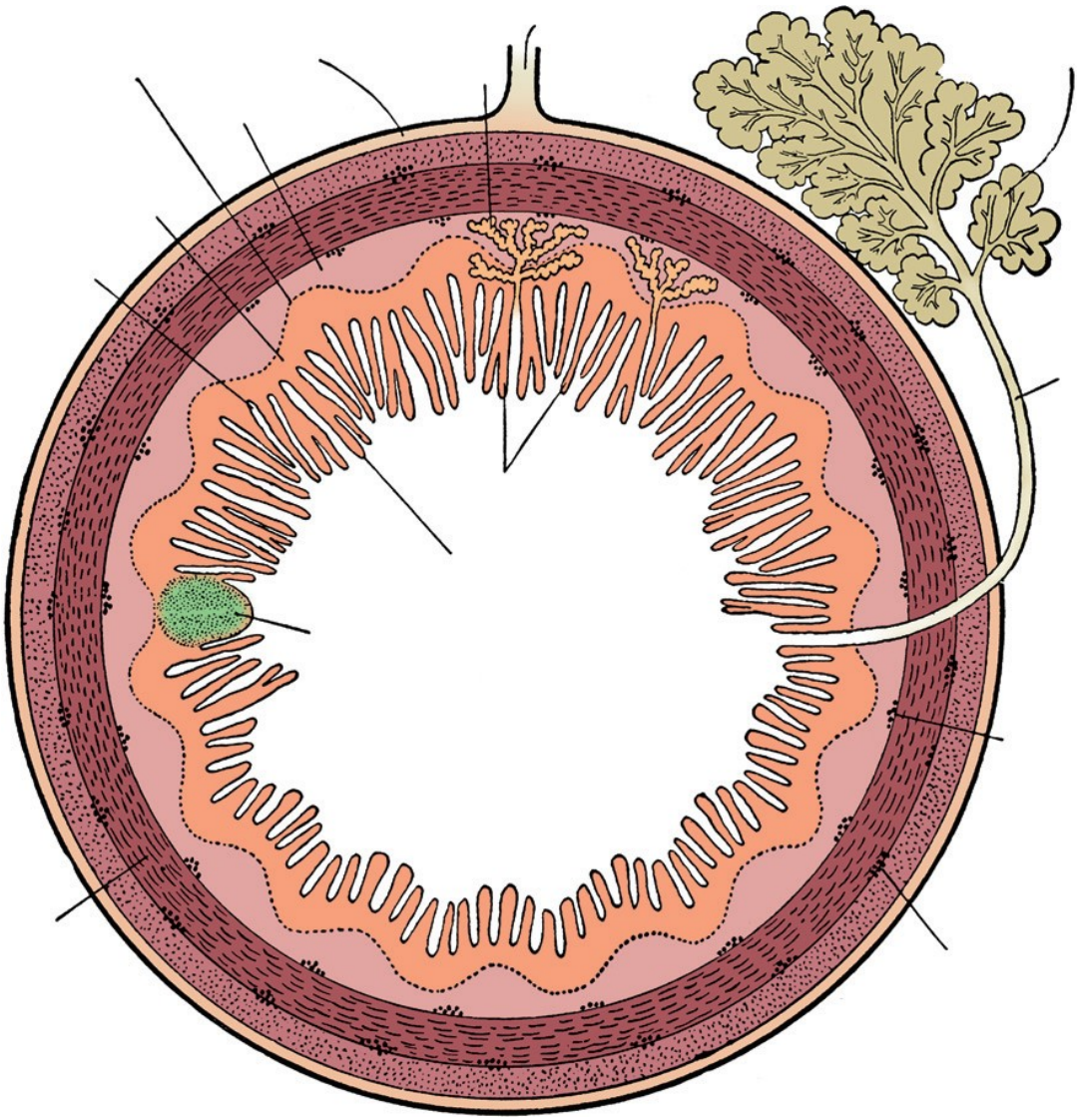

SCHEMATIC CROSS SECTION OF SMALL INTESTINE

PRINCIPLES OF INTESTINAL ANASTOMOSIS

The term anastomosis has been derived from a Greek word, with a literal meaning of ‘without a mouth’. In modern day surgical practice, the term anastomosis can be defined as a joining of two hollow viscera with intention to restore continuity.

The need for anastomosis arise if a portion of hollow tubular viscous has been surgically removed or destroyed by trauma, or there is a distal obstruction. In general surgery an anastomosis may involve:

- Gut – intestinal anastomosis
- Vessel – vascular anastomosis
- Urinary tract
- Biliary tract
- Pancreatic tract

HISTORICAL ASPECTS

In 1826, Antonie lambert, a French surgeon described a seromuscular suturing technique , which has proved to be the mainstay of all gastrointestinal surgeries.

Nicholas sen from USA in 1893 described a two layered technique of intestinal anastomosis , using silk and ordinary sewing needles.

Halsted, a famous surgeon described a single layer closure without incorporation of mucosa.

Connell in 1903 from Chicago, USA described an interrupted single layer technique of intestinal anastomosis with knots lying intraluminally and bites going through all layers.

Kocher described a two layered technique using silk and catgut.

Current method of single layer extramucosal anastomosis was advocated by matheson of Aberdeen.

IDEAL ANASTOMOSIS

An ideal anastomotic technique should have the following features:

- Zero leak rates
- Promotes early recovery of function
- No vascular compromise of the cut margins of a gut
- Should not narrow the lumen of the gut
- Easy to learn, teach and perform
- Technique should preferably be quick to perform.

Such an ideal technique is still to emerge.

BLOOD SUPPLY

For sound healing a good blood supply to both sides of an anastomosis is crucial. It may be possible to see the vessels in the mesentery or, in an obese patient, to feel for their pulsation in order to choose a site for resection where the blood supply of the divided bowel will be optimal. The viability of the ends must be confirmed before commencing the anastomosis.

The mucosa should be pink and the bleeding from cut submucosal vessels should be bright red. (This sign is lost if the bowel is divided by diathermy.) If an artery close to the bowel wall at the level of the anastomosis is divided

before ligation, pulsatile arterial bleeding from the cut end is an extra reassurance. In general, the blood supply to the colon is more precarious than that to the small bowel and stomach. A dusky grey-pink mucosa and bleeding that is the dark ooze of venous back-bleeding are indications that the circulation is inadequate for an anastomosis. The ends must then be resected back to healthy, well-perfused tissue. In a side-toside anastomotic bypass, blood supply is unlikely to be of concern.

TENSION

The two sides of the anastomosis must lie easily together without tension, which increases the danger of disruption. The surgeon must take into account the likely postoperative increase in tension secondary to inflammatory swelling and ileus. Changes in body position and the filling of the stomach or bladder will also change the alignment and the tension of an anastomosis to these organs. Where there is concern, further mobilisation of the ends, without causing damage to the blood supply, is required. If this cannot be achieved, a more sophisticated method of restoring continuity is required.

ANASTOMOTIC DIAMETER

An end-to-end anastomosis inevitably reduces the lumen at the site of the anastomosis, whether hand-sutured or stapled.

Temporarily, the lumen is further narrowed by postoperative oedema, and if it becomes obstructed, the risk of anastomotic breakdown is increased. This problem is greater if the lumen is of small diameter or the luminal contents are viscous. The traditional sutured two-layer anastomotic technique – which is now seldom used for intestinal end-to-end anastomoses – narrowed an anastomosis significantly as the suture line was invaginated.

Paediatric surgeons changed to a single-layer technique before general surgeons, as the narrowing was more critical in the narrow lumen of the neonatal bowel. A side-to-side anastomosis can be fashioned with whatever anastomotic diameter the surgeon chooses. A hand-sewn, end-to-end anastomosis may be enlarged by an oblique division of the ends, or an enlargement can be created by cutting back on the anti-mesenteric border. This is also a useful manoeuvre if the diameters of the two ends are significantly disparate. Temporary intubation of an anastomosis may be protective and is sometimes used for the biliary tract, the pancreatic ducts and the ureter.

MESENTERY

On completion of an anastomosis there is usually a Mesenteric defect, which is a potential site for an ‘internal hernia’. Small bowel may pass through this defect, with resultant volvulus or strangulation, and most surgeons believe that these defects should be closed.

The suture material and method of closure are not important, but care must be taken to avoid injury to mesenteric vessels. A stitch that only picks up the peritoneum of the mesentery is safest.

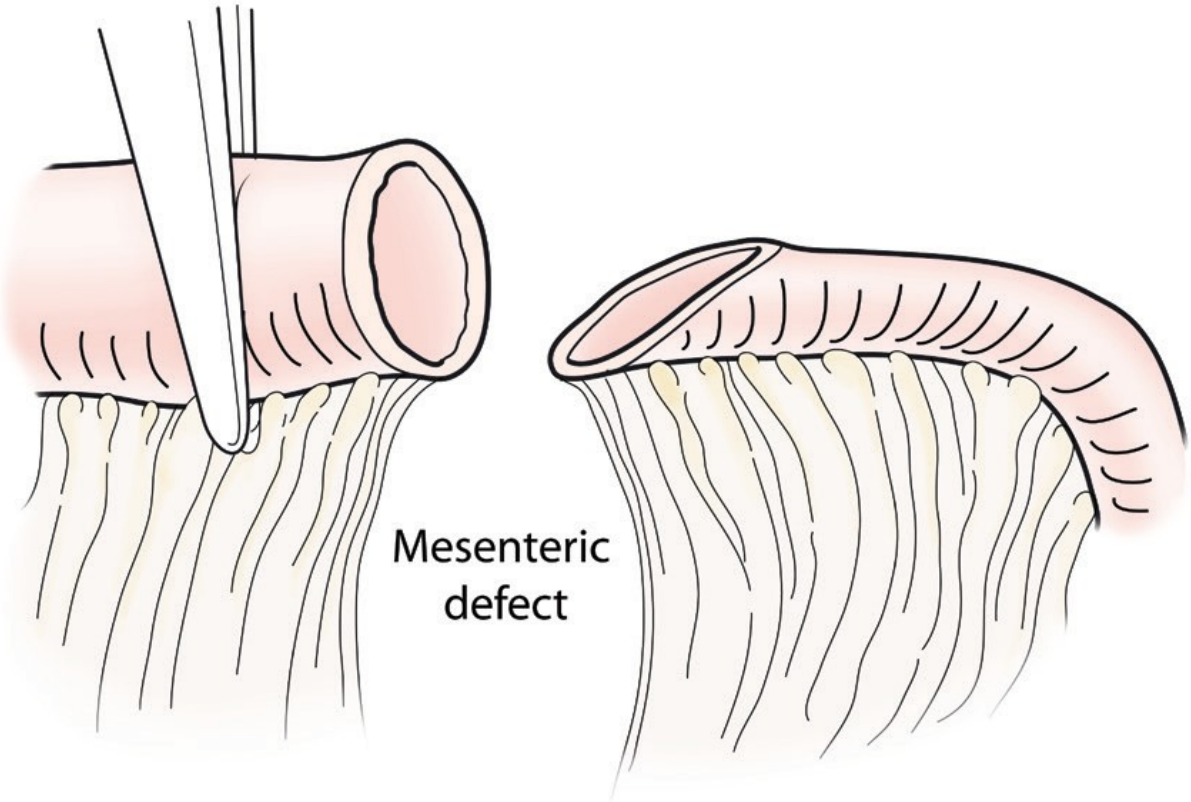

DRAINS

A surgeon may be concerned about an anastomosis because of a marginally adequate blood supply or minimal tension. There may have been peritonitis at the time of surgery or the patient's general condition may be poor. The surgeon may then consider 'protecting' the vulnerable anastomosis with a drain. However, sutures or staples can hold non-viable tissue in position and delay a leak for 1–2 weeks. The drain would have to remain *in situ* for 2 weeks to be of any value in this situation, and there is some concern that a drain in contact with an anastomosis for this length of time could in itself cause damage. However, pancreatic anastomoses are particularly prone to delayed leaks and, therefore, are commonly drained and the drain left *in situ* until this period of danger is passed.

There are, though, some instances where a short-term drain may be of value. For example, many sound urological anastomoses leak a considerable volume of urine during the first 72 hours but then seal and heal satisfactorily, and in biliary surgery a significant bile leak may be identified early if a drain is *in situ*. An infected haematoma that has collected in the 'dead space' of the emptied pelvis after a low anterior resection is believed to be one of the causes of anastomotic breakdown when it later discharges through the anastomosis. A short-term pelvic suction drain is therefore often employed to prevent this collection and to protect the anastomosis.

Low-pressure suction is preferable to high-pressure suction, which may draw tissue into the drain and cause damage. In addition, low-pressure suction is often more effective as the drain holes are less likely to be occluded by tissue drawn into them.

NO EXCESSIVE FORCE

Force must not be excessive when tying the anastomotic sutures, as it would result in strangulation of tissue. If the suture should inadvertently have been placed through the full thickness of the bowel and into the lumen, the strangulated tissue will cause a leak. Tie sutures with no more tension than is needed to approximate both intestinal walls.

NO EXCESSIVE FORCE APPLIED TO THE FORCEPS

When manipulating the ends of the bowel to be anastomosed, there must be no excessive force. If the imprint of forceps teeth is visible on the serosa after the forceps have been removed, the surgeon obviously compressed the tissue with too much force. Pass the curved needle through the tissue with a rotatory motion to minimize trauma. It does not matter whether an intestinal anastomosis is sutured or stapled so long as proper technique is employed.

AVOID COMMON ERRORS

One must avoid the common errors seen among neophytes learning the art of anastomotic suturing:

Do not insert the outer layer of seromuscular sutures with the collapsed bowel resting on a flat surface. An even worse error consists in putting the left index finger underneath the back of the anastomosis while inserting the anterior seromuscular sutures. Both errors make it possible to pass the seromuscular suture through the bowel lumen and catch a portion of the posterior wall. When the sutures are tied, an obstruction is created. Although some of these sutures may later tear out of the back wall in response to peristalsis, others remain permanently in place and produce a stenosis. To prevent this complication, simply have the assistant *grasp the tails of the anastomotic sutures that have already been tied* . Skyward traction on these sutures keeps the lumen of the anastomosis open while the surgeon inserts additional sutures. Another error consists in inserting anastomotic sutures while the bowel is under linear tension. This practice stretches the bowel wall, so it becomes relatively thin, making it difficult to enclose a substantial bite of tissue in the suture. *A sufficient length of intestine* , *proximal and distal* , *should be loosely placed in the operative field* .

After the first seromuscular bite has been taken, the needle is ready to be reinserted into the wall of the opposite

segment of intestine. At this time it is often helpful to use forceps to elevate the distal bowel at a point 3–4 cm distal to the anastomosis. Elevation relaxes this segment of the bowel and permits the suture to catch a substantial bite of tissue, including the submucosa. Each bite should encompass about 4–5 mm of tissue. These stitches should be placed about 4–5 mm from each other.

Contraindications to Anastomosis

Because of the excellent blood supply and substantial submucosal strength of the small bowel, anastomoses are often successful even in the presence of such adverse circumstances as intestinal obstruction and gross contamination of the abdominal cavity. Consequently, the only major contraindications to a primary small bowel anastomosis are peritoneal sepsis, a questionable blood supply, or a patient whose condition on the operating table is precarious. In these cases both ends of the divided small bowel may be brought to the skin as temporary enterostomies or simply stapled closed and returned to the abdomen for a planned second look.

COMPLICATIONS OF BOWEL ANASTOMOSIS

Complications can occur at any time along the course of surgery and the postoperative course. Intra operative complications can occur at any time due to inadvertent injury to any nearby structures. Small bowel enterotomies may take place during lysis of adhesions or colonic dissection and if unrecognized may result in peritonitis and need for subsequent exploration. Bowel could also be injured during the insertion of laparoscopic instruments. Predisposing factors are related to previous surgery involving the retroperitoneal plane, prior radiation, and active retroperitoneal or pelvic sepsis or technical errors that occur when straying away from the correct surgical plane.

Surgical wound infection is the common complication following anastomoses. Perioperative antibiotics are given with the goal of decreasing these events. Good glycemic control is also important in lowering risks for wound infection.

Anastomotic leaks are more common in patients with inflammatory bowel disease. Pelvic abscess may also occur in association with an anastomotic leak or due to an infection of hematoma collection.

Small contained leaks can usually be managed nonoperatively with bowel rest and percutaneous drainage of associated abscess. Large leaks or anastomotic disruptions associated with systemic manifestation will require reoperation and resection of the anastomosis and enterostomy will be kept. 3 to 6 months after the patient recovered, another attempt at restoring the continuity may be considered.

Finally recurrence of certain diseases for which ileal or ileocolic resection and ileo colic anastomosis done can be a problematic and may ultimately require end ileostomy.

Fifty percent to eighty percent of patients are found to have persistent abdominal pain following surgery although some do report improvement in intensity.

TYPES OF ANASTOMOSIS

- End to end anastomosis
- End to side anastomosis
- Side to side anastomosis

INTESTINAL ANASTOMOSIS : intestinal anastomosis may involve

- Joining two ends of similar gut, i.e. jejunojejunal or ileo ileal or colo colic.
- Joining two types of gut, i.e. esophagus and jejunum, stpmach and jejunum, ileum and colon or rectum.
- Joining of gut with another hollow tubular structure, e.g.
  a. Common hepatic duct and jejunum : hepaticojejunostomy
  b. Common bile duct and duodenum : choledochoduodenostomy
  c. Common bile duct and jejunum : choledocho jejunostomy
  d. Gall bladder and jejunum : cholecysto jejunostomy
  e. Pancreatic duct and jejunum : pancreatico jejunostomy

SUTURED END TO END ANASTOMOSES

Sutured end-to-end small bowel anastomosis is often the first that a trainee surgeon performs. Mobility makes the surgery technically easy, the blood supply is good and breakdown uncommon. As discussed

already, the two ends must have a good blood supply and be able to be brought together easily without tension. Discrepancies in diameter between the ends can be adjusted by the spacing of sutures, as the bowel wall is elastic.

Alternatively, the smaller-lumened tube can be cut at the antimesenteric border to equalise the diameter. Care should be taken over orientation, because if there is ample mobility, then one end can be inadvertently rotated. The anastomosis should be undertaken without fear of spillage of contents during the procedure, and non-crushing occlusion clamps may be necessary. They are placed proximally and distally to isolate the area of bowel to be opened from ongoing inflow of gastrointestinal contents until the anastomosis is complete. However, this has the disadvantage of compromising the blood supply, which may be critical to the healing of the anastomosis. Alternatively, a sucker with guard can be introduced into the divided bowel ends and guided up the lumen to clear contents.

Minor bleeding points in the submucosa can be ignored. Precise coagulation diathermy will arrest the more troublesome bleeding points, but many surgeons prefer to divide the bowel with diathermy to reduce bleeding.

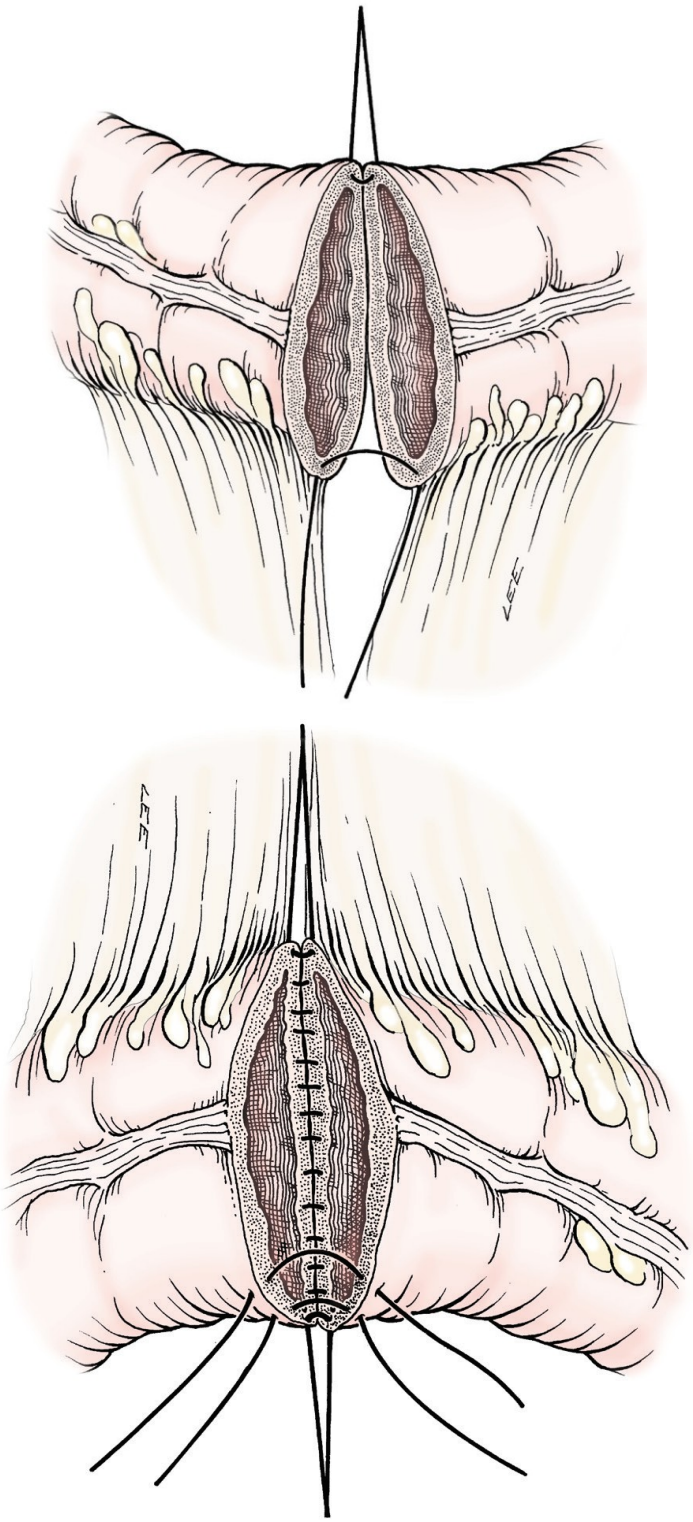
LEE
LEE

TECHNIQUE

A single layer of interrupted extramucosal sutures is now favoured by the majority of surgeons. A continuous suture acts like a drawstring and will tend to narrow the lumen, especially in the early phase when postoperative swelling further tightens the suture. In addition, a continuous suture reduces the blood supply to the cut ends; this is disadvantageous except in very vascular areas where a haemostatic suture may be beneficial. Sutures that include the mucosa have no advantage other than haemostasis. They do not add significantly to the strength of the anastomosis nor do they improve apposition, as the mucosa already lies in apposition after accurately placed extramucosal sutures. Mucosa heals rapidly, and a watertight seal will have formed within 24 hours. Sutures that include the mucosa merely delay this by the trauma and ischaemia that they cause, and in experimental models, a small mucosal ulcer can be seen at each suture site.

Historically, when two layers of sutures were used routinely, it was believed that the second seromuscular layer was important to invaginate and bury the mucosa of the cut ends. This does not confer any benefit and causes narrowing and greater tissue strangulation.

The first two sutures are placed to unite the two ends at the mesenteric and antimesenteric borders, and they divide the anastomosis into two

equal sections. These sutures are tied, the ends left long and held in artery forceps. Each suture should start on the outside and emerge between the mucosa and the muscularis mucosa. It is important to include the muscularis mucosa, which is visible as a white line, as it has significant strength. These layers are distinct and mobile on each other if the bowel has been cut with scissors or a scalpel. Diathermy division of the bowel to some extent 'fuses' the layers, and the anatomy of the layers may be less distinct. The ideal size of the suture bite may be difficult to judge. A larger bite has less danger of cutting out, but it creates a larger bulk of potentially strangulated tissue to narrow the lumen. In the adult small bowel a reasonable compromise is to introduce the suture 0.5 cm from the cut end. The suture is then introduced into the other cut bowel end between the muscularis mucosa and the mucosa and brought out through the peritoneal surface(0.5 cm from the cut end). Care must be taken as the throws on the knot are tightened to prevent the whole suture tightening and strangulating the tissue. The spacing of sutures is difficult to judge, and the temptation to place them very close, in anticipation of the dilatation of postoperative ileus, should be resisted. The additional compromise to the blood supply outweighs any benefits of an apparently more watertight early closure. In an adult small bowel, sutures at intervals of 0.5 cm are a satisfactory compromise. Subsequent sutures are placed until half of the anastomosis is complete. The bowel is then turned over and the other half completed.

In most other situations access is less ideal, and it is important to complete the back wall of the anastomosis first. A similar technique to that described above can be employed if the surgeon starts at the back corner, which is furthest away, and this first suture is left long as a stay suture. This suture makes the placement of the next suture easier, and it is possible to continue along the back wall of the anastomosis until the back corner nearest the surgeon is reached. This last suture is also left long as a stay suture. The front wall is then anastomosed. Another alternative is to introduce the sutures along the back wall of the anastomosis from within the bowel lumen. These sutures have knots in the submucosal plane, which in theory is less than ideal but in practice is satisfactory. In a difficult anastomosis, where access is very restricted, sutures may be *parachuted* or *railroaded* into position. The two ends are only apposed after all sutures are in place. Many of these problems, which are encountered particularly in oesophageal and rectal anastomoses, can be overcome by use of a circular stapling device. In some structures, such as the common bile duct, a separate mobile mucosa may not be apparent. The interrupted sutures should then be placed full thickness if it is not practical to exclude the mucosa.

An *end-to-side sutured anastomosis* is merely an adaptation of the end-to-end technique. An incision is made in the side of the viscus to which the end is to be joined. The length of the incision should be such that

there are two equal ‘lumens’ for the anastomosis. The suture technique used is similar to that described for an end to end anastomosis

SUTURED SIDE TO SIDE ANASTOMOSIS

This is a useful anastomosis when a segment of gastrointestinal tract is to be left *in situ* but bypassed. It may be undertaken in a similar fashion to the end-to-side anastomosis described above and constructed with a single layer of interrupted sutures. If, however, both sides of the anastomosis have a rich blood supply, making haemostasis of the cut ends important, a continuous suture technique has advantages. A second suture layer also adds stability to the anastomosis and there need be no concern in a wide side-to-side anastomosis that a two-layer continuous technique will significantly narrow the anastomotic diameter. Side-to-side anastomosis is a method commonly employed in anastomoses between the stomach and small bowel. The traditional, hand-sewn technique for gastroenterostomy or enteroenterostomy is described below.

Most surgeons use clamps for this operation in order to steady the gut, control haemorrhage and prevent the escape of contents, but others prefer to rely on a skilled assistant. The clamps must be of the light *occlusion* type, which will cause minimum trauma to the segment of each viscus included in the clamp. An 8- or 9-cm portion should be held

within the clamp for a gastroenterostomy, but for an enteroenterostomy about half of this length will suffice. A swab is laid underneath to absorb any spillage and the two clamps are approximated. They are secured with a locking device or are tied together. The outer suture is a continuous seromuscular suture, and the inner suture is an 'alllayer' continuous suture. This is achieved by four separate suturing manoeuvres.

Posterior seromuscular suture. This is a continuous absorbable suture that does not include the mucosa and that unites the adjacent surfaces of gut. A short end is retained in forceps at the start of this layer and, at completion, the suture is retained for later use as the anterior seromuscular suture. The suture is tied to the loop of the last stitch at the end of the posterior seromuscular layer. This locks the continuous suture and also provides a loop of suture material that can be held in artery forceps as a stay suture to steady the anastomosis when the clamps are removed. The lumen of each segment is now opened, within the limits of the posterior seromuscular suture, by an incision parallel to the suture line and approximately 5 mm from it. The incision for a gastroenterostomy will therefore be about 5–6 cm. In the first instance, the incision should be made through the serosal and muscular coats only; the mucosa is then picked up with forceps and incised separately. If diathermy is used

for the incision, care must be taken to avoid injury to the opposite mucosal layer. On occasions when no clamps are employed, a sucker should be introduced through the initial mucosal incision to remove contents and prevent spillage.

Posterior all-layer suture. This suture begins at one extremity of the incisions and unites the posterior cut edges, traversing all coats of the gut. The first stitch should enter the lumen lateral to the end of one incision and, after ligation, the end of the suture is held in forceps. An ordinaryover-and-over continuous suture is employed but, after every five or six stitches, a lock-stitch may be inserted to prevent a possible purse-string effect as the suture is tightened. When the other extremity of the incisions is reached, the suture is carried round the corner and continued in the reverse direction as the anterior all-layer suture. Particular care must be taken when turning the corner to ensure that an all-layer suture is again placed beyond the extremity of the incision.

Anterior all-layer suture. This suture begins as a continuation of the posterior layer, the needle passing from one lumen to the other as before, except that the wall of each gut edge must be traversed separately. As the suture is tightened, the mucosa is inverted by the loop of thread that has been inserted. Any tendency to eversion can be overcome by the assistant gently pressing on the cut

edges with forceps as the suture is tightened. The suture is continued in this manner to complete the join of the cut edges of gut. The suture is tied to the original end that was held in forceps at the start of the posterior all-layer suture. The anastomosis should now be watertight and the clamps are removed.

Anterior seromuscular suture. This suture begins as a continuation of the posterior seromuscular suture and on completion is tied to the end that was held in forceps at the start of the procedure.

Numerous minor modifications of the traditional, handsewn technique for gastroenterostomy or enteroenterostomy are in common use.

TECHNIQUES OF ANASTOMOSIS

Anastomosis can be :

1. Handsewn using sutures
2. Stapled

   Tissue glue has been used to reinforce anastomotic suture lines.

FACTORS WHICH INCREASE THE RATE OF ANASTOMOTIC LEAK

- Emergency surgery , if associated with hypovolemia, as in abdominal trauma, with intra abdominal bleeding.
- Hypovolemia, compromises the splanchnic circulation, which may result in ischemia at the site of anastomosis
- Peritonitis is a major risk factor. Most patients with peritonitis have septicemia with a systemic inflammatory response syndrome. Here there are high circulating levels of inflammatory mediators which include excessive inflammation, (more than required for healing) at the site of anastomosis, rendering it friable and prone to leak.
- Low hemoglobin concentration may cause decreased oxygen carrying capacity of blood inducing relative ischemia at the site of anastomosis.

- Malnutrition leads to low levels of serum protein and albumin, causing interstitial tissue edema, increased suture tension and poor healing.
- Previous history of irradiation. Patients who have been irradiated for malignancy have a higher incidence of anastomotic leak because irradiation induces fibrosis and a reduced blood supply.
- Immunosuppressive drugs includes steroids cause poor tissue healing.
- Unprepared gut. Ana anastomosis performed on unprepared colon with a high fecal bacterial load has an increased chance of leak.
- Malignancy, infection and inflammation will all impair wound healing.
- Distal obstruction should be excluded from before joining two ends. Ongoing obstruction will lead to increased tissue tension and ischemia.
- Ongoing traction on an anastomosis may be seen due to mechanical tension or twists and may also come about secondary to a narrow joint not wide enough to allow passage of fluid. This also leads to ischemia, and the possibility of anastomotic dehiscence.

HANDSEWN ANASTOMOSIS : TECHNICAL ISSUES

CHOICE OF SUTURE MATERIAL;

One should choose a suture which induces the least inflammatory reaction. Majority of sutures act as a foreign body and induce inflammation. It has been seen that silk induces a significantly greater cellular reaction at the site of anastomosis which persists up to 6 weeks in comparison to polypropylene or polyglycolic acid (dexon) or polygalactin (vicryl).

An ideal suture material for anastomosis should cause minimal tissue reaction and inflammation and should provide maximum strength during the lag phase of wound healing. Monofilament and coated braided sutures are most effective but still not ideal.

The choice of suture material is often dependent only on the preference of the surgeon; for example, knots may feel more secure with a braided material but a slippery monofilament material slides better if a parachuting technique is needed. Additionally, the choice between an absorbable and a nonabsorbable suture is again often one of personal preference. However, non-absorbable sutures should be avoided in biliary and urinary anastomoses, where sutures – in particular braided material such as silk – have been found as the nidus within a subsequent calculus.

VICRYL SUTURE:

Vicryl is the braided multifilament suture material which is made of copolymer of lactide and glycolide in the ratio of 90:10, coated with polyglactin and calcium stearate. Its tensile strength remains approximately of about 60 percent at two weeks and 30 percent at 3 weeks. Its absorption is by means of hydrolysis and that too minimal until five to six weeks.it takes around 60 to 90 days for complete absorption.

Vicryl exhibits mild tissue reaction and it is generally used for bowel anastomosis and also in general surgical uses where absorbable sutures required e.g. vascular ligatures, gut anastomosis. It has been the workhorse suture for many applications in most general surgical practices, including undyed for subcuticular wound closures and in ophthalmic surgeries. And vicryl is not recommended for use in tissues that require prolonged approximation under stress.

It is available in many supplies from 1-0 vicryl to 5-0 or 8-0 vicryl suture material. 5-0 vicryl supplies are without needles.

SINGLE LAYER VERSUS DOUBLE LAYER

DOUBLE LAYERED CLOSURE:

Double layered closure is the technique where the first posterior layer is taken continuously using silk and the ends are kept as stay and the second layer is taken using vicryl continuously by taking all the layers of bowel as through and through technique. And again after finishing with vicryl all around, using previous silk, seromuscular suture has to be taken continuously as the reinforcement.

Single layered closure is the technique where the bowel ends are anastomosed using vicryl extramucosally or through and through technique continuously without any reinforcing seromuscular stitches.

Double layered anastomosis which came into vogue before the single layered anastomosis was traditionally thought to be more secure. Hpwever, recent studies have clearly shown the advantages of single layer anastomosis in the form of time saving, less narrowing of intestinal lumen, more rapid vascularization and mucosal haling, rapid increase in strength of the anastomosis in the first few post operative period and the early post operative return of normal bowel function as measured by return of bowel sounds, passage of flatus and stools and the return of oral intake.

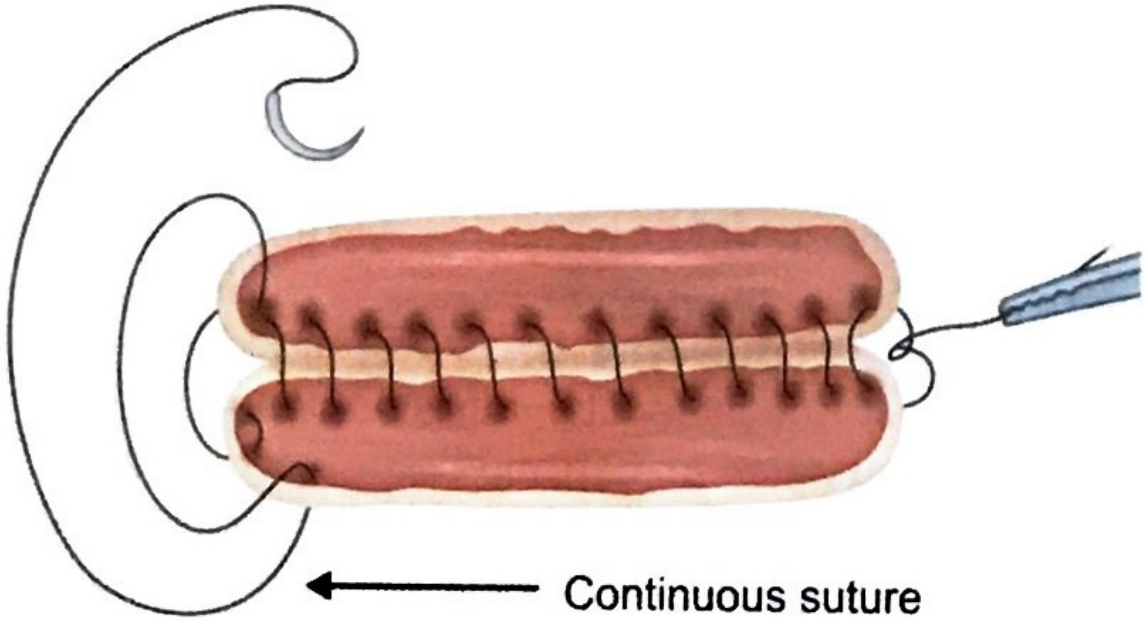

CONTINUOUS SUTURE TO APPROXIMATE THE POSTERIOR WALL

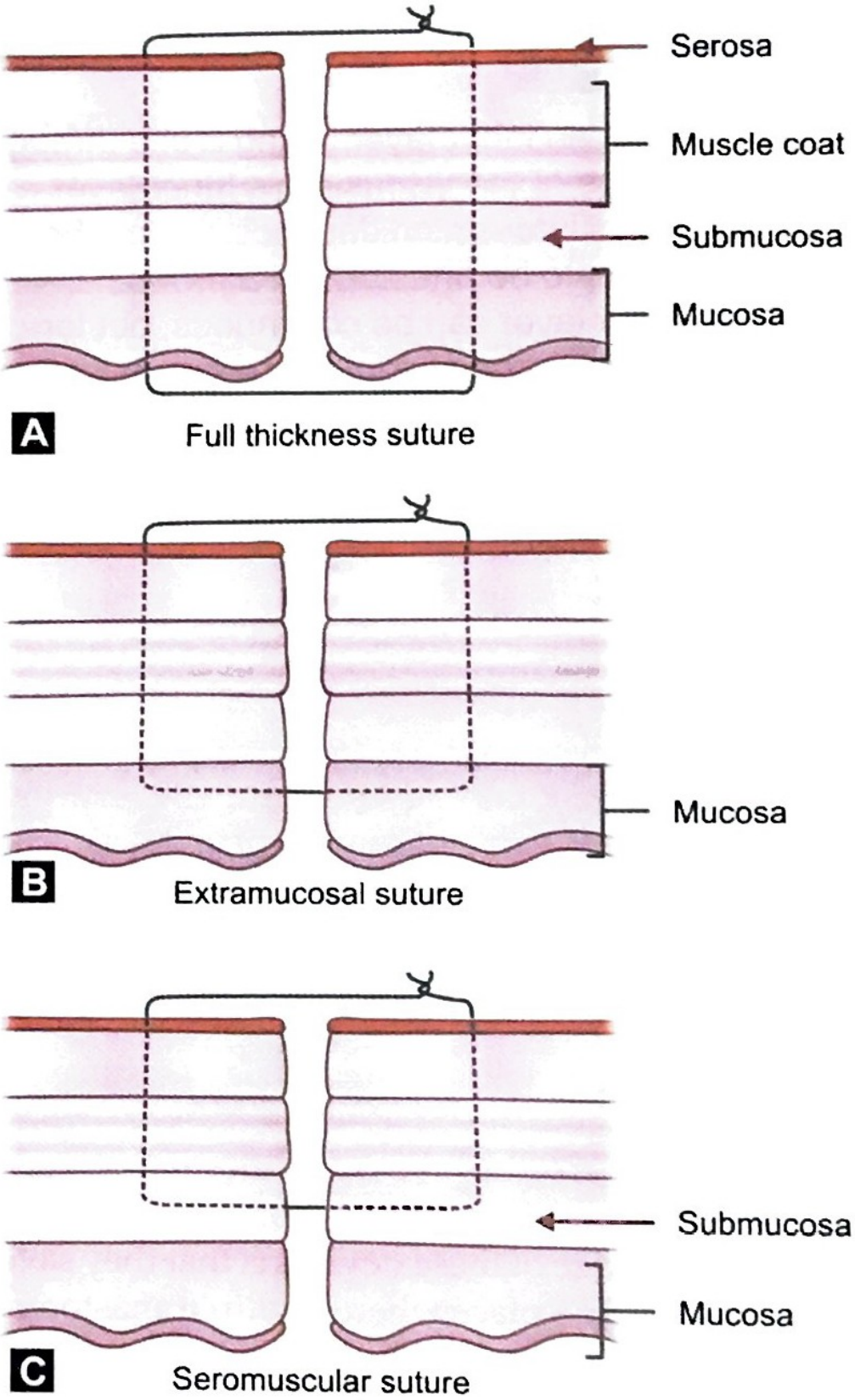
Serosa
Muscle coat
Submucosa
Mucosa
A
Full thickness suture
Mucosa
B
Extramucosal suture
Submucosa
Mucosa
C
Seromuscular suture

TYPES OF SUTURED ANASTOMOSIS

There are multiple techiques in use.

- Single layered interrupted full thickness. This is mainly used in biliary surgery e.g. hepatico jejunostomy , choledochoduodenostomy.

- A single layer interrupted extramucosal technique is the most preferred one. And is mainly used for large or small bowel anastomosis.

- Single layer full thickness continuous technique is commonly employed for gastrojejunal anastomosis. The continuous suture gives the advantage of hemostasis, as the gastric wall is very vascular. It also saves time.

TWO LAYERED ANASTOMOSIS

This consists of an inner layer taking a bite through the full thickness of the viscus. The inner layer can be continuous or interrupted depending upon the portion of viscous to be anastomosed. For small bowel inner layer can be continuous, but for large bowel the inner layer can be interrupted or continuous depending upon surgeon's choice. The outer layer takes a bite takes a bite through the seromuscular layer only and is usually interrupted in colonic surgery.

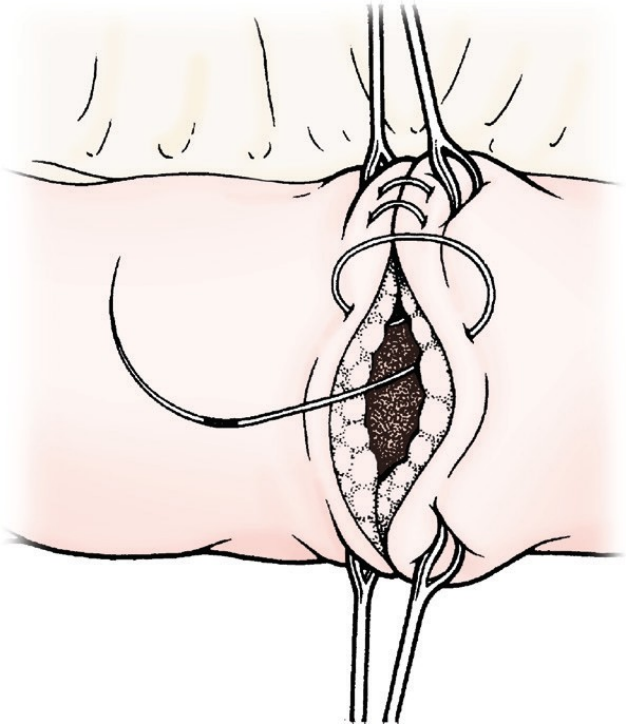

THE TWO LAYERED ANASTOMOSIS

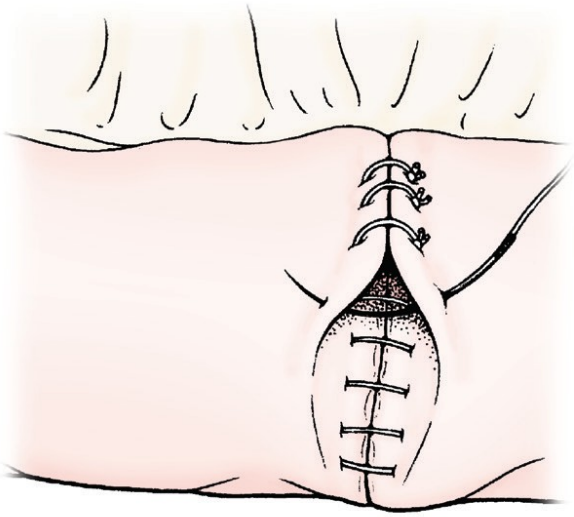

SINGLE LAYERED

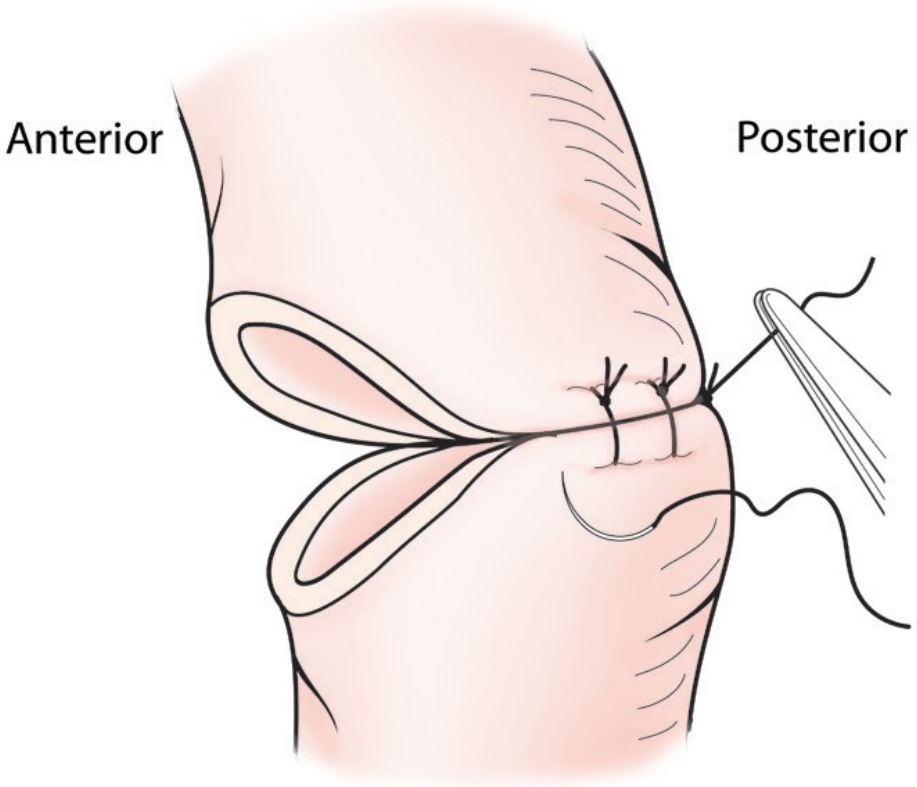

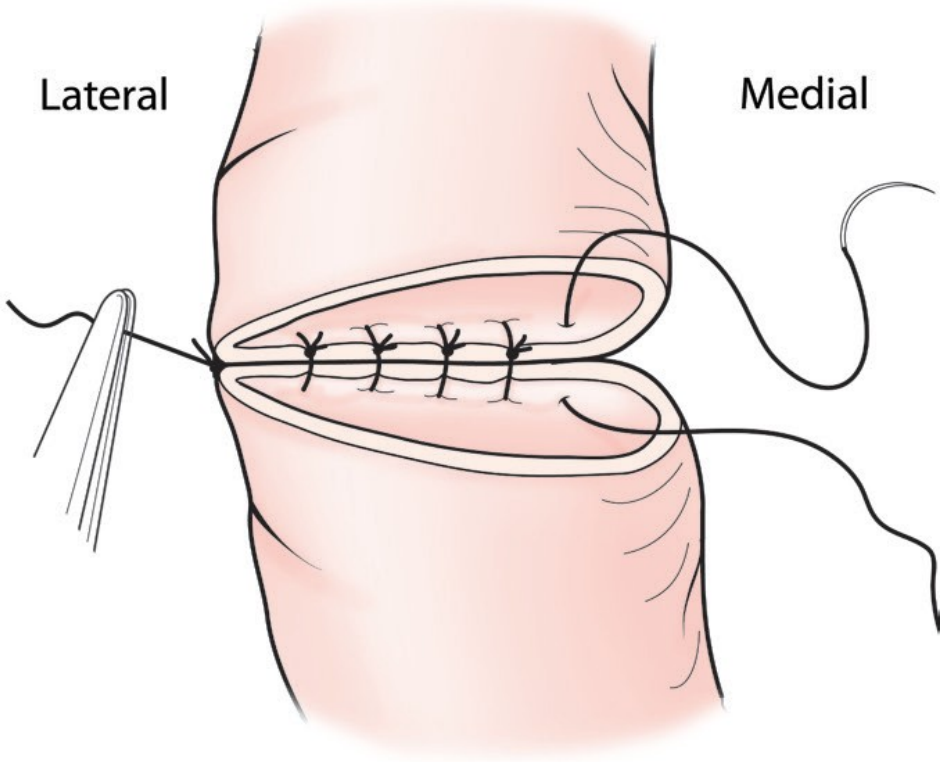

PROTECTING AN ANASTOMOSIS

NASOGASTRIC DECOMPRESSION : routine nasogastric decompression is not mandatory after lower intestinal anastomosis unless there is a significant paralytic ileus with abdominal distension, or there is gastric dilatation or the patient is vomiting. In upper gastrointestinal anastomoses, e.g. gastrojejunostomy or gastro duodenal anastomosis nasogastric suction is essential for 3 to 5 days to avoid any tension on the suture line caused by retention of gastric secretions. Gastric motility takes around 72 hours to recover. Stents are left across anastomoses following hepaticojejunostomy and pancreaticojejunostomy to prevent bile or pancreatic leaks. A nasogastric tube is left after every emergency laparotomy. Stenting an esophagogastric anastomosis in the chest, with gastric decompression is useful, and will prevent an acute gastric dilatation.an unwanted side effect of nasogastric tube placement is discomfort in the pharynx and difficulty coughing.

ABDOMINAL DRAINS AFTER INTESTINAL ANASTOMOSIS

The ability of abdominal drainage to protect an anastomosis has been challenged by yates. The peritoneal cavity cannot be drained effectively by a single drain due to the rapid development of adhesions and the sealing of the drainage tract.

OBSERVATIONS AND DISCUSSIONS

The collected data were analyzed with IBM. SPSS statistics software 23.0 version. To describe about the data descriptive statistics frequency analysis, percentage analysis were used for categorical variables and the mean and standard deviation were used for continuous variables. To find the significant difference between the bivariate samples in the independent groups (single and double) the Mann- Whitney U test was used. To find the significance in categorical data Chi-Square test was used similarly if the expected cell frequency is less than 5 in 2*2 tables then the Fisher's exact was used. In all the above statistical tools the probability value 0.05 is considered as significant level.

AGE DISTRIBUTION

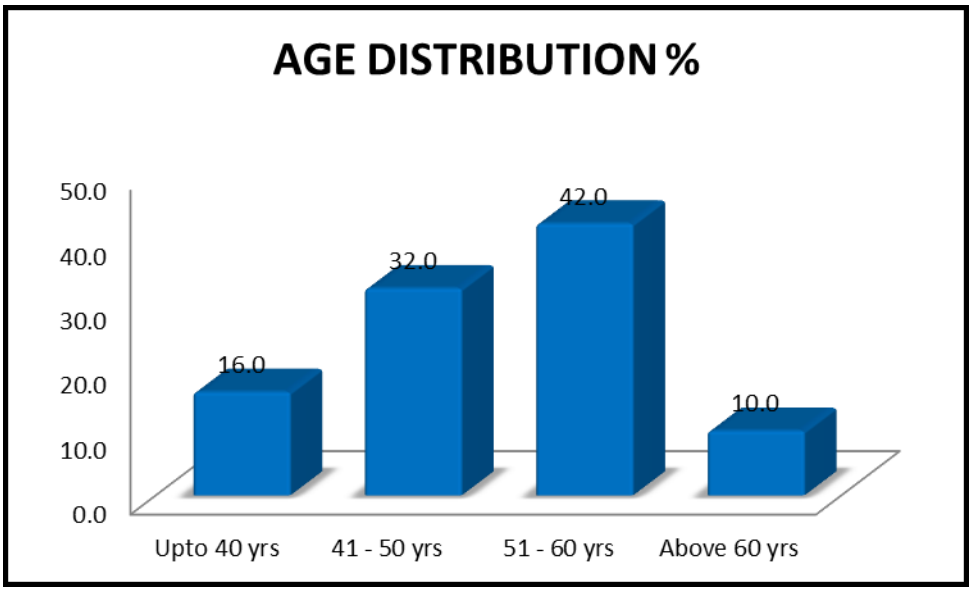

AGE

		Frequency	Percent
Valid	Upto 40 yrs	8	16.0
	41 - 50 yrs	16	32.0
	51 - 60 yrs	21	42.0
	Above 60 yrs	5	10.0
	Total	50	100.0

From the above frequency figures, it is evident that the maximal number of bowel anastomoses(42%) have been done in the age group of 50 to 60 years of age.

GENDER DISTRIBUTION

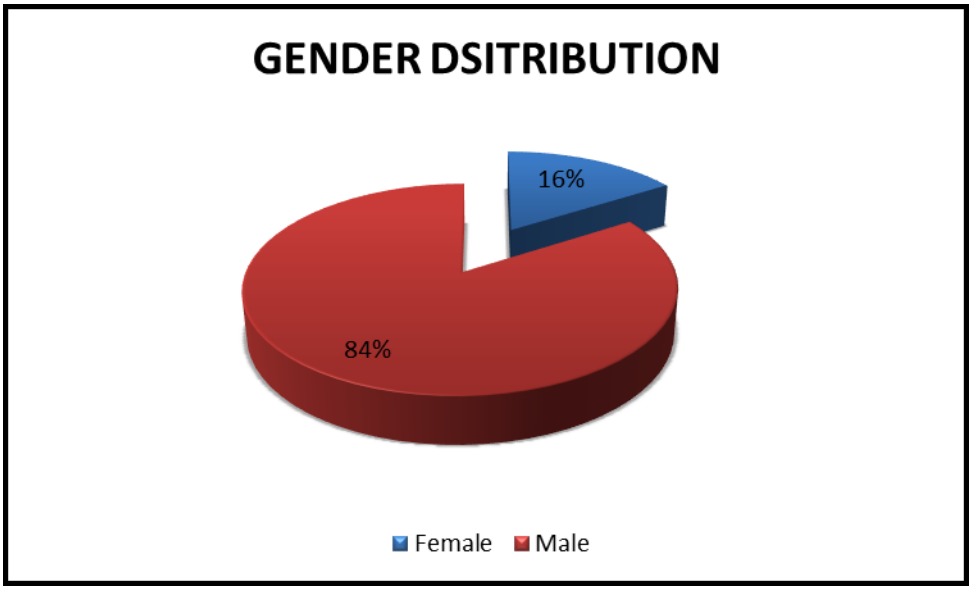

SEX

		Frequency	Percent
Valid	Female	8	16.0
	Male	42	84.0
	Total	50	100.0

It is evident from the above pictures that male patients(84%) have more number of bowel anastomoses.

DIAGNOSIS DISTIBUTION

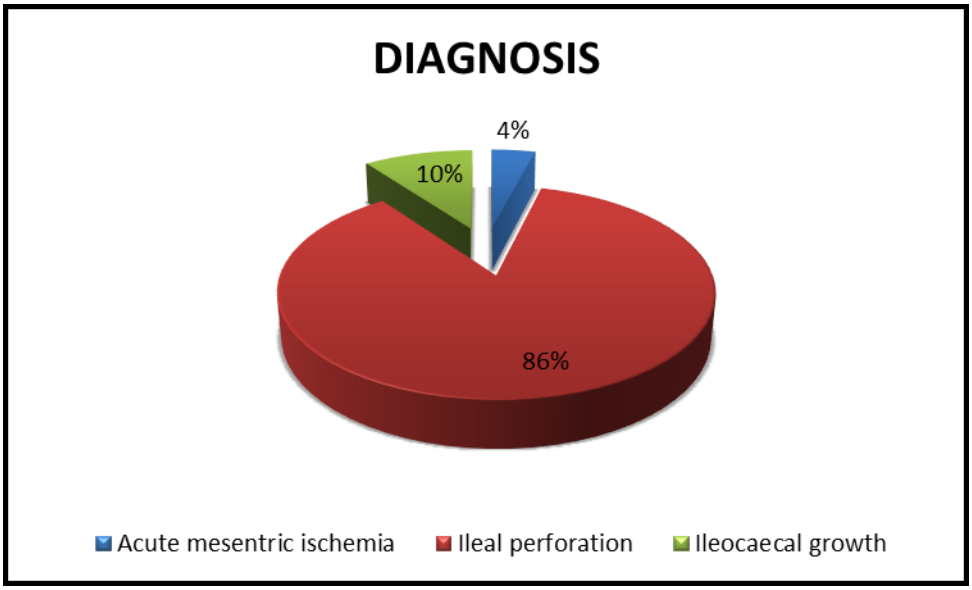

DIAGNOSIS

		Frequency	Percent
Valid	Acute mesentric ischemia	2	4.0
	Ileal perforation	43	86.0
	Ileocaecal growth	5	10.0
	Total	50	100.0

It is observed from the above figures that ileal perforation cases (86%) underwent the maximal number of bowel anastomoses.

CROSS TABS

AGE vs GROUPS

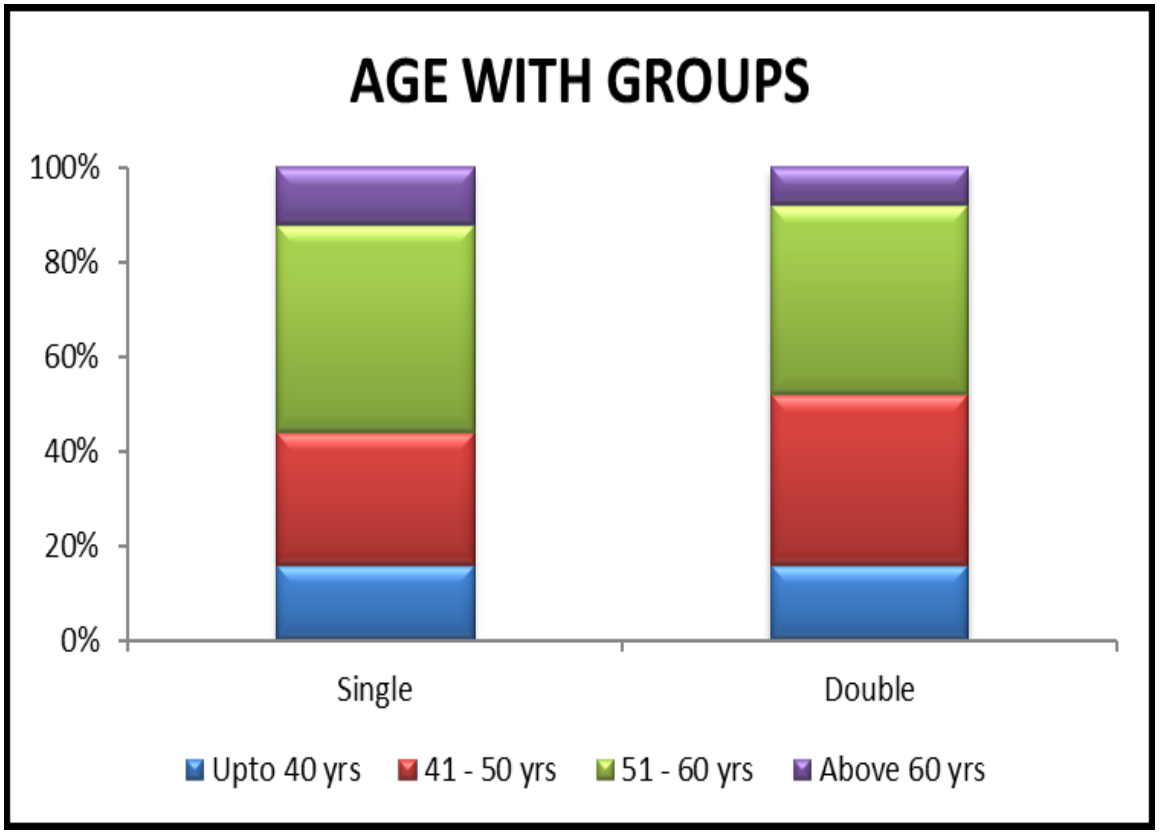

Crosstab

			Groups		Total
			Single	Double	
AGE	Upto 40 yrs	Count	4	4	8
		% within Groups	16.0%	16.0%	16.0%
	41 - 50 yrs	Count	7	9	16
		% within Groups	28.0%	36.0%	32.0%
	51 - 60 yrs	Count	11	10	21
		% within Groups	44.0%	40.0%	42.0%
	Above 60 yrs	Count	3	2	5
		% within Groups	12.0%	8.0%	10.0%
Total		Count	25	25	50
		% within Groups	100.0%	100.0%	100.0%

Chi-Square Tests

	Value	df	Asymp. Sig. (2-sided)
Pearson Chi-Square	.498[a]	3	.919
Likelihood Ratio	.500	3	.919
Linear-by-Linear Association	.230	1	.632
N of Valid Cases	50		

SEX vs GROUPS

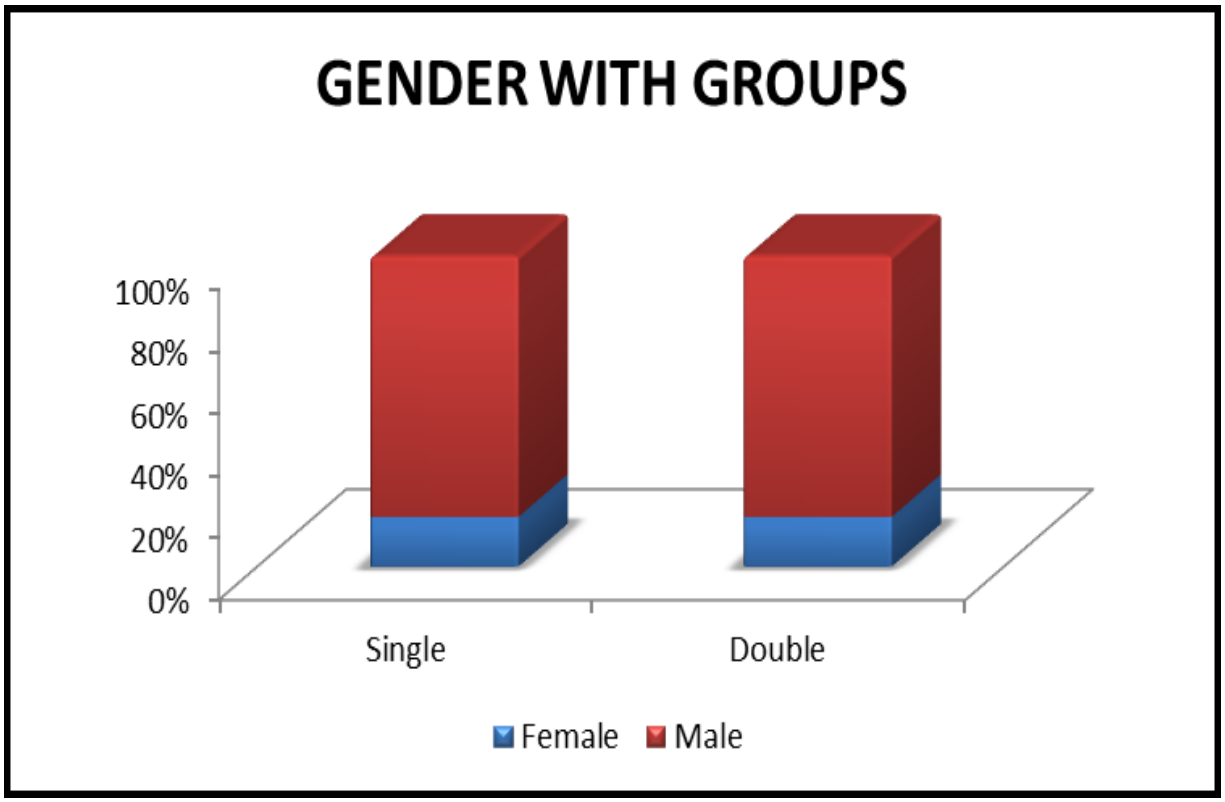

Crosstab

			Groups		Total
			Single	Double	
SEX	female	Count	4	4	8
		% within Groups	16.0%	16.0%	16.0%
	male	Count	21	21	42
		% within Groups	84.0%	84.0%	84.0%
Total		Count	25	25	50
		% within Groups	100.0%	100.0%	100.0%

Chi-Square Tests

	Value	df	Asymp. Sig. (2-sided)	Exact Sig. (2-sided)	Exact Sig. (1-sided)
Pearson Chi-Square	.000[a]	1	1.000		
Continuity Correction[b]	0.000	1	1.000		
Likelihood Ratio	0.000	1	1.000		
Fisher's Exact Test				1.000	.649
N of Valid Cases	50				

DIAGNOSIS vs GROUPS

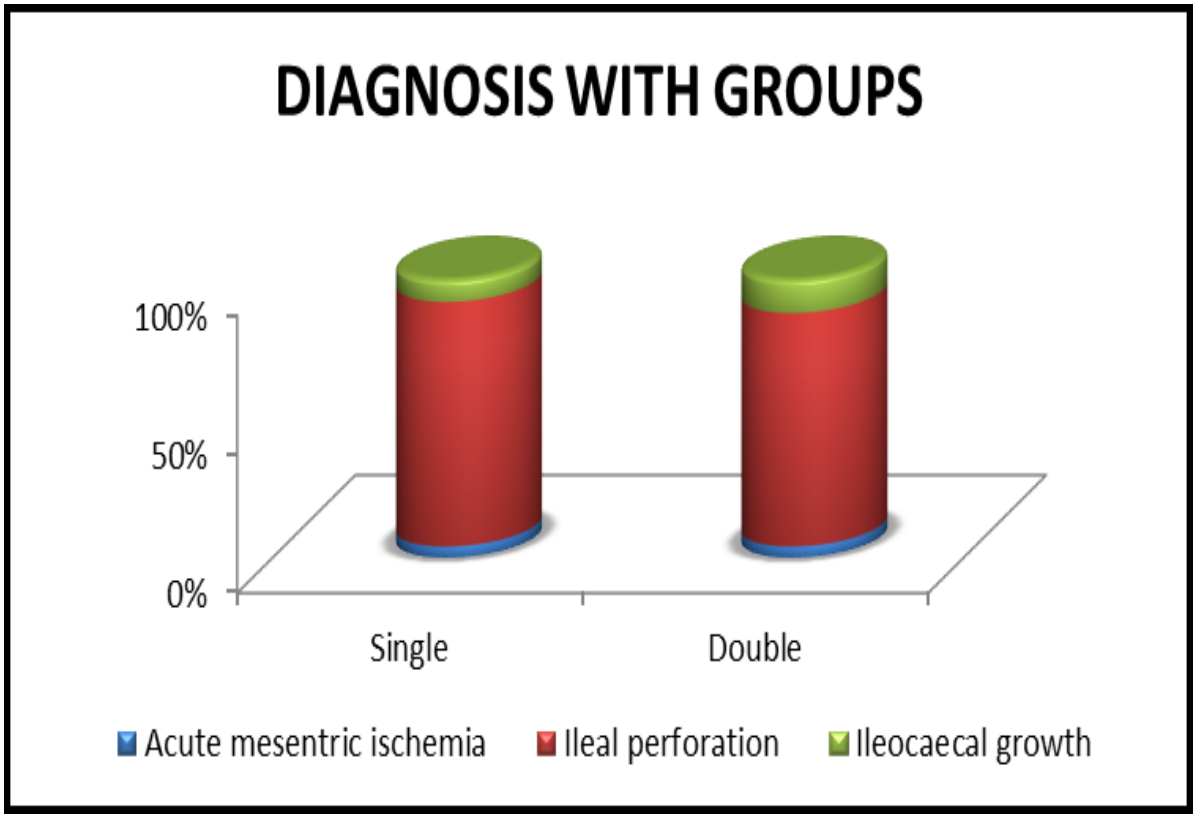

Crosstab

			Groups		Total
			Single	Double	
DIAGNOSIS	acute mesentric ischemia	Count	1	1	2
		% within Groups	4.0%	4.0%	4.0%
	ileal perforation	Count	22	21	43
		% within Groups	88.0%	84.0%	86.0%
	ileocaecal growth	Count	2	3	5
		% within Groups	8.0%	12.0%	10.0%
Total		Count	25	25	50
		% within Groups	100.0%	100.0%	100.0%

Chi-Square Tests

	Value	df	Asymp. Sig. (2-sided)
Pearson Chi-Square	.223[a]	2	.894
Likelihood Ratio	.225	2	.894
N of Valid Cases	50		

NPar Tests

Mann-Whitney Test

Ranks

Groups		N	Mean Rank	Sum of Ranks
BOWEL SOUNDS	Single	25	19.02	475.50
	Double	25	31.98	799.50
	Total	50		
BOWEL MOTILITY FLATUS	Single	25	19.64	491.00
	Double	25	31.36	784.00
	Total	50		
BOWEL MOTILITY STOOLS	Single	25	21.30	532.50
	Double	25	29.70	742.50
	Total	50		
HS	Single	25	16.80	420.00
	Double	25	34.20	855.00
	Total	50		

Group Statistics

Groups		N	Mean	Std. Deviation	Std. Error Mean
BOWEL SOUNDS	Single	25	2.52	.586	.117
	Double	25	3.24	.723	.145
BOWEL MOTILITY FLATUS	Single	25	3.40	.645	.129
	Double	25	4.04	.735	.147
BOWEL MOTILITY STOOLS	Single	25	6.24	.831	.166
	Double	25	6.76	.879	.176
HS	Single	25	8.32	1.030	.206
	Double	25	9.92	1.115	.223

Test Statistics[a]

	Mann-Whitney U	Z	Asymp. Sig. (2-tailed)
BOWEL SOUNDS	150.500	-3.379	.001
BOWEL MOTILITY	166.000	-3.082	.002
FLATUS			
BOWEL MOTILITY	207.500	-2.156	.031
STOOLS			
HS	95.000	-4.343	.001

P value is highly significant in cases of parameters like bowel sounds, day of passing flatus and the duration of hospital stay and relatively significant in case of day of passing stools.

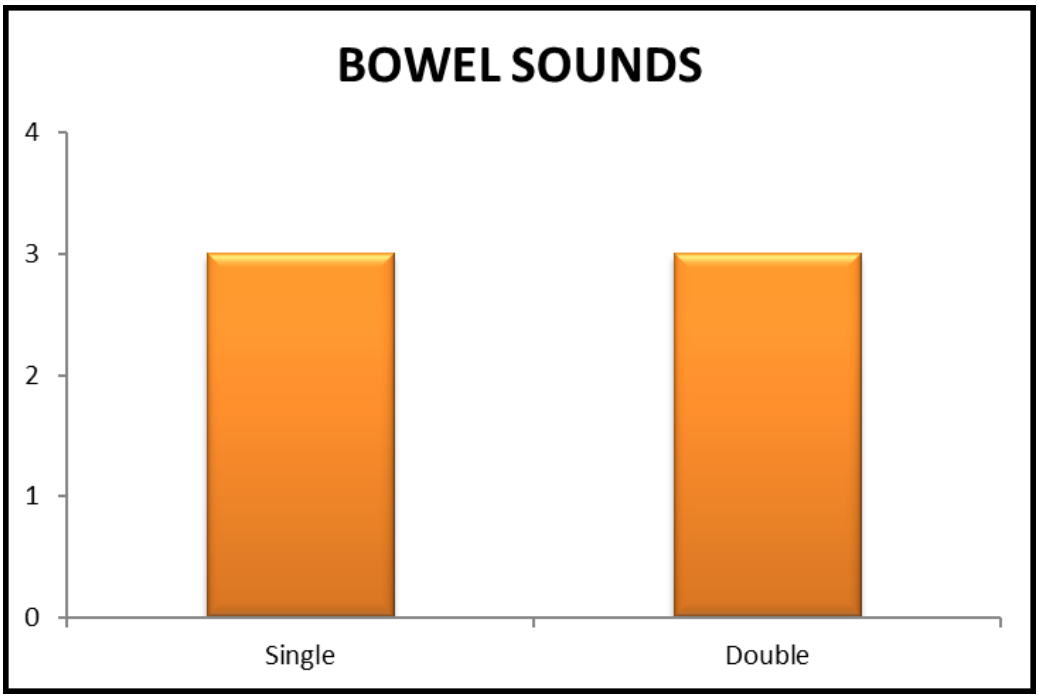

	BOWEL SOUNDS
Single	3
Double	3

From the above figure its evident that the patient's bowel sounds heard on the third post operative day in both the groups i.e. single and double layered closure techniques.

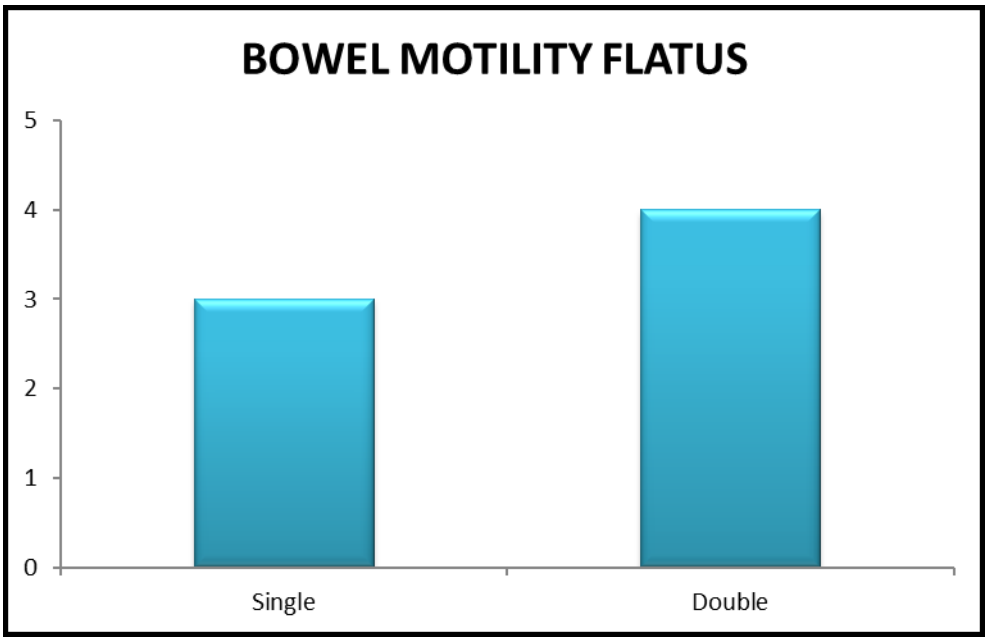

	BOWEL MOTILITY FLATUS
Single	3
Double	4

Its evident that in the assessment of bowel motility patient passed flatus on 3rd post operative day in case of single layered closure and on 4th post operative day in case of double layered closure anastomosis.

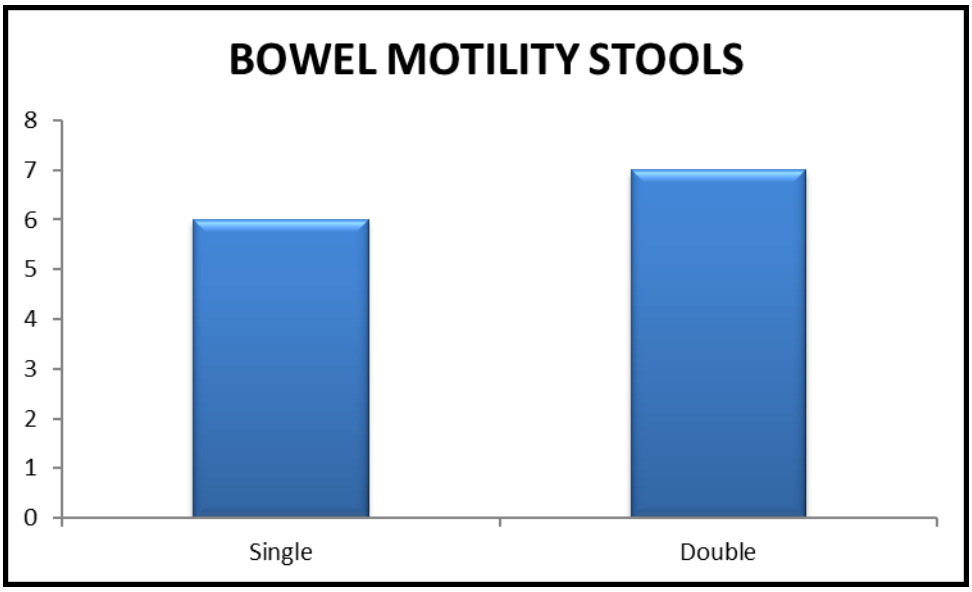

	BOWEL MOTILITY STOOLS
Single	6
Double	7

Its shown that the patients passed stools approximately on 6th post operative day in single layered closure and 7th post operative day in double layered closure anastomosis.

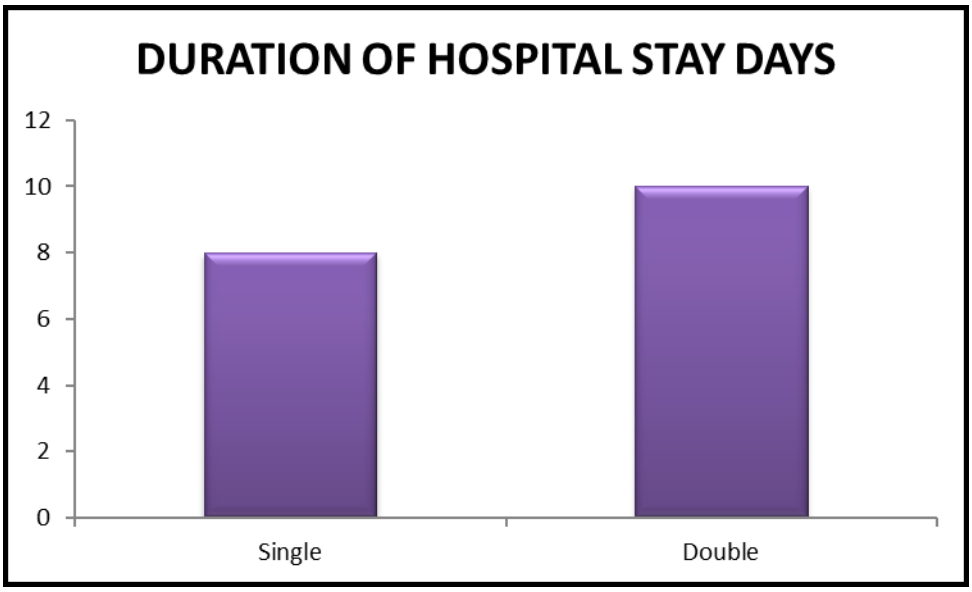

	DURATION OF HOSPITAL STAY DAYS
Single	8
Double	10

The duration of hospital stay after the bowel anastomosis is found to be approximately 8th post operative day for single layered closure and 10th post operative day for double layered closure bowel anastomosis.

Explore

Groups = Single

Descriptives[a]

			Statistic	Std. Error
BOWEL SOUNDS	Mean		2.52	.117
	95% Confidence Interval for Mean	Lower Bound	2.28	
		Upper Bound	2.76	
	5% Trimmed Mean		2.48	
	Median		2.00	
	Variance		.343	
	Std. Deviation		.586	
	Minimum		2	
	Maximum		4	
	Range		2	
	Interquartile Range		1	
	Skewness		.592	.464
	Kurtosis		-.540	.902
BOWEL MOTILITY FLATUS	Mean		3.40	.129
	95% Confidence Interval for Mean	Lower Bound	3.13	
		Upper Bound	3.67	
	5% Trimmed Mean		3.33	
	Median		3.00	
	Variance		.417	
	Std. Deviation		.645	
	Minimum		3	
	Maximum		5	
	Range		2	
	Interquartile Range		1	
	Skewness		1.414	.464
	Kurtosis		1.000	.902

BOWEL MOTILITY STOOLS	Mean		6.24	.166
	95% Confidence Interval for Mean	Lower Bound	5.90	
		Upper Bound	6.58	
	5% Trimmed Mean		6.21	
	Median		6.00	
	Variance		.690	
	Std. Deviation		.831	
	Minimum		5	
	Maximum		8	
	Range		3	
	Interquartile Range		1	
	Skewness		.453	.464
	Kurtosis		.035	.902
HS	Mean		8.32	.206
	95% Confidence Interval for Mean	Lower Bound	7.90	
		Upper Bound	8.74	
	5% Trimmed Mean		8.34	
	Median		8.00	
	Variance		1.060	
	Std. Deviation		1.030	
	Minimum		6	
	Maximum		10	
	Range		4	
	Interquartile Range		1	
	Skewness		-.218	.464
	Kurtosis		-.232	.902

Groups = Double

Descriptives[a]

			Statistic	Std. Error
BOWEL SOUNDS	Mean		3.24	.145
	95% Confidence Interval for Mean	Lower Bound	2.94	
		Upper Bound	3.54	
	5% Trimmed Mean		3.27	
	Median		3.00	
	Variance		.523	
	Std. Deviation		.723	
	Minimum		2	
	Maximum		4	
	Range		2	
	Interquartile Range		1	
	Skewness		-.405	.464
	Kurtosis		-.908	.902
BOWEL MOTILITY FLATUS	Mean		4.04	.147
	95% Confidence Interval for Mean	Lower Bound	3.74	
		Upper Bound	4.34	
	5% Trimmed Mean		4.04	
	Median		4.00	
	Variance		.540	
	Std. Deviation		.735	
	Minimum		3	
	Maximum		5	
	Range		2	
	Interquartile Range		2	
	Skewness		-.064	.464
	Kurtosis		-1.035	.902

BOWEL MOTILITY STOOLS	Mean		6.76	.176
	95% Confidence Interval for Mean	Lower Bound	6.40	
		Upper Bound	7.12	
	5% Trimmed Mean		6.79	
	Median		7.00	
	Variance		.773	
	Std. Deviation		.879	
	Minimum		5	
	Maximum		8	
	Range		3	
	Interquartile Range		1	
	Skewness		-.286	.464
	Kurtosis		-.427	.902
HS	Mean		9.92	.223
	95% Confidence Interval for Mean	Lower Bound	9.46	
		Upper Bound	10.38	
	5% Trimmed Mean		9.91	
	Median		10.00	
	Variance		1.243	
	Std. Deviation		1.115	
	Minimum		8	
	Maximum		12	
	Range		4	
	Interquartile Range		2	
	Skewness		.365	.464
	Kurtosis		-.215	.902

RESULTS

- In my study the total population is 50
- Among those 50, 25 were the patients who had single layered closure of bowel anastomosis and the other 25 we re the one who had double layered closure bowel anastomosis.
- Regarding age distribution the largest population were between 51-60 years.
- Regarding sex distribution, male patients had more bowel anastomosis.
- Regarding diagnosis, ileal perforation was found to be the major cause for bowel resection and anastomosis.
- Post operatively during the follow up, patients records have been evaluated for many parameters like day of bowel sounds, passing flatus, stools and the duration of hospital stay.
- From this study it is found to be there is no difference in returning of bowel sounds in between the two groups (3rd post op day)
- But in case of bowel motility the day of passing flatus (3rd post op day for single layer and 4th post op day for double layer) and the day of passing stools (6th post op day for single layer and 7th post op day

for double layer) is earlier in case of single layered closure than in double layered closure.

- And also the duration of hospital stay after the surgery (8 days for single layer and 10 days for double layer) is also found to be earlier in case of single layered closure than in double layered closure.
- And the p value is also highly significant for single layered closure anastomosis.

DISCUSSION

On analysis of our data and statistics, it was found that the time required for the bowel to return motility in single layered anastomosis was significantly lower with p value <0.001 which was highly significant. Previous studies reported similar results in attaining earlier bowel motility in single layered closure as mentioned in a studies done by Sibabrata et al.(4.18+/-1.22 for single vs 4.85 +/- 1.63 for double), T shah et al. (5.02 for single vs 5.98 for double), wayand et al.(4 for single vs 5 for double)

The duration of hospital stay after the surgery was also found to be minimal in single layered closure patients than the double layered closure patients with highly significant p value of 0.001. This is also evident from the previous studies done by Maurya et al. found a difference of approximately 6 days(11.4 for single / 18.6 for double), Burch et al. observed a two day shorter length of stay in single layer group(7.9/9.9). but the study done by Ordorica et al. found no difference in the duration of hospital stay(10.4/10.4).

CONCLUSION

Intestinal anastomosis has always been a crucial surgical skill for the surgeons and the main complication of anastomotic leak in the post-operative period is the nightmare of all the general surgeons and whenever it is present, it adds more morbidity and mortality for the patients. Keeping in view the lesser intra operative time, early attainment of bowel motility and the shorter duration of hospital stay for single layered closure of bowel anastomosis as compared to the double layered closure, it can be concluded from this study that the single layered closure is safe and better surgical procedure for bowel anastomosis than the double layered closure.

BIBLIOGRAPHY

1) Spectrum of Etiology of Intestinal Obstruction-A Hospital based Study NA Qureshi, SK Bhat, BS Sodhi - INTERNATIONAL JOURNAL OF …, 2017 - ijss-sn.com

2) Coleman MG, McLain AD, Moran BJ (2000) Impact of previous surgery on time taken for incision and division of adhesions during laparotomy. Dis Colon Rectum 43:1297–9.

3) Sinnatamby CS (2011) Last's Anatomy, 12th edn. Churchill Livingstone/Elsevier, Edinburgh.

4) Musella M, Milone M, Bellini M et al. (2011) Laparoscopic sleeve gastrectomy. Do we need to oversew the staple line? Ann Ital Chir 82(4):273–7.

5) Alley JB, Fenton SJ, Harnisch MC et al. (2011) Integrated bioabsorbable tissue reinforcement in laparoscopic sleeve gastrectomy. Obes Surg 1(8):1311–15.

6) Single Layered Versus Double Layered Intestinal Anastomosis: A Randomized Controlled Trial. Kar S1, Mohapatra V2, Singh S3, Rath PK4, Behera TR5.

7) Single-layer versus double-layer intestinal anastomosis: A comparative study T Shah, RK Agarwal, RK Gupta, CS Agrawal, S Khaniya Department of Surgery, B.P. Koirala Institute of Health Sciences, Dharan, Nepal

8) One layered continuous anastamosis of the alimentary tract with absorbable polydiaxonone suture.Chittmittrapap S, et al. J med assoc thai. 1993.

9) Single or double layer? A controlled prospective study on the comparison of 2 suture techniques in gastrointestinal anastamosis. Wayand W, et al. chirug.

10) Continuos single layer technique in gastrointestinal anastamosis. A prospective observational study of emergency and elective operations. Littke MP, et al. zentralbl chilr. 2002.

11) Larsen WJ: Human embryology. New York, 1997, Churchill Livingstone.

12) Skandalakis JE, Gray SW, Ricketts R, et al: Embryology for surgeons:The embryological basis for the treatment of congenital anomalies. Baltimore, 1994, Williams & Wilkins.

13) Cserni T, Paran A, Kanyari Z, et al: New insights into the neuromuscular anatomy of the ileocecal valve. Anatom Rec 292:54, 2009.

14) Gonella J, Bouvier M, Blanquet F: Extrinsic nervous control of motility of small and large intestines and related sphincters. Physiol Rev 67:902, 1987.

15) Burns AJ, Roberts RR, Bornstein JC, et al: Development of the enteric nervous system and its role in intestinal motility during fetal and early postnatal stages. Semin Pediatr Surg 18:196, 2009.

16) Bortoff A: Myogenic control of intestinal motility. Physiol Rev 56:418, 1976.

17) Ahluwalia NK, Thompson DG, Barlow J, et al: Beta adrenergic modulation of human upper intestinal propulsive forces. Gut 35:1356, 1994.

18) Thollander M, Svensson TH, Hellström PM: Stimulation of β-adrenoceptors with isoprenaline inhibits small intestinal activity fronts and induces a postprandial-like motility pattern in humans. Gut 40:376, 1997.

19) Wood JD: Intrinsic neural control of intestinal motility. Annu Rev Physiol 43:33, 1981.

20) Spiller RC, Trotman IF, Adrian TE, et al: Further characterization of the "ileal brake" reflex in man—effect of ileal infusion of partial digests of fat, protein, and starch on jejunal motility and release of neurotensin, enteroglucagon, and peptide YY. Gut 29:1042, 1988.

21) Preston DM, Adrian TE, Christofides ND, et al: Positive correlation between symptoms and circulating motilin, pancreatic polypeptide and gastrin concentrations in functional bowel disorders. Gut 26:1059, 1985.

22) Thomas PA, Akwari OE, Kelly KA: Hormonal control of gastrointestinal motility. World J Surg 3:545, 1979.

23) Harvey RF: Hormonal control of gastrointestinal motility. Dig Des 20:523, 1975.

24) Misiewicz JJ, Waller SL, Kiley N: Effect of oral prostaglandin E1 on intestinal transit in man. Lancet 1:648, 1969.

25) Hansen MB, Arif F, Gregersen H, et al: Effect of serotonin on small intestinal contractility in healthy volunteers. Physiol Res 57:63,

26) 2008.

27) Aros SD, Camilleri M: Small-bowel motility. Curr Opin Gastroenterol 17:140, 2001.

28) MacKeigan JM, Cataldo PA, editors: Intestinal stomas. Principles, techniques, and management, ed 1. St Louis, 1993, Quality Medical Publishing.

29) Dinnick T: The origins and evolution of colostomy. Br J Surg 22:142, 1934.

30) Littre A: Diverses observations anatomiques. Histoire de l'Academie Royale des Sciences II:36, 1732.

31) Baum W: Resection eines carcinomatosen Dickdarmstuckes. Centralblatt fur Chirugie 6:169, 1879.

32) Maydl C: Ein beitrag zur Darmchirugie. Wiener Med Presse 5:500, 1883.

33) Lund F: The value of enterostomy in selected cases of peritonitis. JAMA 41:74, 1903.

34) Brown J: The value of complete physiological rest of the large bowel in the treatment of certain ulcerative and obstructive lesions of this organ. Surg Gynecol Obstet 16:610, 1913.

35) Bargen JA, Brown PW, Rankin FW: Indications for and technique of ileostomy in chronic ulcerative colitis. Surg Gynecol Obstet 55:196, 1931.

36) Rankin FW: Total colectomy: Its indication and technic. Ann Surg 94:677, 1931.

37) Dragstedt LR, Dack GM, Kirsner JB: Chronic ulcerative colitis: A summary of evidence implicating bacterium necrophorum as an etiologic agent. Ann Surg 114:653, 1941.

38) Turnbull RB Jr: Management of the ileostomy. Am J Surg 86:617, 1953.

39) Brooke BN: The management of an ileostomy, including its complications.

40) Maurya SD, Gupta HC, Tewari A, Khan SS, Sharma BD: Double layer versus single layer intestinal anastomosis: a clinical trial. Int Surg. 1984, 69: 339-340.

41) 40.Ordorica-Flores RM, Bracho-Blanchet E, Nieto-Zermeno J, Reyes-Retana R, Tovilla-Mercado JM, Leon-Villanueva V, Varela-Fascinetto G: Intestinal anastomosis in children: a comparative study between two

different techniques. J Pediatr Surg. 1998, 33: 1757-1759. 10.1016/S0022-3468(98)90279-2.

42) Burch JM, Franciose RJ, Moore EE, Biffl WL, Offner PJ: Single-layer continuous versus two-layer interrupted intestinal anastomosis: a prospective randomized trial. Ann Surg. 2000.

S. NO.	NAME	AGE	SEX	DIAGNOSIS	PROCEDURE	BOWEL SOUNDS	BOWEL MOTILITY		ANASTAMOTIC LEAKAGE	DURATION OF HOSPITAL STAY post op
							FLATUS	STOOLS		
1	ganesan	58	male	ileal perforation	ileoileal anastomosis - single layer	3	4	6	no	8
2	saraswathy	55	female	acute mesentric ischemia	jejunotransverse anastomosis - double layer	4	5	7	no	10
3	dhayalan	55	male	ileal perforation	ileoileal anastomosis - single layer	2	4	7	no	9
4	balaji	15	male	ileal perforation	ileoileal anastomosis - single layer	3	5	8	no	10
5	shanmugam	55	male	ileal perforation	ileoileal anastomosis - single layer	2	3	6	no	9
6	rajkumar	29	male	ileal perforation	ileoileal anastomosis - double layer	3	4	6	no	9
7	anbalagan	45	male	ileal growth	ileoileal anastomosis - single layer	4	5	7	no	10
8	anbu	55	male	ileal perforation	ileoileal anastomosis - single layer	3	3	5	no	7
9	ravana	23	female	ileocaecal growth	ileoileal anastomosis - single layer	2	3	6	no	8
10	jhonson	51	male	ileocaecal growth	ileocolic anastomosis - double layer	3	4	6	no	9
11	selvi	42	female	ileal perforation	ileoileal anastomosis - single layer	2	3	5	no	6
12	palani	21	male	ileal perforation	ileoileal anastomosis -double layer	4	4	7	no	8
13	duraisamy	67	male	ileal perforation	ileoileal anastomosis - single layer	3	3	6	no	7
14	annamal	57	female	ileal perforation	ileoileal anastomosis - double layer	4	4	7	no	9
15	ramakrishnan	41	male	ileal perforation	ileoileal anastomosis - single layer	2	4	6	no	7
16	prabhu	47	male	ileal perforation	ileoileal anastomosis - double layer	4	4	7	no	10
17	govindhan	54	male	ileal perforation	ileoileal anastomosis - single layer	3	4	8	no	9
18	ranganathan	58	male	ileaocaecal growth	ileocolic anastomosis - double layer	3	5	7	no	10
19	krishnan	48	male	ileal perforation	ileoileal anastomosis - double layer	3	4	8	no	11
20	kumar	39	male	ileal perforation	ileoileal anastomosis - single layer	2	3	6	no	9
21	venkatesh	45	male	ileal perforation	ileoileal anastomosis - single layer	3	3	6	no	7
22	punniyakodi	56	male	ileal perforation	ileoileal anastomosis - single layer	2	3	7	no	9
23	perumal	37	male	ileal perforation	ileoileal anastomosis - double layer	4	4	7	no	11
24	moorthy	49	male	ileal perforation	ileoileal anastomosis - double layer	3	5	8	no	12
25	elumazhai	43	male	ileal perforation	ileoileal anastomosis - double layer	2	3	6	no	9
26	lakshmi	48	female	acute mesentric ischemia	ileoileal anastomosis - single layer	3	4	7	no	9
27	babu	52	male	ileocaecal growth	ileocolic anastomosis - double layer	2	3	6	no	9
28	ramanathan	60	male	ileal perforation	ileoileal anastomosis - double layer	4	5	8	no	10
29	rajesh	40	male	ileal perforation	ileoileal anastomosis - single layer	3	3	6	no	8
30	anand	47	male	ileal perforation	ileoileal anastomosis - double layer	4	4	7	no	10
31	subramani	51	male	ileal perforation	ileoileal anastomosis - single layer	3	3	5	no	8
32	vedhachalam	56	male	ileal perforation	ileoileal anastomosis - single layer	2	3	6	no	8

S. NO.	NAME	AGE	SEX	DIAGNOSIS	PROCEDURE	BOWEL SOUNDS	BOWEL MOTILITY		ANASTAMOTIC LEAKAGE	DURATION OF HOSPITAL STAY post op
							FLATUS	STOOLS		
33	immanuel	64	male	ileal perforation	ileoileal anastomosis - double layer	3	4	6	no	10
34	tamilarasi	58	female	ileal perforation	ileoileal anastomosis - double layer	2	3	6	no	10
35	ponnuraj	61	male	ileal perforation	ileoileal anastomosis - single layer	2	3	5	no	8
36	devasagayam	59	male	ileal perforation	ileoileal anastomosis - double layer	2	4	7	no	10
37	prasanth	42	male	ileal perforation	ileoileal anastomosis - double layer	3	3	5	no	9
38	vasanthan	48	male	ileal perforation	ileoileal anastomosis - double layer	3	3	6	no	9
39	mannaar	63	male	ileal perforation	ileoileal anastomosis - single layer	3	4	7	no	9
40	govindhammal	59	female	ileal perforation	ileoileal anastomosis - single layer	2	3	6	no	10
41	krishnaveni	53	female	ileal perforation	ileoileal anastomosis - double layer	4	4	7	no	10
42	sudhakar	58	male	ileal perforation	ileoileal anastomosis - single layer	3	3	6	no	8
43	marimuthu	71	male	ileal perforation	ileoileal anastomosis - double layer	3	5	8	no	12
44	arockiaraj	49	male	ileal perforation	ileoileal anastomosis - single layer	2	3	7	no	9
45	pichandi	59	male	ileal perforation	ileoileal anastomosis - single layer	2	3	6	no	8
46	rajagurunathan	43	male	ileal perforation	ileoileal anastomosis - double layer	3	3	5	no	8
47	vinayagam	47	male	ileal perforation	ileoileal anastomosis - single layer	2	3	6	no	8
48	prakash	42	male	ileal perforation	ileoileal anastomosis - double layer	3	4	7	no	10
49	kannapan	51	male	ileal perforation	ileoileal anastomosis double layer	4	5	8	no	12
50	joseph	39	male	ileal perforation	ileoileal anastomosis -double layer	4	5	7	no	11