A PROSPECTIVE STUDY TO COMPARE CONTINOUS VERSUS INTERRUPTED X SUTURE IN PREVENTION OF BURST ABDOMEN

M.S. DEGREE EXAMINATION

BRANCH I - GENERAL SURGERY

APRIL 2019

Department of General Surgery

MADURAI MEDICAL COLLEGE AND GOVT RAJAJI HOSPITAL

Madurai – 20

THE TAMILNADU DR.M.G.R. MEDICAL UNIVERSITY

CHENNAI, INDIA.

BONAFIDE CERTIFICATE

This is to certify that this dissertation titled **"A PROSPECTIVE TO COMPARE CONTINOUS VERSUS INTERRUPTED X SUTURE IN PREVENTION OF BURST ABDOMEN"** submitted by **Dr.C.SATHAIAH** to the faculty of General Surgery, The Tamil Nadu Dr. M.G.R. Medical University, Chennai in partial fulfilment of the requirement for the award of MS Degree Branch I General Surgery, is a bonafide research work carried out by him under our direct supervision and guidance.

Prof.Dr.S.R.DHAMOTHARAN, M.S., FIAGES
Professor and HOD of Surgery
Madurai Medical College,
Madurai- 625020

Prof.Dr. A.M.SYED IBRAHIM MS.,FAIS
Professor of Surgery,
Madurai Medical College,
Madurai- 625020

CERTIFICATE BY THE DEAN

This is to certify that the dissertation entitled **"A PROSPECTIVE STUDY TO COMPARE CONTINOUS VERSUS INTERRUPTED X SUTURE IN PREVENTION OF BURST ABDOMEN"** is a bonafide research work done by **Dr.C.SATHAIAH,** Post graduate student, Dept. of General Surgery, Madurai Medical College And Govt. Rajaji Hospital, Madurai, under the guidance and supervision of **Dr.A.M.SYED IBRAHIM MS FAIS,** Prof of General Surgery, Madurai Medical College and Govt. Rajaji Hospital, Madurai.

PLACE: Madurai **Prof.Dr.D.MARUTHUPANDIAN M.S., FICS.,FAIS.,**

DATE **DEAN,**

Madurai Medical college & Hospital, Madurai

DECLARATION BY THE CANDIDATE

I **Dr. C.SATHAIAH** hereby solemnly declare that this dissertation entitled **"A PROSPECTIVE STUDY TO COMPARE CONTINOUS VERSUS INTERRUPTED X SUTURE IN PREVENTION OF BURST ABDOMEN",** at the department of general surgery, Govt Rajaji Hospital Madurai under the guidance of Prof.Dr.Syed Ibrahim MS, Professor of General surgery, during the period of 6 months. I also declare that this bonafide work has not been submitted in part or full by me or any others for any award, degree, diploma to any other university or board either in india or abroad. This is submitted to the TamilNadu Dr. M.G.R. Medical University, Chennai, in partial fulfilment of the regulations for the award of M.S. degree (Branch I) General Surgery.

PLACE: Madurai

DATE: **Dr.C.SATHAIAH**

ACKNOWLEGMENT

First I would like to give thanks to Lord God Almighty whose blessings made this study possible .At the outset, I wish to express my sincere gratitude to our Unit Chief Prof.Dr.A.M. SYED IBRAHIM MS FAIS for his expert supervision and valuable suggestions. I wish to express my whole hearted thanks to our Assistant Professors DR.LAKSHMI NARAYANAN MS, DR.JANAKIRAMAN MS, DR.SUMATHY MS.DR.KUNDHAVI MS for their constant encouragement and excellent guidance. I express my deep sense of gratitude and heartfelt thanks to Prof.Dr.S.R.DHAMOTHARAN M.S., FIAGES, Head of the Department of General Surgery, Government Rajaji Hospital and Madurai Medical College for his invaluable guidance and helpful suggestions throughout my study. Last but not least, my gratitude to all the patients who submitted themselves for this study.

PLACE: Madurai

Date: Dr.C.Sathaiah

Post graduate in General surgery

Department of General surgery, MMC, Madurai

TABLE OF CONTENTS

INTRODUCTION

Acute wound failure, otherwise known as wound dehiscense or burst abdomen refers to postoperative separation of abdominal musculoaponeurotic layers.wound dehiscence is among the most dreaded complication faced by the surgeon and is of great concern because of the risk of evisceration;the need for some form of intervention and possibility of repeat dehiscence ,surgical wound infection and incisional hernia formation.

Acute wound failure occurs in approximately 1% to 3% of patients who undergo an abdominal operation. Dehiscence most often develops 7 to 10 days postoperatively but may occur anytime after surgery, from 1 to more than 20 days. A multitude of factors may contribute to wound dehiscence .Acute wound failure is often related to technical errors in placing sutures too close to the edge, too far apart, or under too much tension Local wound complications such as hematoma and infection can also predispose to localized dehiscence. In fact, a deep wound infection is one of the most common causes of localized wound separation. Increased intra-abdominal pressure (IAP) is often blamed for wound disruption and factors that adversely affect wound healing are cited as contributing to the complication. In healthy patients, the rate of wound failure is similar whether closure is accomplished with a continuous or interrupted

technique. In high-risk patients, however, continuous closure is worrisome because suture breakage in one place weakens the entire closure.

FACTORS ASSOCIATED WITH WOUND DEHISCENCE

Technical error in fascial closure

Emergency surgery

Intra-abdominal infection

Advanced age

Wound infection, hematoma, and seroma

Elevated intra-abdominal pressure

Obesity,Malnutrition

Chronic corticosteroid use

Previous wound dehiscence

Radiation therapy and chemotherapy ,Systemic disease (uremia, diabetes mellitus Prevention of acute wound failure is largely a function of careful attention to technical detail during fascial closure, such as proper spacing of the suture, adequate depth of bite of the fascia, relaxation of the patient during closure, and achieving a tension-free closure. For very high-risk patients, interrupted closure is often the wisest choice. Alternative methods of closure must be selected when primary closure is not possible without undue tension.

Although retention sutures were used extensively in the past, their use is less common today, with many surgeons opting to use a synthetic mesh or bioabsorbable tissue scaffold.

AIM AND OBJECTIVES

The present study was undertaken to assess the proportion of burst abdomen in post midline laparotomy patient using interrupted X sutures versus continous suture technique in sheath closure.

REVIEW OF LITERATURE

Incision and closure of abdominal wall is one of the most frequently performed surgical procedure

ANATOMY OF ANTERIOR ABDOMINAL WALL

The structural integrity of anterior abdominal wall depends upon the rectus abdominis muscle,muscles if flank,conjoined tendon of the flank muscles that combined to form rectus sheath. The rectus abdominis muscle lies on the either side of the midline, lateral to these are external oblique, internal oblique, and transverse abdominis. The broad sheet like tendons of these latter muscles form aponeuroses that unite with their corresponding members of the other side,forming dense covering of the rectus abdominis muscles,called rectus sheath.

RECTUS SHEATH

Rectus sheath is formed by the conjoined aponeuroses of the flank muscles.The line of demarcationbetween the muscularvand the aponeurotic portion of the external oblique occurs along the vertical line through the Anterior superior iliac spine.The internal oblique and transverse abdominis muscles extend

farther toward the midline,coming closest at the inferior margin,at the pubic tubercle.therefore the muscular fibres of the internal oblique are found underneath the aponeurotic portion of external oblique.

SIGNIFICANCE

In forming the rectus sheath,conjoined aponeuroses of the flank muscles are separable lateral to the rectus muscles,but as they reach the midline,they fuse and lose their separate directions.As consequence,these layers are incised togetherin the midline during any transverse fascial incision. The lower one fourth of the rectus sheath lies entirely anterior to the rectus muscle,while in the upper three fourth it splits to form anterior and posterior rectus sheath.The lower margin of the posterior frectus sheath is recognized as semicircular or arcuate line,occurring midway between umbilicus and pubic symphysis.cranial to this line,linea alba unites anterior and posterior sheathes.sharp dissection is usually needed ,when elevating rectus sheath in pfannestiel incision.when the peritoneum is opened vertically and past the arcuate line,posterior frectus sheath is divided along with the peritoneum and must be repaired during closure.

VESSELS OF ANTERIOR ABDOMINAL WALL

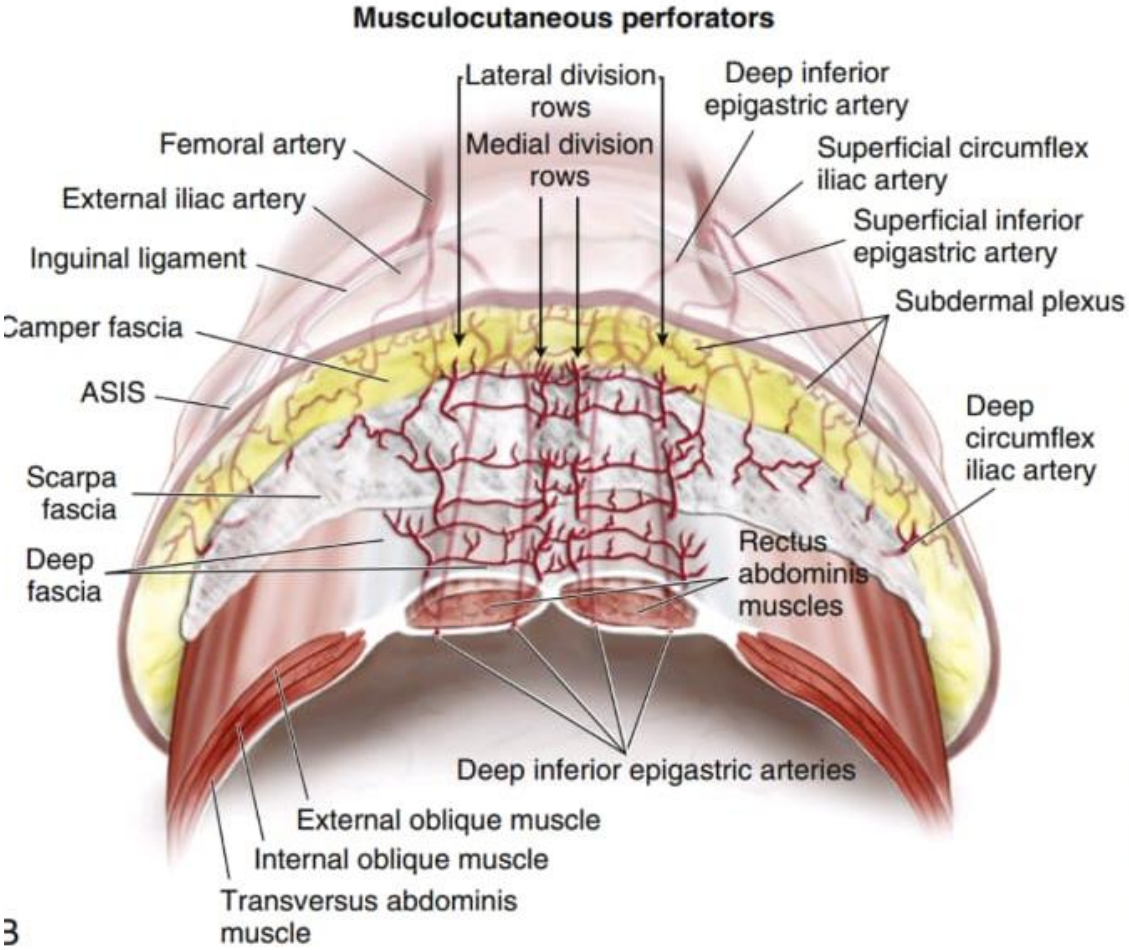

Superior epigastric artery

Inferior epigastric artery

Superficial epigastric artery

Superficial epigastric,runs a diagonal course in subcutaneous plane from femoral vessels towards umbilicus,above fascia scarpa.Deep inferior epigastric artery ,a branch of external iliac vessel found lateral to the rectus sheath runs in a diagonal course towards the umblicus,crossing the muscles lateral border midway between the pubis and umblicus.The angle between the vessel and rectus sheath forms the apex of the hasselbach's triangle,for which the base is formed by the inguinal ligament.

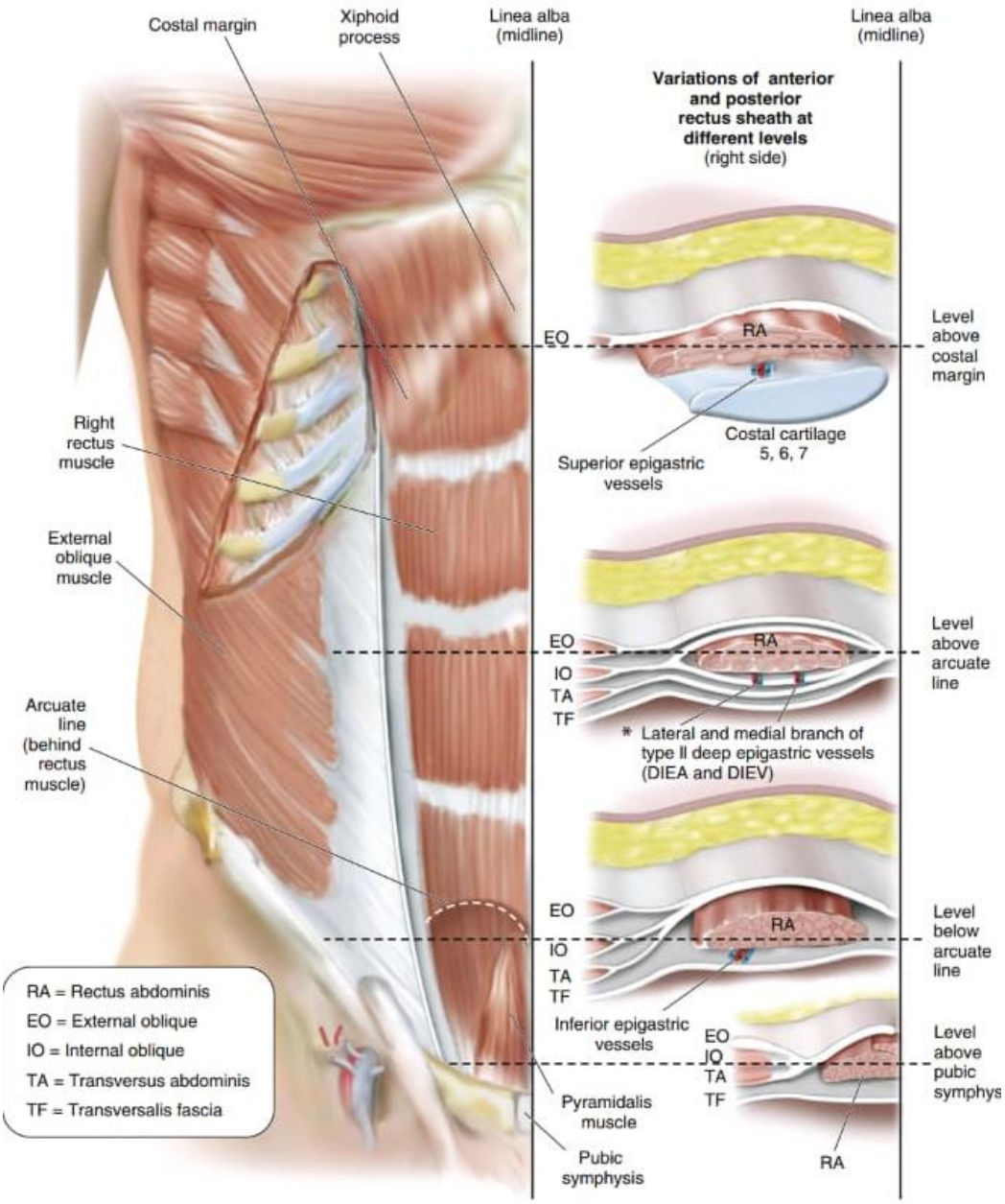

* Common branching patterns:
- Type I DIEA continues as a single vessel (29%).
- Type II DIEA divides into two vessels (57%).
- Type III DIEA is a trifurcation (14%).

STRUCTURE	SIGNIFICANCE
Superficial inferior epigastric artery	Isolate and ligate on line from femoral vessels to umbilicus
Insertion of pyramidal muscle	Identifies the midline
Deep inferior epigastric vessels	Isolate and ligate during maylard incision
Arcuate line	Repair posterior rectus sheath above the line
Bladder reflection on to peritoneum	Enter lateral to midline

WOUND HEALING

Wound complication traced to the

1. Failure of the healing process to eliminate the bacteria
2. Failure of healing process to synthesize adequate quantities of collagen to restore abdominal wall strength

The wound healing process is a balance between the amount of tissue damage done during the operation and ability of the body to decontaminate and repair it.

With the initial incision made, the damage to the blood vessels, expose the blood and platelets to the connective tissue, begins the inflammatory response, that will sterilize and heal the wound. During the initial phase of the process, small vessels in the region of injury become permeable to molecular and cellular mediators of inflammation, which are necessary to eliminate the bacteria by opsonisation, paghocytosis,and cellular killing.Use of vasoconstrictive agents like T saline during incision, causes vasoconstriction limits the initial inflammatory response, associated with increased infection rate.Vasoconstriction limits the outpour of inflammatory mediators, so that bacteria multiply exponentially become established in well numbers.

After this initial phase, the polymorphonuclear neutrophills and wandering macrophages begin the work of digesting damaged tissues, killing the bacteriaand synthesizing chemotactic factors that direct wound repair. These cells may lay the groundwork for the appearance of the fibroblast that will establish the wound strength.These cells have limited activity in the anaerobic environment, their proper function in the wound depends on the oxygen supply to the tissues. hence protecting the capacity of the adjacent tissues to perfuse the healing wound after the operation bhy avoiding unnecessary damage to the tissues.

The next critical factor in the wound healing, is the amount of necrotic tissue created. Actual repair begins from the healthy tissues. prior reaching the incision edge, healing process must must disinfect,digest and remove the dead tissues.when ever there is a delay,bacteria in the ischemic tissue multiplies increasing the need for clean up,delaying repair and increasing the likelihood of infection.Hemostasis by ligation, electrocautery, abrasion and dessication of tissue are all injuries that occur in any incision. The more of these damaging elements present,the more necrotic tissue the body must eliminate before joining the edges of the wound.

ABDOMINAL WALL STRENGTH

The re establishment of abdominal wall strength depends on the synthesis of newer connective tissue,which is occomplished by fibroblast and requires the protein precursors for collagen synthesis. Ischemia caused by

1.Tight sutures

2.Foreign bodies

3.Lack of nutritional factors

4.Inhibitors of cell division

Adversely affect the wound healing.

COLLAGEN

Primary structural protein of the body,synthesized by the fibroblast.It begins to appear in the wound on the second day,as an amorphous gel devoid of strength.Maximum collagen synthesis occurs around on fifth day.deficiency of oxygen,vitamin C,amino acid precursorsinhibit the wound healing.80 % of original wound strength is reached in about 6 weeks.

BURST ABDOMEN

INCISIONS FOR ABDOMINAL SURGERY

Many approaches to the abdomen are suitable and the choice of incision is mainly related to the accessrequired. The surgical indications for each incision and theirexecution are discussed individually below, but the techniquefor opening the peritoneum is similar in all incisionsand therefore considered first.

Opening the peritoneum

The utmost care must be taken to ensure that no underlying viscus is injured during incision of the peritoneum. Except at the umbilical cicatrix and at surgical scars, the peritoneum is separated from the abdominal wall by a variable layer of extraperitoneal fat. When the peritoneum has been exposed, a small bite is taken with artery forceps, and is lifted forwards.

It is an advantage to do this during expiration, when the viscera tend to fall away from the abdominal wall. The fold which is lifted up may be given a gentle shake to dislodge any adherent structure, or it may be pinched between finger and thumb so that its thickness can be estimated. A second artery forceps is then applied alongside the first, and the fold is carefully incised . If an opening is not immediately apparent the forceps should be taken off and re-applied. As soon as the peritoneum is breached, air enters and a space is created between the parietal

peritoneum and intraperitoneal structures. When the initial opening has been made it is enlarged – usually by using scissors or diathermy under direct vision. If the under-surface of the peritoneum is not visible, a finger should be inserted to check that no bowel is adherent to the peritoneum in the line of the incision.

Particular care must be taken in opening an old incision, as the abdominal wall musculature and peritoneum are adherent and often fused into a single layer of fibrous scar to which loops of small bowel may be adherent. Even with great care inadvertent enterotomy may occur and greatly increases morbidity.

MIDLINE INCISIONS

Midline incisions provide good access to the whole abdomen.

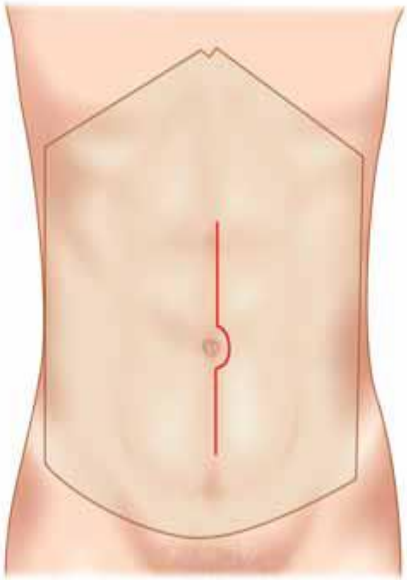

The linea alba may be divided from xiphisternum to symphysis pubis, although commonly a shorter incision is made and only extended if

necessary. A large xiphisternum can be excised if it is restricting access. Troublesome bleeding may then occur from the terminal branches of the internal thoracic artery, which will require diathermy coagulation. The main disadvantage of a midline incision is that it crosses the natural crease lines of the skin and a hypertrophic scar is common, especially in young children.In addition to the cosmetic issues, the thickening and shortening of the scar at the waist crease may be irritated by clothes. The umbilicus presents an additional cosmetic challenge. A straight incision through the umbilicus is favoured by some surgeons, but most prefer to curve the incision around it, taking care to cut the skin perpendicular on the curve. Forceps placed on the umbilical skin, retracting it to one side and holding the skin taut while the skin incision is made, may be helpful. An alternative is to make the whole skin incision paramedian, followed by a midline incision through the linea alba.

The incision is deepened through the subcutaneous fat, either with a scalpel or with diathermy, and any bleeding vessels controlled, until the linea alba is exposed throughout the length of the incision. At the umbilical cicatrix the peritoneum is in close apposition to the linea alba, and this is often the easiest and safest place to gain access to the peritoneal cavity. Two forceps are applied to the linea alba, one either side of the midline, and it is lifted upwards while the fascia is carefully

incised. If this incision does not enter the peritoneal cavity the peritoneum is incised separately.

The linea alba above and below the umbilicus is separated from the peritoneum by a significant layer of extraperitoneal fat and may be divided without immediate entry through the parietal peritoneum, which is then incised as a separate layer. As the incision is extended it is possible, if exactly in the midline, to encounter no muscle fibres. Below the arcuate line however, the linea alba is narrow and there is no posterior sheath. In addition, pyramidalis may be obvious. In this area visible muscle fibres do not indicate that the incision has strayed from the midline. The rectus muscles may be separated right down to the symphysis pubis, but care must be taken in extending the peritoneal division down to this level or an inadvertent incision may be made into the bladder. The peritoneal incision must therefore be deviated laterally if further low division is required for access. In the upper abdomen there is a significant pad of extraperitoneal fat which extends a few centimetres either side of the midline. Some surgeons therefore prefer to divide the peritoneum lateral to this. The fold of the falciform ligament extending from the liver to the anterior abdominal wall may cause some confusion, and it may need to be divided for access. Vessels running within the ligament can cause troublesome bleeding if not secured.

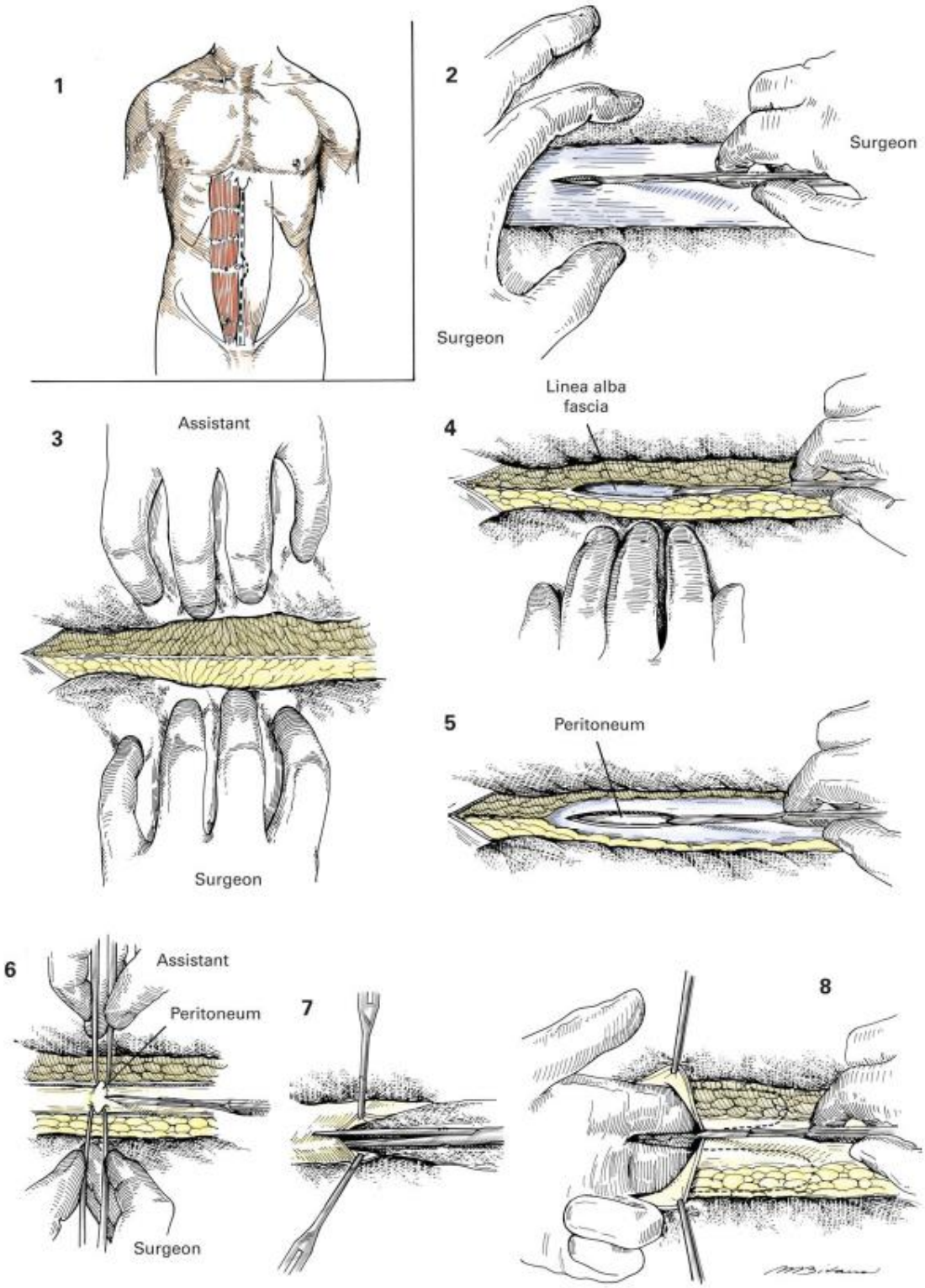
1
2
Surgeon
Surgeon
3
Assistant
Surgeon
4
Linea alba
fascia
5
Peritoneum
6
Assistant
Peritoneum
Surgeon
7
8

Suprapubic incisions are transverse skin incisions placed just above the pubis. The incision through the abdominal wall, however, is a lower abdominal midline incision. The skin and subcutaneous tissue are reflected up, off the anterior rectus sheath, and the remainder of the incision is then vertical. The skin incision lies in, or parallel to, a deep skin crease, in contrast to a midline skin incision which crosses it. If access is required to the prostate or bladder the peritoneum is left intact after separation of the recti and the pre-peritoneal space is developed distally.

CLOSURE OF MIDLINE INCISIONS

The closure of midline incisions is perfectly adequate in a single layer (mass closure), with a continuous suture. The peritoneum may be included in the closure, but this is not essential as it will appose naturally when the fascia is closed.

The suture material must retain tensile strength until the healing fascial scar has developed its own. Thus, either a nonabsorbable material should be used, or an absorbable material which loses its tensile strength slowly. A strong (gauge 1or 0) monofilament nylon or polydioxanone (PDS) suture is therefore suitable. Closure is started at one end and a knot formed.

9

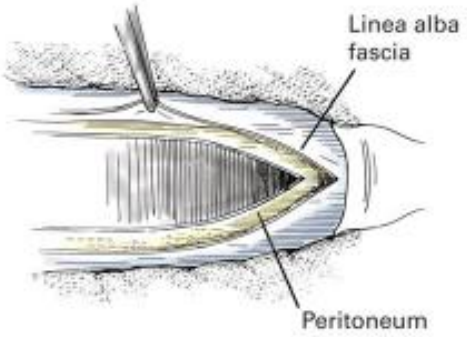

10

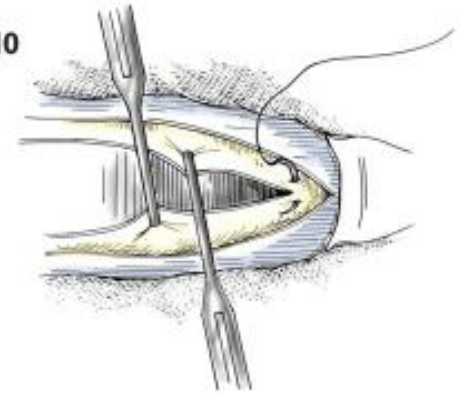

11

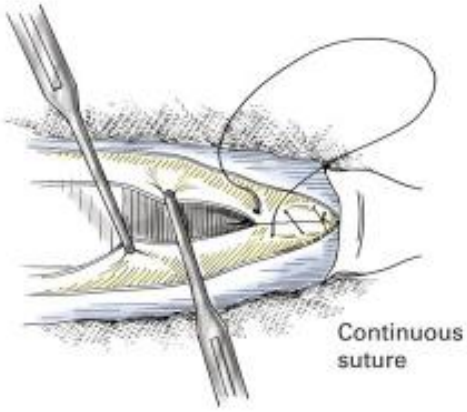

12

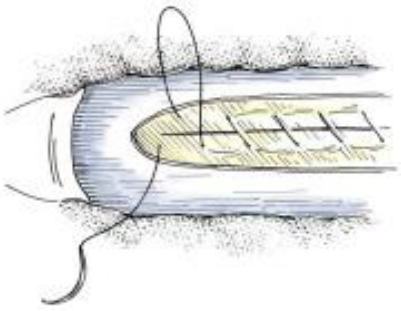

13

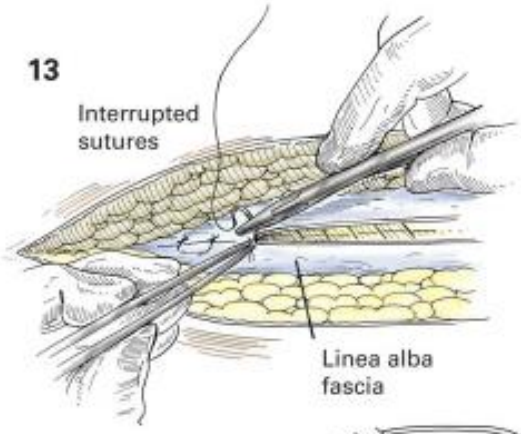

14

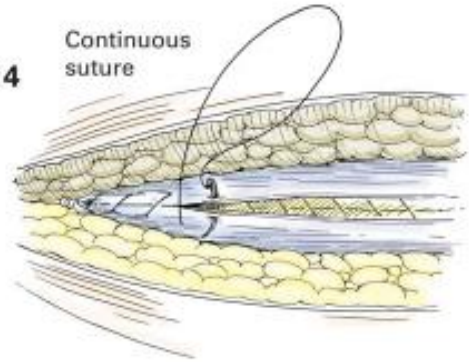

15

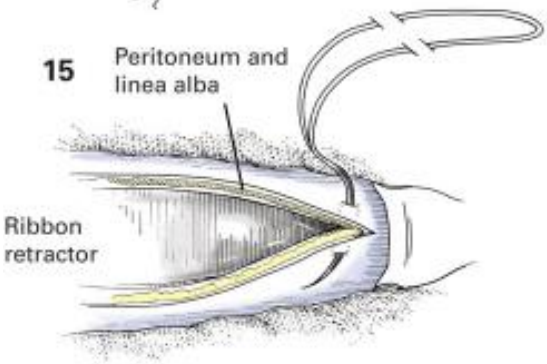

16

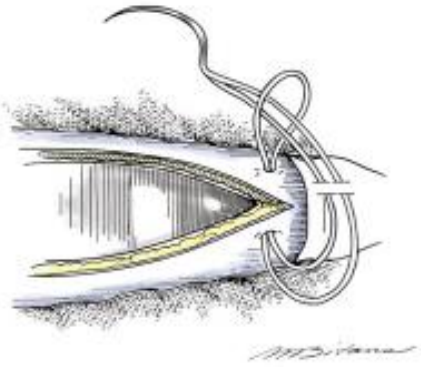

If the first stitch is inserted from under the fascia, the knot will lie deep to the fascia. Each suture should be placed so that it lies no more than 1 cm advanced from the previous suture and the needle should be inserted 1 cm from the cut edge . If the incision has entered the rectus sheath, the anterior sheath may retract, and great care must be taken to include it in the sutures as this is the most important layer for the strength of the wound. The temptation to pull the suture tight must be resisted as this strangulates the tissue. The suture should only be as tight as is required to hold the edges in apposition. If these rules are followed, the total length of suture material used will be at least three times the length of the incision. Two or three lengths of suture will be required for a long midline incision. An Aberdeen knot may be used to tie the suture at the end of a continuous suture, but a more satisfactory method is to start a second suture from the opposite end and tie the two ends together where they meet.

A non-absorbable knot outside the fascia can be troublesome in a thin patient. Again it is possible, by finishing the suture on the inside, to tie a knot which will lie under the fascia. Alternatively, the cut ends of a knot should be passed under an adjacent suture to hold it lying flat. The midline incision only became universally popular with the development of inert non-absorbable suture material such as nylon, and slowly absorbable synthetic material such as PDS. Silk was never popular for

abdominal wall closure after gastrointestinal surgery since, if a wound infection developed, healing did not occur until all infected braided suture material was removed. Catgut was in general use for abdominal closure but, as it lost its tensile strength within two weeks, burst abdomens and incisional herniae were a relatively common complication with midline wounds. Paramedian incisions were favoured for their additional strength. However, it should be remembered that incisional herniae are still more common following midline than following paramedian incisions, even when modern suture materials are used.

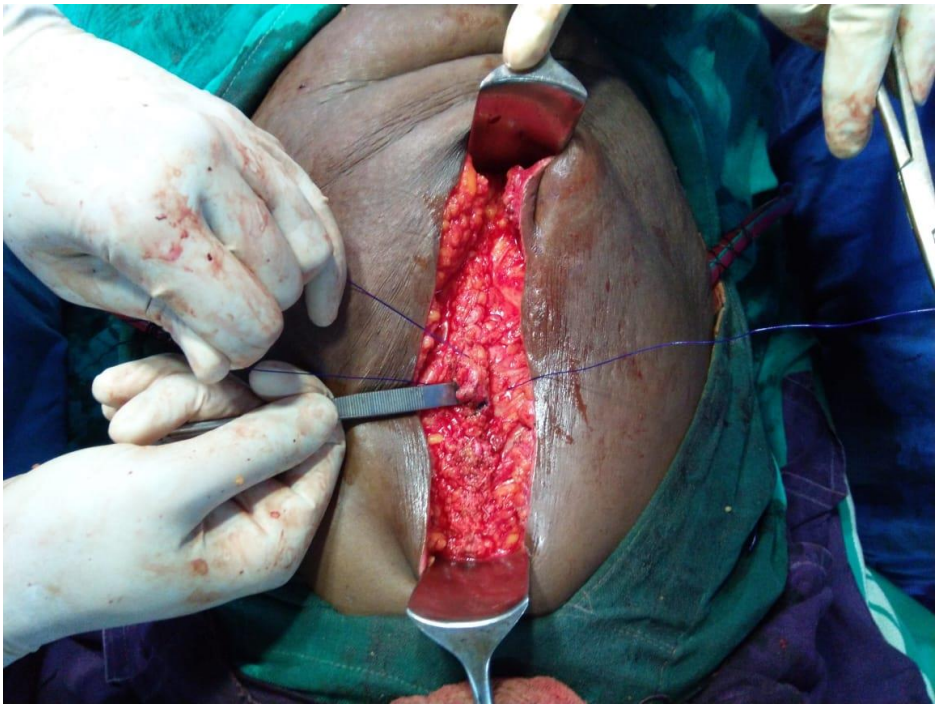

INTERRUPT X STURE



4 Interrupted closure was performed using No.1 prolene suture. A large bite was taken outside in 2cm from the cut edge of the linea alba. The needle emerged on the other side from inside out diagonally 2 cm from the edge and 4cm above and below the first bite. The strand was subsequently crossed or looped around the free end of sutureand continued outside-in ,diagonally at 90 ‘ to the first diagonal. The two end tied just tight enough to approximate the edges of linea alba taking care not to include bowel or omentum between the edges.

This created X like crosses one on the surface and another deep to linea alba. The next X suture was placed 1 cm away from the previous one. Henceforth in a 14 cm long ,3 X sutures were applied .

PARAMEDIAN INCISIONS

These provide broadly similar access to midline incisions, but they are no longer in regular use. They were favoured for their additional strength when catgut was the suture material for abdominal wall closure. The paramedian skin incision avoids the challenges posed by the umbilicus, and is deepened down to the fascia of the anterior layer of the rectus sheath. This is incised in line with the skin incision to expose the rectus muscle, which is displaced laterally preserving its innervation. The muscle must be released from the sheath where it is tethered at the tendinous intersections. The posterior sheath is exposed and then divided in line with the ante-rior incision and the peritoneum is opened as described above.

CLOSURE OF A PARAMEDIAN INCISION

The closure of paramedian incision is undertaken in two layers. After the posterior sheath has been repaired, the rectus muscle is released back into its original position before the anterior sheath is sutured. The muscle lies between the two suture lines and may give some strength to the closure. The additional tension sutures in this old illustration underlines the concern over dehiscence when catgut was in routine use.

Appendix muscle-splitting incisions

These provide limited access, but sufficient for an appendicectomy as the appendix and part of the caecum can be delivered out through the incision. The gridiron and Lanz incisions differ in their skin alignment, but the deeper aspects of the incisions are similar. The external oblique aponeurosis is divided in line with its fibres to expose the fleshy internal oblique. Internal oblique and the underlying transversus are split in line with their fibres by blunt dissection . Retraction displays the peritoneum which is entered as described above. If more extensive access becomes necessary, the incision may be extended upwards and laterally by converting it to a muscle-cutting incision and dividing internal oblique and transversus in line with the external oblique division. Alternatively, medial access can be increased by dividing the lateral edge of the rectus sheath. This allows wider separation of the internal oblique and transversus muscles, and the rectus muscle can be displaced medially CLOSURE OF APPENDIX INCISIONS is performed in layers. The peritoneum is closed first with a continuous absorbable suture. One or two loose absorbable sutures appose the muscles, and finally the external oblique is closed with a continuous or interrupted absorbable suture . Even when catgut was routinely used for these wounds incisional herniae were very rare.

PFANNENSTIEL INCISIONS

Pfannenstiel incisions also avoid the division of muscle. The scar is less obtrusive than the alternative lower abdominal midline incision, but at the cost of altered sensation of the lower abdominal skin. These incisions afford good access to the bladder, prostate and female reproductive organs, and are extensively used by gynaecologists. However, they are less suitable for rectal surgery as the splenic flexure will frequently have to be mobilized before an anastomosis can be performed, and access for this manoeuvre is very limited.

The skin incision is a curved transverse incision, convex downwards, centred a few centimetres above the pubis. The abdominal muscles are not divided transversely. The anterior layer of the rectus sheath alone is divided in line with the skin incision, dissected off the rectus muscle, and sheath and skin are reflected upwards . The rectus muscles are separated in the midline and retracted to expose the transversalis fascia and the peritoneum (above the arcuate line there will also be posterior rectus sheath).

CLOSURE OF PFANNENSTIEL INCISIONS is in layers, and particular care must be taken over the fascial closure at the upper extremity or an incisional hernia may develop at the Umbilicus.

MUSCLE-CUTTING INCISIONS

These can be adapted to provide the access required, and may be either transverse or oblique. The fascia and muscles are generally divided in line with the skin incision.

Diathermy division of the muscle bellies reduces blood loss from small vessels, but larger vessels require individual ligation.

Retraction of the divided muscle fibres is seldom a problem except when the lower rectus muscle is cut transversely. Rectus muscle retraction in the upper abdomen is prevented by the muscle's tendinous intersections, which are attached to the rectus sheath. After division of the abdominal muscles in line with the skin incision, the peritoneum is picked up, incised and the peritoneal cavity entered as described above.

A long transverse muscle-cutting incision, either just above or below the umbilicus, provides good access to most of the abdomen. Access however is partially dependent on patient build, and this incision generally allows better access in those with a short wide abdomen and a wide costal angle. A transverse incision divides the abdominal skin in line with the skin creases and gives a good cosmetic scar. The postoperative pain is restricted to fewer dermatomes, and in particular the avoidance of an upper abdominal wound results in better respiratory effort during the early postoperative period. Access to the oesophageal hiatus and the

pelvis is however usually inferior to that obtained with a long midline incision.

In *infants*, transverse incisions are preferable to midline incisions. The abdominal muscle bulk is small, the abdomen is short and wide and the costal angle is obtuse, allowing easy access to the diaphragm. The pelvis is poorly developed in infancy, and pelvic access is not made any more difficult by a transverse approach. A transverse scar is cosmetically superior in the infant and child, especially as a vertical scar forms a ‘contracture’ as the child grows. In neonatal abdominal surgery the vessels associated with the placenta may still be patent and require formal ligation. The umbilical vein lies in the midline above the umbilicus, initially between the linea alba and the peritoneum before turning deep to run towards the liver in the free edge of the falciform ligament. The umbilical arteries lie either side of the midline below the umbilicus and converge towards the umbilicus from their origin from the internal iliac arteries. They lie between the peritoneum and the abdominal wall muscles.

OBLIQUE SUBCOSTAL MUSCLE-CUTTING INCISIONS

It provide good access to the upper abdomen. A right subcostal (Kocher) incision can be used for liver and biliary surgery, and a left subcostal for splenic surgery. The angulation of the incision overcomes the limitations imposed by a narrow costal angle, but several abdominal nerves are divided. A bilateral subcostal incision – sometimes described as a chevron or rooftop incision – is in essence a modification of a transverse incision which gives excellent access to the upper abdomen, though many of the advantages of a transverse incision at the level of the umbilicus are lost.

Oblique iliac fossa muscle-cutting incisions are useful for access to the sigmoid colon and the ureter. They are similar to the appendix incisions except that no attempt is made to separate the internal oblique and transversus muscles in the line of their fibres. The muscles are cut in the same axis as the incision of external oblique. If access to the retroperitoneal organs is desired the peritoneum is not opened, but swept medially.

LOIN INCISIONS

A loin incision is often just a more posterior variety of the oblique muscle-cutting incision. At the posterior end of the incision latissimus dorsi, serratus posterior inferior and quadratus lumborum replace the external and internal oblique muscles of the more anterior incision . All muscles are divided in line with the skin incision. The incision may be positioned to be subcostal, or over and in line with the 10th to 12th ribs. If the incision is subcostal, posterior division of the renal fascia gives access to the retroperitoneal fat and the peritoneum is swept away anteriorly. A higher incision gives better access to the kidney or adrenal. A supracostal incision along the superior border of the 10th, 11th or 12th rib will usually allow good renal access. Alternatively, the incision may be through the bed of the lowest palpable rib – the 12th, or the 11th if the 12th is rudimentary. The periosteum over the rib is exposed and incised. The rib is freed sub-periosteally, and then divided near its angle and the anterior part removed.

Incision of the bed of the rib gives access into the retroperitoneal space. If the incision is at the level of the 10th rib, access can be increased by conversion to a posterior thoracoabdominal incision. The thoracic component of the incision is deepened and the pleura opened. The diaphragm is incised in line with the incision.

A further alternative in the loin is the **lumbotomy**, in which a vertical incision is made from the lowest rib to the iliac crest along the lateral border of sacrospinalis, and deepened through muscles and fascia into the retroperitoneal space.

CLOSURE OF ALL MUSCLE-CUTTING INCISIONS is usually in two layers, using a continuous suture. The inner layer consists of peritoneum, transversalis fascia, transversus and internal oblique muscles – or the more posterior equivalents – along with the posterior rectus sheath. Most surgeons prefer to use an absorbable suture for this layer. The outer layer consists of external oblique and the anterior rectus sheath, and normally incorporates a variable portion of the rectus muscle. This layer should be closed either with non-absorbable material or with an absorbable suture which retains tensile strength for several weeks. The covering fascia of the muscles has more strength than the muscle fibres and should always be included in the bites. Sutures must not be over-tightened or muscle strangulation occurs.

ANTERIOR THORACO-ABDOMINAL INCISIONS

These incisions provide simultaneous access to the abdomen and chest by division of the costal margin and can be used for access to the lower oesophagus or liver. Division of the costal margin impairs postoperative respiratory function, and this incision is now often avoided in favour of a trans-diaphragmatic or transhiatal approach. Thoraco abdominal incisions extend obliquely upwards and laterally from a point midway between the umbilicus and xiphisternum to cross the costal margin and continue along the 8th interspace. The abdominal portion of the incision is an oblique, muscle-cutting incision.

Alternatively, an initial midline incision can be extended laterally across the costal margin. Entry into the chest may be through an intercostal space or through the base of a rib after resection. The diaphragm can be divided radially from the costal margin towards the hiatus to produce a single abdominothoracic cavity. Alternatively, it can be divided circumferentially 2 cm in from the chest wall – thereby preserving its innervation and leaving a cuff of diaphragm for re-attachment. This incision allows simultaneous access to both chest and abdomen, but these remain as two separate body cavities.

CLOSURE OF THORACO-ABDOMINAL INCISIONS must include careful attention to diaphragmatic closure in order to prevent an iatrogenic diaphragmatic hernia. The use of a chest drain is usually indicated.

CLASSIFICATIONS OF SURGICAL WOUNDS

Class I: Clean

An uninfected operative wound in which no infammation is encountered and respiratory, alimentary, genital, or uninfected urinary is not entered. they are primarily closed, and if necessary, drained with close drainage. 1–5% risk of SSI

Class II: Clean-contaminated

An operative wound in which the respiratory, alimentary, genital, or urinary tracts are entered under controlled conditions and without unusual contamination. In particular, surgeries involving the biliary tract, appendix, vagina, and oropharynx are included in this category provided no evidence of infection or a major break in technique is encountered. 2–9% risk for SSI

Class III: Contaminated Open fresh accidental wounds.

In addition, surgeries with major breaks in sterile technique (eg, open cardiac massage) or gross spillage from the gastrointestinal tract, and incisions in which acute, nonpurulent inflammation is encountered are included in this category. 3–13% risk for SSI.

Class IV: Dirty-infected

Old traumatic wounds with retained devitalized tissue and those that involve existing clinical infection or perforated viscera. 3–13% risk for SSI

SURGICAL SITE INFECTIONS

SSIs are subdivided into two categories:

incisional and

organ/space.

Incisional SSIs are limited to the surgical site. They are further divided into superficial SSIs, which involve the skin and subcutaneous tissue and deep SSIs, which involve the fascial and muscle layers.

Organ/space SSIs can involve any part of the anatomy that was manipulated during the surgery excepting the incision. and infections.

INCISIONAL SSI

SUPERFICIAL INCISIONAL SSI

Infection occurring within 30 days of surgery,

and

Infection involves only skin and subcutaneous tissue;

and

At least one of the following:

1. Purulent discharge

2. Organisms isolated from aseptically cultured fluid or tissue

3. At least one sign of infection: pain or tenderness, localized swelling, redness, or heat

and

the incision is deliberately opened by the surgeon unless the incision is culture negative

4. Diagnosis of SSI by the surgeon or attending Physician

DEEP INCISIONAL SSI

Infection occurring within 30 days of surgery; or within 1 year of operation if implants are in place;

and

Infection involves deep soft tissue;

and

At least one of the following:

1. Purulent discharge

2. Deep incision spontaneously dehiscences or is deliberately opened by a surgeon when the patient has at least one of the following symptoms: fever (>38°C), localized pain or tenderness unless the site is culture negative

3. Evidence of deep infection on direct examination, during reoperation, or on radiological examinations

4. Diagnosis of SSI by the surgeon or attending physician

SPACE/ORGAN SSI

Infection occurs within 30 days of surgery, or within 1 year of operation if implants are in place; **And** Infection involves any part of anatomy that was manipulated during an operation, other than the incision; **and**

At least one of the following

1. Purulent drainage that is placed through a stab wound into the organ space
2. Organism isolated from and aseptically Cultured fluid or tissue
3. Evidence of deep infection on the direct examination, during reoperation, or on radiological examinations
4. Diagnosis of SSI by the surgeon or attending physicianis

The organisms most commonly responsible for SSIs are *Staphylococcus aureus* and coagulase-negative staphylococci. After abdominal surgery, infection with enteric organisms (*Escherichia coli* and *Enterobacter* species) .The use of preoperative prophylactic antibiotics in all clean-contaminated and clean cases with associated risk factors is recommended.

The antibiotic of choice for most upper gastrointestinal procedures is cefazolin or a comparable first-generation cephalosporin. For colorectal surgery, metronidazole is added to this regimen. The administration of a mechanical and oral antibiotic bowel preparation has been recommended prior to colorectal surgery, although this practice has been challenged by recent meta-analyses suggesting no benefit. Preoperative intravenous antibiotics should be administered 30–60 minutes before the incision is made to allow the agent to reach maximal tissue concentration. In obese patients, the antibiotic should be adjusted appropriately. For long procedures, the antibiotic should be readministered after every two halflives to maintain an effective serum concentration.

The treatment for incisional SSIs includes removal of skin stitches or staples to allow drainage of any underlying collection. Antibiotics are indicated in the presence of cellulitis. The effective use of antibiotics depends on (1) appropriate coverage of the offending organisms and (2) maintenance of an adequate tissue concentration of the drug. Cefazolin or an equivalent first- or second-generation cephalosporin is appropriate for uncomplicated incisional SSI.

Wound cultures are obtained in the presence of purulence and are used to guide antibiotic selection. Following abscess drainage, wounds are left open and allowed to close by secondary intention.

Deep space SSIs also require drainage. Increasingly, this is achieved by percutaneous placement of a drain under CT or ultrasound guidance. deep space infections are not amenable to percutaneous drainage require operative drainage. Broad-spectrum antibiotics are indicated until culture data is obtained at which point the spectrum should be narrowed to target the offending organism.

PREVENTION OF SURGICAL SITE INFECTIONS

Preoperative Factors

Preparation of the patient:

1. Identify and treat all infections remote from the surgical site and postpone elective surgery until infection has resolved.
2. Do not remove hair unless it interferes with surgery.
3. If hair is to be removed, remove immediately preoperatively using clippers.
4. Ensure good blood glucose control in diabetic patients and avoid hyperglycemia.
5. Encourage cessation of tobacco use (at least for 30 days before surgery, if possible).
6. Do not withhold blood products, as transfusion does not affect rates of SSI.
7. Require the patient to shower or bathe with an antiseptic solution the night before surgery.
8. Remove gross contamination from the surgical site before performing antiseptic skin preparation.
9. Use an appropriate antiseptic solution for skin preparation.
10. Apply preoperative antiseptic solution for skin preparation in concentric circles moving outward toward the periphery.
11. Keep the preoperative hospital stay as short as possible.

Hand/forearm antisepsis for surgical team:

1. Keep nails short and do not wear artificial nails.

2. Perform a preoperative scrub for at least 2–5 minutes up to the elbows.

3. After performing the surgical scrub, keep the hands up and away from the body (elbows flexed) so that the water runs from the tips of fingers toward the elbows. Dry hands with a sterile towel and don a sterile gown and gloves.

4. Clean underneath each fingernail.

5. Do not wear hand or arm jewelry.

Management of infected or colonized surgical personnel:

1. Educate and encourage surgical personnel who have signs and symptoms of a transmissible infectious illness to report promptly to their supervisor and occupational health personnel.
2. Develop well-defined policies concerning patient care responsibilities when personnel have potentially transmissible infectious conditions. these policies should govern: (1) responsibility of personnel in using health services and reporting illness, (2) work restrictions, and (3) clearance to resume work after an illness that required work restriction. the policies should also identify staff members that have the authority to remove personnel from duty.

3. Obtain appropriate cultures and exclude from duty surgical personnel who have draining skin lesions until infection has been ruled out, or until these personnel have received adequate therapy and infection has been resolved.
4. Do not routinely exclude surgical personnel who are colonized with organisms such as Staphylococcus aureus or group A streptococci, unless they have been linked epidemiologically to dissemination of the organism.

Antibiotic prophylaxis:

1. Administer a prophylactic antimicrobial agent only when indicated, and select it based on its efficacy against the most common pathogens causing SSIs for a specific operation, and in accordance with published recommendations.
2. Administer by the IV route the initial dose of prophylactic antimicrobial agent, timed such that bactericidal concentration of the drug is established in serum and tissue when the incision is made. Maintain therapeutic levels of the agent in serum and tissues throughout the operation, and for a few hours after the incision has been closed.
3. Before elective colorectal operations, in addition to the above measures, mechanically prepare the bowel by using enemas and

cathartic agents. Give nonabsorbable oral antimicrobial agents in divided doses on the day before the operation.

4. For high-risk cesarean sections, administer the prophylactic antimicrobial agent immediately after the umbilical cord is clamped.
5. Do not routinely use vancomycin for prophylaxis.

Intraoperative

Ventilation:

1. Maintain positive pressure ventilation in the operating room with respect to the corridors and adjacent area.
2. Maintain a minimum of 15 air changes per hour, of which at least 3 should be fresh air.
3. Filter all air, recirculated and fresh, through the appropriate filters. per the American Institute of Architects' recommendations.
4. Introduce all air at the ceiling, and exhaust air near the door.
5. Do not use ultraviolet radiation in the operating room.
6. Keep operating suite doors closed except as need for passage of equipment, personnel, or patients.
7. Consider performing orthopedic implant operations in an operating suite supplied with ultraclean air.
8. Limit the number of personnel entering the operating room. Cleaning and disinfection of environmental surfaces:

1. When visible soiling or contamination of surfaces or equipment with blood or other body fluids occurs during an operation, use an Environmental Protection Agency (EPA)-approved hospital disinfectant to clean the a_ ected areas before the next operation.
2. Do not perform special cleaning (in addition to cleaning with routine EPA-approved hospital disinfectant) or closing of operating rooms after contaminated or dirty operations.
3. Do not use tacky mats at the entrance to the operating room suite or individual operating rooms for infection control.
4. Wet vacuum the operating floor with an EPA-approved disinfectant after the last operation of the day or night.

Microbiological sampling:

1. Do not perform routine environmental sampling of the operating room.

Sterilization of surgical instruments:

1. Sterilize all surgical instruments according to published guidelines.
2. Perform flash sterilization only for patient care items that will be used immediately. Do not flash sterilize for reasons of convenience or to save time.

Surgical attire and drapes:

1. Wear a surgical mask that fully covers the mouth and nose when entering the operating room if an operation is about to begin or is underway, or if sterilized instruments are exposed. Wear the mask throughout the operation.
2. Wear a cap or hood to fully cover hair on the head and face.
3. Do not wear shoe covers for prevention of SSIs.
4. Wear sterile gloves if scrubbed as a surgical team member. Put on gloves after donning the sterile gown.
5. Use surgical gowns and drapes that are effective barriers when wet.
6. Change scrub suits that are visibly soiled, contaminated, and/or penetrated by blood or other potentially infectious material.

Asepsis and surgical technique:

1. Adhere to principles of asepsis when placing intravascular devices, spinal or epidural anesthesia catheters, or when dispensing or administering IV drugs.
2. Assemble sterile equipment and solutions immediately prior to use.
3. Handle tissue gently, maintain effective hemostasis, minimize devitalized tissue and foreign bodies, and eradicate dead space at the surgical site.
4. Use delayed primary skin closure or leave an incision open if the surgeon considers the surgical site to be heavily contaminated.

5. If drain is necessary, use closed suction drain, and place it through a separate incision distant from the operating incision. Remove the drain as soon as possible.

Postoperative Incision Care

1. Protect an incision that has been closed primarily with a sterile dressing for 24–48 hours postoperatively.
2. Wash hands before and after dressing changes and before and after any contact with surgical site.
3. When an incision dressing must be changed, use a sterile technique.
4. Educate the patient and family regarding proper incision care, symptoms of SSI, and the need to report such symptoms.

Surveillance

1. Use CDC definitions of SSI without modification for identifying SSIs among surgical inpatients and outpatients.
2. For inpatient cases, use direct prospective observation, indirect prospective detection, or a combination of both for the duration of the patient's hospitalization.
3. When postdischarge surveillance is performed for detecting SSIs following certain operations, use a method that accommodates available resources and data needs.

4. For outpatient cases, use a method that accommodates available resources and data needs.
5. Assign a surgical wound classiffication upon completion of an operation. A surgical team member should make the assignment.
6. For a patient undergoing an operation chosen for surveillance, record those variables shown to be associated with increased risk of SSI.
7. Periodically calculate operation-speci_ c SSI rates strati_ ed by variables shown to be associated with increased risk of SSI.
8. Report appropriately stratified operation-specific SSI rates to surgical team members. the optimum frequency and format of such rate computations will be determined by stratified case-load sizes and the objectives of local, continuous quality improvement.

NECROTIZING WOUND INFECTIONS

Necrotizing soft tissue infections are a heterogeneous group of clinical entities ; however, several fundamental concepts govern the treatment of all. Paramount is early identification followed by operative debridement and initiation of antibiotic therapy. Patients often present early in the postoperative period (ie, within 48 hours) with incisional pain followed by the rapid onset of signs and symptoms of sepsis. While the incision may initially appear benign, more often serous drainage is noted.

Patients may also present with bulla or blebs, crepitus, cutaneous anesthesia, and cellulitis that are refractory to antibiotic therapy. Tenderness that extends beyond the borders of the apparent cellulitis suggests progression ofthe infection to the deeper cutaneous layers and should raise suspicion for an early necrotizing process. Importantly, fewer than 40% of patients exhibit the classic symptoms and signs described and a high degree of suspicion should be maintained in the postoperative patient with early signs of sepsis. In the absence of characteristic clinical features, diagnosis can be challenging. An elevated white blood cell (WBC) count (>15,400/mm 3) and hyponatremia (serum sodium level lower than 135 mmol/L) are sensitive markers for the presence of a necrotizing soft tissue infection; however, they are fairly nonspecific Imaging studies, including plain x-ray and CT, may reveal the presence of soft tissue gas, though this is present in a minority of

cases. The reported sensitivity of MRI for diagnosis of necrotizing soft tissue infection ranges from 89% to 100%, and its specificity ranges from 46% to 86%. However, the frequent presence of subcutaneous air in an early postoperative wound precludes reliable imaging in most cases and, more importantly, imaging may delay appropriate treatment. In suspected cases, immediate surgical exploration and debridement is recommended and constitutes the most important single therapy. *Clostridium perfringens* or group A beta-hemolytic streptococci are the most frequently implicated organisms, but necrotizing infections are often polymicrobial. A sample of debrided tissue should be sent for gram stain and culture, and initial therapy should have a broad spectrum of coverage (eg, penicillin, clindamycin, and an aminoglycoside). Following initial debridement, the wound should be reexamined frequently. Any evidence of extension of the necrotizing process should prompt further debridement. Although the initial management of all necrotizing infections is essentially the same, there are several specific clinical entities that deserve special mention, as they may require unique therapies.

MATERIALS AND METHODS

METHOD OF COLLECTION OF DATA

A total of 100 patients undergoing midline laparotomy after taking written and informed consent and were divided equally in to 50 cases each in the study group(interrupted X)and control group (continous suture) and were followed up in the post operative period.

SOURCE OF DATA:

All patients satisfying inclusion criteria admitted in General surgery Department,GRH for a period of 6 months

MATERIALS AND METHODS:

All patients undergoing emergency and elective laparatomies at GRH, attached to Madurai medical college. This is the prospective study. A written an informed consent to be obtained from the patients to be included in the study and data collected on printed proforma included. Eg-Age, History of related complaints, General examinations, Abdominal examination, Biochemical evaluation of blood sugar, blood urea, electrolytes and other specific investigations. post op course carefully observed and criteria managed to analyse morbidity, hospital stay.

Continous closure were performed using No.1 prolene,care being taken place each bite 1.5 to 2 cm from the linea alba edge with successive bites being placed 1 cm from each other. The edges of linea alba was gently approximated without strangulation with an attempt to keep a suture to wound length ratio 4 Interrupted closure was performed using No.1 prolene suture. A large bite was taken outside in 2cm from the cut edge of the linea alba. The needle emerged on the other side from inside out diagonally 2 cm from the edge and 4cm above and below the first bite. The strand was subsequently crossed or looped around the free end of sutureand continued outside-in ,diagonally at 90 ‘ to the first diagonal. The two end tied just tight enough to approximate the edges of linea alba taking care not to include bowel or omentum between the edges. This created X like crosses one on the surface and another deep to linea alba. The next X suture was placed 1 cm away from the previous one. Henceforth in a 14 cm long ,3 X sutures were applied .

ELIGIBILITY CRITERIA:

A.INCLUSION CRITERIA:

All patient scheduled to undergo midline laparatomy for emergency and elective reasons were included in the study

B.EXCLUSION CRITERIA:

1 .Patients younger than 16 years

2.Patients who had undergone previous laparatomy for any conditions

3.Patients who required a re exploratiobn in post op course were ex

ANALYSIS

Data analysis was done with the help of computer using SPSS 18 software. Using this software range, frequencies, percentages, means, standard deviations, chi square and 'p' values were calculated by One way ANOVA and Chi-square test was used to test the significance of difference between quantitative variables.

OBSERVATION AND RESULTS

In the prospective study on efficacy of Interrupted X suturing technique, in rectus sheath closure for all midline laparatomy in prevention of burst abdomen, conducted in the Department of General surgery at Govt Rajaji Hospital Madurai, for the period of 6 months a total of 100 patients who underwent midline laparatomy for various indications were included in the prospective study and randomized in to two groups, of 50 patients in group A(interrupted X suture) and 50 patients in Group B (continuous suture) were considered for the study.

PATIENT DEMOGRAPHY

AGE AT PRESENTATION

Age Group In Years	Number Of Patients	Percentage	Group A N=50	Group B N=50
<40	32	32%	16(32%)	16(32%)
41-50	25	25%	12(24%)	13(26%)
51-60	26	26%	12(24%)	14(28%)
>60	17	17%	10(20%)	7(14%)

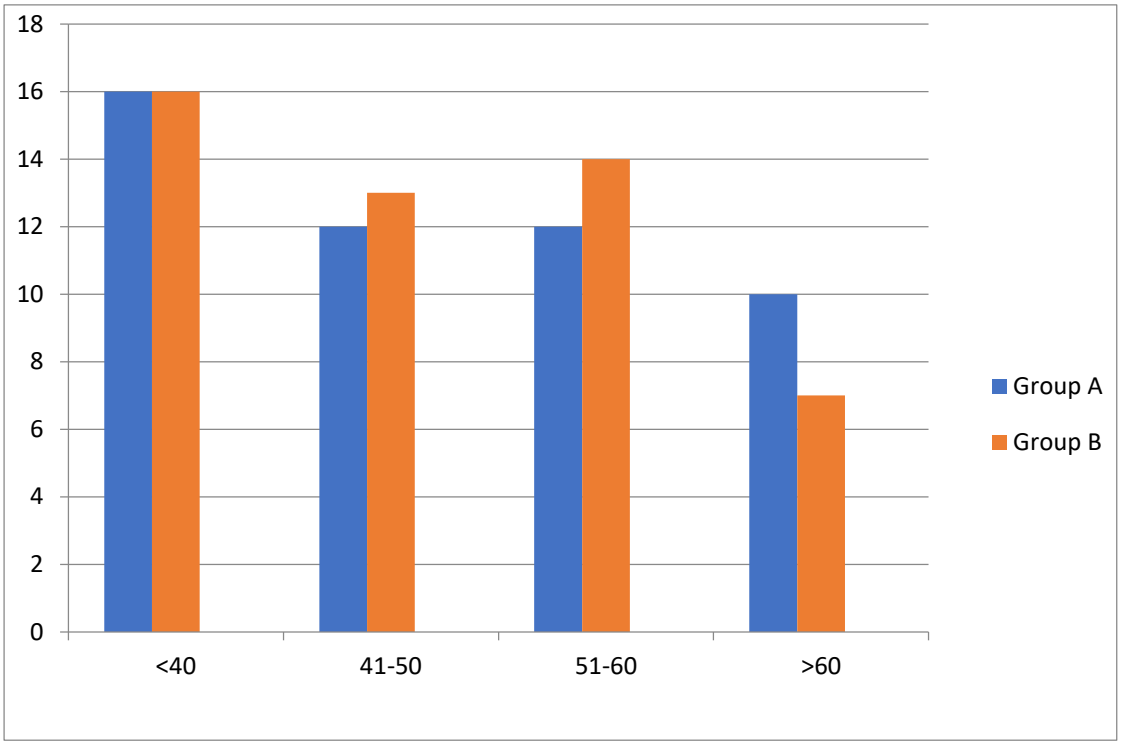

In this study age of the study is more than 26 years,youngest person included in the study series was 26 and eldest was 83 years old.Almost 32 % were in <40 years.This includes 50% in group A and 50 % in group B.Average age ih the study series is 47.

RECTUS SHEATH CLOSURE TECHNIQUE IN EMERGENCY SETTING

TECHNIQUE	A	B	PERCENTAGE
CONTINOUS	25	25	50%
INTERMITTENT	25	25	50%

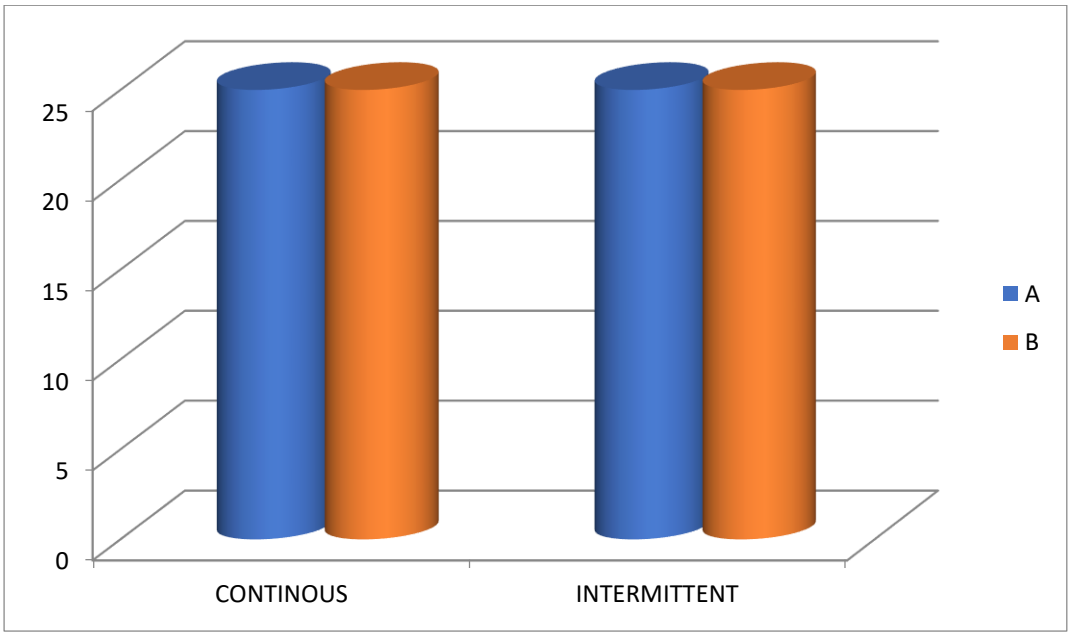

RECTUS SHEATH CLOSURE IN ELECTIVE SETTINGS

TECHNIQUE	A	B	PERCENTAGE
CONTINOUS	25	25	50%
INTERMITTENT	25	25	50%

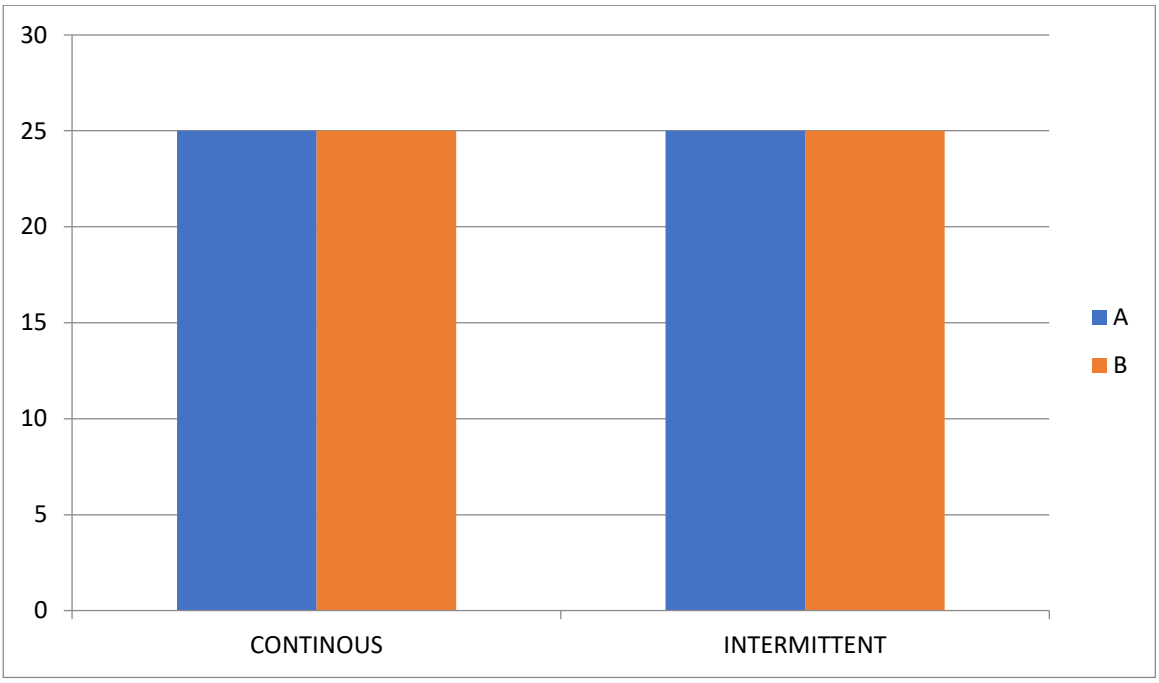

50 % of the population in the study belong to Group A, in which them intermittent X suturing were used, and another 50 % belong to Group B in which them continuous suture were used.

RISK FACTORS

AGE GROUP	A	B	PERCENTAGE IN GROUP A	PERCENTAGE IN GROUP B
<40	3	4	6%	8%
41-50	4	5	8%	10%
51-60	6	8	12%	16%
>60	6	4	12%	8%

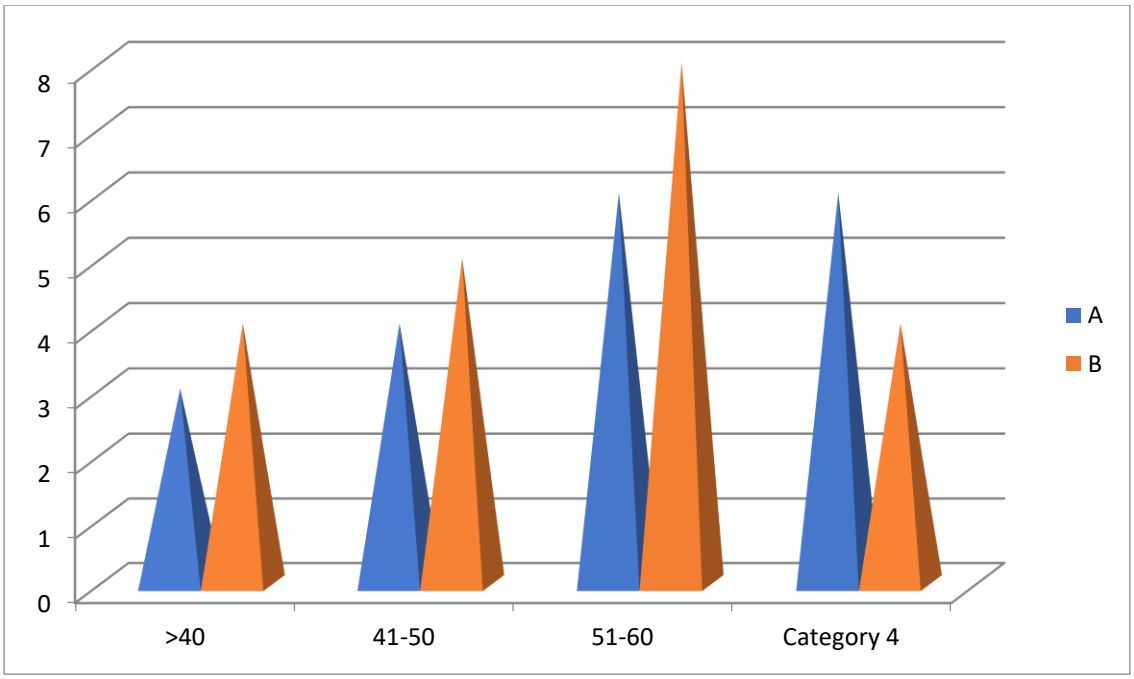

In this study we considered risk factors of the patient like obesity, Diabetes, patient on chronic corticosteroid usage, and on chemotherapy /radiotherapy.

CONSORT DIAGRAM

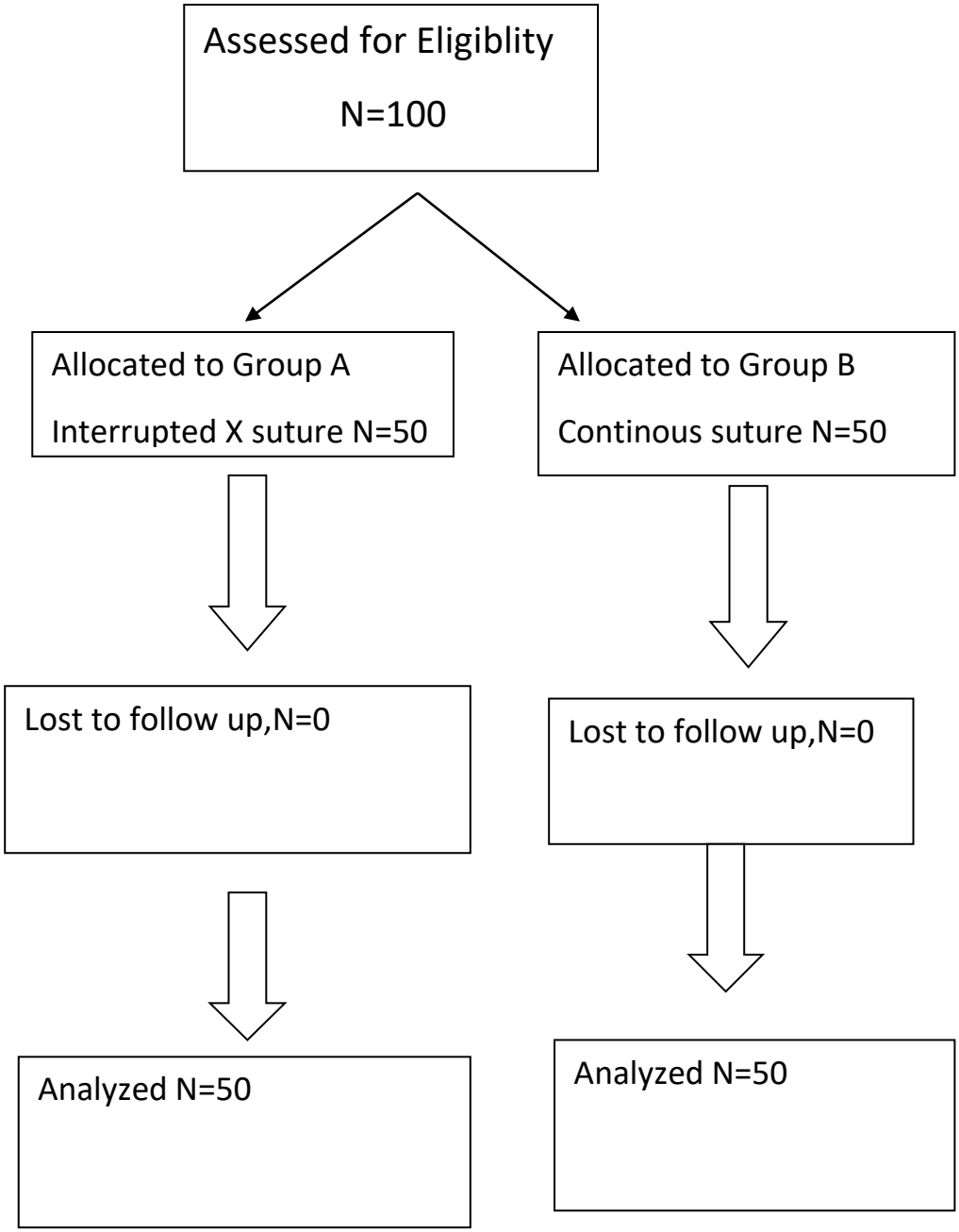

COMPARISON	GROUP A	GROUP B
DEMOGRAPHY		
MEAN AGE	**47.96**	**47.76**
EMERGENCY SETTINGS	**25(50)**	**25(50)**
ELECTIVE SETTINGS	**25(50)**	**25(50)**
RISK FACTORS	**19(38)**	**21(42)**

WOUND DEHISCENCE

EMERGENCY CASES

Interrupted X suture	**4**
Continous	**10**

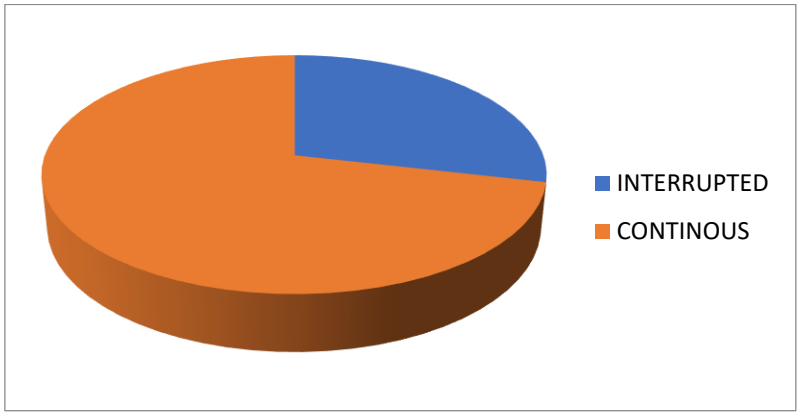

P value=0.0347

ELECTIVE CASES

INTERRUPTED X SUTURE	**2**
CONTINOUS	**8**

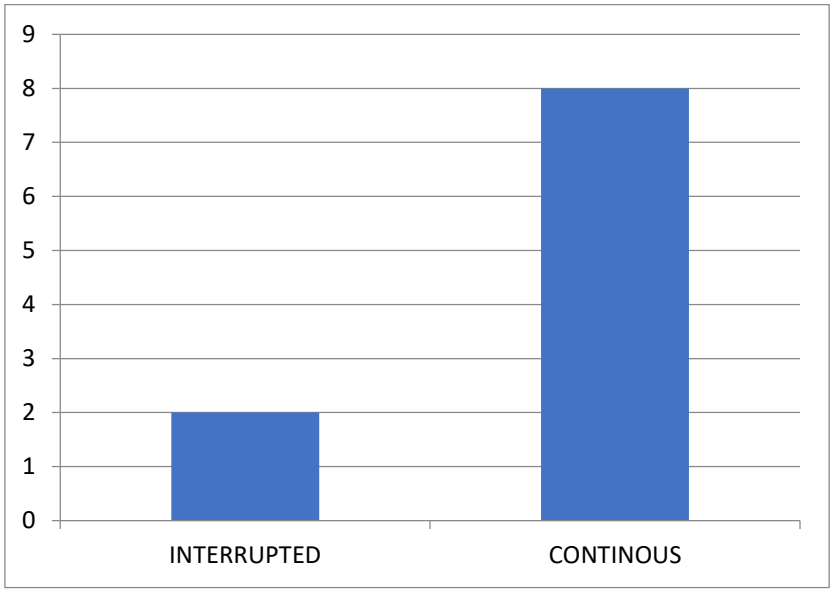

P value=0.021

Out of 100 patients,6 patient in which intermittent X suturing was done developed burst abdomen,18 patients from continuous group developed burst abdomen with significant p value of <0.05

PROLONGED POST OP HOSPITAL STAY

EMERGENCY CASES

Interrupted X suture	**6**
Continous	**12**

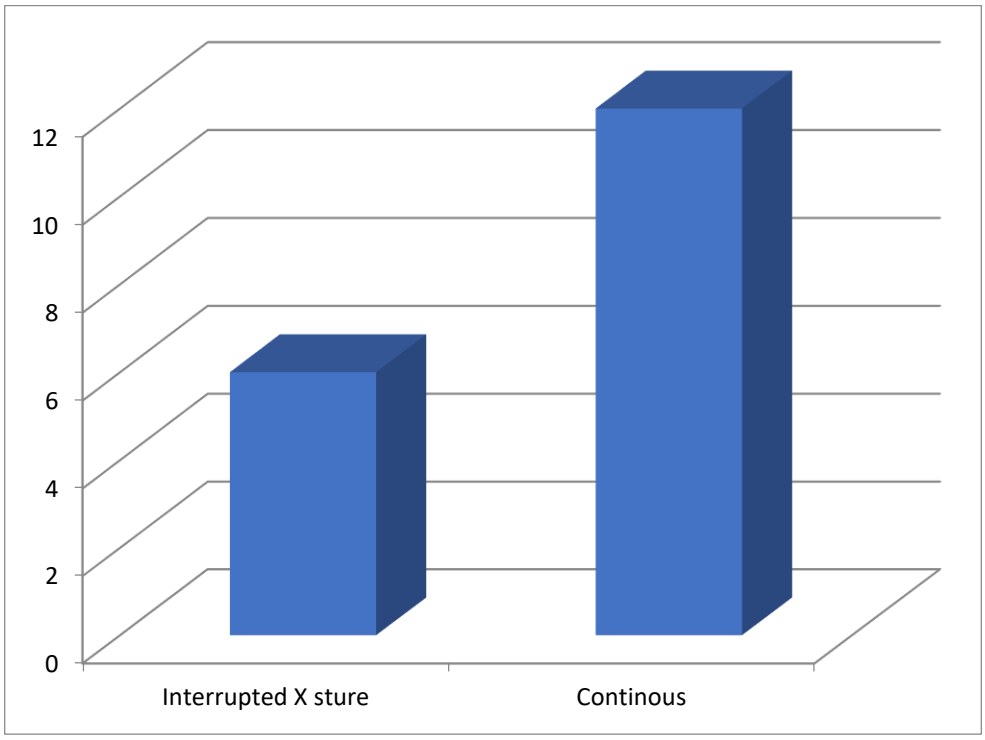

P value=0.044

ELECTIVE CASES

Interrupted X suture	**4**
Continous suture	**10**

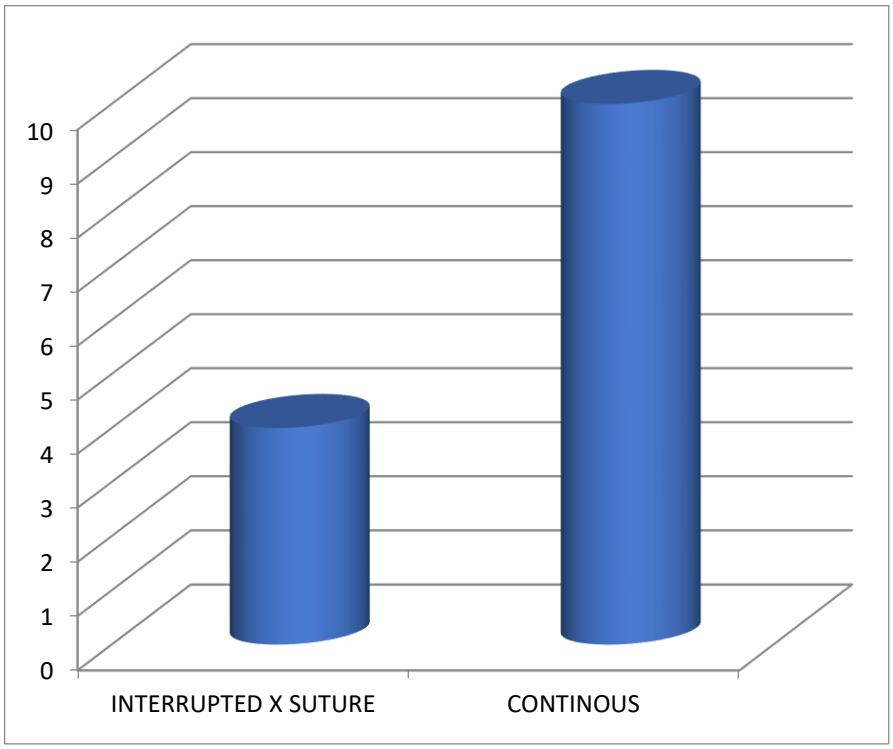

p value=0.0347

NORMAL WOUND HEALING

EMERGENCY CASES

Interrupted X surure	**21**
Continous	**15**

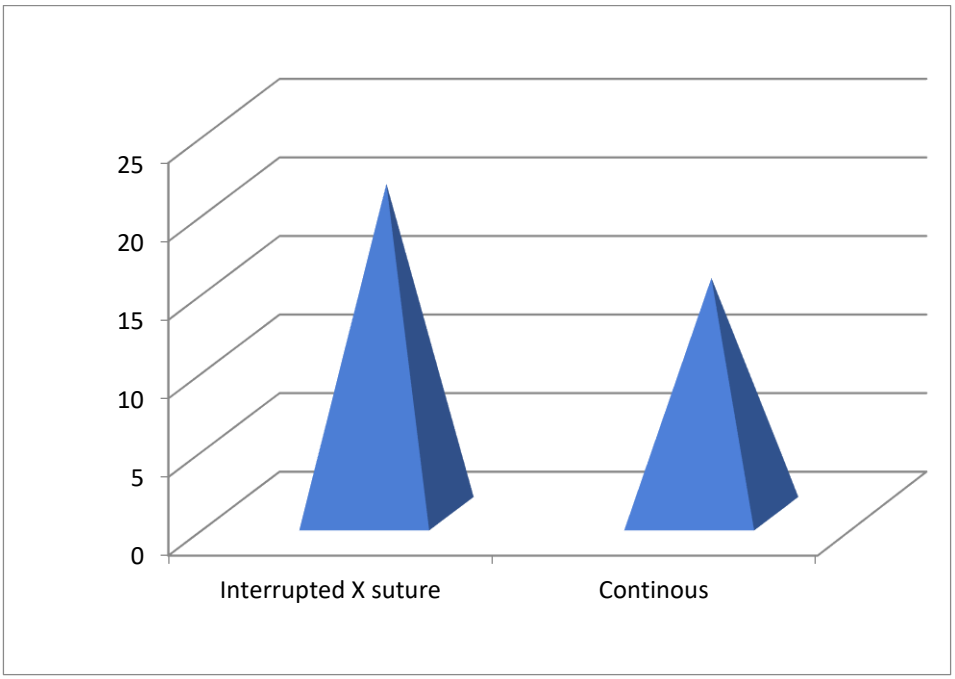

P value=0.03478

ELECTIVE CASES

Interrupted X suture	**23**
Continous	**17**

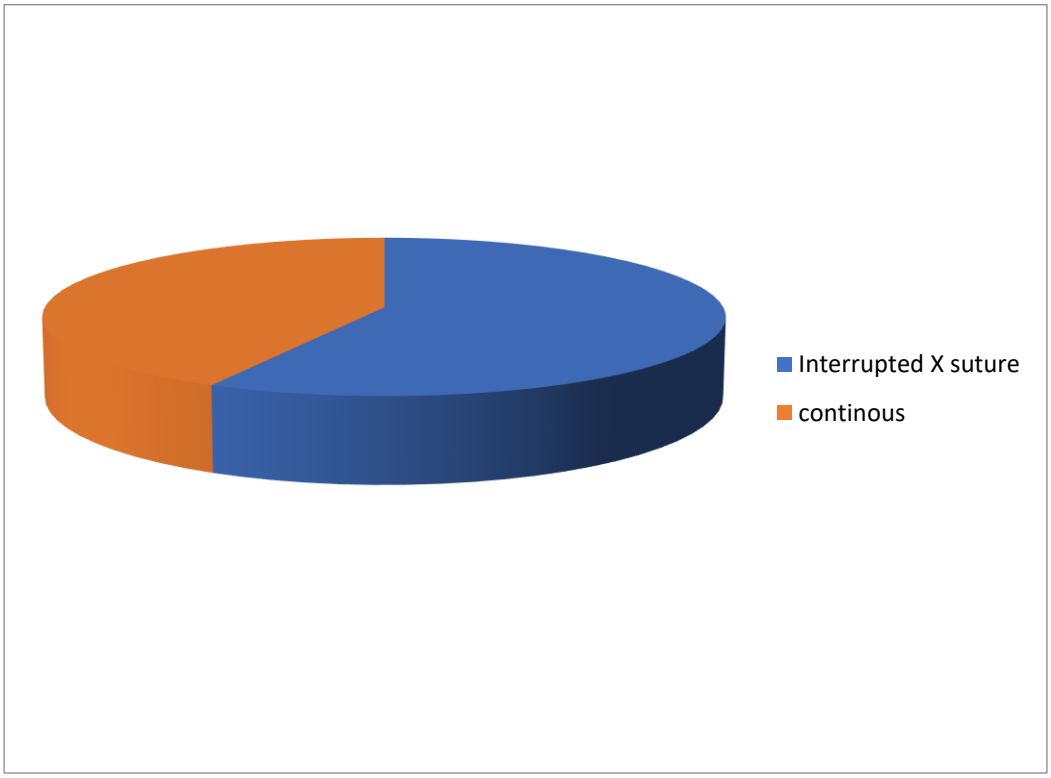

p value=0.02108

INCISIONAL HERNIA

EMERGENCY CASES

Interrupted X suture	**1**
Continous suture	**7**

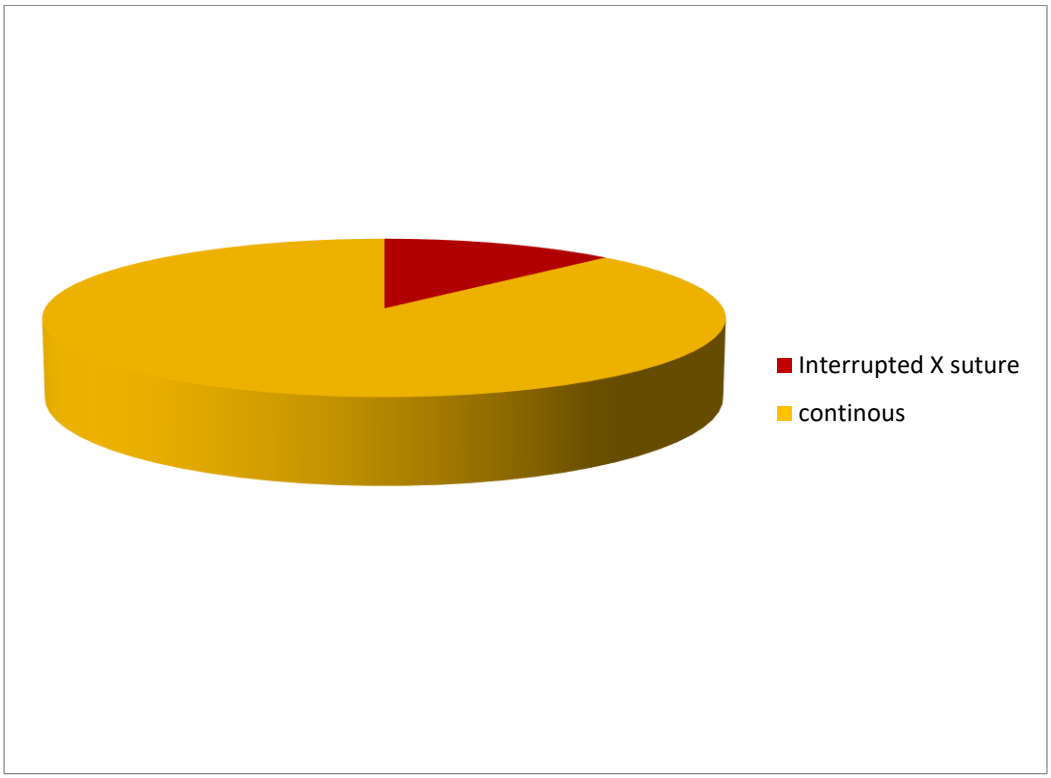

P value=0.013

ELECTIVE CASES

Interrupted X suture	**1**
Continous	**6**

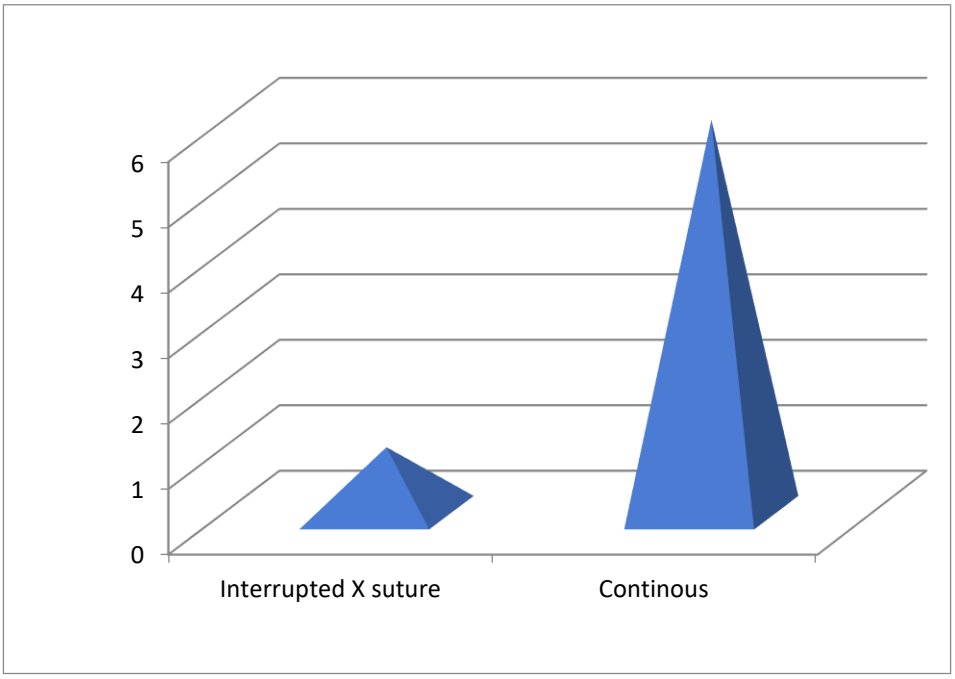

P value=0.026

The following table shows the disease distribution and burst abdomen in those disease

DISEASE	TOTAL CASES	BURST ABDOMEN
Perforation peritonitis	14	4
Hemicolectomy	8	4
Distal gastrectomy	11	2
Intestinal obstruction	12	4
APR	3	1
TVGJ	7	1
CBD exploration	6	2
Sigmoid volvulus	2	1
Mesentric vascular ischemia	2	0
Stab injury abdomen	7	1
Blunt injury abdomen	7	1
Bull gore Injury	6	2

The following table shows the disease distribution and burst abdomen in those disease

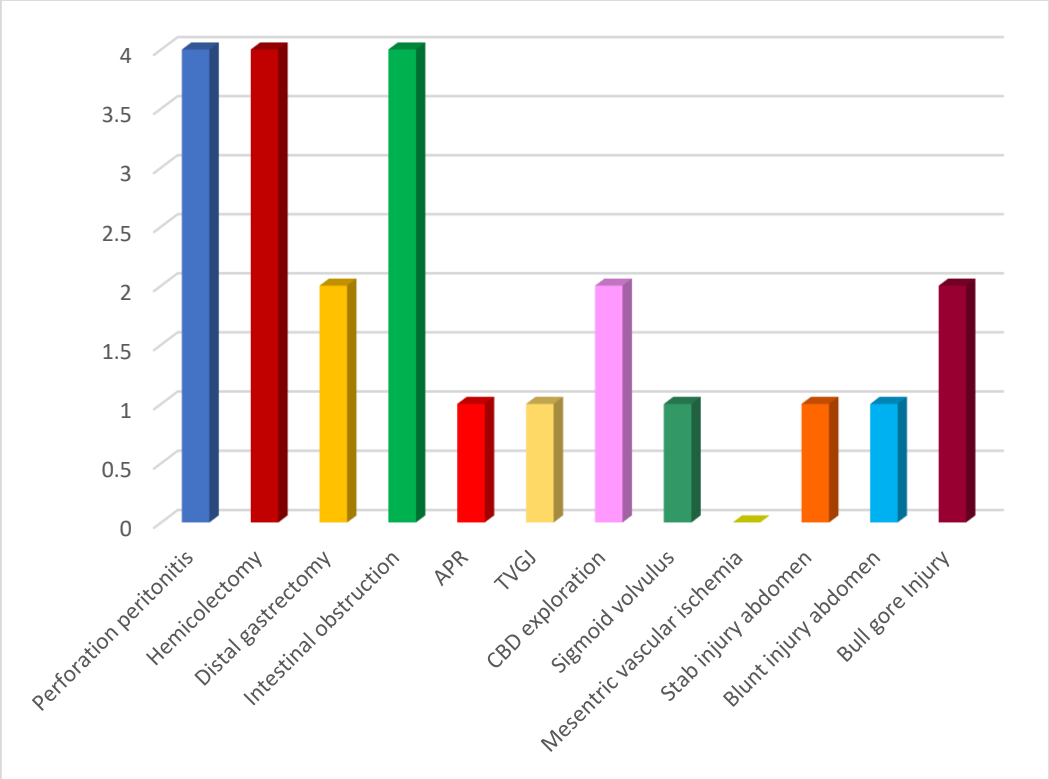

DISCUSSION

In the present study patient operated both in emergency and elective settings, patients in whom rectus sheath closure done using interrupted X suture had a less incidence of wound dehiscence than in whom rectus closure done by continuous method

In this study, patients in whom interrupted X suture was done developed less incidence of incisional hernia than continuous group

In comparing normal wound healing, interrupted X suture group had good healing than continuous group.

In comparing hospital stay, patients in whom interrupted X suturing was done was followed up in the post operative period, had a less incidence of burst abdomen, normal wound healing, hence they had a early recover and short hospital stay.

CONCLUSION

Hence study conducted in 100 patients who underwent laparatomy 50 patients in which them Interrupted X suture was applied, they were followed up in the early post operative period and regular follow up.6 of the patients developed wound dehiscence, in contrast with control group in which 18 patients developed burst abdomen.2 of our patients from the study group developed incisional hernia,13 from control group developed incisional hernia. Therefore, Interrupted X suturing technique overweighs the disadvantages of the continuous suturing technique. Hence the technique should be considered.

BIBILOGRAPHY

1. Tariq M, Jamal A, Khan MA, et al. Comparison of two suturing techniques: Interrupted mass closure and continuous mass closure with polypropelene in laparotomy wound. Pakistan Journal of Medical and Health Sciences 2008;2:174-6.
2. Lofty W. Burst abdomen: Is it a preventable condition? Egyptian Journal of Surgery 2009;28:128-32.
3. Srivastava A, Roy S, Sahay KB, et al. Prevention of burst abdomen wound by a new technique: A randomized trial comparing continuous versus interrupted X–suture. Indian Journal of Surgery 2004; 66:19-27.
4. Blanco E, Aller MA, Ortega L, et al. Vertical figure-of-eight stitches for surgical closure of laparotomies in the rat. Spanish Journal of Surgical Research 2005;8:186-92.
5. Ceydeli A, Rucinski J, Leslie W. Finding the best abdominal closure: An evidence–based review of the literature. Current Surgery 2005;62:220-5.
6. Waqar SH, Malk ZI, Razzaq A, et al. Frequency and risk factors for wound dehiscence/burst abdomen in the midline laparotomies. J Ayub Med Coll Abbohabad 2005;17:70-3.
7. Begum B, Zaman R, Ahmed M, et al. Burst abdomen – A preventable morbidity. Mymensingh Med J 2008;17:63-6.

8. Emad Esmat M. A new technique in closure of burst abdomen TI, TIE and TIES incisions. World J Surg 2006;30:1063-73.
9. Fleischer GM, Rennert A, Ruhmrt M. Infected abdominal wall and burst abdomen. Chirurg 2000;71:754-62.
10. Shukla HS, Kumar S, Misra MC, et al. Burst abdomen and suture material: a comparison of abdominal wound closure with monofilament nylon and chromic catgut. Indian J Surg1981;43:487-91.
11. Singh A, Singh S, Dhaliwal US, et al. Technique of abdominal wall closure: a comparative study. Ind J Surg 1981;43:785-90.
12. Choudhary SK, Choudhary SD. Mass closure versus layer closure of abdominal wound: a prospective clinical study. J Indian Med Assoc 1994;92:229-32.
13. Cleveland RD, Zitsch RP, Laws HL. Incisional closure in morbidly obese patients. Am Surg 1989;55:61-63.
14. Fagniez P, Hay JM, Lacaine F, et al. Abdominal midline incision closure. Arch Surg 1985;120:1351-3.
15. McNeill PM, Sugerman HJ. Continuous absorbable versus interrupted nonabsorbable fascial closure. Arch Surg 1986;121:821-3.
16. Richards PC, Balch CM, Aldrete JS. Abdominal wound closure. A randomized prospective study of 571 patients comparing continuous vs. interrupted suture techniques. Ann Surg 1983;197:238-43.

17. Mayo, Ch. W. and Lee, M. J.: Separations of Abdominal Wounds. A. M. A. Arch. Surg., 62:883, 1951.
18. Madden, J. L.: Atlas of Technics in Surgery. Volume 1. Second edition. New York, Appleton-Century-Croft, 1964.
19. Efron, G.: Abdominal Wound Distruption. Lancet, 19:1287, 1965.
20. Altemeier, W. A. and Berkich, E.: Wound sepsis and Dehiscence. In Hardy, J. D. (ed.) Critical Surgical Illness, Philadelphia, W. B. Saunders Company, 1971.
21. Hunt, T. K.: Wound Complications. In Hardy, J. D. (ed.) Management of Surgical Complications, Philadelphia, W. B. Saunders Company, 1975.
22. Singh A, Singh S, Dhaliwal US, Singh S. Technique of abdominal wall closure: a comparative study. Ind J Surg 1981;43:785 – 90.
23. Shukla HS, Kumar S, Misra MC, Naithani YP. Burst abdomen and suture material: a comparison of abdominal wound closure with monofilament nylon and chromic catgut. Indian J surg. 1981;43:487 – 91.
24. Shukla HS, Kumar S, Misra MC, Naithani YP. Burst abdomen and suture material: a comparison of abdominal wound closure with monofilament nylon and chromic catgut. Indian J surg. 1981;43:487 – 91.
25. Choudhary SK, Choudhary SD, Mass closure versus layer closure of abdominal wound: a prospective clinical study. J Indian Med Assoc. 1994;92:229 – 32.

26. Niggebrugge AH, HansenBE, Trimbos JB, Van de Velde CJ, Zwaveling A, Mechnical Factors influencing the incidence of burst abdomen. Eur J Surg 1995;161:655 – 61.]. Fleischer GM, Rennert A, RĂ 1/4 hmer M. Infected abdominal wall and burst abdomen Chirurg. 2000;71:754 – 62.
27. Anurag Sirvastava, Sapandeep Roy; K.B. Sahay, Vathaluruseenu, Arvind Kumar, Sunil Chumber, et.al Prevention of burst abdominal wound by a new technique: A randomized trial comparing continuous versus interrupted X- suture Indian J Surg. 2004;66:19 – 27.
28. Waqar Sh, Malk ZI, Razzaq A, Abdullah Mt. Shaima A.Zahid Ma. frequency and risk factors for wound dehiscence / burst abdomen in the midline laparotomies. J. Ayub Med Coll. Abbohabad. 2005;17:70 – 3.
29. M. Emadesmat. A new technique in closure of burst abdomen TI, TIE and TIES incisions World J. of surg. 2006;30:1063

PROFORMA

Name: IP no:

Age: Unit:

Sex: D.O.A :

Address: D.O.S

Phone No: D.O.D

CHIEF COMPLAINTS:

PAST HISTORY:

1.History of previous abdominal surgery

2.History suggestive of DM,COPD,TB

- PERSONAL HISTORY:Smoking/alcohol

GENERAL EXAMINATION

1.General survey

2.Body built and nourishment

3.Appearance

4.Anemia

5.pulse/Temp/RR/BP

SYSTEMIC EXAMINATION

Cardiovascular system

Respiratory system

Abdomen

- **INVESTIGATIONS**
- HB
- TLC
- DC
- BT,CT
- ESR
- BLOOD GROUPING/TYPING
- URINE ALBUMIN/SUGAR/DEPOSITS
- RFT
- ECG
- VIRAL MARKERS
- SPECIFIC INVESTIGATIONS TO THE DIAGNOSIS

DIAGNOSIS

MANAGEMENT

SURGICAL

Pre op instructions

Type of anaesthesia

Post op instruction

Post op complication management

Name	age	sex	Emergency/Elective	Nature of surgery	Rectus sheath closure	Normal wound healing	prolonged post op days	Wound dehiscence	Incisional hernia
sajahan	28	M	emergency	perforative peritoniotis	continous	no	yes	yes	yes
Mani	54	M	elective	Hemicolectomy	continous	no	yes	yes	yes
saravanakumar	30	M	emergency	Perforation peritonitis	interrupted	yes	no	no	no
Dhanalakshmi	60	F	elective	Distal gastrectomy	interrupted	no	yes	yes	yes
Ramamoorthy	47	M	emergency	Intestinal obstruction	continous	no	yes	yes	yes
Muniyandi	60	M	elective	Abdominoperineal resection	continous	no	no	yes	no
Vaiyapuri	83	M	emergency	Intestinal obstruction	interrupted	yes	no	no	no
Rangasamy	65	M	elective	TVGJ	interrupted	yes	no	no	no
Sathiyamoorthy	54	M	emergency	Perforation peritonitis	continous	no	yes	yes	yes
Ganesan	45	M	elective	ileal sticture	continous	yes	no	no	no
Fathima	59	F	emergency	Intestinal obstruction	interrupted	yes	no	no	no
santhanalakshmi	55	F	elective	distal gastrectomy	interrupted	yes	no	no	no
Balasubramanian	65	M	emergency	sigmoid volvulus	continous	no	yes	yes	yes
Kumar	52	M	elective	TVGJ	continous	yes	no	no	no
Backiyaseelan	36	M	emergency	Perforation peritonitis	interrupted	yes	no	no	no
selvi	45	F	elective	mesentric cyst excision	interrupted	yes	no	no	no
Mukesh	32	M	emergency	stab injury	continous	yes	no	no	no
Alaguvanthi	60	F	elective	splenectomy	continous	yes	no	no	no
Murugan	42	M	emergency	blunt injury abdomen	interrupted	yes	no	no	no
Vijayapadmanabhan	47	M	elective	right hemicolectomy	interrupted	no	yes	yes	no
Jothilakshmi	49	F	emergency	mesentric vascular ischemia	continous	yes	no	no	no
Anbalagan	63	M	elective	GIST intestine	continous	yes	no	no	no
sevugan	57	M	emergency	stab injury	interrupted	yes	no	no	no
Venkatesh prabu	27	M	elective	chylolymphatic cyst	interrupted	yes	no	no	no
Vellaisamy	55	M	emergency	blunt injury abdomen	continous	yes	no	no	no
Vimala	40	F	elective	Distal gastrectomy	continous	yes	no	no	no
Thavamani	46	F	emergency	Intestinal obstruction	interrupted	yes	no	no	no
Moihideen	40	M	elective	TVGJ	interrupted	yes	no	no	no
Neela	36	F	emergency	blunt injury abdomen	continous	yes	no	no	no
Jamaludeen	40	M	elective	Abdominoperineal resection	continous	yes	no	no	no
Arumugam	63	M	emergency	bull gore injury abdomen	interrupted	yes	no	no	no
Karthiga	30	F	elective	mesentric desmoid tumor	interrupted	yes	no	no	no
Nagaraj	36	M	emergency	Perforation peritonitis	continous	yes	no	no	no
Vellaiyammal	31	F	elective	splenectomy	continous	yes	no	no	no
Jaysundar	36	M	emergency	bull gore injury abdomen	interrupted	no	yes	yes	yes
Ravichandran	48	M	elective	Distal gastrectomy	interrupted	yes	no	no	no
Subbulakshmi	48	F	emergency	Intestinal obstruction	continous	yes	no	no	no
Backiyam	65	F	elective	Hemicolectomy	continous	no	yes	yes	no
Ajith	40	M	emergency	blunt injury abdomen	interrupted	yes	no	no	no
Uma devi	30	F	elective	GIST intestine	interrupted	yes	no	no	no
Chellaiah	65	M	emergency	Perforation peritonitis	continous	yes	no	no	no
Usha	34	F	elective	splenectomy	continous	yes	no	no	no
Ponram	70	M	emergency	mesentric vascular ischemia	interrupted	yes	no	no	no

Lakshmanan	52	M	elective	TVGJ	interrupted	yes	no	no	no
Nagaraj	48	M	emergency	bull gore injury abdomen	continous	yes	no	no	no
Subramani	72	M	elective	Hemicolectomy	continous	yes	no	no	no
Muthupillai	57	F	emergency	Intestinal obstruction	interrupted	no	yes	yes	no
Bhuvaneshwari	33	F	elective	ileal sticture	interrupted	yes	no	no	no
Selvi	42	F	emergency	blunt injury abdomen	continous	yes	no	no	no
Balaji	27	M	elective	mesentric cyst excision	continous	yes	no	no	no
Dhanam	62	F	emergency	stab injury	interrupted	yes	no	no	no
Senthilvel	42	M	elective	TVGJ	interrupted	yes	no	no	no
Palanisamy	70	M	emergency	Intestinal obstruction	continous	yes	no	no	no
Sahayaraj	39	M	elective	splenectomy	continous	yes	no	no	no
Muneeshwari	37	F	emergency	stab injury	interrupted	yes	no	no	no
Menaka	46	F	elective	Distal gastrectomy	interrupted	yes	no	no	no
Meena	60	F	emergency	bull gore injury abdomen	continous	no	yes	yes	yes
Sasikala	49	F	elective	CBD exploration	continous	no	yes	yes	yes
Muniyandi	28	M	emergency	Perforation peritonitis	interrupted	yes	no	no	no
Kannan	39	M	elective	TVGJ	interrupted	yes	no	no	no
Jayalakshmi	43	F	emergency	bull gore injury abdomen	continous	yes	no	no	no
Aandi	60	M	elective	Distal gastrectomy	continous	no	yes	yes	yes
Meenarani	33	F	emergency	stab injury	interrupted	yes	yes	no	no
Raman	55	M	elective	Hemicolectomy	interrupted	yes	no	no	no
Easwari	36	F	emergency	Intestinal obstruction	continous	yes	no	no	no
Velliyan	70	M	elective	Abdominoperineal resection	continous	yes	no	no	no
Pooman	57	M	emergency	Perforation peritonitis	interrupted	yes	yes	no	no
Nagalakshmi	54	F	elective	CBD exploration	interrupted	yes	no	no	no
Sathya	45	F	emergency	blunt injury abdomen	continous	yes	no	no	no
Sundharam	55	F	elective	open cholecystectomy	continous	yes	no	no	no
Gnanadeepa	70	F	emergency	Intestinal obstruction	interrupted	yes	yes	no	no
Karuthapandi	41	M	elective	CBD exploration	interrupted	yes	no	no	no
Thhangavel	32	M	emergency	stab injury	continous	no	yes	yes	yes
Nagakani	29	F	elective	GIST intestine	continous	yes	yes	no	no
Mayakannan	50	M	emergency	sigmoid volvulus	interrupted	yes	no	no	no
Fathima begum	60	F	elective	Distal gastrectomy	interrupted	no	yes	yes	no
Kulanthai	54	M	emergency	Perforation peritonitis	continous	no	yes	yes	yes
Thiyagarajan	53	M	elective	Hemicolectomy	continous	no	yes	yes	yes
Muthaiya	27	M	emergency	Perforation peritonitis	interrupted	yes	no	no	no
Marry	44	F	elective	Distal gastrectomy	interrupted	yes	no	no	no
Dhanalakshmi	54	F	emergency	Intestinal obstruction	continous	yes	yes	no	no
selvam	53	M	elective	CBD exploration	continous	yes	yes	no	no
Raghulakannan	26	M	emergency	Appendicular perfooration	interrupted	yes	no	no	no
Periyasamy	56	M	elective	Distal gastrectomy	interrupted	yes	no	no	no
Rajkumar	28	M	emergency	Perforation peritonitis	continous	no	yes	yes	yes
Mangalam	45	F	elective	Hemicolectomy	continous	yes	no	no	no
Muthayee	35	F	emergency	stab injury	interrupted	yes	no	no	no
Gopal	65	M	elective	Distal gastrectomy	interrupted	yes	no	no	no
Albert sebastein	28	M	emergency	Perforation peritonitis	continous	yes	yes	no	no

Suresh	45	M	elective	TVGJ	continous	no	yes	yes	yes
Mariayammal	65	F	emergency	blunt injury abdomen	interrupted	no	no	yes	no
Palaniappan	56	M	elective	Hemicolectomy	interrupted	yes	no	no	no
Gurusamy	48	M	emergency	Intestinal obstruction	continous	no	yes	yes	no
Muthumari	40	F	elective	CBD exploration	continous	no	yes	yes	no
Rajalakshmi	49	F	emergency	bull gore injury abdomen	interrupted	yes	no	no	no
Sundhari	45	F	elective	open cholecystectomy	interrupted	yes	no	no	no
Sakunthala	52	F	emergency	Intestinal obstruction	continous	no	yes	yes	no
Muthurakku	60	F	elective	Distal gastrectomy	continous	yes	yes	no	no
Abdul raheem	60	M	emergency	Perforation peritonitis	interrupted	yes	yes	no	no
Rajamanickam	45	M	elective	CBD exploration	interrupted	yes	yes	no	no

MADURAI MEDICAL COLLEGE
MADURAI, TAMILNADU, INDIA -625 020
(Affiliated to The Tamilnadu Dr.MGR Medical University, Chennai, Tamil Nadu)

ETHICS COMMITTEE CERTIFICATE

Name of the Candidate	:	Dr.C.Sathaiah
Course	:	PG in MS., General Surgery
Period of Study + College	:	2016-2019 MADURAI MEDICAL COLLEGE
Research Topic	:	To assess the proportion or burst abdomen in post midline Laparatomy patient using interrupted X suture versus continuous suture technique in sheath closure
Ethical Committee as on	:	10.07.2018

The Ethics Committee, Madurai Medical College has decided to inform that your Research proposal is accepted.

Member Secretary | Chairman | Dean / Convenor

Prof Dr V Nagaraajan
M.D., MNAMS, D.M., Dsc.,(Neuro), Dsc (Hon)
CHAIRMAN
IEC - Madurai Medical College
Madurai

DEAN
Madurai Medical College
Madurai-20

17 JUL 2018
மதுரை - 625020

URKUND

Urkund Analysis Result

Analysed Document:	A PROSPECTIVE STUDY TO COMPARE CONTINOUS VERSUS INTERRUPTED X SUTURE IN PREVENTION OF BURST ABDOMEN.docx (D42403418)
Submitted:	10/11/2018 7:38:00 AM
Submitted By:	drsathaiah@gmail.com
Significance:	14 %

Sources included in the report:

Dr Ketan Thesis.docx (D21805547)
PLAGER.docx (D42257651)
PROSPECTIVE STUDY OF "EFFECT OF PROPHYLACTIC RETENTION SUTURES IN MIDLINE LAPAROTO MY IN HIGH-RISK PATIENTS FOR PREVENTION OF WOUND DEHISCENCE.docx (D42263091)
https://www.glowm.com/section_view/heading/Operations%20on%20the%20Abdominal%20Wall/item/38

Instances where selected sources appear:

31

CERTIFICATE

This is to certify that this dissertation work titled **"A PROSPECTIVE STUDY TO COMPARE CONTINOUS VERSUS INTERRUPTED X SUTURE IN PREVENTION OF BURST ABDOMEN"** of the candidate **Dr. C. SATHAIAH** with **Registration Number 221611123** for the award of **MASTER DEGREE** in the branch of **GENERAL SURGERY** I have personally verified the urkund.com website for the purpose of plagiarism check. I found that the uploaded thesis file contains from introduction to conclusion pages and result shows **14%** of plagiarism in the dissertation.

Guide & Supervisor sign with Seal