“STUDY OF FUNCTIONAL OUTCOME IN PROXIMAL HUMERUS FRACTURE FIXATION USING DELTOID SPLITTING APPROACH”

Dissertation submitted in partial fulfillment of the requirements for the degree of

M.S. DEGREE – BRANCH II
ORTHOPAEDIC SURGERY

GOVT. STANLEY MEDICAL COLLEGE
THE TAMILNADU DR. M. G. R. MEDICAL UNIVERSITY
CHENNAI, TAMILNADU

May 2019

DECLARATION BY THE CANDIDATE

I hereby declare that this dissertation titled "**STUDY OF FUNCTIONAL OUTCOME IN PROXIMAL HUMERUS FRACTURE FIXATION USING DELTOID SPLITTING APPROACH"** is a bonafide and genuine research work carried by me under the guidance of **Dr. K. Mohan Kumar, M.S. (ORTHO).,** Professor, Department of Orthopaedics, Govt Stanley Medical College, Chennai.

Place :

Date : **Dr. Parthasarathy S**

CERTIFICATE BY THE GUIDE

This is to certify that the dissertation titled "**STUDY OF FUNCTIONAL OUTCOME IN PROXIMAL HUMERUS FRACTURE FIXATION USING DELTOID SPLITTING APPROACH"** is a bonafide work done by **Dr. Parthasarathy S** in partial fulfilment of the requirement for the degree of **M. S.(Orthopaedics)**

Place :

Date :

Dr. K. Mohan Kumar

Professor of Orthopaedics,

Govt Stanley Medical College,

Chennai.

ENDORSEMENT BY THE HOD/PRINCIPAL OF THE INSTITUTION

This is to certify that the dissertation titled "**STUDY OF FUNCTIONAL OUTCOME IN PROXIMAL HUMERUS FRACTURE FIXATION USING DELTOID SPLITTING APPROACH"** is a bonafide work done by **Dr. Parthasarathy S** under the guidance of **Dr. K. Mohan Kumar , M.S. (ORTHO).,** Professor, Department of Orthopaedics, Govt Stanley Medical College, Chennai.

Dr. PONNAMBALA NAMASIVAYAM
Dean,
Govt Stanley Medical College,
Chennai-01

Dr. T. THOLGAPIYAN
Professor& HOD,
Department of Orthopaedics,
Govt Stanley Medical college,
Chennai-01

Place:
Date:

Place:
Date:

ACKNOWLEDGEMENT

At the outset, I always thank the god for giving me the strength to perform all my duties.

It indeed gives me immense pleasure to recall the people who have helped me in the completion of dissertation, naming all the people who have helped me in achieving this goal would be impossible, yet I attempt to thank a selected few who have helped me in diverse and important ways.

I acknowledge and express my humble gratitude and sincere thanks to my beloved teacher and guide **Dr. K. Mohan Kumar, M.S. (ORTHO).,** for his valuable suggestion, fatherly guidance, great care and attention to even small details, that he has so willingly shown in the preparation of this dissertation.

I owe a great deal of respect and gratitude to my professor & HOD**, Dr. T. THOLGAPIYAN D.Ch., M.S (Ortho)** for his wholehearted support and guidance for completion of this dissertation.

I also express my sincere thanks to my Professors **Dr. S. S. Sukumaran** D.ortho, M. S.(Ortho), **Dr. C. Ashokan** D.ortho, M. S.(Ortho), Dr **K. THANIGAIMANI** M.S (Ortho) , **Dr. Kosalaraman** M. S.(Ortho),Assistant professors **Dr. Balakrishnan** D.Ortho, **Dr. R. Ramaraj** M.S. **(**Ortho), **Dr. Vinoth Rajkumar** D.ortho, M. S.(Ortho), , **Dr. Guruprasath** D.ortho, M. S.(Ortho), **Dr. V. Prabhu** D.ortho, M. S.(Ortho), **Dr. Varrdhaman Dhariwal** M. S.(Ortho) department of Orthopaedics, Govt Stanley Medical College for their timely suggestions and all round encouragement.

My sincere thanks to the staff especially my post graduate colleagues, Paramedical colleagues and my friends for their wholehearted support.

I am deeply indebted to my parents, brothers, sisters, wife and friends whose constant encouragement and support helped me to complete my dissertation.

Finally, I thank my patients who formed the backbone of this study without whom this study would have not been possible.

ETHICAL COMMITTEE APPROVAL

GOVERNMENT STANLEY MEDICAL COLLEGE & HOSPITAL,CHENNAI_-01

INSTITUTIONAL ETHICS COMMITTEE

TITLE OF THE WORK : STUDY OF FUNCTIONAL OUTCOME IN PROX HUMERUS FRACTURE FIXATION USING DELTOID SPLITTING APPROACH.

PRINCIPAL INVESTIGATOR : DR. (MAJ)PARTHASARATHY S
DESIGNATION : PG IN MS ORTHOPAEDICS,
DEPARTMENT : DEPARTMENT OF ORTHOPAEDICS, GOVT. STANLEY MEDICAL COLLEGE.

The request for an approval from the Institutional Ethical Committee (IEC) was considered on the IEC meeting held on 22.07.2017 at the Council Hall, Stanley Medical College, Chennai-1 at 10am.

The members of the Committee, the secretary and the Chairman are pleased to approve the proposed work mentioned above, submitted by the principal investigator.

The Principal investigator and their team are directed to adhere to the guidelines given below:

1. You should inform the IEC in case of changes in study procedure, site investigator investigation or guide or any other changes.
2. You should not deviate from the area of the work for which you applied for ethical clearance.
3. You should inform the IEC immediately, in case of any adverse events or serious adverse reaction.
4. You should abide to the rules and regulation of the institution(s).
5. You should complete the work within the specified period and if any extension of time is required, you should apply for permission again and do the work.
6. You should submit the summary of the work to the ethical committee on completion of the work.

MEMBER SECRETARY,
IEC, SMC, CHENNAI

PLAGIARISM CERTIFICATE

This is to certify that this dissertation work titled **"STUDY OF FUNCTIONAL OUTCOME IN PROXIMAL HUMERUS FRACTURE FIXATION USING DELTOID SPLITTING APPROACH"** is of the candidate **Dr. Parthasarathy S** with registration Number **221612052** for the award of M.S. **Orthopaedics** in the branch of MS Orthopaedics Branch II. I personally verified the urkund.com website for the purpose of plagiarism Check. I found that the uploaded thesis file contains from introduction to conclusion pages and result shows 12 percentage of plagiarism in the dissertation.

Guide & Supervisor sign with Seal.

https://secure.urkund.com/view/4127

URKUND

Document	STUDY OF FUNCTIONAL OUTCOME IN PROX HUMERUS FRACTURE FIXATION USING DELOID SPLITTING APPROACH-1.pdf (D42226217)
Submitted	2018-10-07 19:32 (+05:0-30)
Submitted by	Parthasarathy Suyambu (parthasarathy_5506@yahoo.com)
Receiver	parthasarathy_5506.mgrmu@analysis.urkund.com
Message	Thesis Show full message

12% of this approx. 19 pages long document consists of text present in 21 sources.

Sources Highlights

Rank	Path/Filename
	thesis plagiarism.docx
	37 Mahaveer Prasad.pdf
	https://www.ncbi.nlm.nih.gov/pmc/articles/PMC3535990/
	http://tampub.uta.fi/handle/10024/98065
	http://www.achot.cz/dwnld/achot_2012_4_307_316.pdf
	https://openarchive.ki.se/xmlui/handle/10616/40605
	https://www.ncbi.nlm.nih.gov/pmc/articles/PMC4443467/
	https://emedicine.medscape.com/article/1261320-treatment
	http://www.webmedcentral.com/wmcpdf/Article_WMC00…
	https://www.hindawi.com/journals/aorth/2018/5904028/
	http://www.actaorthopaedica.be/acta/download/2017-1/0…
	sethu writeup FOR PRINT .docx
	https://www.ncbi.nlm.nih.gov/pmc/articles/PMC3047638/
	biological reconstruction of Acromioclavicular JOINT endo…

0 Warnings Reset Export Share

"STUDY OF FUNCTIONAL OUTCOME IN PROX HUMERUS FRACTURE

62% # 1 Active

Dissertation submitted

in partial fulfillment of the requirements for the degree of

M.S.

DEGREE – BRANCH II

ORTHOPAEDIC

SURGERY GOVT. STANLEY MEDICAL COLLEGE THE TAMILNADU DR. M. G. R. MEDICAL UNIVERSITY CHENNAI,

Urkund's archive: Tamil Nadu Dr. M.G.R. Medical University / bio… 62%

Dissertation submitted

in partial fulfillment of the regulation for the award of

M.S. Degree in

Surgery Branch II

THE TAMILNADU Dr. M. G. R. MEDICAL UNIVERSITY CHENNAI – 600 032.

TAMILNADU May 2019

DECLARATION BY THE CANDIDATE I hereby declare that this dissertation entitled "STUDY OF

FUNCTIONAL OUTCOME IN PROX HUMERUS FRACTURE FIXATION USING DELOID SPLITTING APPROACH"

is a bonafide and genuine research work carried by me under the guidance of Dr. Mohan Kumar K, M.S. (ORTHO)., Professor, Department of Orthopaedics, Govt Stanley Medical College, Chennai. Place : Date : Dr. Parthasarathy S

CERTIFICATE BY THE GUIDE This is to certify that the dissertation entitled "STUDY OF

FUNCTIONAL OUTCOME IN PROX HUMERUS FRACTURE FIXATION USING DELOID SPLITTING APPROACH"

is a bonafide work done by Dr. Parthasarathy S in partial fulfilment of the requirement for the degree of

M. S.(Orthopaedics) Place : Date : Dr. Mohan Kumar K Professor of Orthopaedics, Govt Stanley Medical College, Chennai.

ENDORSEMENT BY THE HOD/PRINCIPAL OF THE INSTITUTION This is to certify that the dissertation entitled "STUDY OF

FUNCTIONAL OUTCOME IN PROX HUMERUS FRACTURE FIXATION USING DELOID SPLITTING APPROACH" is a bonafide work done by Dr. Parthasarathy S under the guidance of Dr. Mohan Kumar K, M.S. (ORTHO)., Professor, Department of Orthopaedics, Govt Stanley Medical College, Chennai. Dr. PONNAMBALA NAMASIVAYAM Dr. T. THOLGAPIYAN Dean, Professor& HOD, Govt Stanley Medical College, Department of Orthopaedics, Chennai-01 Govt Stanley Medical college, Chennai-01 Date: Date: Place: Place:

ACKNOWLEDGEMENT At the outset. I always thank the god for giving me the strength to perform all my duties. It indeed gives me immense

pleasure to recall the people who have helped me in

TABLE OF CONTENTS

INTRODUCTION

Proximal humeral fracture is defined as fractures occurring at or proximal to the surgical neck of the humerus. It affects 2.4% of women over the age of 75 years.[4] It is the commonest fracture affecting the shoulder girdle in adults and its incidence is rising. Studies of approximately 50 years ago showed that proximal humeral fractures comprised 4% of all fractures and approximately one-half of all humerus fractures.[5] The current fracture epidemiology shows that nowadays proximal humeral fractures account for almost 7% of all fractures and make up 80% of all humeral fractures. In patients above the age of 65 years proximal humeral fractures is the second most frequent upper extremity fracture, and the third most common nonvertebral osteoporotic fracture after proximal femur and distal radius fractures, accounting for >10% of fractures in this patient population.[6]

In the adult population, proximal humeral fractures have a unimodal distribution.[7] The incidence of proximal humeral fractures fluctuates with age. Extrapolation of the data shows that the incidence of proximal humeral fractures in males and females aged 20 to 29 years is 7.5 and 9.1/year, respectively and that the incidences in the 80 to 89 years population are 390 and 512/year. 197% increase in the incidence of proximal humeral fractures in 80- to 89-year females. Of interest is the fact that there has been a 358% increase in the incidence of proximal humeral fractures in 80- to 89-year males suggesting that improved male health has resulted in more osteoporotic fractures.[7]

Females are more commonly affected than males and it has been demonstrated that 15% to 30% of fractures occur in males but it seems likely that this proportion will rise.[8] The incidence has been shown to increase exponentially at a rate of over 40% every 5

years at age 40 in females and age 60 in males. The calculated annual incidence has been stated to be 36/year for males and 78/year for females

.

It seems likely that the average age of patients who present with proximal humeral fractures is also rising. In 2002 the average age of patients with proximal humeral fractures was 63 years but the average age to be 66 years in 2010/11. The vast majority of patients are 50 years or older.[9]

The vast majority of proximal humeral fractures are treated nonoperatively. However, surgical treatment is becoming more frequent, with fracture reconstruction increasing at a higher rate than prosthetic replacement. The rate of surgically treated fractures shows variability, ranging from less than 10% to 40% or more. Interestingly, in regions with lower incidence of fractures, surgical treatment is more likely.[10]

As with other osteoporosis-related fractures, additional risk factors for proximal humeral fractures include low bone mass and an increased risk of falls. Furthermore patients with poor vision, use of hearing aid, diabetes mellitus, depression, alcohol consumption, use of anticonvulsive medication, and a maternal history of hip fracture have been identified as being at increased risk of sustaining a proximal humeral fracture. A personal history of spinal or upper or lower extremity fracture has also been found to be more prevalent in patients with proximal humeral fractures than in controls. Hormonal replacement therapy and calcium intake have been found to be protective factors.[11]

Although most studies support good outcomes of nonoperative treatment of nondisplaced fractures, a recent prospective study has shown that marked functional impairment may occur even in nondisplaced proximal humeral fractures with over two-thirds of patients having chronic pain. This is of relevance taking into account that elderly patients with two-part proximal humeral fractures are generally considered healthy, with over 90% living at home and taking care of their own dressing and personal

hygiene. The impact of lost quality of life in this patient population may therefore be considerable.[9]

Overall, patients with proximal humerus are more fit than patients suffering proximal femur fractures, but less than those with distal radius fractures. However, more complex fractures are found in more frail and older patients. As a consequence, up to one-third of patients with proximal humeral fractures may require hospital admission, despite nonoperative treatment.[12]

Proximal humeral fractures pose an increased risk for subsequent distal radius and proximal femur fractures. Patients with proximal humeral fractures have a greater than 5 times risk of suffering a hip fracture within 1 year than matched pairs without proximal humeral fractures.[13] When analyzing individuals 45 years or older, patients with proximal humeral fractures have a higher mortality rate than age-matched controls. This risk has been found to be more marked in subjects at the younger extreme of this group and is likely related to increased comorbidity as a possible underlying cause.

The surgical modalities consist of K- Wire, TBW, Screws, IMIL Nail, Arthroplasty or Plate. Most frequently used is the Plate. The commonly used surgical approaches are Deltopectoral approach and Deltoid splitting approach

HISTORY

The history of proximal humerus fractures starts as early as :-

- In the earliest known surgical text, Edwin Smith Papyrus three cases of humeral fractures are described Reduction by traction followed by bandaging with strips of cloth with alum, oil, and honey is described.[14]

- In the Hippocratic Corpus (circa 440–340 BC) the author of On Fractures distinguishes prognostically between proximal and distal fractures of the humerus. A fracture of the head of the humerus is considered milder than injuries near the elbow joint.[15]
- In The Alexandrian School of Medicine (third century BC) fracture-dislocations of the proximal humerus are mentioned, and it is discussed whether the dislocation should be reduced before or after setting the fracture.[16]
- In Celsus (25 BC to AD 50) humeral shaft fractures are distinguished from proximal and distal humeral fractures. Pathoanatomical patterns including transverse, oblique, and multi-fragmented fractures, their typical patterns of displacement, and the sensation of crepitus are described.[17]
- In Albucasis of Cordoba (936–1013)87 plasters of mill-dust and egg-white are

applied after reduction. Provided no swelling or inflammation is present splints made from pine or palm tree are subsequently applied. Finally, the forearm is bandaged to the humerus, placing the hand open on the uninjured shoulder.[18]

- Albucasis' principle of bandaging can be found in the bandage later ascribed to Velpeau (1795–1867)[18]

- Joseph Duverney (1648–1730)92 distinguishes four different 'species' of fracture of the proximal humerus: transverse fractures, oblique fractures, fractures with splinters, and fractures with bone shivered to pieces.[19]
- Pierre-Joseph Desault (1744–1795)93-95 characterizes fractures of the proximal humerus according to trauma mechanism[20]
- The difficulties of distinguishing displaced or impacted fractures of the proximal humerus from glenohumeral dislocations and fracture-dislocations are discussed by Sir Astley Cooper (1768–1841)[21]
- In 1851, Johann Ludwig Wilhelm Thudichum (1829–1901) publishes a comprehensive classification based on the anatomic level of the fracture lines[22]
- Robert Liston's (1794–1847) bandage allows for a permanent valgus pressure. The

bandage is extended to the forearm and hand to prevent soft tissue swelling. “Middledorpf’s triangle” (1824–1868) fixes the upper arm in abduction. Hamilton’s (1813–1886) adhesive plasterbandage applies a permanent traction and Bardenheuer’s (1839–1913) extension apparatus allows for differentiated traction during the immobilization period. After Antonius Mathijsen (1805–1878) introduced the hard setting plaster of Paris bandage in 1852plaster bandages for fractures of the proximal humerus are developed. Hennequin’s (1836–1910) plaster bandage uses the principle of the later hanging cast.

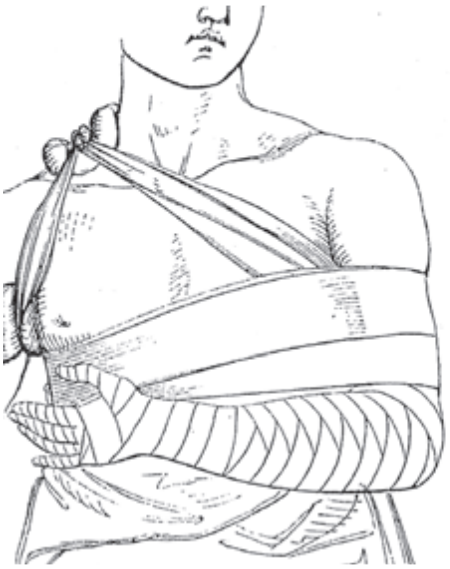

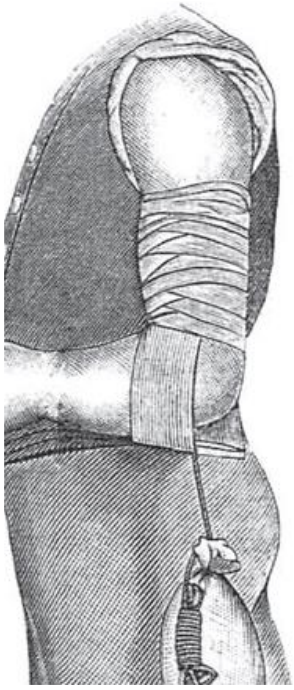

- Emil Theodor Kocher (1841–1917) proposed the last comprehensive pre-radiological classification system[23]
- To capture the patho anatomy and pathophysiology of proximal humeral fractures Ernest Amory Codman (1869–1940)110 suggests studying the involvement of four

distinct anatomical segments along the lines of the epiphyseal union: the greater tuberosity, the lesser tuberosity, the humeral head, and the humeral shaft . The four-segment approach is radiographically defined, but takes into account the muscular forces of the rotator cuff acting on the four segments. Codman's approach profoundly influenced later classifications.[24]

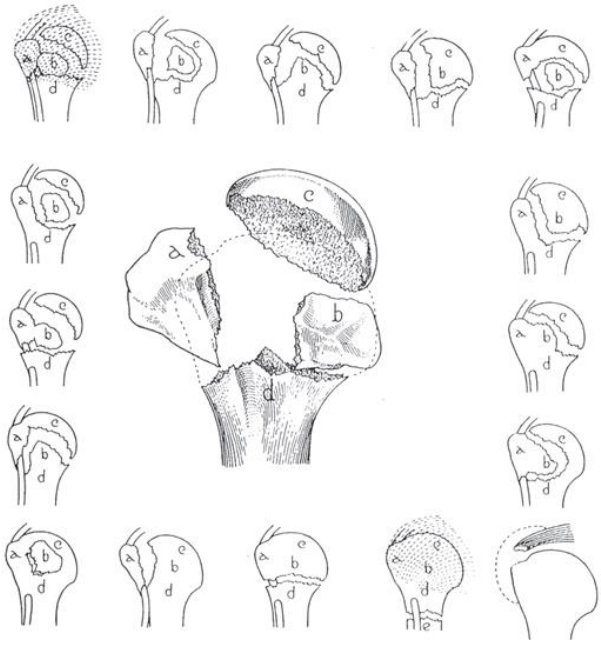

- Charles Neer first refers to Codman's classification in 1953111. In his classification from 1970 Neer integrates fracture anatomy, biomechanics, and the notion of displacement. It is built upon knowledge of the effect of muscles attaching to free segments, rotator cuff integ- rity, the effect of the vascular supply to the humeral head, and condition of the articular surface. Neer's extension of Codman's four-segment approach was a breakthrough in classification of proximal humeral fractures.[25]

AIM AND OBJECTIVES

Proximal humerus fractures are common fractures which increases morbidity in a person manifolds. So most of the time there is necessity to do surgical reduction and fixation.

Aim of this study is to prospectively analyze the functional Outcome proximal humerus fracture fixation using Deltoid splitting approach in Department of Orthopaedics, Government Stanley Medical College Hospital, Chennai between May 2016 and October 2018

MATERIALS AND METHODS

This is a prospective study of 21 cases of Proximal Humerus fractures treated by surgical fixation through Deltoid splitting approach.

The period of survey extends from May 2016 to October 2018.

Inclusion criteria

Patients of age >18 irrespective of sex with proximal humerus fracture

Exclusion criteria

Patients aged less than 18 years

Patient with other associated humerus fracture

Patient with other associated fracture around shoulder

Fracture dislocation

Patient with compound fracture

Patient with pathological fracture

All patients who fulfils the inclusion criteria will be included in the study. The proximal humerus fracture is classified according to Neer's classification system. Once these patients become fit for definitive procedure appropriate internal fixation is done using deltoid splitting approach. Following surgery patients will be hospitalized for required period of time (usually 5 to 7 days) and followed up for 6months and Functional outcome measured using Constant Murley score periodically

The cases were analyzed as per the following criteria :-

- Age distribution
- Sex distribution
- Average age
- Side of injury

- Type of fracture
- Mode of injury
- Associated injury
- Fixation modality
- Complication
- Functional Outcome

REVIEW OF LITERATURE

- Chen et al concluded that Anterolateral deltoid splitting using locking plate fixation provided a feasible alternative for surgery of proximal humerus fractures in different age groups and yielded comparable outcomes when the neck-shaft angle was properly restored. Surgeons must be cautious regarding potential complications, especially with screw penetration when using the locking plate through a less invasive approach[262]
- Shin et al concluded that the use of a modified anterolateral deltoid splitting approach with axillary nerve bundle mobilization in the treatment of proximal humeral fractures yielded excellent outcomes. This approach is a useful alternative to the deltopectoral or the deltoid splitting approaches in the treatment of proximal humeral fractures[27]
- Vijayvargiya et al's study demonstrates that locking plate fixation gives good functional outcomes in treatment of proximal humerus fractures. There was no significant difference in the two approaches used for exposure. The results are comparable to various studies conducted by other authors which states that locking plates provide better functional and radiological outcomes as compared to other fixation methods like Tension band wiring, percutaneous K-wire fixation, non-locking plates, intramedullary nails[28]
- Traver in his study demonstrated a progressive, irreversible increase in axillary nerve length and strain, resulting in microscopic damage to the neuronal structure during a deltoid-splitting approach. Prolonged soft tissue retraction can place the axillary nerve at substantial risk for injury.[29]
- Koljonen concluded that MIPO for fixation of proximal humeral fractures using a locking plate is safe and effective in enabling an early return of shoulder function.[30]
- Korkmaz has in his study found that Deltoid splitting approach, especially with

AO/ASIF B and C type fractures, enables reduction and plate fixing under 270 degree control of the proximal humerus without forceful retraction and soft tissue damage, providing easy access to posterior tubercular fragment. Compared to deltopectoral approach, patients treated with deltoid splitting approach achieved higher Constant scores at an earlier stage. Lateral deltoid splitting approach, by exploring the axillary nerve, is a useful surgical technique which provides an expansive and multi-dimensional control without risking the deltoid muscle function and the axillary nerve[31]

- Samart et al in their study found that There is linear correlation between distance from the lateral acromial edge to axillary nerve and the upper arm length. The authors can predict the danger zone in the location of the anterior upper branch of the axillary nerve[32]
- Lin T et al concluded that the use of MIPO with a locking compression plate in the management of proximal humerus fractures is a safe and superior option compared to ORIF.[33]
- Chou Y C has concluded that When performing shoulder hemiarthroplasty for complex proximal humeral fractures, they found that the anterolateral deltoid-splitting approach provides an easier route for assessing posterior fracture fragments and managing rotator cuff tissue. The anterolateral deltoid-splitting approach was shown to be an acceptable alternative route for shoulder hemiarthroplasty than the standard deltopectoral approach[34]
- Somasundaram has found the use of locking plates, calcium sulphate bone substitute and tuberosity repair with high-strength sutures to be a safe and reliable method of internal fixation for complex proximal humeral fractures and fracture-dislocations. Furthermore, we have also found the use of the extended deltoid-splitting approach to be safe and to provide excellent exposure facilitating accurate

reduction for fixation of the fracture patterns involving displacement of both lesser and greater tuberosities and for fracture-dislocations.[35]

- Ninck J concluded that the anterolateral percutaneous deltoid splitting approach the relative position of the axillary nerve to the holes of a specific implant is of relevance for avoidance of iatrogenic lesions to the nerve[36]
- Zhao JP found that use of PHILOS plate through mini-open deltoid-splittin approach for the treatment of proximal humeral fractures has follow advantages: simple recover,minor-injuries and small tissue invasion, which is an ideal method to treat proximal humeral fractures[37]
- WU CH et al found that no statistically significant difference in clinical, radiographic, and electrophysiological outcomes between the deltopectoral approach and deltoid-splitting approach while surgical treatment of proximal humeral fractures.[38]
- Khan LA concluded that Deltoid splitting approach is a useful alternative in the treatment of complex proximal humeral fractures, providing good access for reduction and implant placement without adverse effects.[39]
- Abhinav G in his study found that The traditional 5-cm deltoid split is probably too generous. We believe 4.2 cm is a safer limit.[40]
- Robinson et ala found that Deltoid splitting approach provides enhanced surgical exposure and offers a useful alternative to the deltopectoral approach in the operative treatment of 3- and 4-part proximal humeral fractures.[41]
- William GR in his study found that the choice of surgical approach is dictated by the fracture pattern and includes an extended deltopectoral approach and a superior deltoid-splitting approach. Fixation techniques are myriad and are dependent on the fracture pattern. Potential fixation methods include intramedullary rods, interfragmentary sutures or wires, and extramedullary plates and screws or blade

plates. Successful results are predicated on obtaining adequate enough fixation to allow early passive motion. Results also are influenced by the quality of the reduction and patient compliance.[42]

- Hepp et al concluded that the choice of approach for exposure of the proximal humerus region may influence the functional outcome. Stable osteosynthesis is important, but the outcome of operatively treated proximal humerus fractures is dependent on soft tissue management as well.[43]
- Gardner et al found that minimally invasive techniques have many potential benefits for fracture healing, but new surgical approaches often must be used to take full advantage of these newer methods. Splitting the anterior deltoid raphe from the acromion distally allowed direct access to the lateral plating zone of the proximal humerus. The bare spot in this region may be a safe area for plate application, if the plate is placed appropriately with thorough knowledge of the vascular anatomy. These findings may be of particular importance if the vascular supply to the humeral head has already been partially compromised by preceding trauma. This direct approach to the lateral bare spot on the proximal humerus may minimize iatrogenic vascular injury when treating these fractures[44]
- Lill HS et al demonstrated that with good short-term results, Deltoid splitting technique seems to be a suitable procedure for displaced humeral head fractures[45]

ANATOMY

Bone

The proximal humerus consists of the humeral head, the greater and lesser tuberosities, and the humeral shaft. The region of transition between the articular cartilage and surrounding bone is defined as the anatomic neck, whereas the region immediately inferior to the tuberosities is termed the surgical neck. Several studies have analyzed the anatomy of the proximal humerus and have shown considerable variation between individuals.

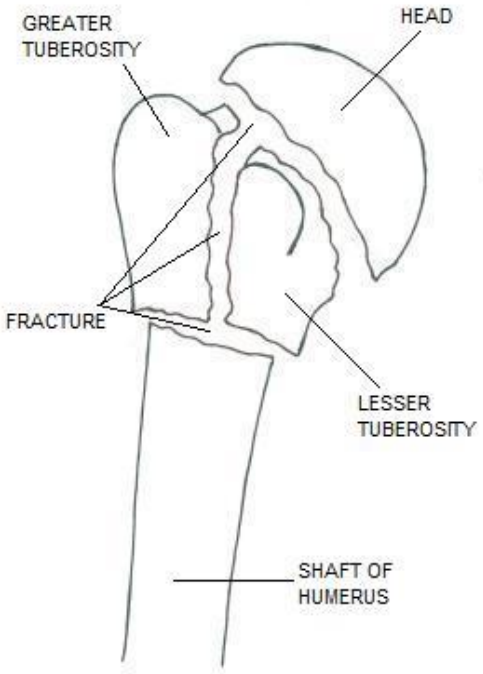

FOUR PART HUMERUS FRACTURE

The mean radius of curvature of the humeral head is 25 mm, ranging from 23 to 29 mm. The humeral head height, defined as the perpendicular distance from the plane of the anatomic neck to the surface of the humeral head consistently is approximately three-fourths of the radius of curvature of the humeral head. Although the head size varies the surface arc covered by hyaline cartilage is approximately 160 degrees.[46] In the coronal plane, the angle between the anatomic neck and the humeral shaft averages 41 degrees, ranging from 30 to 50 degrees. In the axial plane, the posterior angle of the

anatomic neck of the humerus with relation to the epicondylar axis averages 17 degrees and ranges from 5 degrees of anteversion to 50 degrees of retroversion. In the coronal plane, the geometric center of the humeral head is located 4 to 14 mm medial to the axis of the humeral shaft. In the sagittal plane the center of the humeral head can be located from 4 mm anterior to 14 mm posterior to the axis of the humeral shaft. The humeral canal diameter averages 12 mm and ranges from 10 to 14 mm. [46]

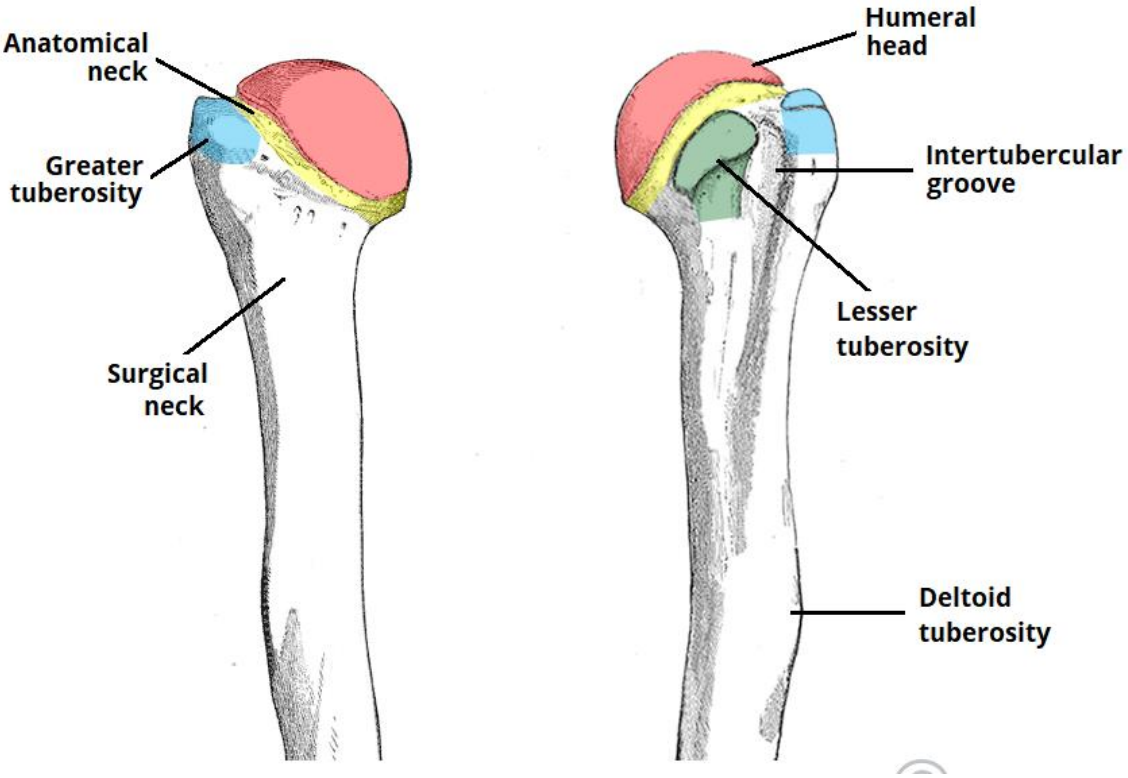

The greater tuberosity lies laterally on the proximal humerus and is the insertion point for the supraspinatus tendon superiorly, the infraspinatus tendon posterosuperiorly and the teres minor tendon posteriorly.The greater tuberosity is located on average 9 mm distal to the most proximal aspect of the humeral head (range: 6 to 10 mm). This head to tuberosity distance is important in facilitating adequate rotator cuff function. Too short a distance leads to insufficient rotator cuff tension and subacromial impingement, whereas

a very low tuberosity may lead to excessive tendon strain and failure. Inability to reconstitute the correct head tuberosity distance has been shown to give poor results in both arthroplasty and fracture reduction.[47]

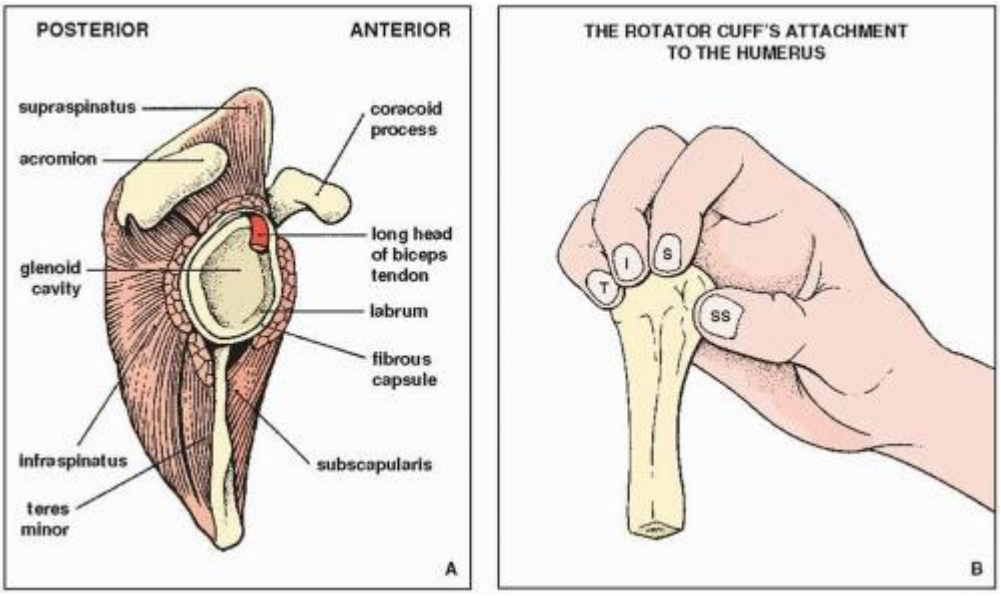

The lesser tuberosity is situated anteriorly in the proximal humerus. It is the insertion site of the subscapularis muscle. The lesser and greater tuberosities are separated by the bicipital groove, which serves as the track for the long head of the biceps to travel from its supraglenoid insertion inside the glenohumeral joint to the anterior aspect of the arm.

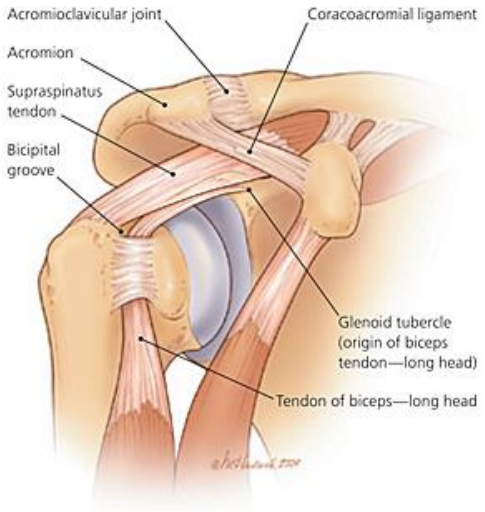

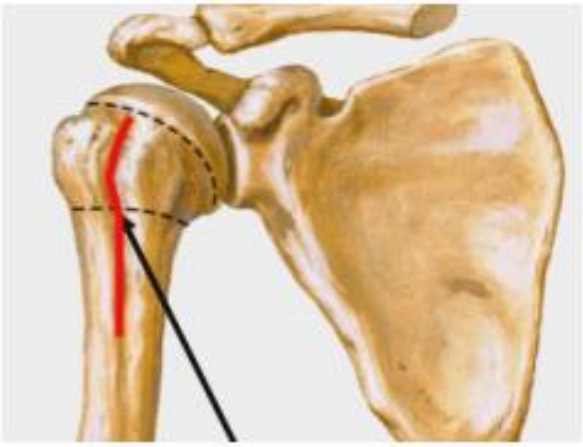

The bicipital groove has a spiral trajectory from superior and laterally toward the midline inferiorly. Proximally, the bicipital groove consistently lies 7 mm anterior to the

intramedullary (IM) axis of the humerus and serves as a reliable reference point to establish humeral head retroversion.The bicipital groove is covered by the transverse ligament and the insertion of the coracohumeral ligament. The bone surrounding the bicipital groove is strong cortical bone and is therefore fractured only in cases of high energy trauma or severe osteopenia. It is therefore a useful landmark for fracture reduction.

Vascularity

Perfusion of the upper extremity is mainly from the axillary artery and its branches. Perfusion of the proximal humerus arises from the axillary artery where it passes between the pectoralis minor and teres major muscles. At this level, the axillary artery gives off the humeral circumflex arteries .

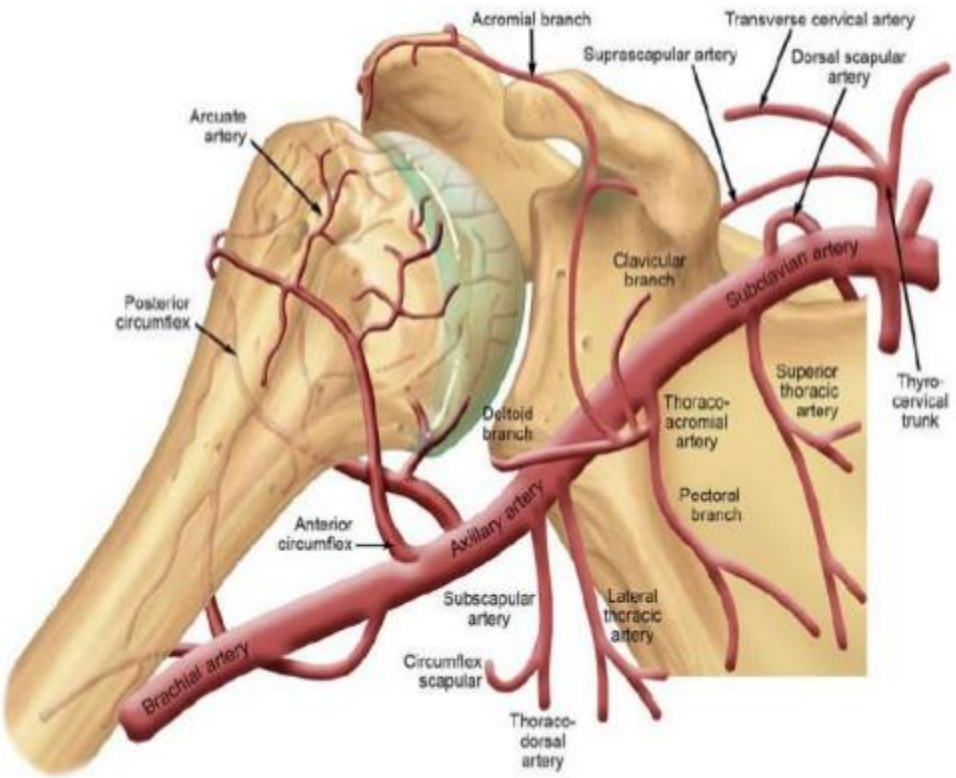

The ACHA runs horizontally behind the conjoined tendon over the anterior aspect of the surgical neck of the humerus to anastomose laterally with the PCHA. At the level of

the biceps tendon the ACHA gives off a branch that ascends behind the long head of the biceps on the surface of the bicipital groove proximally. Within 5 mm of the articular surface it penetrates the cortical bone, becoming the arcuate artery which provides vascularity to most of the humeral head.[48]

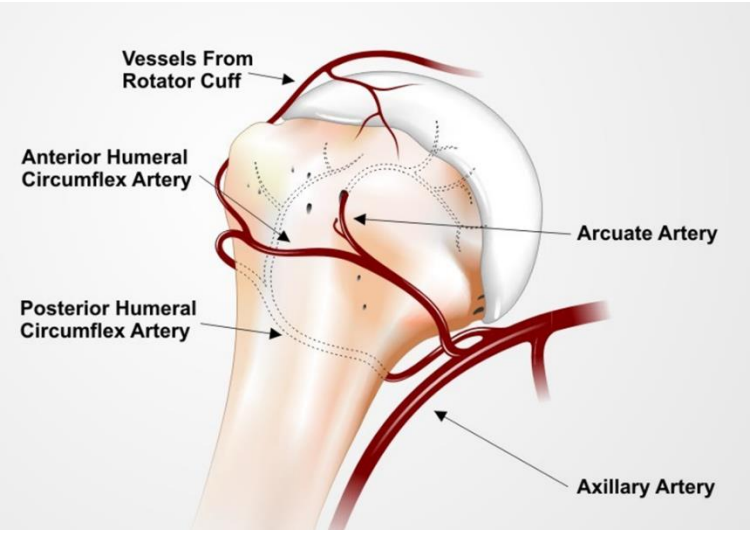

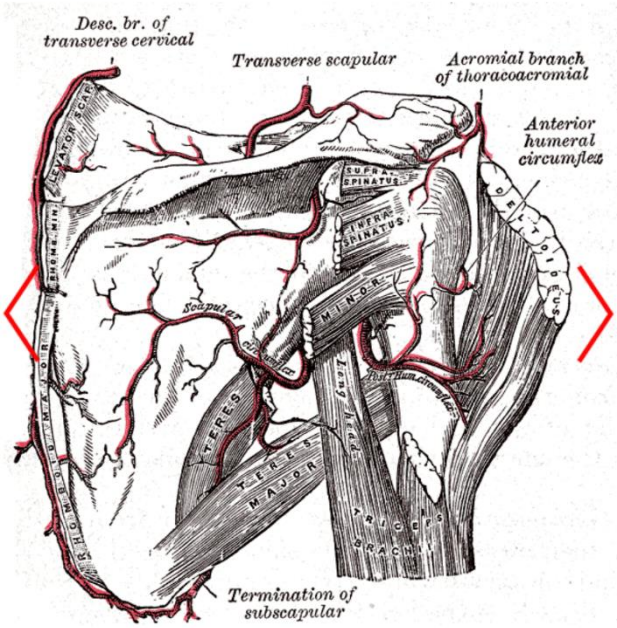

The PCHA arises as a larger branch at the same level as the ACHA at the lower margin of the subscapularis muscle. It travels posteriorly with the axillary nerve giving off several branches that pierce the posteromedial aspect of the proximal humeral metaphysis providing vascularity to the humeral head. The PCHA finally crosses the quadrilateral

space winding around the surgical neck and anastomosing anteriorly with the ACHA. While some authors have found the arcuate artery from the anterolateral ascending branch of the ACHA to be the main arterial supply to the humeral head, several studies have shown branches from the PCHA to the posteromedial head to be at least equally important.

Muscles

The rotator cuff muscles play an important role in displacement of the proximal fracture segment, whereas pectoralis major is responsible for displacing the shaft segment. The rotator cuff is composed of the subscapularis anteriorly, the supraspinatus superiorly, and the infraspinatus and teres minor posteriorly. The subscapularis muscle originates from the subscapularis fossa on the anterior surface of the scapular body and inserts into the lesser tuberosity. The supra- and infraspinatus muscles originate from the posterior surface of the scapular body above and below the scapular spine, respectively. The teres minor muscle originates from the lateral border of the scapular body. These three muscles insert onto the greater tuberosity of the proximal humerus.

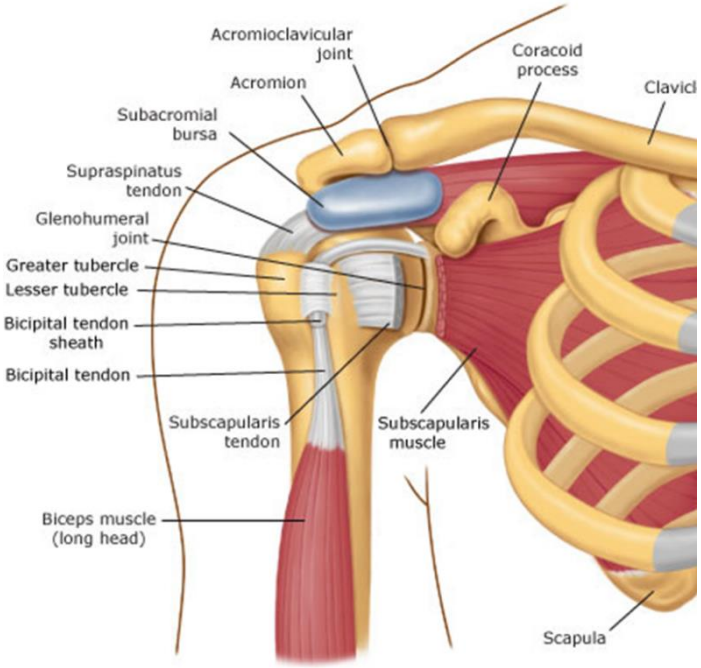

The supraspinatus inserts superiorly, the infraspinatus posterosuperiorly, and the teres minor posteriorly.These muscles play a key role in shoulder function, and are

essential to preserve a rotational fulcrum during activation of the deltoid. The subscapularis muscle is innervated by the upper and lower subscapular nerves which originate from the posterior cord of the brachial plexus. It derives its perfusion from the subscapular artery which is the largest branch of the axillary artery. The supra and infraspinatus muscles are innervated by the suprascapular nerve which originates from the upper trunk of the brachial plexus. Blood supply is provided by the suprascapular artery which comes from the thyrocervical trunk which originates from the subclavian artery. The teres minor is innervated by the axillary artery and perfused by the posterior humeral circumflex and the circumflex scapular arteries which originate from the subscapular artery.

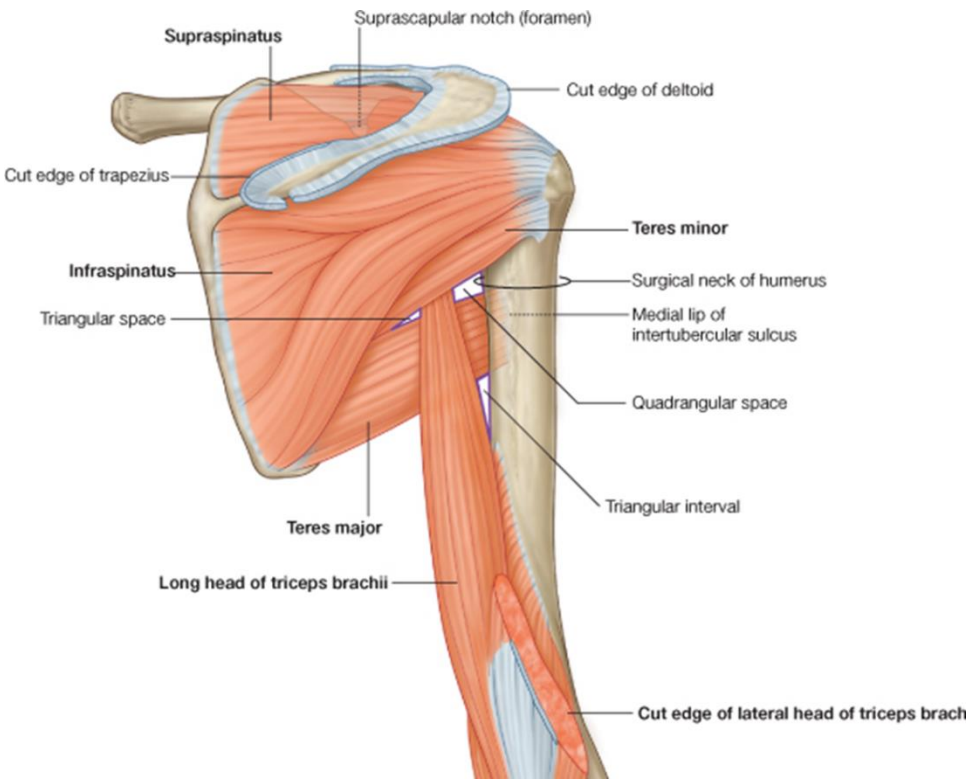

In proximal humeral fractures rotator cuff tears may start through the rotator cuff interval. In arthroplasty reconstruction of proximal humeral fractures, separation of the lesser and greater tuberosities may be safely performed through the rotator interval to avoid damage to the rotator cuff.

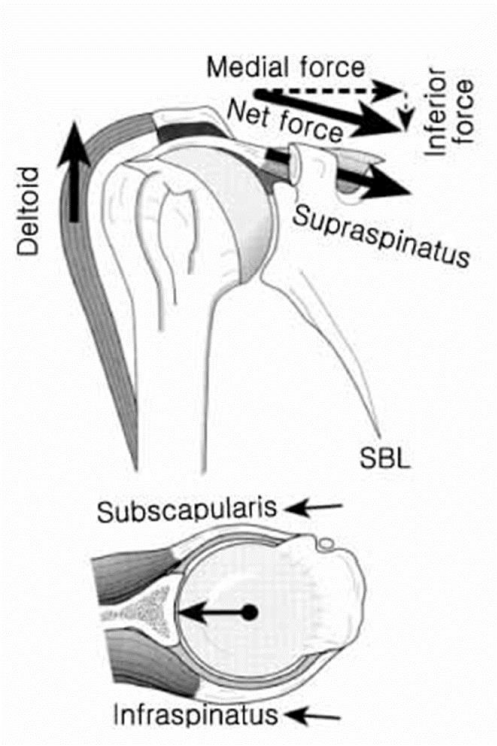

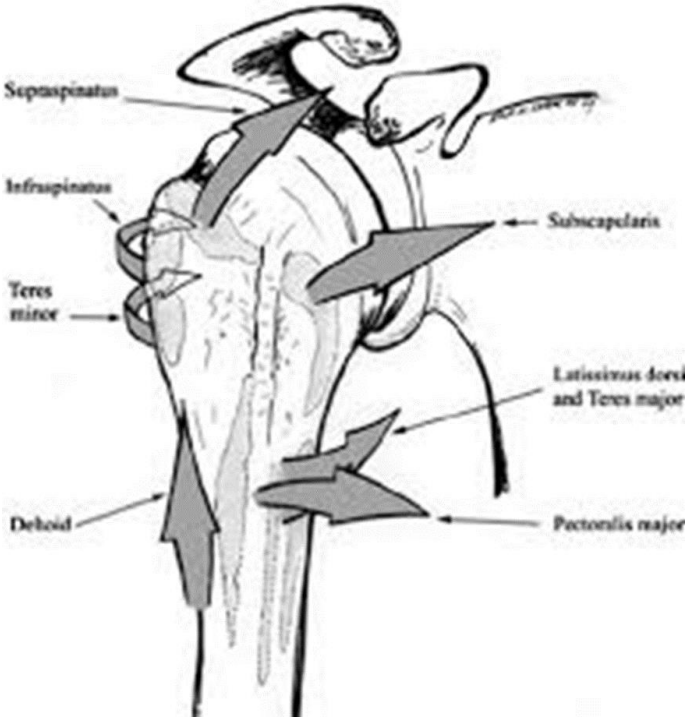

The long head of the biceps originates at the supraglenoid tubercle, traveling over the humeral head across the rotator interval into the intertubercular groove. During its course through the intertubercular groove the tendon is covered by the transverse humeral ligament. Muscle fibers of the long head join those of the short head at the level of the middle third of the humerus. Due to its location, the long head of the biceps can serve as a useful landmark for orientation particularly in comminuted fractures. The tendon can be identified in the proximal third of the arm and traced proximally to locate the intertubercular groove and tuberosities.

The deltoid originates on the anterior aspect of the lateral third of the clavicle, the periphery of acromion, and the lateral third of the scapular spine. It is commonly described as consisting of three segmental units, anterior, middle and posterior, which respectively provide shoulder flexion, abduction and extension. The anterior deltoid originates from the clavicle and the anterior aspect of the acromion.[49] A fibrous raphe

extending from the anterolateral corner of the acromion distally separates the anterior from the middle deltoid. The deltoid fibers converge laterally inserting onto the deltoid tuberosity of the humerus in a trapezoidal fashion. The insertion measures 5 to 7 cm in length with a width of 22 mm proximally and 13 mm distally. Distally, interconnections of the deltoid and its fascia with the lateral intermuscular septum and the brachialis muscle allow for partial release of the deltoid during surgical approach without the need for repair.The deltoid muscle isnnervated by the axillary nerve. Blood supply to the deltoid is provided by the PCHA.

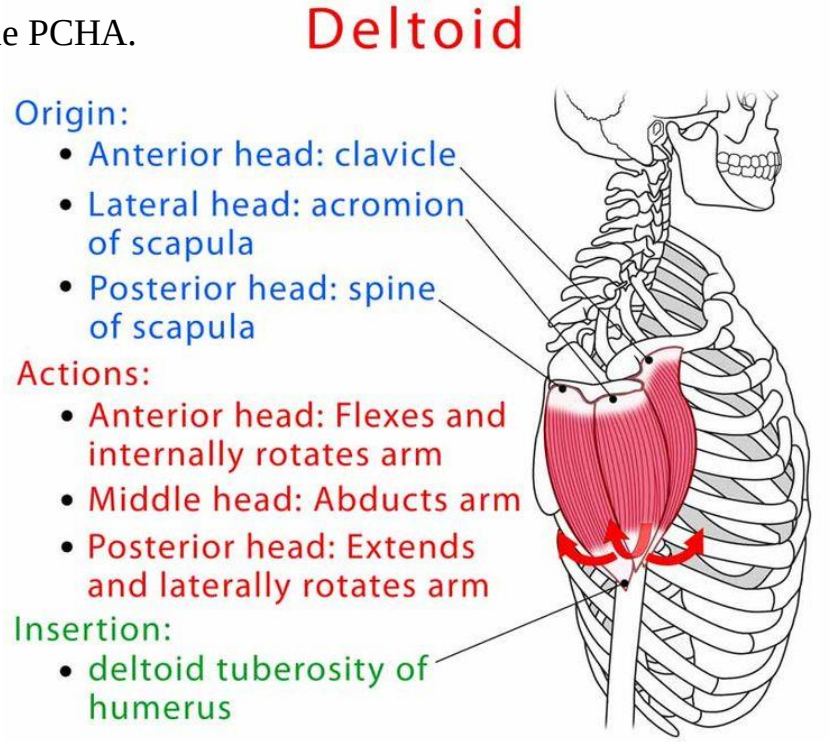

Muscle forces

- In ***one part*** or minimally displaced #s- the periostium, rotator cuff, joint capsule attachments hold the fragments together.
- ***Two part #;***

  in displaced **surgical neck**:shaft displaced forward& medially-P.major Gt& head in neutral bcoz cuff is intact& balanced.

  In**# GT**-sup.post displaced.

  In # LT-medial.
- ***Three part #;***

  When displaced SN is component along with GT:, the unopposed pull of sub scapularis internally rotates the articular, face post. This pattern may be accompanied with longitudinal tear of cuff.

  SN along with LT:unopposed pull of cuff causes articular surface face ant.
- **Four part#:**

  GT-sup.post

  LT-ant.medial

  shaft-medially

  deltoid insertion causes-abduction of proximal fragment.

Articular segment may impact on shaft or displaced

Nerves

Several nerves are at risk of damage from manipulation of the proximal humerus or surgery. The axillary nerve can be injured by the initial injury, or secondarily by percutaneous fixation. The axillary nerve is one of the terminal branches of the posterior cord of the brachial plexus. Its motor fibers innervate the teres minor and deltoid muscles; the sensory component innervates the skin overlying the lateral aspect of the proximal arm. At the level of the proximal humerus, the axillary nerve passes from anterior to posterior, accompanied by the posterior circumflex artery, inferior to the anatomic neck through the quadrilateral space surrounded by teres major superiorly, the long head of the triceps medially, teres major inferiorly, and the humeral shaft laterally.

After giving off the branch to the teres minor, it passes anteriorly on the undersurface of the deltoid at a distance ranging from 2 to 7 cm distal to the acromion. [50] This distance has been found to be inversely proportional t the length of the deltoid. It crosses the anterior deltoid raphe between the anterior and middle deltoid in the form of a single terminal branch allowing for preservation of the innervation of the anterior deltoid when the nerve is isolated during the deltoid-splitting approach.[51]

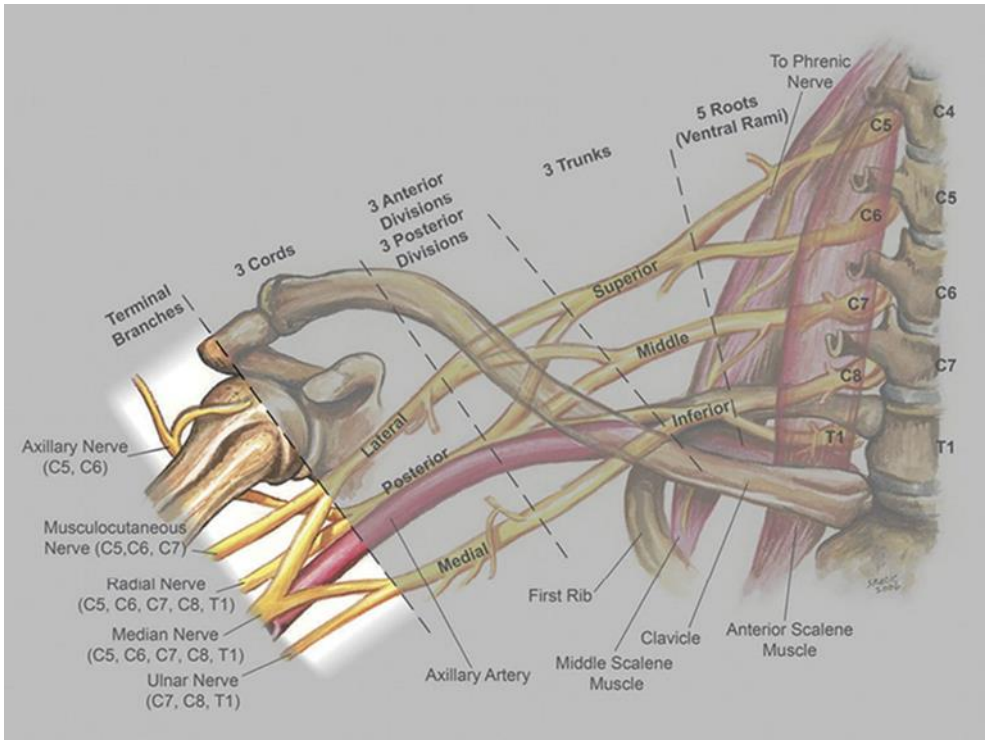

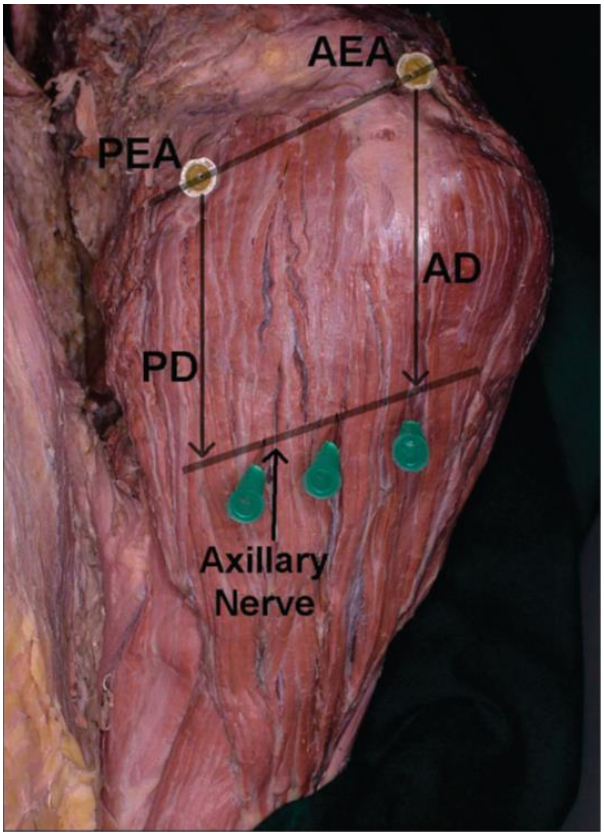

The musculocutaneous nerve is at risk from medial retraction when performing the deltopectoral approach. The musculocutaneous nerve originates from the lateral cord of the brachial plexus. The most proximal motor branch to the coracobrachialis muscle is located about 3 to 4 cm distal to the tip of the coracoid, being less than 5 cm in 75% of cases.[52]The musculocutaneous nerve then enters the coracobrachialis at a mean distance of 5.6 cm inferior to the coracoid process.

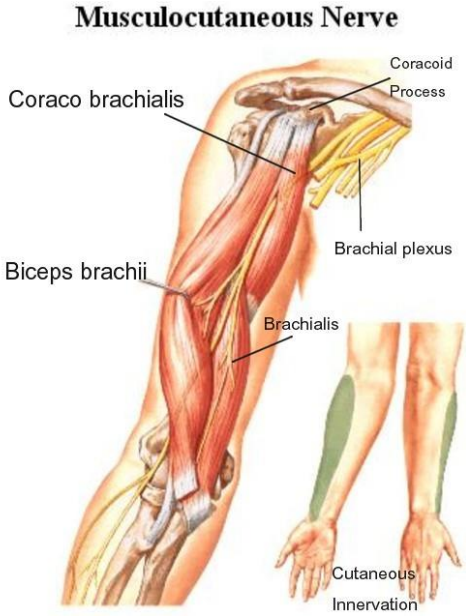

Farther distally, it pierces the biceps at an average of 10 cm distal to the coracoid. It then travels between biceps and the underlying brachialis muscle innervating both muscles. It ends as the lateral antebrachial cutaneous nerve providing sensation to the lateral aspect of the forearm.

MECHANISM OF INJURY

Approximately half of all proximal humeral fractures occur at home with the majority occurring as a consequence of falls on level ground. In individuals 60 years or older, over 90% of proximal humeral fractures result from a fall from a standing height. In younger individuals there is a higher incidence of proximal humeral fractures occurring outside the home, as a result of higher-energy trauma, such as a fall from a height, motor vehicle accidents (MVAs), sports, or assaults.[53]

9.4% were caused by falls from a height, MVAs, sports, or assaults. The average age of this group was 42.5 years and 71% were males.[53]

The proximal humerus can fracture as a consequence of three main loading modes: compressive loading of the glenoid onto the humeral head, bending forces at the surgical neck, and tension forces of the rotator cuff at the greater and lesser tuberosities. When the glenoid impacts on the humeral head during a fall in individuals with normal bone, the proximal humeral epiphysis appears to be able to resist local compressive loads. The energy is then transferred further distally, where the weaker metaphyseal bone may yield, resulting in a surgical neck fracture.

In individuals with osteoporotic bone, weaker epiphyseal bone may yield simultaneously with the surgical neck, thereby leading to more complex multifragmentary fractures. In isolated greater tuberosity fractures, and in the exceptionally rare isolated lesser tuberosity fracture the mechanism of fracture is usually a dislocation of the glenohumeral joint with tension failure of the fragment secondary to the pull of the rotator cuff on the tuberosities.

Tension forces may also play a role in multifragmentary fractures, where tuberosity fractures are caused in combination with compression of the humeral head. These tension forces play a further role in displacement because of the unopposed pull of the rotator cuff muscles on the tuberosities, once they have become unstable.

Apart from bone quality fracture configuration is influenced by the amount of kinetic energy conveyed to the shoulder, and by the position of the upper limb during injury. High-energy fractures in normal bone result in marked comminution of the surgical neck area with extension into the proximal humeral shaft with the integrity of the proximal humeral epiphysis usually being preserved.

When falling onto the outstretched hand with the shoulder in flexion, abduction, and internal rotation the glenoid forces the humeral head into valgus, hinging around the inferomedial aspect of the stronger calcar bone. This is called Valgus impaction type of injury.

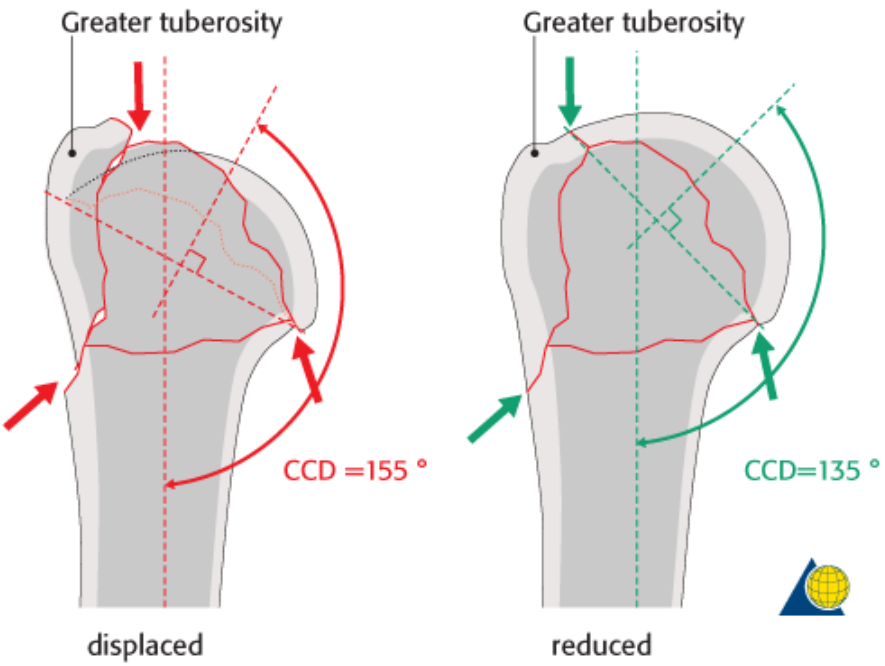

In the event that the patient falls directly onto the shoulder the deforming force on the humeral head will create a Varus deformity which, due to the natural retroversion of the humeral head will most probably cause a posterior rotational deformity of the head segment. This is called Varus Extension type of injury

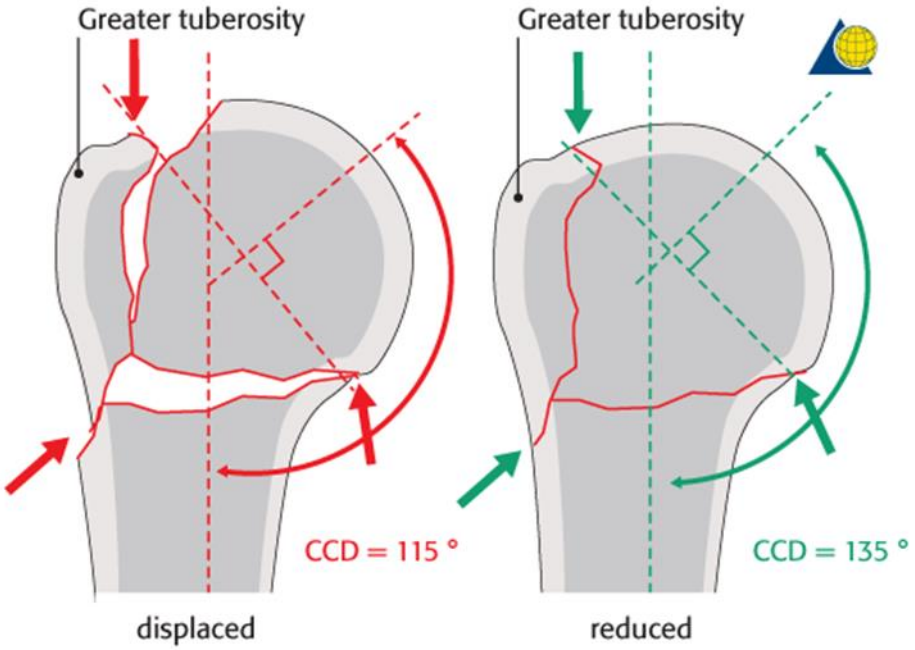

a.

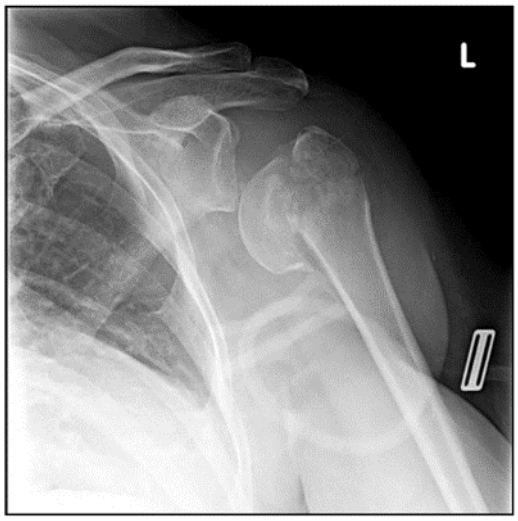

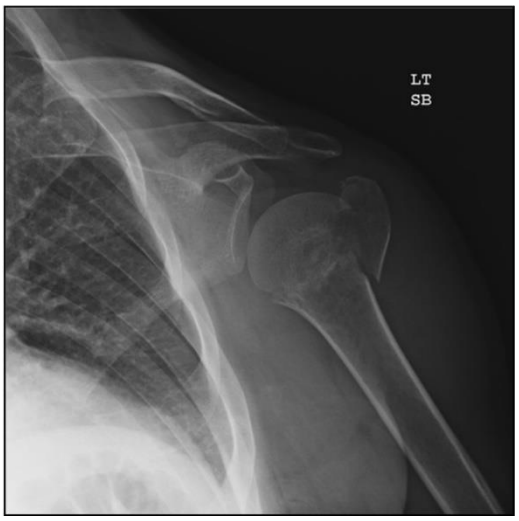

CLASSIFICATION

❖ Thudichum (1851)

I. Anatomical neck fractures

A. intra-capsular fracture without impaction

B. intra-capsular fracture with impaction

II. Fractures of greater tuberosity

III. Fractures of lesser tuberosity

IV. Epiphysiolysis

A. epiphysiolysis

B. fracture involving the epiphyseal line

V. Surgical neckfractures

A. extracapsular fractures without impaction

B. extracapsular fracture with impaction

❖ **KOCHERS** based on different anatomic levels.

I Anatomic neck

II Epiphyseal region

III Surgical neck.

Did not included #s at multiple level, degree of displacement, dislocations, mechanism.

❖Watson Jones

I Impacted #s.

II Impacted abducted #s.

❖ **Codman's** based on epiphyseal region-

four possible #s GT ,LT ,anatomic head, shaft

❖NEER'S

Displacement defined as greater than 45 degrees of angulation or 1 cm of separation.

1-One part fracture – No displacement or angulation<45 degrees or

seperation <1cm

2-Two part fracture – Displacement of 1 fragment

3-Three part fracture – Displacement of two individual fragments from remaining humerus

4-Four part fracture – Displacement of all four segments

5-#Dislocation (anterior or posterior) regardless number of displaced segment

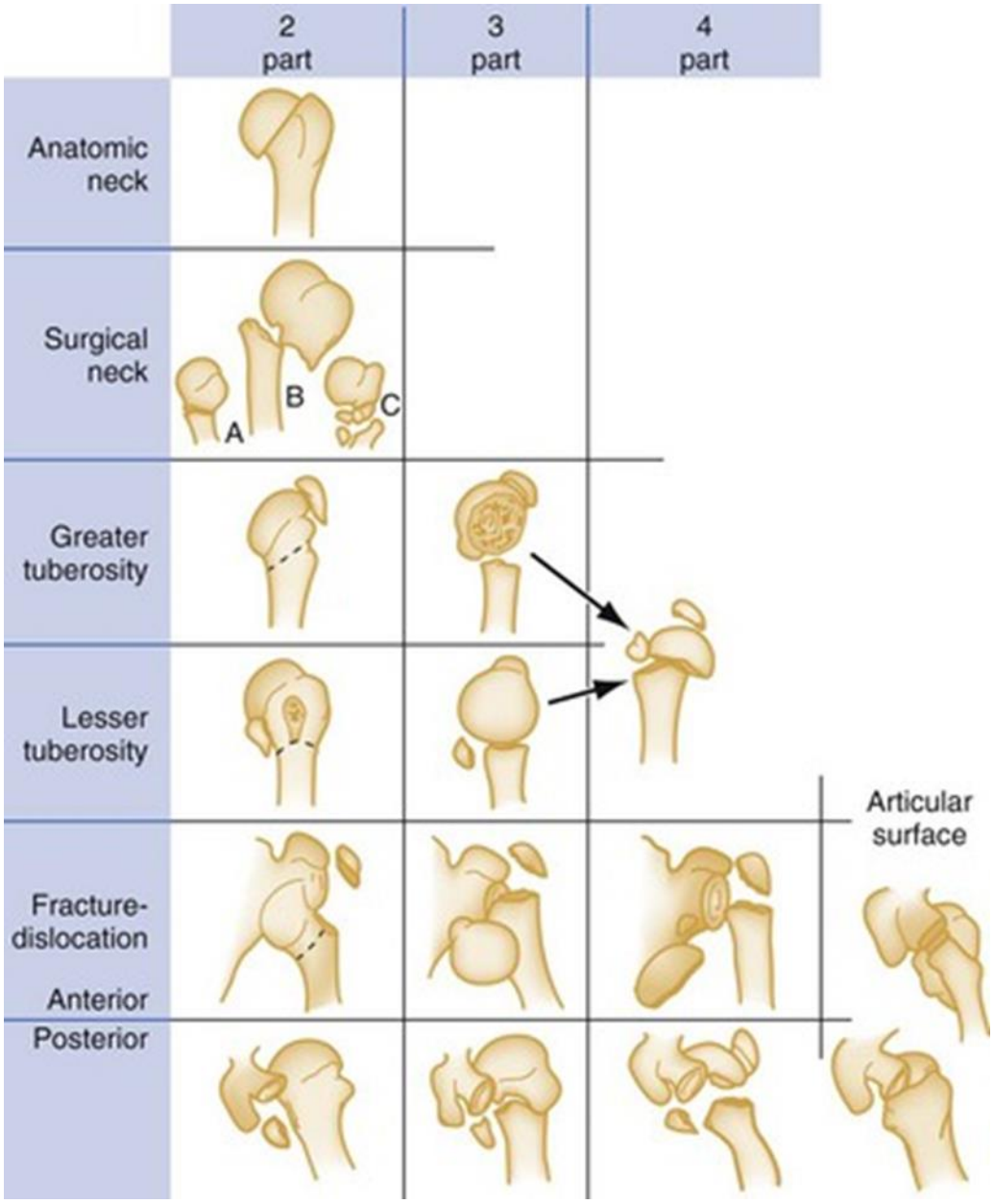

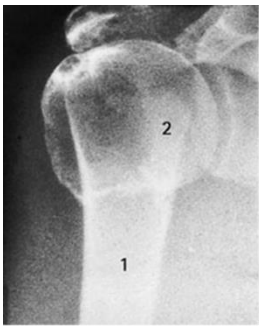

2Part

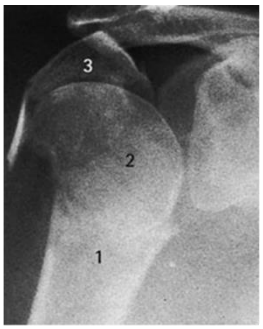

3Part

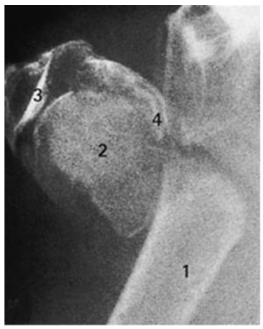

4Part

Type V

❖ AO

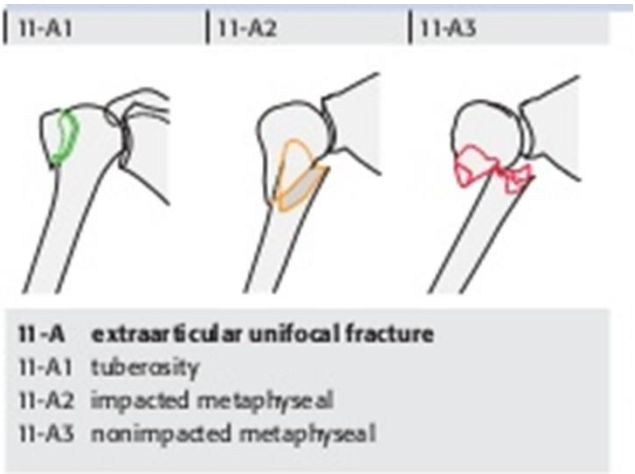

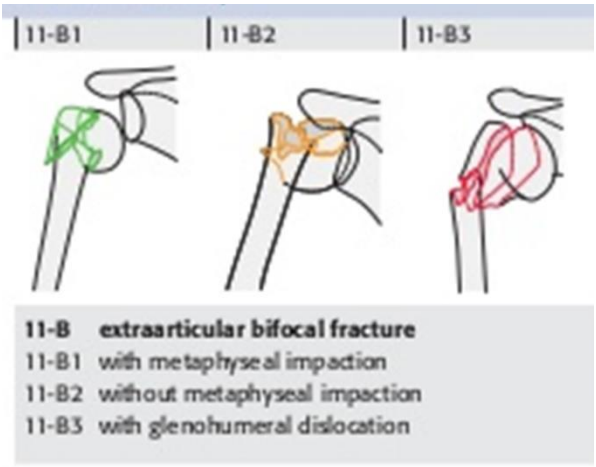

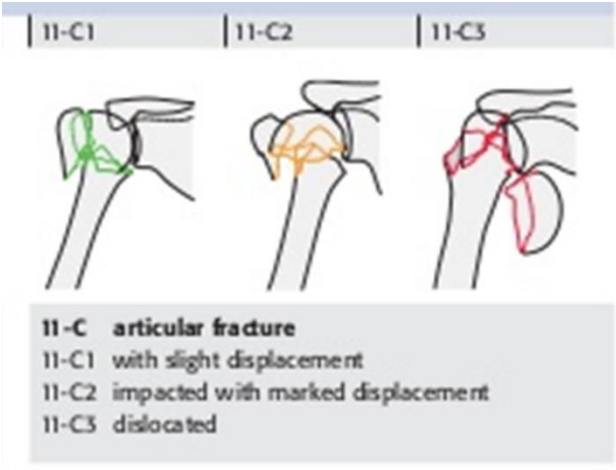

MANAGEMENT

- **Radiographic evaluation**

  X-ray

  1- AP view

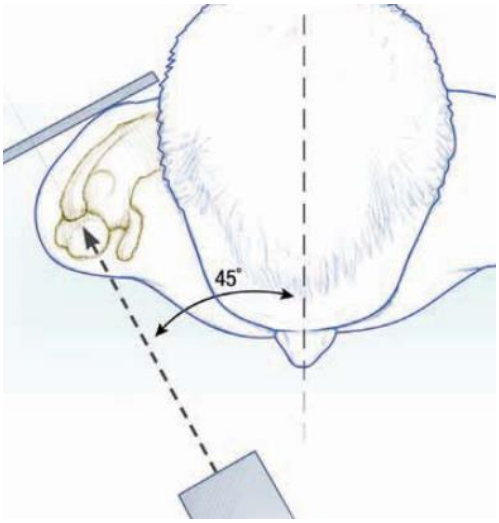

  2- lat view

  3-axillary views

  (Axillary and scapular-lateral views should always be obtained, to exclude dislocation of the shoulder)

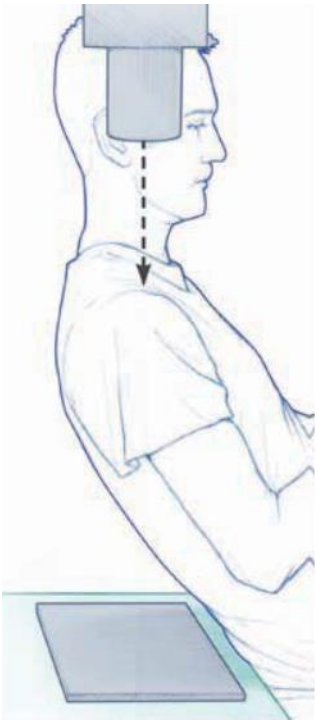

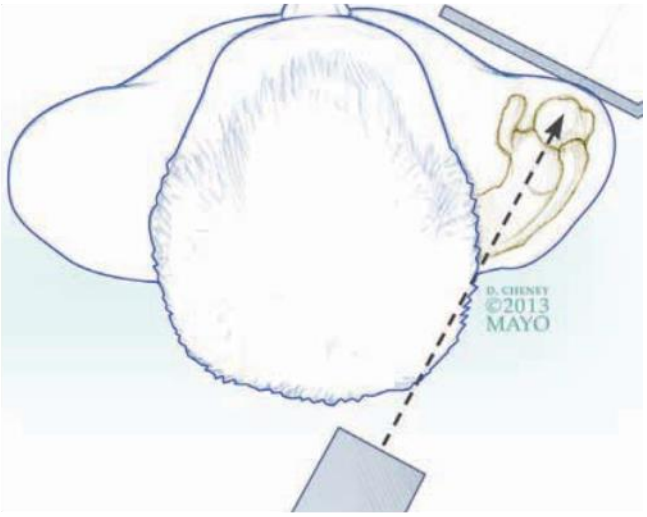

CT Scan

To analyse :-

1- articular fractures

2- impression

3- head split

4- glenoid fractures

5- assess tuberosity displacement for operative decision making

- **Preoperative Anaesthesia evaluation**
- **Treatment options**

1 part # - Mostly conservative management

2 part # - Operative procedure if displacement >1cm – K-Wires /Screws/Plates

3part # - Operative procedure – K-Wires /Screws/Plates

4part # - Operative procedure – K-Wires /Screws/Plates/Arthroplasty

Advantages and Disadvantages of Techniques Used to Treat Displaced Fractures of the Proximal Humerus

TECHNIQUE	ADVANTAGES	DISADVANTAGES
Nonoperative treatment	Function as good as operative treatment for many fractures Low risk of infection and other operative complications	Malunion inevitable: ▪ Cuff dysfunction/stiffness more likely ▪ Later salvage surgery more difficult Risk of nonunion increased
Minimally invasive techniques	Reduced injury to soft-tissue envelope Lower risk of infection	Steep learning curve Risk of axillary nerve/vascular injury Less stable fixation
Intramedullary nailing	More stable fixation technique in osteoporotic bone Minimal dissection required for insertion	Rotator cuff dysfunction after anterograde insertion Poor results in multipart fractures High rate of late implant removal
Open reduction and plate fixation	Anatomic fracture reduction possible ▪ Improved functional outcome ▪ Later revision easier Most stable fixation in multipart fractures ▪ Rigid implants ▪ Adjuvant bone grafting possible	Open surgical approach required: ▪ Increased risk of infection ▪ Increased risk of osteonecrosis
Hemiarthroplasty	Risk of nonunion, osteonecrosis, symptomatic malunion avoided Low reoperation rate	Poor functional outcome Late arthroplasty complications difficult to treat in elderly patients

Different fixation modalities

K-Wire

Screws

Plates

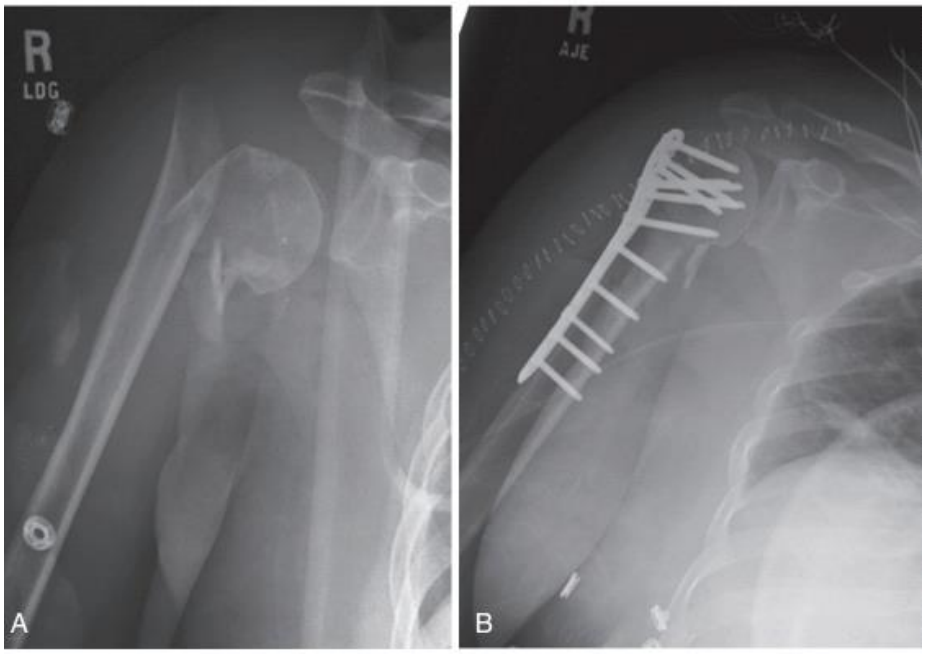

Nails

Replacement

❖ Rehabilitation

- Arm Sling applied immediately post op
- Limb elevated
- Passive elbow, wrist and hand movements started on the day of surgery
- This continued for one week
- Passive range of movements of shoulder started at 2weeks
- First forward elevation, external rotation and pendulum exercises started
- Passive exercise for 4-6 weeks
- If healing adequate active exercise after 4-6 weeks
- Strengthening exercise after adequate ROM is achieved
- Free mobilization out of sling after 6 weeks

Hertel's criteria

Good predictors of ischemia

Length of metaphyseal head extension (accuracy 0.84 for calcar segments <8 mm)

Integrity of the medial hinge (accuracy 0.79 for disrupted hinge)

Basic fracture pattern (accuracy 0.7 for fractures comprising the anatomic neck)

Poor predictors of ischemia

Angular displacement of the head (angulations over 45 deg)

Extent of displacement of the tuberosities (displacement over 10 mm)

Gleno-humeral dislocation

Head-split components

By combination of the above criteria : anatomic neck, short calcar, disrupted hinge, positive predictive values of up to 97% obtained in Hertel's study.[54]

Hertel's criteria

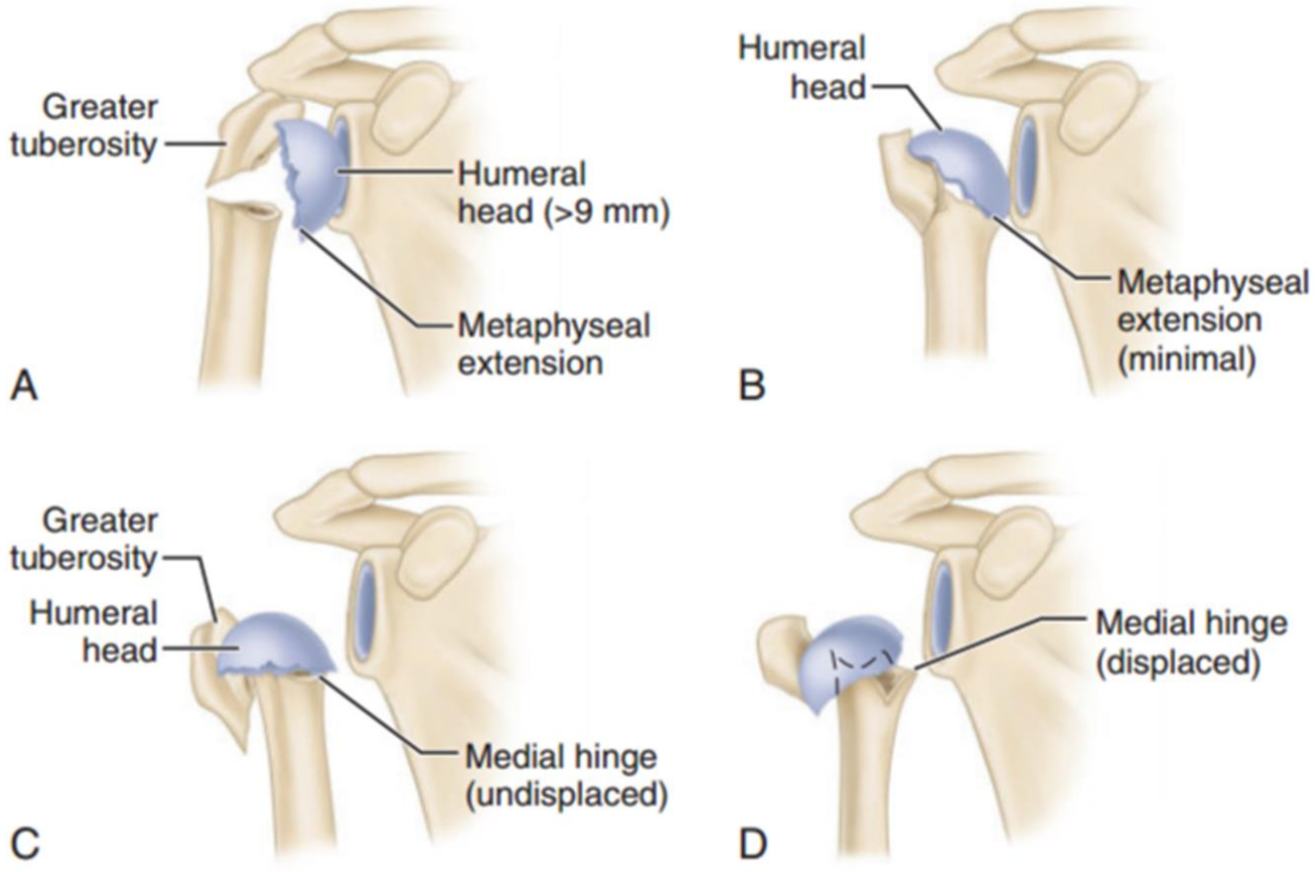

DELTOID SPLITTING APPROACH

- Useful for nailing (A- and B-type fractures) and osteosynthesis of fractures of the greater tuberosity (A1.1)
- Easy and wide exposure of prox humerus
- Better exposure for suturing of rotator cuff to LCP to prevent varus collapse
- Low incidence of malreduction
- Better Functional outcome

Patient positioning

Beach chair position

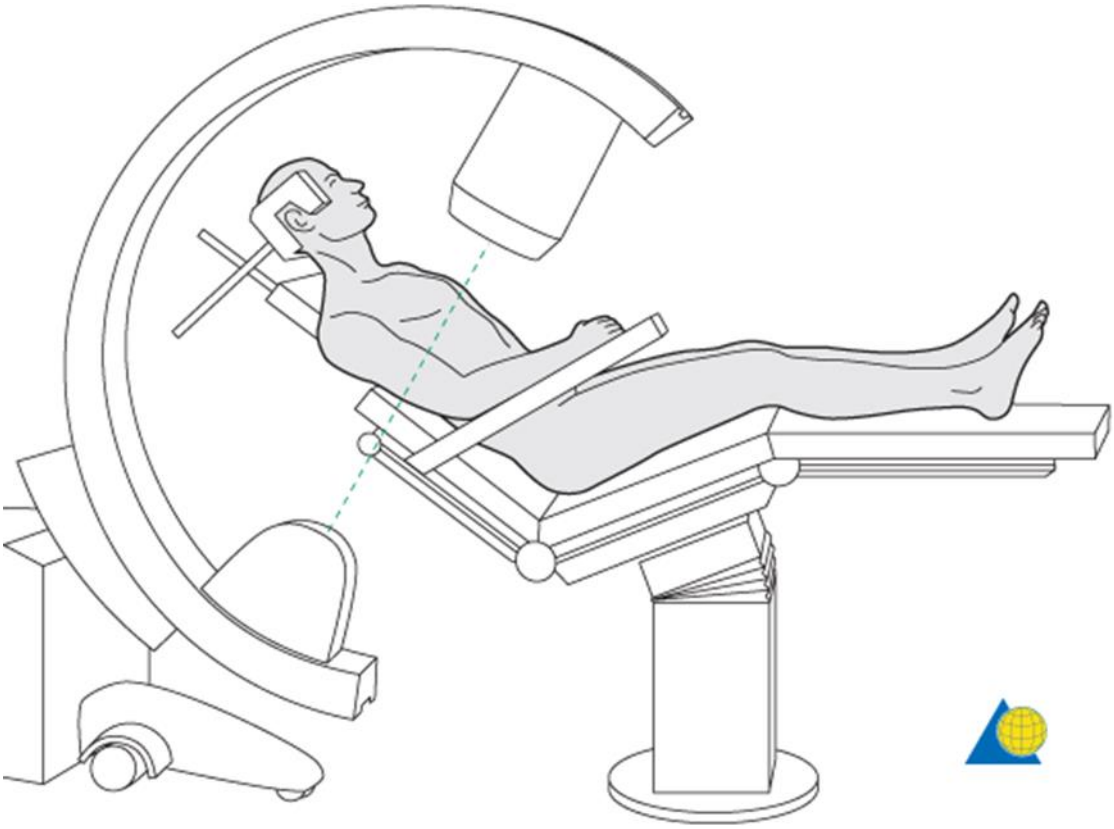

Incision

Landmarks : Anatomical landmarks

A) Lateral border of the acromion

B) Lateral side of the proximal humeral shaft

Both landmarks can easily be palpated.

Starts at lateral end of acromion and extended vertically down

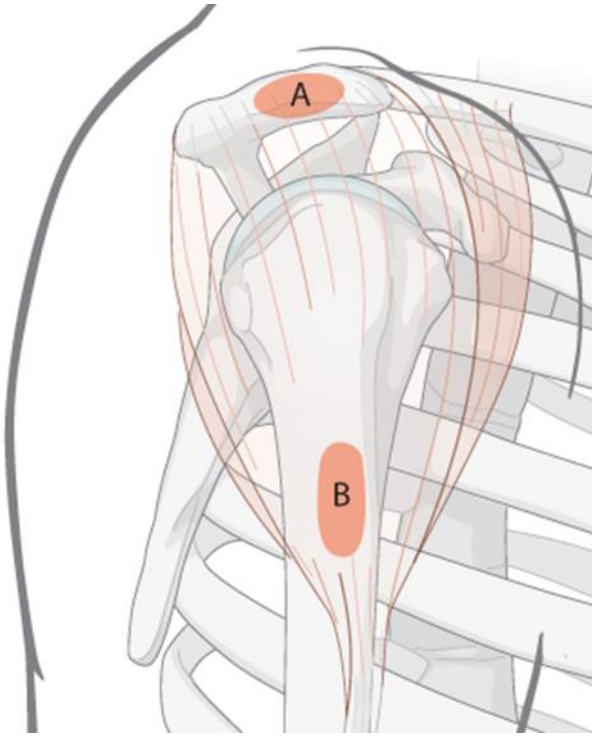

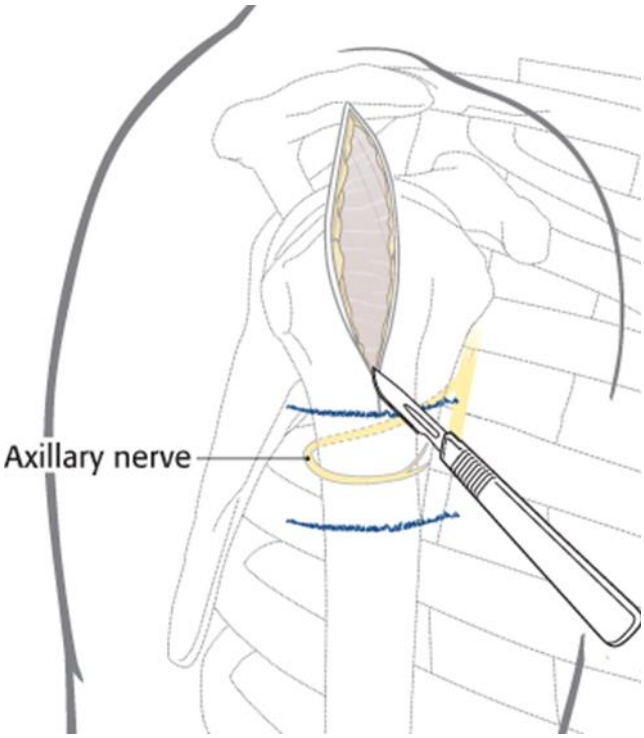

This approach utilizes a relatively avascular plane, away from the anterior and posterior circumflex humeral arteries

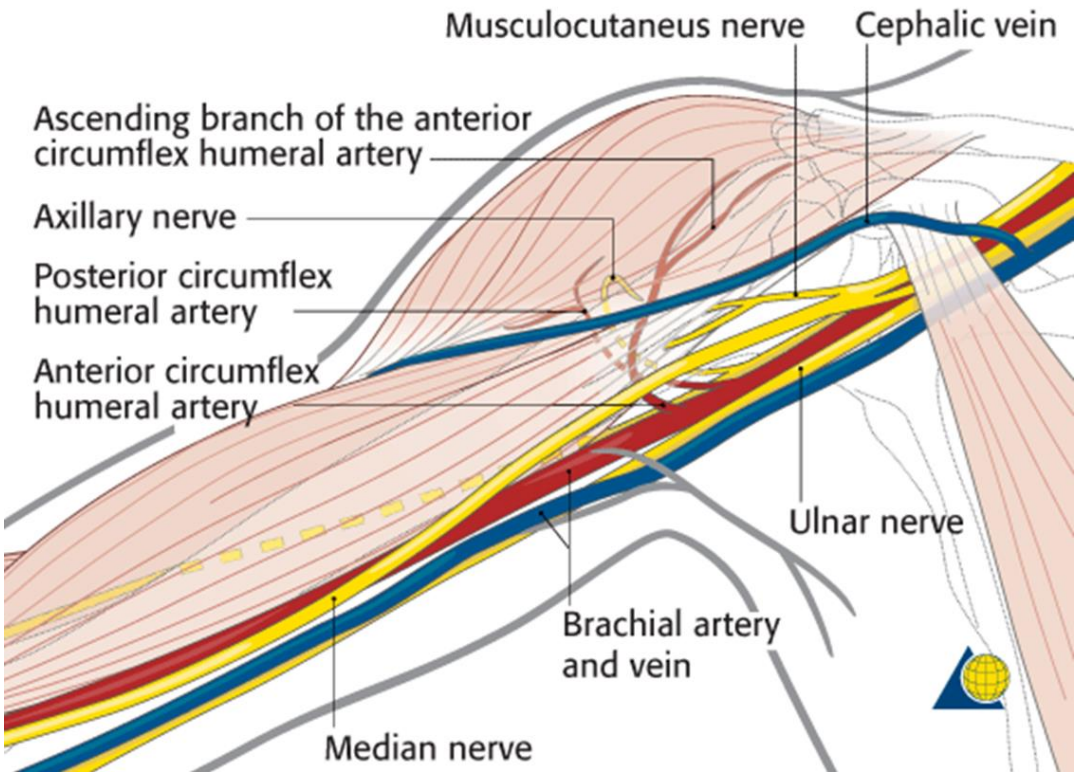

Exposure of the middle third part of the deltoid muscle

Expose the middle third (acromial) part of the deltoid muscle and split the muscle between its fibers.

For maximum exposure, split the deltoid up to the margin of the acromion,

But do not split it distally more than 5 cm from its origin to avoid damaging the axillary nerve and paralyzing the anterior part of the

deltoid

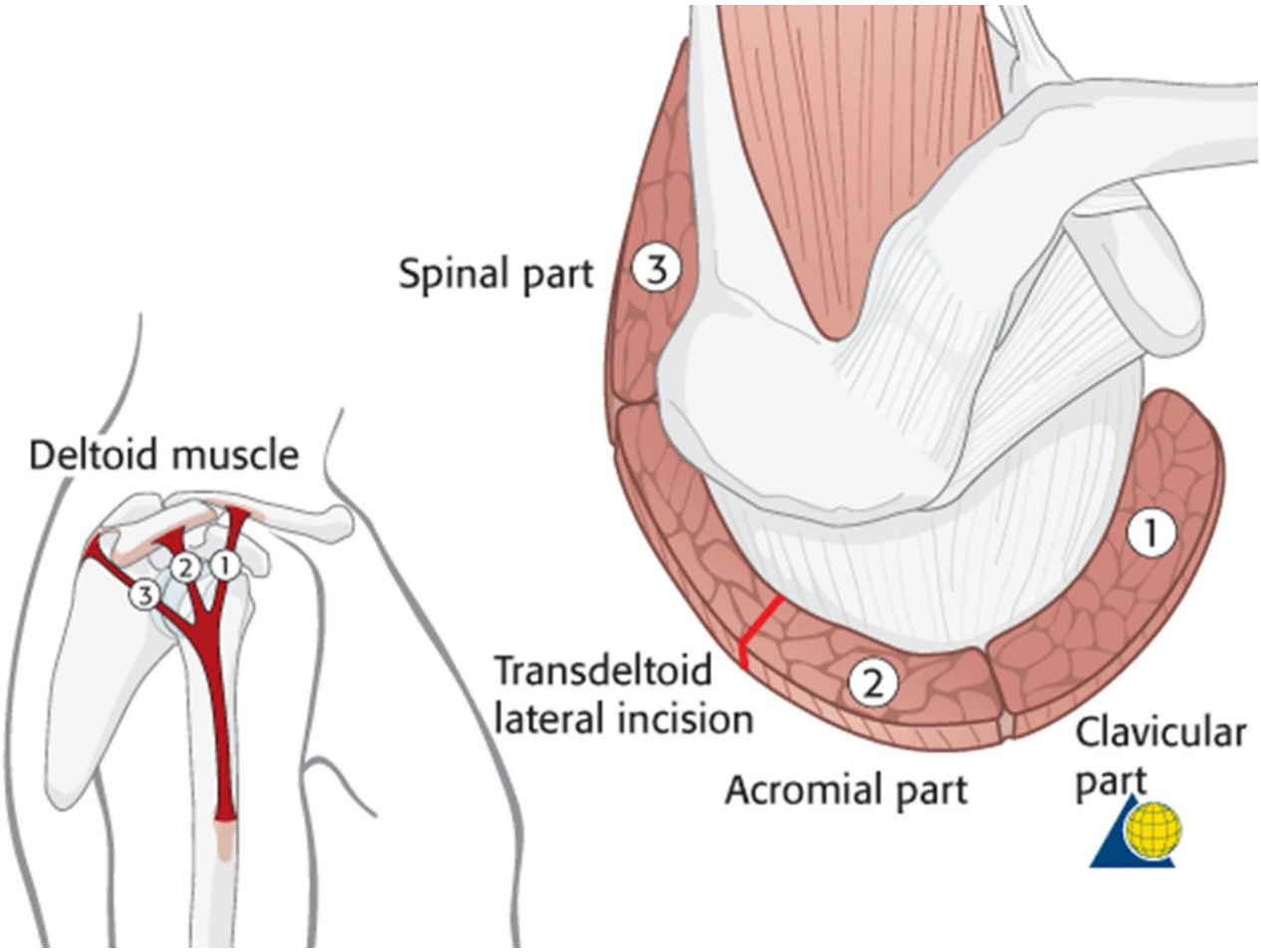
Spinal part
3
Deltoid muscle
2
1
3
1
Transdeltoid
lateral incision
2
Clavicular
part
Acromial part

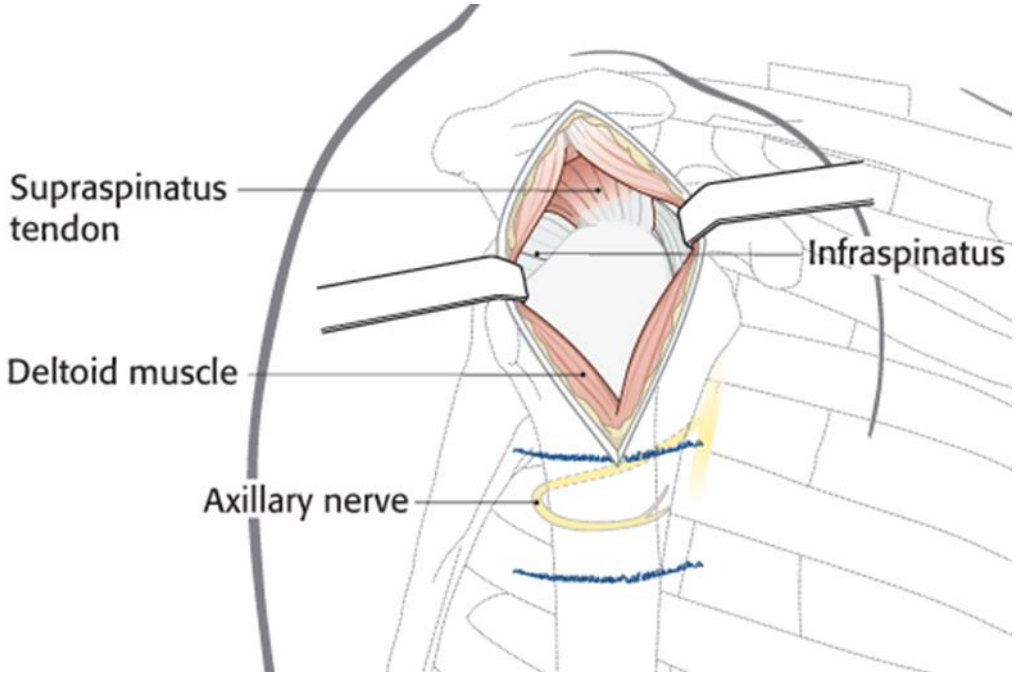
Supraspinatus
tendon
Infraspinatus
Deltoid muscle
Axillary nerve

Axillary nerve

5cm below the acromion, which is 1 cm above the course of the axillary nerve.

If a plate is to be passed underneath the axillary nerve, as in minimally invasive plate osteosynthesis (MIPO),

Mark a second line 2 cm distal to the first, below which the axillary nerve should not be encountered.

The space between these two lines is the danger zone on the lateral humerus

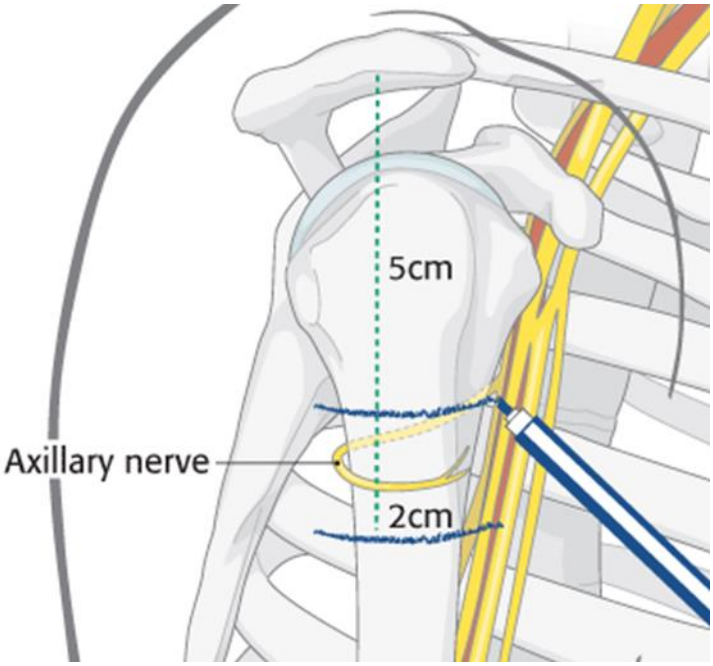

COMPLICATIONS

Early complication:

*Rotator cuff syndrome
* Vascular injury .
* Nerve injury.
* Biceps tendon rupture
* Thoracic injury

Late complication:

* stiffness of the shoulder.
* malunion.
* infection
* Avascular necrosis.

MASTER CHART

Sr. No	Name	Age/ Sex	Mode of injury	Neer's type / side	Associated injuries	Fixation	Complication	Constant score at 6weeks/Grade	Constant score at 3 months/Grade	Constant score at 6 months/Grade
1	Bommi	50/F	Self fall	3/L	nil	LCP	nil	60/Fair	70/Good	74/Good
2	Mani megalai	65/F	Sel fall	4/R	nil	LCP	Stiffness	40/Poor	60/Fair	62/Fair
3	Veera Raghavan	46/M	RTA	3/R	nil	LCP	Nil	70/Good	84/Excellent	84/Excellent
4	Rama lingaam	70/M	Self fall	4/R	nil	LCP	Stiffness	40/Poor	58/Fair	60/Fair
5	Kamala	59/F	Sel fall	3/R	nil	LCP	Nil	64/Fair	74/Good	78/Good
6	Vasantha	63/F	Self fall	3/R	nil	LCP	Nil	68/Fair	74/Good	80/Good
7	Arivazhagan	62/M	Self fall	3/R	nil	LCP	Nil	64Fair	76/Good	82/Good
8	Arockiaraj	39/M	RTA	2/L	nil	LCP	Nil	74/Good	84/Excellent	86/Excellent
9	Bhasker	35/M	RTA	3/L	nil	LCP	Nil	72/Good	88/Excelent	88/Excellent
100	Chandrasekhar	31/M	RTA	2/L	nil	LCP	Nil	74/Good	86/Excellent	88/Excellent
11	Dhana Lakshmi	45/F	RTA	3/R	nil	LCP	Nil	66/Fair	74/Good	80/Good
12	Jayaraman	49/M	RTA	3/R	nil	LCP	Nil	64/Fair	76/Good	78/Good
13	Kasim	48/M	Self fall	2/L	nil	LCP	Nil	66/Fair	78/Good	80/Good
14	Manonmani	65/F	Self fall	3/L	nil	LCP	Nil	68/Fair	76/Good	80/Good
15	Balaji	36/M	RTA	2/L	nil	LCP	Nil	72/Good	86/Excellent	88/Excellent
16	Raja	45/M	RTA	2/L	nil	LCP	Nil	76/Good	88/Excellent	92/Excellent
17	Rajeshwari	45/F	RTA	2/L	nil	LCP	Nil	70/Good	78/Good	80/Good
18	Selva Ganesh	20/M	RTA	2/R	nil	LCP	Nil	80/Good	88/Excellent	94/Excellent
19	Suresh Kumar	39/M	RTA	2/R	nil	LCP	Nil	68/Fair	76/Good	82/Good
20	Vasantha	65/F	Self fall	2/R	nil	LCP	Nil	64/Fair	78/Good	78/Good
21	Vijayakumar	35/M	RTA	2/L	nil	Screws	Nil	78/Good	86/Excellent	88/Excellent

CONSTANT MURLEY SCORE[55]

Clinician's name (or ref) _____ Patient's name (or ref) _____

Answer all questions, selecting just one unless otherwise stated

During the past 4 weeks.....

1. Pain
○ Severe
○ Moderate
○ Mild
○ None

2. Activity Level (check all that apply)		
○	yes	Unaffected Sleep
○	no	
○	yes	Full Recreation/Sport
○	no	
○	yes	Full Work
○	no	

3. Arm Positioning
○ Up to Waist
○ Up to Xiphoid
○ Up to Neck
○ Up to Top of Head
○ Above Head

4. Strength of Abduction [Pounds]	
○ 0	○ 13-15
○ 1-3	○ 15-18
○ 4-6	○ 19-21
○ 7-9	○ 22-24
○ 10-12	○ >24

RANGE OF MOTION

5. Forward Flexion
○ 31-60 degrees
○ 61-90 degrees
○ 91-120 degrees
○ 121-150 degrees
○ 151-180 degrees

6. Lateral Elevation
○ 31-60 degrees
○ 61-90 degrees
○ 91-120 degrees
○ 121-150 degrees
○ 151-180 degrees

7. External Rotation
○ Hand behind Head, Elbow forward
○ Hand behind Head, Elbow back
○ Hand to top of Head, Elbow forward
○ Hand to top of Head, Elbow back -
○ Full Elevation

8. Internal Rotation
○ Lateral Thigh
○ Buttock
○ Lumbosacral Junction
○ Waist (L3)
○ T12 Vertebra
○ Interscapular (T7)

Print page | Close Window | Reset

To save this data please print or Save As CSV

The Constant Shoulder Score is 0

Grading the Constant Shoulder Score
(Difference between normal and Abnormal Side)

>30 Poor	21-30 Fair	11-20 Good	<11 Excellent

Reference for Score: Constant CR, Murley AH. A clinical method of functional assessment of the shoulder. Clin Orthop Relat Res. 1987 Jan;(214):160-4. link to pubmed

Reference for Grading: Fabre T, Piton C, Leclouerec G, Gervais-Delion F, Durandeau A. Entrapment of the suprascapular nerve. J Bone Joint Surg Br. 1999 May;81(3):414-9.

OBSERVATION

This study comprised of 21 patients who were admitted in the department of Orthopaedic Surgery, Govt. Stanley Medical College Hospital. The following are the observations and the results compiled at the end of the study. The results were analysed.

Age wise distribution (n=21)

Table No .1

S.NO	Age group(in years)	No. of cases	%
1	21-30	1	4%
2	31-40	6	28.5%
3	41-50	7	33.3%
4	51-60	1	4%
5	61-70	6	28.5%

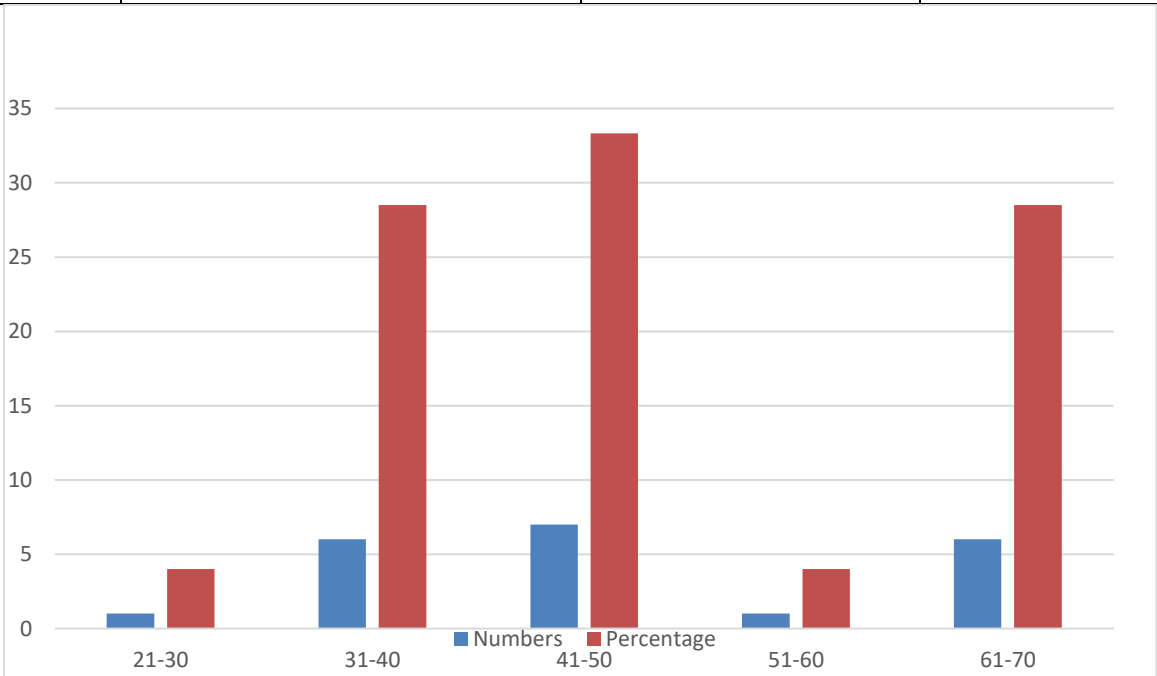

Average age

Table No. 2

Sex	Average
Male	42.69
Female	57.1

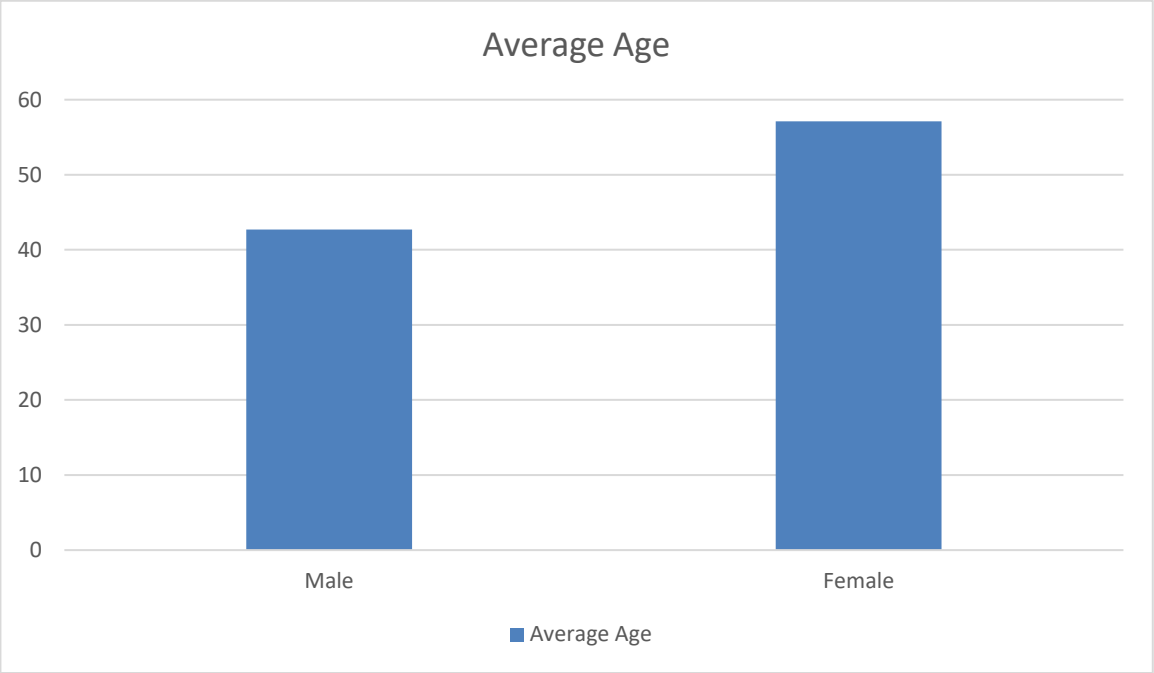

Sex wise distribution (n=21)

Table No. 3

S.NO	Sex	NO of cases	%
1	Male	13	62
2	Female	8	38

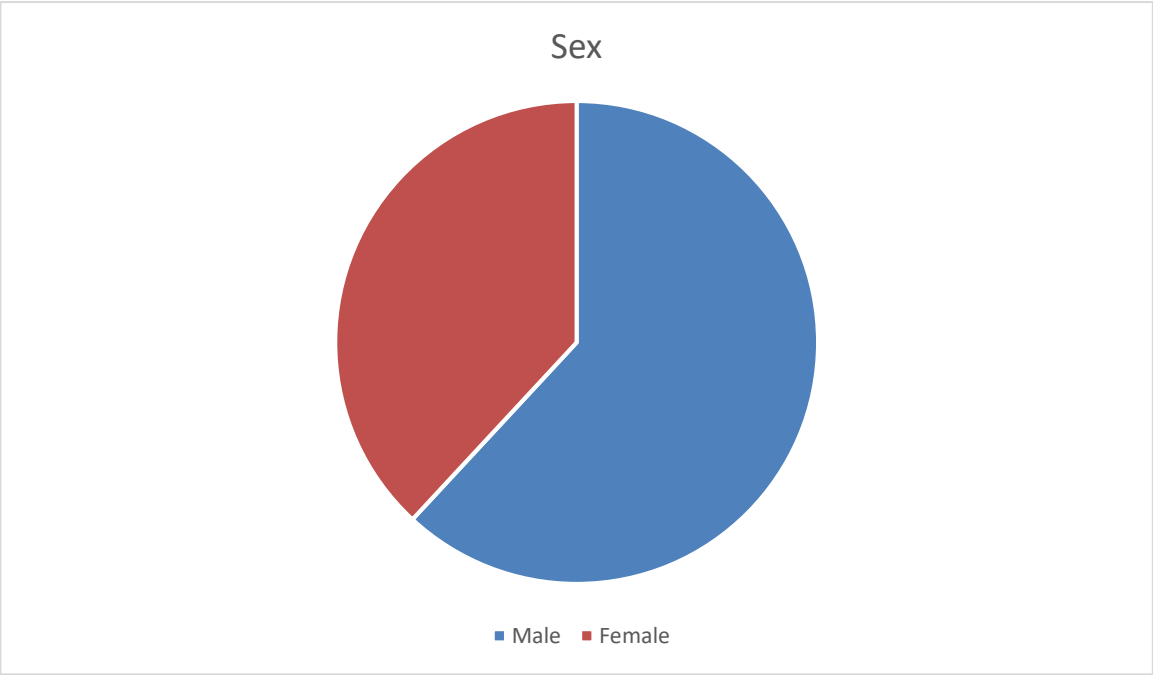

Distribution according to side

Table No.4

S.NO	Side	No of cases	%
1	Right	11	52%
2	Left	10	48%

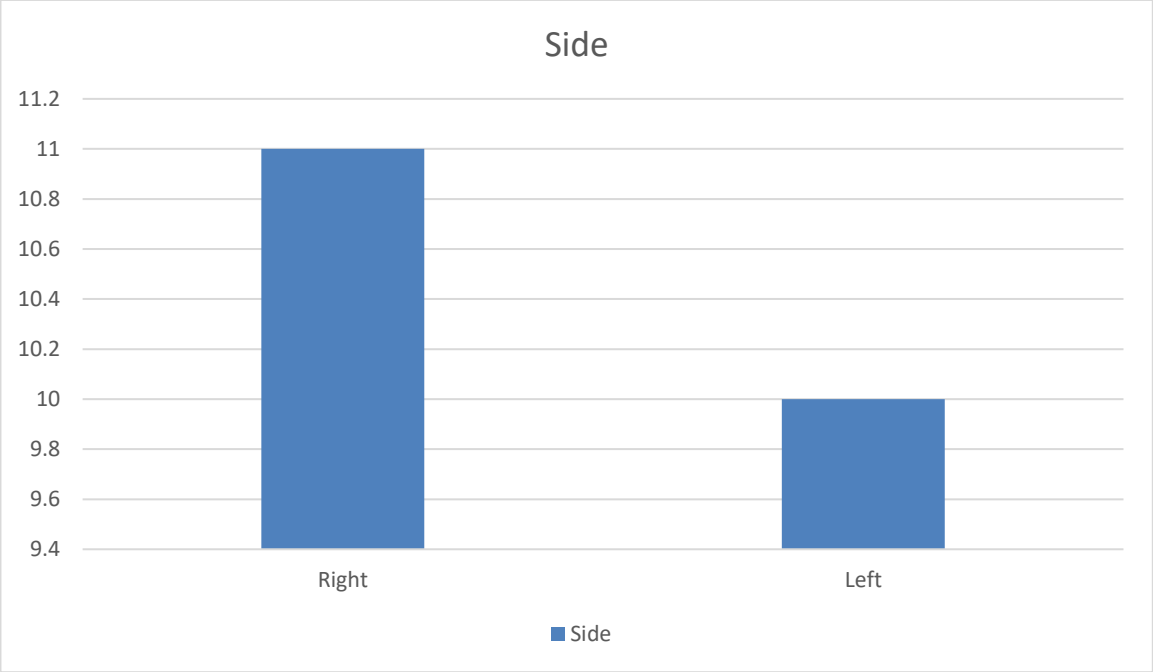

Distribution according to Mode of injury

Table No.5

S.NO	Mode	No of cases	%
1	RTA	12	57%
2	Self fall	9	43%

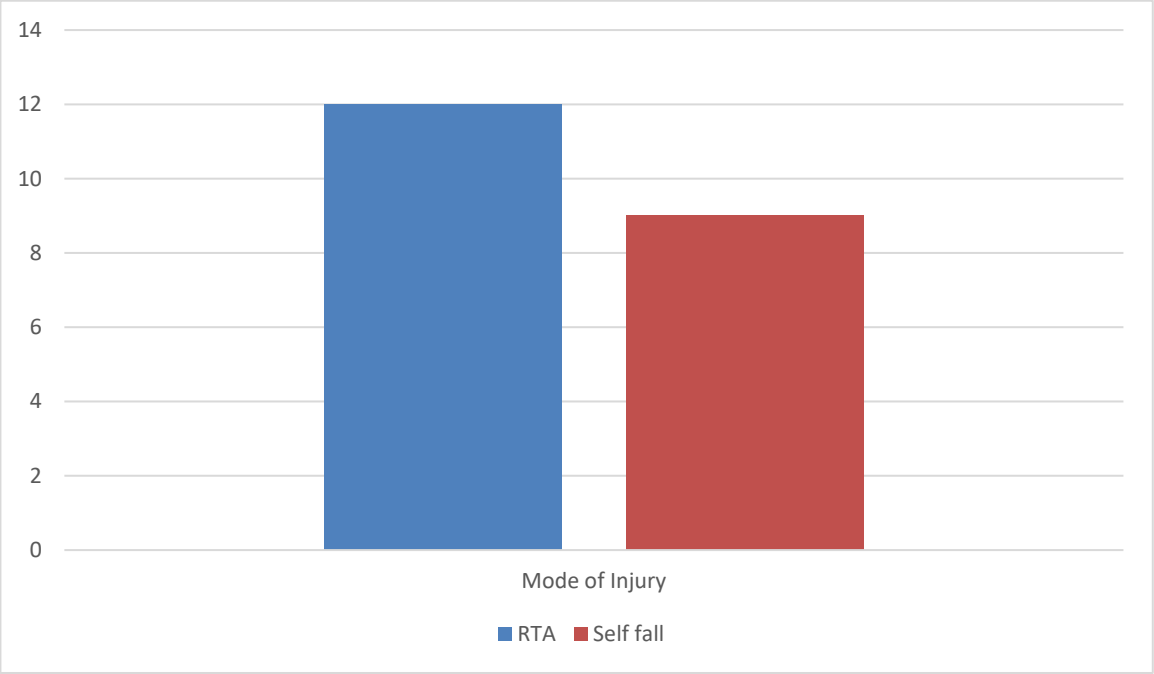

Distribution according to Associated injuries

Table No.6

S.NO	Associated Injuries
1	Nil

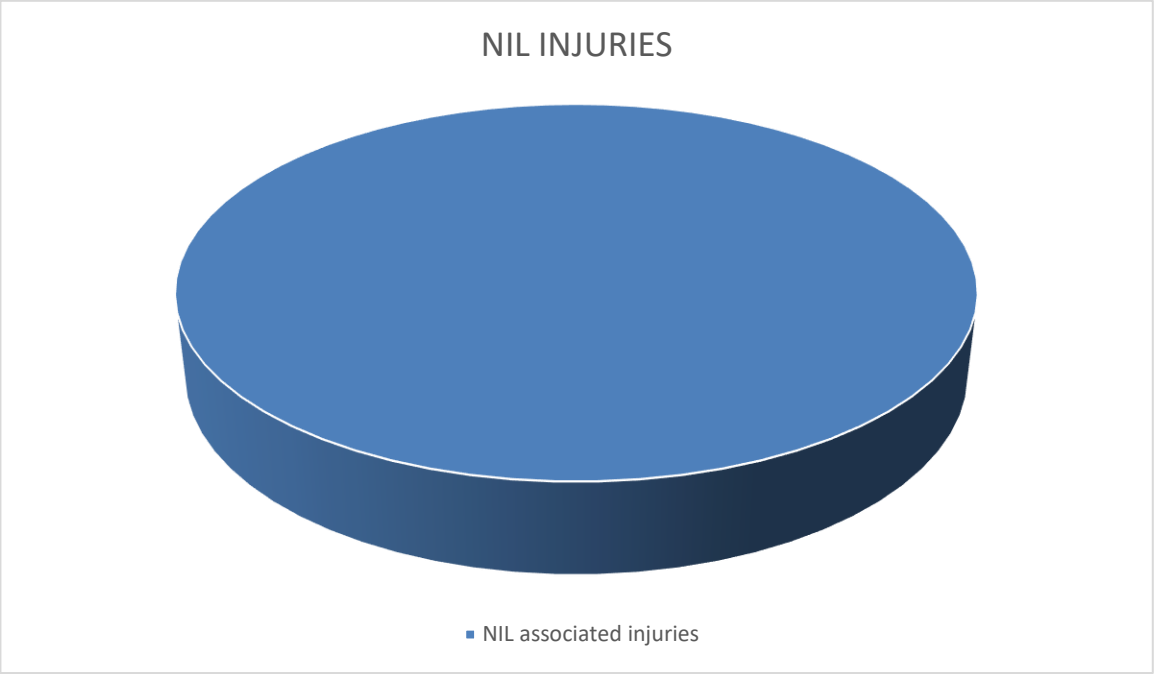

Distribution according to NEERS'S TYPE

Table No.7

S.NO	Type	No of cases	%
1	I	0	0
2	II	10	47.5%
3	III	9	42.8%
4	IV	2	9.5%
5	V	0	0

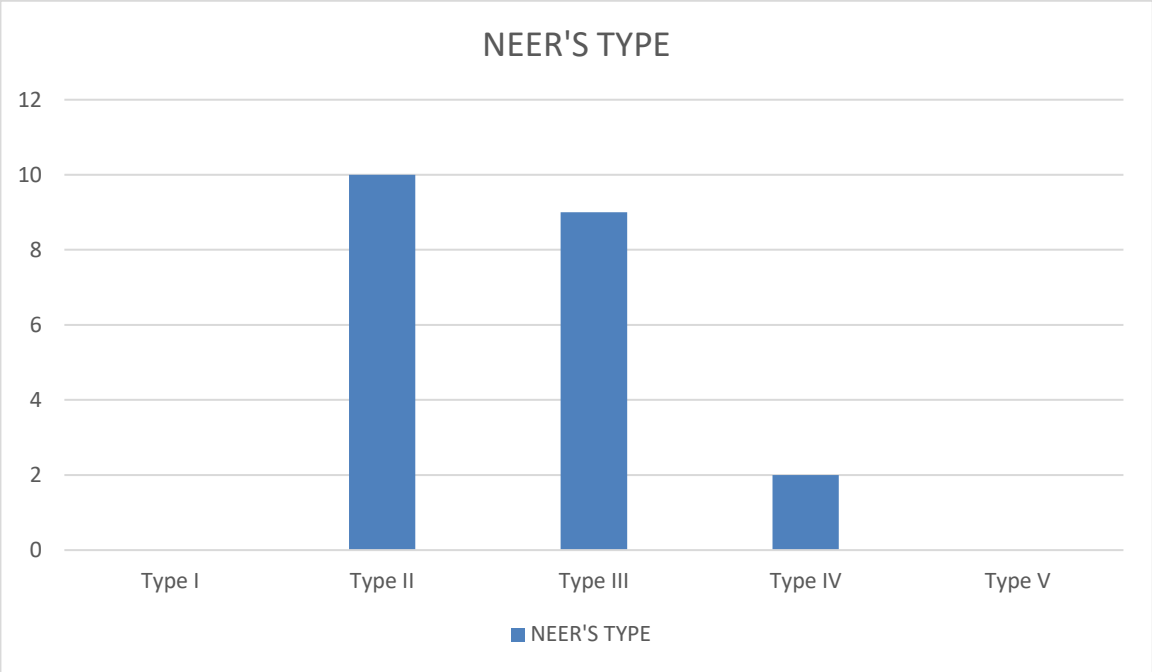

Distribution according to Fixation modalities

Table No.8

S.NO	Modalities	No of cases	%
1	LCP	20	95.2%
2	Screws	1	4.8%

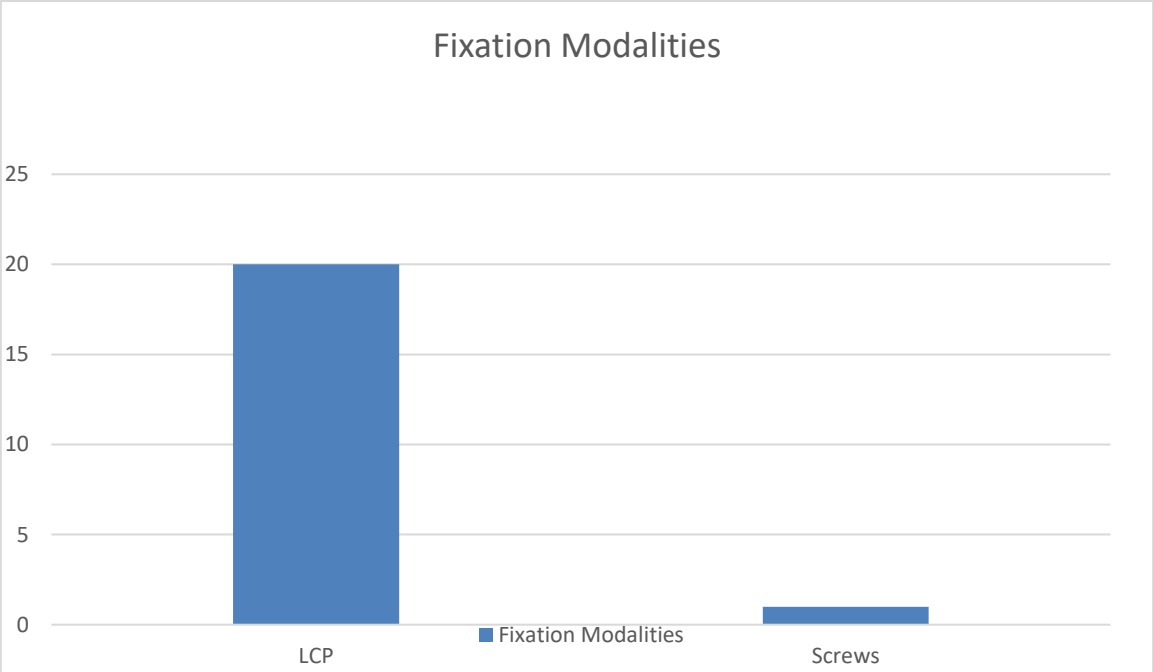

Distribution according to Complications

Table No.9

S.NO	Complications	Number	%
1	Stiffness	2	9.5%

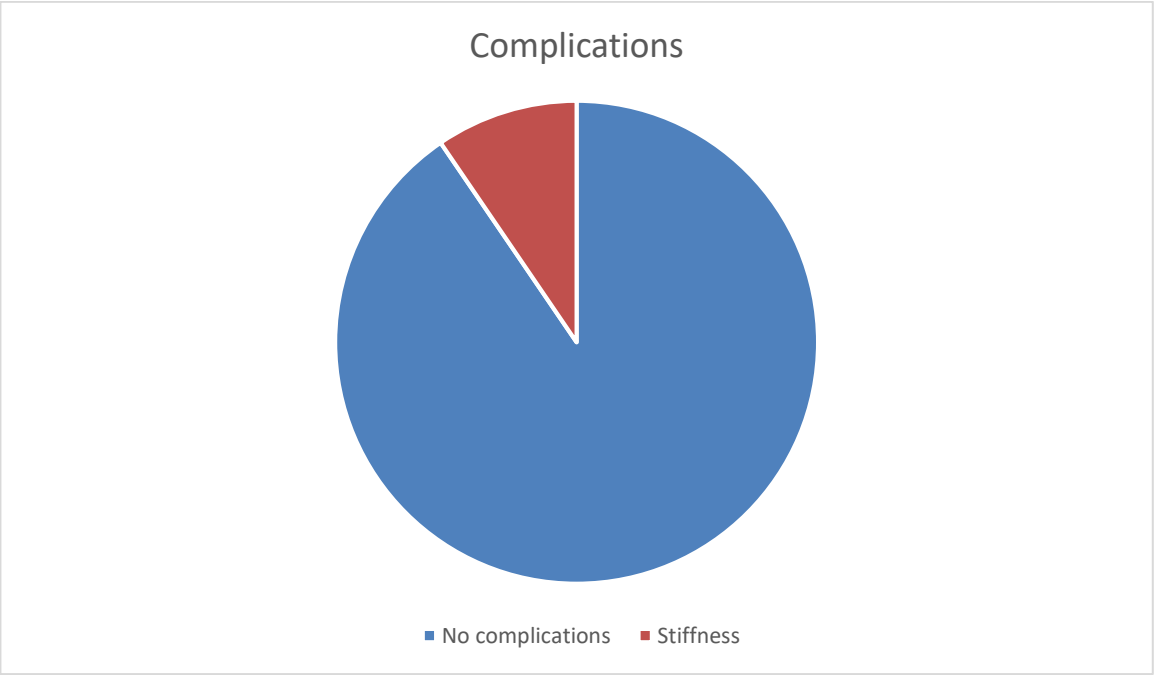

Distribution according to Functional Outcome

Table No.10

S.NO	Outcome	No of cases	%
1	Fair	2	9.5%
2	Good	11	52.3%
3	Excellent	8	38%

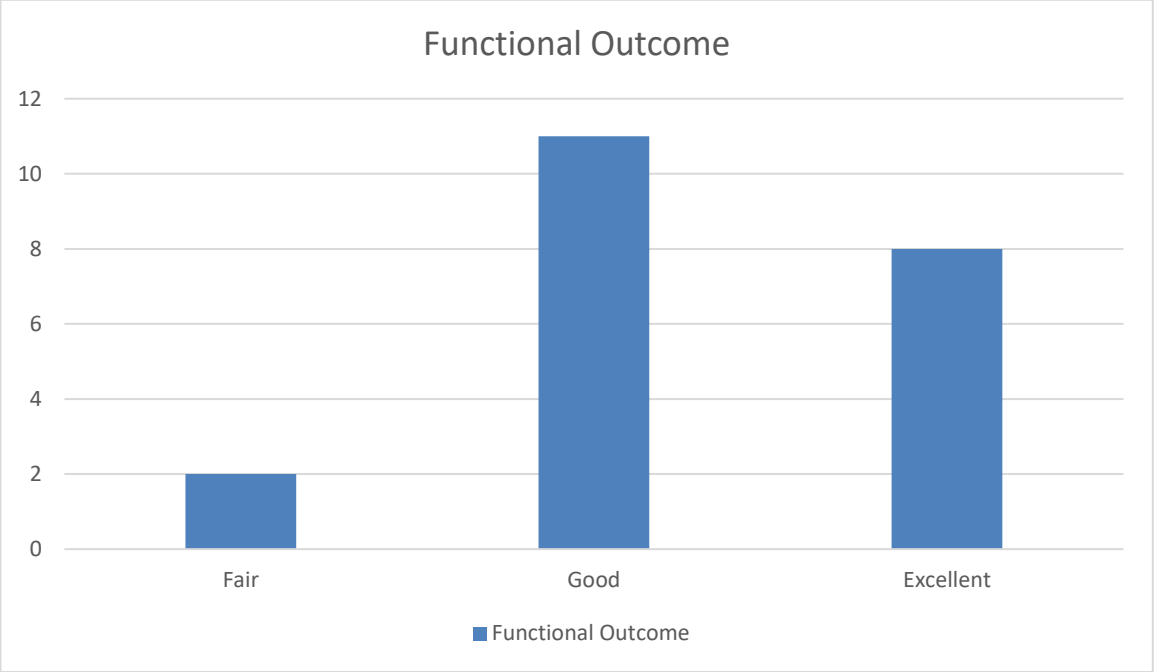

DISCUSSION

Proximal Humerus fractures are one of the commonest fractures associated with old age and osteoporosis. The management of these fractures become difficult and special because of these factors. In ancient times most of them were managed conservatively and resulted in satisfactory results in some and increased comorbidities in many. So treatment of proximal humerus is evolving in recent times. The fracture fixation methods has evolved from K-Wires to Locking Compression plates. The Deltoid splitting approach is also part of the new advances. The results of this approach is comparable with Deltopectoral approaches and has some advantages specific to this approach.

This approach is useful for nailing (A- and B-type fractures) and osteosynthesis of fractures of the greater tuberosity (A1.1). Gives easy and wide exposure of prox humerus. Provides better exposure for suturing of rotator cuff to LCP to prevent varus collapse.This approach is associated with low incidence of malreduction

This study is a prospective functional outcome analysis post fracture fixation of proximal humerus fractures using Deltoid splitting approach.The total patients were 21.All were evaluated clinically and radiologically and classified according to Neer's classification. All patients underwent fixation using Deltoid splitting approach.

The proximal humerus fractures are common in old age and osteoporotic bone. In our study the maximum patients were in 41-50 age group(33.3%). 28.5% each in both 31-40 and 61-70 years of age group.The average age for both sexes are different. The average age for male is 42.69 years and for female is 52.71 years. In our study there is wide distribution in age. The proximal humerus fracture is more common in Females than in males. In our study 13 patients were male (62%) and 8 (38%) patients were female.

The fractures are common in dominant side in most cases. In our study 11 patients has right sided injury and 10 has left sided injury. Almost equal distribution is observed. In our study we have noted that the proximal fractures in young adults occurs as a result of high energy trauma like Motor vehicle accidents and in older age group the cause is accident self fall.57% (12 patients) sustained injury due to Motor vehicle accidents and 43%(9patients) sustained injury due to self fall at home.The proximal humerus fractures are not usually associated with other injuries. In our research work also we have observed that none of the fractures are associated with other injuries.

In our study we have observed that there was no Neer's type I fractures. There were 10 patients who were classified as Type II accounted for 47.5%, 9 patients were classified as Type III accounted for 42.8% and 2 patients were classified as Type IV accounted for 9.5%. Worldwide, Locking compression plate is the preferred treatment of choice in all age groups[33]. We have fixed all fractures except one, with LCP. In one patient we have used Screw fixation. In 95.2% (20 patients) fracture was fixed with LCP and in 4.8% (one patient) fracture was fixed with Screws. In all cases Deltoid splitting approach was used.

In 2 cases we encountered shoulder stiffness in 2 as a complication. The stiffness gradually improved with aggressive rehabilitation and regular follow up.These patients were aged >60yrs, so rehabilitation is difficult. In our study we didn't encounter any Regimental batch of anesthesia (due to axillary nerve involvement) or Anterior deltoid weakness.

The functional outcome was measured using Constant Murley score at 6weeks,3 months and 6 months postoperatively. The score improved as aggressive rehabilitation progressed.2 patients (9.5%) had Fair functional outcome at 6 months. 11 patients (52.3%) has good functional outcome at 6months.8 patients (38%) had excellent functional outcome at 6 months.

The functional outcome mainly depends on age, type of fracture, approach used for

the fracture fixation, fracture reduction and rehabilitation. The two approaches for fracture fixation Deltopectoral and deltoid splitting have almost equal functional outcome.
The deltoid splitting approach is very good option for treating Neer's type 2,3,4 and repair of rotator cuff is also feasible. The disadvantage is that fracture dislocation is difficult to manage and it requires most of the time Deltopectoral approach. The complications associated with Deltoid splitting approach is minimal and incidence of malreduction is negligible. The repair of rotator cuff also adds to better outcome in this approach.

It is observed that young adults mostly males have better functional outcome than old age patients. Mostly because of early reporting to hospital, good bone stock, no comorbidities and good patient compliance in rehabilitation follow up. In old age group functional demands are less and they can well manage with an outcome of fair to good. The simpler the fracture pattern and early reduction using this approach gives excellent results. Type 2 and 3 are best to treat with this approach providing excellent results.

The importance of physical rehabilitation cannot be ignored. The strict rehabilitation protocol should be followed. Even if there is minor malreduction , with proper rehabilitation good functional outcome can be achieved.The patients who will develop stiffness during the course of treatment can be rehabilitated with aggressive physiotherapy.

There is no significant difference in clinical, radiographic, and functional outcomes between the deltopectoral approach and deltoid-splitting approach in surgical treatment of proximal humeral fracture.[38]The Deltoid splitting approach gives easy access to rotator cuff and the the LCP can be used like a suture plate by suturing to the rotator cuff. It aids in better reduction and prevents varus collapse.

INTRAOPERATIVE

Position

Landmarks

Incision

Incision extended

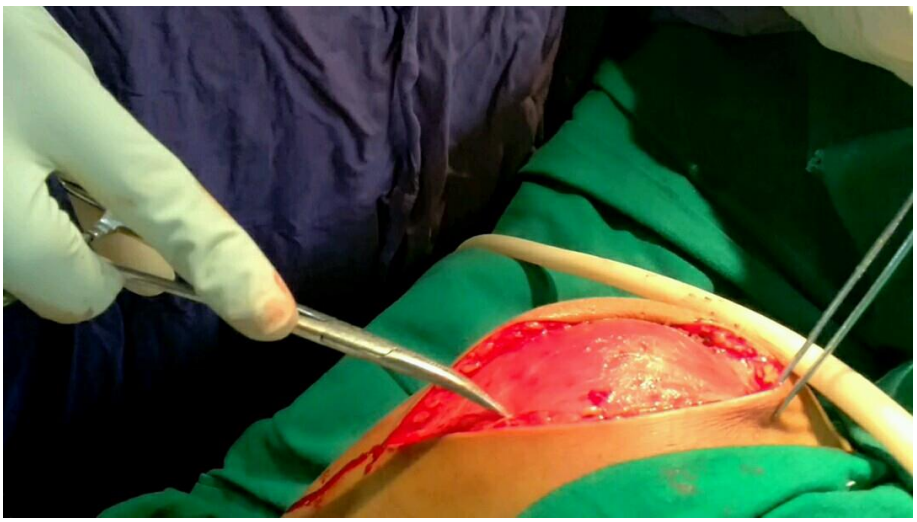

Splitting

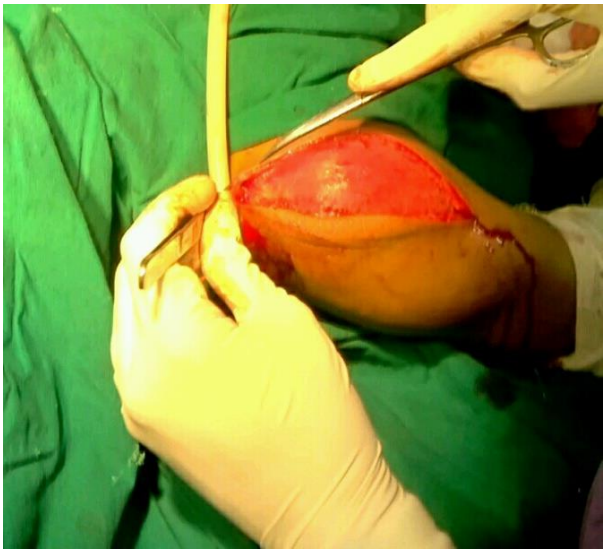

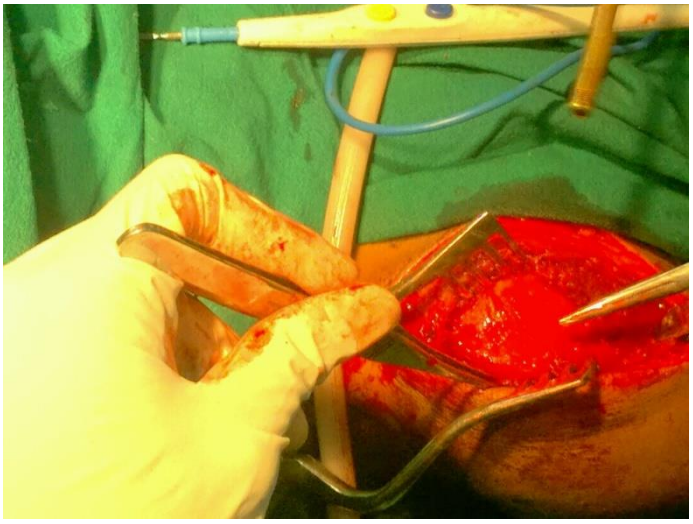

Splitting **Bursa**

Axillarynerve

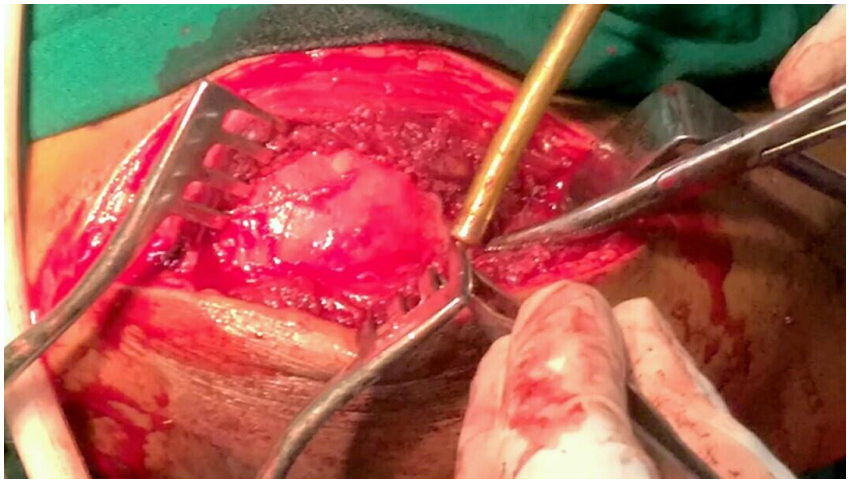

Fracture reduction

Plating

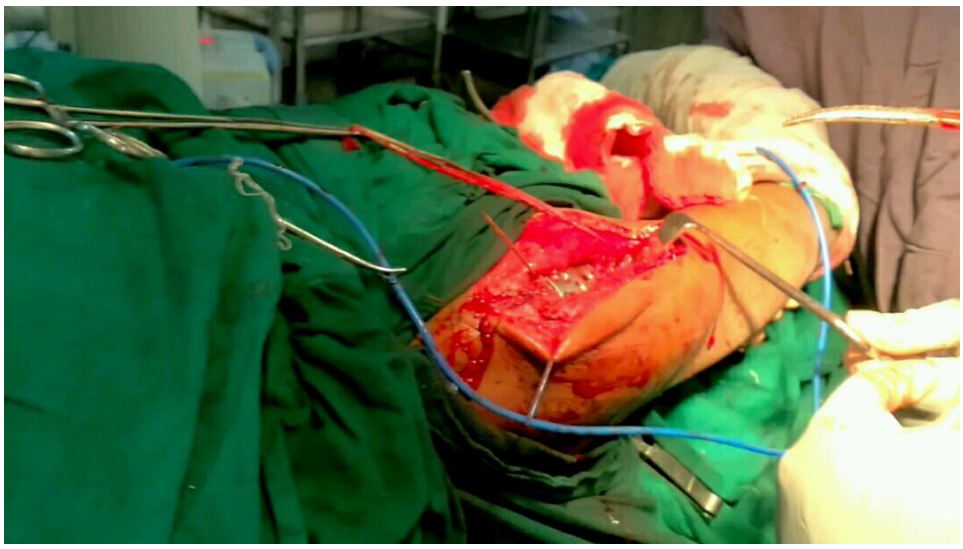

Final

Reduction

Final C-Arm Image

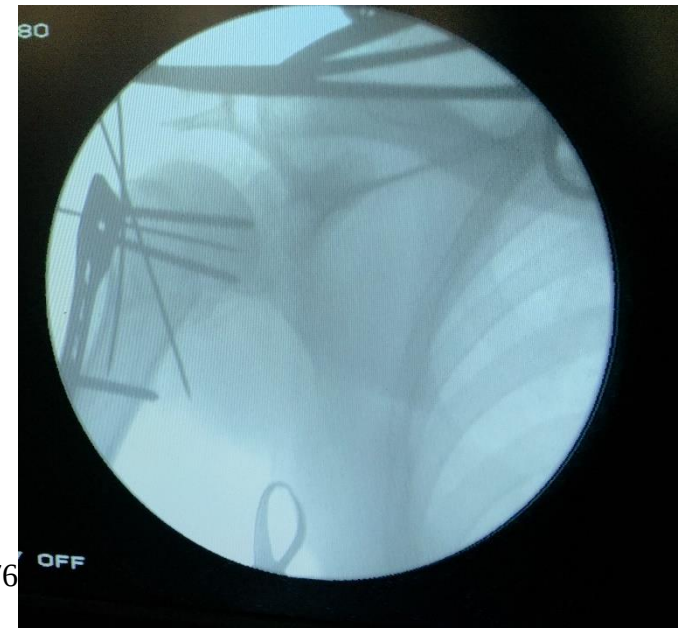

CASE -I

Pre Op X-Ray

-

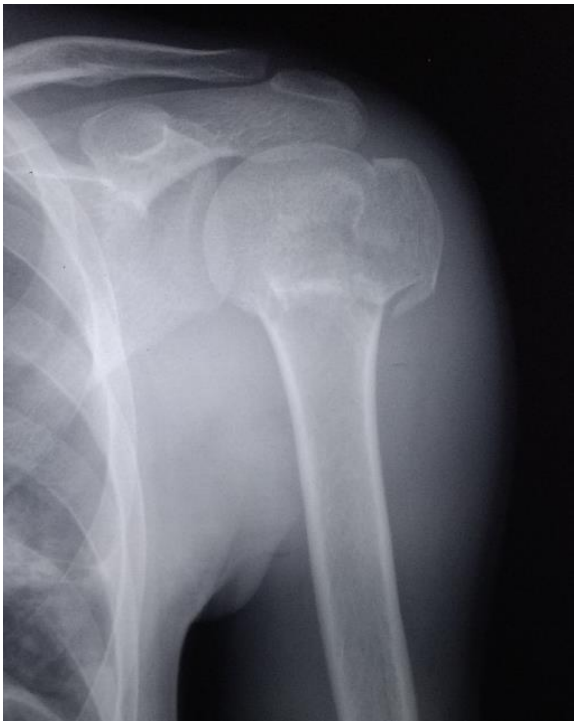

Post Op X-Ray

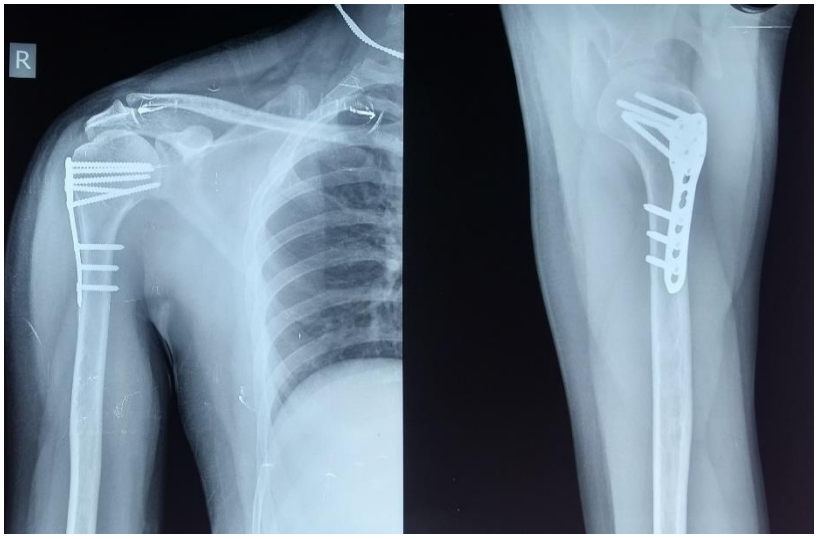

Clinical pictures



CASE – II

Pre Op X-Ray

Post Op X- Ray

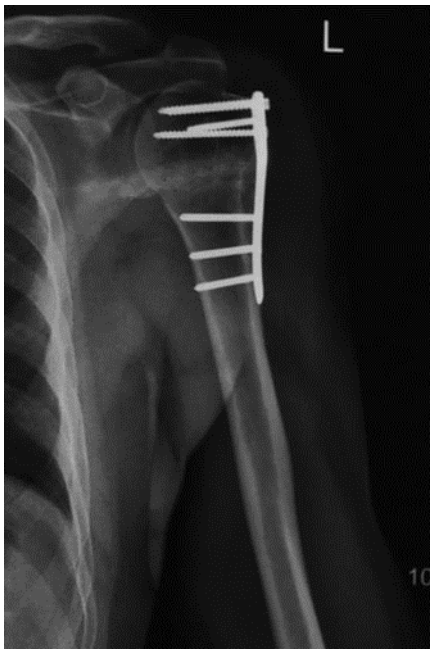

Clinical Pictures

CASE – III

Pre Op X-Ray

Post Op X-Ray

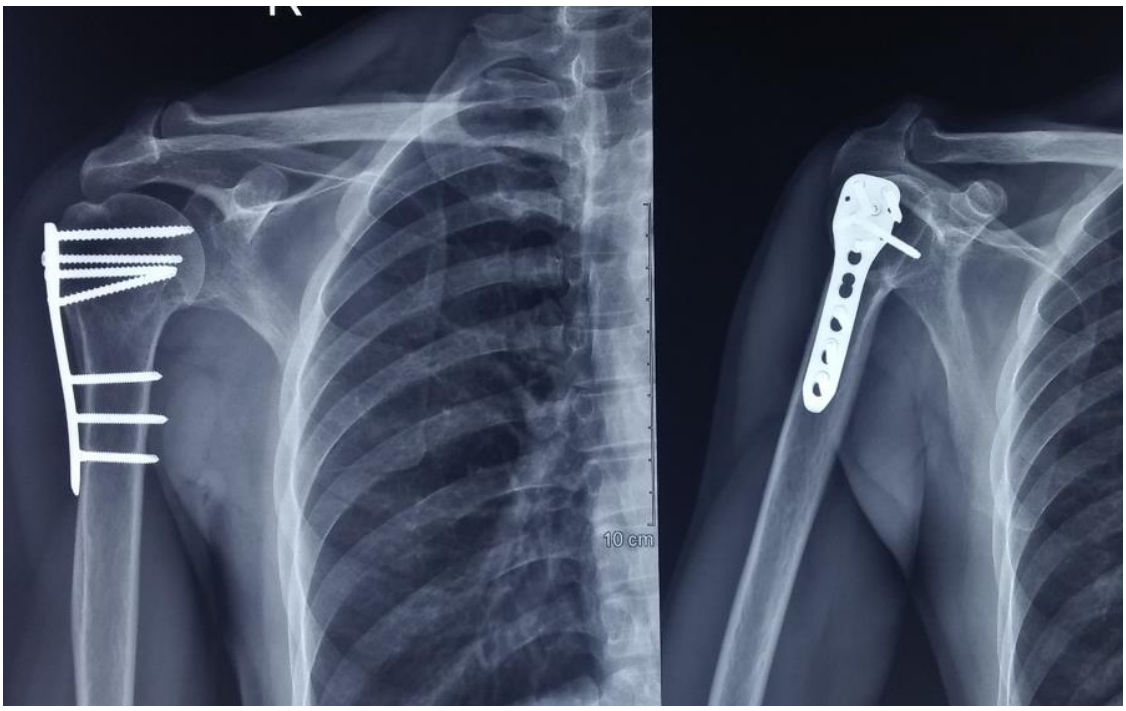

Clinical Pictures

CASE – IV

Pre Op X-Ray

Post Op X-Ray

Clinical pictures

CASE – V

Pre Op X-Ray

Post Op X-Ray

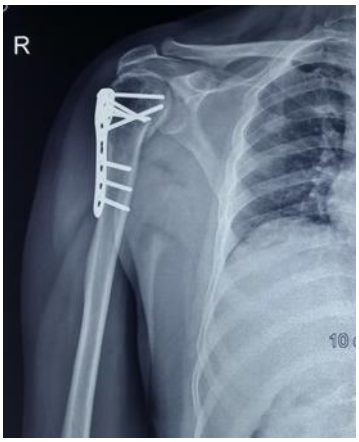

Clinical Pictures

CASE VI

Preop Xray

Postop Xray

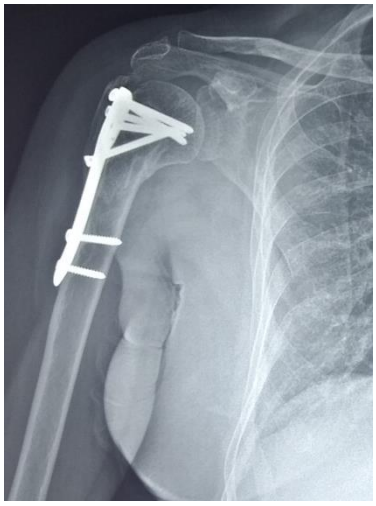

Clinical pictures

CONCLUSION

Deltoid splitting approach is an viable and easy approach for Proximal Humers fracture fixation. This approach is useful for nailing (A- and B-type fractures) and osteosynthesis of fractures of the greater tuberosity (A1.1). Gives easy and wide exposure of prox humerus. Provides better exposure for suturing of rotator cuff to LCP to prevent varus collapse.This approach is associated with low incidence of malreduction. In this study the Functional outcome is found to be good.

Bibliography

1.Campbell's Orthopaedic surgery 13th edition

2.Rockwood and Green's fractures in adults 8th edition

3.AO Manual of internal fixation 2nd edition

4. Lee SH, Dargent-Molina P, Breart G. Risk factors for fractures of the proximal humerus: results from the EPIDOS prospective study. J Bone Miner Res. 2002;17(5):817–825.

5. Horak J, Nilsson BE. Epidemiology of fracture of the upper end of the humerus. Clin Orthop Relat Res. 1975;(112):250–253.

6. Baron JA, Barrett JA, Karagas MR. The epidemiology of peripheral fractures. Bone. 1996;18(suppl 3):209S–213S.

7. Court-Brown CM, Garg A, McQueen MM. The epidemiology of proximal humeral fractures. Acta Orthop Scand. 2001;72(4):365–371.

8. Bell JE, Leung BC, Spratt KF, et al. Trends and variation in incidence, surgical treatment, and repeat surgery of proximal humeral fractures in the elderly. J Bone Joint Surg Am. 2011;93(2):121–131.

9. Court-Brown CM, Garg A, McQueen MM. The translated two-part fracture of the proximal humerus. Epidemiology and outcome in the older patient. J Bone Joint Surg Br. 2001;83(6):799–804.

10. Bell JE, Leung BC, Spratt KF, et al. Trends and variation in incidence, surgical treatment, and repeat surgery of proximal humeral fractures in the elderly. J Bone Joint Surg Am. 2011;93(2):121–131.

11. Chu SP, Kelsey JL, Keegan TH, et al. Risk factors for proximal humerus fracture. Am J Epidemiol. 2004;160(4):360–367

12. Lind T, Kroner K, Jensen J. The epidemiology of fractures of the proximal humerus. Arch Orthop Trauma Surg. 1989;108(5):285–287.

13. Olsson C, Nordqvist A, Petersson CJ. Increased fragility in patients with fracture of the proximal humerus: A case control study. Bone. 2004;34(6):1072–1077.

14. Allen JP. The art of medicine in Ancient Egypt. New York: The MetropolitanMuseum of Art, 2005.

15. Hippocrates. Oeuvres complètes d'Hippocrate (translation by É. Littré).Vol. 3. Paris: J.-B. Baillière, 1841.

16. Oribasii Collectionum Medicarum Reliqviae (ed. Ioannes Raeder). Vol.IV, 1933.

17. Albucasis. On surgery and instruments: a definitive edition of the Arabic text with English translation and commentary by M.S. Spink and G.LLewis. Berkeley: University of California Press, 1973.

18. Velpeau A. Nuveaux éléments de médicine opératoire, 5th ed. Paris,1840
19. Duverney M. The diseases of the bones (translated by Samuel Ingham).London: Tho. Osborne, 1762.

20. Cooper A. A treatise on dislocations; and on fractures of the joints (first published 1822), 2nd. ed. London, 1823.

21. Desault PJ, Chopart F. Traité des maladies chirurgicales. Vol. 1-2. Paris, 1796.

22. Thudichum L. Ueber die am oberen Ende des Humerus vorkommende Knochenbruche (dissertation). Giessen: J. Ricker'sche Buchandlung, 1851.

23. Kocher T. Beiträge zur Kenntniss einiger Praktisch wichtiger Fracturformen. Basel: Carl Sallmann, 1896.

24. Codman EA. The shoulder: rupture of the supraspinatus tendon and other lesions in or about the subacromial bursa. Malabar, Florida: Krieger, 1934.

25. Neer CS, Brown TH, Jr., Mclaughlin HL. Fracture of the neck of the humerus with dislocation of the head fragment. Am J Surg 1953; 85: 252-8.

26.BMC Musculoskelet Disord. 2017 Nov 28;18(1):495. doi: 10.1186/s12891-017-1840-6.
Influence of age, gender, and radiographic features on the deltoid splitting approach for surgical osteosynthesis in displaced proximal humerus fractures: a comparison study.
Chen A, Chiu C, Hsu , Chan .

27.Injury. 2017 Nov;48(11):2569-2574. doi: 10.1016/j.injury.2017.09.007. Epub 2017 Sep 8.
A modified deltoid splitting approach with axillary nerve bundle mobilization for proximal humeral fracture fixation. Shin YH1, Lee , Choi , Kim , Pyo , Baek .

28. J Clin Diagn Res. 2016 Aug;10(8):RC01-5. doi: 10.7860/JCDR/2016/18122.8281. Epub 2016 Aug Outcome Analysis of Locking Plate Fixation in Proximal Humerus Fracture. Vijayvargiya , Pathak , Gaur .

29.J Orthop Trauma. 2016 May;30(5):240-4. doi: 10.1097/BOT.0000000000000492.Is the Axillary Nerve at Risk During a Deltoid-Splitting Approach for Proximal Humerus Fractures?Traver , Guzman , Cannada , Kaar SG.

30. J Orthop Surg (Hong Kong). 2015 Aug;23(2):160-3.Minimally invasive plate osteosynthesis for proximal humeral fractures. Koljonen , Fang C, Lau T, Leung , Cheung .

31. Ulus Travma Acil Cerrahi Derg. 2015 Mar;21(2):113-8. doi: 10.5505/tjtes.2015.74150.
[Comparison of lateral deltoid splitting and deltopectoral approaches in the treatment of proximal humerus fractures].Korkmaz , Erdem , Karakaplan , Görmeli , Selçuk , Maraş, Karataş .

32.J Med Assoc Thai. 2014 Aug;97 Suppl 8:S27-33.The correlation between acromion-axillary nerve distance and upper arm length; a cadaveric study. Samart S, Apivatgaroon A, Lakchayapakorn K,Chemchujit B.

33. BMC Musculoskelet Disord. 2014 Jun 16;15:206. doi: 10.1186/1471-2474-15-206.Minimally invasive plate osteosynthesis with a locking compression plate is superior to open reduction and internal fixation in the management of the proximal humerus fractures.Lin T, Xiao B, Ma X, Fu , Yang S.

34. J Shoulder Elbow Surg. 2013 Aug;22(8):e1-7. doi: 10.1016/j.jse.2012.10.039. Epub 2013 Jan 16. Shoulder hemiarthroplasty for proximal humeral fractures: comparisons between the deltopectoral and anterolateral deltoid-splitting approaches. Chou Y, Tseng IC, Chiang CW, Wu CC.

35. Injury. 2013 Apr;44(4):481-7. doi: 10.1016/j.injury.2012.10.030. Epub 2012 Nov 27.Proximal humeral fractures: the role of calcium sulphate augmentation and extended deltoid splitting approachin internal fixation using locking plates.Somasundaram K1, Huber CP, Babu V, Zadeh H.

36. Unfallchirurg. 2013 Nov;116(11):1000-5. doi: 10.1007/s00113-012-2242-8.[Treatment ofproximal humerus fractures: relative position of different locking plates to the axillary nerve].Ninck J1, Heck S, Gick S, Koebke J, Pennig D, Dargel J.

37.Zhongguo Gu Shang. 2012 Feb;25(2):155-7.[Application of PHILOS plate through mini-opendeltoid-splitting approach for the treatment of proximal humeral fractures]. Zhao JP1, Hu WK, Zhang QL, Lin J, Zhou Q, He JJ, Zhuge TY.

38. J Trauma. 2011 Nov;71(5):1364-70. doi: 10.1097/TA.0b013e31820d165d. Locked plating forproximal humeral fractures: differences between the deltopectoral and deltoid-splitting approaches.

Wu CH1, Ma CH, Yeh JJ, Yen CY, Yu SW, Tu YK.

39. Injury. 2009 Feb;40(2):181-5. doi: 10.1016/j.injury.2008.05.031. Epub 2008 Dec 18.Assessment of axillary nerve function and functional outcome after fixation of complex proximalhumeral fractures using the extended deltoid-splitting approach.Khan LA1, Robinson CM, Will E,Whittaker R.

40.Int J Shoulder Surg. 2008 Jul;2(3):52-5. doi: 10.4103/0973-6042.42577.A contribution to the calculation of a safe deltoid split. Abhinav G1, Sivaraman B, Matthew N, Grahame J S T.

41. J Orthop Trauma. 2007 Oct;21(9):657-62.The extended deltoid-splitting approach to the proximalhumerus. Robinson CM1, Khan L, Akhtar A, Whittaker R.

42. Orthop Clin North Am. 2000 Jan;31(1):1-21.Two-part and three-part fractures: open reduction and internal fixation versus closed reduction and percutaneous pinning.Williams GR Jr1, Wong KL.

43. J Shoulder Elbow Surg. 2008 Jan-Feb;17(1):21-8. Epub 2007 Nov 1.The surgical approach for locking plate osteosynthesis of displaced proximal humeral fractures influences the functional outcome.Hepp P1, Theopold J, Voigt C, Engel T, Josten C, Lill H.

44. J Orthop Trauma. 2006 Oct;20(9):602-7.Vascular implications of minimally invasive plating of proximal humerus fractures. Gardner MJ1, Voos JE, Wanich T, Helfet DL, Lorich DG.

45. Zentralbl Chir. 2004 Jan;129(1):43-8. [The angle stable locking-proximal-humerus-plate (LPHP) for proximal humeral fractures using a small anterior-lateral-deltoid-splitting-approach - technique and first results]. Lill H1, Hepp P, Rose T, König K, Josten C.

46. Pearl ML, Volk AG. Coronal plane geometry of the proximal humerus relevant to prosthetic arthroplasty. J Shoulder Elbow Surg. 1996;5(4):320–326.

47. Iannotti JP, Gabriel JP, Schneck SL, et al. The normal glenohumeral relationships. An anatomical study of one hundred and forty shoulders. J Bone Joint Surg Am. 1992;74(4):491–500.

48. Gerber C, Schneeberger AG, Vinh TS. The arterial vascularization of the humeral head.

An anatomical study. J Bone Joint Surg Am. 1990;72(10):1486–1494.

49. Klepps S, Auerbach J, Calhon O, et al. A cadaveric study on the anatomy of the deltoid insertion and its relationship to the deltopectoral approach to the proximal humerus. J Shoulder Elbow Surg. 2004;13(3):322–327.

50. Burkhead WZ Jr, Scheinberg RR, Box G. Surgical anatomy of the axillary nerve. J Shoulder Elbow Surg. 1992;1(1):31–36.

51. Gardner MJ, Griffith MH, Dines JS, et al. The extended anterolateral acromial approach allows minimally invasive access to the proximal humerus. Clin Orthop Relat Res. 2005;(434):123–129.

52. Clavert P, Lutz JC, Wolfram-Gabel R, et al. Relationships of the musculocutaneous nerve and the coracobrachialis during coracoid abutment procedure (Latarjet procedure). Surg Radiol Anat. 2009;31(1):49–53.

53. Court-Brown CM, Garg A, McQueen MM. The epidemiology of proximal humeral fractures. Acta Orthop Scand. 2001;72(4):365–371.

54.Predictors of humeral head ischemia : Hertel R. Hertel, A. Hempfing, M. Stiehler, M. Leunig. JSES, Volume 13, 2004, Pages 427-433

55. Constant CR, Murley AH. A clinical method of functional assessment of the shoulder. Clin Orthop Relat Res 1987 Jan;214(214):160-164

CASE PROFORMA

CASE NO :

NAME: FATHER'S NAME:

AGE: SEX: I.P.NO: WARD:

OCCUPATION: RELIGION: CONTACT NO:

ADDRESS:

PARTICULARS OF INJURY

DATE OF INJURY : DATE OF ADMISSION:

DATE OF PRE ANAESTHETIC CHECKUP: DATE OF SURGERY:

DATE OF DISCHARGE:

HISTORY:

TYPE OF INJURY: CLOSED/OPEN

SIDE OF INJURY: RIGHT/LEFT/BOTH

MODE OF INJURY:

ASSOCIATED INJURY:

COMORBIDITY:

DIAGNOSIS & CLASSIFICATION:

PREOPERATIVE TREATMENT:

DEATAILS OF OPERATIVE PROCEDURE:

POST OPERATIVE CARE:

FOLLOW-UP

PHYSIOTHERAPY ADVISED:

TIME OF ACTIVITY:

PARTIAL:

FULL:

FUNCTION AT

6 WEEKS

3 MONTHS:

6 MONTHS:

GOVT.STANLEY MEDICAL COLLEGE, CHENNAI- 600 001

INFORMED CONSENT

DISSERTATION TOPIC:

"STUDY OF FUNCTIONAL OUTCOME IN PROX HUMERUS FRACTURE FIXATION USING DELTOID SPLITTING APPROACH"

PLACE OF STUDY: GOVT. STANLEY MEDICAL COLLEGE, CHENNAI
NAME AND ADDRESS OF PATIENT:

I, _____ have been informed about the details of the study in my own language.

I have completely understood the details of the study.

I am aware of the possible risks and benefits, while taking part in the study.

I understand that I can withdraw from the study at any point of time and even then, I will continue to receive the medical treatment as usual.
I understand that I will not get any payment for taking part in this study.

I will not object if the results of this study are getting published in any medical journal, provided my personal identity is not revealed.

I know what I am supposed to do by taking part in this study and I assure that I would extend my full co-operation for this study.

Name and Address of the Volunteer:

Signature/Thumb impression of the Volunteer
Date:

Witnesses:
(Signature, Name & Address)
Date:

Name and signature of investigator: (Dr.(Maj) Parthasarathy S)

GOVT.STANLEY MEDICAL COLLEGE, CHENNAI- 600 001

INFORMED CONSENT

DISSERTATION TOPIC:

‘‘*STUDY OF FUNCTIONAL OUTCOME IN PROX HUMERUS FRACTURE FIXATION USING DELTOID SPLITTING APPROACH*’’

PLACE OF STUDY: GOVT. STANLEY MEDICAL COLLEGE, CHENNAI

NAME AND ADDRESS OF PATIENT:

நான், _____ எனது சொந்த மொழியில் ஆய்வு விவரங்களை பற்றி தெரிவிக்கப்பட்டது.

நான் முற்றிலும் ஆய்வு விவரங்களை புரிந்து கொண்டேன்.

ஆய்வு பங்கெடுத்துக்கொண்டுள்ள நான், சாத்தியமான அபாயங்கள் மற்றும் பயன்களை அறிந்து இருக்கிறேன்.

நான் எந்த நேரத்திலும் ஆய்வு இருந்து திரும்ப முடியும் மற்றும் அதன் பின்னர், நான் வழக்கம் போல் மருத்துவ சிகிச்சை பெற தொடரும் என்று புரிந்து கொள்ள.

நான் இந்த ஆய்வில் பங்கு எடுத்து எந்த பணம் பெற முடியாது என்று புரிந்து.

நான் ஆட்சேபிக்கிறேன் மாட்டேன் இந்த ஆய்வின் முடிவு, எந்த மருத்துவ இதழில் கிடைக்கும் என்றால், என் தனிப்பட்ட அடையாள வெளிப்படவில்லை வழங்கப்படும்.

நான் இந்த ஆய்வு பகுதியாக எடுத்து செய்ய வேண்டும் என்று எனக்கு நான் இந்த ஆய்வு என் முழு ஒத்துழைப்பு நீட்டிக்க என்று உறுதியளிக்கிறேன்.

பெயர் மற்றும் தொண்டர் முகவரி:

தொண்டர் கையொப்பம் / பெருவிரல் ரேகை

நாள்:

சாட்சிகள்:

(கையொப்பம், பெயர் மற்றும் முகவரி)

நாள்:

பெயர் மற்றும் புலன்விசாரணை கையொப்பம்: (Dr(Maj) Parthasarathy S)