"CHALLENGES IN COCHLEAR IMPLANT SURGERY AND POST OPERATIVE FOLLOW - UP"

Dissertation Submitted to

THE TAMILNADU DR. M.G.R. MEDICAL UNIVERSITY

Dissertation submitted in partial fulfillment of the regulations for the award of the degree of

M.S.DEGREE BRANCH – IV
OTORHINOLARYNGOLOGY

UPGRADED INSTITUTE OF OTORHINOLARYNGOLOGY
MADRAS MEDICAL COLLEGE
CHENNAI – 600003

THE TAMILNADU DR. M.G.R. MEDICAL UNIVERSITY
CHENNAI

MAY 2019

DECLARATION

I solemnly declare that the dissertation **"CHALLENGES IN COCHLEAR IMPLANT SURGERY AND POST OPERATIVE FOLLOW - UP "** is done by me at the Upgraded Institute of Otorhinolaryngology, Madras Medical College and Government General Hospital, Chennai during September 2016 – August 2018 under the guidance and supervision of **Prof.Dr.R.MUTHUKUMAR., MS, DLO., DNB.,** This dissertation is submitted to The Tamil Nadu Dr. M.G.R. Medical University, towards partial fulfillment of rules and regulations for the award of M.S. DEGREE IN OTORHINOLARYNGOLOGY (BRANCH - IV)

Dr. M.KALAI
M.S. E.N.T. Postgraduate,
Upgraded Institute of Otorhinolaryngology,
Madras Medical College, Chennai.

Place :
Date :

BONAFIDE CERTIFICATE

This is to certify that this dissertation entailed "**CHALLENGES IN COCHLEAR IMPLANT SURGERY AND POST OPERATIVE FOLLOW - UP",** submitted by **Dr. M. KALAI,** appearing for M.S. ENT., (Branch IV) Degree examination in May 2019, is a bonafide record of the work done by her under my direct guidance and supervision in partial fulfillment of rules and regulations of the Tamil Nadu Dr. M.G.R. Medical University , Chennai , Tamil Nadu, India.

Prof. Dr.R.Muthukumar, MS., DLO., DNB
Director
Upgraded Institute of Otorhinolaryngology,
Madras Medical College,
Rajiv Gandhi Govt. General Hospital,
Chennai-600003.

Dr.R.Jayanthi, MD., FRCP.,
Dean,
Madras Medical College,
Rajiv Gandhi Govt. General Hospital,
Chennai-600003.

PLAGIARISM CERTIFICATE

This is to certify that this dissertation work titled **"CHALLENGES IN COCHLEAR IMPLANT SURGERY AND POST OPERATIVE FOLLOW - UP"** of the candidate Dr.M.Kalai with registration number 221614004 for the award of M.S. Degree in the branch of Otorhinolaryngology. I personally verified the urkund.com website for the purpose of plagiarism check. I found that the uploaded thesis file contains from the introduction to conclusion pages and result shows 6% percentage of plagiarism in the dissertation.

Prof. Dr.R.Muthukumar, MS., DLO., DNB
Director
Upgraded Institute of Otorhinolaryngology,
Madras Medical College,
Rajiv Gandhi Govt. General Hospital,
Chennai-600003.

ACKNOWLEDGEMENT

I would like to acknowledge with sincere gratitude to the great people who have made it possible for my successful completion of the thesis.

I would like to express my sincere gratitude to **Prof.Dr.JAYANTHI, M.D.,** the DEAN, Madras Medical College, for having permitted me to use the hospital material in this study.

I would like to thank **Prof.Dr.R.MUTHUKUMAR, M.S. D.L.O. D.N.B.,** The Director and Professor, Upgraded Institute of Otorhinolaryngology, and also my guide for the study. I am deeply indebted to my guide for giving me support in choosing the topic and for scholarly guidance in the conduct of the study. I am thankful to him for the supervision, constant encouragement, mental support and constructive suggestions at every stage of the study, which helped me to complete the study. I express my heartfelt gratitude for his painstaking efforts in completion of the study in a better way.

I am grateful to **PROF.DR.N.SURESH KUMAR MS., DLO.**, Upgraded Institute of Otorhinolaryngology, for the encouragement and support all through my study under his guidance and support during the conduction of the study.

I am greatly indebted to **Prof.DR.M.N.SANKAR, MS. DLO., PROF.DR.F.ANTONY IRUDHAYARAJAN MS., DLO.,** Professor, Upgraded Institute of Otorhinolaryngology, for his valuable support and guidance during the study.

I am greatful to my co-guide, **DR.K.SEMMANASELAN, MS DLO.,** Assistant Professor, for his valuable support, guidance and resources provided to the study and technical support related to the study.

I express my sincere thanks to all the Assistant Professors**,** **Dr.S.SHENBAGAVALLI, DR.PRAVEEN KUMAR.J, DR.VIVEK .M** , for their thoughtful guidance throughout the work.

I thank the Secretary and Chairman of Institutional Ethical Committee, Government General Hospital and Madras Medical College, Chennai.

I also thank **Dr.Nithya, Dr.Janarthanam** my colleagues and other post graduates, audiologist mrs.johnsy, for their valuable suggestions and helpfulness in the study.

I am thankful to all the staff members in the department of ENT& audiology for the help provided in the completion of the study.

I am very grateful to my mother, my sister,my uncle, for standing with me all the time and for the mental support and encouragement in the completion of the study.

I express my sincere thanks to my mother, **Mrs.M.Malasri**, for helping in completing the study in a better way and also in standing with me during the difficult times.

Finally and most importantly without the support and consent of the study participants, it would have been a futile exercise. I am thankful to all the study participants and their parents for giving consent, study related information and co-operating with the study procedures.

Above all I thank God Almighty for his immense blessings.

Dr. M.Kalai

INDEX

INTRODUCTION

In last quarter of 20th century cochlear implantation gained widespread acceptance all around the world with advancement in technology and surgical experience for rehabilitation of profound to severe bilateral sensory neural hearing loss. Cochlear implant surgery stands high in position because of its ability to restore one of the special senses. Congenital severe to profound hearing loss limits the child ability to develop communication skills by affecting auditory and linguistic development. Cochlear Implantation provides greater access to sound, speech understanding, auditory abilities and linguistic development. Cochlear implant has evolved from single channel electrode to complex multichannel electrode, this provides near normal understanding of speech and in some cases, enjoyment of music. Challenges in cochlear implant surgery starts from pre-operative evaluation of the child. Pre-operative evaluation should include hearing assessment (brainstem evoked response audiometry, oto acoustic emissions, impedance audiometry) radiological assessment (HRCT Temporal bone with cochlear cuts, MRI Brain with internal acoustic meatus screening), general/systemic examination, pediatrician, psychologist, cardiologist, ophthalmologist opinion, evaluation of causes of hearing loss, rule out syndromic causes preoperatively to plan for effective management during surgery or post operatively. since the

introduction of high-risk newborn hearing screening as a routine procedure detection of hearing loss in early life and early rehabilitation with implantation in severe – profound hearing loss has improved more compared to previous decades. Cochlear implant surgery is a technically demanding surgery in which every step of surgery should be precise. As like any other surgery cochlear implant surgery also has its own challenges because of increasing number of surgeries by newer surgeons who are in learning curve. Although number and severity of complications were reduced with experience, avoidance of this challenges during surgery and post-operative period was the main objective for each implant surgeon. Post-operative device programming is difficult in pediatric patients, it is important that the thresholds are accurate and the device set at comfortable levels for optimal functioning of the implant. The purpose of this study is to evaluate the major and minor challenges during surgery and post-operative period & how to overcome all those challenges were highlighted.

AIMS AND OBJECTIVES

1) To establish & discuss the intra & post-operative challenges of cochlear implant surgery.

2) Methods to avoid those challenges.

3) Methods to manage those challenges.

INCLUSION CRITERIA

- Children aged between 1-12 years
- Both sexes (female and male)
- Bilateral profound sensory-neural hearing loss with no response in BERA
- No appreciable benefit with hearing aid
- No medical or anatomic contraindications
- Motivated parents for cochlear implant surgery & Willingness to comply with follow-up procedure

EXCLUSION CRITERIA

- Age below 6 months and above 12 years
- Children with cochlear nerve aplasia and central auditory lesion
- Child with active ear disease
- Children with mental and behavioural disorders

SAMPLING AND SAMPLE SIZE

- Non-probability (Convenient) sampling was used for the study. The children admitted for cochlear implant surgery at the institute was selected consequently, who satisfy the inclusion criteria

- A total of 250 children were included in this study.

INNER EAR

EMBRYOLOGY OF INNER EAR

The inner ear development is independent from external & middle ear, they are connected by stapes supra structure. The development of labyrinth starts first with membranous labyrinth development followed by bony labyrinth.

The inner ear is derived from a pair of surface sensory placodes (otic placodes) that appear during 4th week of intrauterine life in the head region behind the second pharyngeal arch.

This otic placodes folding inwards from surface forms depression initially, then entirely separated from surface forming a fluid filled vesicle/sac (otic vesicle) that is surrounded by epithelium.

The vesicle sinks into mesenchyme, some parts of which closely surrounds oto cyst forms otic capsule.

The oto cyst finally lies close to developing vestibulo-cochlear-facial ganglion complex and developing hind brain. Oto cyst will

differentiate to form components of the membraneous labyrinth. The organ of corti forms initially from the central domain on the medial side of the oto cyst. Sox 2 regulates organ of corti development through Jag1 (notch ligand signaling).

The membraneous labyrinth is formed from the otic vesicle, it is the first part of ear to make its appearance, by 6th week of embryonic life.

3 semicircular canals are well formed with ampullated expansions and crus commune. At this stage, dependent portion of vesicle elongated as cochlear pouch and assumes like snail-shell coil. At the end of 1st month inner ear exhibits only an endolymphatic space. The 1st perilymphatic space is form within the oval window, in the vestibule, cisterna peri lymphatica. The 2nd perilymphatic space form with in round window, this is the Scala tympani. Scala vestibuli appears as an extension from cisterna peri lymphatica in the basal portion of cochlea. The aqueductus cochlea develops as an out-pouch from sub arachnoid space.

The formation of vestibular end-organs advances more rapidly than cochlear end organs, hairs appears early on vestibular end organ than cochlear end organ. At 7th week macula develops from utricular and saccular epithelium at the points where the nerves enter their walls. By 12th week hair cells and supporting cells can be differentiated. Between 14th – 16th weeks otoconia has appeared in gelatinous layer.

The epithelium of cochlear duct begins to differentiate in the basal turn at 8th week, followed by middle and apical turns, Organ of corti and tectorial membrane are recognizable in the basal turns by 12th week, hair cells and supporting cells differentiated by 12th week. Tunnel of corti formed at 15th week. The inner ear is the only organ that reaches full adult size and complete differentiation by mid-term, even before fetus attains its viability.

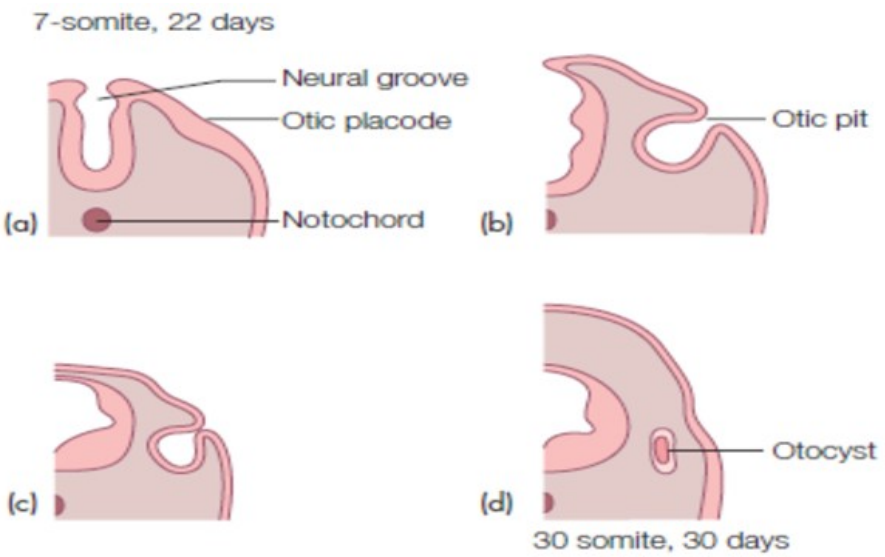

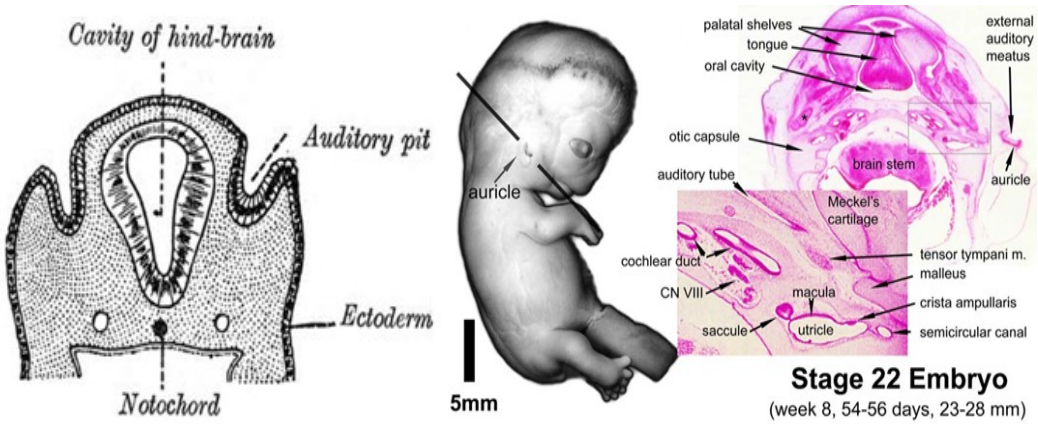

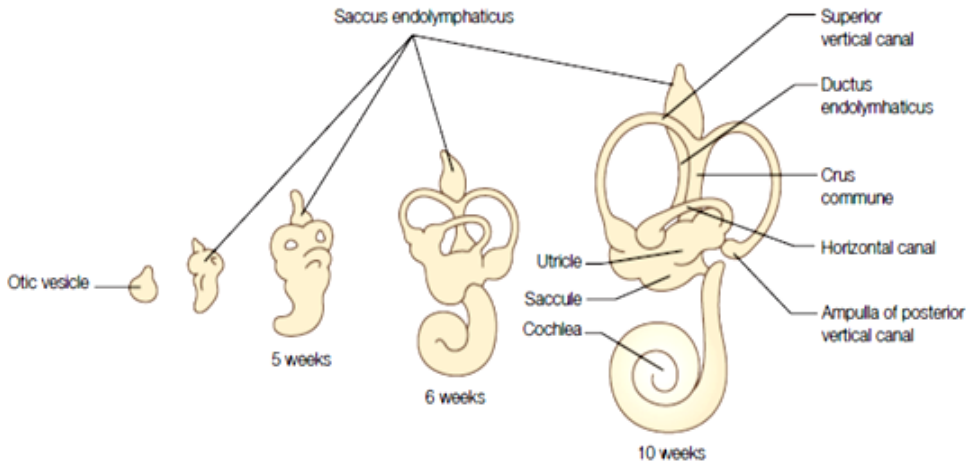

BONY LABYRINTH

Develops from the otic capsule. This is a mesenchymal condensation surrounding the membranous labyrinth, the mesoderm changes to pre-cartilage to true cartilage. Membranous labyrinth is embedded in a cartilaginous ear capsule at the end of 2nd month of intra uterine life. This becomes dedifferentiated and by the process of incrustation otic capsule forms by 5th month of intra uterine life

ANATOMY OF INNER EAR

BONY LABYRINTH

The bony labyrinth comprises the vestibule, semicircular canals, and the cochlea, bone is trilaminar,

1) Inner endosteal layer

2) Outer periosteal layer

3) Mixed layer of intrachondral and endochondral bone, characterized by globuli interossei

Central chamber of bony labyrinth is called the vestibule, it has recess like elliptical recess which houses utricle, spherical recess which houses saccule, and the cochlear recess which houses basal end of cochlear duct.

The Cochlea is a bony spiral that has 2.5 – 2.75 turns round a central pyramid called modiolus, base of modiolus directed towards IAC and transmits nerves to cochlea, thin plate of bone called osseous spiral lamina which winds around modiolus and it divides bony cochlea.

Bony cochlea contains 3 compartments those are scala vestibuli, scala tympani, scala media. scala tympani and Scala vestibuli filled with perilymph and through helicotrema both communicate with each other.

Scala vestibuli is closed by footplate of stapes, it separates it from middle ear, scala tympani is closed by secondary tympanic membrane, it is also connected with aqueduct of cochlea to subarachnoid space.

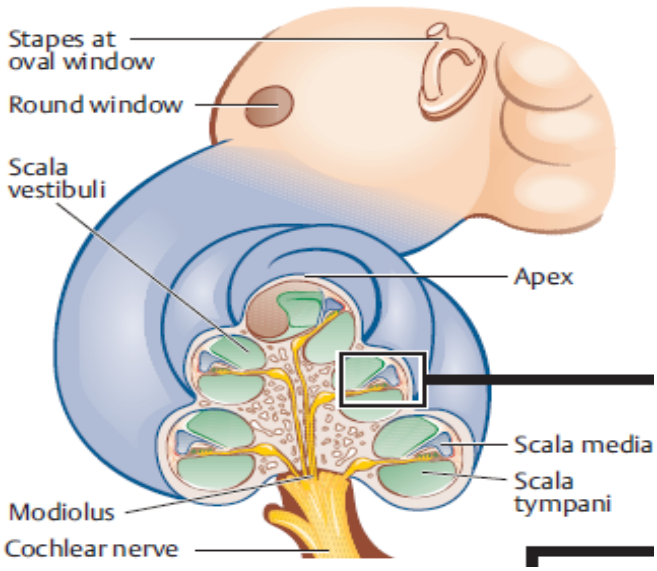

There are 3 semicircular canals: the lateral (horizontal), posterior and superior (anterior vertical). Non ampullated ends of the posterior and superior canals fuse to form the crus commune, ampullated end of each duct contains crista ampullaris (neurosensory epithelium). All 5 opens into the vestibule.

MEMBRANOUS LABYRINTH

The membranous labyrinth, consisting of

1) Cochlear duct,

2) Three semicircular ducts and their ampullae,

3) Otolithic organs (the utricle and the saccule), and the

4) endolymphatic duct and sac

COCHLEAR DUCT

Also called scala media/membranous cochlea, it occupies mid portion of cochlear canal, it is triangular in cross section. It has 3 walls

1) Basilar membrane supports the organ of corti.

2) Stria vascularis – concerned with endolymph secretions.

3) Reissner's membrane, it separates cochlear duct from scala vestibuli.

The membranous labyrinth is filled with endolymph. Thinner inner part of basilar membrane is called zona arcuata, Thicker outer part is zona pectinata.

Organ of corti is spread like ribbon along the entire basilar membrane. It has tunnel of corti, it composed of two rows of inner and outer hair cells. Tunnel of corti forms triangle with the basilar membrane it is filled with cortilymph.

Inner hair cells are 3500 (one row) in number, Outer hair cells are 12000 (3or 4 rows) in number. As age advances generalized reduction in number of hair cells. Hair cells are supported by Pillar cells, Hensen's cells, Deiter's cells. Tips of outer hair cells are attached to the undersurface of tectorial membrane.

Saccule is connected to the cochlear labyrinth by the membranous cochlear reuniens. saccule and utricle connected with each other through endolymphatic duct. Utricle is bigger in size than saccule. posterior wall of utricle has 5 openings of semicircular canals.

Macula – vestibular receptor organ of the saccule and utricle. Macula of saccule lies vertically, in utricle it lies horizontally. These macula composed of hair cells, supporting cells, and gelatinous mass. Gelatinous mass (Statoconial membrane) is composed of muco polysaccharides, and otolith/statoconia (calcium carbonate crystals).

Membraneous Semicircular canal occupies bony semicircular canals. Ampullated end of semicircular canal accommodates the specialized vestibular epithelium called crista. These cristae also have supporting cells, hair cells, and gelatinous mass (cupula).

The hair cells are of 2 types

Type 1 – are flask shaped with nerve chalice, these cells seen in the summit of the cristae.

Type 2 – are cylindrical with no nerve chalice. found more towards the periphery in the cristae.

The hair cells consists of many stereocilia (smaller) and one kinocilium (which is tall and prominent). A curve line called striola divides each macula into medial and lateral halves.

The endolymphatic sac lies about 10 mm posterolateral to the porus of the internal auditory canal in a slight depression called the endolymphatic fossette. The endolymphatic duct runs from the posterior wall of the saccule and joins the utriculosaccular duct, and passes along with the vestibular aqueduct ends in endolymphatic sac.

INTERNAL AUDITORY CANAL

The internal auditory canal, is an osseous channel within the petrous part of temporal bone between inner ear and posterior cranial fossa dura that is traversed by the superior and inferior vestibular

nerves, cochlear nerve, facial nerve, and nervus intermedius, as well as the labyrinthine artery and vein.

THE AUDITORY NERVE

The rudiment of 8th cranial nerve appears as auditory ganglion at 4th week. At first it fuses with 7th nerve cranial nerve and later separate. The cells of ganglion derived from neural crest and neuro ectoderm of auditory vesicle. The auditory ganglion divides into a vestibular and a cochlear part, associated with division of 8th nerve. By 7th week cochlear nerve has its main characteristics (twisting fibers), at 8th week spiral ganglion recognizable. At 12th week spiral ganglion and cochlear nerve have linked up with their sensory end organ.

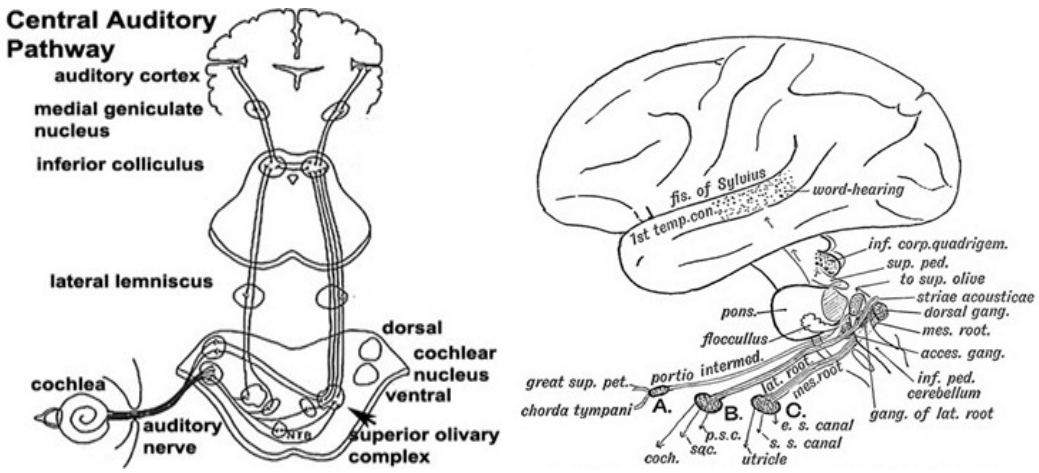

HEARING LOSS

Hearing impairment is the most common sensory deficit affecting human populations, All ages from infancy to older age groups. According to World Health Organization (WHO) [2] estimates, 360 million people – living with hearing loss, this constitutes about 5.3% of

the world population. Among them, 328 million (91%) are adults and 32 million (9%) are children.]

In India burden of hearing impairment is high. In India approximately 63 million (6.3%) people were suffering from moderate to severe hearing impairment. The prevalence of adult onset and childhood onset deafness is estimated to be 7.6% and 2.00% respectively, Hearing disability is the second frequent cause of disability in India, the incidence being 7/100000 population. The prevalence of hearing disability is 291 persons per 100000 population, higher in rural areas than urban areas. [5] In India, one in 1000 babies are born profoundly deaf (≥90 dB in better ear) and the burden would be higher, if nearly 40,000 births per day are considered.

Hearing loss in children can be congenital or acquired. The consequences of hearing problems are well known. Many of the children with congenital permanent hearing impairment have difficulties in speech and language development. Mild to moderate hearing loss in children can result in developmental delays. Profound hearing loss can lead to significant speech and language delays, resulting in lack of communication skills.

Young children face challenges in developing spoken language, psychological functioning and academic achievement with severe to profound sensorineural hearing loss. [7] Permanent hearing loss have negative impact on

the development of auditory skills, speech and language, and educational attainment of children.

It has been noted that 80% of all deafness is avoidable - 50% preventable and about 30% treatable or can be managed with assistive devices. The available treatment for children and other profoundly hearing impaired individuals are hearing aid and cochlear implant surgery. Surgery is indicated for individuals in whom the hearing aids fail or individuals not candidates for hearing aid.

HEARING LOSS (CONGENITAL) – ETIOLOGY

1) 50% Genetic

2) 50 % acquired

Childhood onset hearing loss

1) 50% genetic

2) 25% acquired

3) 25% unknown

GENETIC HEARING LOSS

- 75% autosomal recessive
- 25% autosomal dominant
- 1-2% X linked
- Rare mitochondrial

- 75% non-syndromic
- 25% syndromic

Autosomal Dominant Syndromes	Autosomal Recessive Syndromes
1.Waardenburg syndrome	1.Usher syndrome
2.Treacher Collins syndrome	2.Pendred syndrome
3.Apert syndrome	3.Jervel and lange Nielsen
4.Crouzon syndrome	4.Goldenhar (oculo auriculo vertebral syndrome)
5.Stickler syndrome	**X Linked Disorders**
6.Bronchio oto renal syndrome	1.Alport's syndrome
7.Neurofiromatosis	2.Otopalatal – digital
	3.Norrie syndrome

PERINATAL CAUSES OF HEARING LOSS

- Hypoxia
- Kernicterus
- Persistent fetal circulation

POST NATAL CAUSES OF HEARING LOSS

- Meningitis (suppurative labyrinthitis) – ossification of labyrinth, (steroids helps to prevent hearing loss)
- Viral infection : mumps
- Ototoxins / chemotherapy
- Trauma (acoustic,blunt,penetrating)

- Perilymph fistula
- Neoplasm – medulloblastoma,fibrous dysplasia,histiocytosis
- Autoimmune (rare in children)

COCHLEAR ANOMALIES AND THEIR DEFINITIONS

Malformations	Definition
Michel Deformity (3rd week)	Complete absence of cochlear & vestibular structures
Cochlear Aplasia (4th week)	Complete absence of cochlea
Common Cavity Deformity (early 5th week)	Cystic cavity without any differentiation into cochlea and vestibule
Incomplete Partition Type-I (late 5th week)	Cochlea of normal size but cystic with no internal structures identified
Cochlear Hypoplasia (early 6th week)	Small cochlea with either intact or incomplete partition
Incomplete Partition-II (7th week)	Cochlea is shortened to 1.5 turns with an intact basal turn & cystic apex

INDICATIONS FOR COCHLEAR IMPLANTATION

1) Audiometry indications: - Severe to profound hearing loss with little or no benefit from conventional hearing aids

2) Congenital deaf children /pre-lingual deaf children – No ABR response at 90 dB or more, no response on 3 months free field testing with hearing aids

3) Post lingual deafness in adults – free field speech audiometry with hearing aids at 65-75 dB sound pressure level with a score of < 50%.

4) Early deafened adults & adolescents – free field speech audiometry with hearing aids at 65- 75 dB SPL with score of <50 % + additional evaluation of speech intelligibility, lip reading skills.

CONTRAINDICATIONS FOR COCHLEAR IMPLANTATION

1) Cochlear nerve aplasia

2) Cochlea aplasia, michel deformity

3) Central reason for deafness

RELATIVE CONTRAINDICATIONS

1) Psychiatric pathology

2) Bilateral cochlear ossification

3) Cochlear nerve hypoplasia

PRE – OPERATIVE EVALUATION

1) AUDIOLOGICAL EVALUATION – BERA, OAE, IMPEDENCE, PTA

2) RADIOLOGICAL EVALUATION – HRCT Temporal bone with cochlear cuts , MRI Brain with Internal Auditory Meatus screening

3) GENERAL AND SYSTEMIC EVALUATION AND ANAESTHETIC FITNESS – Pediatrician, Psychologist, Ophthalmologist, Cardiologist opinion, Torch screening, Genetic screening, Routine blood investigations (complete blood count, bleeding, clotting time, blood grouping, typing, viral markers) anaesthetic fitness .

4) Pneumoccocal polysaccharide vaccine and meningococcal vaccine to be given prior to surgery.

5) Proper pre and post-operative counselling regarding realistic expectation, outcomes and challenges of surgery has to be explained to the parents of child and advice regarding post-operative audio-verbal therapy and its importance.

6) Candidates with possible less favourable outcome – like post meningitis, inner ear malformation, cytomegalovirus infection. These poor outcomes have to be explained prior to surgery.

LEVELS OF OUTCOME

1) Signal function (awareness of sounds)

2) Support of lip-reading skills

3) Open set speech understanding

HISTORY OF COCHLEAR IMPLANTS

- 1957 – Andre Djourno & Charles Eyries invented original cochlear implant
- 1961 – William House invented first cochlear implant
- 1964 – Blair Simmons & Robert J.White at Stanford university implanted 6 channel electrode in patient's cochlea
- 1977 – Modern multi-channel implant invented & implanted by Ingeborg Hochmair, Erwin Hochmair
- 1978 – Graeme Clark from Australia invented multichannel implant
- 1980 – US FDA began regulation of cochlear implant
- 1984 – FDA approved the use of cochlear implant in adults
- 1985 – nucleus system approved by USFDA
- 1989 – MED-EL founded by Ingeborg
- 1990 – USFDA approved the use of cochlear implant in children above 2 years
- 1996 – Advanced Bionics Corporation implant approved by USFDA
- 2000 – FDA Approved the use of implant more than 1 year of age

COCHLEAR IMPLANT DEVICE

Cochlear implantation technique changed the therapeutic possibilities for profound congenital or acquired sensory neural hearing loss patients. These were implantable biomedical devices, that will not cure deafness but will provide some degree of auditory perception to patients with SNHL. Cochlear implantation is a tool to gain hearing ability and to obtain age appropriate communication skills in children with severe to profound sensorineural hearing loss.

Multi factorial process is required for selecting right candidates for cochlear implantation. Team must have ENT surgeon, Audiometrist, speech language therapist, psychologists, social worker.

Outcome of surgery depends on patient & implant related factors.

Candidacy Profile for Cochlear Implantation : 3 Groups

1) Post lingually deaf children & adults

2) Pre lingually deafened children

3) Early pre and perilingually deafened adults and adolescents

Cochlear implant bypass the normal hearing process, they replace it with electric hearing. Electric Signals which directly stimulates the auditory nerve. Brain adapts this electric signal hearing as sound and speech.

2 components of implant are external speech processor & internal actual implant.

- One or more microphones to pick up sound from environment
- A speech processor, which filters unwanted sounds & prioritize audible speech
- A transmitter that sends power and processed sound signals to inner device by radiofrequency.

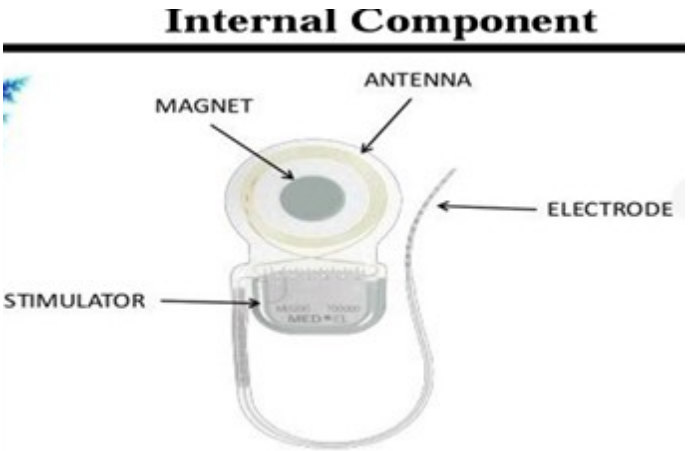

- A Receiver stimulator – which receives signals from speech processor & convert them into electric impulses

- An electrode array – which has to be embedded in cochlea.

Before the advent of cochlear implants, the resources for hearing disability were limited to development of communication skills and use of hearing aids. The cochlear implant development has created an opportunity to gain an understanding of the auditory system and better prospects for individuals with profound sensorineural hearing loss.

COCHLEAR IMPLANTATION PROCEDURE

SURGICAL STEPS OF COCHLEAR IMPLANTATION

1) Post auricular skin incision
2) Musculo periosteal flap
3) Mastoidectomy
4) Posterior tympanotomy / facial recess approach
5) Identification of round window
6) Receiver well creation
7) Implant fixation
8) Electrode insertion
9) Impedence and NRT testing
10) Electrode fixation using soft tissue plug
11) Wound closure

SKIN INCISION

4 Types

- Lazy S Incision
- Normal retro auricular incision Wide C shaped retro auricular incision
- Minimal access incision

The choice of incision depending upon the surgeon, main aim of the incision is that enough space for speech processor & without creating pressure points on the skin, it should prevent extrusion of array, should provide proper coverage of the implant.

When there is a previous surgery use the same incision before, because multiple incisions leads to more scarring which result in skin necrosis & defects.

LAZY S INCISION

Advantage: good access for drilling out the receiver stimulator well, it gives proper implant coverage

Dis advantage: because of more lateral placement of facial nerve over mastoid tip in children, incision has to be avoided over the mastoid tip.

WIDE C SHAPED RETRO AURICULAR INCISION

Indication: Well pneumatized mastoids, where more access is needed in subtotal petrosectomy

Disadvantage: Wound & unsighty scar over receiver stimulator,

MINIMAL ACCESS INCISION

Dis advantage: severe stretching of skin for getting access creates problematic scarring of the skin, sometimes 2 incisions are needed for access mastoid and middle ear one incision & other for receiver stimulator placement, this creates infections & flap related problems.

MUSCULO PERIOSTEAL FLAP

- It should cover the entire implant receiver stimulator caze post operatively
- It may be anteriorly placed, inferiorly placed, posteriorly placed musculo periosteal flap to get best coverage of implant
- Don’t create too large pocket between temporal muscle, the periosteal flap and the skin this leads to a hematoma and infection

MASTOIDECTOMY

- When no pathology, limited mastoidectomy enough.
- Internal rim of cortical bone left along the cavity to hold the electrode array.
- Identification of horizontal & tympanic part of facial nerve, short process of incus, lateral semicircular canal.

POSTERIOR TYMPANOTOMY

- It has triangle shape, widening posterior tympanotomy improves the visibility of cochlea & round window niche to improve the working space, increasing illumination of microscope.
- Facial nerve has to be identified before further widening, inexperienced surgeons tend to drill away from facial nerve may lead to tympanic annulus damage
- Chordae tympani exposed till chordal crest, if needed it can be removed for better access
- Hypotympanic pneumatization if extensive that obscure the view of round window niche

IDENTIFICATION OF ROUND WINDOW

- Usually seen in restricted manner
- Bony over gang covers superiorly & bony projection covers inferiorly
- For proper scala tympani insertion superior part has to be removed
- Round window is dark grey in colour

- Pseudo membrane is whitish in colour
- In fibrosis / labyrinthitis ossificans white aspect of round window seen

RECEIVER WELL CREATION

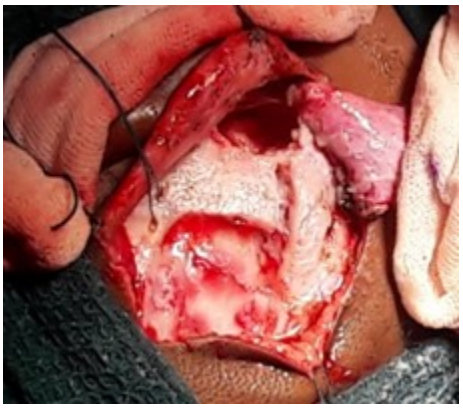

- With the help of templates receiver stimulator well has to be drilled
- Some types of implants may need only a pocket & fixed with screws
- In children / adult with thin bone removal of external circle of tabula interna offers adequate fit even in shallow cortical bone.

IMPLANT FIXATION

- 2 Small bony canals superior & inferior of the receiver stimulator is needed for fixation of implant using non resorbable sutures
- Tight suturing of temporal muscle over the implant is necessary
- Damage to emissary vein & dura has to be avoided
- Drilling a canal from receiver well to mastoid cavity for electrode array placement, helps to protect the electrode array
- Mobilization of skin and muscle should be minimal to prevent post-operative hematoma
- Firm bandage for 24 – 48 hours is essential
- Before electrode array insertion into cochlea, receiver has to be fixed.

DIFFERENCE BETWEEN ROUND WINDOW INSERTION & COCHLEOSTOMY

Safe & easy access to scala tympani	In case of difficulty indentifaction of round window
Minimal drilling needed	Drilling more
Atraumatic insertion	Traumatic insertion compared to RW insertion
Good chances of saving residual hearing	Residual hearing will be affected
less vestibular complaints post operatively	More vestibular complaints

MARGIN COCHLEOSTOMY

Hook Region is identified by crista fenestrae on inferior border of round window, this forms narrowest point to scala tympani, it may present as obstacle during electrode array insertion, this need to be opened up more to again adequate access to scala tympani

- While insertion of electrode it is important to prevent entry of blood & bone dust into cochlea
- Hyaluronic acid can used as lubricant during insertion
- Avoid intra cochlear trauma while inserting electrodes

ADVANCED – OFF STYLET TECHNIQUE

After insertion of 1st part of electrode array (mark on the array), last part pushed off the stylet while stylet is in stable position

Friction free implantation, kinking of electrode has to be avoided

Once the resistance met, electrode array needs to be drawn back slightly & after gentle rotatory movements procedure repeated.

Electro Acoustic Stimulation: it helps to save intracochlear structures & preserve residual hearing, lesser post-operative dizziness.

IMPEDENCE & NRT MEASUREMENT

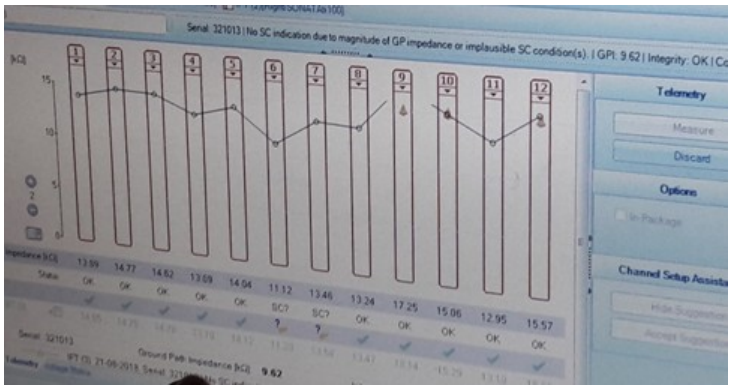

ELECTRODE FIXATION USING SOFT TISSUE PLUG

Small rectangular piece of soft tissue / muscle plug harvested from temporal muscle, is used to fix the implant in position. Small muscle piece can also used for posterior tympanotomy fixation. Fibrin glue may also be used.

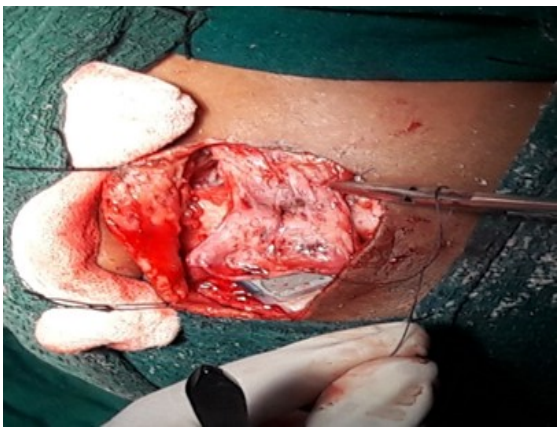

WOUND CLOSURE

Musculo periosteal & skin flaps are closed in 2- 3 layers, sutured using an absorbable suture. Tight mastoid bandage at least for 24- 48 hours, additional protection of implant by wearing hat,cap,or loose fitting head bandage in unstable children who are tumble often.

MATERIAL AND METHODS

STUDY DESIGN

Cross sectional study

STUDY SETTING

The study was conducted at Upgraded Institute of Otorhinolaryngology, Rajiv Gandhi Government General Hospital, Chennai – 600003.

STUDY PERIOD

The study was conducted from SEPTEMBER 2016 to SEPTEMBER 2018 over a period of 2 years.

STUDY SUBJECTS

Children admitted for cochlear implant surgery during the study period at Upgraded Institute of Otorhinolaryngology, Rajiv Gandhi Government General Hospital, Chennai, who satisfy the inclusion criteria

DATA COLLECTION

- The data was collected from the parents using semi-structured questionnaire / Case proforma.
- Clinical examination and other relevant investigations were done before and after the surgery.
- Complete audiological examination was done before and after the surgery.
- Intra-operative and post-operative challenges both major and minor challenges were observed and highlighted.

- Measures taken to overcome those challenges were discussed here.

DATA ANALYSIS

- Statistical analyses were performed with SPSS Statistics 16.0 (SPSS inc. Chicago,lllinois). All characteristics were reported with descriptive statistics. All categorical variables were evaluated with Pearson Chi-Square test. Comparison of mean frequency of speech cycles were examined with Kruskal Wallis test. A p value of ≤ 0.05 was considered statistically significant.
- The Data collected in the case proforma was entered into Microsoft excel sheet and data analysis was done by using SPSS statistical software.
- Quantitative and qualitative data were expressed in mean and proportions.
- Comparison was done using appropriate statistical methods and appropriate tests of significance were used.

ETHICAL CONSIDERATIONS

- Before starting the study, the study protocol was approved by the Institutional Ethics Committee.
- Informed written consent was obtained from the parents / guardian of the study participants before the study.
- The information collected was only used for the study purpose and strict confidentiality is maintained throughout the study.

CHALLENGES ENCOUNTERED IN OUR STUDY AND ITS MANAGEMENT

PREOPERATIVE CHALLENGES

Challenge 1 :- Pre-Operative Secretory Otitis Media

We had 4 patients with pre-operative secretory otitis media, with complaints of repeated upper respiratory tract infection, On examination tympanic membrane was retracted in 3 patients,1 patient had normal tympanic membrane. Impedence audiometry shows B Curve in all 4 patients. HRCT Temporal bone shows bilateral otomastoiditis in all 4 cases. 3 weeks of higher oral antibiotics given for all 4 patients and impedence repeated after 3 weeks shows A Curve in 2 patients, and persistent B Curve in 1 patient, C curve in 1 patient, we proceeded with cochlear implant surgery in all four patients, intra-operatively thick glue and brisk bleeding noted in the patient with persistent B curve, two patient had glue and lesser bleed compared to those with persistent B curve. one another patient had not much bleeding. So we concluded that proper pre-operative clinical assessment of otitis media & impedence audiometry is a good tool for diagnostic as well as treatment plan. In some cases if impedence findings misleading, clinical findings will help to decide further management option. Adequate Appropriate antibiotics will helps to reduce intra-operative bleeding in these cases. None of our cases needed adenoidectomy with grommet insertion pre-operatively for

secretory otitis media. Effective antibiotic control helps to prevent additional surgeries in selected cases.

Challenge 2 – Pre-Operative Chronic Suppurative Otitis Media

- A 4 years old male child came with chief complaints of not responding to loud sounds since birth, On evaluation bilateral chronic suppurative otitis media with subtotal perforation noted with bilateral grade 3 tonsillar hypertrophy

- We proceeded with adenotonsillectomy followed by right cortical mastoidectomy with temporalis fascia grafting followed by cochlear implantation on right side as 3 staged procedure (minimum 3 months interval in between the procedures)

- Child is on regular follow up and developed sound awareness. now we did myringoplasty for left ear, with good graft uptake.

- In our case tympanic membrane perforation alone noted (inactive mucosal disease), so we proceeded with adenotonsillectomy, myringoplasty, and cochlear implant surgery as 3 staged procedure.

CHALLENGES RELATED TO INCISION AND FLAP COVER

Challenge 3 – wound infection

Case-1

- A 1-year old female child a known case of bilateral profound sensory neural hearing loss underwent right cochlear implantation under general anaesthesia.
- After mastoid dressing removal on 7th day signs of wound infection noted. (redness, tenderness)
- Early intervention in the form of higher intravenous antibiotics, local wound care by proper cleaning and dressing of wound with mega heal ointment local application attempted. Signs of infection subsided with good wound healing and implant in-situ, patient is on regular follow-up. With no evidence of re-infection at present.

Case-2

- A 3 years old male child underwent right cochlear implantation.
- Fever with wound infection and discharge from wound site was noted.
- Pus culture report came as methicillin resistant staphylococcus aureus.
- Injection linezolid, injection ampicillin & local wound care with mega heal ointment was given.

- Inspite of above measures wound site dehiscence noted – with the help of plastic surgeon rotational flap was done

- Again recurrent wound dehiscence and flap infection was noted revision rotational flap was done

- Again wound dehiscence noted, so we proceeded with wound exploration, biofilm and pus collection noted in between the implant and bed

- So, implant explantation was done.

- Post-operatively wound was healthy. So we proceeded with implantation in opposite ear

- Now patient is on regular follow-up with no such complications, Now patient having good sound awareness response.

WOUND DEHISCENCE/WOUND GAPING

Case-3

- A 7 years old female child post right cochlear implantation extrusion of suture material noted through a skin defect

- Wound resuturing was attempted
- Again there is small defect noted
- With the help of plastic surgeon temparo-parieto fascial flap was attempted after confirming implant function
- Now wound was healthy and child was on regular follow-up, word recognition present now.

Case-4

- A 3 years old female child post right cochlear implantation wound gaping
- After confirming the implant function rotational flap was attempted
- Now wound was healthy and patient was in regular follow-up, at present patient developed word recognition scores.

MANAGEMENT OPTIONS

- Wound infection has to be avoided by proper pre-operative sterile methods like (sterile microscope cover, proper cleaning and painting of ear, sterile drapes, covering other areas of body properly to avoid surgical site contamination)

- Intra-operative intravenous antibiotics,

- Post-operative proper antibiotics cover with sterile dressing, sterile ward is needed to prevent further cross infections.

- As early as possible rotational flap has to be given

- Ethilon suture material may cause wound dehiscence following primary infection – ethilon suture has to be removed at 10th post-operative day to prevent wound infection

- Inadequate musculo periosteal flap that inadequately covers receiver stimulator, in case of secondary infection it may lead to wound gaping, so adequate receiver stimulator covering is essential to prevent wound gaping.

S. No.	Status of Infection	Management In Our Cases
1.	Wound infection – minimal	Early intervention with intravenous antibiotics, local ointment application
2.	Exposure of the implant/ wound gaping	Rotational flap if it fails revision rotational flap,if it again fails explantation may be needed
3.	Device extrusion – penetration of prolene suture through the skin externally	Instead prolene ethibond can be used, if it fails rotational flap is used. (trimming of prolene done carefully or has to be avoided)
4.	Wound infection – severe	Rotational flap – if it fails – explantation

DEVICE EXTRUSION

Occasionally the receiver stimulator or electrodes may extrude through skin even many years after surgery

Factors responsible for extrusion are

- Skin incision
- Flap
- Choice of sutures
- Fixation of receiver stimulator
- Position of receiver stimulator

Other patient factors are

- Previous ear surgery
- Mal nutrition, anaemia
- Dermatological /infectious disease

All these factors affect wound healing, when the local blood supply is compromised.

Management: covering flap under general anaesthesia either rotational or temparoparito facial flaps.

None of our cases had device extrusion/electrode migration/ magnet migration

Challenge 4 – Seroma/Hematoma

A 4 years old female child post right cochlear implant 15th post-operative day, came with chief complaints of swelling at implant site 3 days, no history of fever, trauma & pain over the swelling

On examination swelling noted over the wound site upper 3rd of incision site, which was not warmth & non-tender.

Aspiration with wide bore needle was attempted. serous fluid was evacuated and sent for pus culture and sensitivity, that shows no growth. with 1 week of Intravenous Antibiotics and compressive mastoid dressing swelling was subsided. Wound was healthy, patient discharged and on regular follow-up now, With word recognition obtained now.

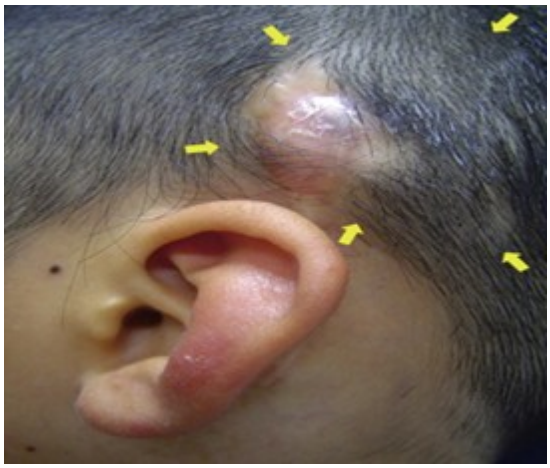

- This is more common in children due to thin skin and thin soft tissue
- This leads to tendency to prone to soft tissue trauma & subsequent infections

Usually it gets normalized by 3 days by conservative measures like aspiration, intravenous antibiotics, and tight dressing. If not subsiding with above measures incision and drainage needed.

INTRA-OPERATIVE CHALLENGES

Challenge 5 – Intra Operative Bleeding

Scenario 1 :- Emissary Vein Bleeding

It is common during drilling for receiver stimulator well creation, we encountered 10 of our cases had mastoid emissary vein bleeding. In 5 cases bleeding subsided with cautery, 3 cases bleeding subsided with bone wax, 2 cases luminal packing with surgicel controlled the bleeding from emissary foramen.

Scenario 2 :- Edematous Middle Ear Mucosa

5 patients - known case of congenital bilateral profound sensory neural hearing loss after proper cochlear implant candidacy evaluation we proceeded with right cochlear implantation under general anesthesia – intra-operatively thick edematous middle ear mucosa noted, managed with adrenaline-soaked cotton balls.

MANAGEMENT OPTIONS

1) It is the most common complication in children compared to adults because of recurrent otitis media and upper respiratory tract infection in children.

2) It also increases the surgery duration

3) Because of edematous mucosa, bleeding is more (inflamed mucosa bleeds more)

4) Edematous mucosa obscure view of round window niche

5) While attempting removal of edematous mucosa – mucosal strands obscure the round window view

6) All these problems can be avoided intra-operatively by adrenaline-soaked cotton balls (decongestants)

7) Proper pre-operative evaluation with impedence audiometry and radiological evaluation will help to anticipate edematous middle ear mucosa, and can be reduced this by pre-operative antibiotics

Scenario 3 :- Types Of Mastoid And Bleeding

- In our series of 250 patients (young children) - >150 children had well pneumatized mastoid, nearly 100 patients had less pneumatized mastoid.

- Young children have mastoid cavity with less pneumatization and more bone marrow causing more bleeding during mastoidectomy

- To achieve good hemostasis in marrow mastoid cases by using dimond burr and less irrigation, and bone wax. Heating problem which leads to heat injury should be avoided around peri labyrinthine area.

- Mastoidectomy has to be completed in shorter time. Compared to adults young children will develop hypovolemic shock with less blood loss.

- In case of narrow/sclerosed mastoid normal anatomical landmarks are altered, identification of short process of incus and facial nerve is difficult. while searching for normal anatomy bleeding will be more. This problem should be anticipated before surgery by proper radiological assessment of mastoid pneumatization, anatomy of facial nerve, sigmoid sinus& round window.

Challenge 6 :- Csf Leak

Scenario 1 :-Anomalous Cochlea

A 3 years old male child with bilateral profound sensory neural hearing loss, HRCT Temporal bone shows bilateral common cavity malformations with wide internal auditory canal, MRI shows hypoplastic cochlear nerve on right side with normal cochlear nerve on left side. So, we proceeded with compressed electrode insertion on left

side. Intra operatively after cochleostomy brisk CSF leak was noted, it was controlled by hypotensive anaesthesia, head end elevation & hyper ventilation by anaesthetist, thick muscle plug closure was done by the surgeon.

Scenario 2 :- Csf Leak While Drilling Receiver Stimulator Bed

- 3 of our cases we encountered CSF leak while creating bony well for receiver-stimulator and also while creating small holes for the tie-down suture to secure the receiver-stimulator onto the cranium.
- This problem was overcome by bone wax application in all 3 cases
- In children cranial bone is thin, this problem mostly solved by bone wax application, Drilling the bone by holding hand burr parallel to lateral surface of temporal bone,
- Other options are self-drilling screws to anchor sutures. With 3mm length screws, sufficient stability is available even in very thin cranial bones by inserting screws in oblique fashion.

CSF LEAK More common in anomalous cochlea

Usually subsides with conservative measures like head end elevation and hyper ventilation, hypotensive anaesthesia by anaesthetist

Lumbar puncture and drain usually avoided as much as possible because of fear of meningitis

Challenge 7 :- Perilymph Gusher

- A 3 years old male child a known case of congenital bilateral profound sensory neural hearing loss, On evaluation MRI & HRCT Temporal bone shows bilateral endolymphatic duct dilated, and the sac enlarged.

- We proceeded with right cochlear implant under general anaesthesia, gusher of fluid coming out while attempting insertion of electrodes.

- It was reduced by itself in about 10 min by supportive measures (Head end elevation, hyperventilation by anaesthetist).

- Tight soft tissue plug kept over the round window area to prevent electrode extrusion.

- Enlarged vestibular aqueduct syndrome is the most common cause for perilymph gusher during surgery, isolated enlarged vestibular aqueduct syndrome or other associated cochleo-vestibular anomalies has to be ruled out by pre-operative radiological investigations.

- If we found pre-operatively precautions to be taken to control perilymph gusher by measures like head end elevation, hyperventilation by anesthetist.

CHALLENGE RELATED TO INJURY OF EAC AND MIDDLE EAR STRUCTURES WHILE DRILLING

Challenge 8 :- Injury To Chordae Tympani Nerve, Canal Wall Injury, Tympanic Membrane Injury

Scenario 1 :- Chordae Tympani Injury

- We encountered chordae tympani injury in 15 cases. All 15 cases had narrow facial recess <3mm - assessed by pre-operative HRCT Temporal bone.

- In some cases, chordae tympani have anatomical variations in location like may arise from more proximal portion of the facial nerve.

- In all our cases chordae injury occurred during posterior tympanotomy widening in patients who had narrow facial recess. Difficulty in round window identification leads to further widening of facial recess damaged the nerve during surgery

- Taste disturbance is more likely when chordae tympani is stretched rather then divided. None of our patients experienced any taste disturbances in post-operative period because most of our patients were young children and taste sensation also carried out by other nerves compensate this injury.

- If taste disturbance manifestation occurs it is usually 1-2 months. Temporary taste disturbances it will settle with regeneration of nerve.

Scenario 2 :- Canal Wall Injury And Tympanic Membrane Injury

- Posterior canal wall injury encountered in 5 of our cases
- One patient had associated tympanic membrane injury also
- We managed all patients with temporalis fascia grafting, all 5 patients is on regular follow-up with healed neo tympanum.
- Entry into the facial recess too laterally away from facial nerve may result in injury to the annulus / tympanic membrane and entry into EAC (manifested by betadine sign – leakage of betadine through the operative site in facial recess area, it indicates injury to annulus / entry into EAC)
- Too much lateral drilling has to be avoided in these cases
- If damage has occurred proper covering of defect either by temporalis fascia or cartilage graft, and the patient should be followed adequately to anticipate the development of cholesteatoma later on.

Challenge 9 :- Injury To Ossicles

A 3 years female child underwent right cochlear implantation surgery after proper preoperative evaluation and confirmation of

candidacy for implantation – during surgery injury to stapes supra structure was encountered.

MANAGEMENT OPTIONS

- Incus dislocation, Incudo Stapedial joint disruption, stapes supra structure injury are the very rare complications
- These complications may occur while widening facial recess area for further exposure with drill
- This complication can be avoided by proper drilling methods like drill should be used as a shaver, and too much pressure while drilling has to be avoided to prevent injury
- Proper surgical anatomy of facial recess has to be learned to prevent injury
- In our series we encountered single case of stapes supra-structure injury, with no other ossicles injury
- Drilling directly over the short process of incus has to be avoided to prevent direct transmission of vibrations to cochlea and associated further worsening of sensory neural hearing loss.
- None of our cases had incus or malleus injury

Challenge 10 :- Injury To Facial Nerve

Scenario 1 - Injury To Facial Nerve

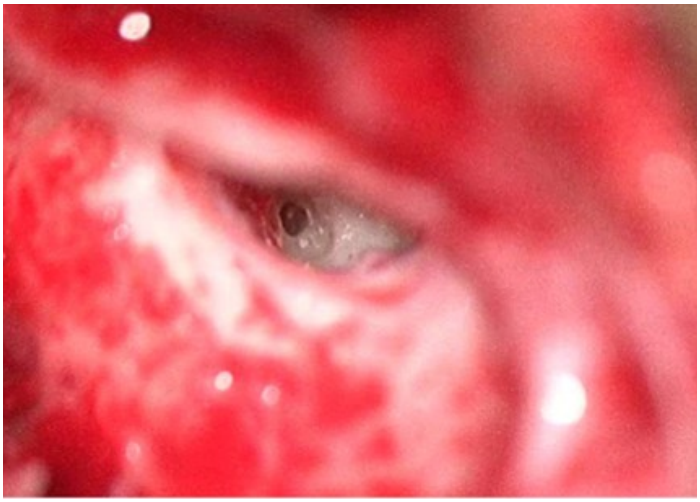

- Possible nerve injuries are thermal injury to nerve, facial nerve sheath injury, facial nerve transection
- We experienced 2 types of facial palsy – thermal injury in 5 cases, nerve sheath injury in 3 cases. these 2 types may lead to temporary facial palsy
- No permanent facial palsy noted in our series
- Temporary facial palsy as a result of thermal injury has occurred in 5 of our patients, all these patients were recovered completely with in 10th post-operative day
- To prevent thermal injury adequate saline irrigation, blunt cutting burr (teeths of cutting burr close to each other) and post-operative intravenous steroids for 1 week gives good results

- Exposure of facial nerve sheath without nerve transection – noted in 3 of our patients – who had the narrow facial recess, sclerosed mastoid (identification of short process is difficult), posteriorly placed round window, high facial ridge

- Cases with only nerve sheath exposure without nerve disruption usually recovers completely in 1- 2 months.

- In case of inadvertent injury to facial nerve, exposure of nerve above and below the site of injury is needed.

- Injury more common in anterior tympanic aspect of bone over facial canal

- In right cochlear implantation right hand drilling will obscure proper microscopic view of structures, to prevent this complication left hand drilling for right ear , holding suction tip at right hand will avoid facial nerve injury at the lower aspect of facial recess

- In left cochlear implantation – injury more common in upper facial recess area , it is also avoided by left hand drilling

Scenario 2 :- Anomalous Facial Nerve

4 years old male child a known case of congenital bilateral profound sensory neural hearing loss planned for right cochlear implantation – intra operatively anomalous facial nerve encountered. For the fear of further widening of facial recess may lead to nerve injury we

proceeded with cochleostomy. Initially we were not able to identify round window niche so we elevated tympano meatal flap to search for round window niche, but there was more prominent carotid pulsations noted, (malpositioned carotids) so we proceeded with facial recess cochleostomy approach.

MANAGEMENT OPTIONS

- Anomalous facial nerve – in this case vertical segment probably had 2 divisions
- Intra-operative facial nerve monitoring is very useful in cases of anomalous nerves to prevent nerve damage
- Almost all anomalous facial nerve situated laterally, so drilling more laterally avoids nerve injury
- Constant landmarks will helps to identify the nerve more precisely even in cases of anomalous nerves.

Challenge 11 – Difficulty In Identification Of Round Window Niche And Cochleostomy

- 4 patients known case of congenital SNHL underwent cochlear implantation – intra-operatively difficulty in round window identification encountered, so we proceeded with cochleostomy
- In our series 1 patient had anomalous cochlea,1patient had anomalous facial nerve & 2 other patient had difficulty in round

window identication because of more posteriorly placed round window – so all 4 patients we proceeded with cochleostomy.

COCHLEOSTOMY

- A point on promontory immediately anterior to the middle and inferior third of round window niche is taken as the centre of the cochleostomy
- RW membrane is usually 1-1.5 mm inferior to stapedial tendon,
- It is safer to begin the cochleostomy too low than too high
- It is excavated with a 1.5mm diamond burr down to the depth of 1.5mm or until blue line of endosteum is seen, endosteum opened with straight pick
- Care is taken to use sufficient irrigation (surgical glycerine) to avoid heating the cochlea and prevents entry of blood and bone dust into the scala tympani
- Topical intratympanic steroids through cochleostomy site – hearing preservation

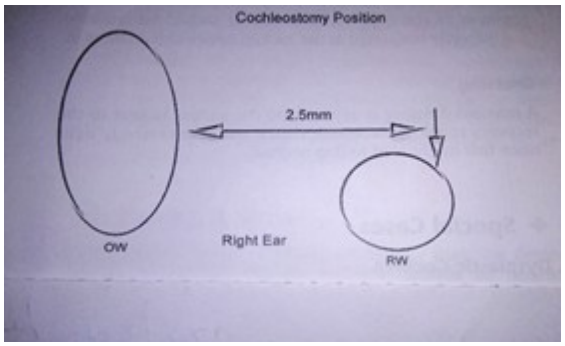

ADVANTAGES OF COCHLEOSTOMY

- Easier to access and enters the cochlea past the hook area
- Easier to pack hence prevent perilymph fistula
- Allows straighter and more direct insertion of electrode into scala tympani and avoids damage to basilar membrane
- In RW electrode insertion this problem is over - come by inserting electrode at oblique/anterior angle to the surface

Challenge 12 :- Difficulty In Insertion Of Electrodes

- 2 Patients known case of Congenital bilateral profound SNHL, HRCT, MRI – normal cochlea, nerves
- We proceeded with right cochlear implantation – during electrode insertion difficulty encountered,
- 8 electrodes were inserted successfully so forceful reinsertion avoided.

DO'S AND DON'T'S

1) Any difficulty in insertion of electrodes to full length – don't try further.
2) Stop if resistence is encountered.
3) Minimum insertion of 8 electrodes is sufficient. Complete cochlear coverage full length electrode

4) Forceful insertion – scala vestibuli insertion by tearing basilar membrane, electrode contact with nerve ending may not be perfect.

5) Atraumatic electrode insertion mandatory.

Challenge 13 :- Cochlear Ossification – Labyrinthitis Ossificans

A 5 years old female child, post meningitic child with post lingual bilateral profound sensory neural hearing loss, We evaluated for cochlear implant candidacy, Brain stem evoked response audiometry shows no response at 90 dB , Otoacoustic emissions absent on both ears .On High resolution CT scan shows bilateral oto mastoiditis , MRI shows normal cochlea and cochlear nerves, impedence audiometry shows bilateral A curve .

We planned for left cochlear implantation under general anesthesia, after obtaining fitness, intra operative findings : sclerosed mastoid , difficulty in identification of round window niche , thick bone noted infront of round window membrane ,on further drilling round window identified. But difficulty in insertion of electrodes were encountered, only 3 electrodes were able to inserted. Procedure was stopped. ART Recorded in 3 electrodes post operatively.

Post operatively HRCT Temporal bone was taken that shows labyrinthitis ossificans on both sides ,left more than right.

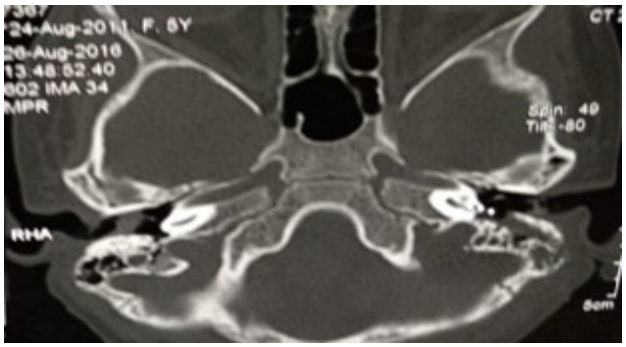

Post op HRCT shows implant insitu with labyrinthitis ossificans changes.

We proceeded with revision surgery, intra operatively thick bone noted infront of round window membrane it was drilled, further basal turn drilling was attempted, 8 electrodes insertion was completed successfully, further insertion difficulty encountered. So we stopped forceful insertion. Post operatively ART recorded in all 8 electrodes. After 21 days programming & switch on attempted. Patient was on regular followup with good responses (Word recognition present now).

- Labyrinthitis ossificans is the more common complication following meningitis
- In our case we managed with basal turn drill out if there is difficulty with basal turn drill out alone mid turn drill out can be proceeded for electrode insertion
- In total cochlear ossification auditory brainstem implant is the treatment option

MANAGEMENT OPTIONS

Grade 0	No fibrosis on CT / MRI	Normal cochlear implantation
Grade 1	Ossification only at round window/upto half of scala tympani	Drill out round window niche & basal turn drill
Grade 2	Ossification in more than half of scala tympani	Scala vestibuli insertion
Grade 3	Ossification of basal turn of scala tympani & scala vestibuli	Drill out basal turn & normal electrode insertion /basal with middle turn cochleostomy & double electrode array
Grade 4	Total ossification of cochlea	1.Drill out basal turn with mid turn & double /triple electrode array 2.If no cochlear lumen then ABI is useful

Grade 1 usually have comparable results with standard implantation

Grade 2 better results with scala vestibuli insertion , (More risk of vertigo)

Grade 3 , 4 & 5 worse results than standard CI.

Challenge 14 : - Post Ventriculo-Peritoneal Shunt Cochlear Implantation

A 3 years old male child came with chief complaints of not responding to loud sounds since birth. On evaluation congenital bilateral profound sensory neural hearing loss was noted.

On radiological evaluation: Obstructive hydrocephalus with dilatation of ventricles noted. Cochlea and nerves appears normal.

Neurosurgeon opinion obtained – VP (ventriculo peritoneal shunt) surgery on right side was done – post operative CT scan taken that shows shunt insitu.

Neurosurgeon suggests as there is no contraindication for cochlear implant surgery, & suggests avoid cautery during surgery.

We proceeded with left cochlear Implant under general anaesthesia.

Post-operative period uneventful.

Post op x-ray mastoid shows implant insitu

During procedure cautery has to be avoided is the main precaution in this case because of placement of VP shunt

Child is on regular follow-up with both implant and shunt insitu, & good speech responses.

Challenge 15:- Anomalous Cochlea

- In our series we encountered 8 cases of anomalous cochlea
- 3 of our cases had syndromic hearing loss, other 5 cases had non-syndromic hearing loss
- All cases were diagnosed pre-operatively with radiological investigations

- Management options selected according to the status of cochlea and nerves
- Most cases received compressed electrodes fixation
- 7 cases were in routine follow-up till now with poor speech responses in relation to patient having normal cochlea

Patient details	Diagnosis	Syndromic/ nonsyndromic	Radiology	Implant option
Akshaya	Cong SNHL	Waardenberg syndrome	Mondini both sides, with normal cochlear nerves	After test electrode confirmation compressed electrode insertion was done on right side
Diwakar	Congenital	Non-syndromic	Mondini on both sides with left cochlear nerve absent	Compressed electrode form 19 on right side
Shiyasri	Congenital	Goldenhar syndrome	Left ear mondini with normal cochlear nerve, right michels aplasia	Left compressed form 19 electrode
Harshika	Congenital	Non-syndromic	Right michel ‘s aplasia ,left mondini deformity with hypoplastic nerve on left side	Left compressed form 19 electrode
Srivignesh	Congenital	Non-syndromic	Right severe dysplastic cochlea with	Left compressed electrode,

Patient details	Diagnosis	Syndromic/ nonsyndromic	Radiology	Implant option
			cochlear nerve absent, left common cavity with normal nerve and wide IAC	intra operative CSF gusher controlled by tight muscle plug
Sarathy	Congenital	Non-syndromic	Bilateral common cavity with normal cochlear nerves	Right Lateral semicircular canal insertion of compressed electrode
Abdul Rahman	Congenital	Klippel Feil syndrome	Bilateral cochlear nerve absent with normal cochlea on both sides	Referred for ABI
Mohammed Fouzan	Congenital	Non-syndromic	Bilateral hypoplastic cochlea with bilateral hypoplastic nerve	Form 24 electrode on right side

- Proper pre-operative assessment and selection of type of electrodes is essential for effective management

- Anticipate intra-operative complication like CSF leak will help the surgeon to reduce unnecessary anxiety during surgery.

- Outcomes depends upon cochlea and nerves, usually these patients have poorer outcome compared to patients having normal cochlea and nerves.

POST-OPERATIVE CHALLENGES

Challenge 16 :- Device Failure

4 Patients suffered from device failure. 3 patient had history of fall injury, 1 patient had gradual detoriation of sound awareness with cochlear implant. we evaluated & impedence was high in > 8 electrodes in all 4 patients. Impedence re-test done on 3 occasions all reports shows inconsistent responses, high impedence in > 8 electrodes . so audiologist confirmed hard device failure (X ray shows implant insitu).

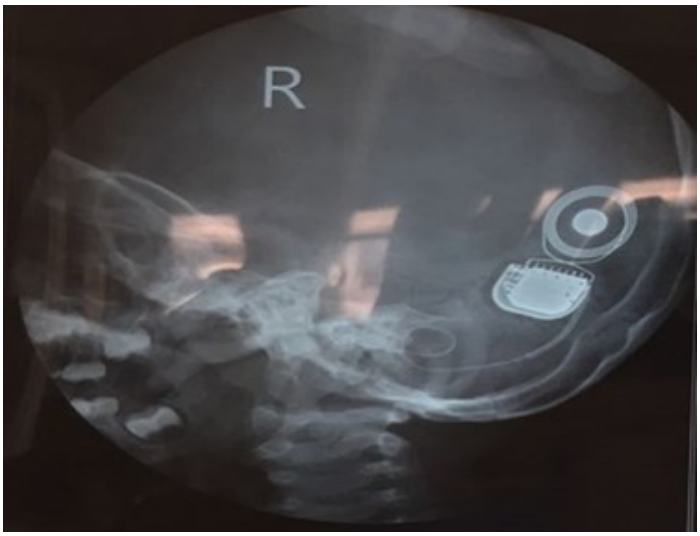

It is one of the major complications requiring explantation and reimplantation surgery.

Most probable reason for failure

- Trauma
- Electronic dysfunction
- CSF leakage

Device failure – 2 types

- ❖ Hard device failure
- ❖ Soft device failure

HARD DEVICE FAILURE

Absence of auditory input or electronic lock between internal and external components. (proven malfunctioning device)

This is the most common reason for re-implantation.

Causes are

- ❖ Failure from impact
- ❖ Sealing failure
- ❖ Electronic failure
- ❖ Electrode problem
- ❖ No specific cause

SOFT DEVICE FAILURE

Defined as malfunction of implant but without any proof with available in vivo methods of testing.(suspected device failure without any proof).

Evaluation of Device Failure

- ❖ Symptoms: careful history of auditory & non-auditory symptoms

- Medical evaluation: physical examination, imaging to assess electrode position, evaluate central nervous system pathology, rule out intra cochlear ossification or infection

- Audiologic evaluation: assess speech performance & mapping to evaluate drop in performance, change in sensitivity to stimulation, failure to achieve expected benefit.

- Device assessment: device integrity testing, trouble shooting, programming

Diagnosis of device failure confirmed by

1) Evaluation of function of implant thoroughly by the implant team & manufacturer

2) Suspected implant has to be removed, examined, and technical failure should be identified

Conservative approach usually followed for soft device failure initially because this is a working diagnosis, if this is a proven malfunction of device it is considered as hard device failure.

Device failure is more among pediatric population because of tendency of repeated fall injury, infections& more complex surgical anatomy in young children.

Challenge 17:- Post-Operative Acute Suppurative Otitis Media

4 patients known case of congenital bilateral profound sensory neural hearing loss, post right cochlear implant

Came with chief complaints of ear pain in the operated ear for 3 days with history of upper respiratory tract infection

On otoscopic examination tympanic membrane was congested, bulged, cone of light was absent, leach of blood vessels seen over the handle of malleus

One week of IV Antibiotics symptoms relieved and tympanic membrane came back to normal

None of our patient required revision surgery/cholesteatoma formation.

All patients improved with conservative measures.

It is the most common challenge in pediatric age group compared to adults because of the more horizontally placed eustachian tube & recurrent upper respiratory tract infection in children

Routine cortical mastoidectomy in cochlear implant surgery gives some protective effect on otitis media. It reduces the incidence of chronic otitis media by establishing drainage.

REVIEW OF LITERATURE

Kempf HG et al – complications of cochlear implant surgery in children (1997 Nov 18) – intra operatively, obliteration of the cochlea occurred in 66 patients, cochlear dysplasia in 8, CSF leakage in 7, nearly 5 % patients had signs of infection in the mucosa of middle ear. Post operatively early complications occurred in 1% to 2.5 % of patients: flap complications, electrode dislocation, facial nerve problems, and incorrect insertion of electrode. Delayed complications included otitis media and stimulation of facial nerve. They concluded proper preparation of the implantation site, experienced and well-trained surgeons, & awareness of the operative and post-operative risks are necessary.

Turk ORL Arsivi, 2001; 39 (2): 89-95 – C.Batman – Cochlear implantation: patients, problems and surgical complications – most significant problems due to wound breakdown and flap related complications – solved the problem by extended endaural flap design of Hannover . electrode misplacements and compressions – partial slippage of electrode tie into radical mastoidectomy cavity required revision operation – array was supported with a tragal cartilage after obliterating cavity. Problems with perilymph and CSF leak occur typically in cases of congenital abnormalities. In these cases, the entry point into the scala tympani carefully sealed with fibrous tissue. If necessary the whole middle ear and mastoid must be packed. If complete fibrosis or ossification of the

scala tympani – scala vestibuli insertion attempted. care should be taken not to injure the facial nerve while doing posterior tympanotomy

R.Jain.S.K.Mukherji – Cochlear implant failure: Imaging evaluation of the electrode course (2002) – cochlear implantation is a safe surgical procedure with good results in terms of overall hearing improvement. However due to very small distances between the cochlea and adjacent structures, malpositioning of the electrode may occur. It is important to take post implant CT can help differentiate patients with irreversible or refractory hearing loss, who do not improve despite normally positioned electrode, from those with malpositioned electrode. In the later group of patients another attempt can be made by correctly re-implanting electrode.

Michel A.Mecca et al(April 6,2003) – complication of cochlear implant surgery – case report – post operatively patient experienced vestibular symptoms with no improvement in hearing. High resolution temporal bone CT scanning demonstrated extracochlear positioning of the CI electrode in superior semicircular canal

Rabindra R.Tambyraja,et al MD,(March 2005) - Cochlear Implant Complications – Structural limitations of database, in addition to disparate reporting quality, made systematic analysis difficult, current structure of the MAUDE database is only modestly useful for analyzing trends in complications and cannot answer critical questions, including

device type comparison, they suggest changing the current report format to include patient age, duration of implant, presence of anatomical abnormalities, & details on spontaneous device failures

Frederic venial, MD; Marielle sicard, AuD (Dec 2008); - Reliability and complications of 500 consecutive cochlear implantations – shown overall rate of complications was 16% ,with minor complications – 5.6%, major complications – 3.2% , & reimplantation – 7.2%, reasons for revision surgery were hard device failure, soft device failure, infection, trauma, they concluded cochlear implant is a safe technique with low complication rate, however certain complications may require specific attention to prevent or correct them.

Sheng – Dean Luo (2009) – Mastoid pressure dressing for cochlear implantation – This study shows statistically insignificant difference between mastoid pressure dressing / simple gauze dressing. The key to preventing hematomas is careful tissue handling and minimally invasive techniques. Mastoid pressure dressing alone rarely provides enough pressure to prevent hematoma.

Taryn Davids et al(May 2009) – Soft tissue complications after small incision pediatric cochlear implantation (2009) – there were 385 consecutive children implanted with 462 cochlear implants. Of these 322 were primary single sided implants,124 bilateral implants, and 16 re-implants for device failure. Median follow up was 2.9 years. there were

2 minor complications – seroma & hematoma managed conservatively, 5 major complications – 2 major seromas,2 soft tissue infections, one extrusion leading to device migration. All these 5 requires device explantation. Use of small incision technique combined with device fixation as a safe method of cochlear implantation

Luiz Rodolpho Penna Lima Junior **–** post operative complications in implanted patients in the cochlear implant program of Rio Grande do Norte – Brazil (Jan 2010) – study shown 33 patients (13.2 %) had post-operative complications, minor complications affected 20 cases (8%), while major complications occurred in 13 cases (5.2%). Hematomas, device failures and infections had the highest clinical relevance. This review reinstates the safety of the surgical procedure in relation to the possible occurrence of post-operative complications and emphasizes the need for continuous surgeon education and training

Akbar Pirzadeh et al (July 2011) – Complications related to cochlear implants: experience in Tehran (2011) – 24 patients (13.6%) experienced complications. early complications Occurred in 9(37.7%) patients within first 24 hours. 8 patients (4.5%) had major complications including facial nerve paralysis, suture rupture and prosthesis rejection. Minor complications were found in 16 cases (9%) which were managed medically.

Selena E.Heman – Ackah et al(Aug 2011) **–** pediatric cochlear implantation: candidacy evaluation, medical and surgical considerations

and expanding criteria – cochlear implantation within the pediatric population is safe and effective. Most complications reported represent minor complications, with major complications accounting for only 20-30 % of all complications on average, presence of inner ear malformations has been correlated with increased rate of complications in pediatric cochlear implantation. Complications after implantation may be classified as early (with in first 2 weeks of implantation), late (> 2 weeks). Most common complications are infection, hematoma, seroma, facial nerve paresis, CSF fistulas, device failures, cholesteatomas

Mohammad Ajallouoyan et al (Dec 2011) – a report of surgical complications in series of 262 consecutive pediatric cochlear implantations in Iran – shown minor complications occurred in 18.7% cases, most common post-operative complications were temporary facial weakness (5.7%) all of which were reversible, magnet wound in 5.3%, keloid formation in 3.8%, wound infection in 0.8%, otitis media in 2%, electrode movement, meningitis, vertigo, laryngospasm each in 0.4% cases were detected in this study, and they concluded cochlear implantation in children continues to be reliable and safe in experienced hands with a low percentage of severe complications as long as the patient is monitored closely.

Joseph L.Russell et al – cochlear implantation (October 2012) – most common complications were related to the surgical wound – in 4% cases. This

includes infection, flap necrosis, & extrusion of the receiver – stimulator. These complications can be avoided by careful placement of incisions, & by keeping the skin flap over the receiver stimulator 6-7 mm thick. Other complications include acute otitis media (2%), damaged or misplaced electrodes (1 %) and facial nerve paresis (0.5 %). meningitis (<0.6) occurs rarely – this risk was mitigated by vaccination – pneumovax & Hemophilus vaccination

Kadir Serkan Orhan et al(4 Feb 2012) – Complications & their management following pediatric cochlear implantation (Sep 2005- May 2010) – 13 major (3.8 %) & 12 minor (3.5 %) complications were observed. Major complications included local flap failure, soft device failure, magnet displacement following head trauma, electrode displacement into vestibule, reference electrode migration to dura mater with facial paralysis, electrode extrusion from the external auditory canal, hard device failure after trauma, electrode breaking into mastoid cavity, bleeding from sigmoid sinus during the operation, minor complications included vestibular symptoms, seroma formation, recurrent acute otitis media, hematoma following head trauma and seizure. These complications should be kept in mind during CI surgery and the surgeon should be work to avoid them and be familiar with them enough to treat them

A.Danesi et al.,(24 May 2015) Complications in a series of 4400 pediatric cochlear implantation – shown cochlear implantation is reliable and safe procedure in experienced hands, with very low serious

complications, major intra & post-operative complications are intra-operative CSF leakage, flap (skin) necrosis, post-operative meningitis, severe facial nerve damage, massive hemorrhage, device failure.

DC Gheorghe and A Zamfir – chiru – Anton (26 May 2015) – Complications in cochlear implant surgery – shown 8.86% complications have occurred – impossibility of establishing a reliable cochleostomy due to ossification, air in the cochlea through lack of sealing of cochleostomy (exteriorization of the electrode array), cochlear implant post-operative migration from its bed, weak hearing discrimination due to "double electrodes" in the scala tympani, gusher. they concluded cochlear implanting needs to respect the technical steps of surgery & best technical / tactical solution has to be found to whatever complications arise in complex or malformed cases

Bradford Terry et al – Delayed complications after cochlear implantation (Nov 2015) – total number of delayed complications were 5.7% ,with vestibular complications 3.9%,device failure (3.4%) , taste problems (2.8%). Less common complications includes cholesteatoma (0.5%), facial nerve palsy (0.6%). They concluded patient should receive life time follow up to monitor for potential complications and to facilitate their care if complications occur.

RESULTS OF OUR STUDY

Cochlear implantation has been successful in pediatric population, with experienced surgeons, and proper preoperative counselling to parents & proper post-operative follow up. In literature 4- 40 % cases reported challenges. Our study has comparable results with literature. Major challenges are defined as failure of implantation, revision surgery, re-implantation, Minor challenges are those not necessitating re operation / implant not threatened / medical & conservative management will solve the problem. In our series of 250 patients of congenital bilateral profound sensory neural hearing loss cochlear implant surgery done in our institute over the period of 2 years by experienced surgeons. Challenges encountered in our study was 31.2% (78 cases) both minor and major challenges. Among these major challenges contribute to 10.2% (8 cases) low incidence, and minor challenges contribute to 89.74%(70 cases) most of them are trivial intra-operative problems that are solved by proper precautions. We encountered major challenges like device failure in 4 cases, revision surgery in 2 patient, 1 patient had labyrinthitis ossificans, 1 patient had wound infection with biofilm formation, and 2 patients had wound gaping for that rotational flap was done. Minor challenges like chordae tympani nerve injury in 15 cases, emissary vein bleeding in 10 cases, seroma 1 case , transient facial palsy in 8 patients, 4 patients presented with post operative otitis media, 2 patients had difficulty in

insertion of electrodes,8 patients had anomalous cochlea,1 patient had hydrocephalus post ventriculoperitoneal shunt implantation done, one patient had perilymph gusher, 5 patients had posterior canal wall injury, one patient had stapes injury, one patient had anomalous facial nerve and undergone cochleostomy, 3 patients had difficulty in round window identification& underwent cochleostomy, 5 patients had edematous middle ear mucosa,one patient had preoperative chronic otitis media as staged procedure implantation done, 3 patients had pre-operative secretory otitis media, one patient had CSF gusher while doing cochleostomy, another 3 patient had CSF leak while drilling for receiver stimulator fixation.

Category		Minor	Major	Total
Anomalous Cochlea	Count	7	0	7
	% within challenges	100.0%	.0%	100.0%
	% within M_m	11.1%	.0%	2%
	% of Total	2%	.0%	2%
Anomalous facial nerve	Count	1	0	1
	% within challenges	100.0%	.0%	100.0%
	% within M_m	1.4%	.0%	.4%
	% of Total	.4%	.0%	.4%
Perilymph gusher	Count	1	0	1
	% within challenges	100.0%	.0%	100.0%
	% within M_m	1.4%	.0%	.4%
	% of Total	.4%	.0%	.4%
Chordae tympani nerve injury	Count	15	0	15
	% within challenges	100.0%	.0%	100.0%
	% within M_m	21.7%	.0%	6.0%
	% of Total	6.0%	.0%	6.0%
Csf gusher	Count	1	0	1
	% within challenges	100.0%	.0%	100.0%
	% within M_m	1.4%	.0%	.4%
	% of Total	.4%	.0%	.4%

Category		Minor	Major	Total
Csf leak while drilling rs fixation	Count	3	0	3
	% within challenges	100.0%	.0%	100.0%
	% within M_m	4.3%	.0%	1.2%
	% of Total	1.2%	.0%	1.2%
Csom & snhl	Count	1	0	1
	% within challenges	100.0%	.0%	100.0%
	% within M_m	1.4%	.0%	.4%
	% of Total	.4%	.0%	.4%
Difficulty in id of rw cochleostomy, asom	Count	1	0	1
	% within challenges	100.0%	.0%	100.0%
	% within M_m	1.4%	.0%	.4%
	% of Total	.4%	.0%	.4%
Difficulty in insertion of electrodes	Count	1	0	1
	% within challenges	100.0%	.0%	100.0%
	% within M_m	1.4%	.0%	.4%
	% of Total	.4%	.0%	.4%
Difficulty in rw id cochleostomy	Count	1	0	1
	% within challenges	100.0%	.0%	100.0%
	% within M_m	1.4%	.0%	.4%
	% of Total	.4%	.0%	.4%
Edematous middle ear mucosa	Count	5	0	5
	% within challenges	100.0%	.0%	100.0%
	% within M_m	7.2%	.0%	2.0%
	% of Total	2.0%	.0%	2.0%
Emissary vein bleeding	Count	10	0	10
	% within challenges	100.0%	.0%	100.0%
	% within M_m	14.5%	.0%	4.0%
	% of Total	4.0%	.0%	4.0%
Facial nerve sheath exposed	Count	2	0	2
	% within challenges	100.0%	.0%	100.0%
	% within M_m	2.9%	.0%	.8%
	% of Total	.8%	.0%	.8%
Facial nerve sheath exposed, wound infection	Count	1	0	1
	% within challenges	100.0%	.0%	100.0%
	% within M_m	1.4%	.0%	.4%
	% of Total	.4%	.0%	.4%

Category		Minor	Major	Total
Hard device failure	Count	0	3	3
	% within challenges	.0%	100.0%	100.0%
	% within M_m	.0%	37.5%	1.2%
	% of Total	.0%	1.2%	1.2%
Hard device failure, asom	Count	0	1	1
	% within challenges	.0%	100.0%	100.0%
	% within M_m	.0%	12.5%	.4%
	% of Total	.0%	.4%	.4%
Injury to posterior canal wall and tympanic membrane	Count	1	0	1
	% within challenges	100.0%	.0%	100.0%
	% within M_m	1.4%	.0%	.4%
	% of Total	.4%	.0%	.4%
Injury to stapes supra structure	Count	1	0	1
	% within challenges	100.0%	.0%	100.0%
	% within M_m	1.4%	.0%	.4%
	% of Total	.4%	.0%	.4%
Labyrinthitis ossificans, difficulty in insertion of electrodes	Count	0	1	1
	% within challenges	.0%	100.0%	100.0%
	% within M_m	.0%	12.5%	.4%
	% of Total	.0%	.4%	.4%
Otitis media	Count	3	0	3
	% within challenges	100.0%	.0%	100.0%
	% within M_m	4.3%	.0%	1.2%
	% of Total	1.2%	.0%	1.2%
Perilymph gusher	Count	1	0	1
	% within challenges	100.0%	.0%	100.0%
	% within M_m	1.4%	.0%	.4%
	% of Total	.4%	.0%	.4%
Posterior canal wall injury	Count	4	0	4
	% within challenges	100.0%	.0%	100.0%
	% within M_m	5.8%	.0%	1.6%
	% of Total	1.6%	.0%	1.6%
Secretory otitis media	Count	3	0	3
	% within challenges	100.0%	.0%	100.0%
	% within M_m	5.7%	.0%	1.6 %
	% of Total	1.2 %	.0%	1.6 %

Category		Minor	Major	Total
Seroma	Count	1	0	1
	% within challenges	100.0%	.0%	100.0%
	% within M_m	1.4%	.0%	.4%
	% of Total	.4%	.0%	.4%
Thermal injury to facial nerve	Count	5	0	5
	% within challenges	100.0%	.0%	100.0%
	% within M_m	7.2%	.0%	2.0%
	% of Total	2.0%	.0%	2.0%
Wound gaping	Count	0	2	2
	% within challenges	.0%	100.0%	100.0%
	% within M_m	.0%	25.0%	.8%
	% of Total	.0%	.8%	.8%
Wound infection	Count	0	1	1
	% within challenges	.0%	100.0%	100.0%
	% within M_m	.0%	12.5%	.4%
	% of Total	.0%	.4%	.4%
No challenges	Count	0	0	174
	% within challenges	.0%	.0%	100.0%
	% within M_m	.0%	.0%	69.0%
	% of Total	.0%	.0%	67.0%
Total	Count	69	8	250
	% within challenges	27.4%	3.2%	100.0%
	% within M_m	100.0%	100.0%	100.0%
	% of Total	27.4%	3.2%	100.0%

Chi-Square Tests

	Value	df	Asymp. Sig. (2-sided)
Pearson Chi-Square	5.040E2a	60	.000
Likelihood Ratio	361.579	60	.000
N of Valid Cases	252		

a. 88 cells (94.6%) have expected count less than 5. The minimum expected count is .03.

Age wise distribution of Radiographic findings in study group Crosstab

Age Group		RF_grp				Total	P value
		Normal	**Sclerosed Mastoid**	**Anamolous Cochlea**	**B/L otomas-toiditis**		
0-2 yrs	Count	18	4	0	0	22	0.259
	% within age_grp	81.8%	18.2%	.0%	.0%	100.0%	
	% of Total	23.4%	5.2%	.0%	.0%	28.6%	
3-4 yrs	Count	31	5	7	4	47	
	% within age_grp	66.0%	10.6%	14.9%	8.5%	100.0%	
	% of Total	40.3%	6.5%	9.1%	5.2%	61.0%	
5-6 yrs	Count	6	0	1	1	8	
	% within age_grp	75.0%	.0%	12.5%	12.5%	100.0%	
	% of Total	7.8%	.0%	1.3%	1.3%	10.4%	
Total	Count	55	9	8	5	77	
	% within age_grp	71.4%	11.7%	10.4%	6.5%	100.0%	
	% of Total	71.4%	11.7%	10.4%	6.5%	100.0%	

Age wise distribution of syndromic and and non syndromic cases in study group

Age Group		Dia_grp			Total	P value
		Non syndromic SNHL	**syndromic SNHL**	**post menin**		
0-2 yrs	Count	22	0	0	22	0.031*
	% within age_grp	100.0%	.0%	.0%	100.0%	
	% of Total	28.6%	.0%	.0%	28.6%	
3-4 yrs	Count	44	3	0	47	
	% within age_grp	93.6%	6.4%	.0%	100.0%	
	% of Total	57.1%	3.9%	.0%	61.0%	
5-6 yrs	Count	7	0	1	8	
	% within age_grp	87.5%	.0%	12.5%	100.0%	
	% of Total	9.1%	.0%	1.3%	10.4%	
Total	Count	73	3	1	77	
	% within age_grp	94.8%	3.9%	1.3%	100.0%	
	% of Total	94.8%	3.9%	1.3%	100.0%	

Chisquare test * shows $p<0.05$

Distribution of speech responses based on syndromic and non syndromic cases in study group

Dia Group		SR_grp			Total	
		speech awareness	**Speech recognition**	**word recognition**		**P value**
Non syndromic SNHL	Count	15	2	55	72	
	% within Dia_grp	20.8%	2.8%	76.4%	100.0%	
	% of Total	20.0%	2.7%	73.3%	96.0%	
syndromic SNHL	Count	2	0	0	2	
	% within Dia_grp	100.0%	.0%	.0%	100.0%	0.121
	% of Total	2.7%	.0%	.0%	2.7%	
post menin	Count	0	0	1	1	
	% within Dia_grp	.0%	.0%	100.0%	100.0%	
	% of Total	.0%	.0%	1.3%	1.3%	
Total	Count	17	2	56	75	
	% within Dia_grp	22.7%	2.7%	74.7%	100.0%	
	% of Total	22.7%	2.7%	74.7%	100.0%	

Significant in terms of speech responses are syndromic SNHL patients have less speech response compared to non-syndromic patients.

RF_grp * SR_grp Crosstabulation

RF Group		SR_grp			Total	
		sound awareness	**Sound recognition**	**word recognition**		**P value**
Normal	Count	6	2	46	54	
	% within RF_grp	11.1%	3.7%	85.2%	100.0%	
	% of Total	8.0%	2.7%	61.3%	72.0%	
Sclerosed mastoid	Count	3	0	5	8	
	% within RF_grp	37.5%	.0%	62.5%	100.0%	
	% of Total	4.0%	.0%	6.7%	10.7%	
Anamolous cochlea	Count	7	0	1	8	
	% within RF_grp	87.5%	.0%	12.5%	100.0%	0.001*
	% of Total	9.3%	.0%	1.3%	10.7%	
B/L otomas toiditis	Count	1	0	4	5	
	% within RF_grp	20.0%	.0%	80.0%	100.0%	
	% of Total	1.3%	.0%	5.3%	6.7%	
Total	Count	17	2	56	75	
	% within RF_grp	22.7%	2.7%	74.7%	100.0%	
	% of Total	22.7%	2.7%	74.7%	100.0%	

Chisquare test * shows $p<0.05$.

Speech responses based on number of frequency of speech cycles

Speech Cycles	N	Mean	Std. Deviation	Std. Error	Mini mum	Maxi mum	Mean rank	P value
Sound awareness	17	22.53	17.749	4.305	5	78	15.15	
Sound recognition	2	27.00	1.414	1.000	26	28	16.75	0.001*
Word recognition	56	54.70	16.630	2.222	4	82	45.70	
Total	75	46.67	21.605	2.495	4	82		

Kruskal wallis test * $p<0.05$

M_m Crosstabulation

		M_m		Total	P value
		minor	major		
Pre op	Count	10	0	10	0.001*
	% within M_m	14.5%	.0%	13.0%	
	% of Total	13.0%	.0%	13.0%	
Intra op	Count	54	1	55	
	% within M_m	78.3%	12.5%	71.4%	
	% of Total	70.1%	1.3%	71.4%	
Post op	Count	5	7	12	
	% within M_m	7.2%	87.5%	15.6%	
	% of Total	6.5%	9.1%	15.6%	
Total	Count	69	8	77	
	% within M_m	100.0%	100.0%	100.0%	
	% of Total	89.6%	10.4%	100.0%	

Chisquare test * shows $p<0.05$

CF * AF Crosstabulation

CF		AF				Total	P value
		Impe dence normal	**Impedence high in all electrodes**	**Impedence high in > 8 electrodes**	**Impe dence b curve**		
Bilateral subtotal central perforation, grade 3 tonsillar hypertrophy	Count	1	0	0	1	1	0.001*
	% within AF	.0%	.0%	.0%	1.4%	1.3%	
	% of Total	.0%	.0%	.0%	1.3%	1.3%	
Implant insitu	Count	0	1	2	0	3	
	% within AF	.0%	50.0%	100.0%	.0%	3.9%	
	% of Total	.0%	1.3%	2.6%	.0%	3.9%	
Implant insitu - swelling	Count	1	0	0	0	1	
	% within AF	1.4%	.0%	.0%	.0%	1.3%	
	% of Total	1.3%	.0%	.0%	.0%	1.3%	
Implant insitu, tm congested and retracted	Count	3	0	0	0	1	
	% within AF	4.2%	.0%	.0%	.0%	4.3%	
	% of Total	4.2%	.0%	.0%	.0%	4.3%	
Implant insitu, tm retracted and congested	Count	0	1	0	0	1	
	% within AF	.0%	50.0%	.0%	.0%	1.3%	
	% of Total	.0%	1.3%	.0%	.0%	1.3%	
Implant insitu, wound gaping	Count	2	0	0	0	2	
	% within AF	2.8%	.0%	.0%	.0%	2.8%	
	% of Total	2.8%	.0%	.0%	.0%	2.8%	
Tm intact	Count	63	0	0	0	63	
	% within AF	90%	.0%	.0%	.0%	81.8%	
	% of Total	81.8%	.0%	.0%	.0%	81.8%	
Tm-retracted	Count	0	0	0	1	1	
	% within AF	.0%	.0%	.0%	33.3%	1.3%	
	% of Total	.0%	.0%	.0%	1.3%	1.3%	
Total	Count	70	2	2	3	77	
	% within AF	100.0%	100.0%	100.0%	100.0%	100.0%	
	% of Total	90.9%	2.6%	2.6%	3.9%	100.0%	

Chisquare test * shows $p<0.05$

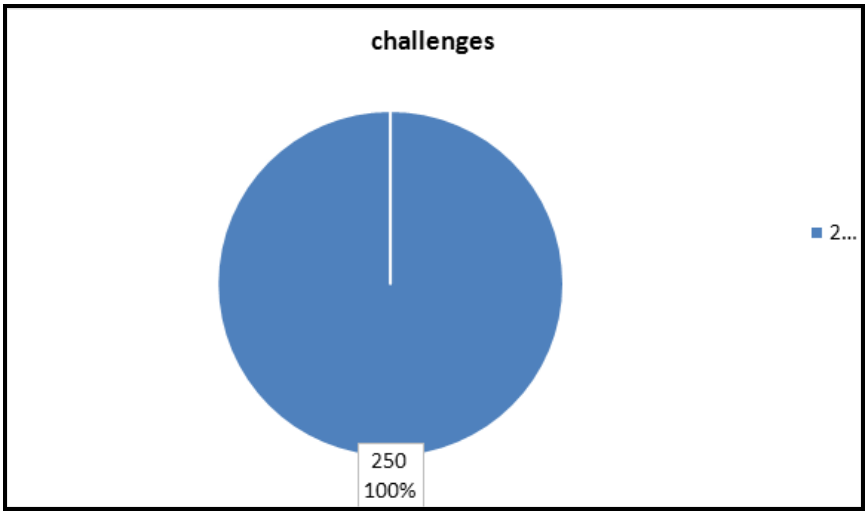
challenges
250
100%
2...

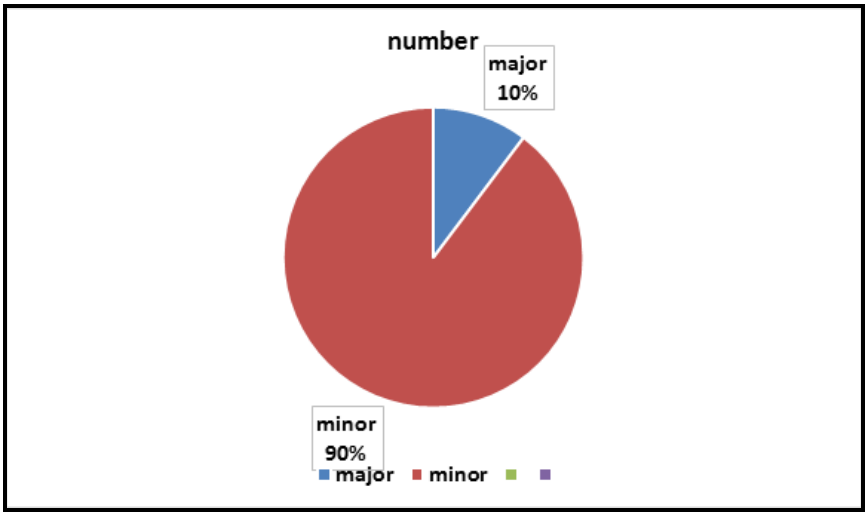
number
major
10%
minor
90%
major
minor

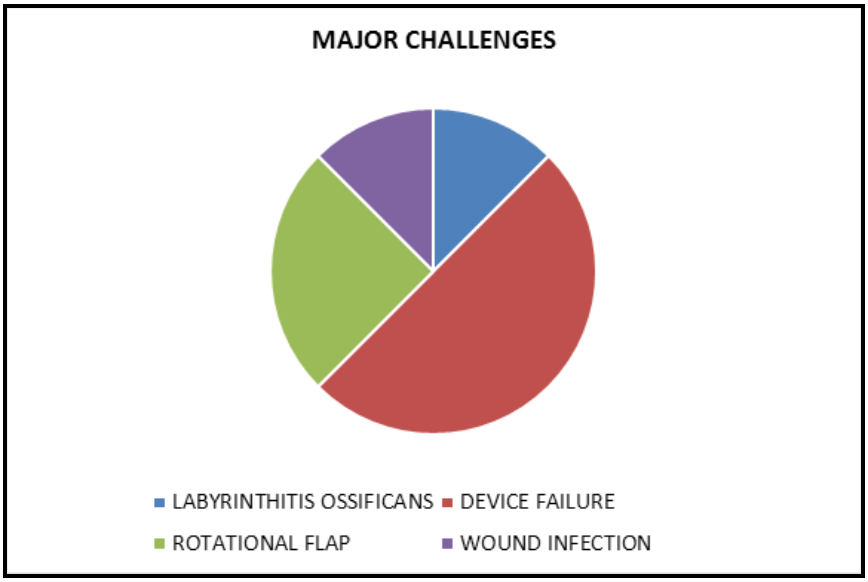
MAJOR CHALLENGES
LABYRINTHITIS OSSIFICANS
DEVICE FAILURE
ROTATIONAL FLAP
WOUND INFECTION

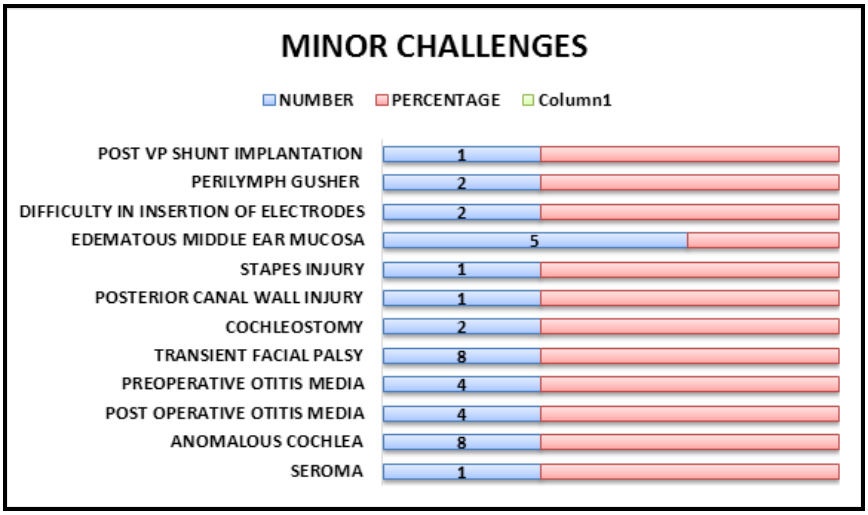
MINOR CHALLENGES
NUMBER
PERCENTAGE
Column1
POST VP SHUNT IMPLANTATION
PERILYMPH GUSHER
DIFFICULTY IN INSERTION OF ELECTRODES
EDEMATOUS MIDDLE EAR MUCOSA
STAPES INJURY
POSTERIOR CANAL WALL INJURY
COCHLEOSTOMY
TRANSIENT FACIAL PALSY
PREOPERATIVE OTITIS MEDIA
POST OPERATIVE OTITIS MEDIA
ANOMALOUS COCHLEA
SEROMA
1
2
2
5
1
1
2
8
4
4
8
1

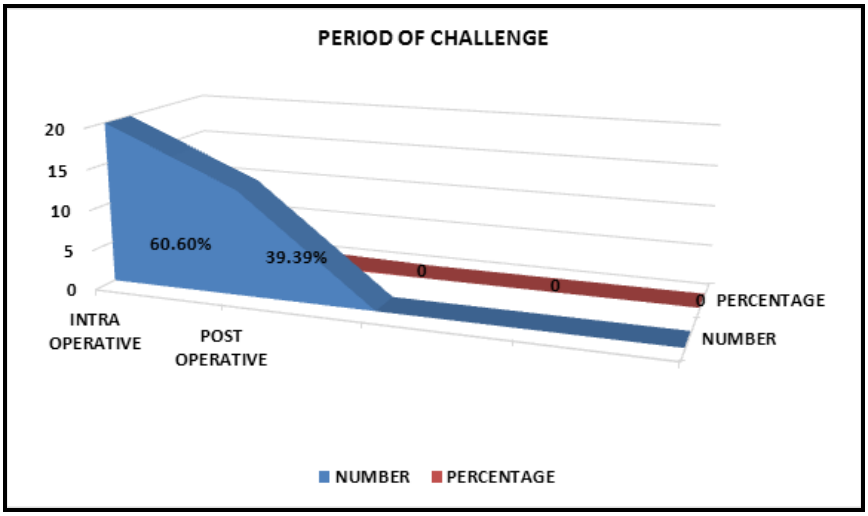
PERIOD OF CHALLENGE
20
15
10
5
0
60.60%
39.39%
0
0
0
INTRA OPERATIVE
POST OPERATIVE
PERCENTAGE
NUMBER
NUMBER
PERCENTAGE

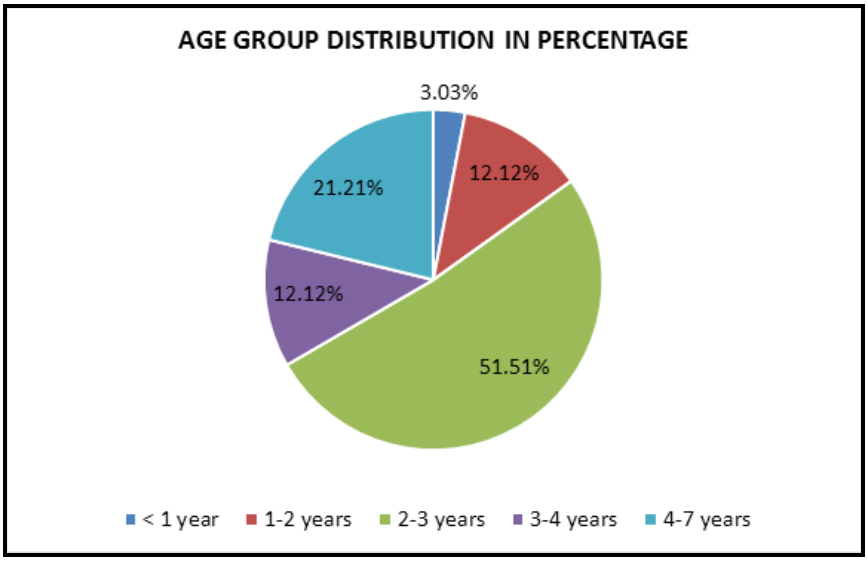
AGE GROUP DISTRIBUTION IN PERCENTAGE
3.03%
12.12%
51.51%
12.12%
21.21%
< 1 year
1-2 years
2-3 years
3-4 years
4-7 years

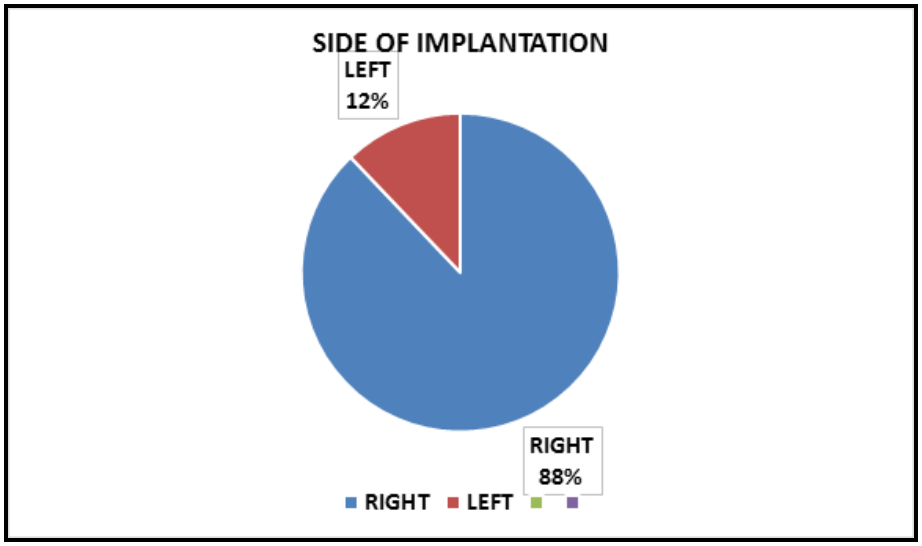
SIDE OF IMPLANTATION
LEFT
12%
RIGHT
88%
RIGHT
LEFT

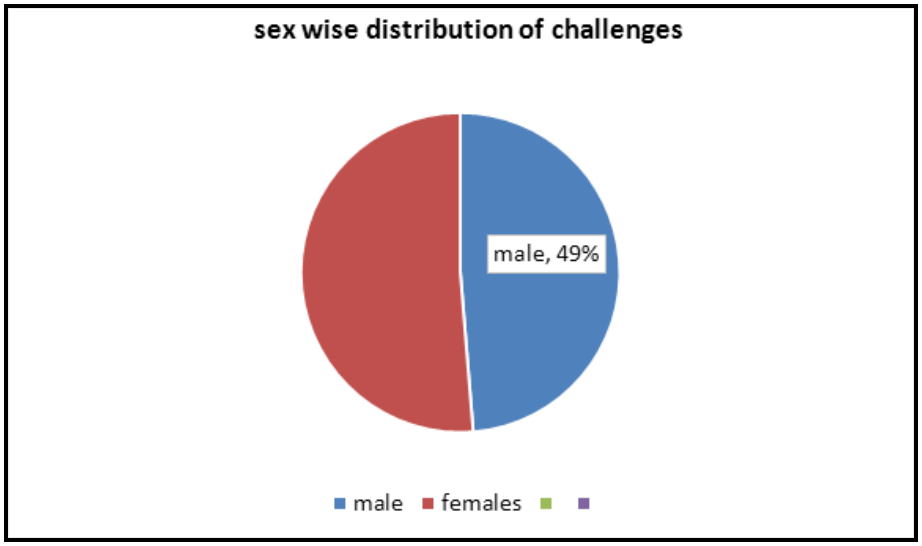
sex wise distribution of challenges
male, 49%
male
females

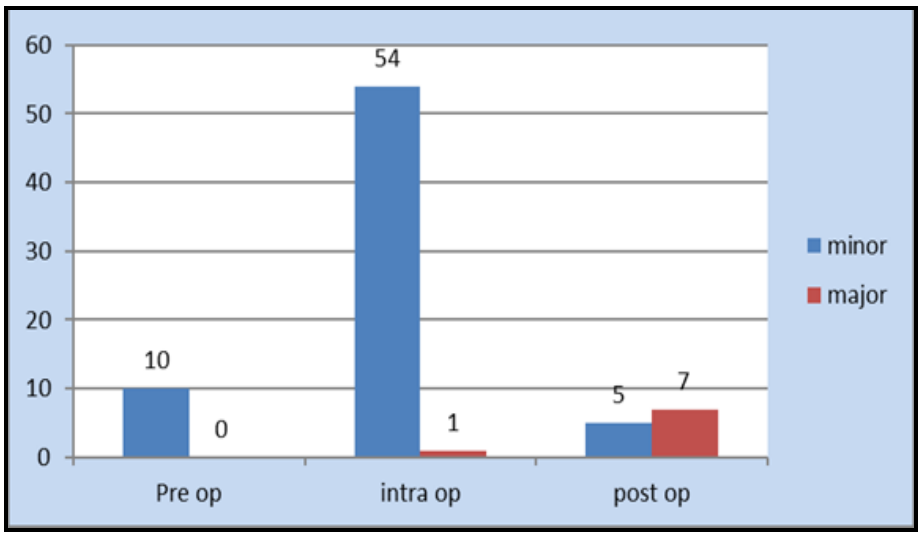
60
50
40
30
20
10
0
10
0
54
1
5
7
Pre op
intra op
post op
minor
major

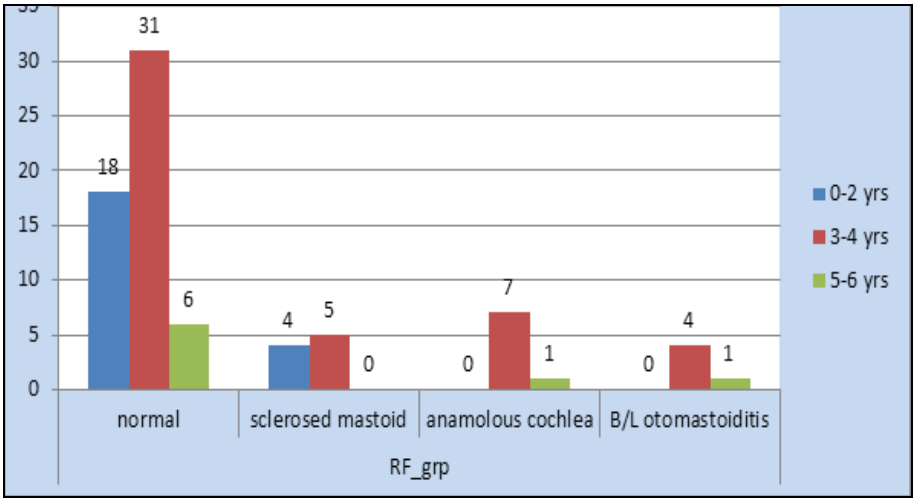
31
30
25
20
18
15
10
6
5
4
5
0
0
7
1
0
4
1
0
0-2 yrs
3-4 yrs
5-6 yrs
normal
sclerosed mastoid
anamolous cochlea
B/L otomastoiditis
RF_grp

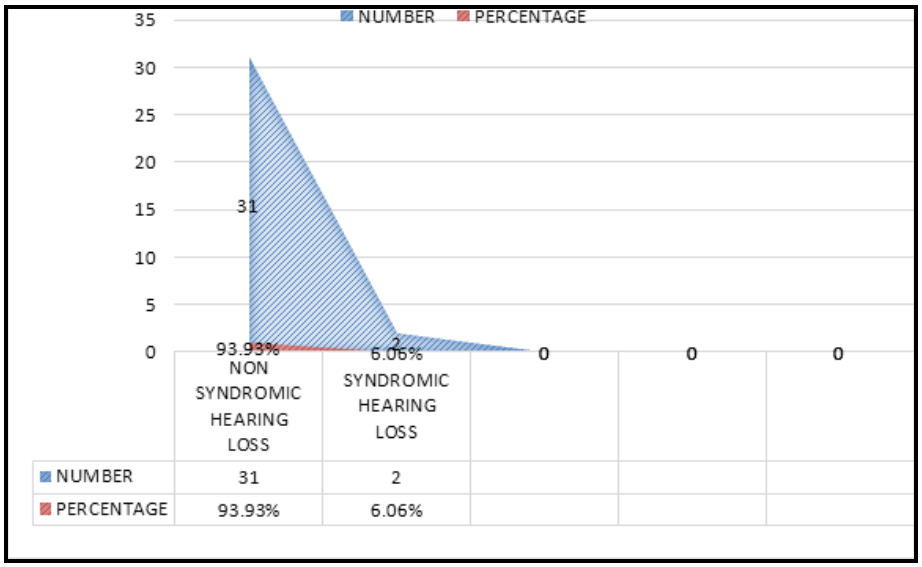
NUMBER
PERCENTAGE
35
30
25
20
15
10
5
0
31
93.93%
2
6.06%
0
0
0
NON SYNDROMIC HEARING LOSS
SYNDROMIC HEARING LOSS
NUMBER 31 2
PERCENTAGE 93.93% 6.06%

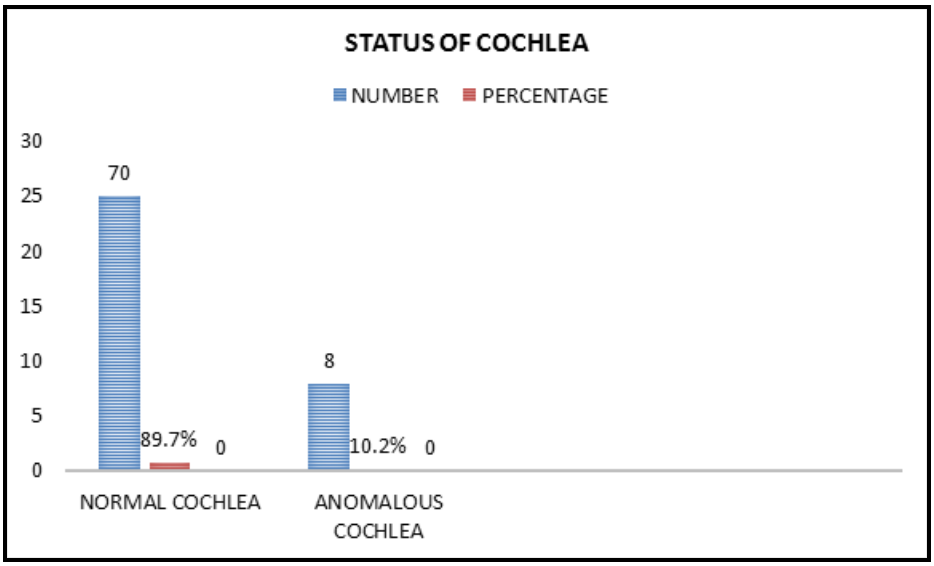
STATUS OF COCHLEA
NUMBER
PERCENTAGE
30
25
20
15
10
5
0
70
89.7%
0
8
10.2%
0
NORMAL COCHLEA
ANOMALOUS COCHLEA

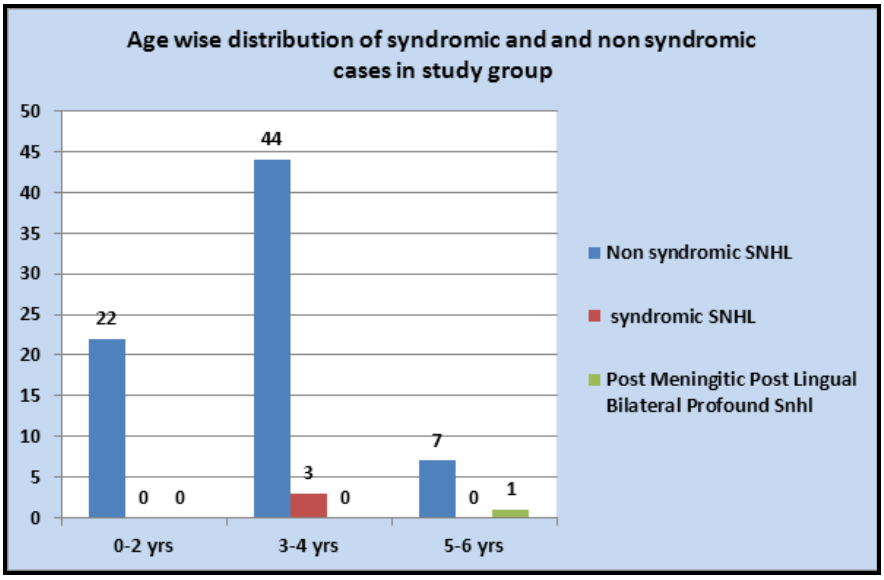
Age wise distribution of syndromic and and non syndromic cases in study group
50
45
40
35
30
25
20
15
10
5
0
22
0
0
44
3
0
7
0
1
0-2 yrs
3-4 yrs
5-6 yrs
Non syndromic SNHL
syndromic SNHL
Post Meningitic Post Lingual Bilateral Profound Snhl

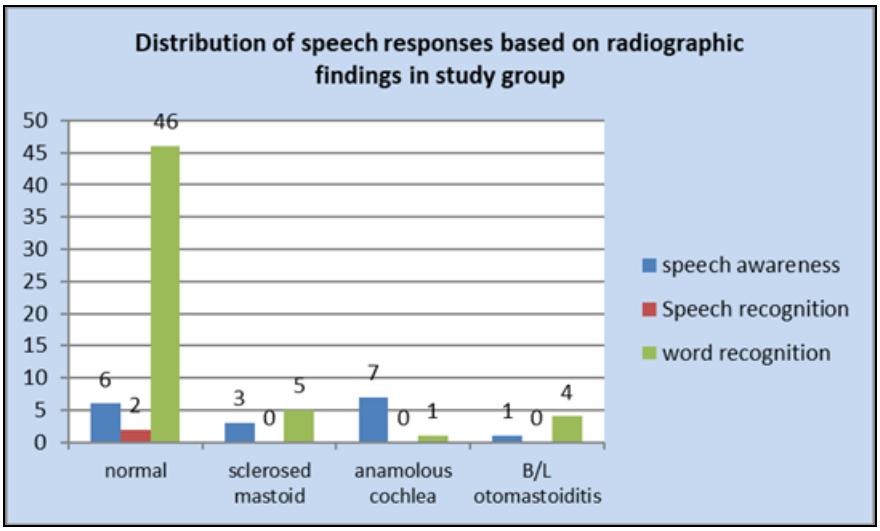
Distribution of speech responses based on radiographic findings in study group
50
45
40
35
30
25
20
15
10
5
0
6
2
46
3
0
5
7
0
1
1
0
4
normal
sclerosed mastoid
anamolous cochlea
B/L otomastoiditis
speech awareness
Speech recognition
word recognition

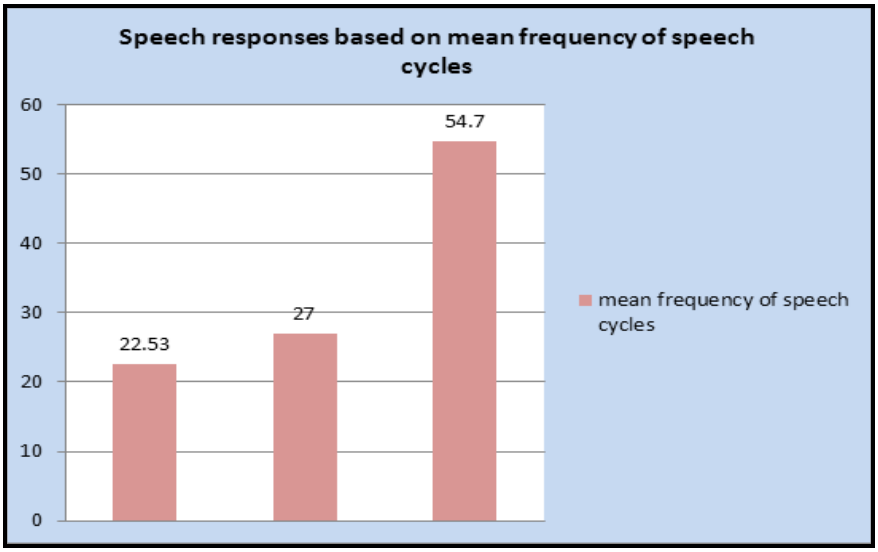
Speech responses based on mean frequency of speech cycles
60
50
40
30
20
10
0
22.53
27
54.7
mean frequency of speech cycles

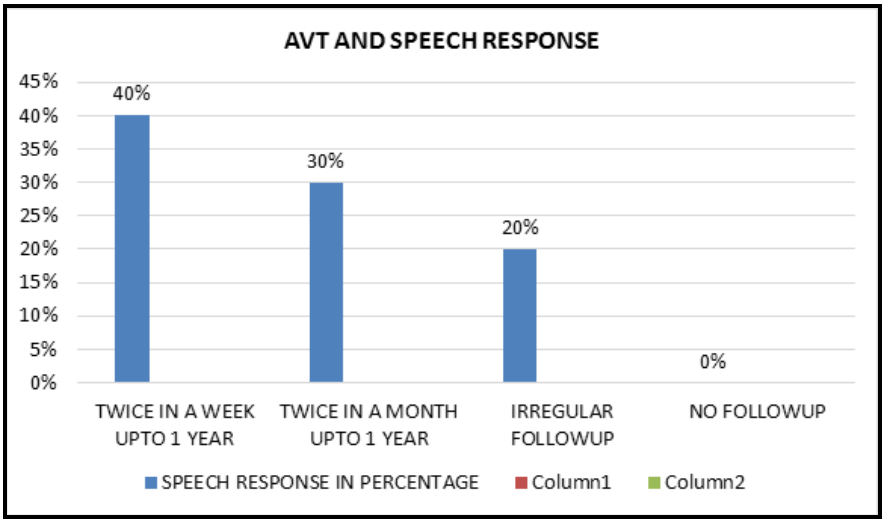
AVT AND SPEECH RESPONSE
45%
40%
35%
30%
25%
20%
15%
10%
5%
0%
40%
30%
20%
0%
TWICE IN A WEEK UPTO 1 YEAR
TWICE IN A MONTH UPTO 1 YEAR
IRREGULAR FOLLOWUP
NO FOLLOWUP
SPEECH RESPONSE IN PERCENTAGE
Column1
Column2

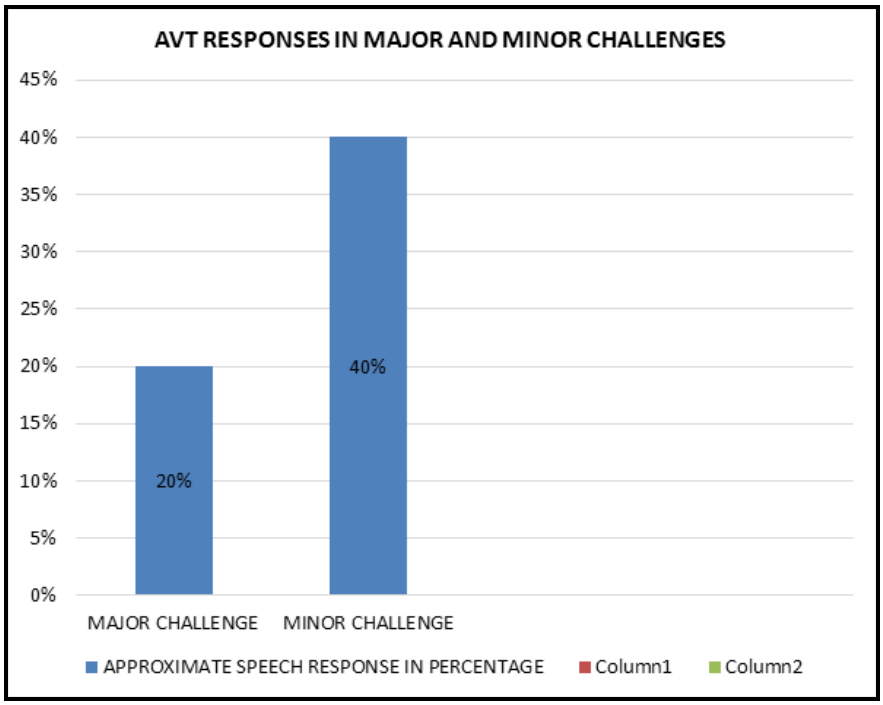
AVT RESPONSES IN MAJOR AND MINOR CHALLENGES
45%
40%
35%
30%
25%
20%
15%
10%
5%
0%
20%
40%
MAJOR CHALLENGE
MINOR CHALLENGE
APPROXIMATE SPEECH RESPONSE IN PERCENTAGE
Column1
Column2

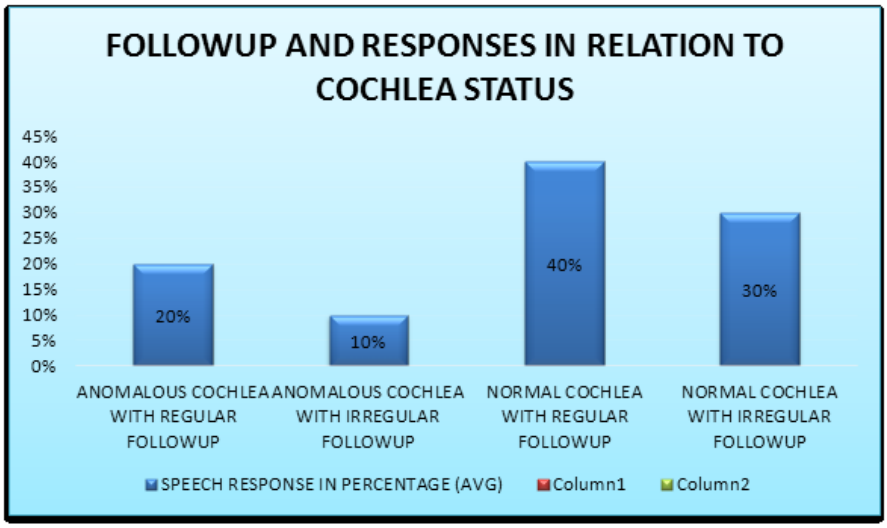
FOLLOWUP AND RESPONSES IN RELATION TO COCHLEA STATUS
45%
40%
35%
30%
25%
20%
15%
10%
5%
0%
20%
10%
40%
30%
ANOMALOUS COCHLEA WITH REGULAR FOLLOWUP
ANOMALOUS COCHLEA WITH IRREGULAR FOLLOWUP
NORMAL COCHLEA WITH REGULAR FOLLOWUP
NORMAL COCHLEA WITH IRREGULAR FOLLOWUP
SPEECH RESPONSE IN PERCENTAGE (AVG)
Column1
Column2

DISCUSSION

Cochlear implantation is generally a safe procedure, every step is a surgical challenge in cochlear implant surgery. Pre-operative evaluation in a profound SNHL child is a most challengeable task. Proper pre-operative assessment with HRCT Temporal bone with cochlear cuts, MRI brain with IAM screening is essential for identification of anatomical variations, anatomy of facial nerve, anomalies of cochlea, presence/absence of cochlear nerve. All these factors help in decide us to know the treatment options like is implant indicated for this patient, if yes which type of electrode insertion needed for the particular patient. Imaging also helps for selection of better ear for implantation pre-operatively. We have evaluated all 250 patients with imaging HRCT Temporal bone and MRI Brain, Syndromic workup, pediatrician, psychiatrist opinion, ophthalmologist opinion, cardiologist opinion, anaesthetist opinion obtained for all patients. Needed cases we obtained neurologist opinion. Vital factors that deciding challenges are anatomic variations, inner ear abnormalities, surgical techniques, and surgeon's experience. All of our cases were immunized with pneumococcal polysaccharide vaccine and meningococcal vaccine prior to surgery. With no incidence of post-operative meningitis in our series. Most of our cases has undergone right cochlear implantation. In cases of anomaly or other factors if that affects right side more we implanted in left ear.

Inspite adequate pre-operative evaluation, awareness of anatomical abnormalities, meticulous surgical techniques and proper post-operative management, still challenges may be encountered. In literature challenges were 4 – 35 %. In our series of 250 patients we encountered challenges in 78 patients which was 31%. Decrease in challenges compared to olden days related to improvement in technology, anatomy-based flap design, learning curve of medical faculty.

In our institute we are routinely following post aural lazy S incision in all cases. All patients belong to pediatric population, so careful avoidance of facial nerve injury by properly selected incisions was followed in all of our cases. In our series none had incision site related facial palsy. This type of incision has less incidence of post-operative wound break down. Younger children usually have thin flaps and more wound break down and more device extrusion. But because of newer arrival of thinner and smaller devices has led this complication down. And also improved flap design has drastically reduce this problem. In our series initially we followed anteriorly placed musculo-periosteal flap. Now we are using posteriorly placed /inferiorly placed musculo-periosteal flap depending upon surgeons preference. Flap failures are less in our series because of properly selected anatomical based flap with adequate covering of entire receiver stimulator.

Proper intra & post-operative antibiotics reduces the chances of wound infection. One patient with major wound infection leads to

explantation, and another patient with wound infection responded well to conservative measures. Wound gaping noted in 1 patient corrected with rotational flap, one another patient had wound dehiscence improved with temparo parietal fascial flap. Our series have comparable results with Bajaj et al & Ahmad Danesi et al studies. They have more flap failure with wide C Post auricular incision and no flap failure with small straight incisions. In our series only one case required explantation. Reduction of magnet strength prevent wound breakdown in selected cases.

In our series we encountered emissary vein bleeding in 10 cases that were controlled by bone wax and surgicel luminal packing, Bleeding is more in pediatric implantation because of more marrow mastoid and more incidence of sclerotic mastoid, and one another problem that leads to bleeding was edematous middle ear mucosa (5 cases), this is also a most common complication in children because of recurrent otitis media. None of our patient had injury to major vessels like carotid injury, injury to sigmoid sinus, injury to jugular bulb. In literature not, much details regarding emissary vein bleeding.

We are routinely following cortical mastoidectomy with facial recess approach, narrow facial recess was encountered in 50 patients of our series, this was associated with more problems like facial nerve injury, chordae tympani injury, tympanic membrane injury, dural injury, difficulty in round window identification. None of our cases had permanent facial nerve palsy, 5 patients had thermal injury to facial nerve which was

recovered within 3-4 weeks days of post-operative period, another 3 patients had nerve sheath injury and temporary facial palsy (House Brackmann grade 3) that was recovered with-in 3 months period with intravenous steroids, physiotherapy. None of our cases had partial / complete nerve transection. Long term results are satisfactory with complete recovery in all of our patients with no evidence of synkinesis and disfigurement in our series. Mohammed Ajalloueyan MD et al in Iran @ 2011 – report of surgical complications in 262 pediatric cochlear implantations results shows 15 cases of temporary facial palsy slighty higher incidence compared to our series. Hoffmann & Cohen – cochlear corporation database for 1905 pediatric implants series reported 18 cases of facial nerve injuries. They have not mentioned about whether the paralysis is permanent or temporary and all. Frederic venial, MD et al (2008) – reliability and complications of 500 consequetive cochlear implantations – 1 case of transient facial palsy – house Brackmann grade 4 as a result of facial nerve (mastoid segment) warming during posterior tympanotomy drilling, & full recovery was noted within 15 days with steroid therapy. In our series lesser incidence of facial nerve injury and only temporary palsy compared to other studies attributed to increased anatomical knowledge of facial nerve and facial recess, usage of facial nerve monitoring in cases of anomalous cochlea helps to avoid the nerve damage in most of the circumstances.

Facial Nerve Injuries – Article Review

Chen et al (1997)	Thom et al (2001) – 888 patients	Selena E.Hemman (2011)	Akbar Pirzadeh et al (2011)	Mohammed Ajallouoyan et al (Dec 2011)	A Danesi et al (2015)	Bradford terry et al (2015)	Our series
2 patients with facial palsy fully recovered in 3 months	10 patients with delayed onset facial palsy	9 % patients had facial nerve sheath exposure, they have concluded intra operative nerve monitoring helps to minimize injury, copious irrigation and prevent inadverent contact of drill shaft with facial nerve minimizes injury	Facial nerve palsy in 1 case recovered in 1 week	Temporary facial weakness in 15 cases	Severe facial nerve damege in 3 cases &managed with cable grafts,20 cases had thermal injury to facial nerve recovered with in 1 week	31 cases of delayed onset facial palsy with probable causes are neural edema, vasospasm, viral reactivation, treatment with steroids, antiviral, physiotherapy for faster resolution of symptoms	5 cases of thermal injury induced facial palsy and 3 cases of injury to nerve sheath all patients recovered completely with in 3 months

In our series we encountered chordae tympani injury in 10 patients with no significant post-operative taste disturbances. 5 patients had canal wall injury and one patient with tympanic membrane injury had temporalis fascia grafting, with no evidence of post-operative cholesteatoma formation on 6 months follow-up period. All patient had well healed neo tympanum in 6 months follow-up period. Not much data regarding posterior canal wall injury and grafting in literature.

CSF Leak encountered in one case of anomalous cochlea after cochleostomy it was controlled with tight soft tissue plug. 3 patients had CSF leak at the site of cranial bone drilling for fixation of receiver stimulator, controlled with bone wax in all 3 cases. None of our patients had tegmen and dural injury with CSF Leak. Increased risk of CSF leak and perilymph gusher in cases of all types of anomalous cochlea should be anticipated before surgery. We concluded proper pre-operative radiological diagnosis with intra operative measures like small cochleostomy, use of conical based external arrays and proper sealing of the inner ear helps to prevent CSF leak in anomalous patients. DC Gheorghe et al (2015 – complications in cochlear implant surgery) reported 2 cases of CSF gusher in anomalous cochlea. Ahmad Daneshi et al (2015) – complications in a series of 4400 pediatric cochlear implantation, reported 17 cases of intra-operative CSF leakage, mostly with inner ear anomalies. They have mention that this is not a major concern, and usually stops with hyperventilation. Selena E. Heman-Ackah MD et al (2011) –

reported CSF fistula in 1% pediatric patients after implantation, secondary meningitis only in small percentage cases. CSF fistulas can be prevented by packing cochleostomy around electrode to prevent leak.

Perilymph gusher was noted in one patient with endolymphatic sac dilatation, it was controlled with conservative measures. None of our patient had post-operative CSF leakage.

Four patients had difficulty in round window identification and underwent cochleostomy. Presence of retro cochlear, infra cochlear air cells, hypotympanic air cells mimics the appearance of round window niche. These false perceptions can be overcome by presence of round window reflex & antero superiorly placed round window niche, hypo tympanic air cells always point antero inferiorly and round window reflex absent in air cells. Batman et.al (1995) described retro cochlear cells can mimic round window in some cases in his series on Cochlear implantation problems and surgical challenges. All literature results shows Cochleostomy usual site is antero inferior to round window membrane, we concluded that we are routinely doing cochleostomy for cases with difficulty in round window identification, so practically difficult to identify round window area. We routinely perform cochleostomy 2.5mm inferior to oval window (oval window taken as a constant landmark)

Two patients had difficulty in electrode insertion. 8 electrodes inserted successfully in these 2 patients. Forceful insertion avoided in these 2 cases to assure atraumatic electrode insertion. We are routinely following atraumatic

method for electrode insertion. Michel A.Mecca et al – complication of cochlear implantation surgery (2003) mentioned the optimal position of electrodes along the perimodiolar and closer to spiral ganglion cells for target stimulation, deeper insertion is needed for low frequency perception. DC Gheorghe et al – complications in cochlear implant surgery (2015) – reported that cochlea that prevent full electrode array insertion can be challenging, use of short array, partial insertion, voluntary inactivation of some electrodes post-operatively gives good results.

Jiam NT et al (2016)	**Adunka et al (2014)- cochleostomy versus RW insertions**	**Thomas J Balkany et al (2010) – perceived angle of RW affects electrode insertion**	**In our series**
Cochleostomy associated with higher likelihood of interscalar exertions compared to RW insertion	No statistically significant difference in post-operative preservation of residual hearing in RW versus cochleostomy techniques.	When hearing preservation is the goal RW insertion is the valid option, less traumatic insertion at 137-degree, traumatic insertion at 147 degree.	We performed cochleostomy in 4 cases (only in cases with difficulty in RW identification), we are routinely following atraumatic RW insertion of electrodes

Revision surgery needed in 6 of our patients, 4 patients had device failure (Frederic Venail MD et al (2017) – in his series of 500 Consequetive cochlear implantations reliability and complications – results shows 30 cases of device failure, in which 13 cases electronic failure was the cause. Some patients had history of retro auricular pain as a primary manifestation of device

failure. In our series among 4 cases 3 patients had history of fall injury followed by detoriation of responses. Re-implantation is the only acceptable treatment option in these cases.

We encountered labyrinthitis ossificans in one patient – post meningitic labyrinthitis ossificans is a challenging problem, if early intervention to correct sensory neural hearing loss not taken it can lead to total cochlear ossification rapidly, in case of total ossification auditory brainstem implant is the option. Some studies promote use intra venous steroids in prevention of ossification process with no proven results. In our series patient required revision surgery and basal turn drill out for insertion of electrodes. Child is now having good speech discrimination scores. C.Batman et al (2001) – cochlear implantation in 67 patients – mentioned in his series that labyrinthine ossificans restricting the depth of insertion of electrode array into cochlea. They have implanted 12 post meningitic patients with 3 patients had labyrinthitis among them. They have mentioned that drilling 1.5mm inferior to pyramidal process is needed in case of round window obliteration, continuous drilling along circum modiolar trough is needed for complete electrode insertion. R.JAIN,S.K.MUKHERJI et al (2002) he mentioned that pre-operative plain films and HRCT can not detect ossification in post meningitic patients with labyrinthitis, So pre implant evaluation with T2 weighted MRI for identification of fibrosis or ossification that can not be detected with CT.

Because of more resistant wound infection one patient needs explantation in our series (infection that was not responded to intensive medical treatment and rotational flap 2 times), So we proceeded with explantation & after a period of 6 months implantation in opposite ear, after proper infection control measures. We are routinely following cortical mastoidectomy with facial recess approach, narrow facial recess was encountered in 50 patients of our series, this was associated with more problems like facial nerve injury, chordae tympani injury, tympanic membrane injury, dural injury, difficulty in round window identification. None of our cases had permanent facial nerve palsy, 5 patients had thermal injury to facial nerve which was recovered within 3-4 weeks days of post-operative period, another 3 patients had nerve sheath injury and temporary facial palsy (House Brackmann grade 3) that was recovered with-in 3 months period with intravenous steroids, physiotherapy. None of our cases had partial / complete nerve transection. Long term results are satisfactory with complete recovery in all of our patients with no evidence of synkinesis and disfigurement in our series. Mohammed Ajalloueyan MD et al in Iran @ 2011 – report of surgical complications in 262 pediatric cochlear implantations results shows 15 cases of temporary facial palsy slighty higher incidence compared to our series. Hoffmann & Cohen – cochlear corporation database for 1905 pediatric implants series reported 18 cases of facial nerve injuries. They have not mentioned about whether the paralysis is permanent or temporary and all. Frederic venial, MD et al (2008) – reliability and complications of 500

consequetive cochlear implantations – 1 case of transient facial palsy – house Brackmann grade 4 as a result of facial nerve (mastoid segment) warming during posterior tympanotomy drilling, & full recovery was noted within 15 days with steroid therapy. In our series lesser incidence of facial nerve injury and only temporary palsy compared to other studies attributed to increased anatomical knowledge of facial nerve and facial recess, usage of facial nerve monitoring in cases of anomalous cochlea helps to avoid the nerve damage in most of the circumstances.

Batman C et al, (2001) – cochlear implantation surgical complications series, in his series he described most significant complications were flap related wound break down. They have concluded that use of extended end aural flap design of hannover, proper flap design and size. Additional measures like flap incision must be well away from the implant and properly sutured without tension. Care of the flap is important that it should not be crushed by instruments, should be kept warm and moist during procedure. Frederic Venail, MD et al – reliability & complications of 500 consecutive cochlear implantations - re implantation in 3 cases with infections un responsive to intensive medical treatment, all 3 cases re implanted in his series in opposite ear 1-3 months after infection has cleared. All of this related to skin flap break down and subsequent exposure of receiver. Akbar Pirzadeh et al (2011) – complications related to cochlear implant, reported flap failures one of the most common complication, which resolved by post auricular incision instead wide C incision. Mohammed Ajalloueyan MD et al – report of 262 pediatric

cochlear implantation complications in Iran – Reported 2 cases of wound infection and one case of post-operative meningitis. They concluded infections makes important contributions to surgical challenges either directly or indirectly. Fortunately, majority of infections treated with no adverse effects on device because of early identification and aggressive treatment of infections.

Device failures are more common in children because of the tendency to recurrent fall injury leads to hard device failure. comparable results with Frederic venial MD et al studies (2008) revision surgery in their series were hard device failure, soft device failure, infection, trauma. Rabindra R. Tambyraja, MD et al (2005) – cochlear implant complications – proposed new entry for MAUDE (manufacturer user facility and distributor experience) Database for malfunctioning devices. Categorization and rationalization of device related and patient related factors were highlighted in this study. Luiz Rodolpho Penna Lima Junior et al – postoperative complications in cochlear implant patients of Rio Grande do Norte – Brazil – in 250 patients reported 4 cases of device failure comparable results to our study, 3 patient undergone revision surgery and 1 patient refused revision surgery.

One of our patients had seroma noticed in 15th post-operative day, aspiration shows serous material, subsided with aspiration and conservative methods like tight compressive mastoid dressing, local wound care and systemic antibiotics. Sheng – Dean Luo et al – mastoid pressure dressing for cochlear implantation in 92 patients (2008) found that no significant benefits

for use of mastoid pressure dressing following implantation, there is associated increased incidence of peri orbital edema, forehead skin necrosis from restricted lymphatic and venous drainage as a complication of pressure dressing. So, they concluded that after un complicated implantation abandoning of pressure bandages. Taryn Davids, MD et al (2009) – soft tissue complication after small incision cochlear implantation in pediatric age group – in 462 patients – mentioned their series about pre-operative vaccination, prophylactic antibiotics, strict aseptic technique all these helps in reducing the risk of surgical site infection. Smaller incision and thinner skin flap like minimal access approaches minimize the risk of soft tissue infection by reducing dead space, vascular compromise, decreasing post-operative edema, and permitting early device activation. In addition, creation of well for receiver stimulator fixation prevents device migration and reducing the potential of soft tissue infections. Selena E. Heman-Ackah, MD et al (2011) – pediatric cochlear implantation and complications – reported wound infection is the most commonly reported challenge presenting as wound infection or otitis media. They concluded that peri-operative antibiotics and compressive sterile dressing reduce this complication.

In our series One child had hydrocephalus undergone ventriculo-peritoneal shunt followed by cochlear implantation in opposite ear. With measures followed to avoid cautery during implant surgery, and implantation done in opposite ear for that patient. No such challenge encountered in literature.

Post-operative otitis media we encountered in 4 of our patients, all 4 patients effectively managed with higher intravenous antibiotics, none needed revision surgery/cholesteatoma. Frederic Venail, MD (2008) – Reliability and complications of 500 cochlear implantations, reported that slightly higher incidence of post-operative otitis media, device failure, magnet displacement in children compared to adults, in his series post-operative otitis media 5 cases managed conservatively with systemic oral antibiotics.

None of our cases experienced electrode/device migration, magnet stimulation, facial nerve stimulation in the post-operative period. Device migration can be avoided by proper fixation of receiver stimulator by sutures, adequate flap covering and drilling of temporal bone adequately.

Above all proper technical guidance from skillful mentor is necessary for successful ci avoiding complications. Even though mentor is not available within the theatre he has to be available with in the theatre during implantation procedure

Post-operative radiological confirmation of implant position with x-ray mastoid is taken for all patients. Most of all patients were followed upto 1 year post-operative period with audio-verbal therapy and proper maping post-operatively. Speech responses were assessed in all patients and compared in patients with challenge and without challenges by a good audiologist team and ENT surgeons.

CONCLUSION

In summary, cochlear implantation is a safe surgical procedure with good results in terms of hearing improvement. Power of our study is that in our institute all operations were performed in homogenous pediatric patient population with well-trained surgeons, along with adequate post-operative follow-up which aids in early identification of all those challenges. Overall challenge rates were comparable to literature but with lesser major challenges. Proper selection of the patients by early identification of hearing loss and surgical intervention by cochlear implantation may aid in good post-operative hearing outcomes. Incidence of major complications are very low and most of the minor complications responded well to conservative measures. Thorough pre-operative radiological assessment of middle ear and inner ear anatomy helps in taking adequate precautions during cochlear implant surgery with regards to appropriate length of cochlea measurements in deciding the type of electrode for that particular patient, avoiding challenges, and getting a good functional outcome. Extrusion of the cochlear implant device is avoided by proper methods for fixation of receiver stimulator adequate depth and adequate fixing of device using fixation suture with ethibond. Complications of prolene sutures extruding through skin was obviated by ethibond sutures usage. Posterior canal wall injury can be managed by temporalis fascia grafting. Round window identification through the facial recess approach can be safely done by following the precautions discussed in the surgical

technique. Adequate saline irrigation, proper sized cutting and diamond burrs, usage of skeeter burr while drilling facial recess for round window identification helps to avoid facial nerve injury both mechanically and thermally. Avoidance of unnecessary Cochleostomy as round window insertion of electrodes is the natural atraumatic method for electrode insertion.

Cochlear implant surgery can be done as staged procedure in cases of CSOM complicating profound SNHL. However, the surgeons must be familiar with all these challenges in order to prevent minor and major challenges. Various challenges are highlighted and techniques evolved in order to overcome those challenges.

Benefits outweigh the risk, so it is worth stressing that implant procedure directly associated with surgeon's continuous education and training measures. So, surgeon have to work to avoid these challenges and be familiar enough to treat them. Based on our experience regional center of excellence for cochlear implant surgery has to be developed in future, so that skill of cochlear implant surgery will improve, and also national wide successful cochlear implant program is possible in near future.

All cochlear implant center should have adequate audiologist backup. The audiologist must specially be trained in neural response telemetry, audio verbal therapy, switch on, mapping and management in trouble shooting.

BIBLIOGRAPHY

1) Sennaroglu L, saatci – A new classification for cochleo vestibular malformations. Laryngoscope 2002

2) Gelfand SA. Essentials of Audiology. Second edition 2007, thieme medical publishers

3) Cochlear implant. Available at https://en.wikipedia.org/ wiki/ cochlear implant

4) Susan B Waltzman, J Thomas roland Jr,cochlear implants. Third edition 2014. Thieme publications

5) Cohen NL, Hoffman RA, Stroschein M. medical or surgical complications (1988-97)

6) Kempf HG, Johann K, Lenarz – complications in pediatric cochlear implant surgery

7) Scott brown text book 7th edition

8) Glasscock shambaugh text book 6th edition

9) Kameswaran M , Raghunandhanan S – outcomes of cochlear implant surgery

10) Kempf HG et al – complications of cochlear implant surgery in children (1997 Nov 18)

11) Turk ORL Arsivi, 2001; 39 (2): 89-95 – C.Batman – Cochlear implantation: patients, problems and surgical complications

12) R.JAIN.S.K.MUKHERJI – Cochlear implant failure: Imaging evaluation of the electrode course (2002)

13) Michel A.Mecca et al(April 6,2003) – complication of cochlear implant surgery – case report

14) Rabindra R.Tambyraja,et al MD,(March 2005) - COCHLEAR IMPLANT COMPLICATIONS

15) Sheng – Dean Luo (2009) – Mastoid pressure dressing for cochlear implantation

16) Taryn Davids et al(May 2009) – Soft tissue complications after small incision pediatric cochlear implantation (2009)

17) Luiz Rodolpho Penna Lima junior – post operative complications in implanted patients in the cochlear implant program of Rio Grande do Norte – Brazil (Jan 2010)

18) Akbar Pirzadeh et al (July 2011) – Complications related to cochlear implants: experience in Tehran (2011)

19) Selena E.Heman – Ackah et al(Aug 2011) – pediatric cochlear implantation: candidacy evaluation, medical and surgical considerations and expanding criteria

20) Mohammad Ajallouoyan et al(Dec 2011) – a report of surgical complications in series of 262 consecutive pediatric cochlear implantations in Iran

21) Joseph L.Russell et al – cochlear implantation (October 2012)

22) Kadir Serkan Orhan et al(4 Feb 2012) – Complications & their management following pediatric cochlear implantation (Sep 2005-May 2010)

23) Danesi et al.,(24 May 2015) Complications in a series of 4400 pediatric cochlear implantation

24) DC Gheorghe and A Zamfir – chiru – Anton (26 May 2015) – Complications in cochlear implant surgery

25) Bradford Terry et al – Delayed complications after cochlear implantation (Nov 2015)

APPENDIX
ABBREVIATIONS

ART	:	Auditory Response Telemetry
AVT	:	Audio Verbal Therapy
BERA	:	Brain Stem Evoked Response Audiometry
CI	:	Cochlear Implant
CT	:	Computed Tomography
dB	:	Decibels
EABR	:	Evoked Auditory Brainstem Response
IA	:	Impedence Audiometry
MRI	:	Magnetic Resonance Imaging
NRT	:	Neural Response Telemetry
OAE	:	Oto Acoustic Emissions
PTA	:	Pure Tone Audio Metry
SOM	:	Secretory Otitis Media
SD	:	Standard Deviation
SE	:	Standard Error
SNHL	:	Sensory Neural Hearing Loss

PROFORMA

NAME : AGE/SEX:

IP/OP NO :

ADDRESS : MOBILE NO:

SOCIOECONOMIC STATUS:

DOA: DOS: DOD:

COMPLAINTS:

CLINICAL FINDINGS:

RIGHT EAR LEFT EAR

TYMPANIC MEMBRANE & MIDDLE EAR STATUS

INVESTIGATIONS:

1)HRCT TEMPORAL BONE:

2)MRI BRAIN wITH IAC CUT

3)AUDIOLOGICAL EVALUATION:

DIAGNOSIS:

PROCEDURE:

INTRAOPERATIVE FINDINGS:

POSTOPERATIVE FOLLOW UP:

X-RAY MASTOID:

NO. OF. VISIT	IMPLANT STATUS	SPEECH RESPONSE	REMARKS

INSTITUTIONAL ETHICS COMMITTEE
MADRAS MEDICAL COLLEGE, CHENNAI 600 003

EC Reg.No.ECR/270/Inst./TN/2013
Telephone No.044 25305301
Fax: 011 25363970

CERTIFICATE OF APPROVAL

To

Dr.M.Kalai
PG in M.S. ENT
Upgraded Institute of Oto Rhino Laryngology
Madras Medical College
Chennai 600 003

Dear Dr.M.Kalai,

The Institutional Ethics Committee has considered your request and approved your study titled **"CHALLENGES IN COCHLEAR IMPLANT SURGERY AND POST-OPERATIVE FOLLOW-UP" - NO.27052017**

The following members of Ethics Committee were present in the meeting hold on **02.05.2017** conducted at Madras Medical College, Chennai 3

1.Prof.Dr.C.Rajendran, MD.,	:Chairperson
2.Prof.R.Narayana Babu, MD.,DCH.,Dean, MMC,Ch-3	:Deputy Chairperson
3.Prof.Sudha Seshayyan,MD., Vice Principal,MMC,Ch-3	:Member Secretary
4.Prof.S.Suresh,MS.,Prof.of Surgery,MMC, Ch-3	: Member
5.Prof.S.Mayilvahanan,MD,Director,Inst. of Int.Med,MMC, Ch-3	: Member
6.Tmt.J.Rajalakshmi, JAO,MMC, Ch-3	: Lay Person
7.Thiru S.Govindasamy, BA.,BL,High Court,Chennai	: Lawyer
8.Tmt.Arnold Saulina, MA.,MSW.,	:Social Scientist

We approve the proposal to be conducted in its presented form.

The Institutional Ethics Committee expects to be informed about the progress of the study and SAE occurring in the course of the study, any changes in the protocol and patients information/informed consent and asks to be provided a copy of the final report.

Member Secretary – Ethics Committee

MEMBER SECRETARY
INSTITUTIONAL ETHICS COMMITTEE
MADRAS MEDICAL COLLEGE
CHENNAI-600 003

S. NO	PATIENT NAME	AGE/SEX	CLINICAL FINDINGS	AUDIOLOGICAL	RADIOLOGICAL FINDINGS	DIAGNOSIS	PROCEDURE
1	ANBU	3Y/M	TM-RETRACTED	IMPEDENCE - B CURVE	BILATERAL OTOMASTOIDITIS	CONG SNHL	RIGHT COCHLEAR IMPLANT
2	VIGNESH	3Y/M	TM-CONGESTED&RETRACTED	IMPEDENCE- B CURVE-2	BILATERAL OTO MASTOIDITIS	CONG SNHL	RIGHT CI
3	SURENDAR	4Y/M	TM-CONGESTED & RETRACTED	IMPEDENCE - B CURVE- 2	BILATERAL OTO MASTOIDITIS	CONG SNHL	RIGHT CI
4	MUKIL ARASU	3Y/M	BILATERAL SUBTOTAL CENTRAL	BERA,OAE- ABSENT	BILATERAL OTO MASTOIDITIS	CONG SNHL	TONSILLECTOMY-RIGHT
5	IGRA FATHIMA	1Y/FCH	TM- INTACT	BERA,OAE- ABSENT	NORMAL	CONG SNHL	RIGHT CI
6	VIMAL RAJ	3Y/M	TM INTACT	BERA,OAE- ABSENT	NORMAL	CONG SNHL	RIGHT CI
7	INDHUMATHY	6Y/F	IMPLANT INSITU,WOUND GAPING	IMPEDENCE NORMAL	IMPLANT INSITU	POST IMPLANTATION	TEMPAROPARIETAL
8	RITHIKA DEVI	4Y/F	IMPLANT INSITU- WOUND GAPING	IMPEDENCE NORMAL	IMPLANT INSITU	POST CI- WOUND GAPING	ROTATIONAL FLAP
9	SAMEERA	2Y/FCH	IMPLANT INSITU - SWELLING AT UPPER	IMPEDENCE NORMAL	IMPLANT INSITU	POST CI- SEROMA	ASPIRATION , INCISION AND
10	JACKSON	3Y/M	TM INTACT	BERA,OAE- ABSENT	NORMAL	CONG SNHL	RIGHT CI
11	KAVIYA	4Y/F	TM INTACT	BERA,OAE - ABSENT	NORMAL	CONG SNHL	RIGHT CI
12	MOUNISHWARAN	3Y/MCH	TM INTACT	BERA,OAE - ABSENT	NORMAL	CONG SNHL	RIGHT CI
13	VIDHYA ROOBINI	3Y/F	TM INTACT	BERA,OAE- ABSENT	NORMAL	CONG SNHL	RIGHT CI
14	SANTHOSH	3/M	TM INTACT	BERA,OAE- ABSENT	NORMAL	CONG SNHL	RIGHT CI
15	RAJINA DEVI	2Y/F	TM INTACT	BERA,OAE- ABSENT	NORMAL	CONG SNHL	RIGHT CI
16	DURGA	2Y/F	TM INTACT	BERA,OAE - ABSENT	NORMAL	CONG SNHL	RIGHT CI
17	THIRUVASAN	3Y/M	TM INTACT	BERA,OAE - ABSENT	NORMAL	CONG SNHL	RIGHT CI
18	KEERTHANA	4Y/F	TM INTACT	BERA,OAE - ABSENT	NORMAL	CONG SNHL	RIGHT CI
19	HARINI	2Y/F	TM INTACT	BERA,OAE - ABSENT	NORMAL	CONG SNHL	RIGHT CI
20	NAVEEN	2Y/M	TM INTACT	BERA,OAE - ABSENT	NORMAL	CONG SNHL	RIGHT CI
21	KUMARAN	5Y/M	TM INTACT	BERA,OAE- ABSENT	NORMAL	CONG SNHL	RIGHT CI
22	MOHAMMED HAMEED	2Y/M	TM INTACT	BERA,OAE - ABSENT	NORMAL	CONG SNHL	RIGHT CI
23	DHIVYA DHARSHINI	3Y/F	TM INTACT	BERA,OAE- ABSENT	NORMAL	CONG SNHL	RIGHT CI
24	YOGESH	4Y/M	TM INTACT	BERA,OAE - ABSENT	NORMAL	CONG SNHL	RIGHT CI
25	SRI VIGNESH	3Y/M	TM INTACT	BERA,OAE - ABSENT	BILATERAL COMMON CAVITY,	CONG NON SYNDROMIC	LEFT CI
26	OM PRAKASH	2Y/M	TM INTACT	BERA,OAE - ABSENT	NORMAL	CONG SNHL	RIGHT CI
27	PRADEEP	3/M	TM INTACT	BERA,OAE - ABSENT	NORMAL	CONG SNHL	RIGHT CI
28	KOMAL	5Y/M	TM INTACT	BERA,OAE - ABSENT	NORMAL	CONG SNHL	RIGHT CI
29	HARISH	3Y/M	TM INTACT	BERA,OAE - ABSENT	BILATERAL ENDOLYMPHATIC	CONG SNHL	RIGHT CI
30	ASWITHA	3/F	TM INTACT	BERA,OAE - ABSENT	NORMAL	CONG SNHL	RIGHT CI
31	JEEVASRI	1Y/F	TM INTACT	BERA,OAE - ABSENT	NORMAL	CONG SNHL	RIGHT CI
32	ASWITHA	3Y/F	TM INTACT	BERA,OAE - ABSENT	NORMAL	CONG SNHL	RIGHT CI
33	YAZHINI	2Y/F	TM INTACT	BERA,OAE - ABSENT	NORMAL	CONG SNHL	RIGHT CI
34	MANOJ	4Y/M	TM INTACT	BERA,OAE - ABSENT	NORMAL	CONG SNHL	RIGHT CI
35	SAJITH KUMAR	3Y/M	TM INTACT	BERA,OAE - ABSENT	NORMAL	CONG SNHL	RIGHT CI
36	KALYANA SUNDARAM	2Y/M	TM INTACT	BERA,OAE- ABSENT	NORMAL	CONG SNHL	RIGHT CI
37	SHARMILA	3Y/F	TM INTACT	BERA,OAE - ABSENT	NORMAL	CONG SNHL	RIGHT CI
38	KEERTHIKA	2Y/F	TM INTACT	BERA,OAE - ABSENT	NORMAL	CONG SNHL	RIGHT CI
39	MOUNISH	2Y/M	TM INTACT	BERA,OAE - ABSENT	NORMAL	CONG SNHL	RIGHT CI
40	JESYLN	3Y/F	TM INTACT	BERA,OAE - ABSENT	NORMAL	CONG SNHL	RIGHT CI
41	MANISHA	4Y/F	TM INTACT	BERA,OAE - ABSENT	NORMAL	CONG SNHL	RIGHT CI
42	HARSHA	2Y/F	TM INTACT	BERA,OAE - ABSENT	NORMAL	CONG SNHL	RIGHT CI
43	MOUSHIKA	3Y/F	TM INTACT	BERA,OAE- ABSENT	NORMAL	CONG SNHL	RIGHT CI
44	FAHATH BASHA	4Y/M	TM INTACT	BERA,OAE - ABSENT	NORMAL	CONG SNHL	RIGHT CI
45	PRATHISH	3Y/M	TM INTACT	BERA,OAE- ABSENT	NORMAL	CONG SNHL	RIGHT CI
46	MAHESH KUMAR	2Y/M	TM INTACT	BERA,OAE - ABSENT	NORMAL	CONG SNHL	RIGHT CI
47	MONISHA	2Y/F	TM INTACT	BERA,OAE- ABSENT	NORMAL	CONG SNHL	RIGHT CI
48	SASIKUMAR	3Y/M	TM INTACT	BERA,OAE- ABSENT	NORMAL	CONG SNHL	RIGHT CI
49	DHARANIVASAN	4Y/M	TM INTACT	BERA,OAE - ABSENT	NARROW SCLEROSED MASTOID	CONG SNHL	RIGHT CI
50	BLESSIMA	3Y/F	TM INTACT	BERA,OAE- ABSENT	NORMAL	CONG SNHL	RIGHT CI
51	MAHALAKSHMI	4Y/F	TM INTACT	BERA,OAE - ABSENT	NARROW SCLEROSED MASTOID	CONG SNHL	RIGHT CI
52	SAHAYA ROHIT	1Y/M	TM INTACT	BERA,OAE - ABSENT	NORMAL	CONG SNHL	RIGHT CI
53	PRIYADHARSHINI	3Y/F	TM INTACT	BERA,OAE - ABSENT	NORMAL	CONG SNHL	RIGHT CI
54	BHAVANI	2Y/F	TM INTACT	BERA,OAE - ABSENT	NORMAL	CONG SNHL	RIGHT CI
55	KAVIYADHARSHINI	4Y/F	TM INTACT	BERA,OAE - ABSENT	NORMAL	CONG SNHL	RIGHT CI
56	VIJAYA KUMAR	3Y/M	TM INTACT	BERA,OAE - ABSENT	SCLEROSED MASTOID	CONG SNHL	RIGHT CI

S. NO	PATIENT NAME	AGE/SEX	CLINICAL FINDINGS	AUDIOLOGICAL	RADIOLOGICAL FINDINGS	DIAGNOSIS	PROCEDURE
57	DHANUSRI DEVI	1Y/F	TM INTACT	BERA,OAE - ABSENT	SCLEROSED MASTOID	CONG SNHL	RIGHT CI
58	JAGADHEESH	4Y/M	TM INTACT	BERA,OAE - ABSENT	SCLEROSED MASTOID	CONG SNHL	RIGHT CI
59	ALAGU JEEVITHA	1Y/F	TM INTACT	BERA,OAE - ABSENT	SCLEROSED MASTOIDS ON BOTH	CONG SNHL	RIGHT CI
60	KARTHIKA	3Y/F	TM INTACT	BERA,OAE - ABSENT	NORMAL	CONG SNHL	RIGHT CI
61	PRATHIKSHA	4Y/F	TM INTACT	BERA,OAE - ABSENT	NORMAL	CONG SNHL	RIGHT CI
62	DEEPIKA	6 Y/ F	TM INTACT	BERA,OAE - ABSENT	BILATERAL OTO MASTOIDITIS	POST MENINGITIC POST	LEFT CI
63	NISHANTH	3Y/M	TM INTACT	BERA,OAE - ABSENT	OBSTRUCTIVE HYDROCEPHALUS	CONG NON SYNDROMIC	RIGHT CI POST VP SHUNT
64	AKSHAYA	3Y/F	TM INTACT	BERA,OAE - ABSENT	MONDINI (IP 2) BOTHSIDES, WITH	CONG SYNDROMIC SNHL	RIGHT CI WITH
65	DIWAKAR	5Y/M	TM INTACT	BERA,OAE - ABSENT	MONDINI (IP2) ON BOTH SIDES,	CONG NON SYNDROMIC	RIGHT CI WITH
66	SHIYASRI	3Y/F	TM INTACT,PRE AURICULAR TAGS	BERA,OAE - ABSENT	RIGHT- MICHEL'S APLASIA, LEFT-	CONG SYNDROMIC SNHL(	LEFT CI WITH COMPRESSED
67	HARSHIKA	3Y/F	TM INTACT	BERA,OAE - ABSENT	RIGHT - MICHEL'S APLASIA,LEFT-	CONG NON SYNDROMIC	LEFT CI WITH COMPRESSED
68	SARATHY	4Y/M	TM INTACT	BERA,OAE - ABSENT	BILATERAL COMMON CAVITY	CONG NON SYNDROMIC	RIGHT CI WITH
69	MOHAMMED FOUZAN	4Y/M	TM INTACT	BERA,OAE - ABSENT	BILATERAL HYPOPLASTIC	CONG NON SYNDROMIC	RIGHT CI WITH
70	ABDUL RAHMAN	3Y/M	TM INTACT	BERA,OAE - ABSENT	NORMAL COCHLEA WITH	CONG SYNDROMIC	REFERRED TO HIGHER
71	ASWIN	6Y/M	IMPLANT INSITU	IMPEDENCE HIGH IN ALL	IMPLANT INSITU	POST RIGHT COCHLEAR	DEVICE EXPLANTATION
72	NARESH	2Y/M	IMPLANT INSITU	IMPEDENCE HIGH IN > 8	IMPLANT INSITU	POST RIGHT CI HARD	DEVICE EXPLANTATION
73	MANIKANDAN	6Y/M	IMPLANT INSITU, TM RETRACTED AND	IMPEDENCE HIGH IN ALL	IMPLANT INSITU	POST RIGHT CI HARD	DEVICE EXPLANTATION
74	HARSHAVARDHINI	4Y/F	IMPLANT INSITU	IMPEDENCE HIGH IN	IMPLANT INSITU	POST RIGHT CI HARD	EXPLANTATION AND
75	SOPHIKA	6Y/F	IMPLANT INSITU, TM CONGESTED AND	IMPEDENCE NORMAL	IMPLANT INSITU	POST COCHLEAR IMPLANT	CONSERVATIVE
76	RAJESH	2Y/M	IMPLANT INSITU, TM CONGESTED AND	IMPEDENCE NORMAL	IMPLANT INSITU	POST RIGHT CI OTITIS	CONSERVATIVE
77	RAKSHITHA	3Y/F	IMPLANT INSITU, TM CONGESTED	IMPEDENCE NORMAL	IMPLANT INSITU	POST RIGHT CI OTITIS	CONSERVATIVE

S. NO	INTRA-OPERATIVE	POST-OPERATIVE	DOS	DATE OF SWITCH ON	TOTAL	SPEECH RESPONSE	CHALLENGE ENCOUNTERED	MAJOR/MI
1	GLUE AND BLEEDING NOTED	IMPLANT INSITU	06/09/2016	06/10/2016	52	WORD RECOGNITION	PRE-OPERATIVE SECRETORY OTITIS MEDIA	MINOR
2	THICK GLUE,BRISK BLEEDING	IMPLANT INSITU	08/11/2016	24/11/2016	48	WORD RECOGNITION PRESENT	PRE-OPERATIVE SECRETORY OTITIS MEDIA	MINOR
3	GLUE AND BLEEDING NOTED	IMPLANT INSITU	08/08/2017	24/08/2017	35	WORD RECOGNITION PRESENT	PRE-OPERATIVE SOM	MINOR
4	RW INSERTION	IMPLANT INSITU	27/03/2018	02/05/2018	14	SOUND AWARENESS - PRESENT	CSOM & SNHL	MINOR
5	FACIAL NERVE SHEATH EXPOSED	HB 3 PALSY,WOUND	27/08/2018	19/09/2018	5	SOUND AWARENESS PRESENT	INTRA OP FACIAL NERVE SHEATH	MINOR
6	RW INSERTION	WOUND INFECTION	31/10/2016 - 09/05/2017	07/06/2017	40	SOUND AWARENESS PRESENT	WOUND INFECTION	MAJOR
7	IMPLANT INSITU	IMPLANT INSITU	14/07/2016	28/07/2016	55	WORD RECOGNITION - PRESENT	POST-OPERATIVE WOUND GAPING	MAJOR
8	IMPLANT INSITU	IMPLANT INSITU	05/05/2015 - 05/06/2016	03/06/2015	60	WORD RECOGNITION PRESENT	POST OP - WOUND GAPING	MAJOR
9	IMPLANT INSITU	IMPLANT INSITU	30/11/2016	25/01/2017	56	WORD RECOGNITION PRESENT	POST OP - SEROMA	MINOR
10	EMISSARY VEIN BLEEDING	IMPLANT INSITU	20/12/2016	12/01/2017	53	WORD RECOGNITION PRESENT	INTRA OP - EMISSARY VEIN BLEEDING	MINOR
11	EMISSARY VEIN BLEEDING	IMPLANT INSITU	21/09/2016	06/10/2016	60	WORD RECOGNITION PRESENT	INTRA OP- EMISSARY VEIN BLEEDING	MINOR
12	EMISSARY VEIN BLEEDING	IMPLANT INSITU	07/01/2017	24/01/2017	45	WORD RECOGNITION PRESENT	INTRA OP - EMISSARY VEIN BLEEDING	MINOR
13	EMISSARY VEIN BLEEDING	IMPLANT INSITU	10/01/2017	27/01/2017	60	WORD RECOGNITION PRESENT	INTRA OP - EMISSARY VEIN BLEEDING	MINOR
14	EMISSARY VEIN BLEEDING	IMPLANT INSITU	12/06/2017	29/06/2017	45	WORD RECOGNITION PRESENT	INTRA-OP EMISSARY VEIN BLEEDING	MINOR
15	EMISSARY VEIN BLEEDING	IMPLANT INSITU	23/05/2017	14/06/2017	45	WORD RECOGNITION PRESENT	INTRA OPERATIVE EMISSARY VEIN BLEEDING	MINOR
16	EMISSARY VEIN BLEEDING	IMPLANT INSITU	19/04/2017	09/05/2017	55	WORD RECOGNITION PRESENT	EMISSARY VEIN BLEEDING	MINOR
17	EMISSARY VEIN BLEEDING	IMPLANT INSITU	20/04/2017	09/05/2017	65	WORD RECOGNITION PRESENT	EMISSARY VEIN BLEEDING	MINOR
18	EMISSARY VEIN BLEEDING	IMPLANT INSITU	15/05/2017	15/05/2017	54	WORD RECOGNITION PRESENT	INTRA-OP EMISSARY VEIN BLEEDING	MINOR
19	EMISSARY VEIN BLEEDING	IMPLANT INSITU	05/12/2017	29/12/2017	35	WORD RECOGNITION PRESENT	INTRA OP- EMISSARY VEIN BLEEDING	MINOR
20	EDEMATOUS MIDDLE EAR MUCOSA	IMPLANT INSITU	10/05/2017	31/05/2017	45	WORD RECOGNITION PRESENT	INTRA OP - EDEMATOUS MIDDLE EAR MUCOSA	MINOR
21	EDEMATOUS MIDDLE EAR MUCOSA	IMPLANT INSITU	02/12/2017	28/12/2017	25	SOUND AWARENESS PRESENT	INTRA OP - EDEMATOUS MIDDLE EAR MUCOSA	MINOR
22	EDEMATOUS ME MUCOSA	IMPLANT INSITU	02/04/2018	27/04/2018	18	SOUND AWARENESS PRESENT	INTRA OP- EDEMATOUS ME MUCOSA	MINOR
23	EDEMATOUS ME MUCOSA	IMPLANT INSITU	11/12/2017	29/12/2017	32	WORD RECOGNITION PRESENT	INTRA OP- EDEMATOUS ME MUCOSA	MINOR
24	EDEMATOUS ME MUCOSA	IMPLANT INSITU	15/06/2016	01/07/2016	55	WORD RECOGNITION PRESENT	INTRA OP - EDEMATOUS ME MUCOSA	MINOR
25	CSF GUSHER	IMPLANT INSITU	12/06/2018	29/06/2018	12	SOUND AWARENESS PRESENT	INTRA OP - CSF GUSHER	MINOR
26	CSF LEAK WHILE DRILLING FOR	IMPLANT INSITU	01/06/2017	29/06/2017	45	WORD RECOGNITION PRESENT	INTRA OP - CSF LEAK WHILE DRILLING RS	MINOR
27	CSF LEAK WHILE DRILLING RS FIXATION	IMPLANT INSITU	29/05/2017	22/06/2017	36	WORD RECOGNISION PRESENT	INTRA OP CSF LEAK WHILE DRILLING RS	MINOR
28	CSF LEAK WHILE DRILLING RS FIXATION	IMPLANT INSITU	05/02/2018	27/02/2018	28	SOUND RECOGNITION PRESENT	INTRA OP CSF LEAK WHILW DRILLING RS	MINOR
29	PERILYMPH GUSHER	IMPLANT INSITU	14/07/2017	21/08/2017	60	WORD RECOGNITION PRESENT	INTRA OP - PERILYMPH GUSHER	MINOR
30	CHORDAE TYMPANI INJURY	IMPLANT INSITU	19/12/2017	10/01/2018	28	WORD RECOGNITION PRESENT	INTRA OP - CHORDAE TYMPANI NERVE INJURY	MINOR
31	CHORDAE TYMPANI INJURY	IMPLANT INSITU	17/02/2018	28/02/2018	26	SOUND RECOGNITION PRESENT	INTRA OP CHORDAE TYMPANI INJURY	MINOR
32	CHORDAE TYMPANI INJURY	IMPLANT INSITU	19/12/2017	10/01/2018	36	WORD RECOGNITION PRESENT	INTRA OP - CHORDAE TYMPANI NERVE INJURY	MINOR
33	INJURY TO CHORDAE TYMPANI NERVE	IMPLANT INSITU	27/07/2017	23/08/2017	58	WORD RECOGNITION PRESENT	INTRA OP CHORDAE TYMPANI NERVE INJURY	MINOR
34	CHORDAE TYMPANI INJURY	IMPLANT INSITU	22/06/2016	15/07/2016	68	WORD RECOGNITION PRESENT	INTRA OP CHORDAE TYMPANI INJURY	MINOR
35	CHORDAE TYMPANI INJURY	IMPLANT INSITU	27/08/2016	22/09/2016	55	WORD RECOGNITION PRESENT	INTRA OP CHORDAE TYMPANI INJURY PRESENT	MINOR
36	CHORDAE TYMPANI INJURY	IMPLANT INSITU	25/08/2016	23/08/2016	69	WORD RECOGNITION PRESENT	INTRA OP CHORDAE TYMPANI NERVE INJURY	MINOR
37	INJURY TO CHORDAE TYMPANI	IMPLANT INSITU	24/11/2016	20/12/2016	70	WORD RECOGNITION PRESENT	INTRA OP CHORDAE TYMPANI INJURY	MINOR
38	INJURY TO CHORDAE TYMPANI	IMPLANT INSITU	20/10/2016	17/11/2016	78	WORD RECOGNITION PRESENT	INTRA OP CHORDAE TYMPANI NERVE INJURY	MINOR
39	INJURY TO CHORDAE TYMPANI	IMPLANT INSITU	02/08/2016	08/09/2016	78	WORD RECOGNITION PRESENT	INTRA OP CHORDAE TYMPANI NERVE INJURY	MINOR
40	INJURY TO CHORDAE TYMPANI	IMPLANT INSITU	18/07/2016	16/08/2016	80	WORD RECOGNITION PRESENT	INTRA OP CHORDAE TYMPANI NERVE INJURY	MINOR
41	INJURY TO CHORDAE TYMPANI	IMPLANT INSITU	03/08/2016	31/08/2016	66	WORD RECOGNISION PRESENT	INTRA OP CHORDAE TYMPANI NERVE INJURY	MINOR
42	INJURY TO CHORDAE TYMPANI	IMPLANT INSITU	30/08/2016	29/08/2016	56	WORD RECOGNITION PRESENT	INTRA OP CHORDAE TYMPANI NERVE INJURY	MINOR
43	INJURY TO CHORDAE TYMPANI	IMPLANT INSITU	23/08/2016	22/09/2016	68	WORD RECOGNITION PRESENT	INTRA OP CHORDAE TYMPANI NERVE INJURY	MINOR
44	INJURY TO CHORDAE TYMPANI	IMPLANT INSITU	15/07/2017	17/08/2017	50	WORD RECOGNITION PRESENT	INTRA OP CHORDAE TYMPANI NERVE INJURY	MINOR
45	POST CANAL WALL AND TYMPANIC	IMPLANT	11/12/2017	12/01/2018	35	WORD RECOGNITION PRESENT	INTRA OP INJURY TO POSTERIOR CANAL WALL	MINOR
46	POSTERIOR CANAL WALL INJURY	IMPLANT INSITU	20/12/2017	19/01/2018	39	WORD RECOGNITION PRESENT	INTRA OP POSTERIOR CANAL WALL INJURY	MINOR
47	INJURY TO POSTERIOR CANAL WALL	IMPLANT	13/03/2018	11/04/2018	30	SOUND AWARENESS PRESENT	INTRA OP POSTERIOR CANAL WALL INJURY	MINOR
48	INJURY TO POSTERIOR CANAL WALL	IMPLANT INSITU	25/01/2018	22/02/2018	38	WORD RECOGNITION PRESENT	INTRA OP POSTERIOR CANAL WALL INJURY	MINOR
49	INJURY TO POSTERIOR CANAL WALL	IMPLANT INSITU	06/09/2016	05/10/2016	70	WORD RECOGNITION PRESENT	INTRA OP POSTERIOR CANAL WALL INJURY	MINOR
50	INJURY TO STAPES SUPRA STRUCTURE	IMPLANT INSITU	17/07/2018	09/08/2018	8	SOUND AWARENESS PRESENT	INTRA OPERATIVE INJURY TO STAPES SUPRA	MINOR
51	THERMAL INJURY TO FACIAL NERVE	IMPLANT INSITU,HB 3	25/10/2016	24/11/2016	45	WORD RECOGNITION PRESENT	INTRA OP THERMAL INJURY TO FACIAL NERVE	MINOR
52	THERMAL INJURY TO FACIAL NERVE	IMPLANT INSITU, HB	16/12/2016	06/01/2017	58	WORD RECOGNITION PRESENT	INTRA OPERATIVE THERMAL INJURY TO	MINOR
53	THERMAL INJURY TO FACIAL NERVE	IMPLANT INSITU, HB	11/10/2016	15/11/2016	68	WORD RECOGNITION PRESENT	INTRA OPERATIVE THERMAL INJURY TO	MINOR
54	THERMAL INJURY TO FACIAL NERVE	IMPLANT INSITU,HB	16/11/2016	14/11/2016	78	WORD RECOGNITION PRESENT	INTRA OPERATIVE THERMAL INJURY TO	MINOR
55	THERMAL INJURY TO FACIAL NERVE	IMPLANT INSITU, HB	09/11/2016	07/12/2016	80	WORD RECOGNITION PRESENT	INTRA OPERATIVE THERMAL INJURY TO	MINOR
56	FACIAL NERVE SHEATH EXPOSED	IMPLANT INSITU,HB	28/09/2016	02/11/2016	68	WORD RECOGNITION PRESENT	INTRA OPERATIVE FACIAL NERVE SHEATH	MINOR

S. NO	INTRA-OPERATIVE	POST-OPERATIVE	DOS	DATE OF SWITCH ON	TOTAL	SPEECH RESPONSE	CHALLENGE ENCOUNTERED	MAJOR/MI
57	FACIAL NERVE SHEATH EXPOSED	IMPLANT INSITU			25	SOUND AWARENESS PRESENT	INTRA OPERATIVE FACIAL NERVE SHEATH	MINOR
58	ANOMALOUS FACIAL NERVE - PROPABLY	IMPLANT INSITU	05/09/2016	04/10/2016	15	LOST FOLLOW-UP	INTRA OPERATIVE ANOMALOUS FACIAL NERVE	MINOR
59	DIFFICULTY IN ID OF RW -	IMPLANT INSITU	23/09/2016	28/10/2016	10	LOST FOLLOWUP	INTRA OPERATIVE DIFFICULTY IN RW ID -	MINOR
60	DIFFICULTY IN RW ID - COCHLEOSTOMY	IMPLANT INSITU,	02/11/2016	08/12/2016	80	WORD RECOGNITION PRESENT	INTRA OP - DIFFICULTY IN ID OF RW -	MINOR
61	DIFFICULTY IN INSERTION OF	IMPLANT INSITU	12/09/2016	19/10/2016	82	WORD RECOGNITION PRESENT	INTRA OP - DIFFICULTY IN INSERTION OF	MINOR
62	LABYRINTHITIS OSSIFANS,DIFFICULTY IN	IMPLANT INSITU	10/12/2016 - 07/02/2017	16/03/2017	68	WORD RECOGNITION PRESENT	INTRA OPERATIVE LABYRINTHITIS OSSIFICANS,	MAJOR
63	RW INSERTION OF NORMAL ELECTRODES	IMPLANT AND VP	19/07/2017	17/07/2017	55	WORD RECOGNISION PRESENT	INTRA OPERATIVE CAUTERY USAGE AVOIDED	MINOR
64	RW INSERTION OF COMPRESSED	IMPLANT INSITU	25/10/2016	24/11/2016	78	SOUND AWARENESS PRESENT	PRE OPERATIVE ANOMALOUS COCHLEA	MINOR
65	RW INSERTION OF COMPRESSED	IMPLANT INSITU	13/02/2018	14/03/2018	25	SOUND AWARENESS PRESENT	PRE OPERATIVE ANOMALOUS COCHLEA	MINOR
66	RW INSERTION OF COMPRESSED	IMPLANT INSITU	03/04/2018	04/05/2018	12	SOUND AWARENESS PRESENT	PREOPERATIVE ANOMALOUS COCHLEA	MINOR
67	RW INSERTION OF COMPRESSED	IMPLANT INSITU	02/04/2018	09/05/2018	18	SOUND AWARENESS PRESENT	PRE OPERATIVE ANOMALOUS COCHLEA	MINOR
68	LATERAL SEMI CIRCULAR CANAL	IMPLANT INSITU	18/10/2016	17/11/2016	40	SOUND AWARENESS PRESENT	PREOPERATIVE ANOMALOUS COCHLEA	MINOR
69	RW INSERTION OF FORM 24 ELECTRODES	IMPLANT INSITU	18/06/2018	18/07/2018	8	SOUND AWARENESS PRESENT ON	PRE OPERATIVE ANOMALOUS COCHLEA	MINOR
70							PREOPERATIVE ANOMALOUS COCHLEA	MINOR
71	ELECTRODES BROKEN	IMPLANT INSITU	27/03/2015 - 05/08/2017	23/04/2015 - 30/08/2017	62, 45	WORD RECOGNITION PRESENT	POST OPERATIVE DEVICE FAILURE	MAJOR
72	ELECTRODE BROKEN	PARENTS NOT					POST OPERATIVE HARD DEVICE FAILURE	MAJOR
73	IMPLANT AND ELECTRODE CONTINUITY	IMPLANT INSITU	14/05/2016 - 07/06/2018	29/06/2016 - 05/07/2018	65- 12	WORD RECOGNITION PRESENT	POST OP - HARD DEVICE FAILURE, POST OP	MAJOR
74	ELECTRODE DISCONTINUITY NOTED	IMPLANT INSITU	19/03/2014 - 06/08/2018	15/04/2014- 05/09/2018	80 - 4	WORD RECOGNITION PRESENT	POST OPERATIVE HARD DEVICE FAILURE	MAJOR
75		IMPLANT INSITU	14/06/2016	06/07/2016	55	WORD RECOGNITION PRESENT	POST OPERATIVE OTITIS MEDIA	MINOR
76			22/08/2016	14/08/2016	70	WORD RECOGNITION PRESENT	POST OPERATIVE OTITIS MEDIA	MINOR
77			06/07/2017	18/08/2017	57	WORD RECOGNITION PRESENT	POST OPERATIVE OTITIS MEDIA	MINOR

URKUND

Urkund Analysis Result

Analysed Document: plagarism upload.docx (D42765399)
Submitted: 10/19/2018 10:44:00 AM
Submitted By: kalaisathyasri@gmail.com
Significance: 6 %

Sources included in the report:

Kalaimani FINAL DISSERTATION - Copy.docx (D31547851)
Dr Mahesh kumari dissertation plagiarism check.docx (D31339112)
Sengottuvelu Dissertation.doc (D32544752)
https://en.wikipedia.org/wiki/Cochlear_implant

Instances where selected sources appear:

27